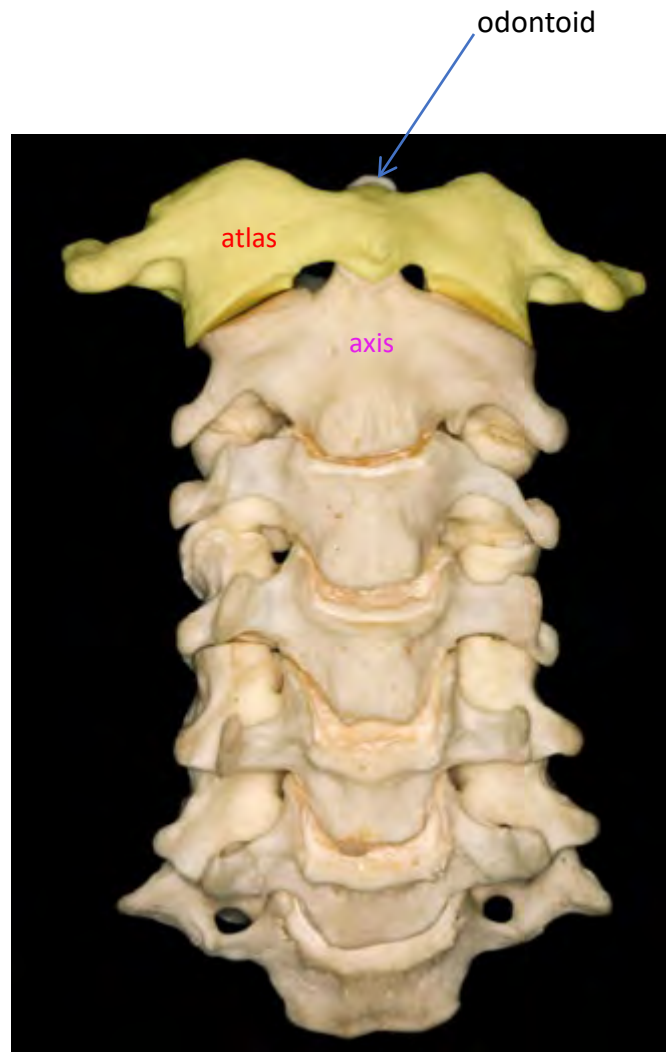

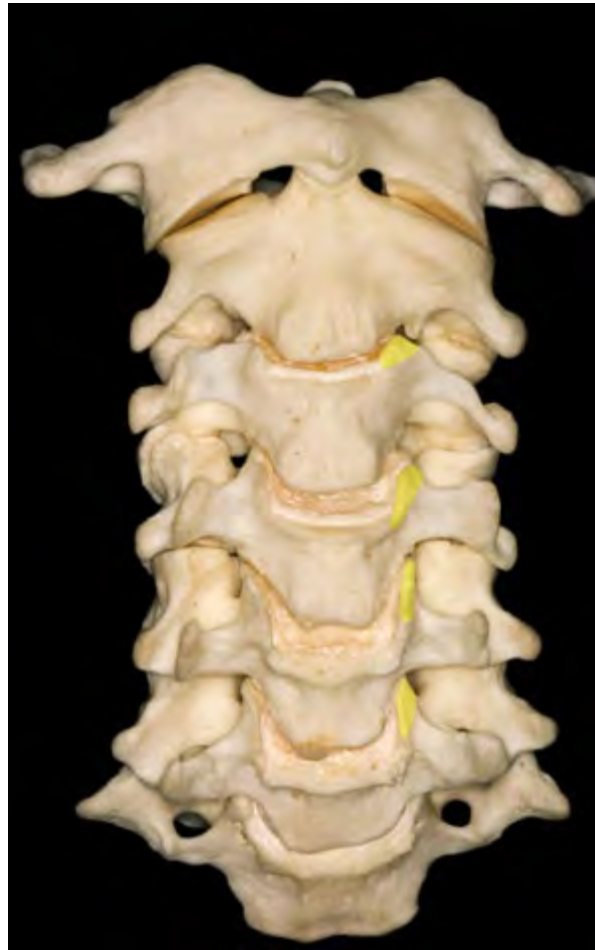# Review: Rhoton Top 100

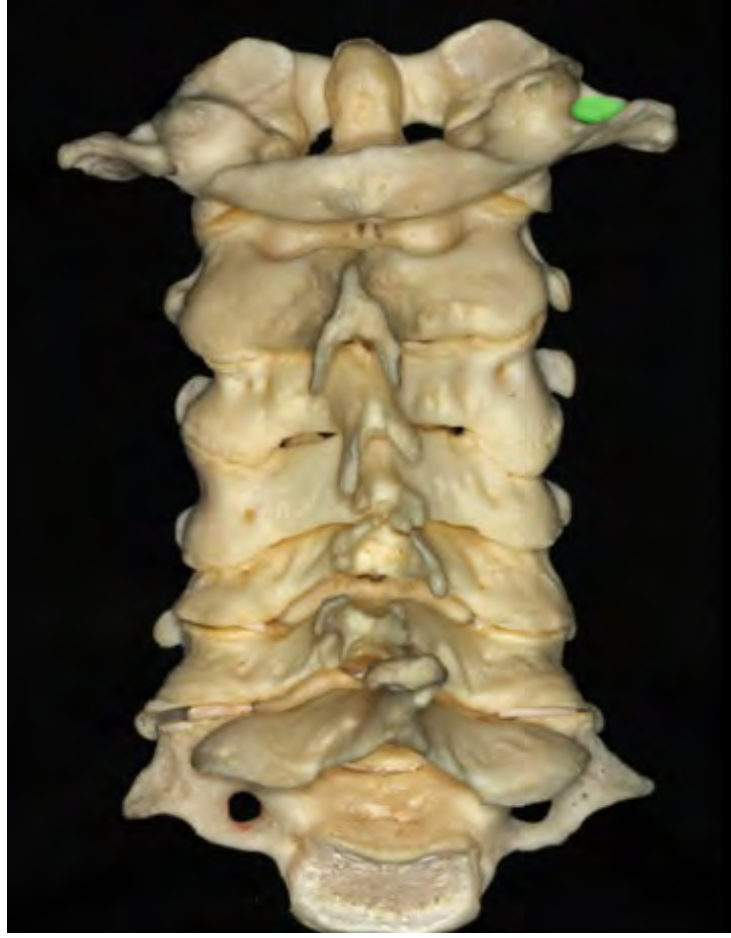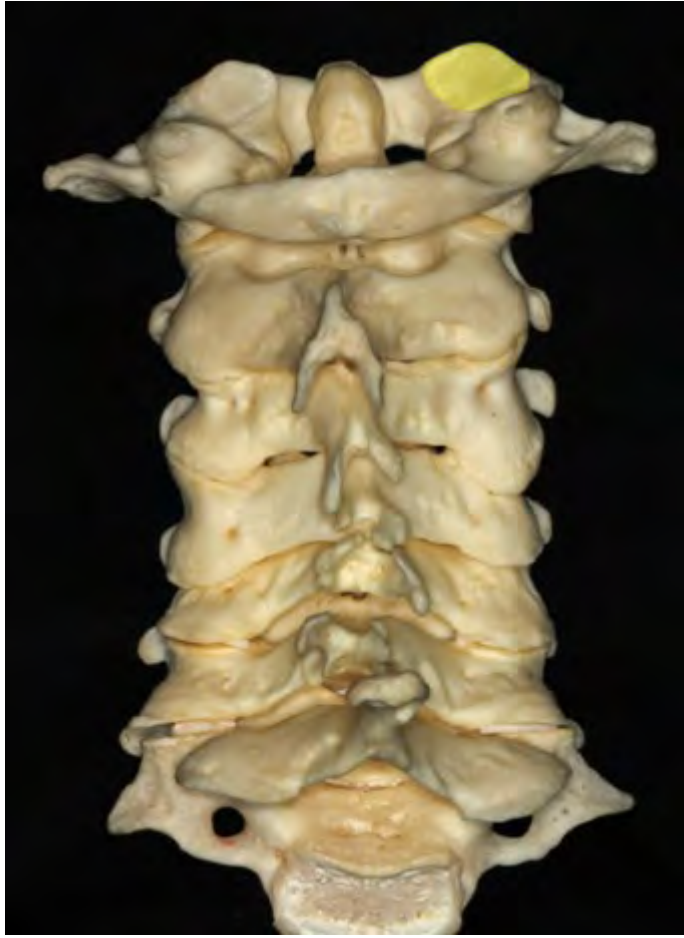## Acknowledgements:

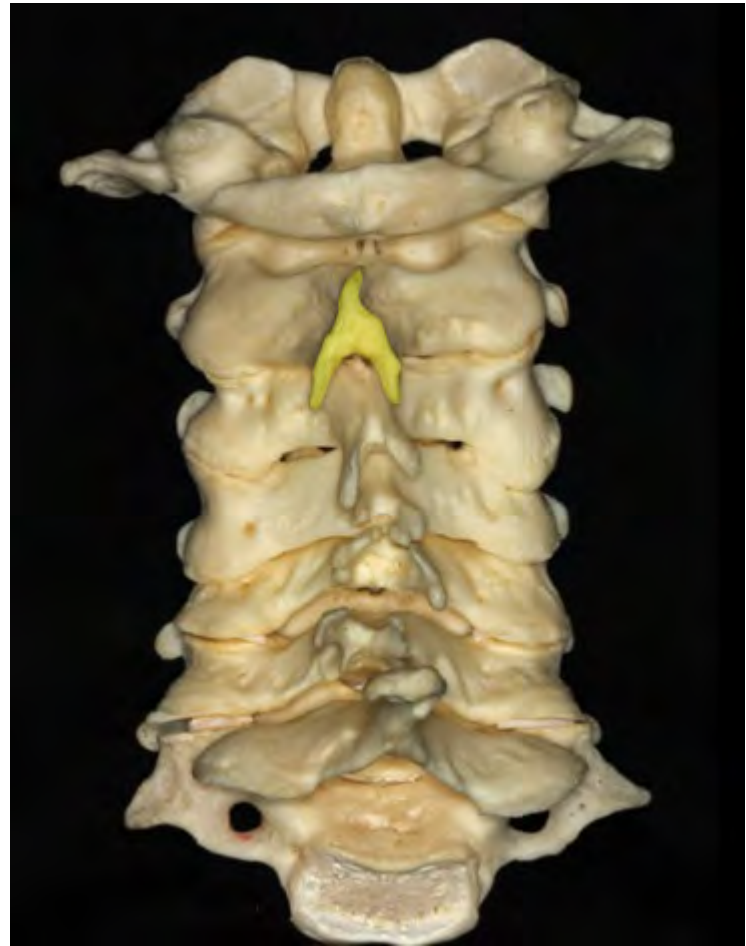
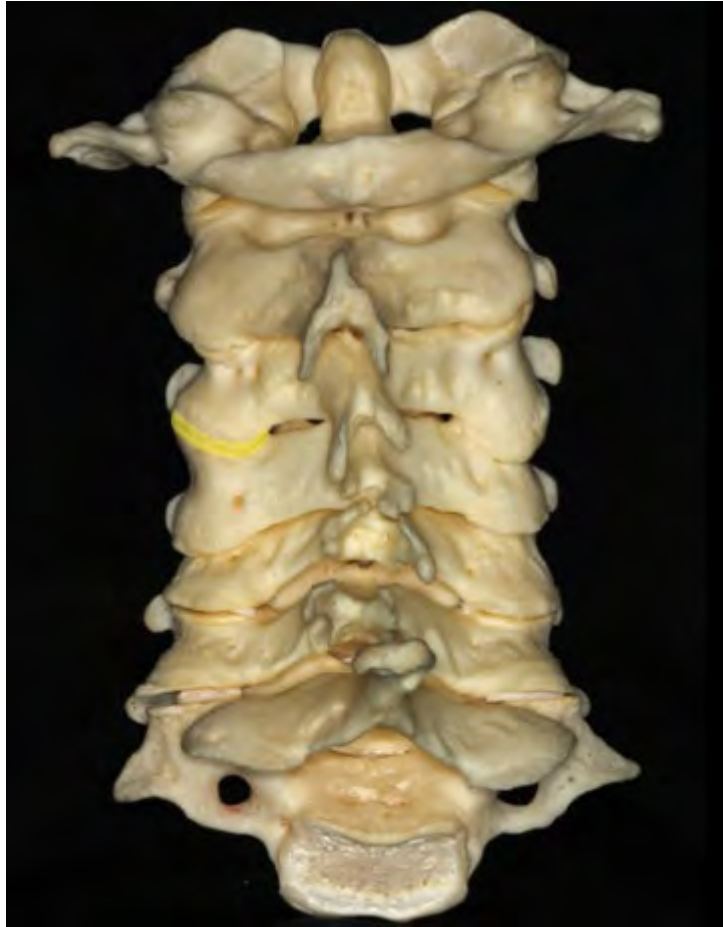The material in this presentation compiled by Kristen Scheitler MD, Mayo Clinic, and derived from The Rhoton Collection®

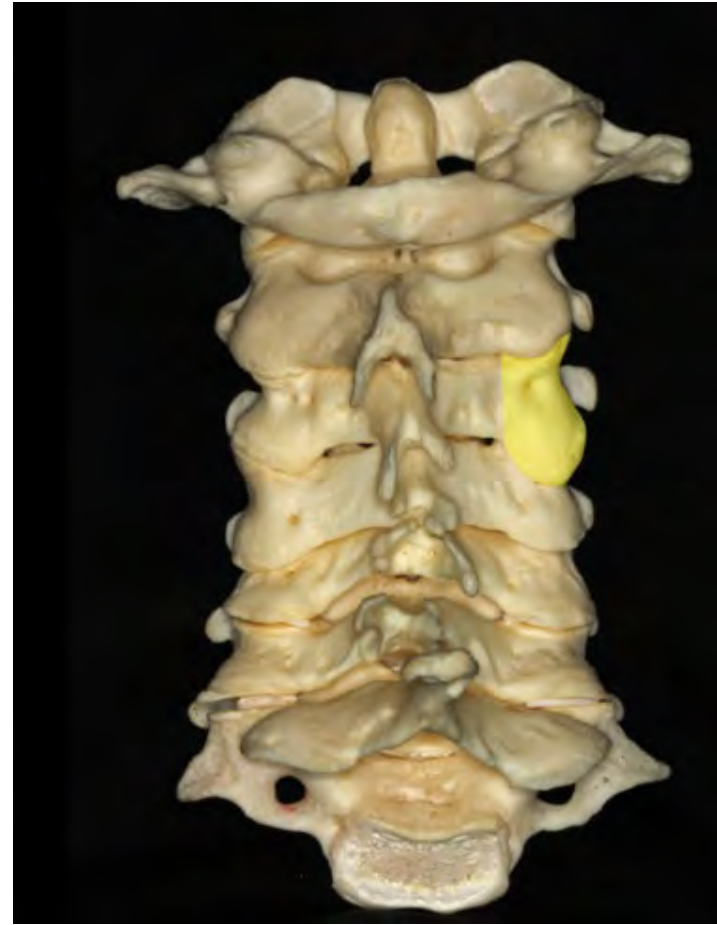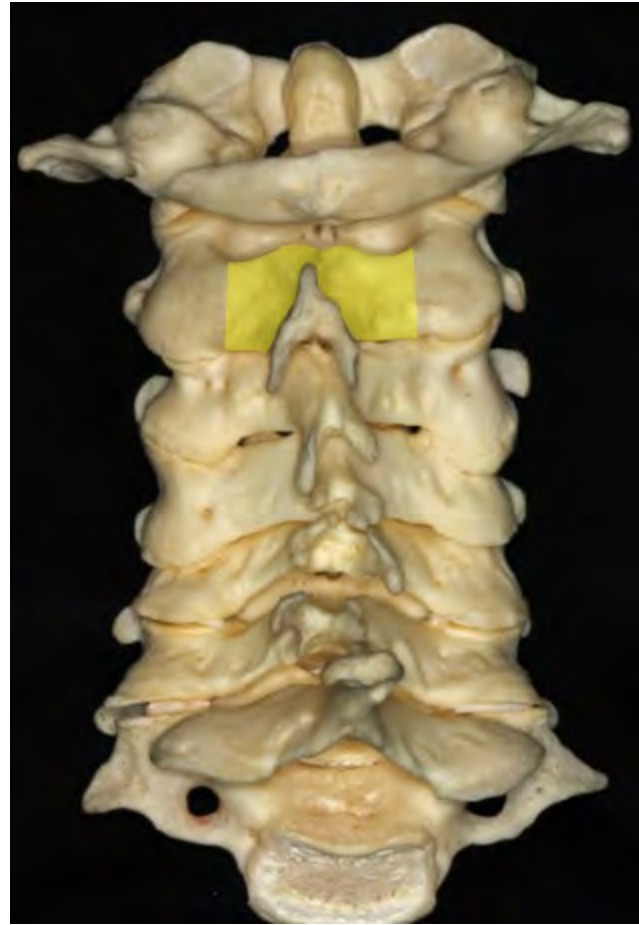
Those wishing to support access to and expansion of the The Rhoton Collection® can make a tax deductible donation to NREF Albert L. Rhoton Fund

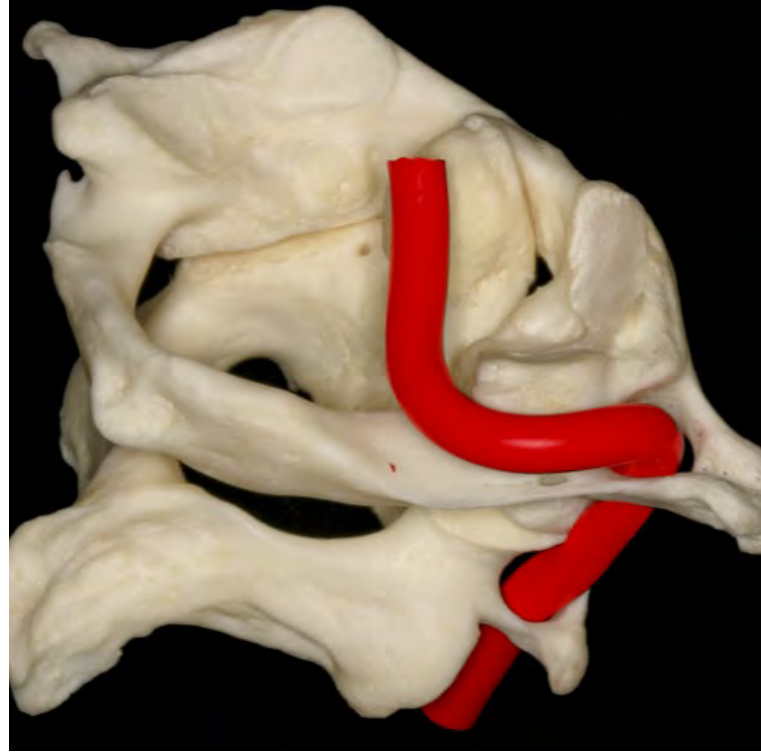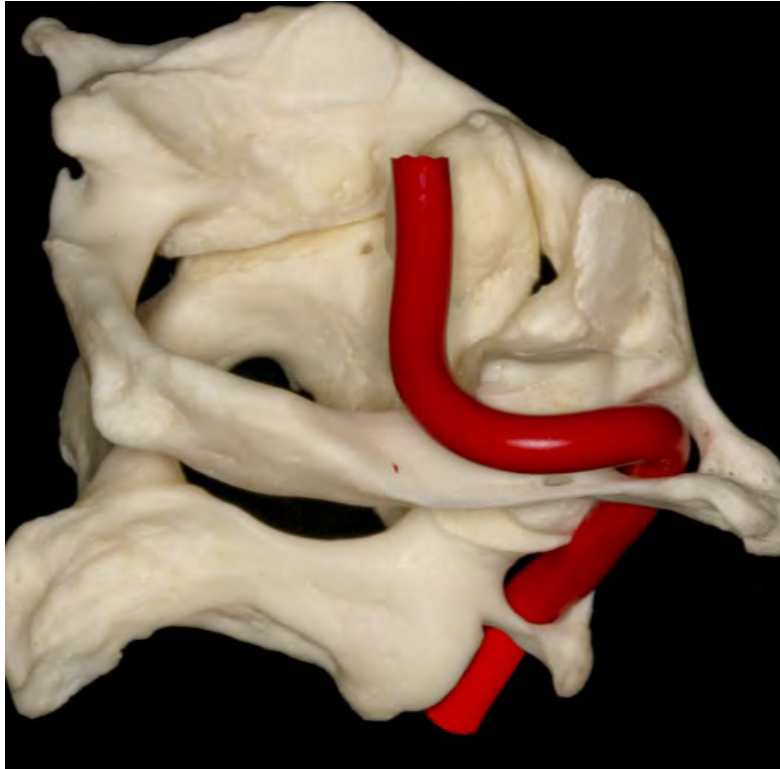



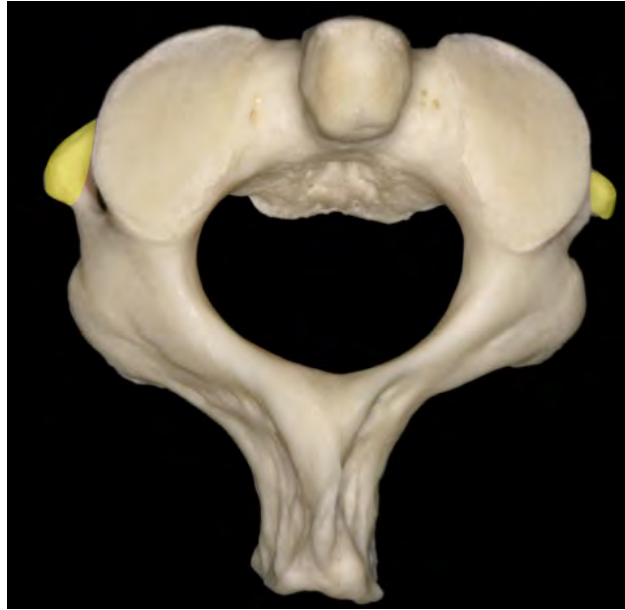
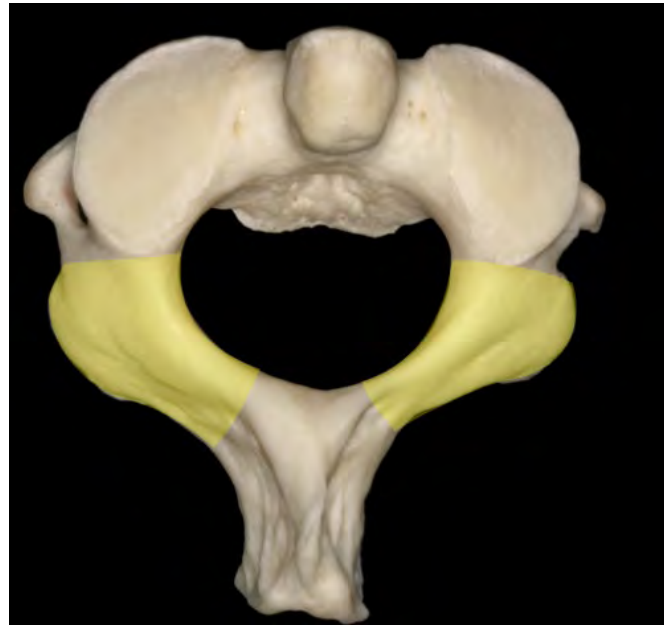
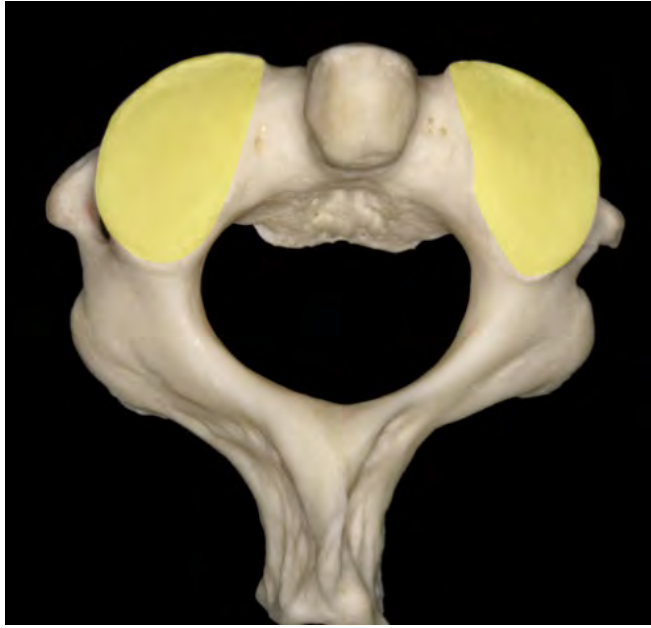
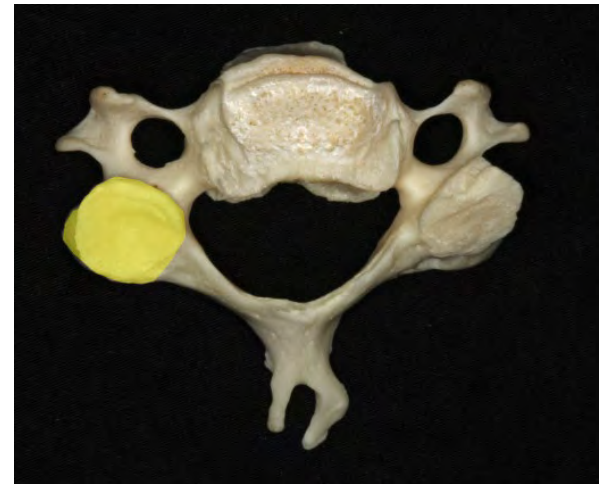
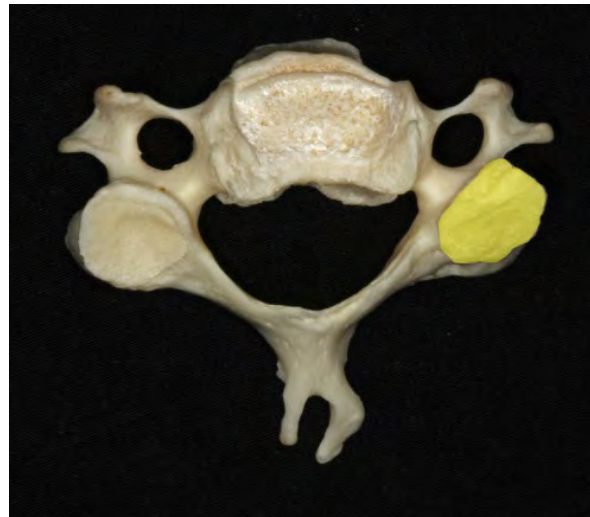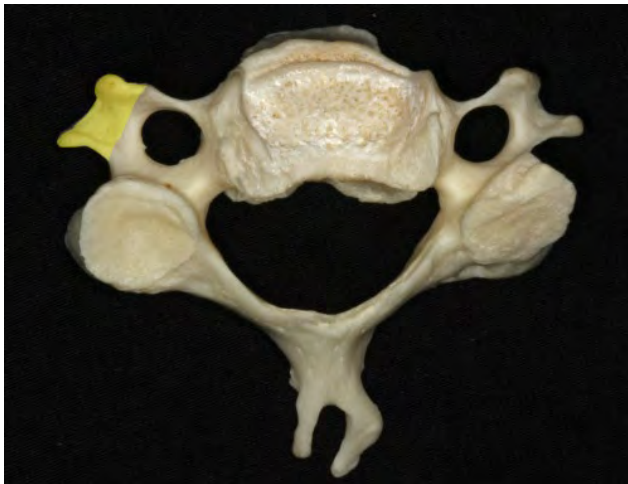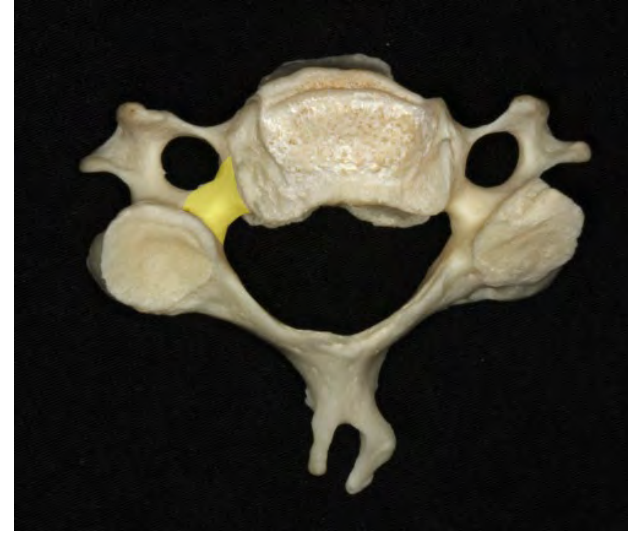
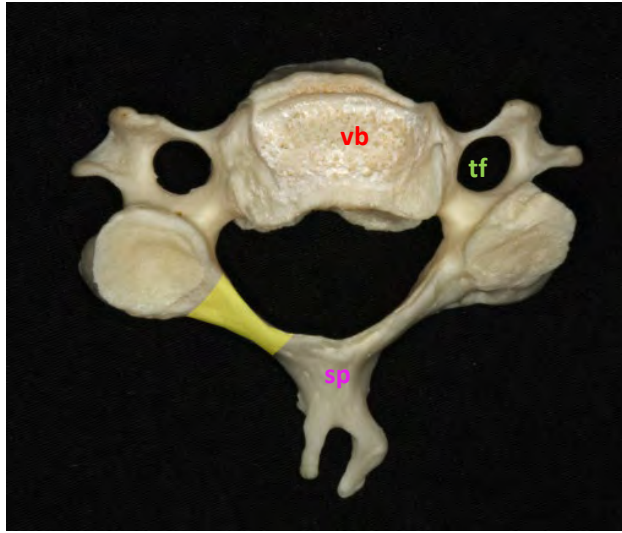




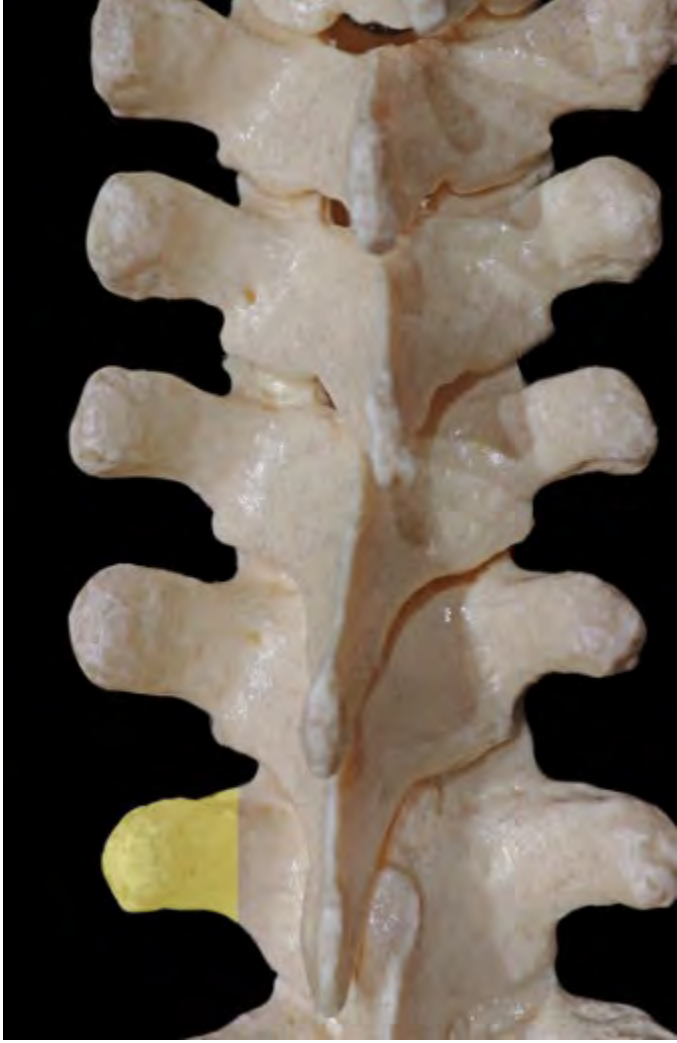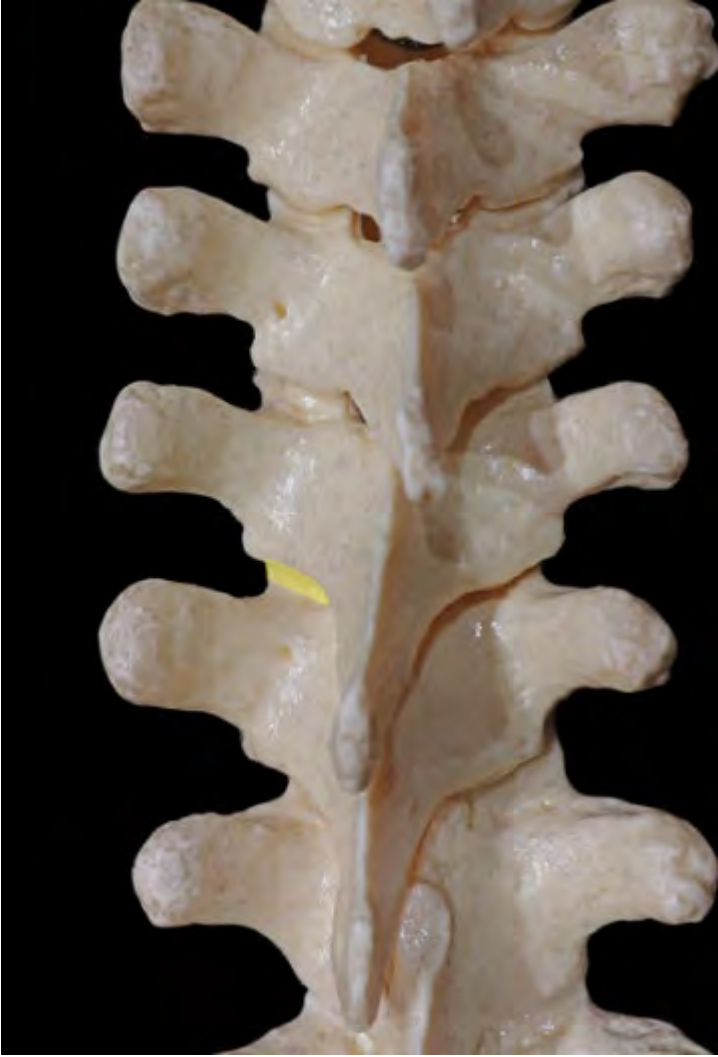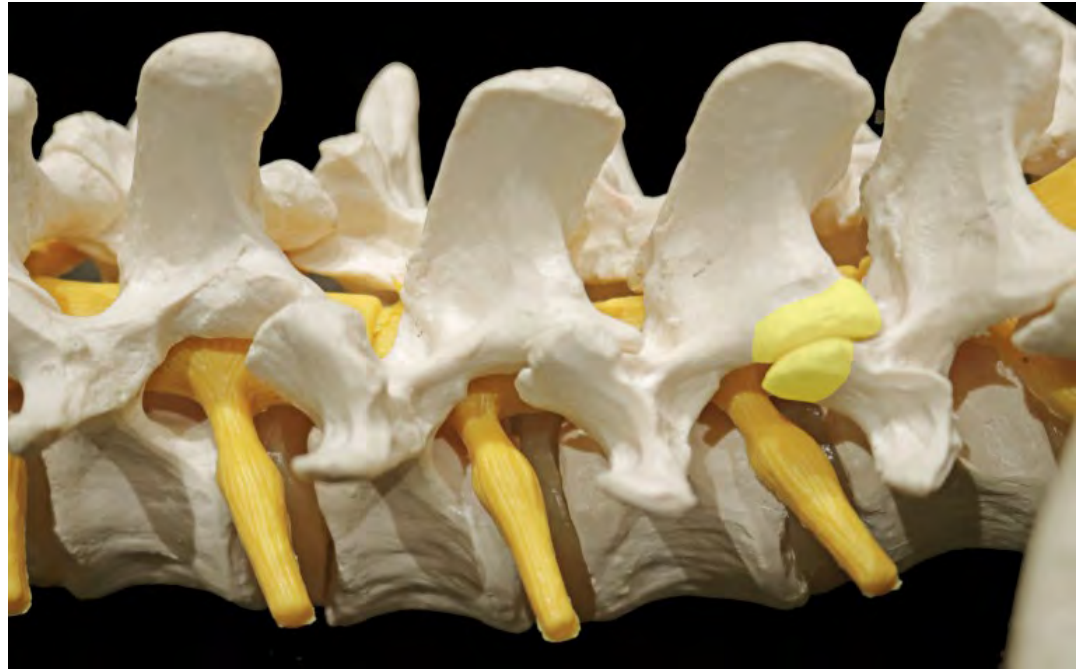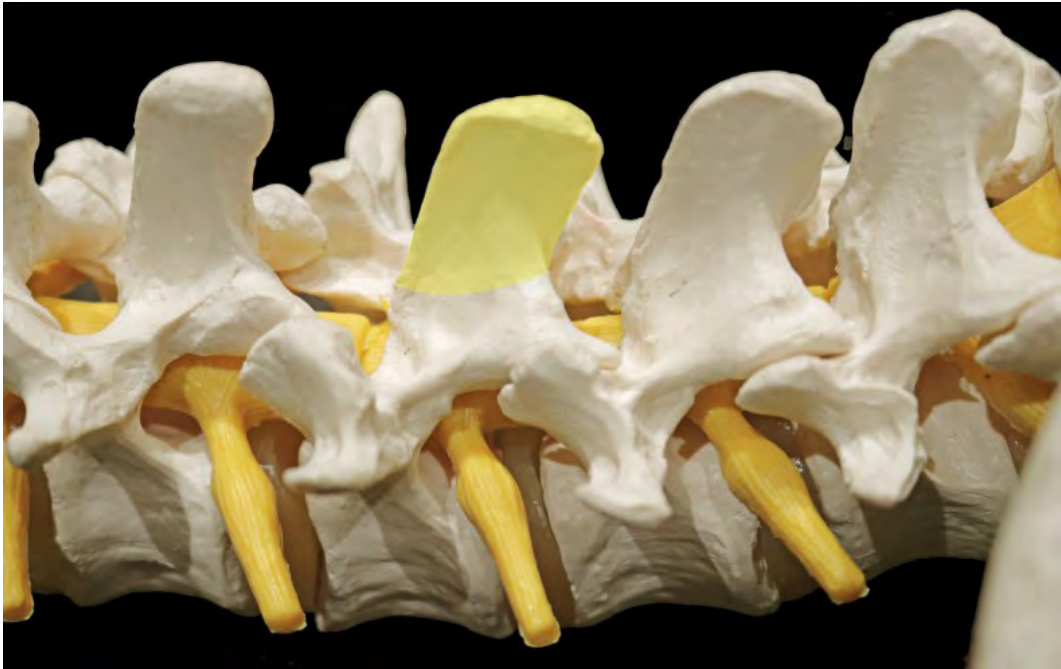






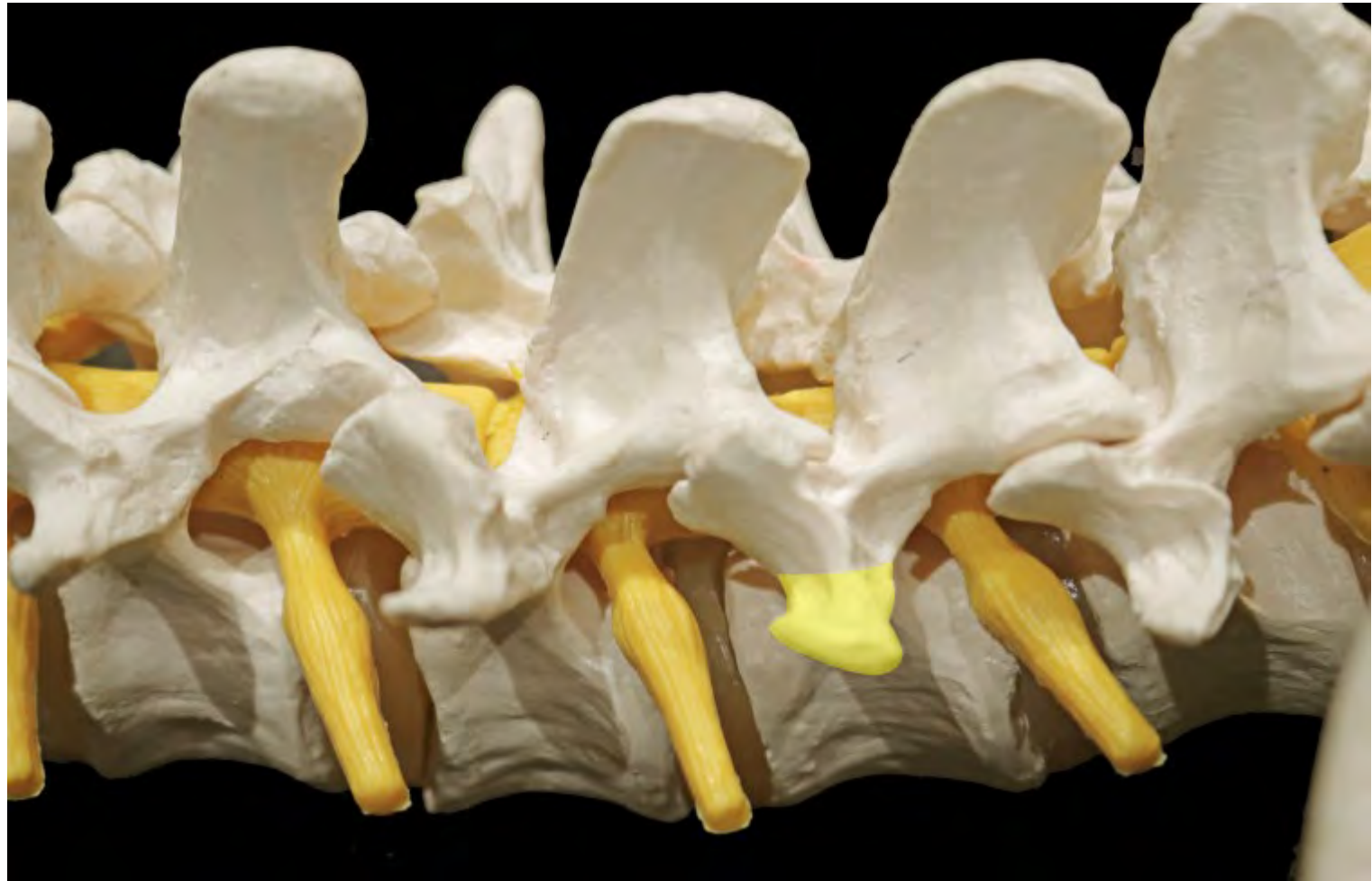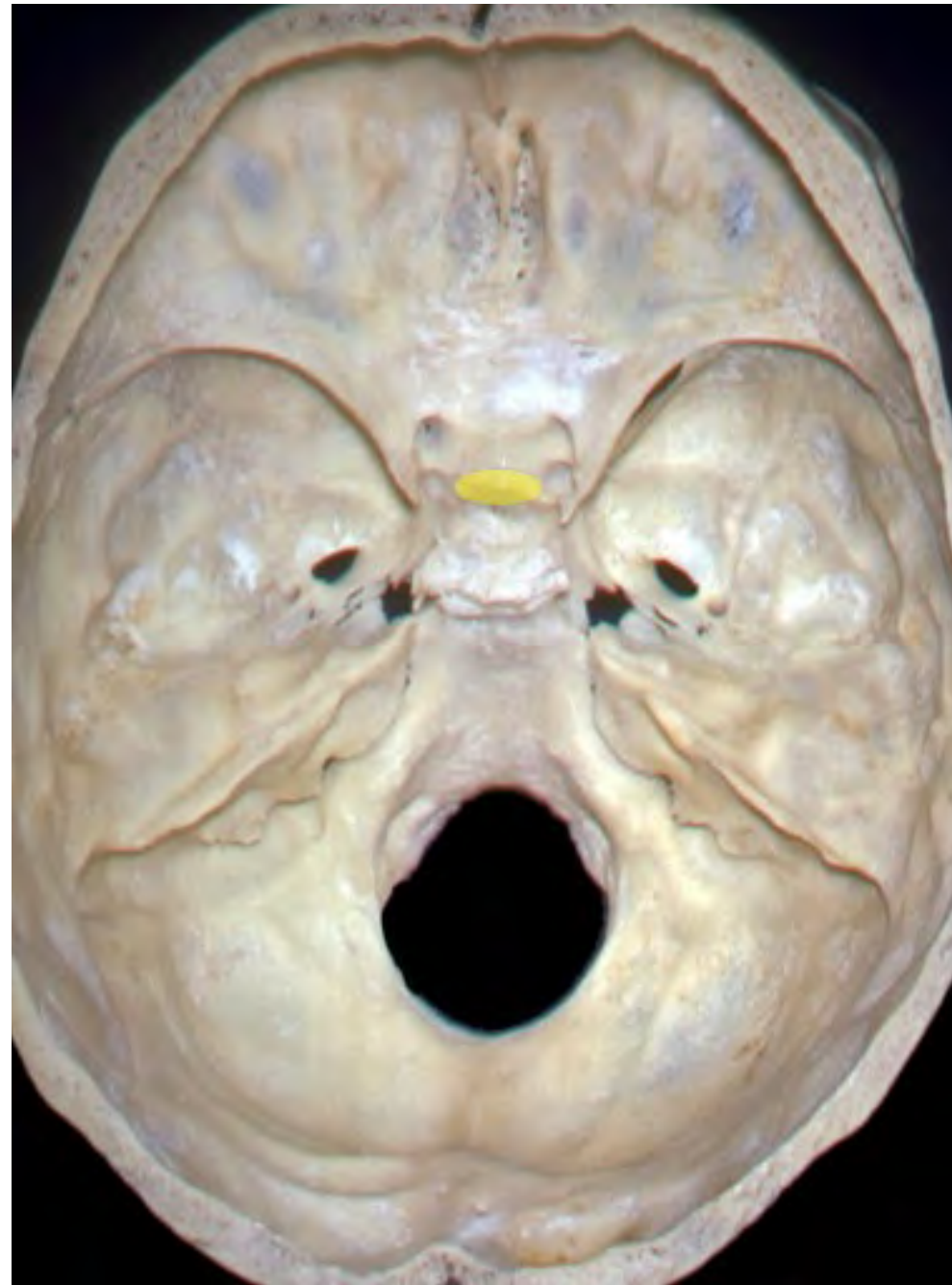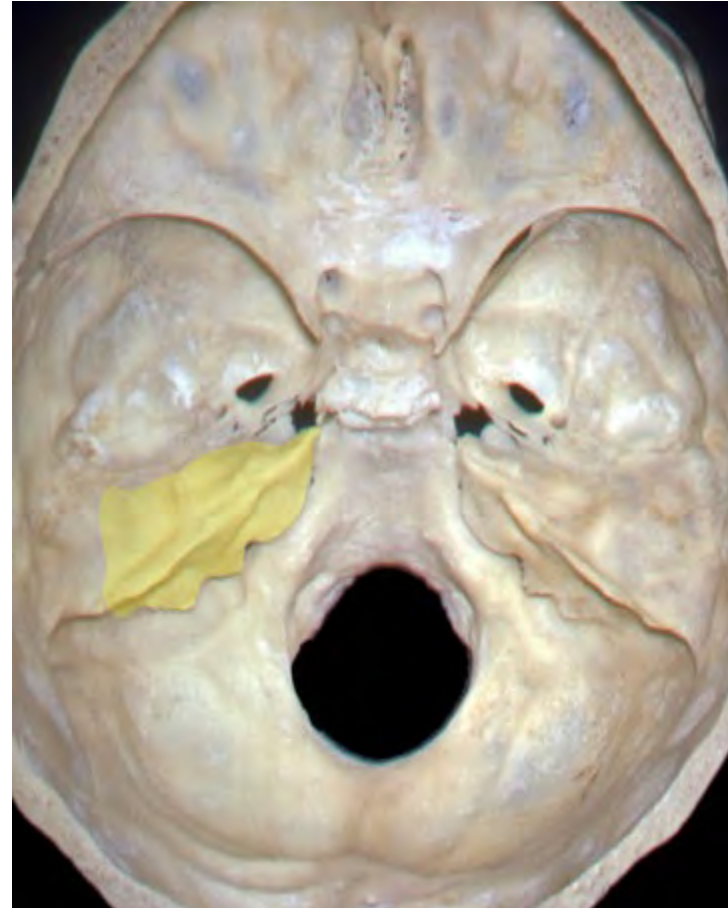













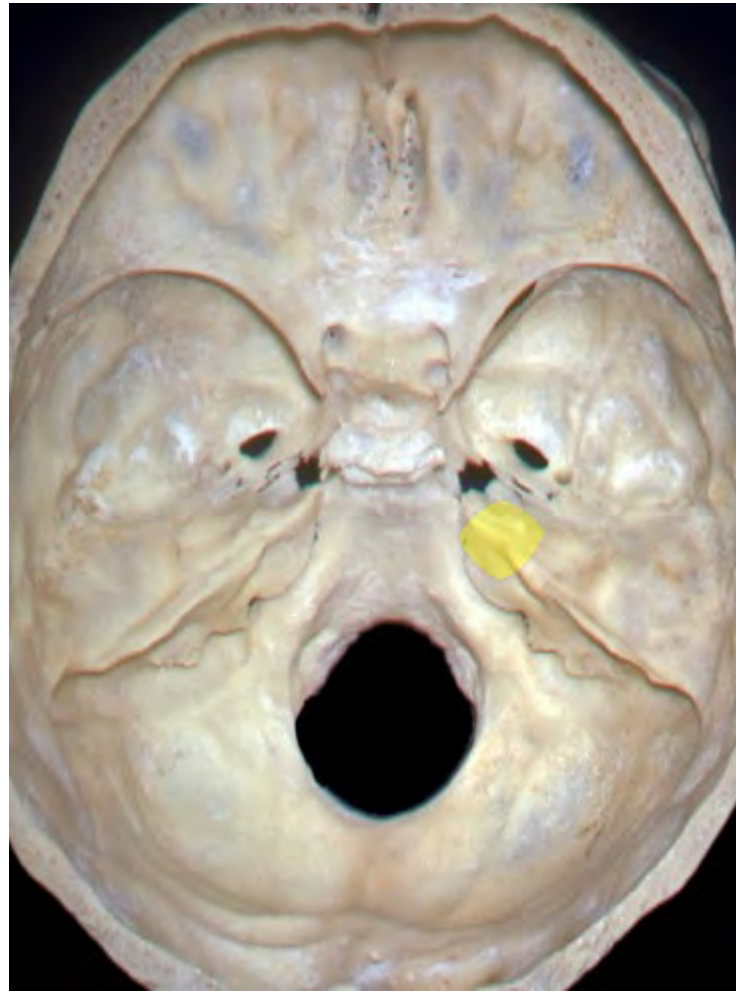


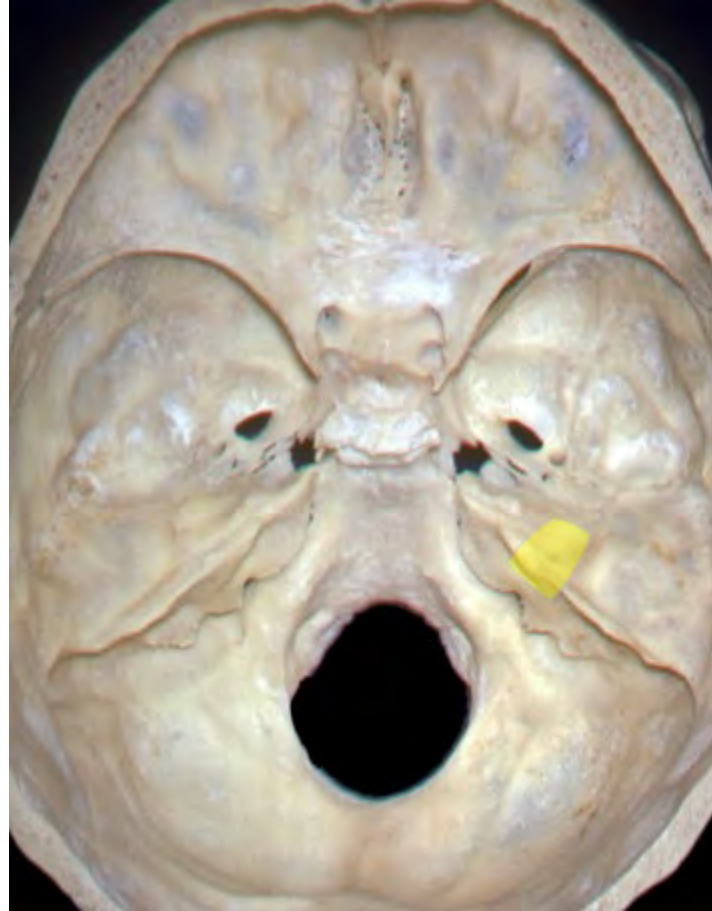




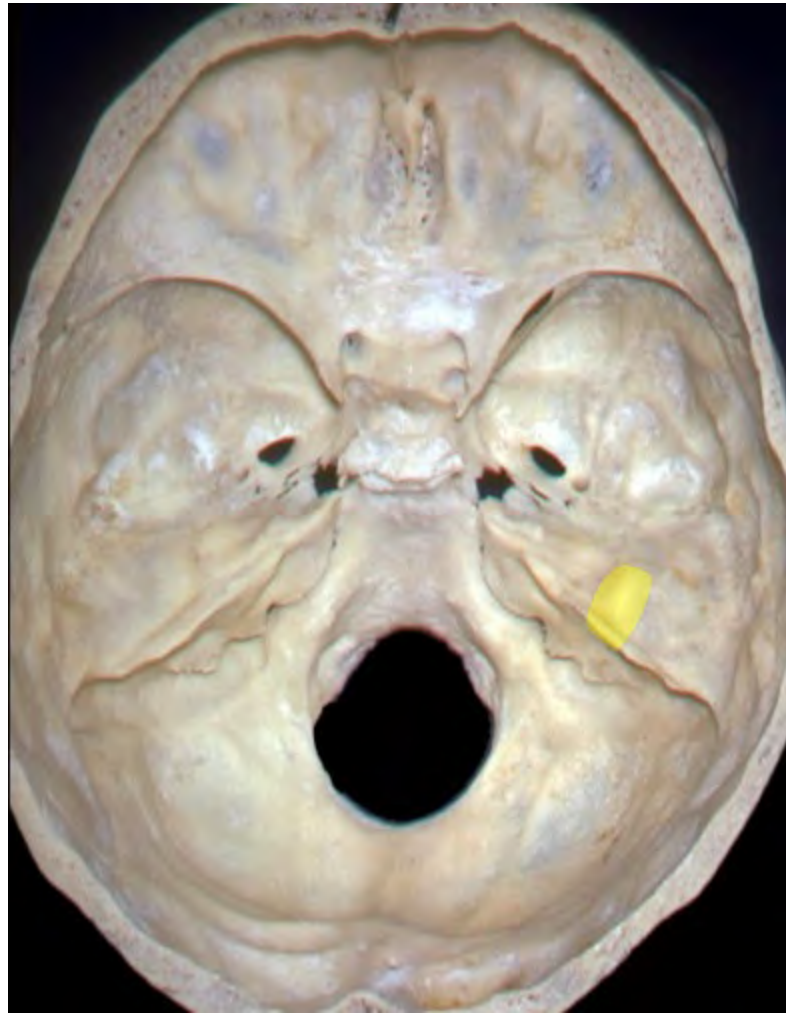


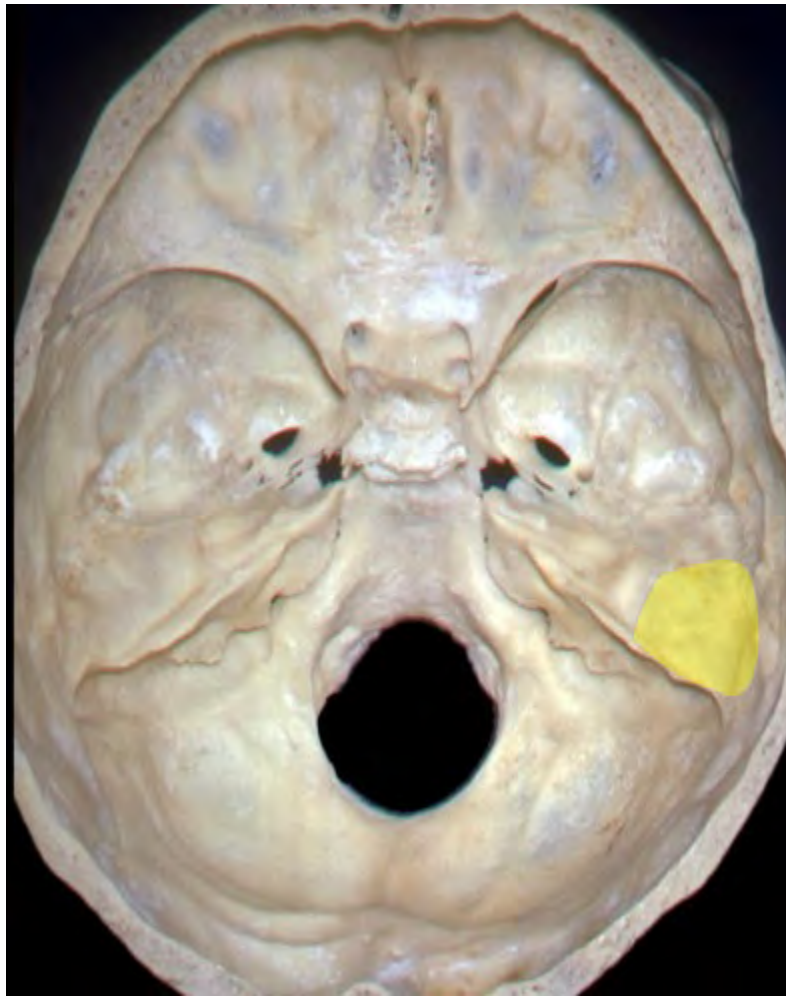


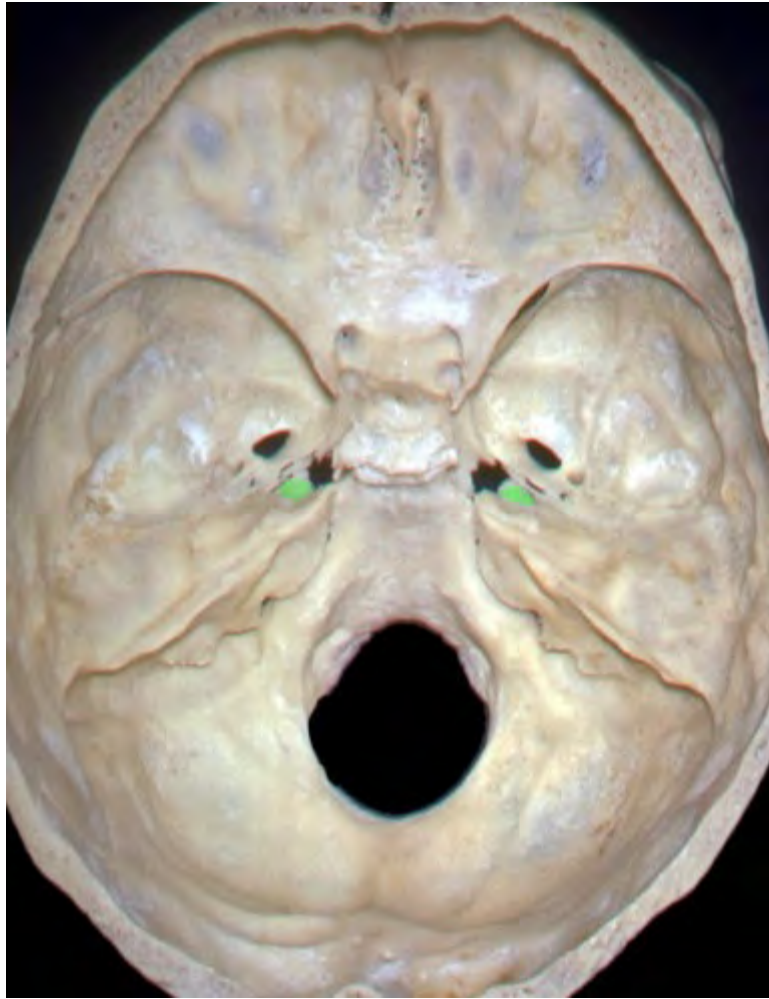


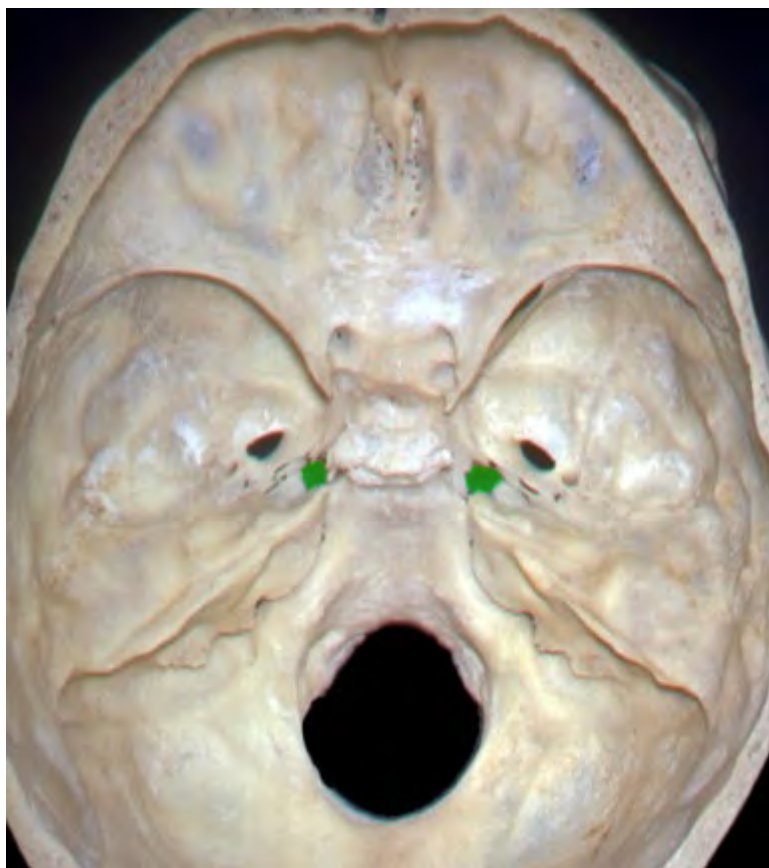


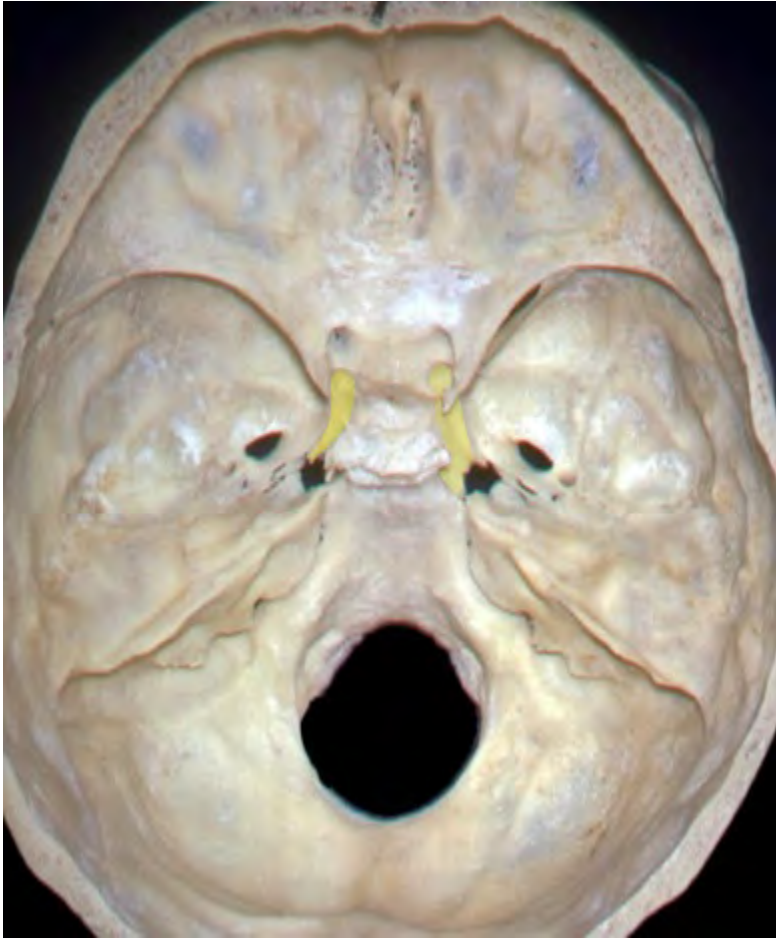


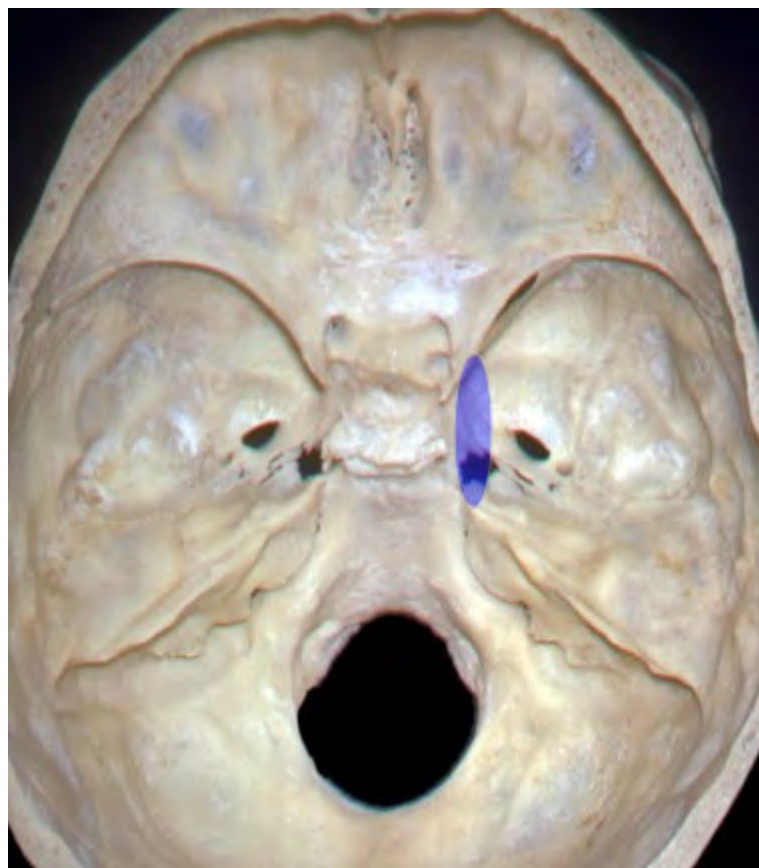


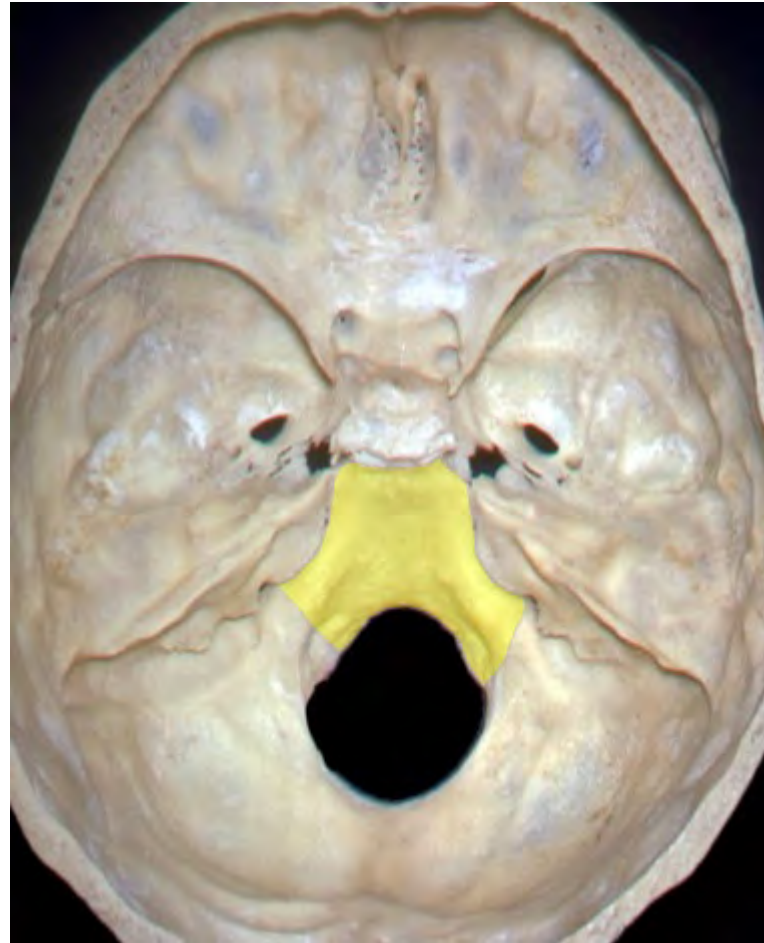


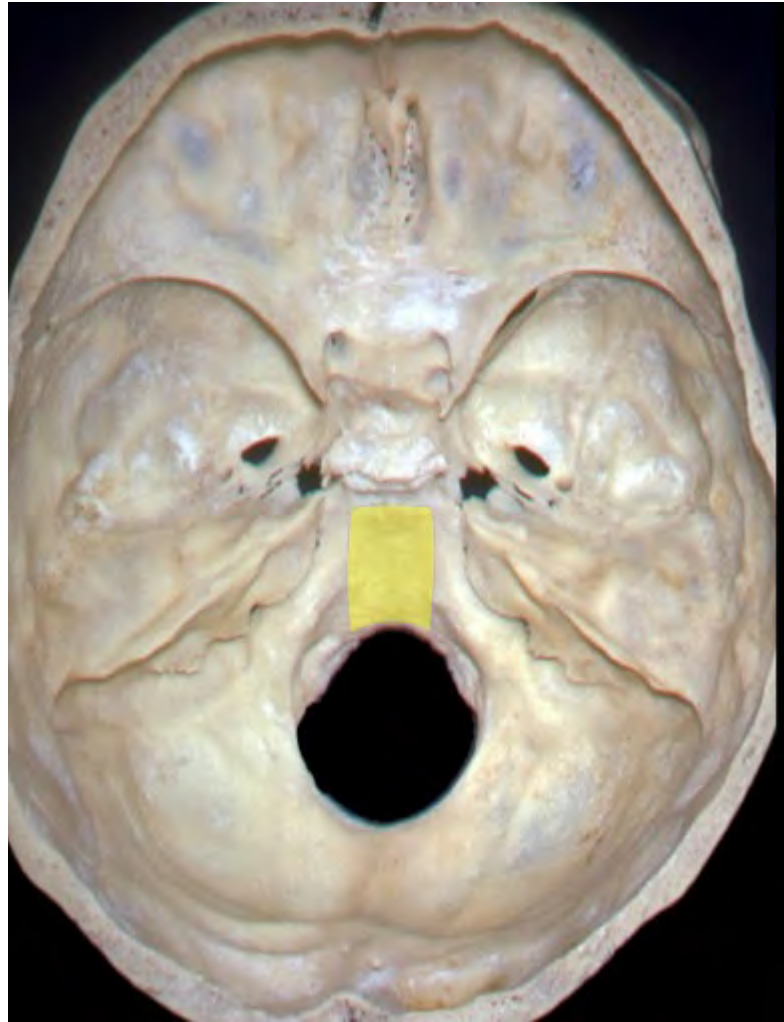




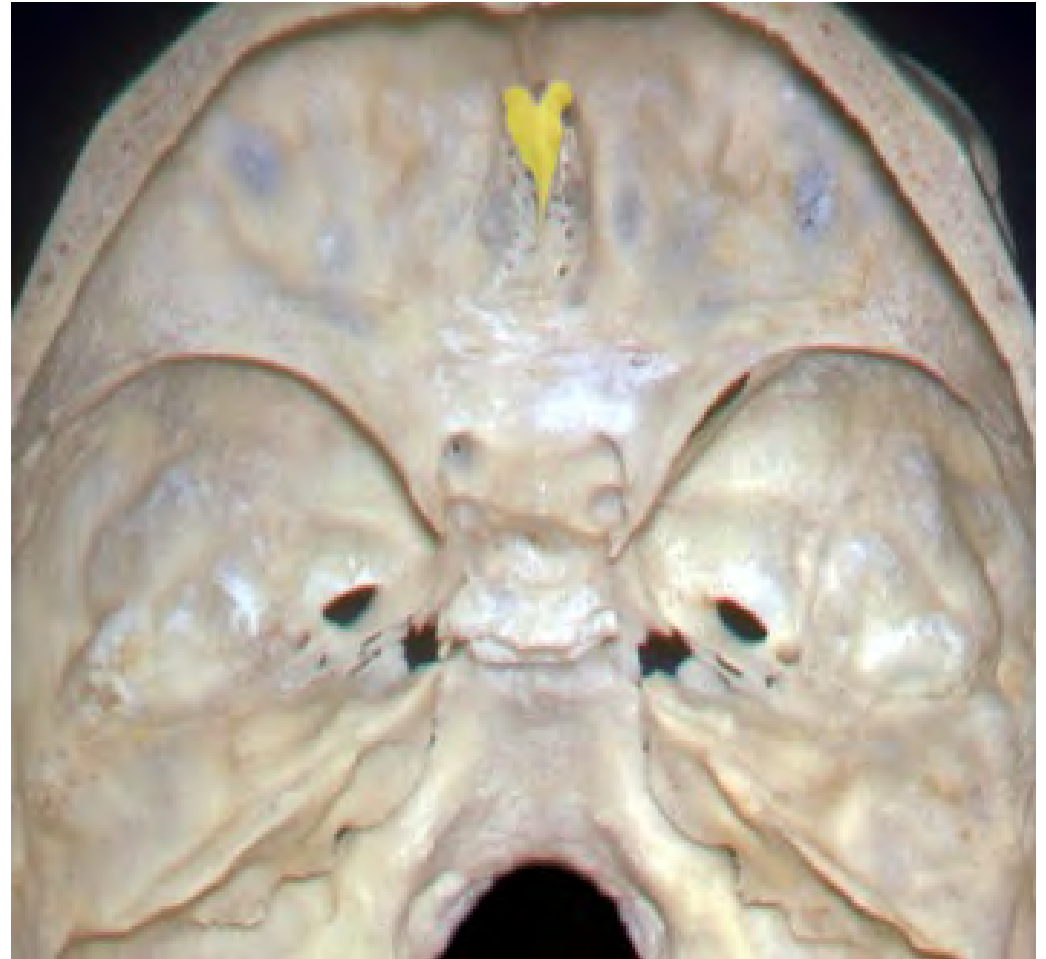
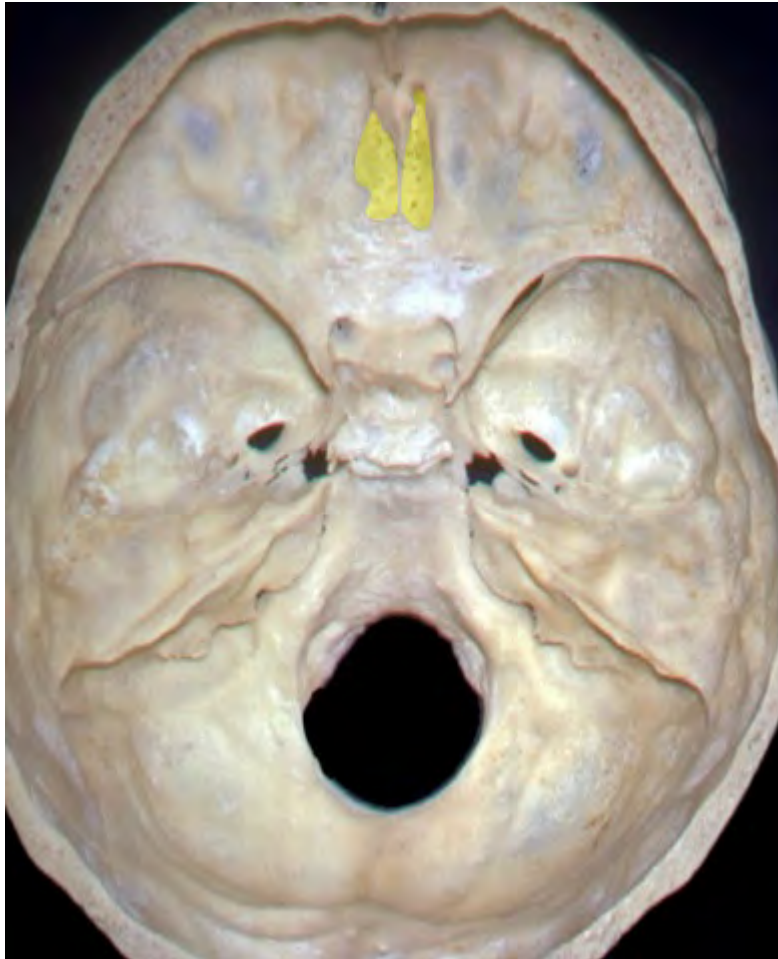


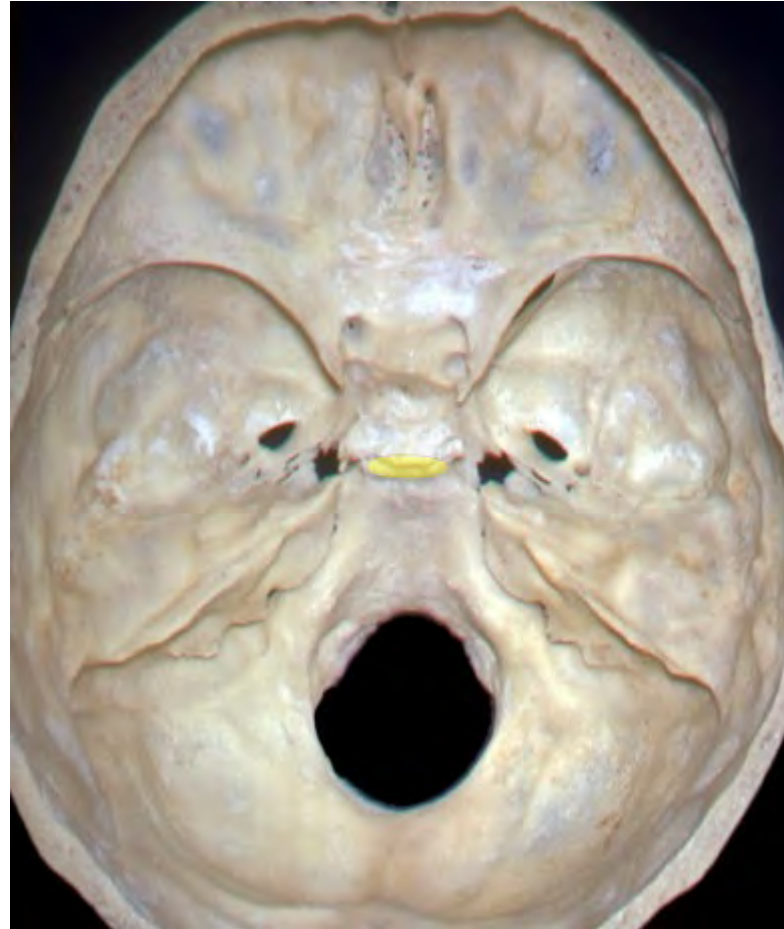
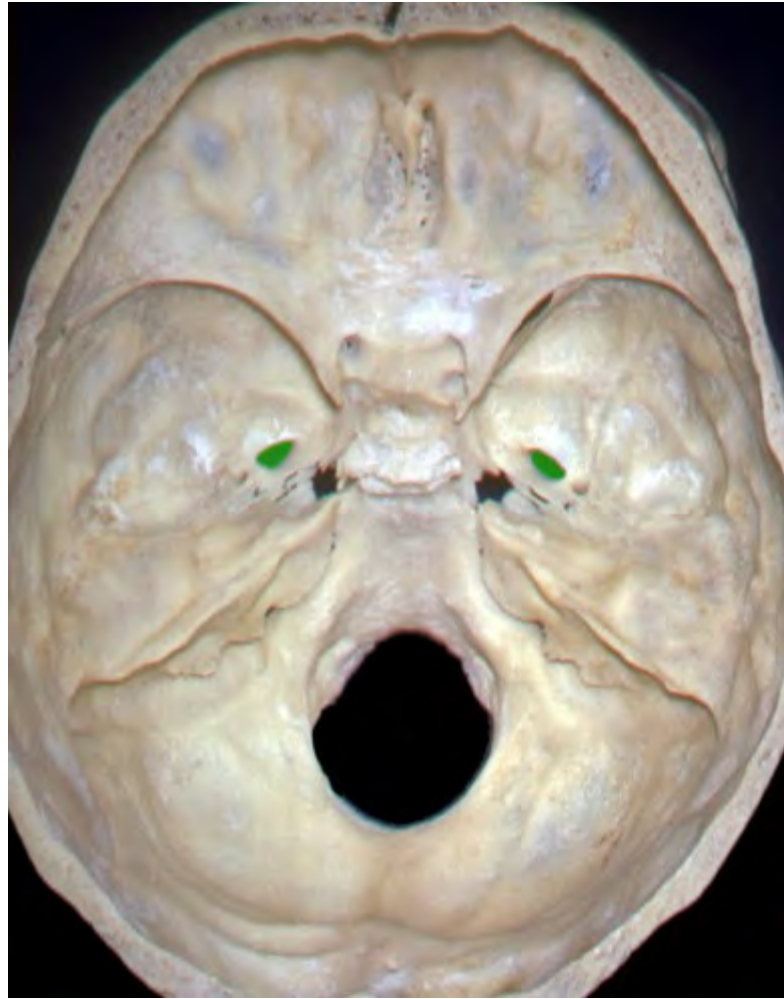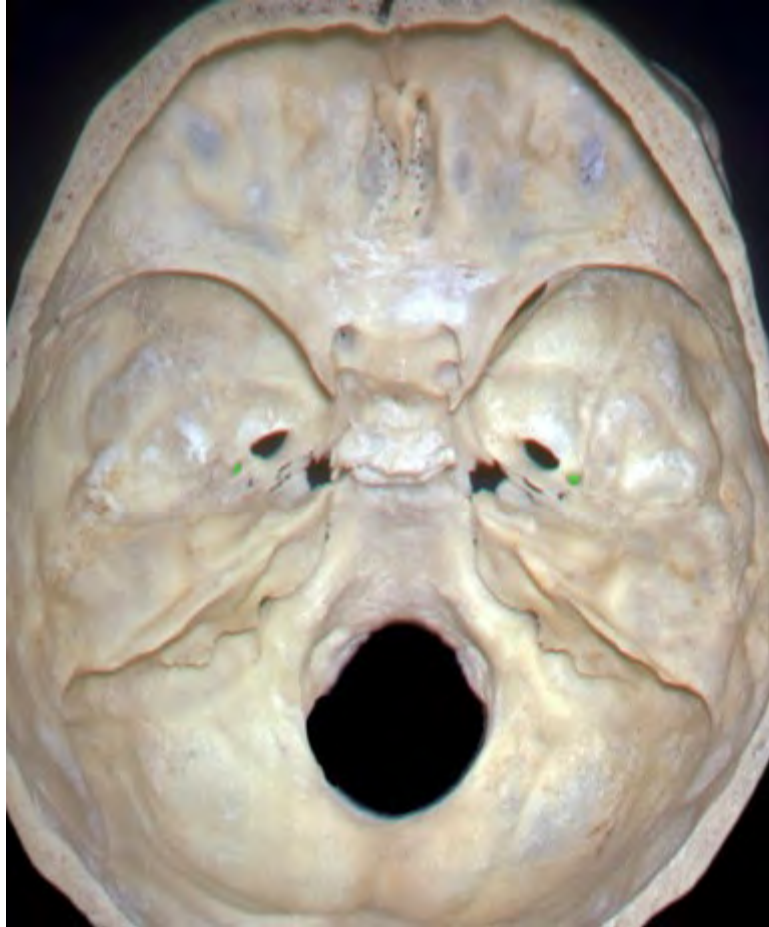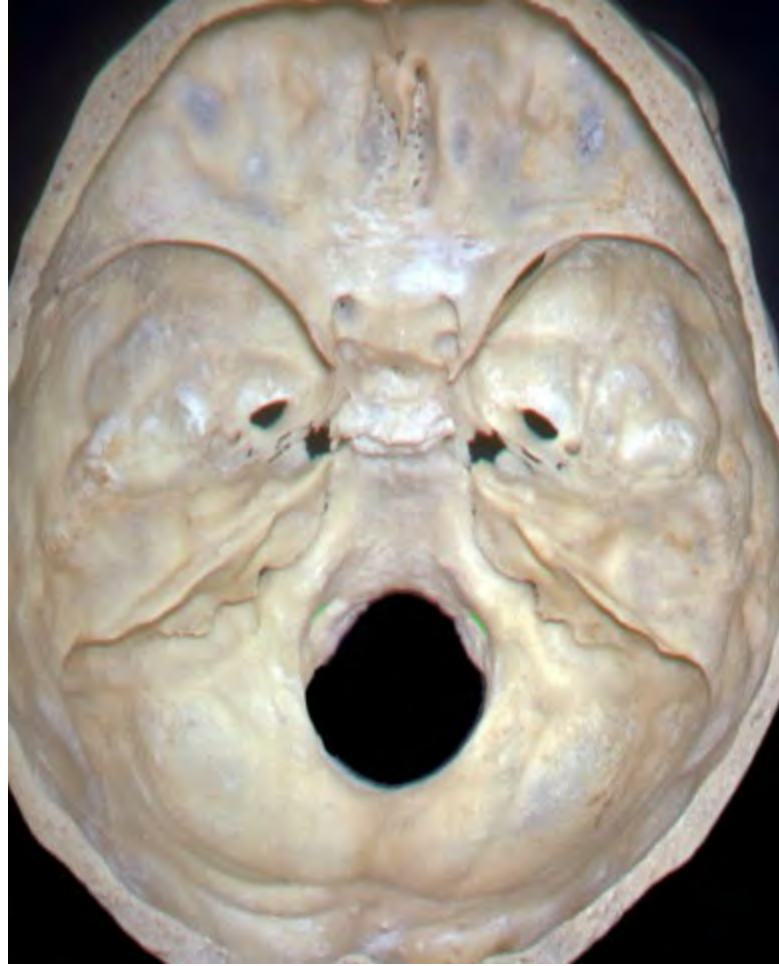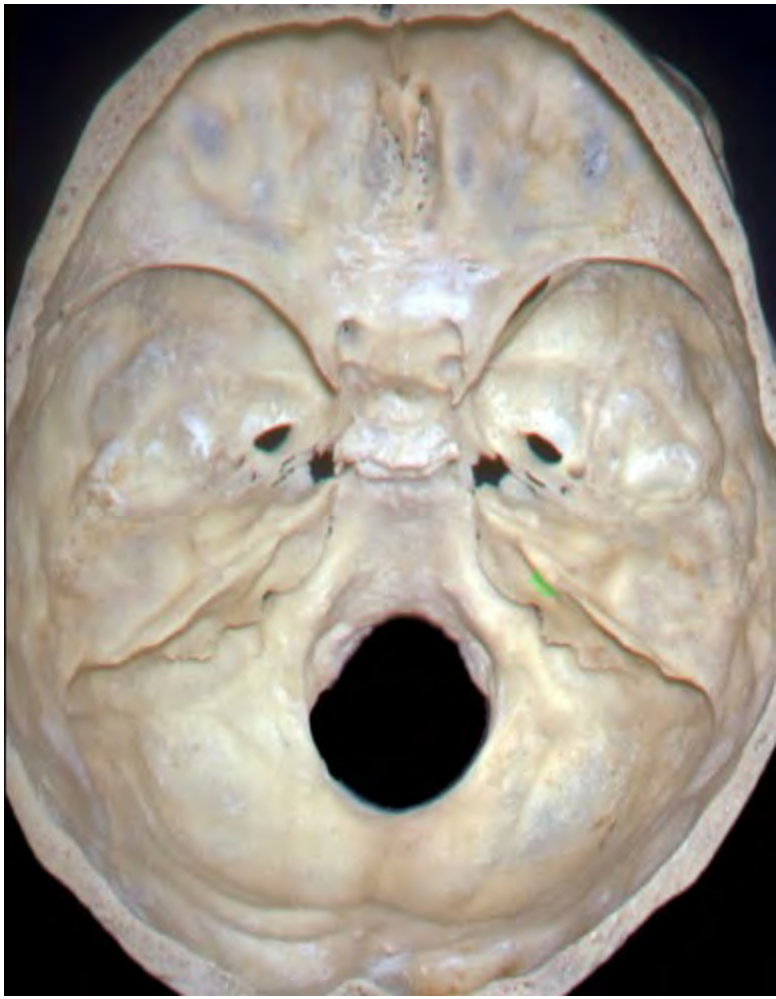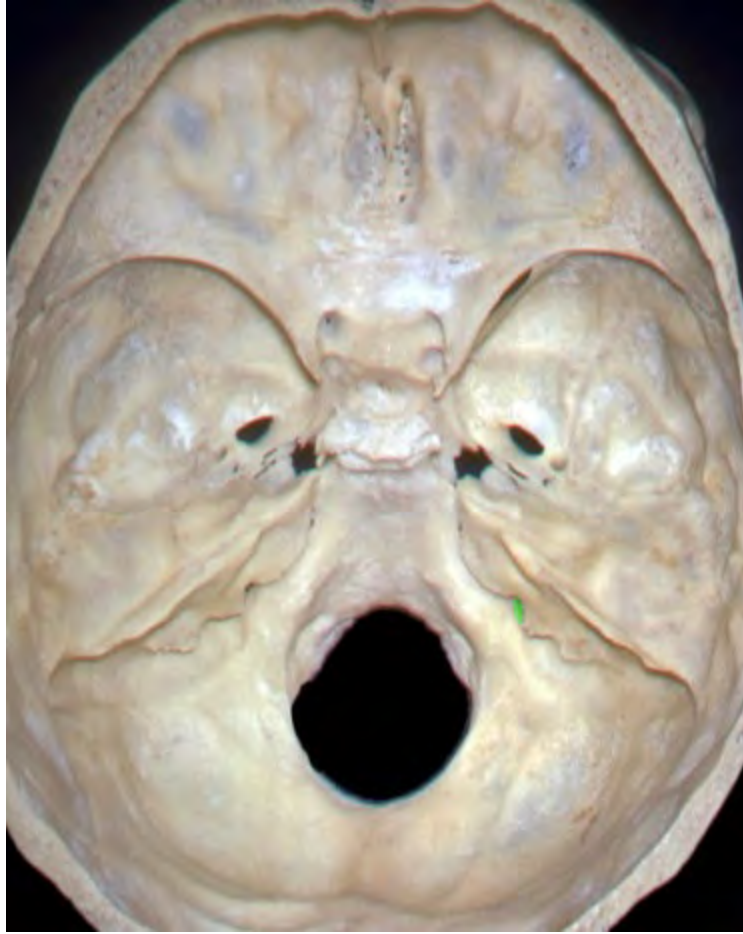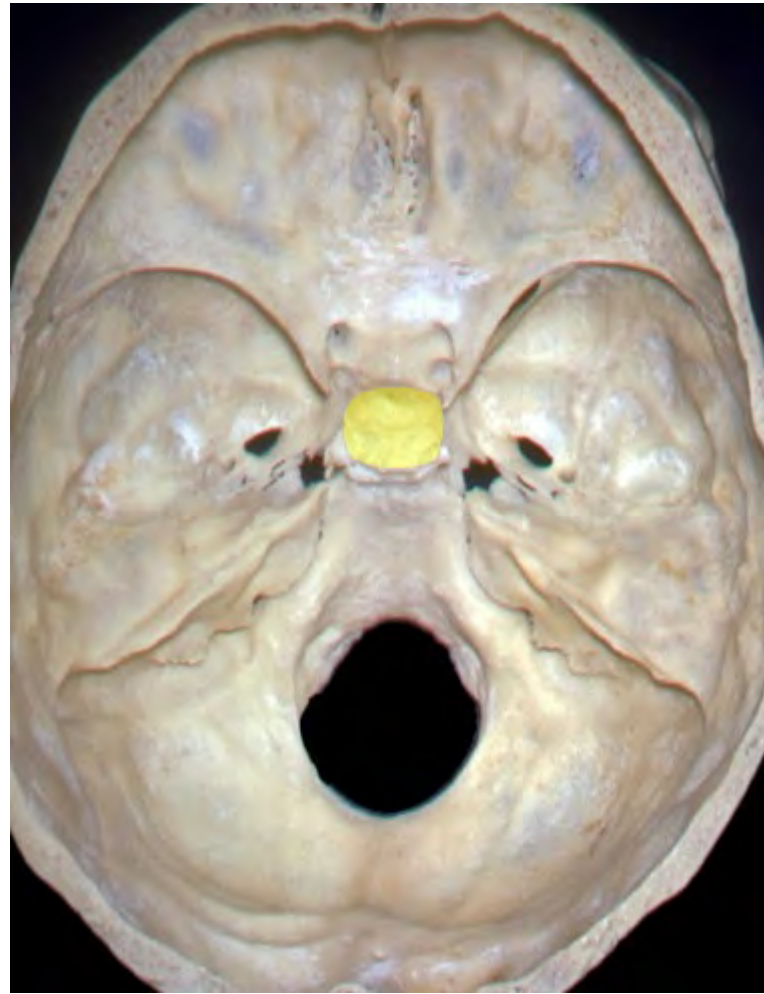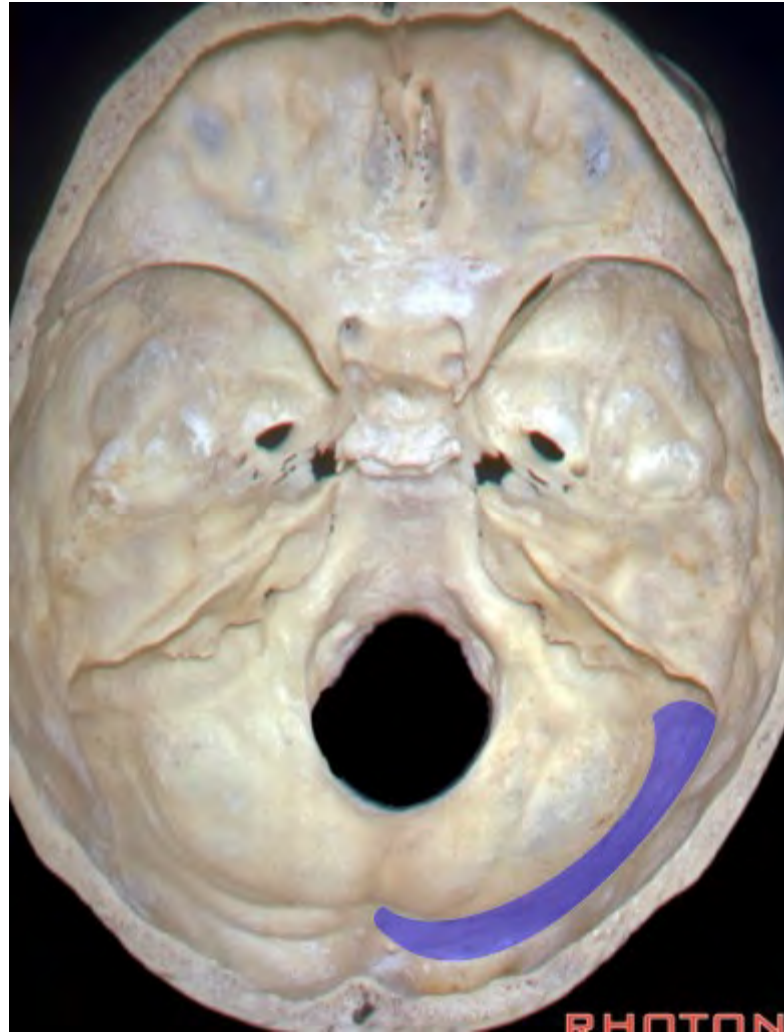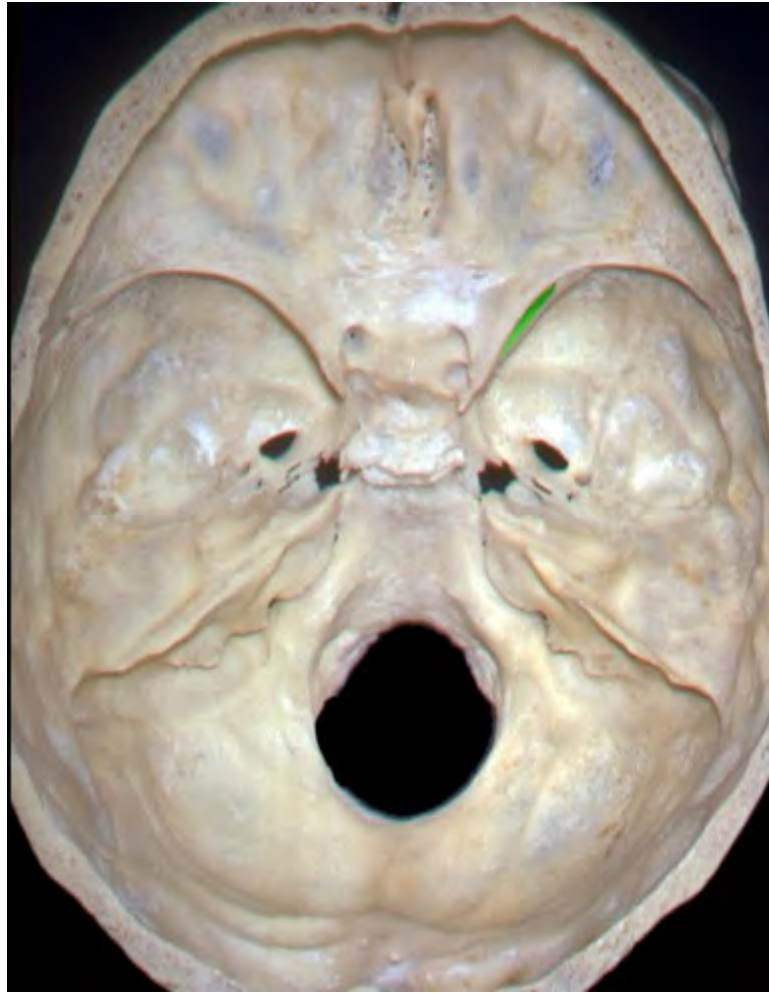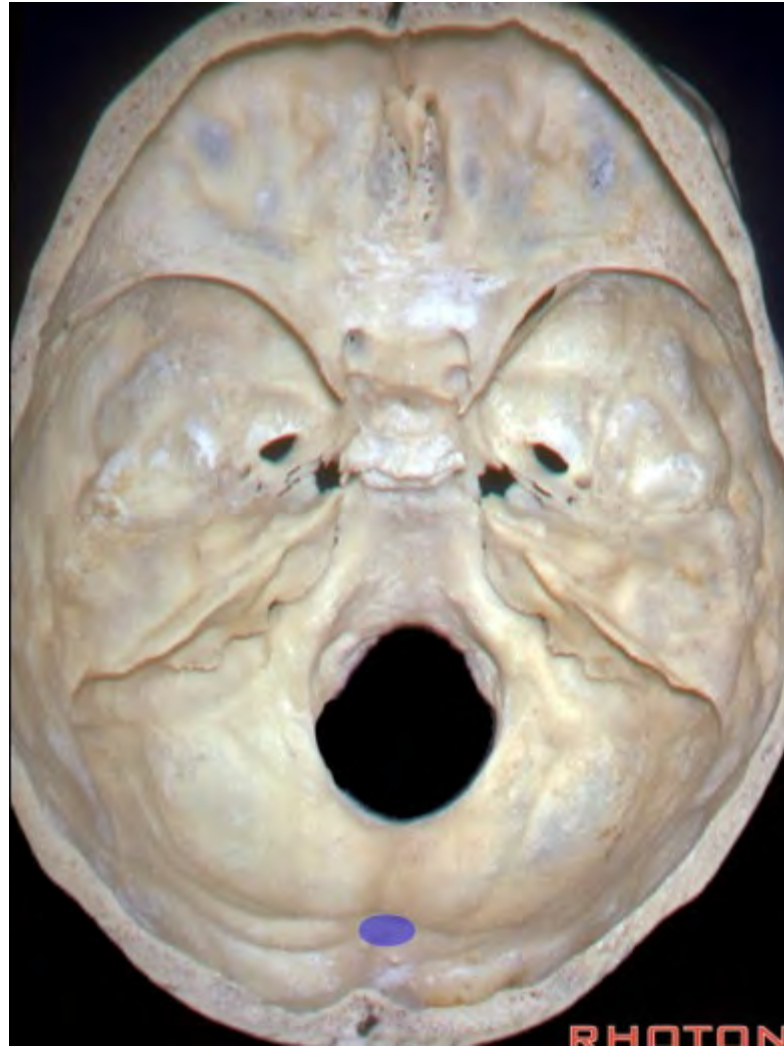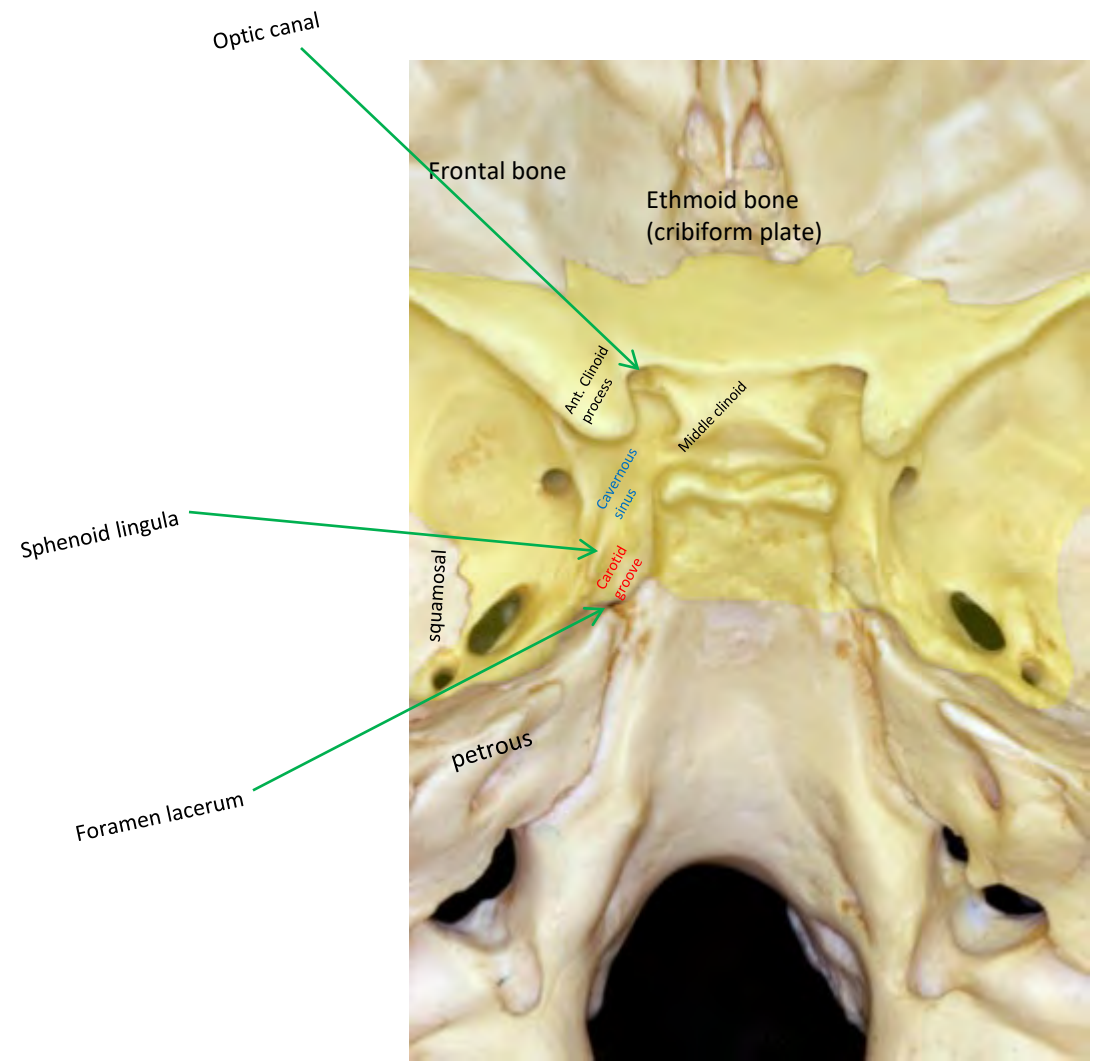


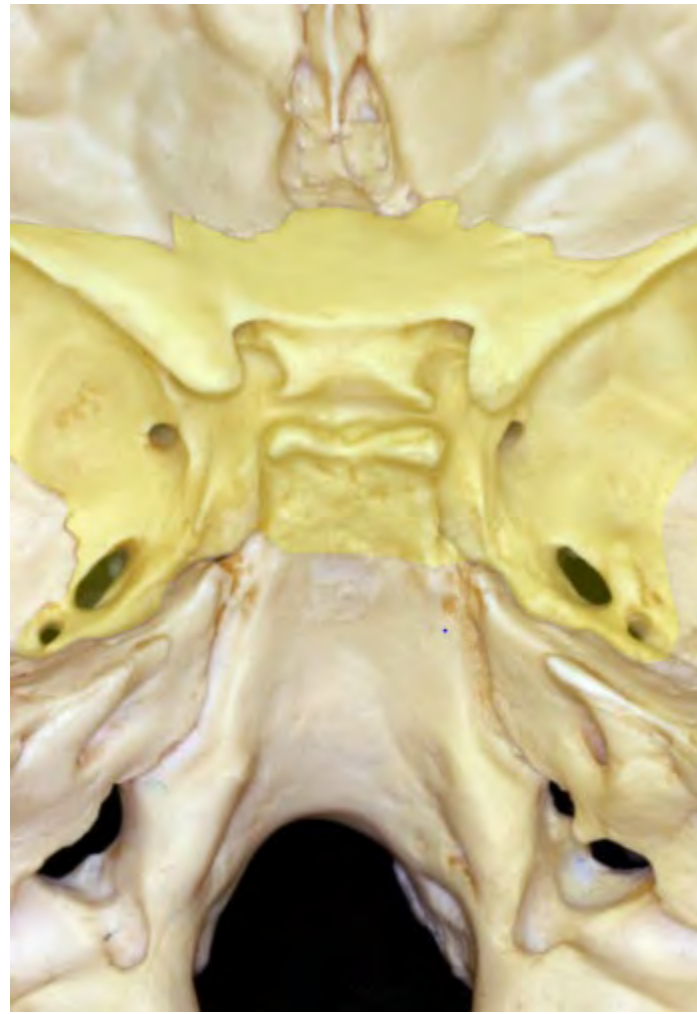


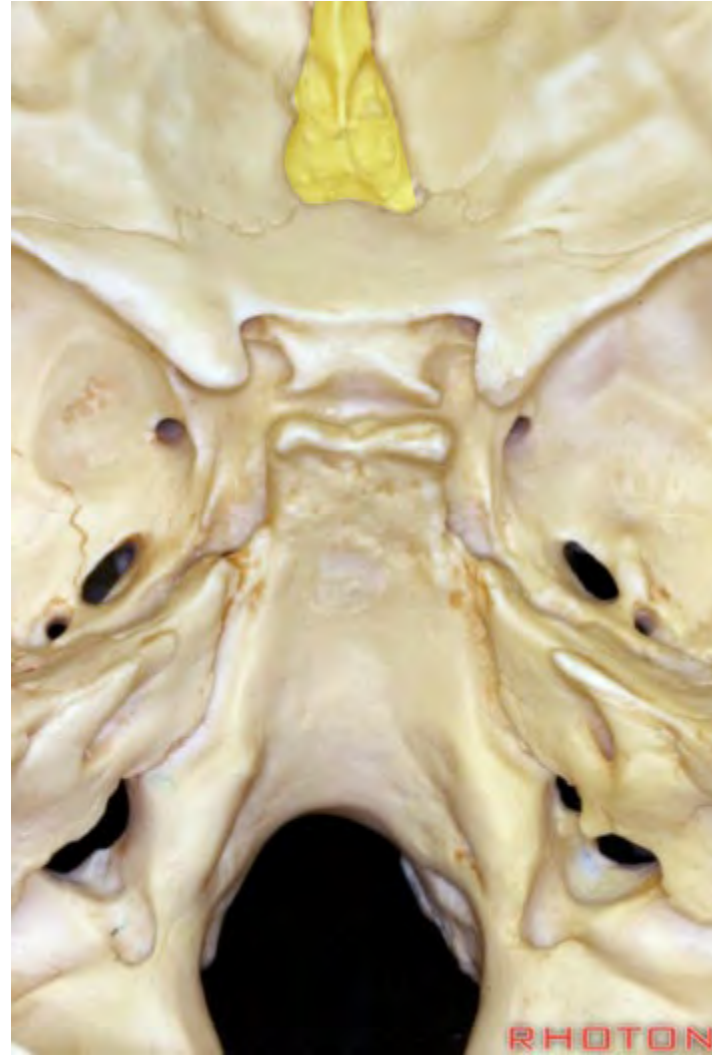


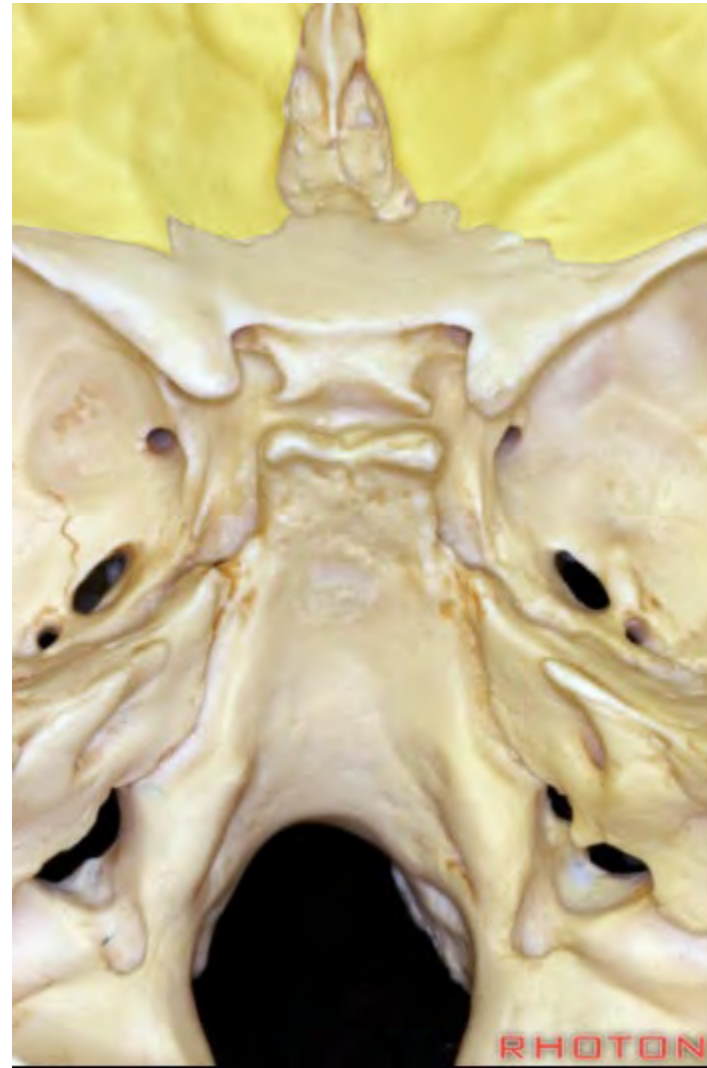




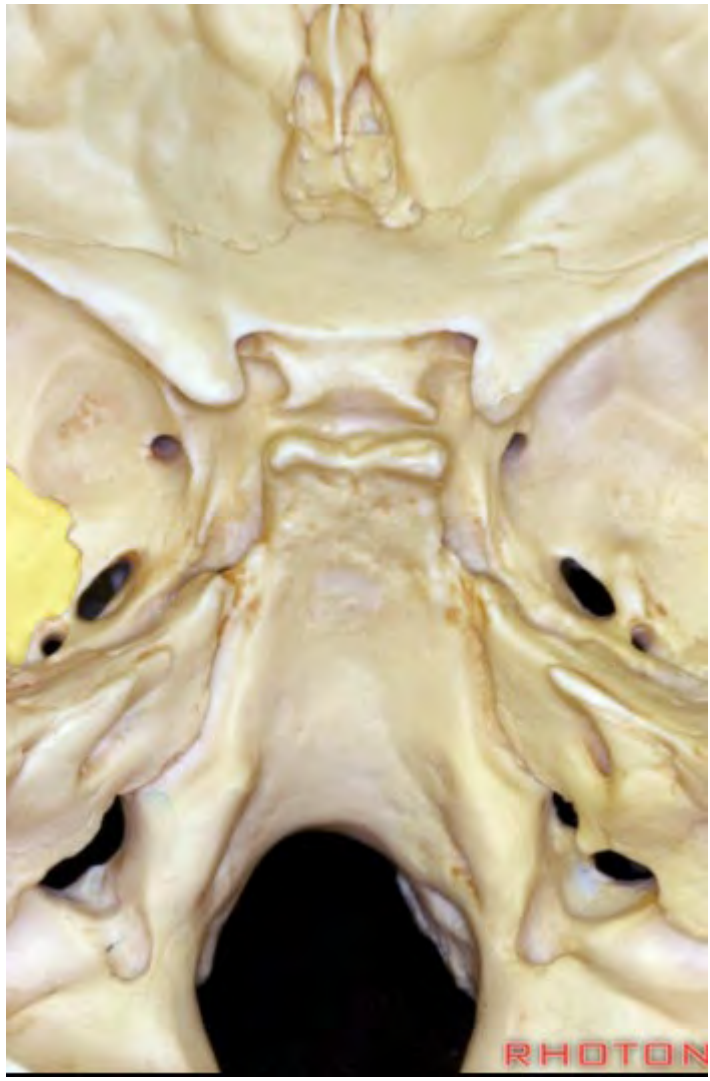




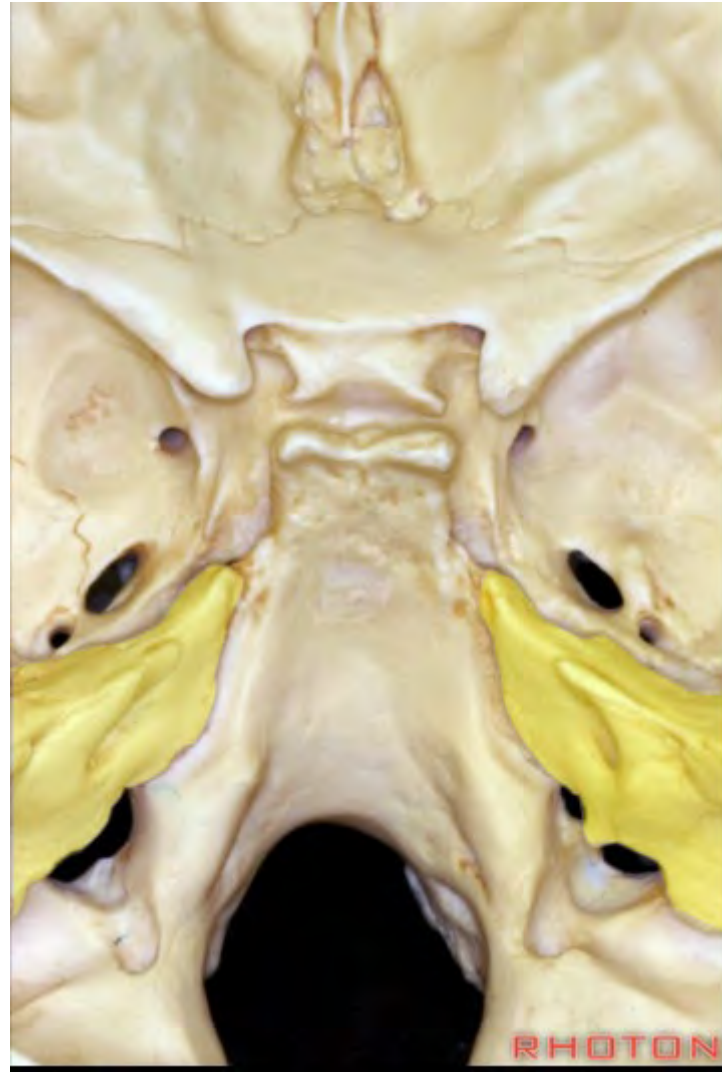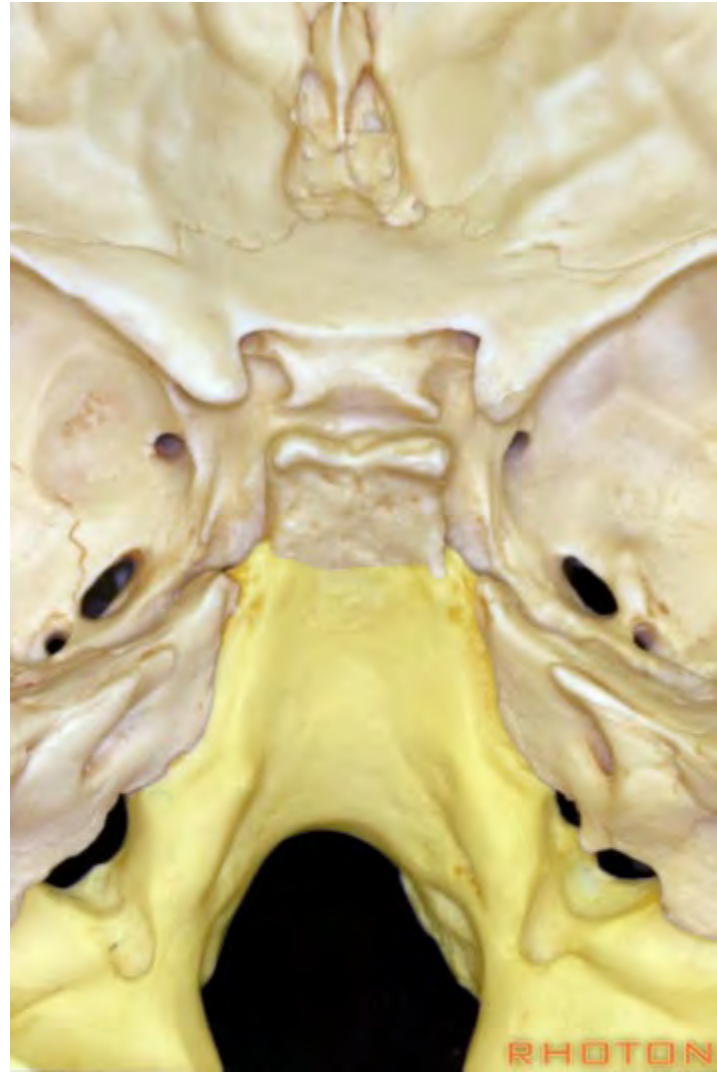


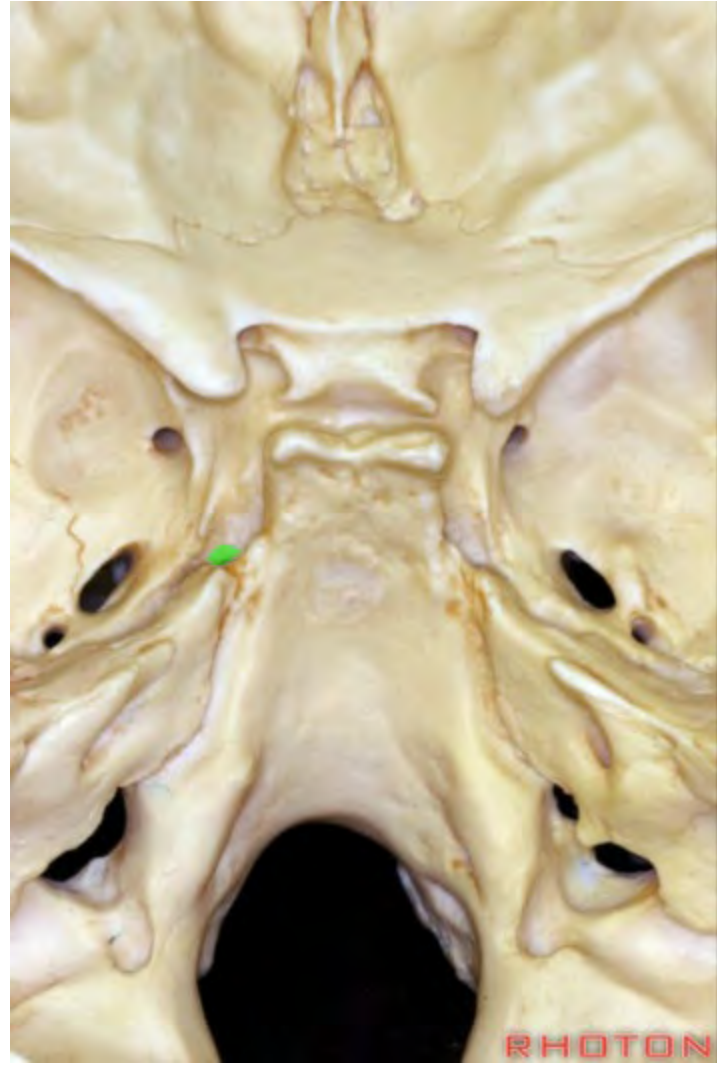


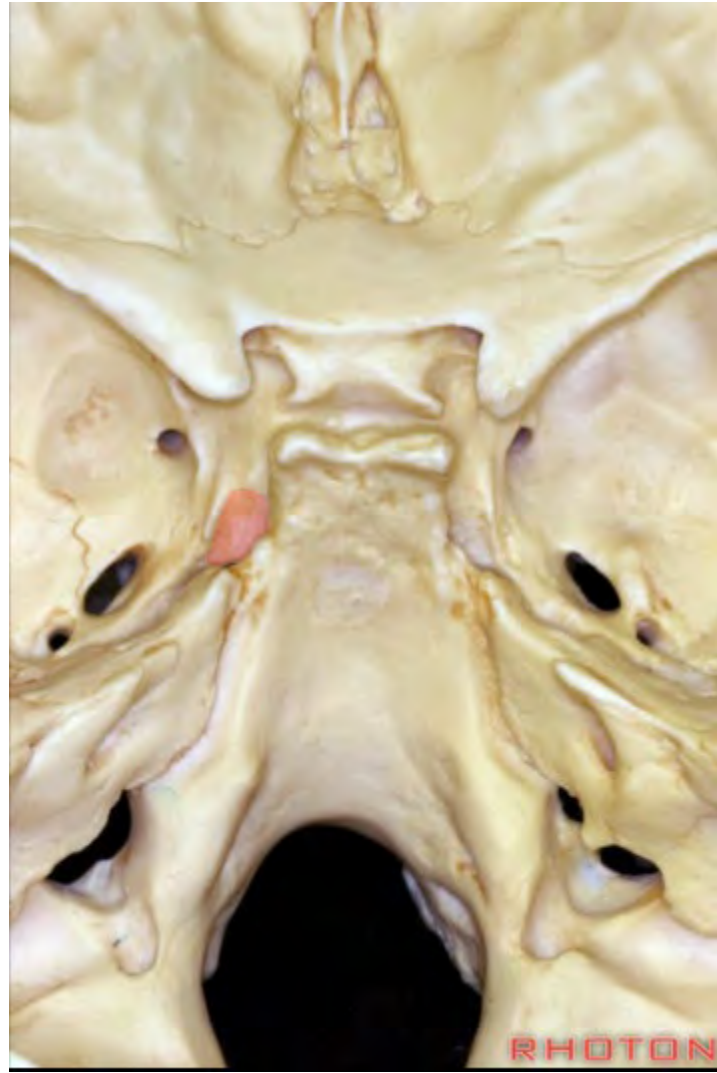


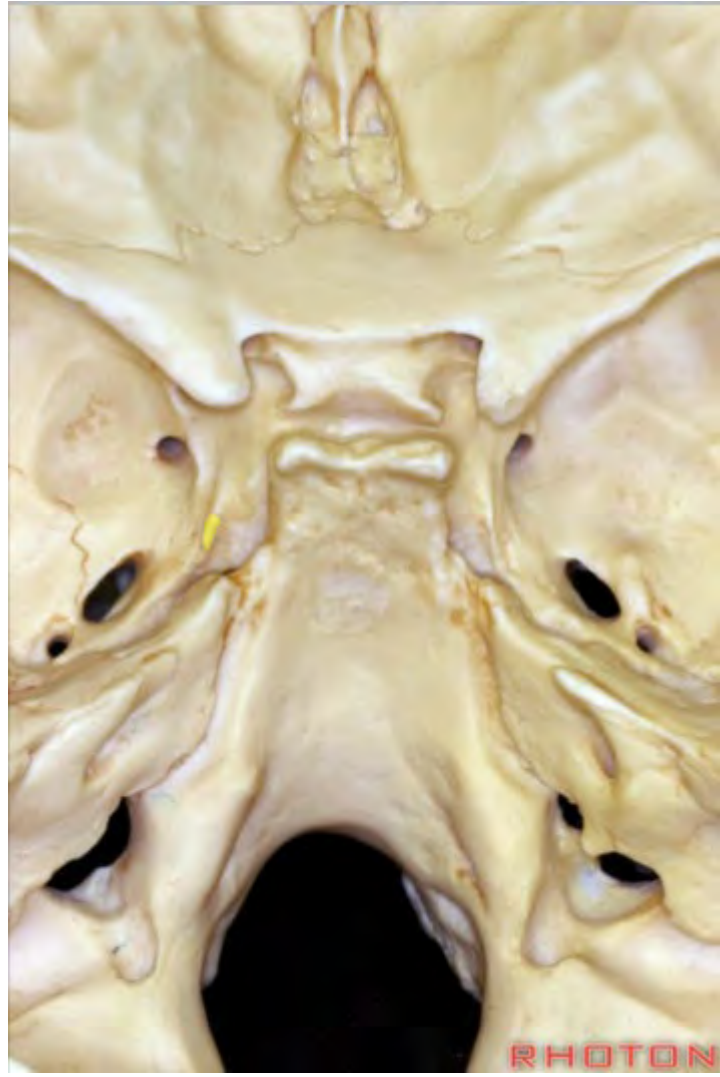


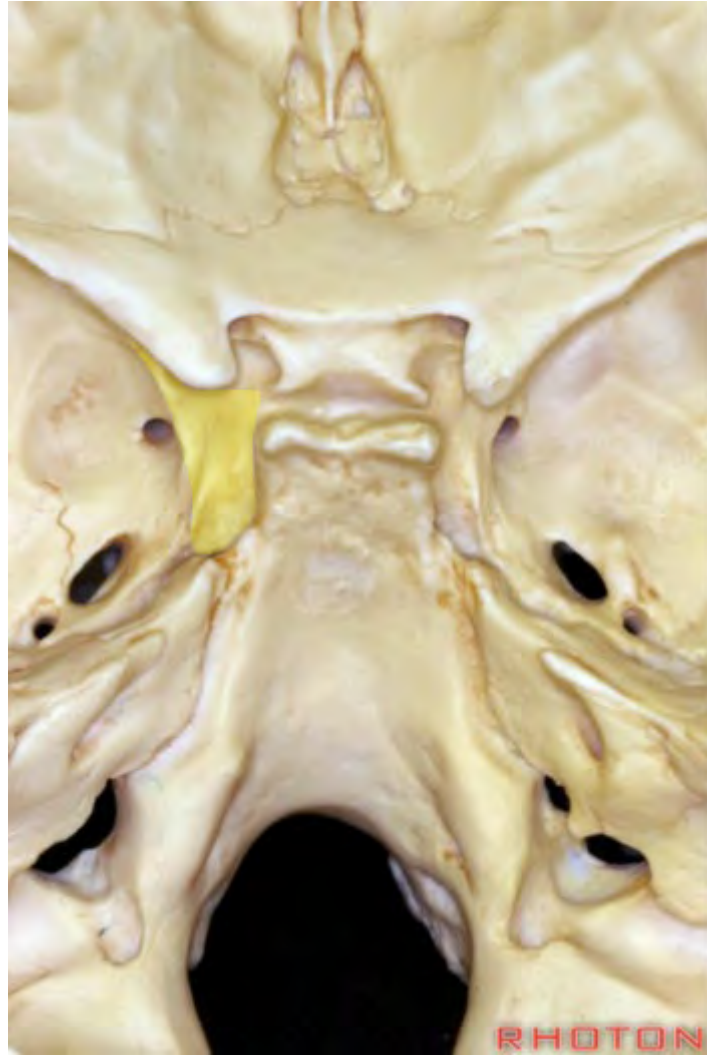


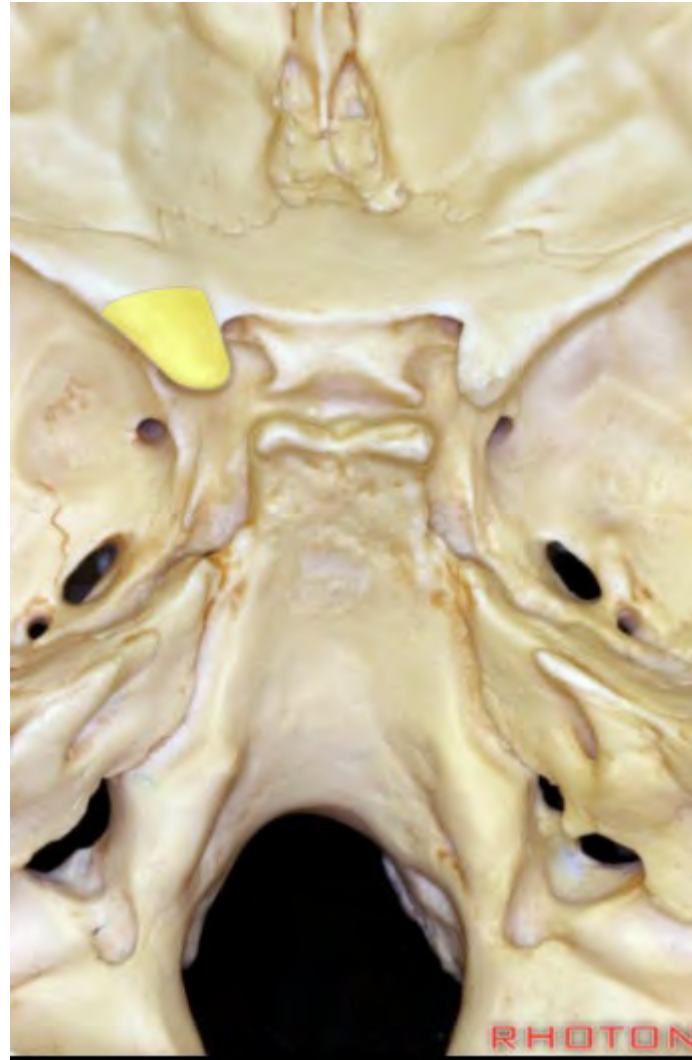




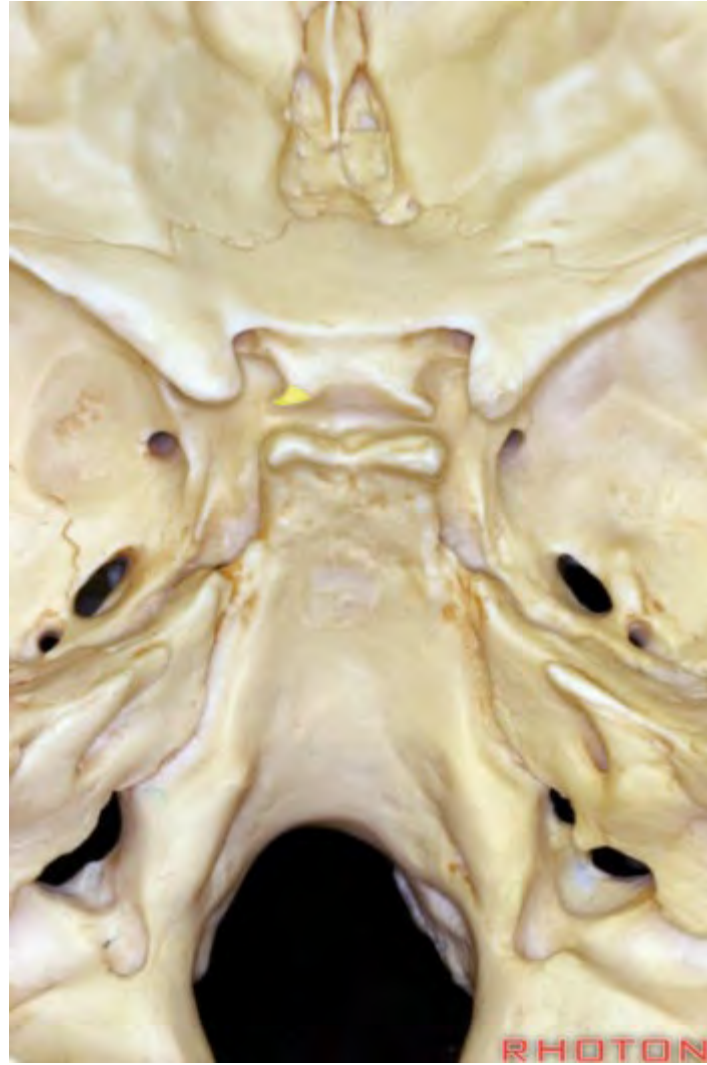


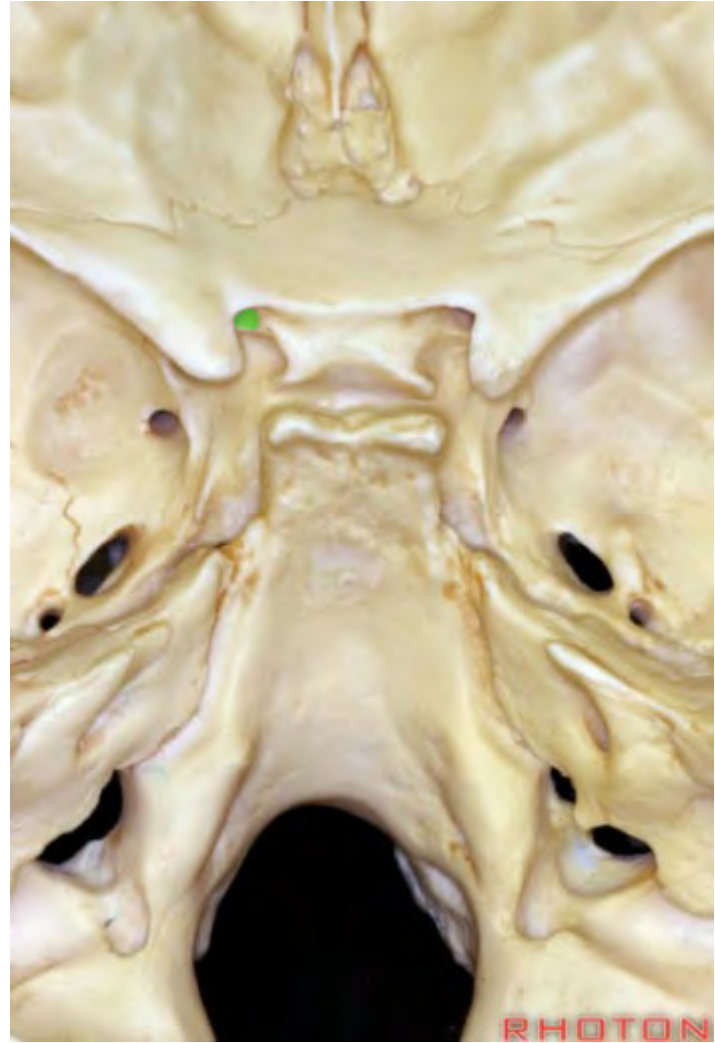


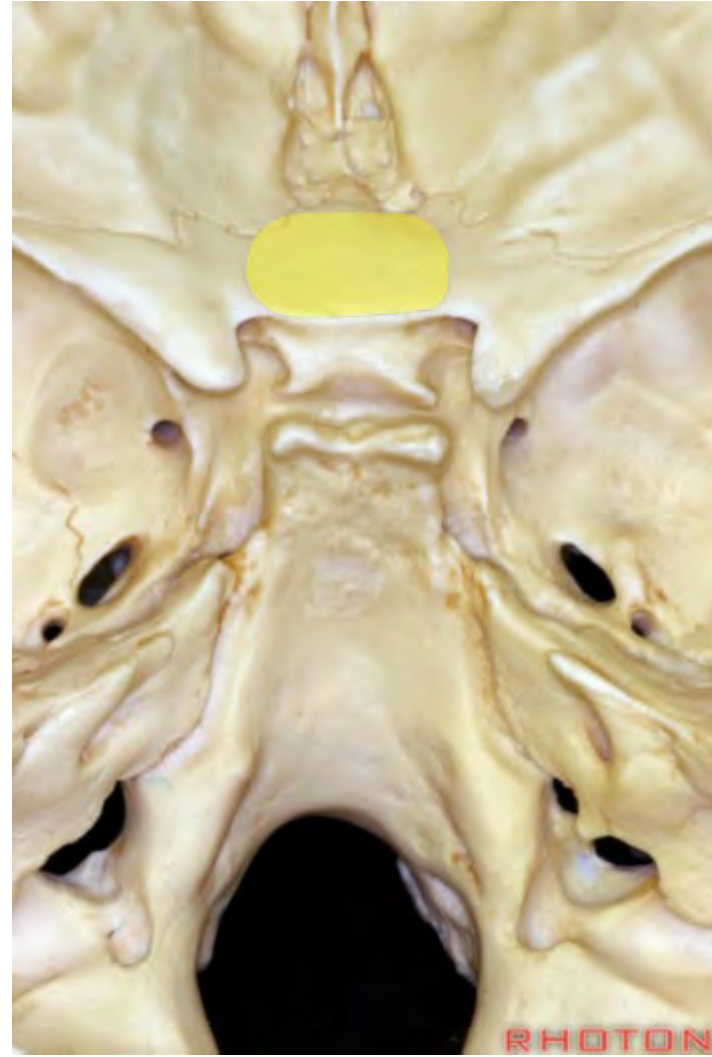




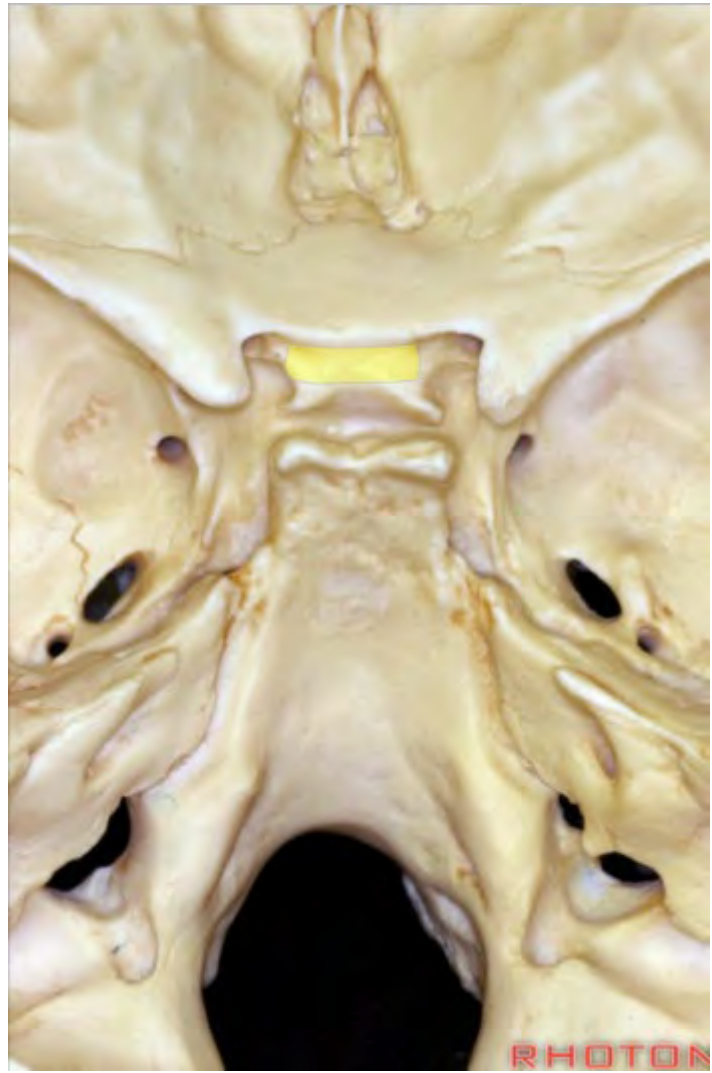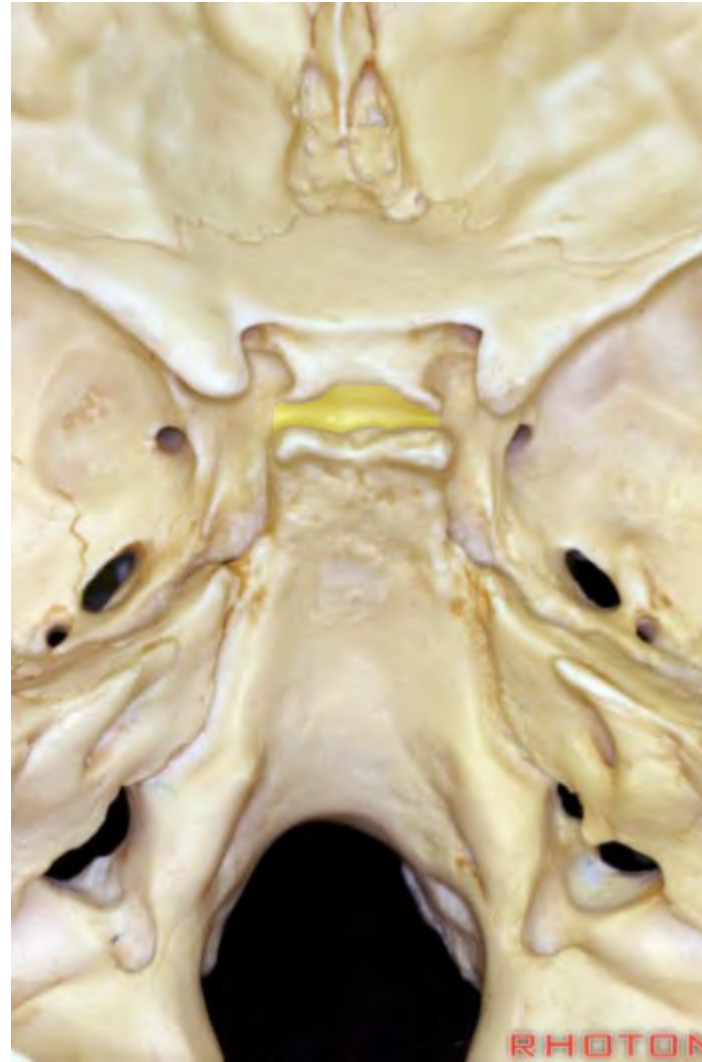


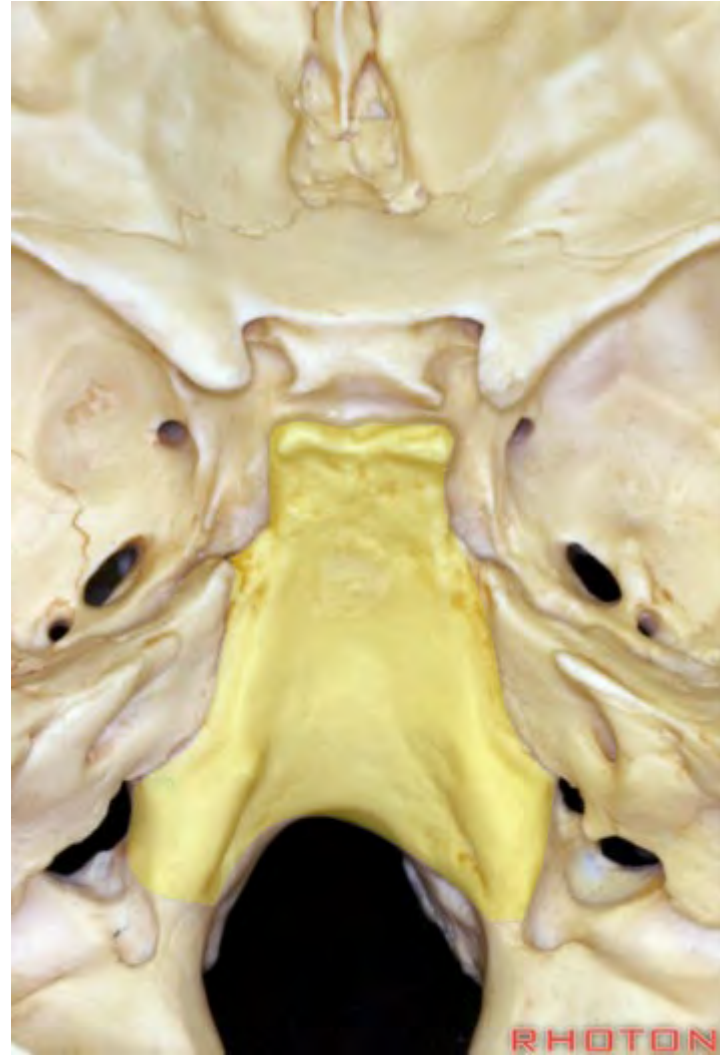




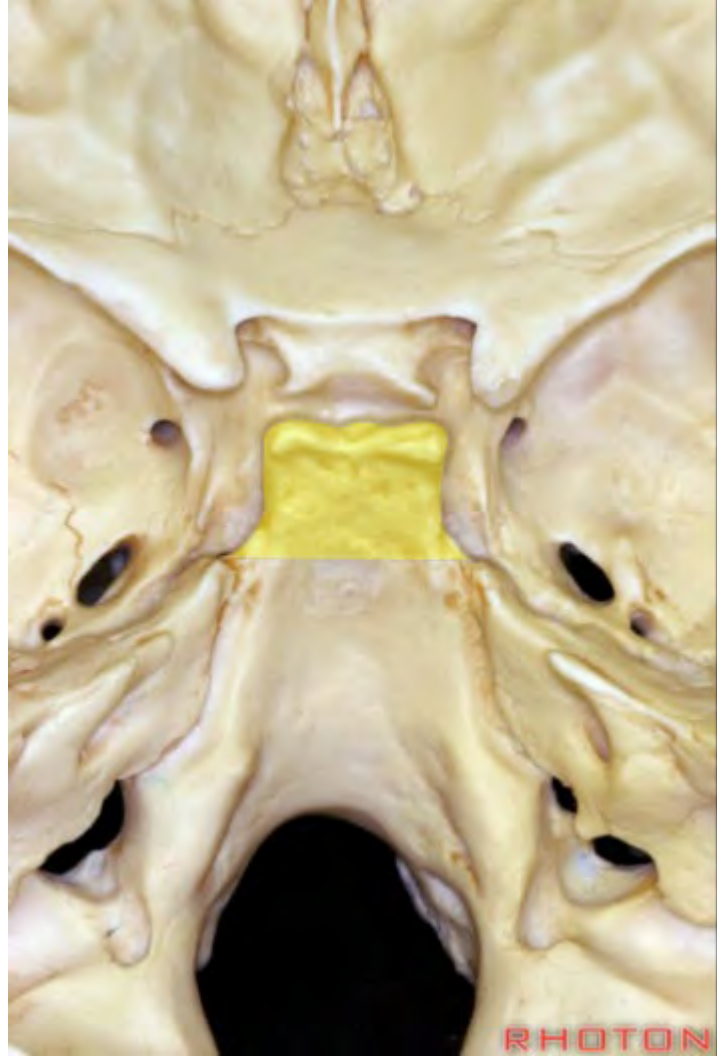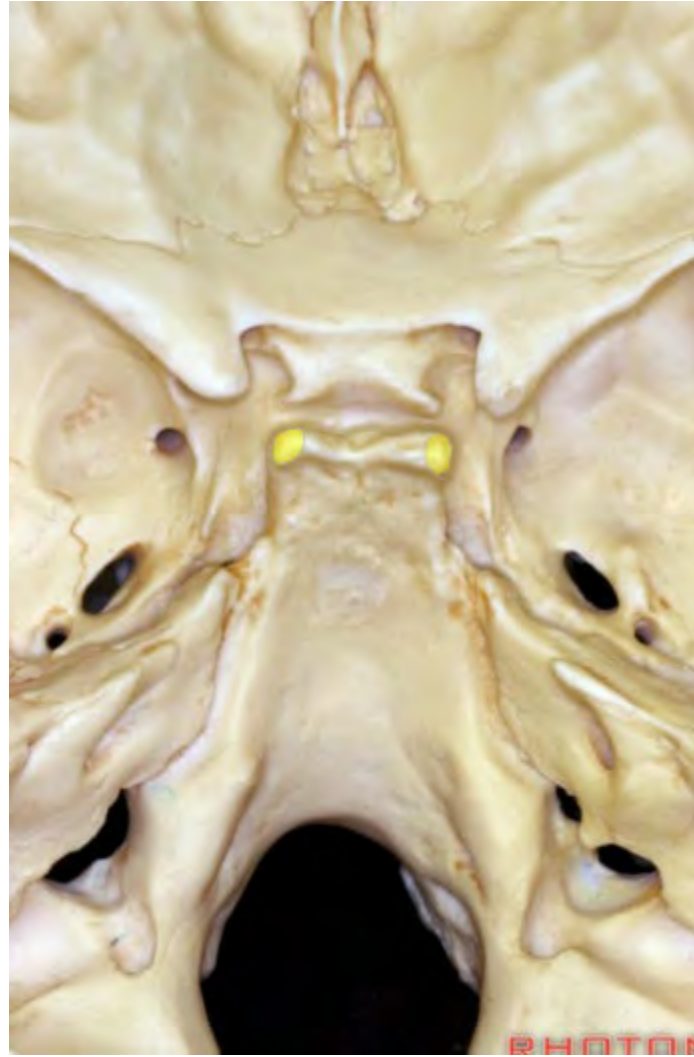




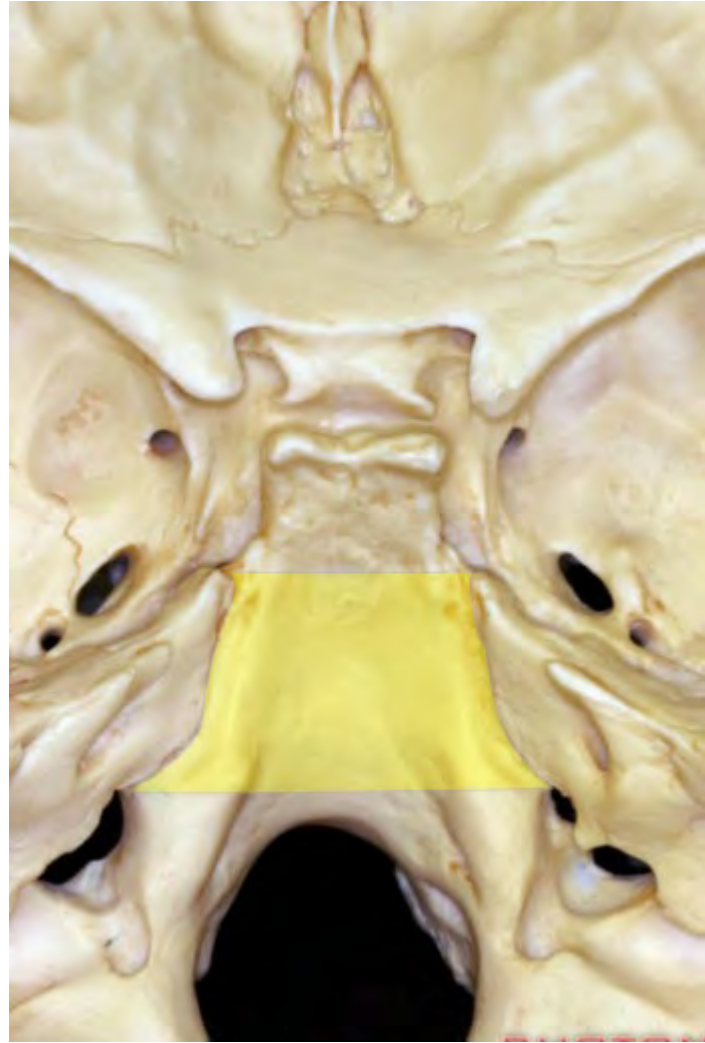


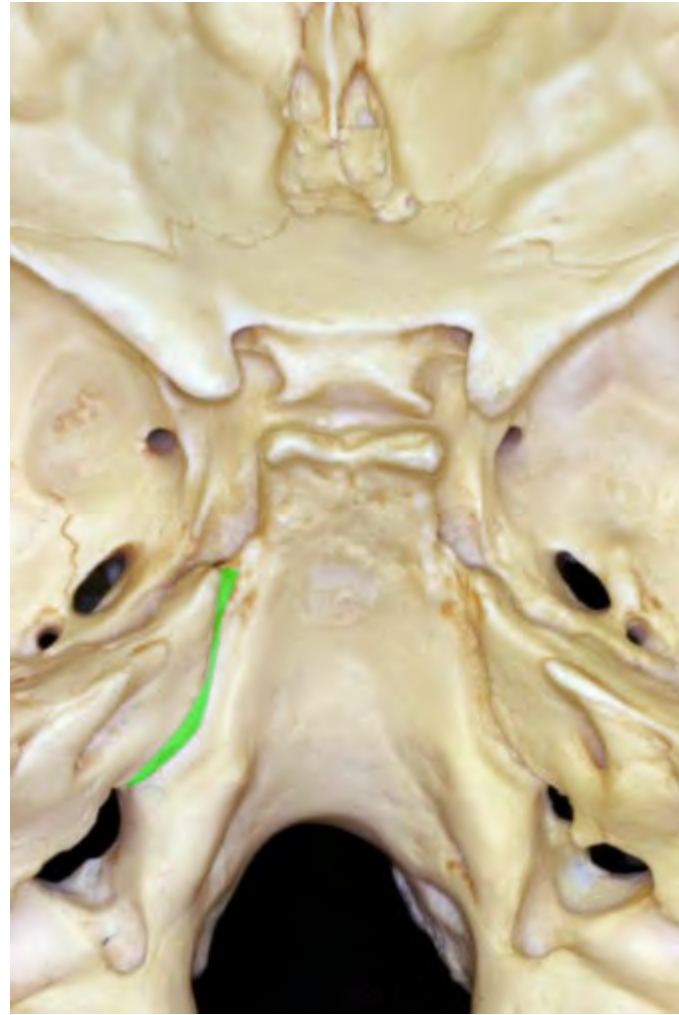


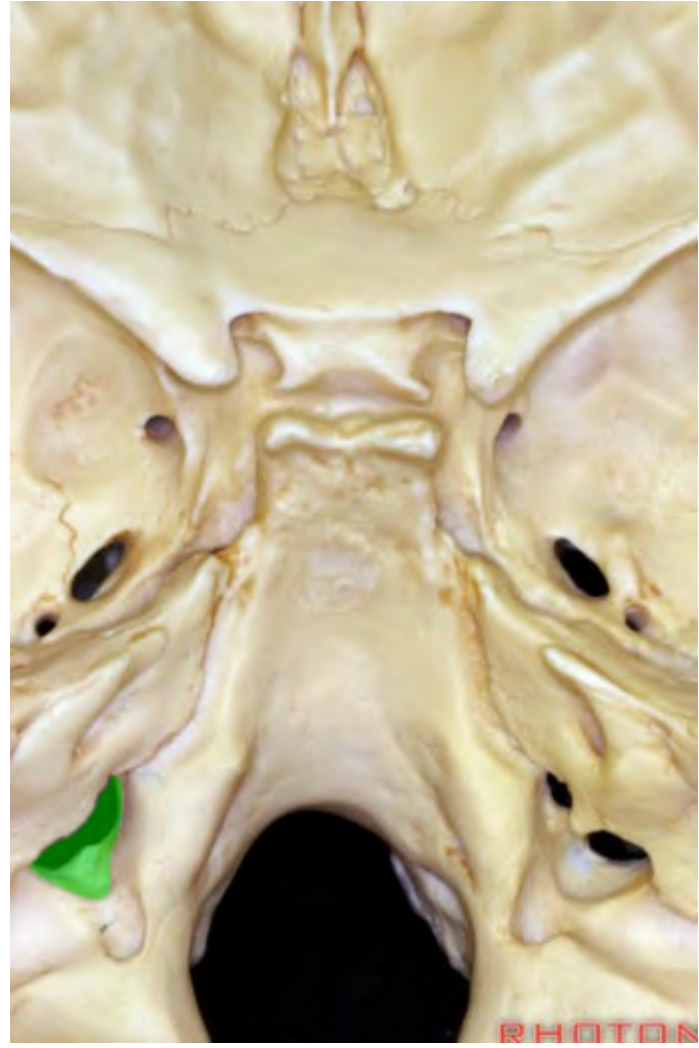


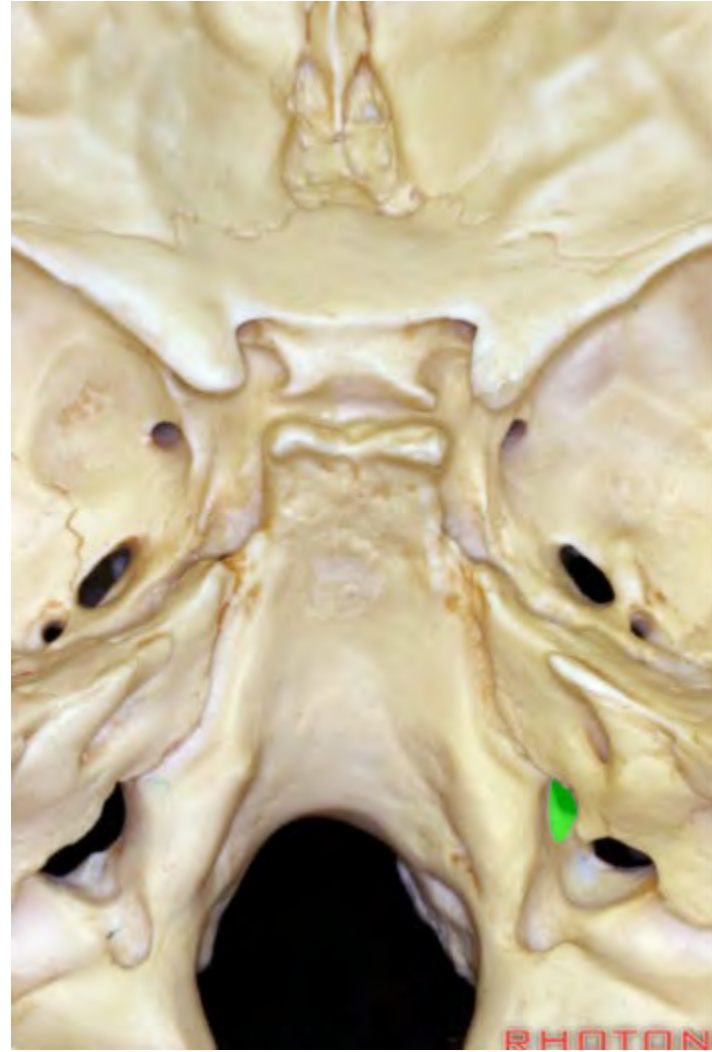


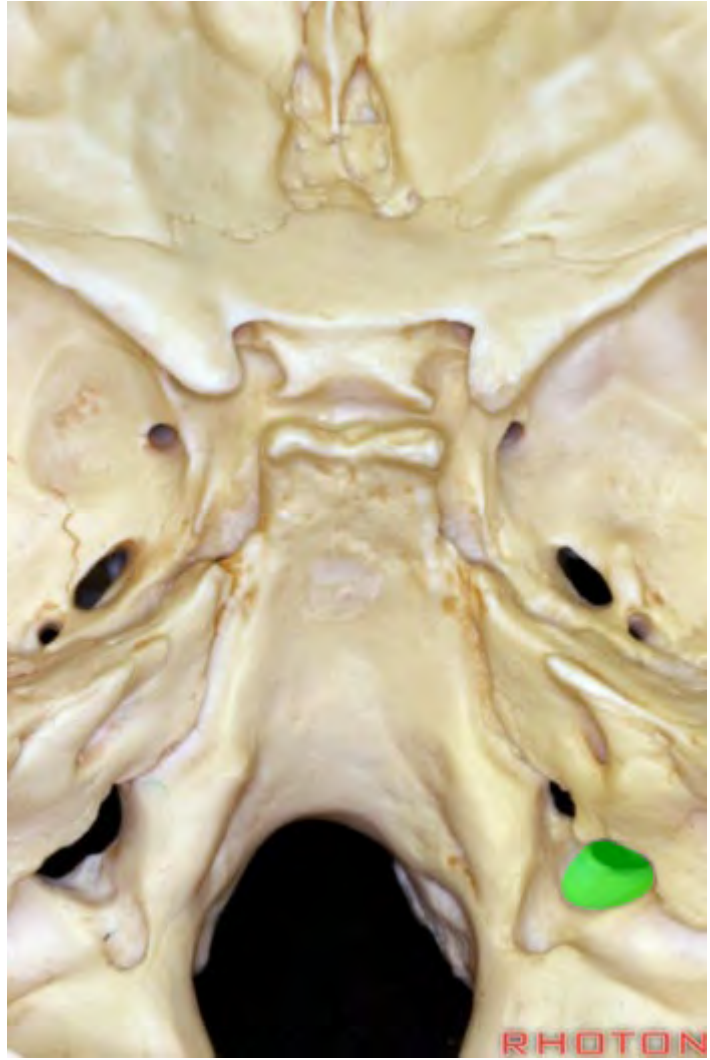


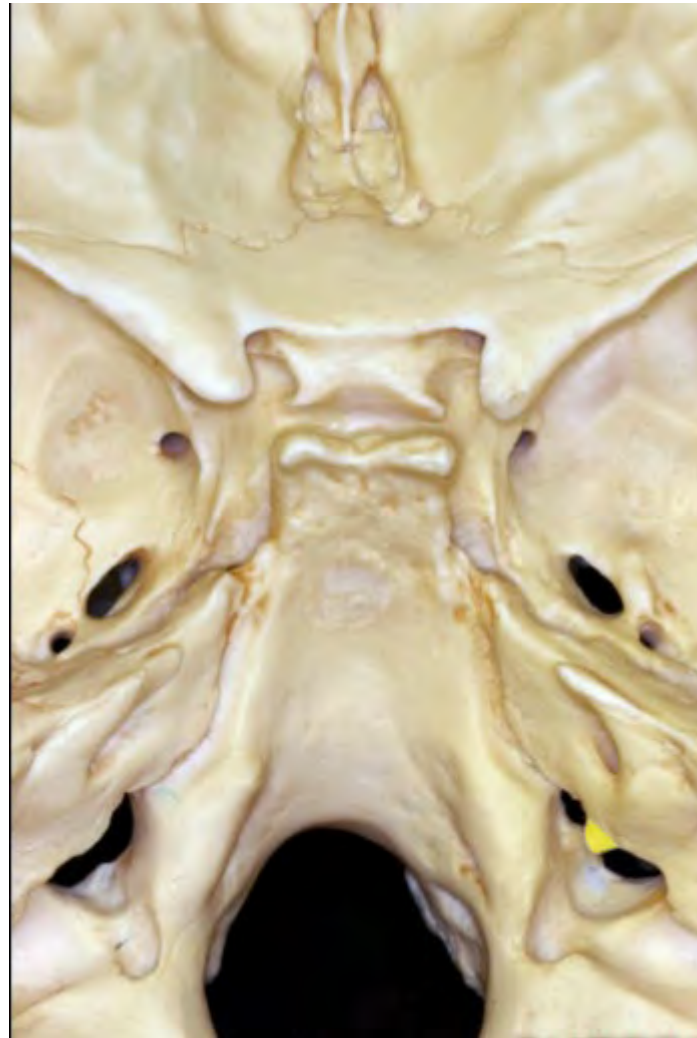


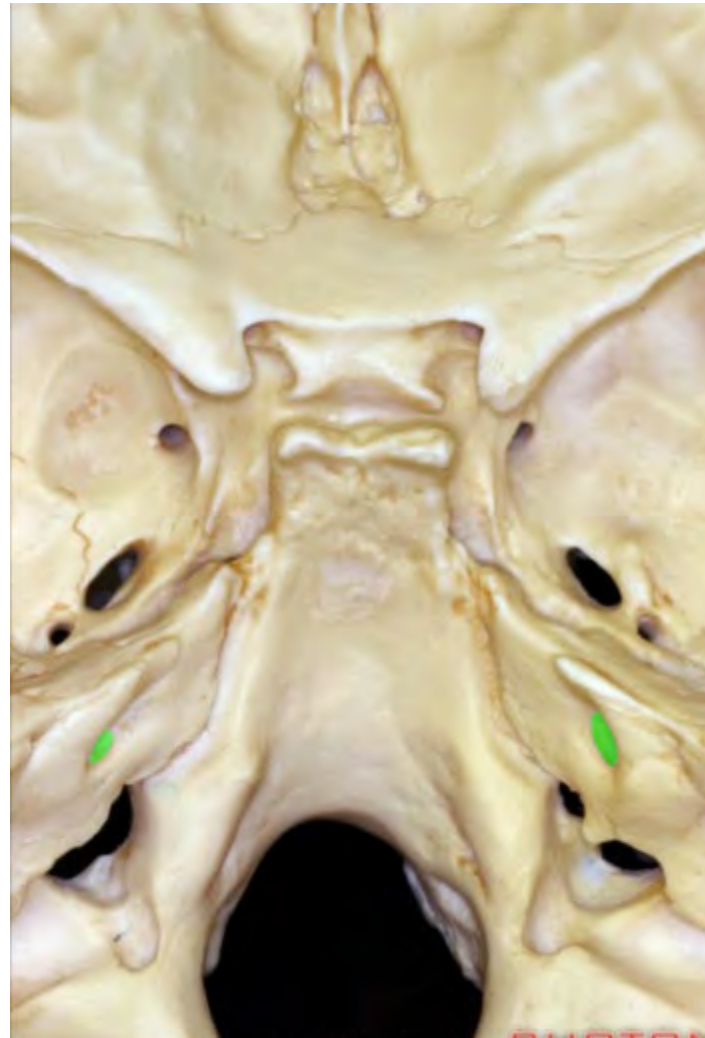


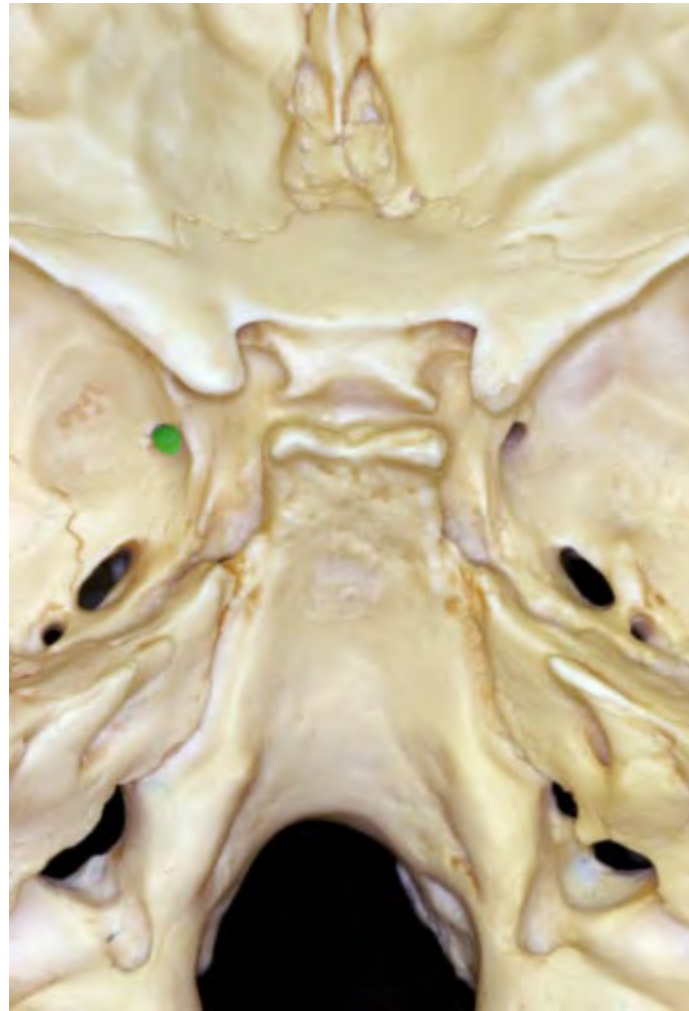




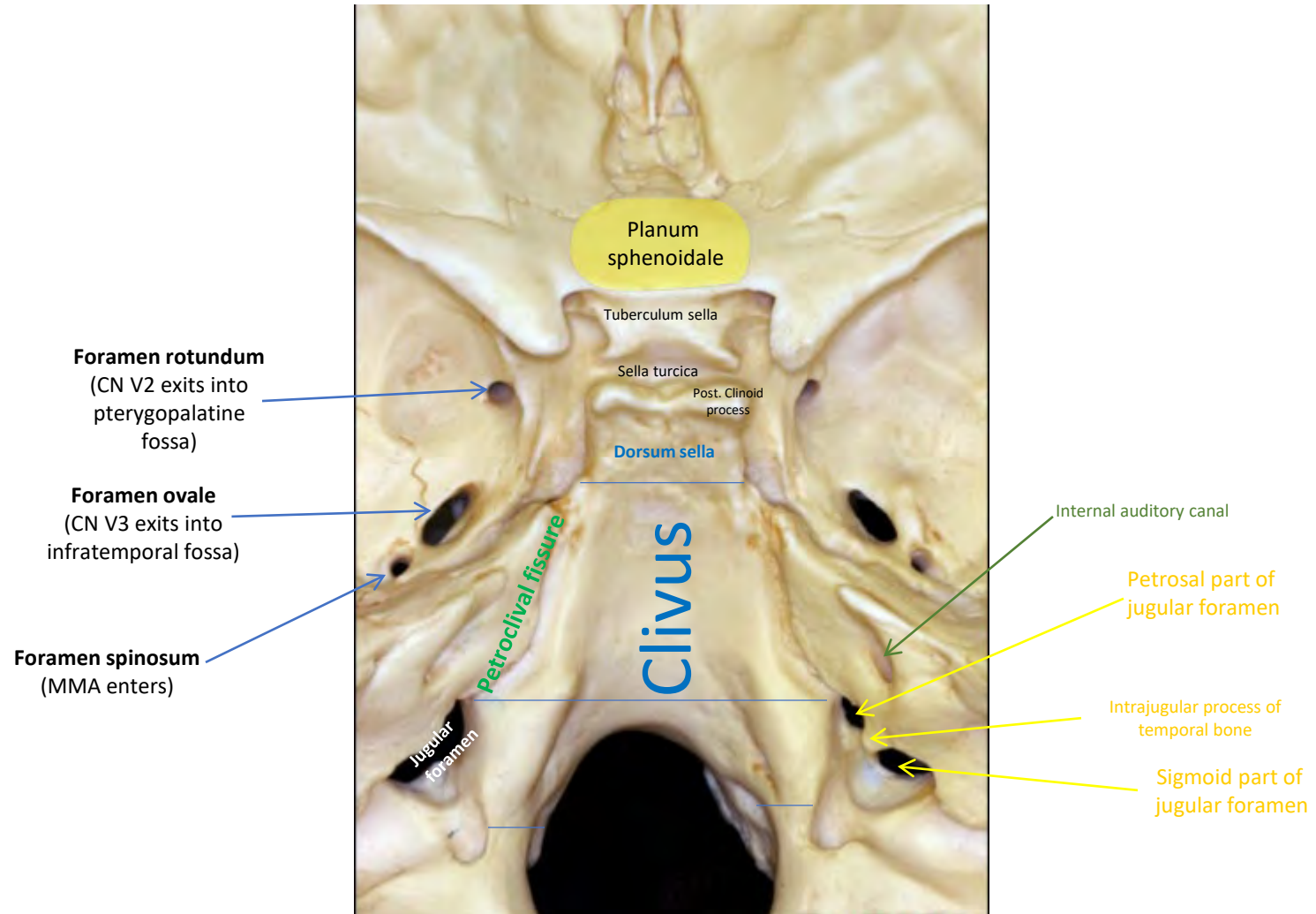


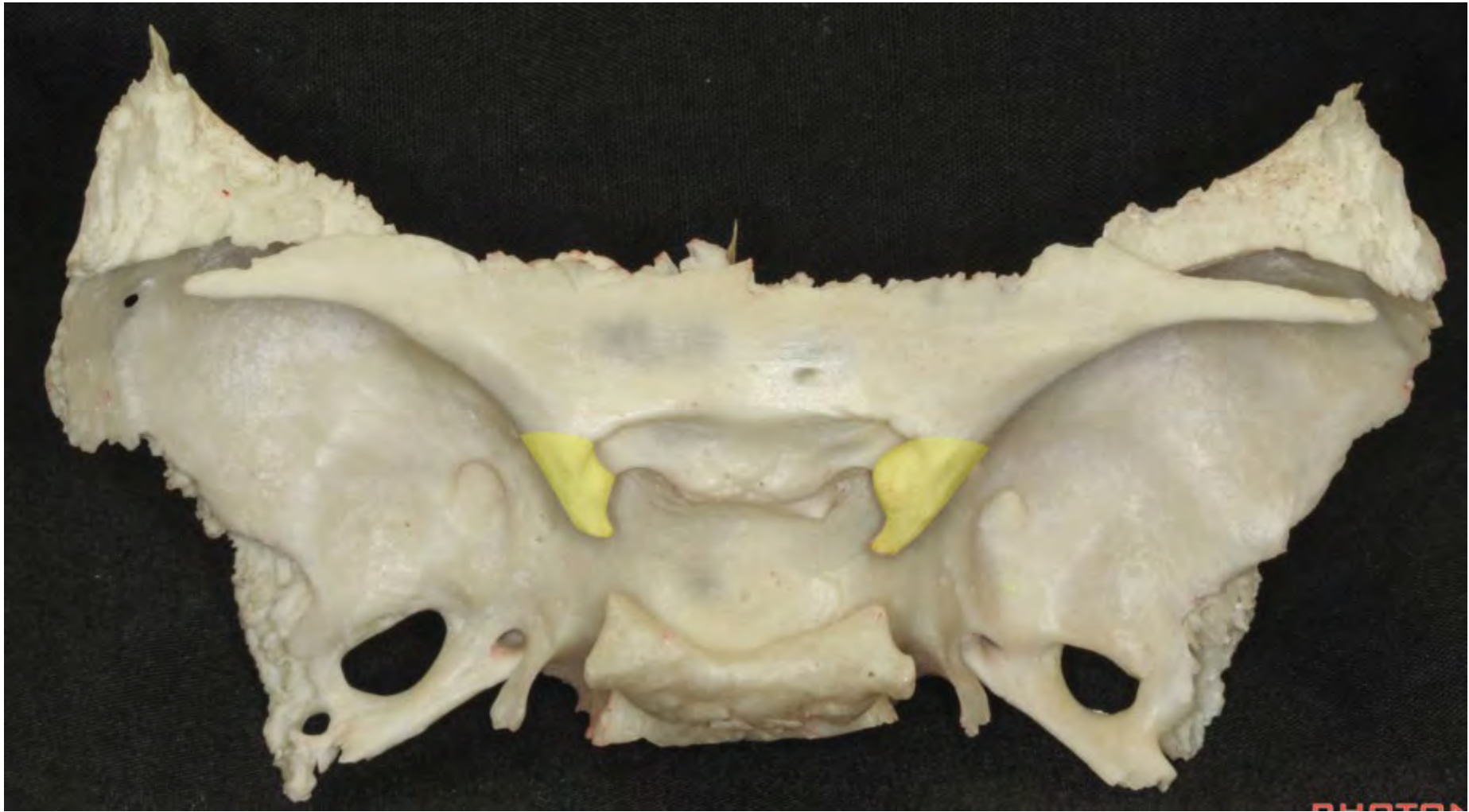




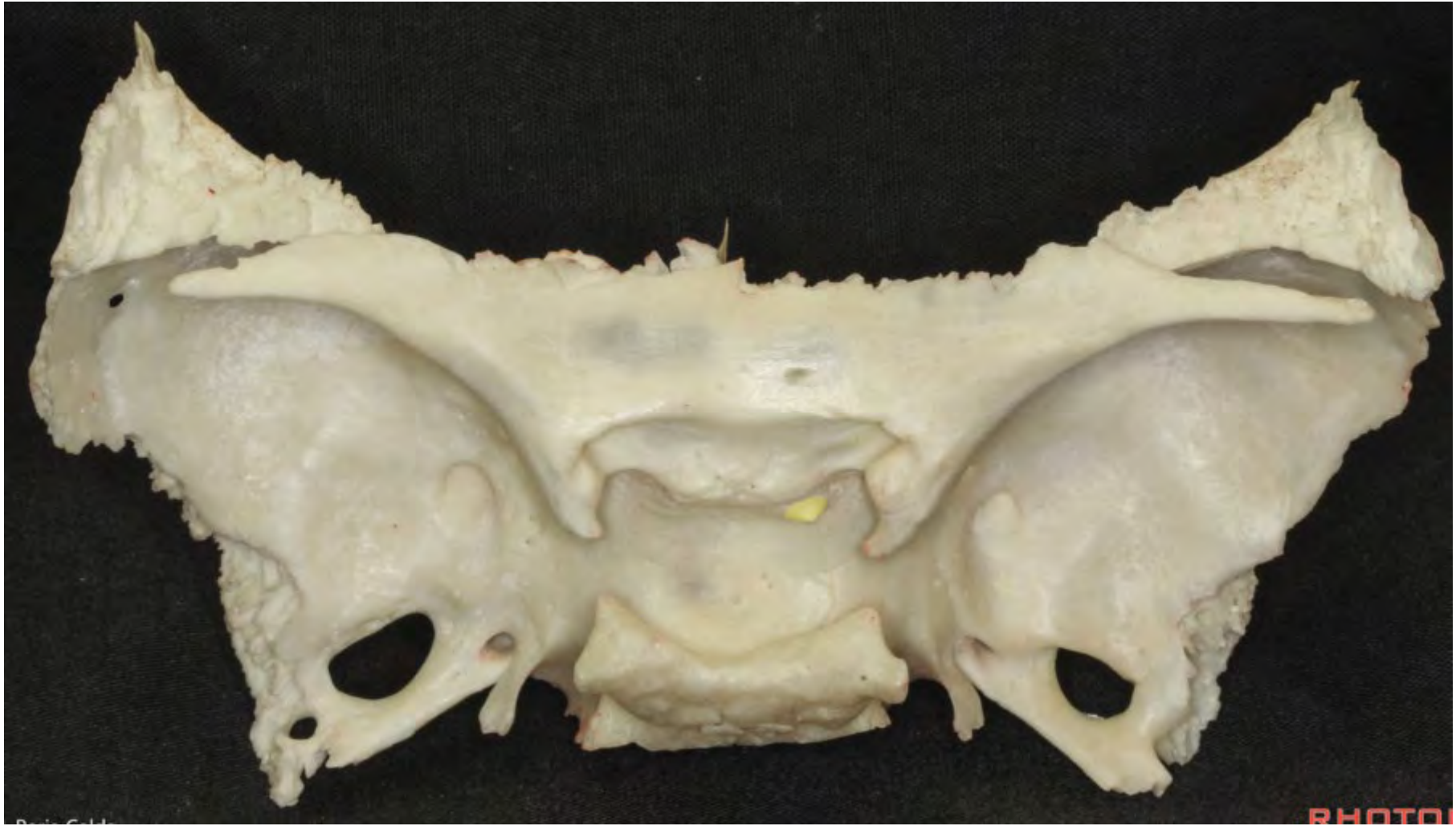


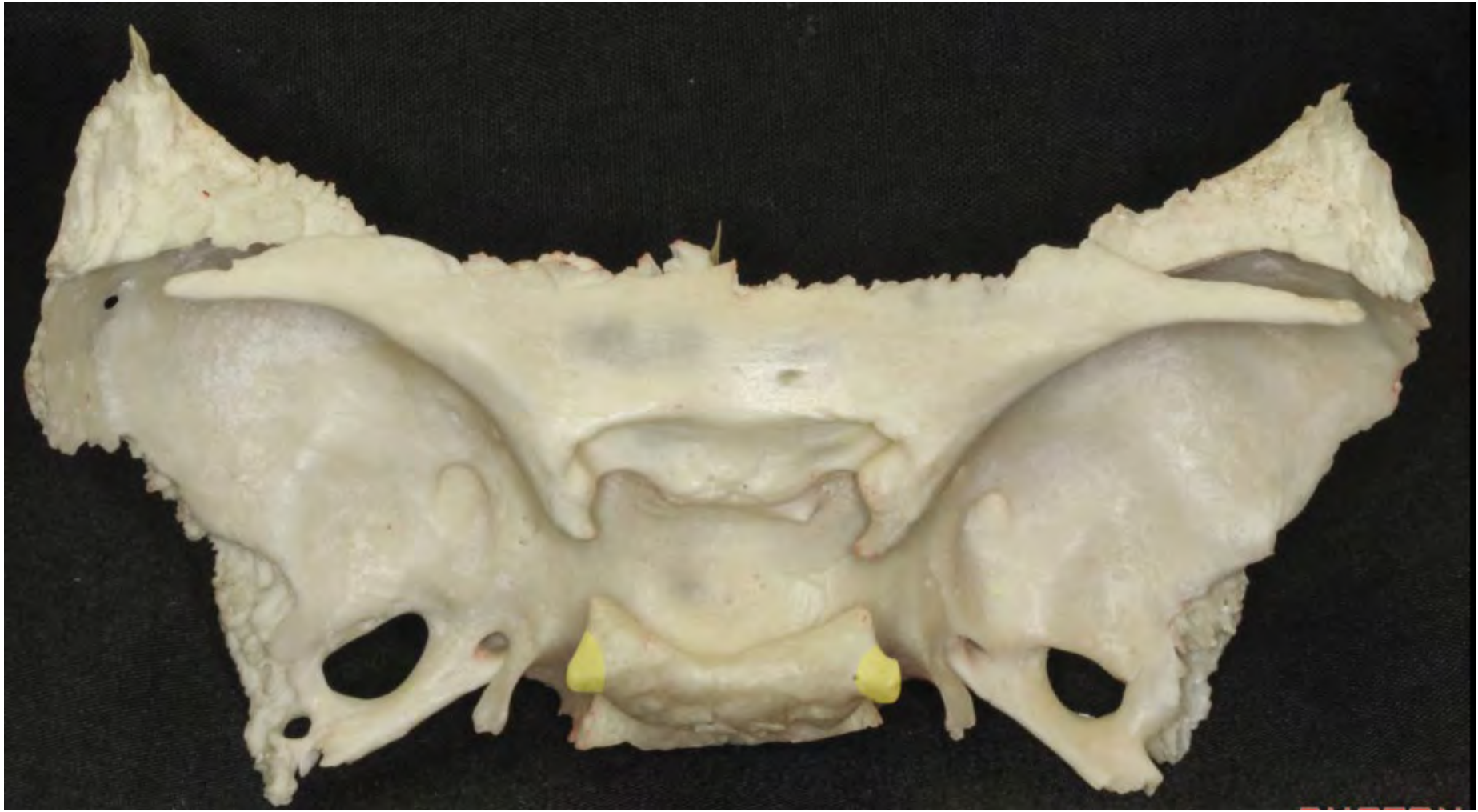


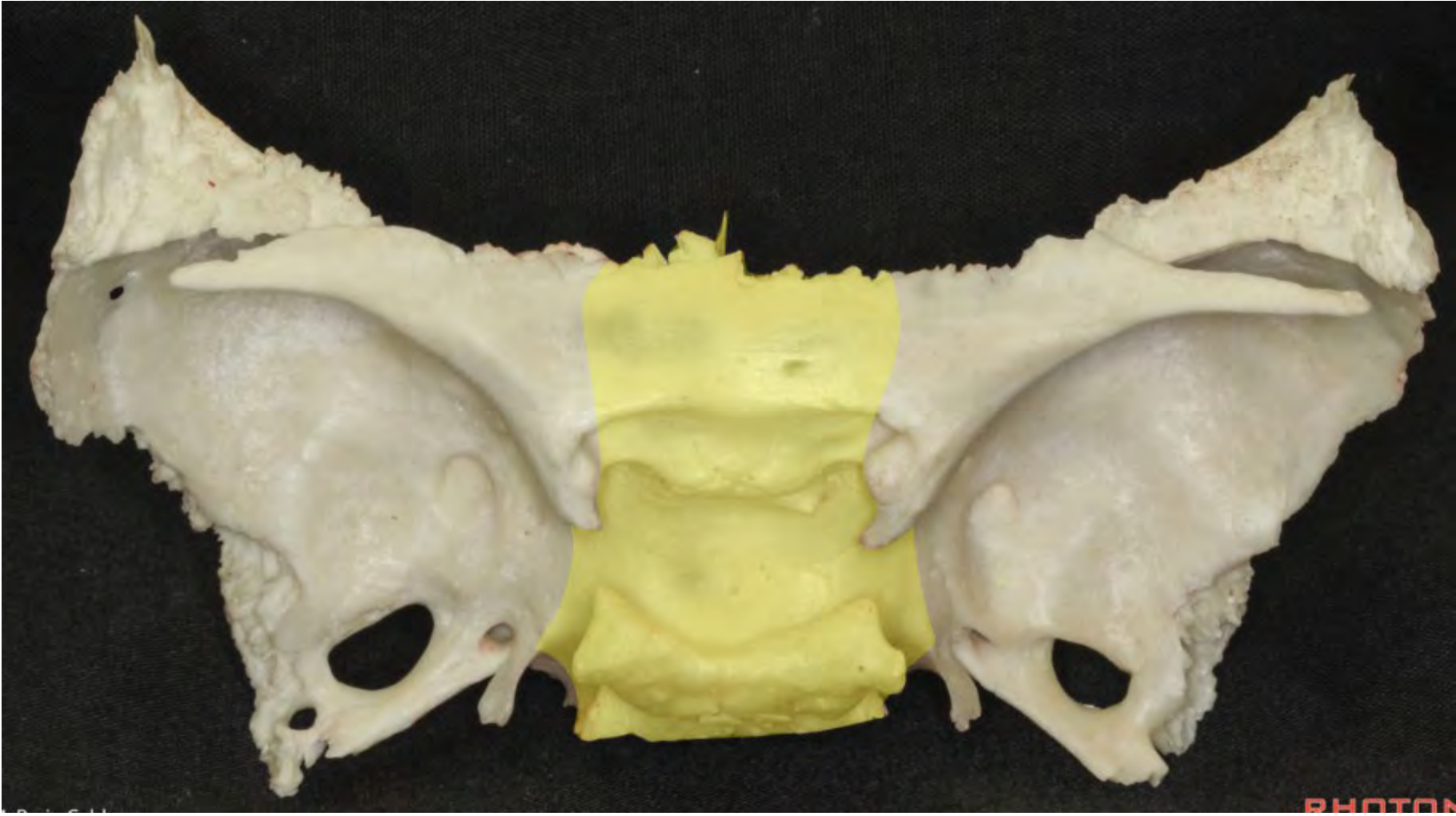


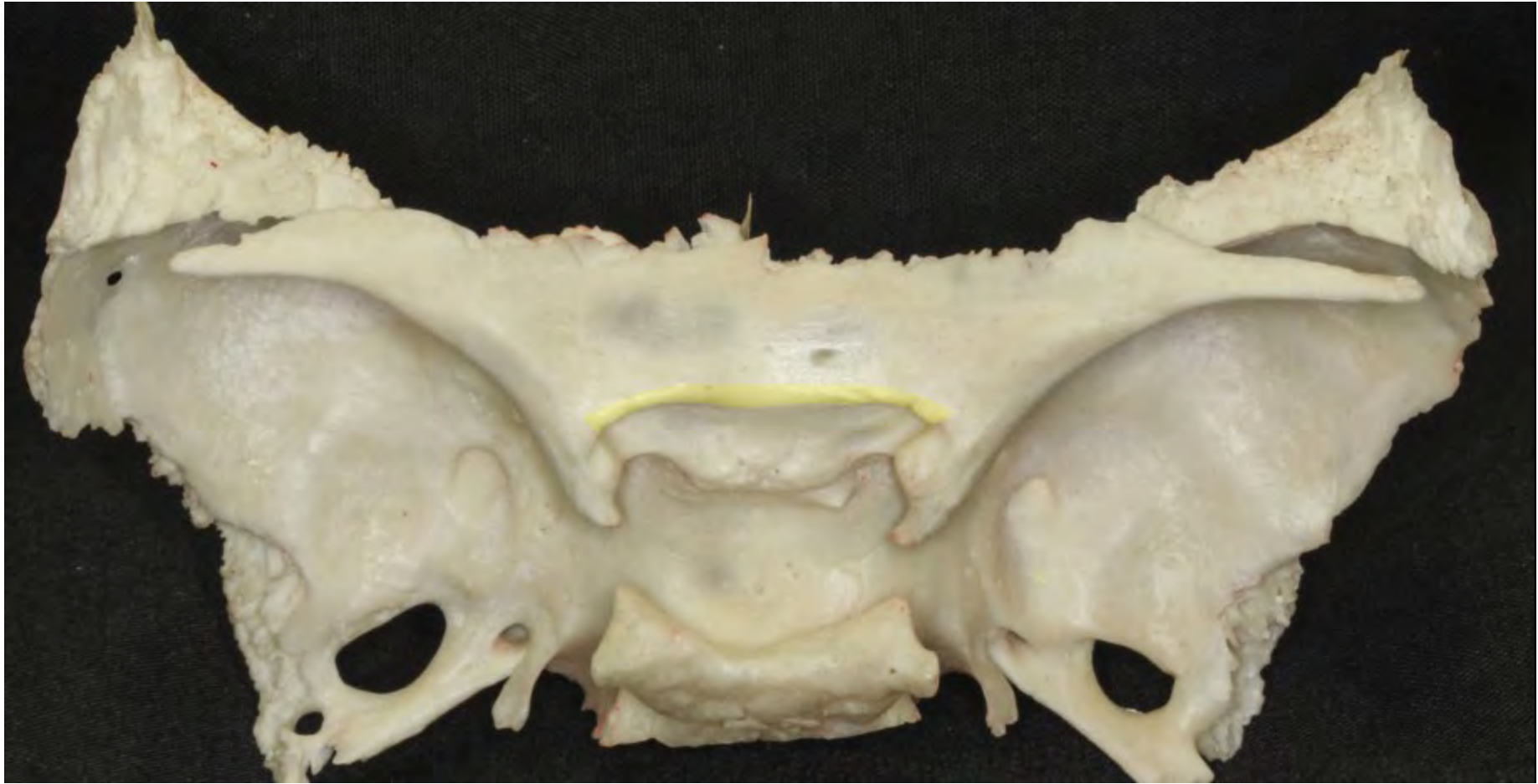


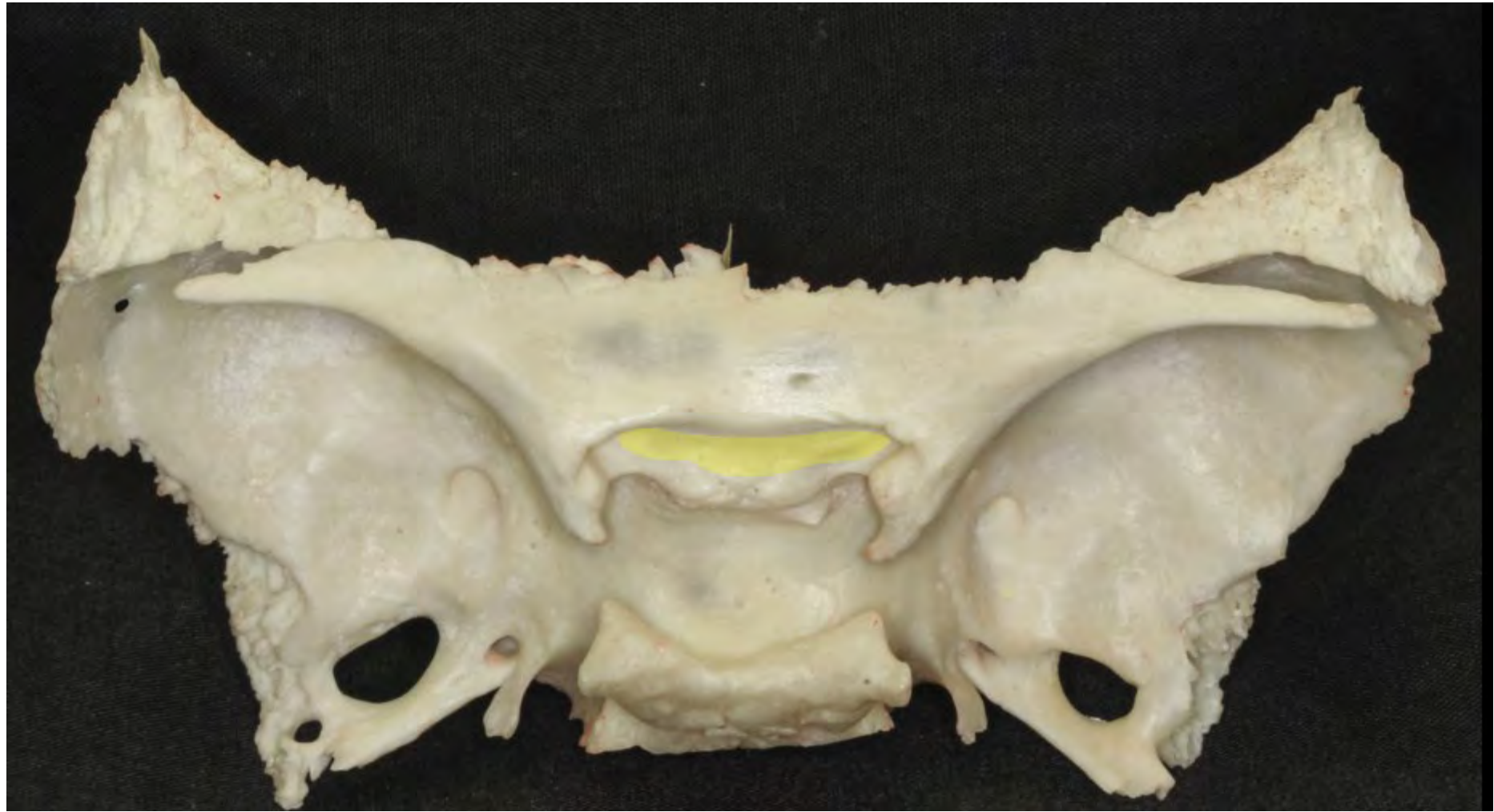
PHOTO

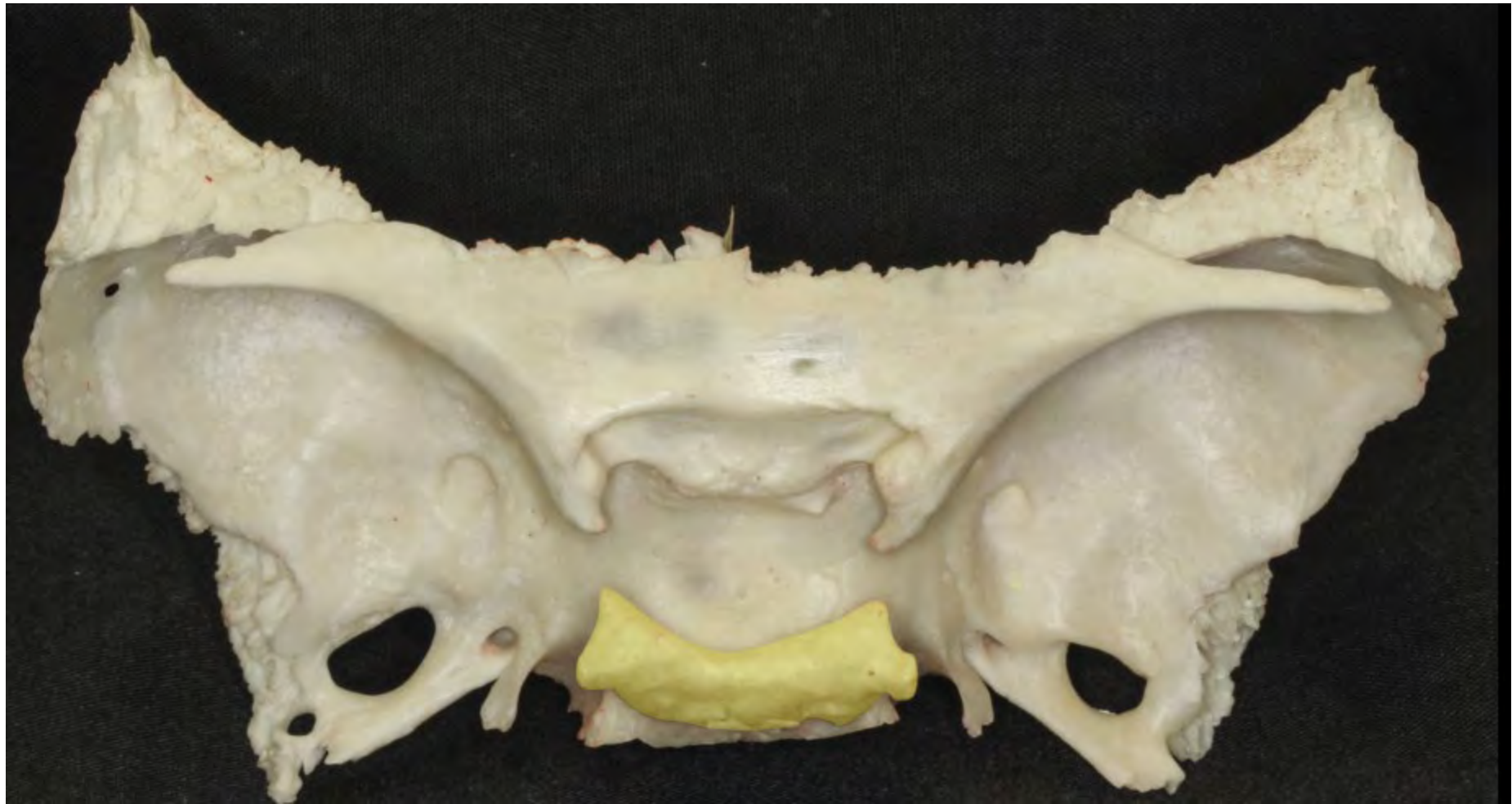




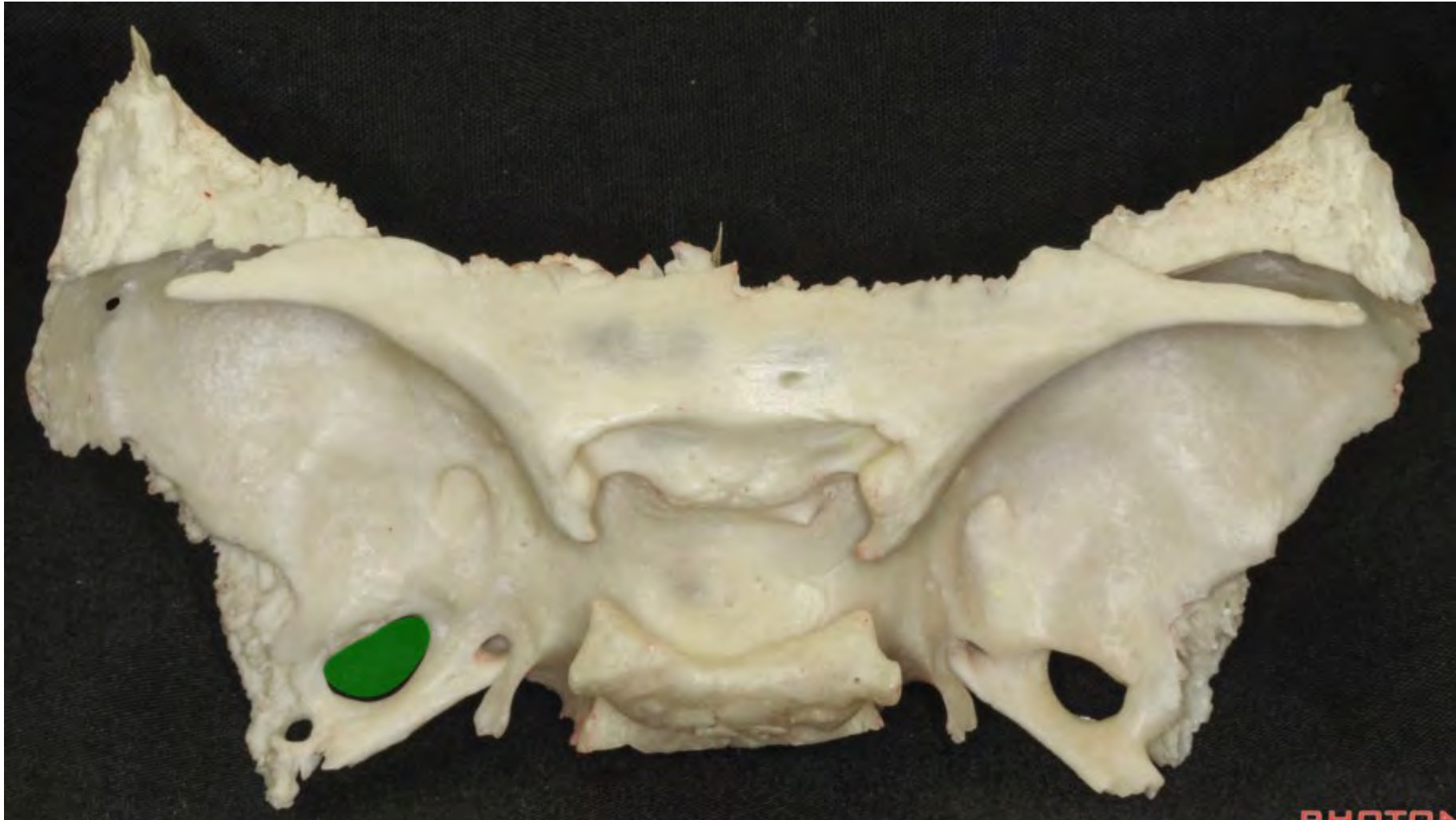


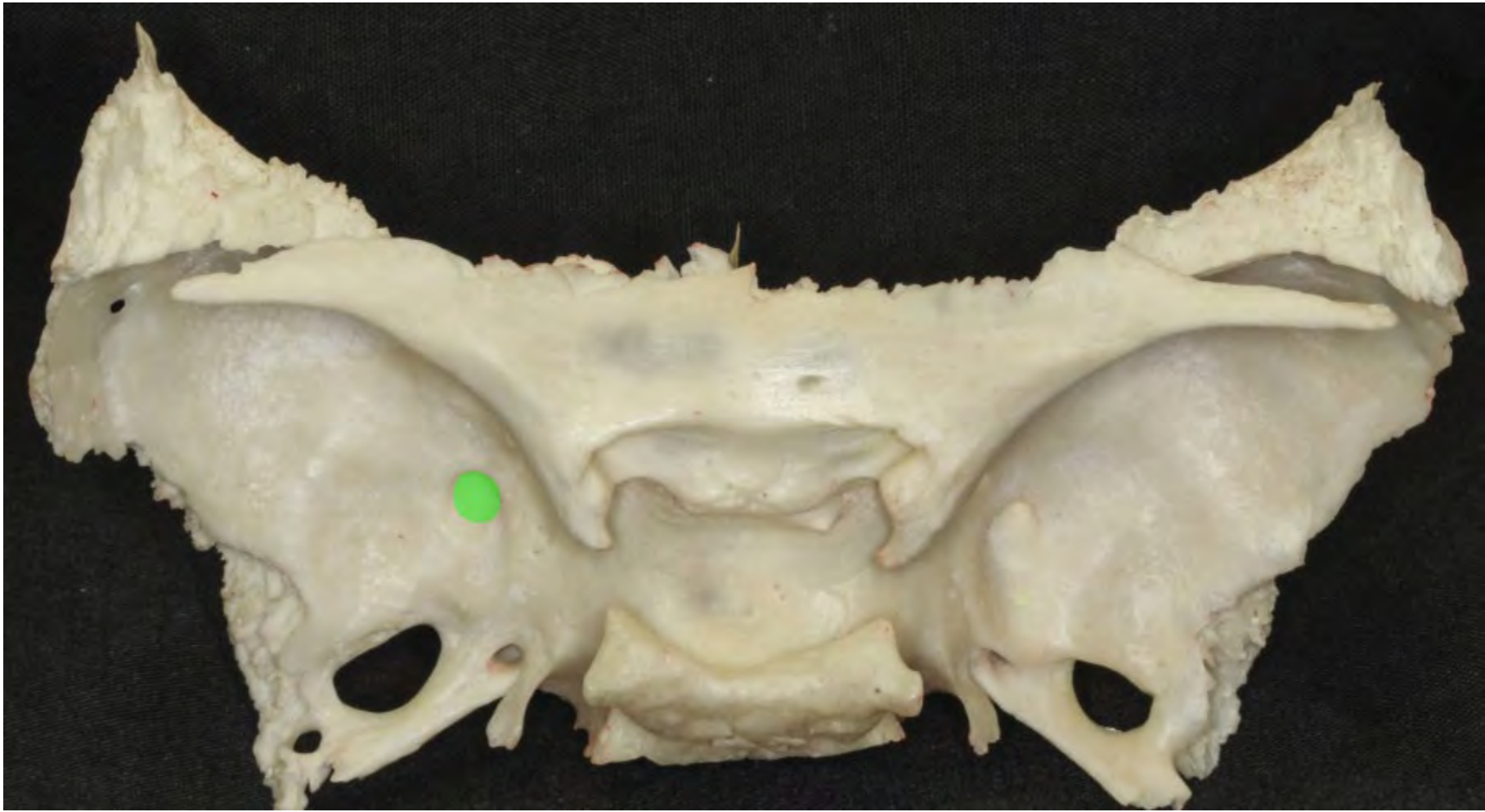


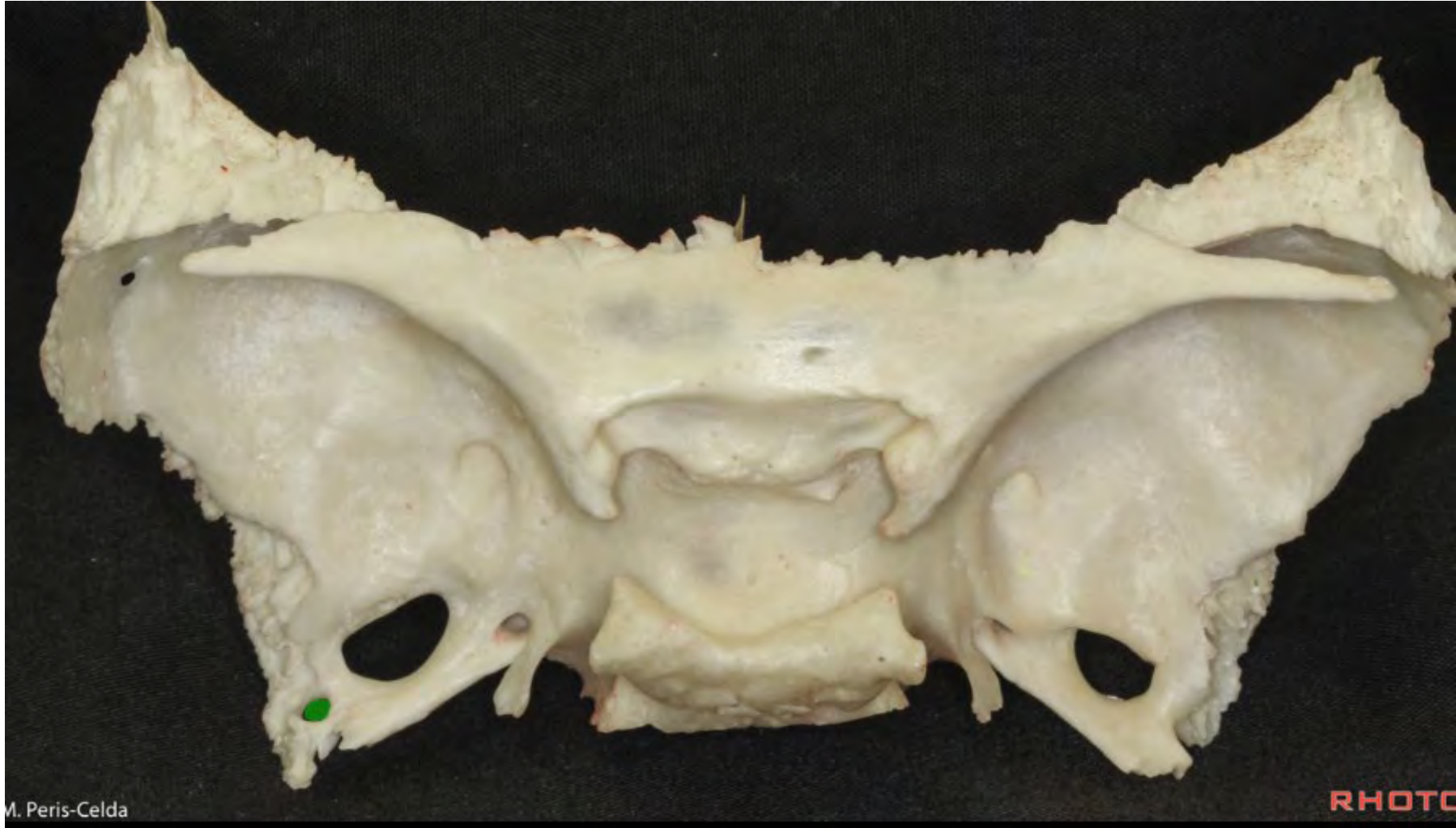






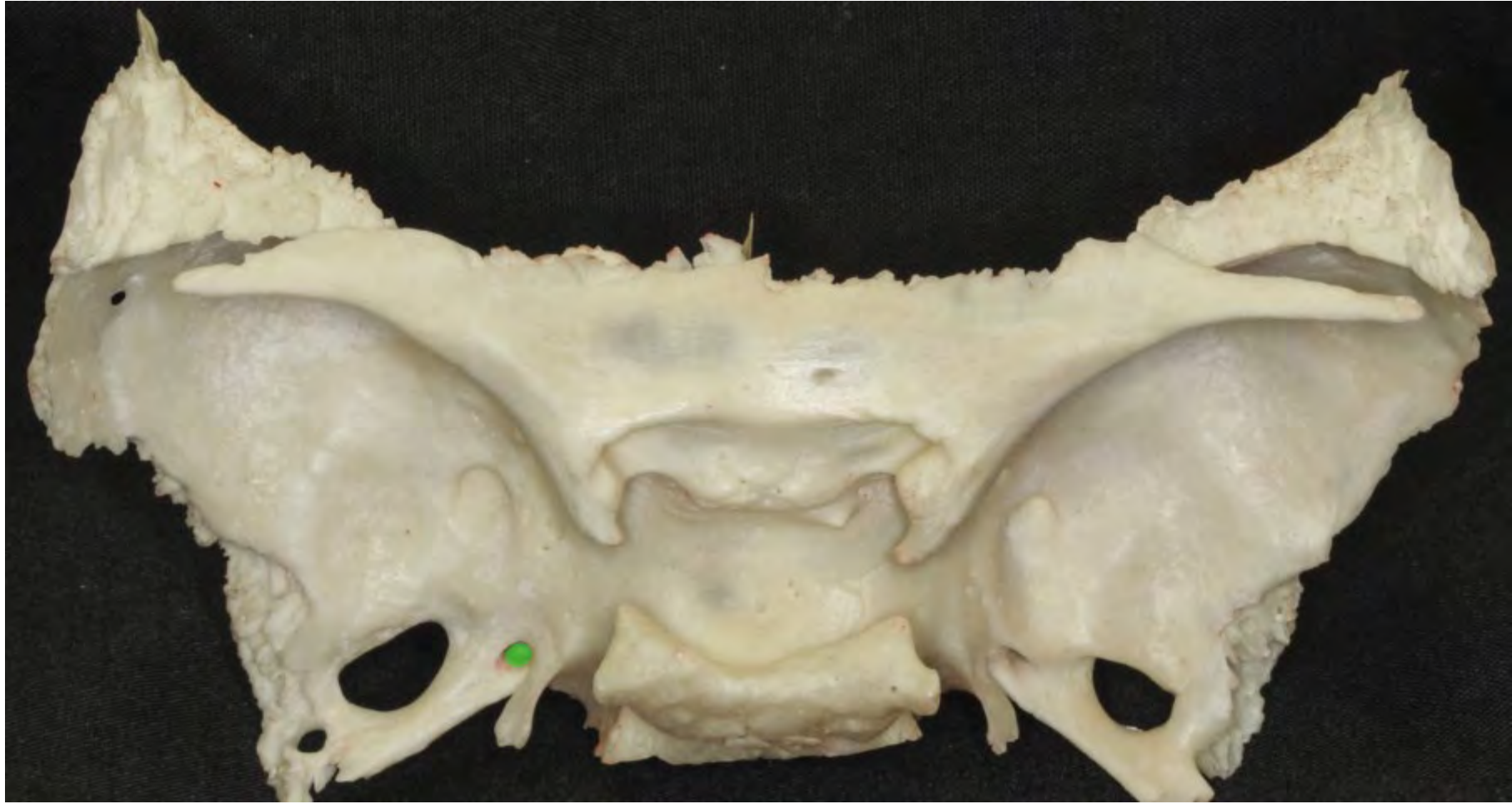


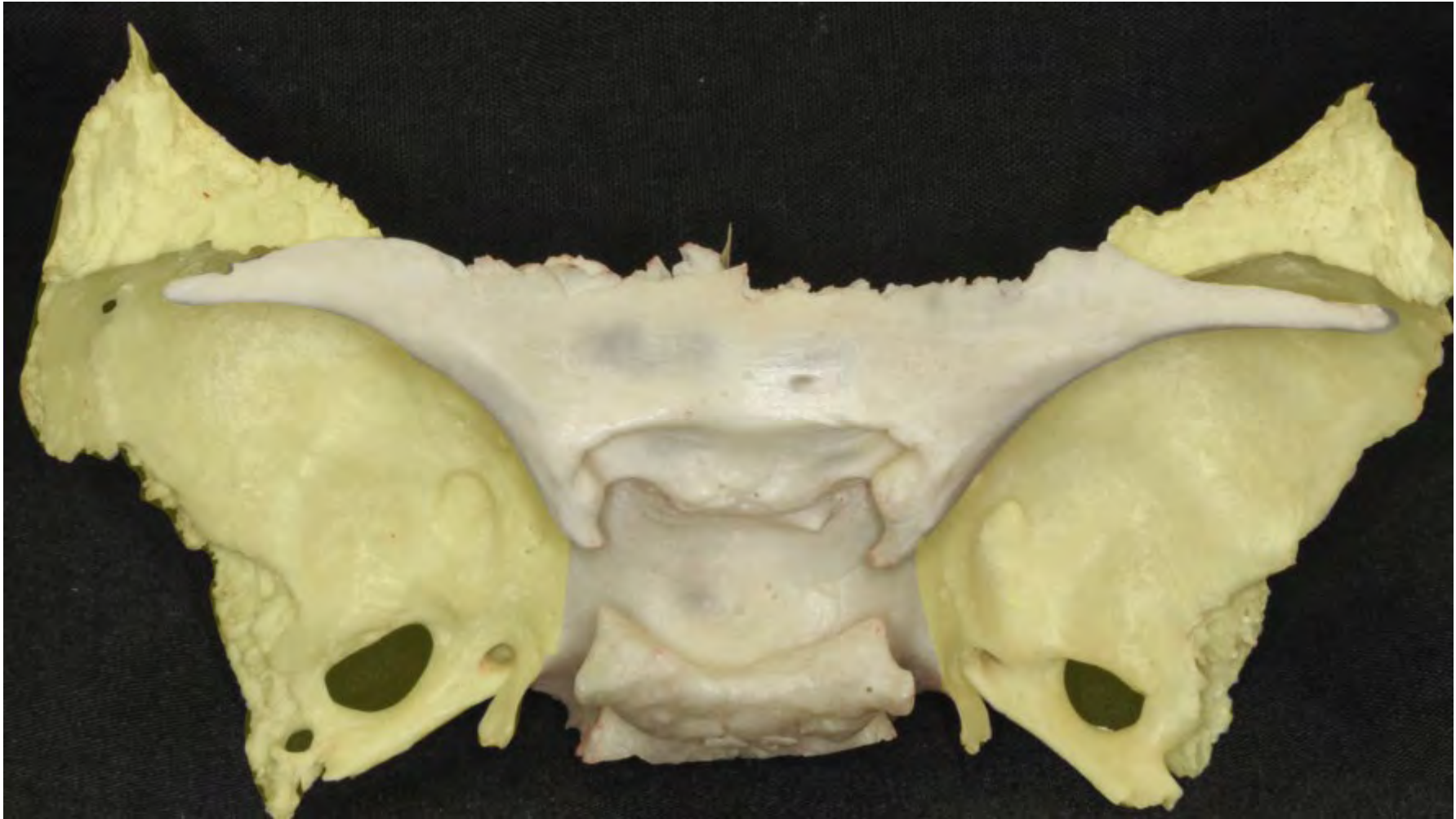

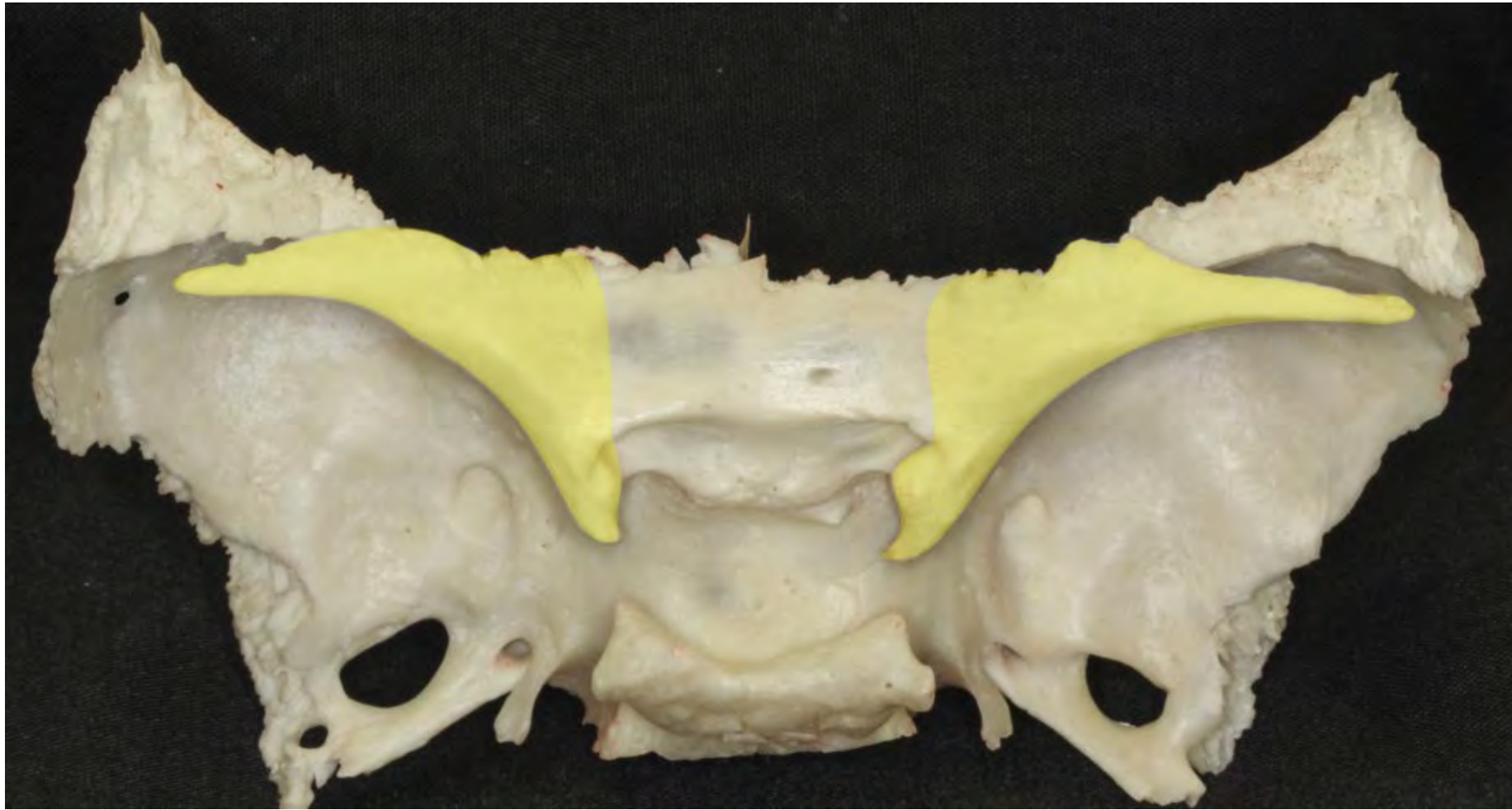


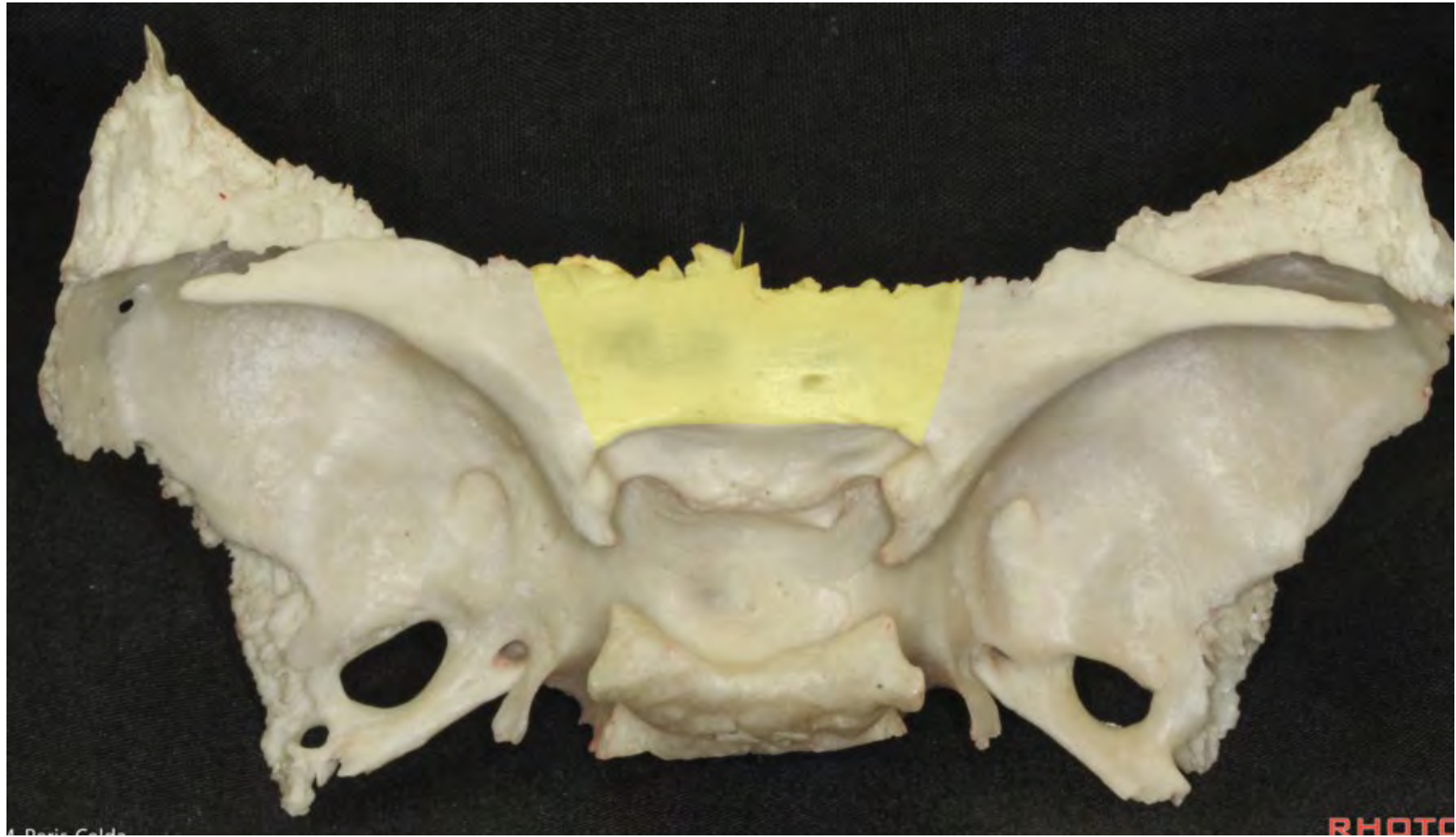
M. Peris-Celda

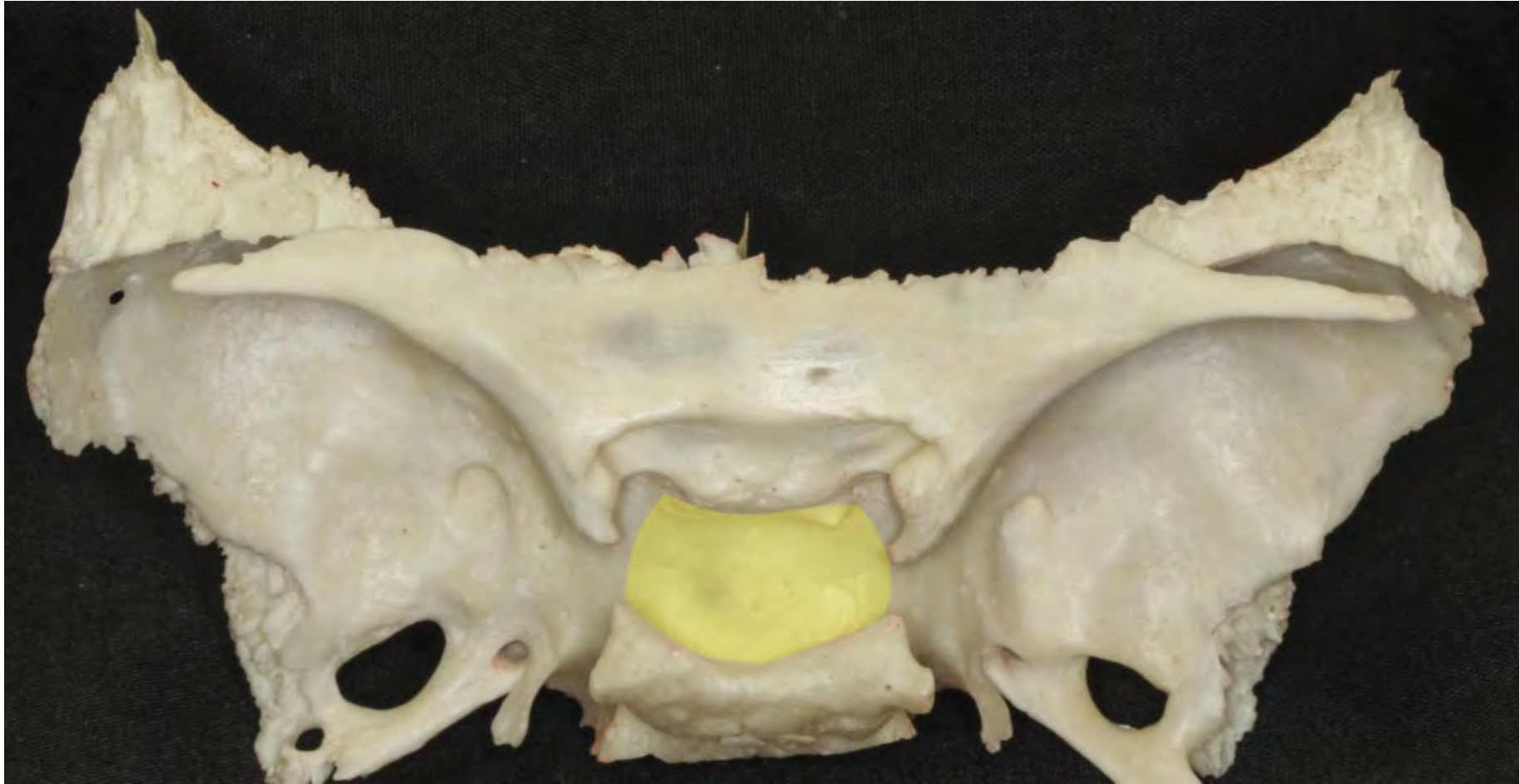
RHOTO



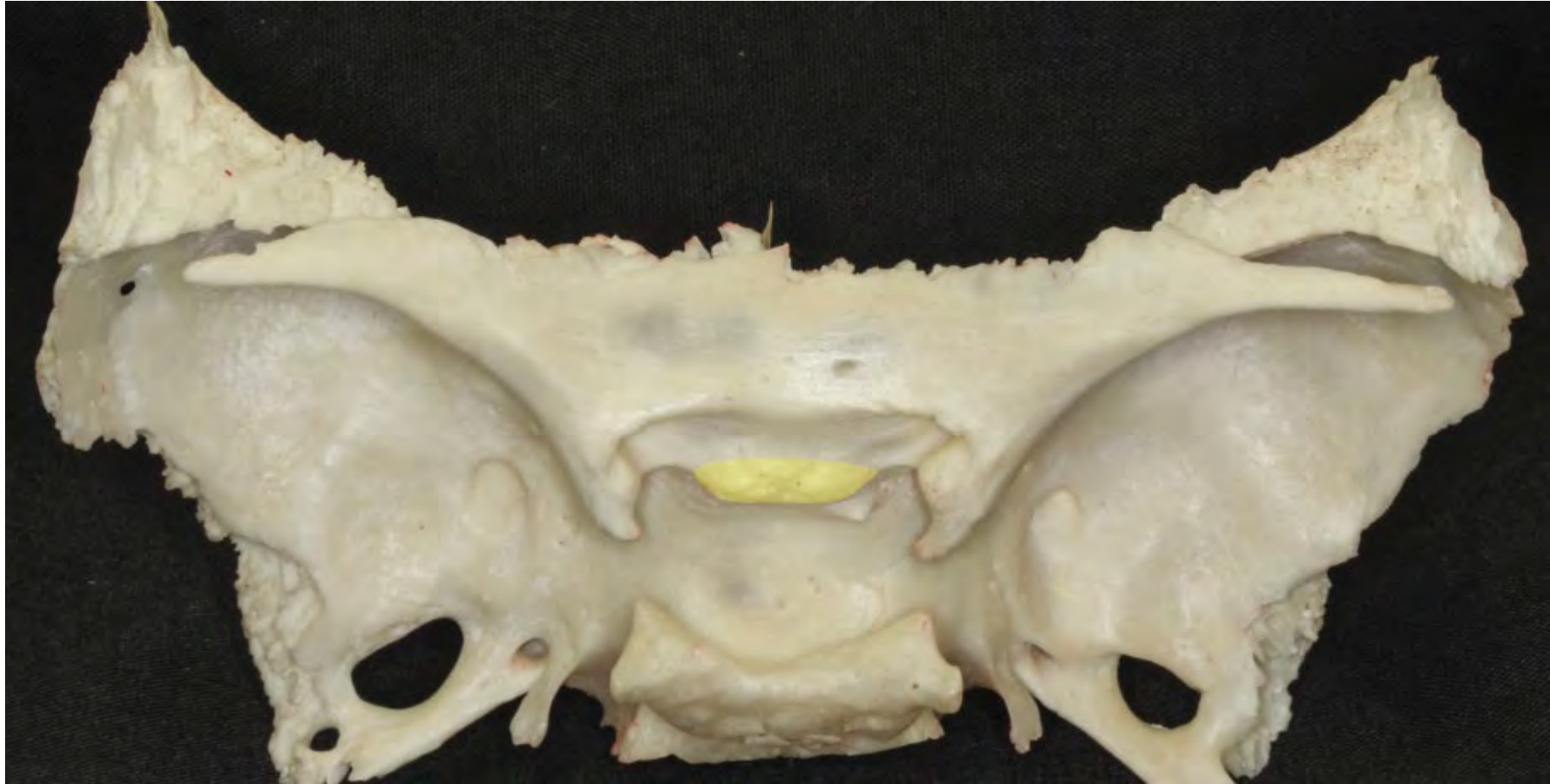


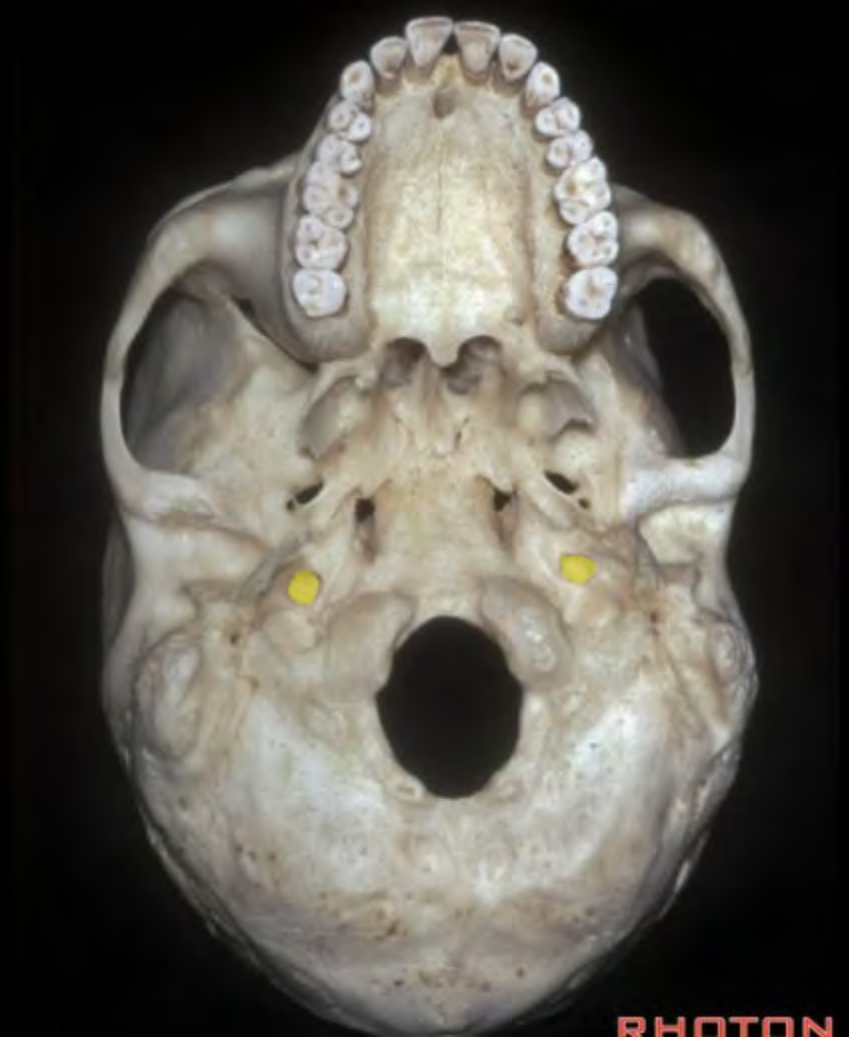


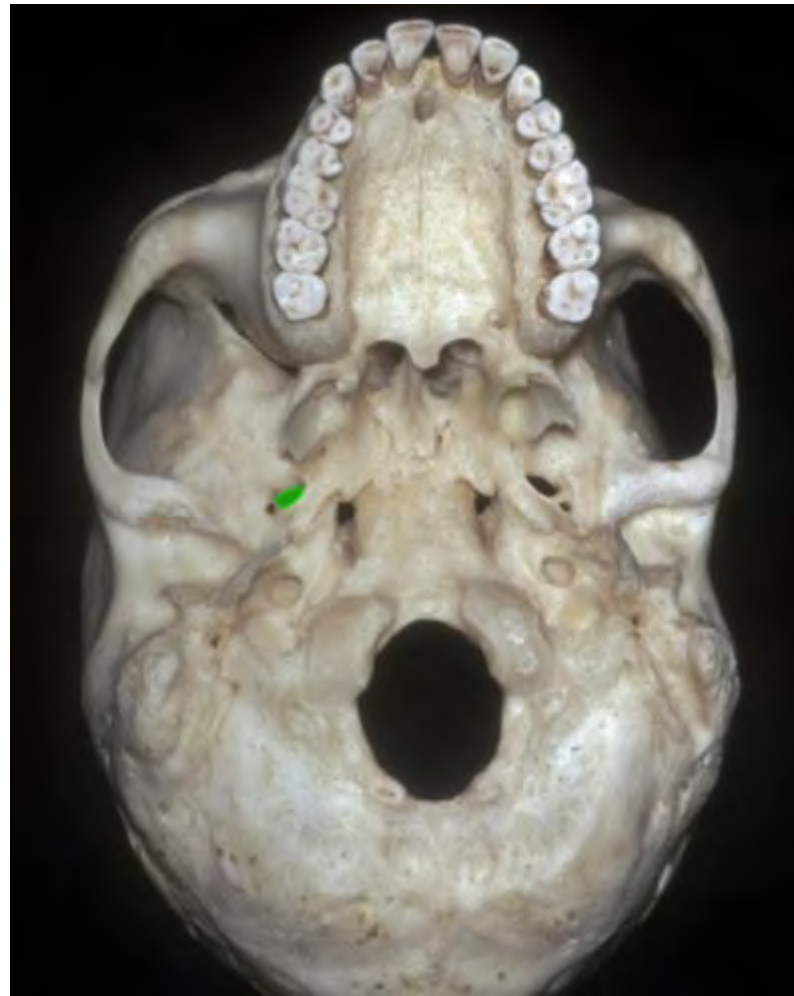


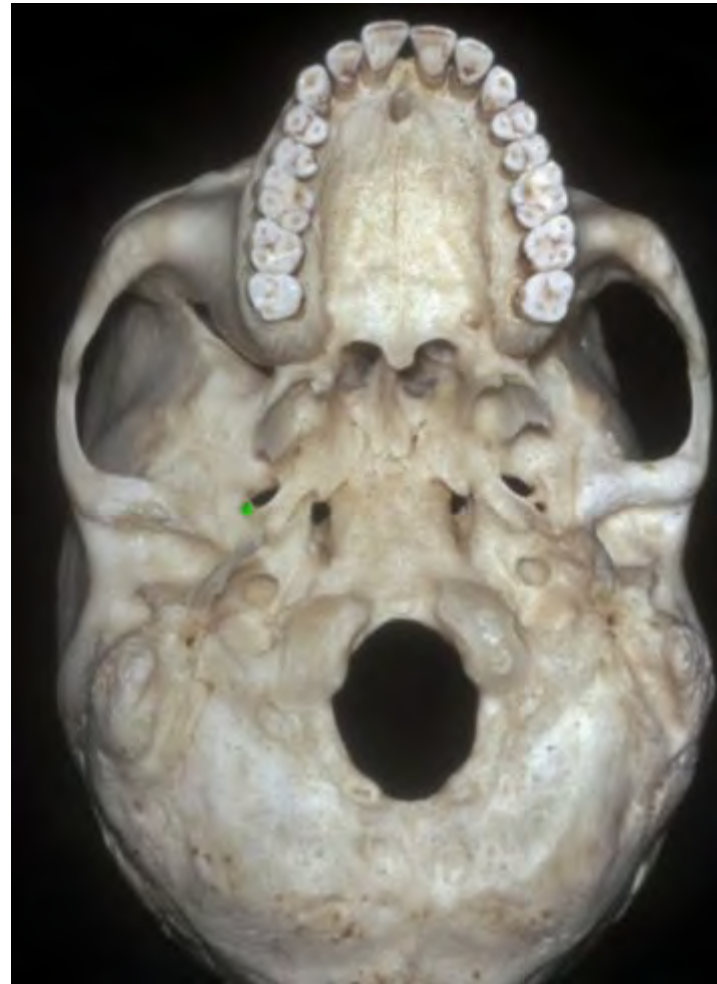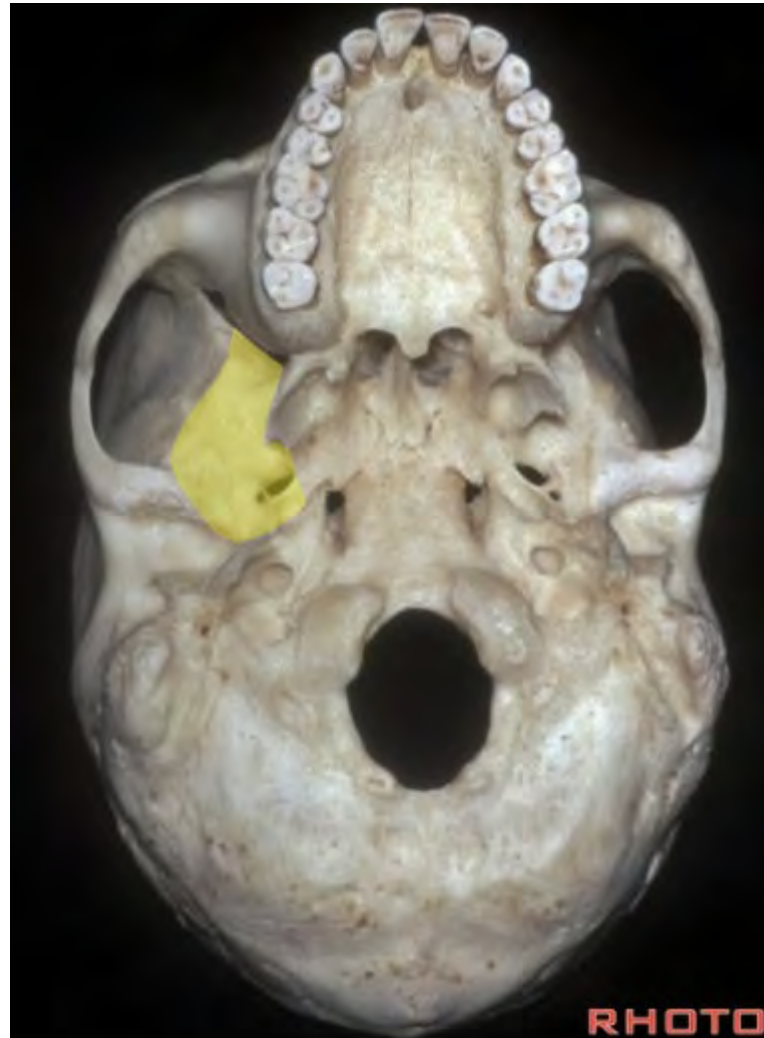





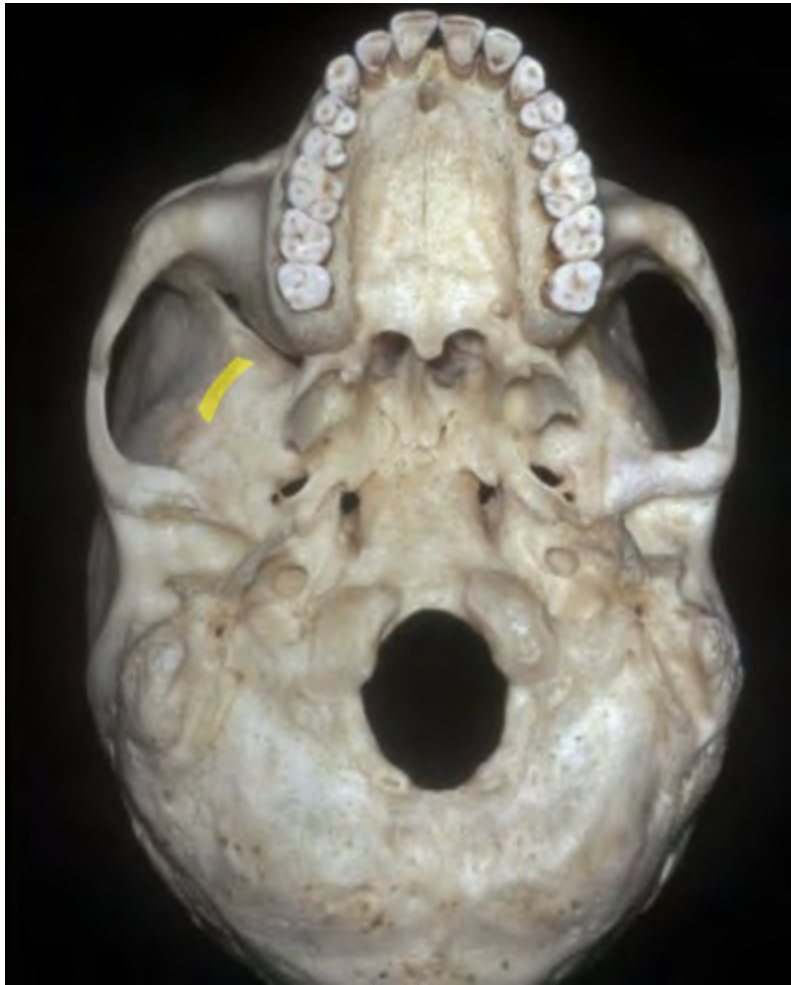


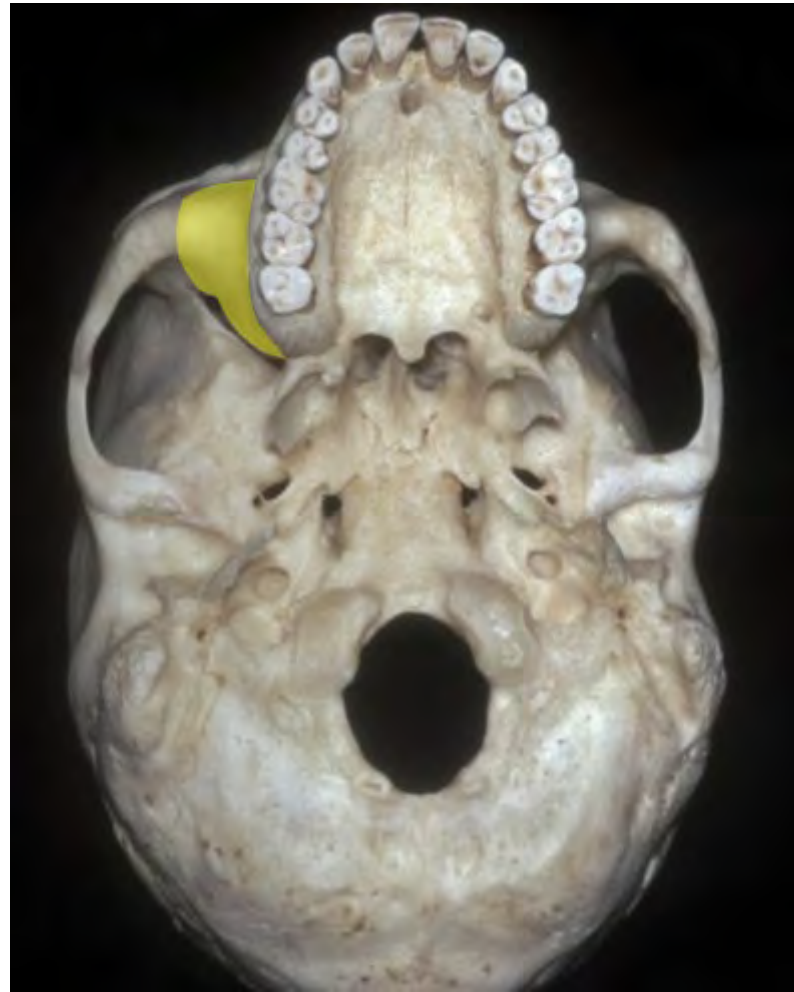


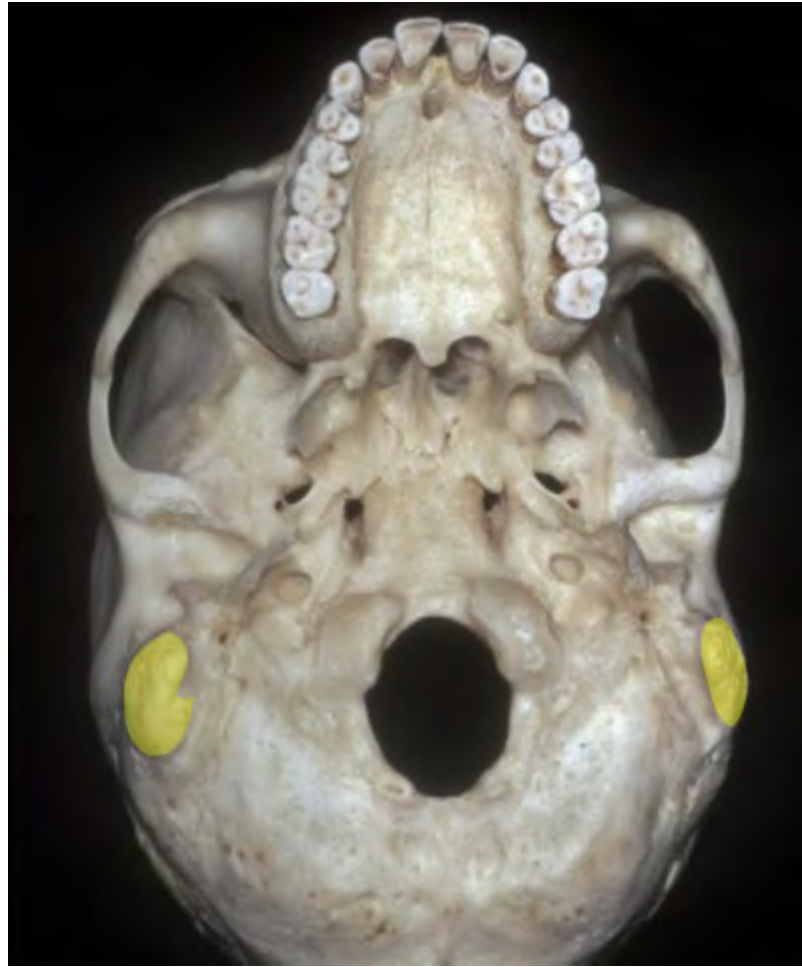




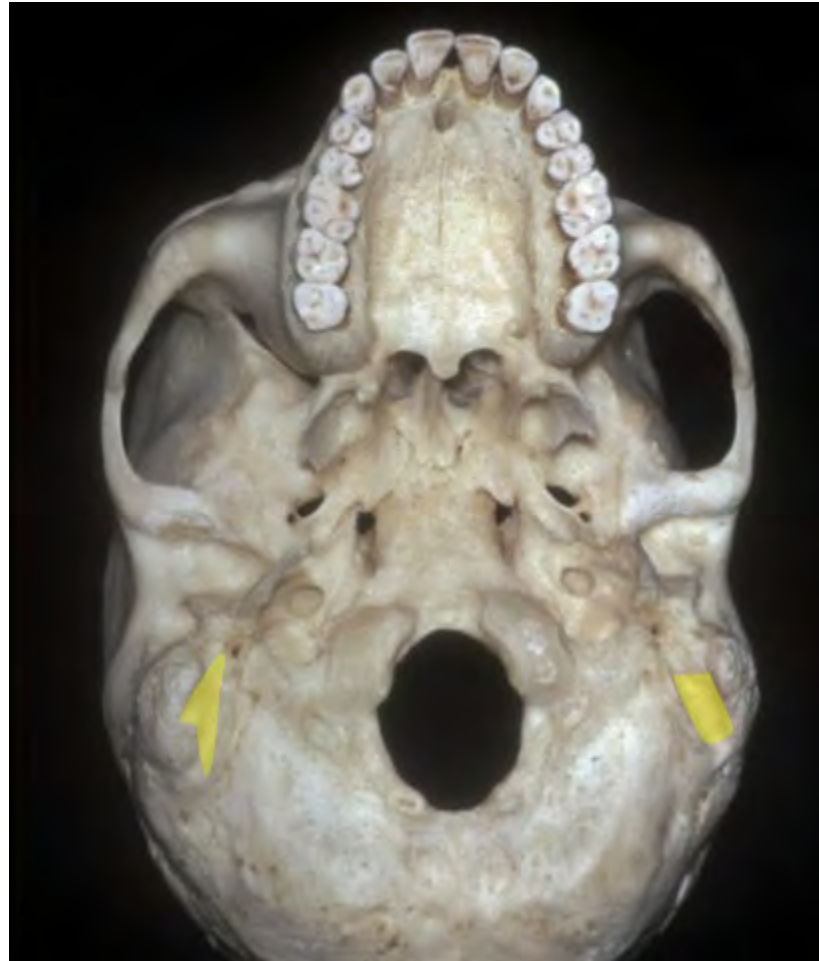


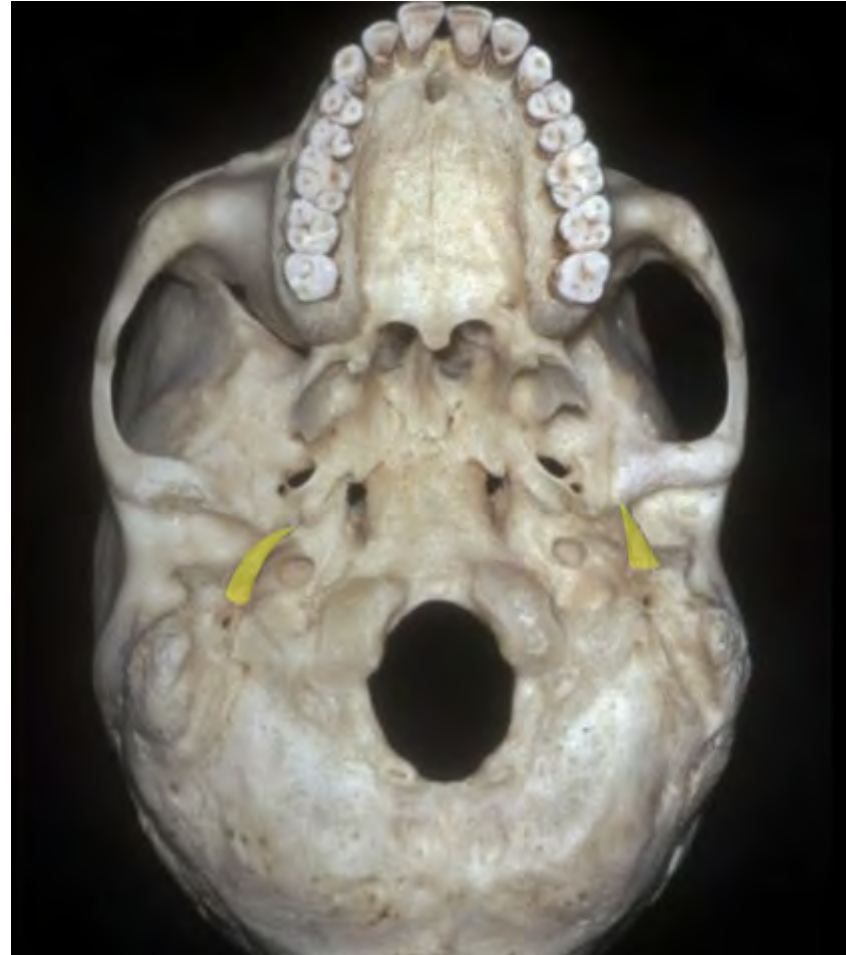


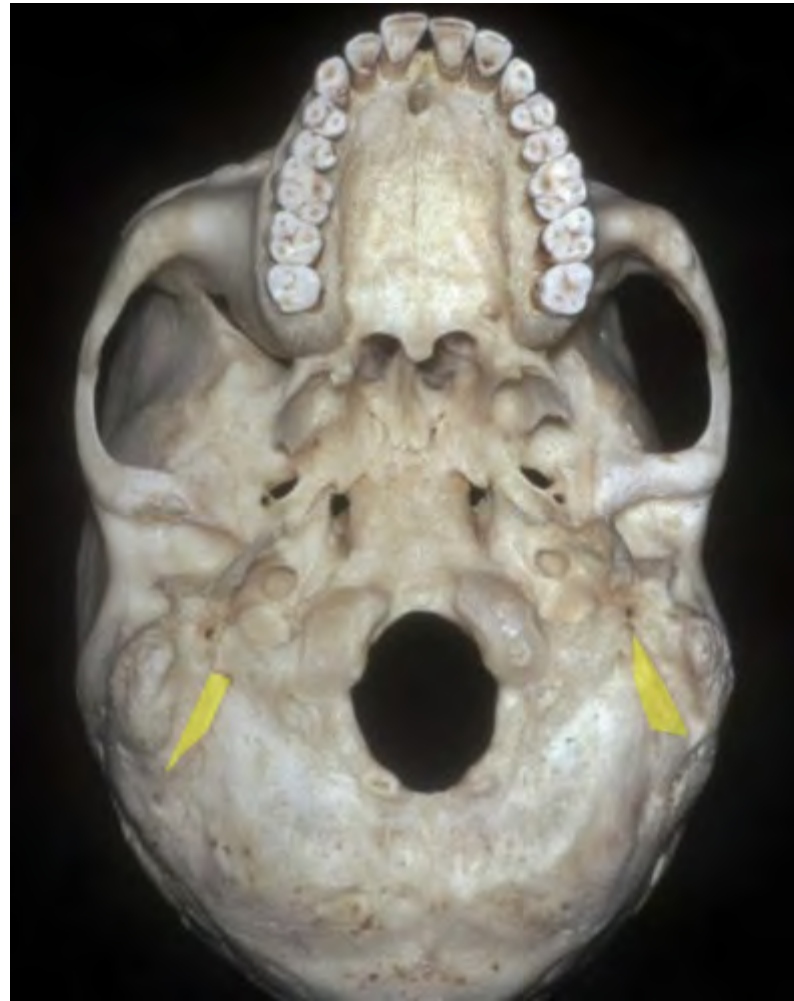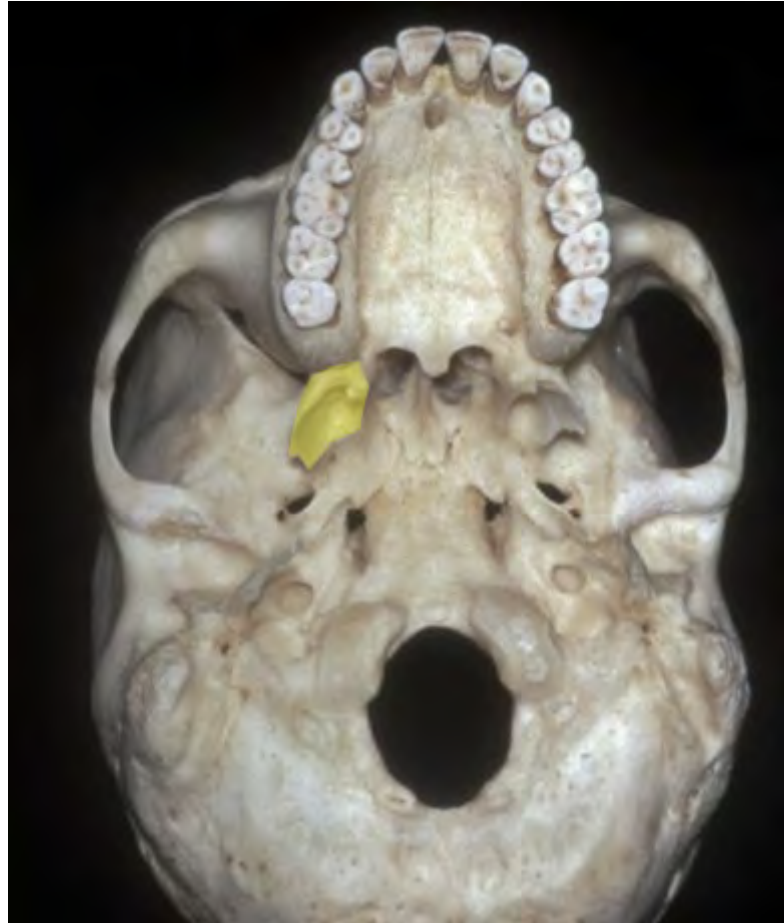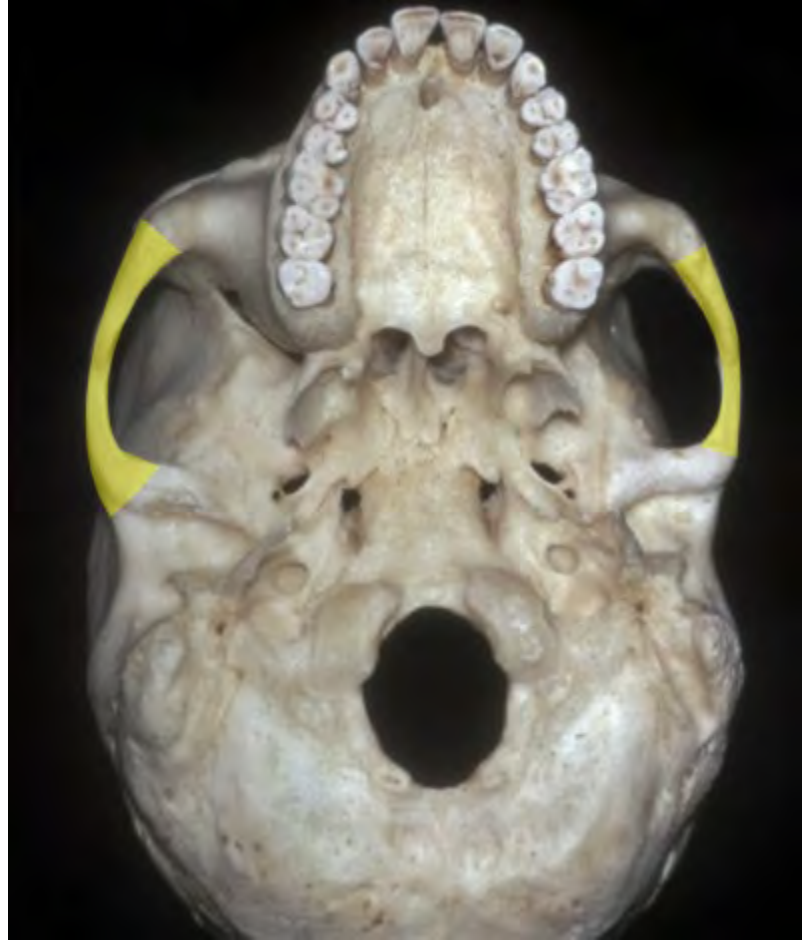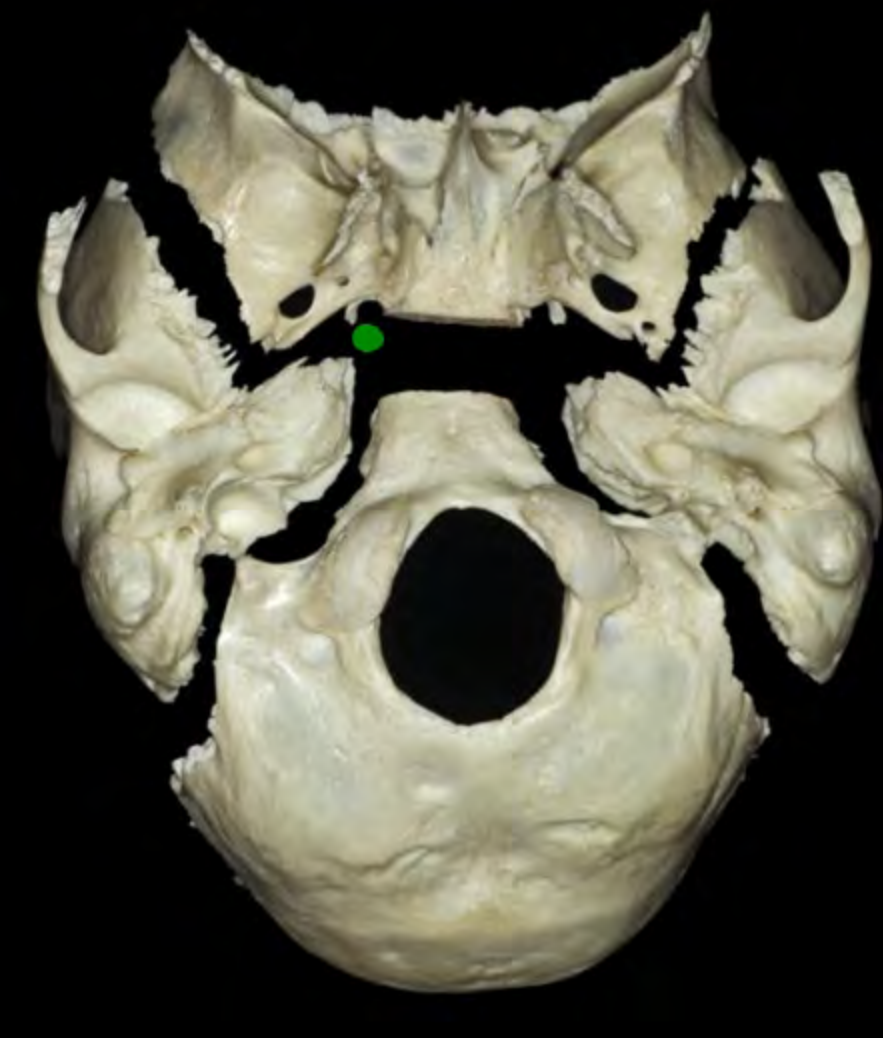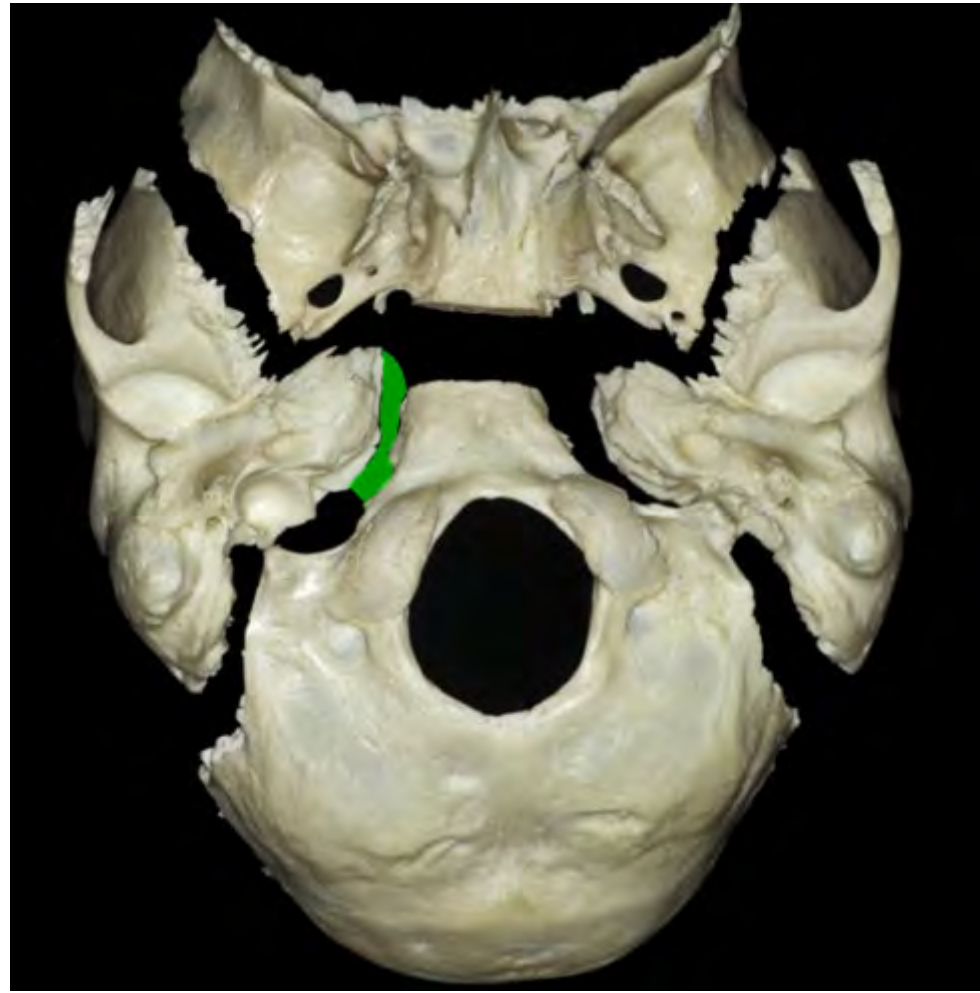


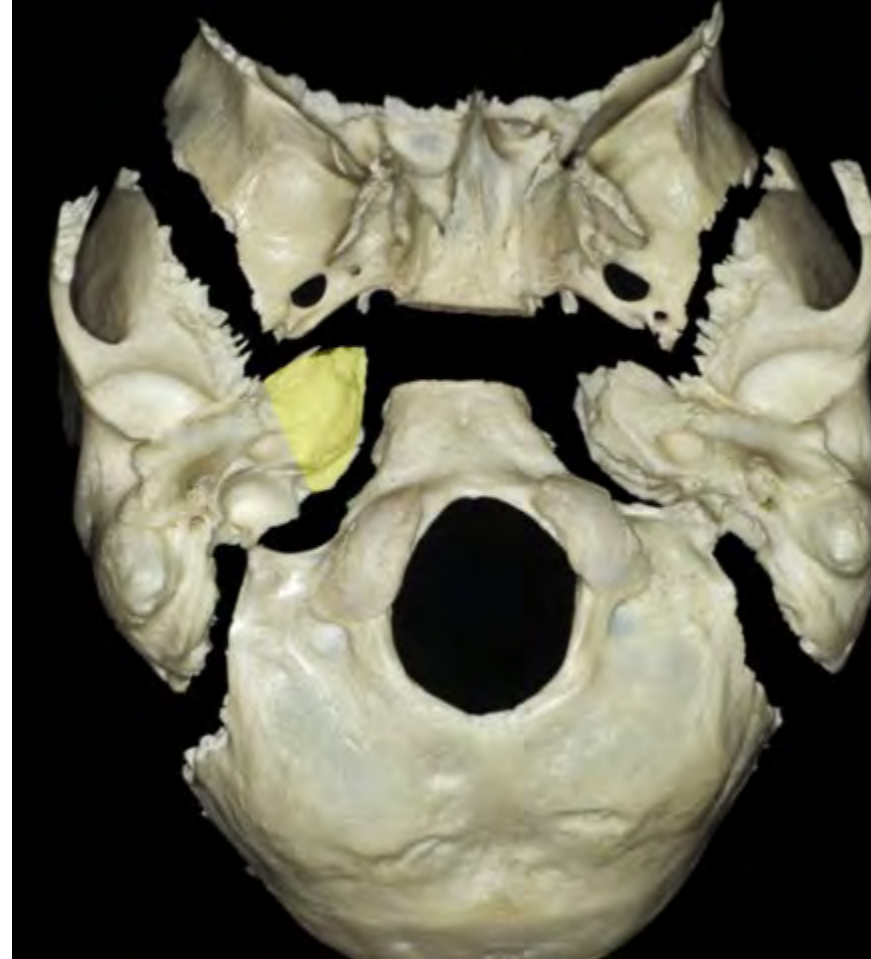




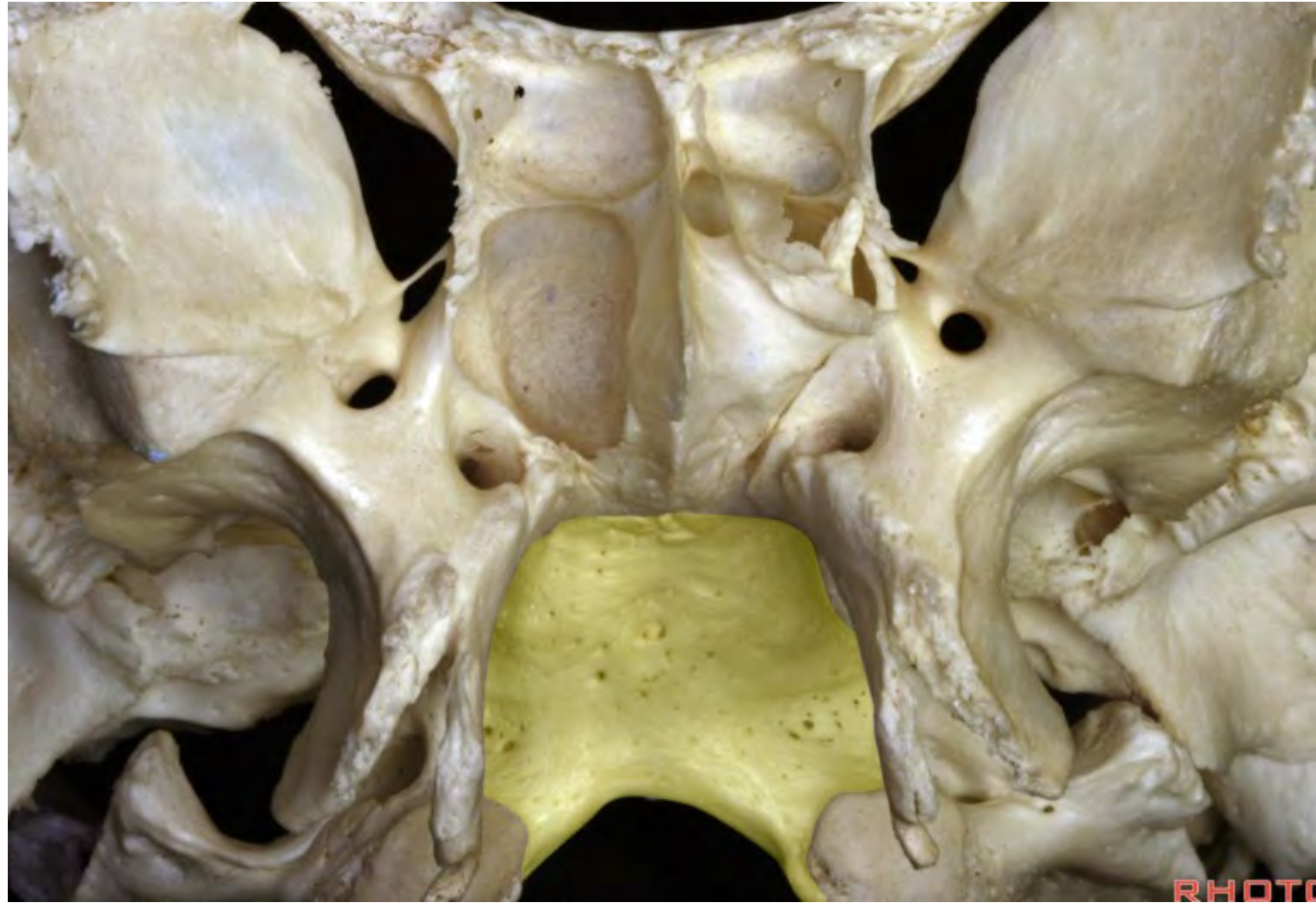




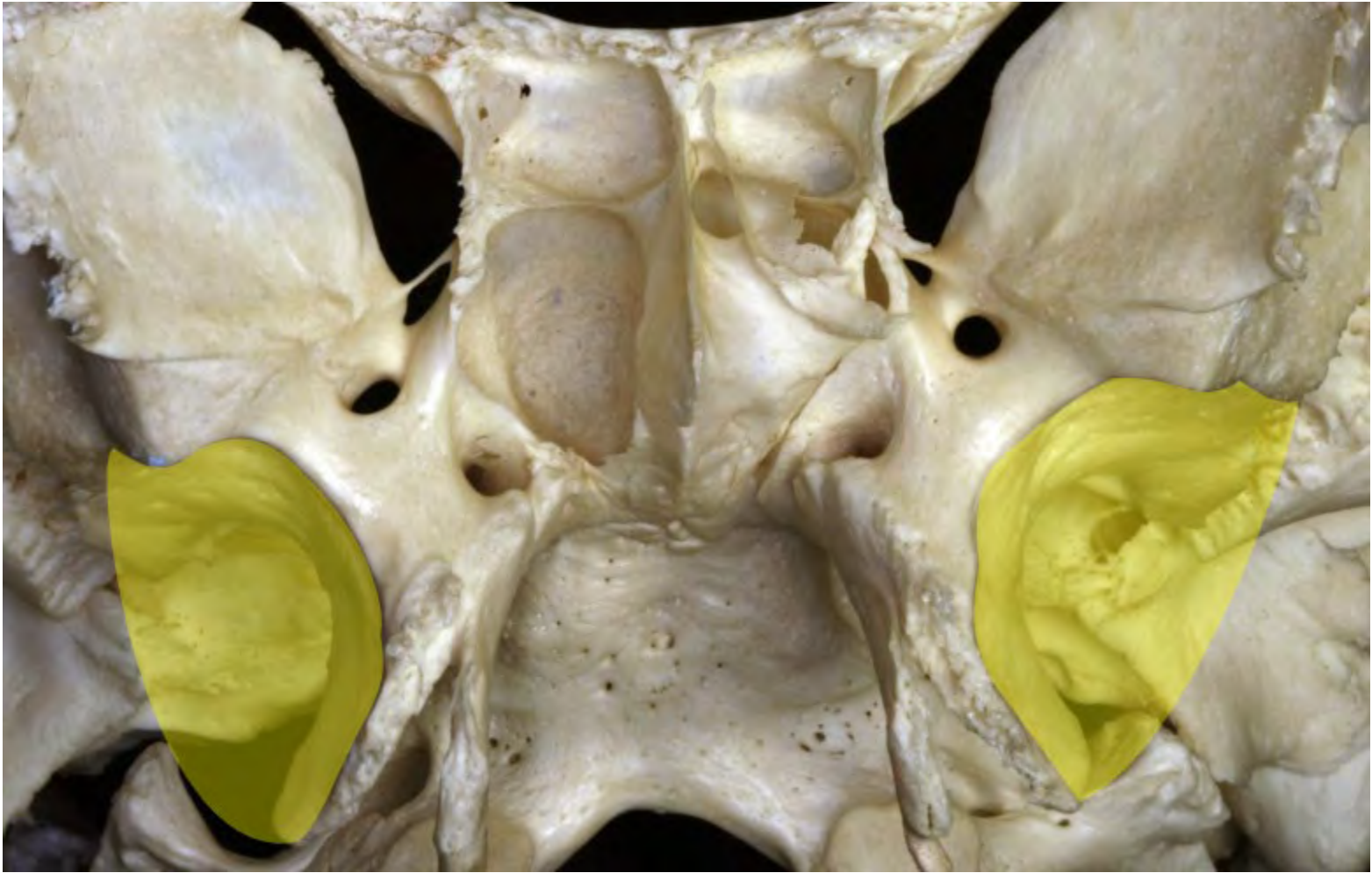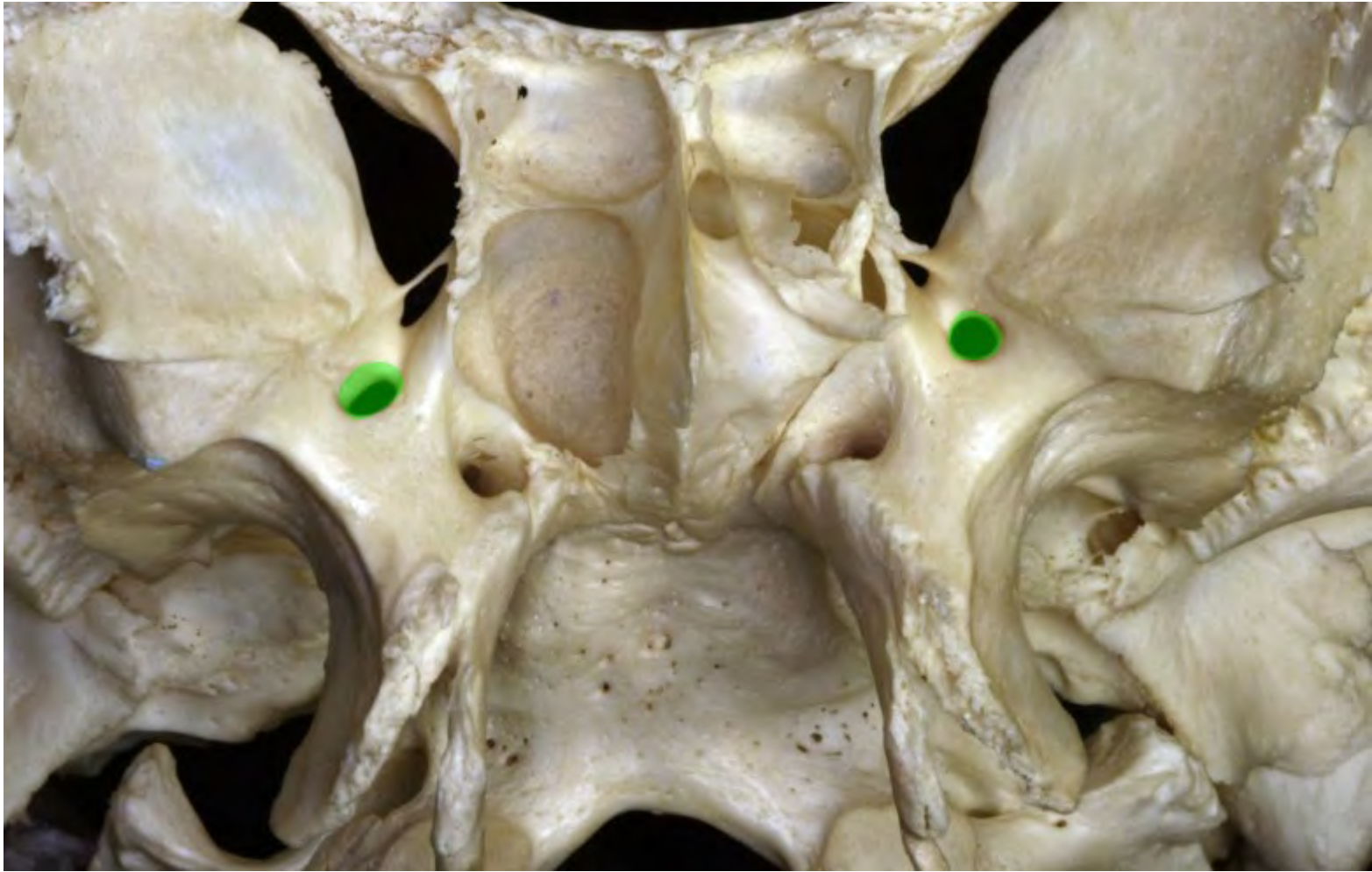


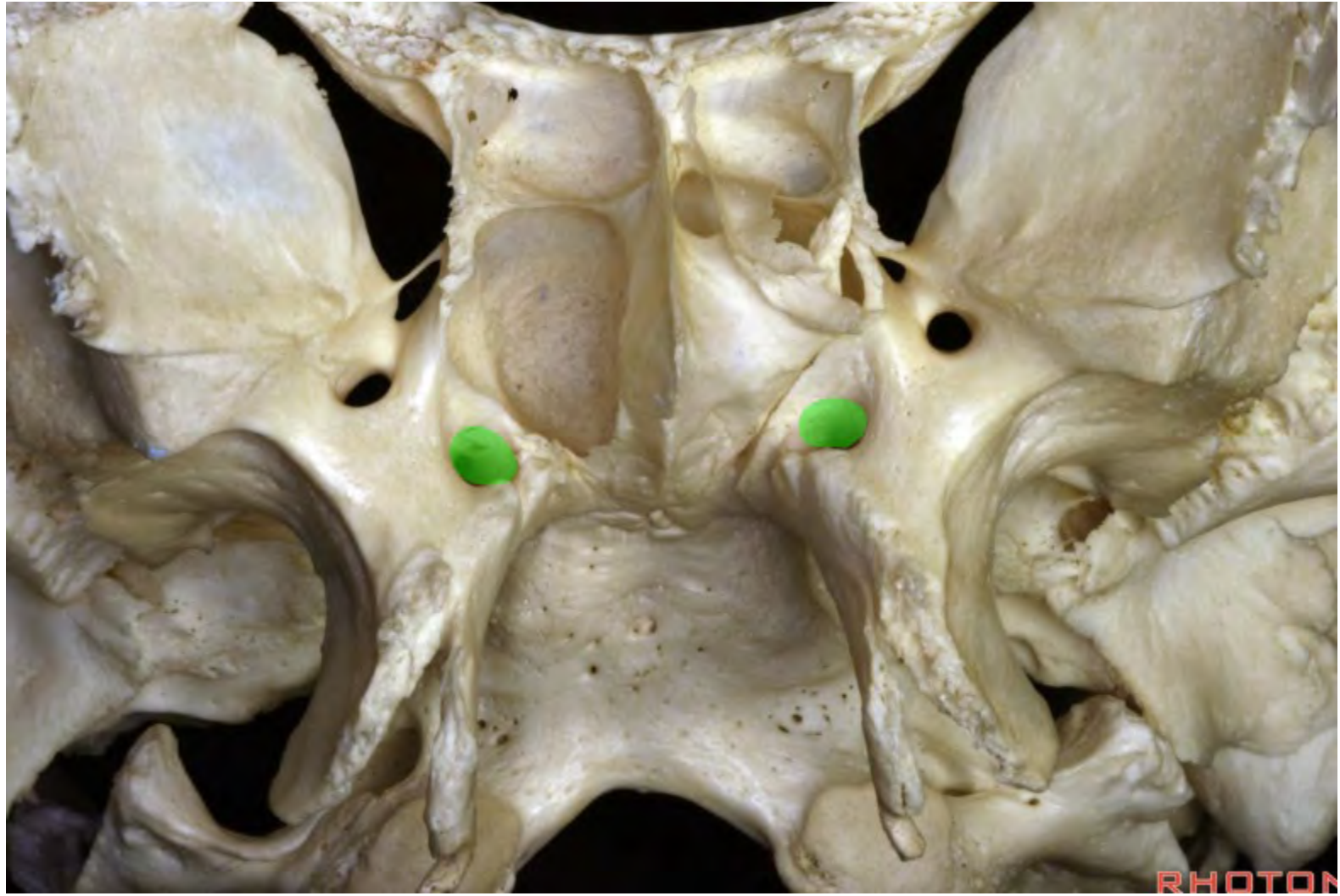






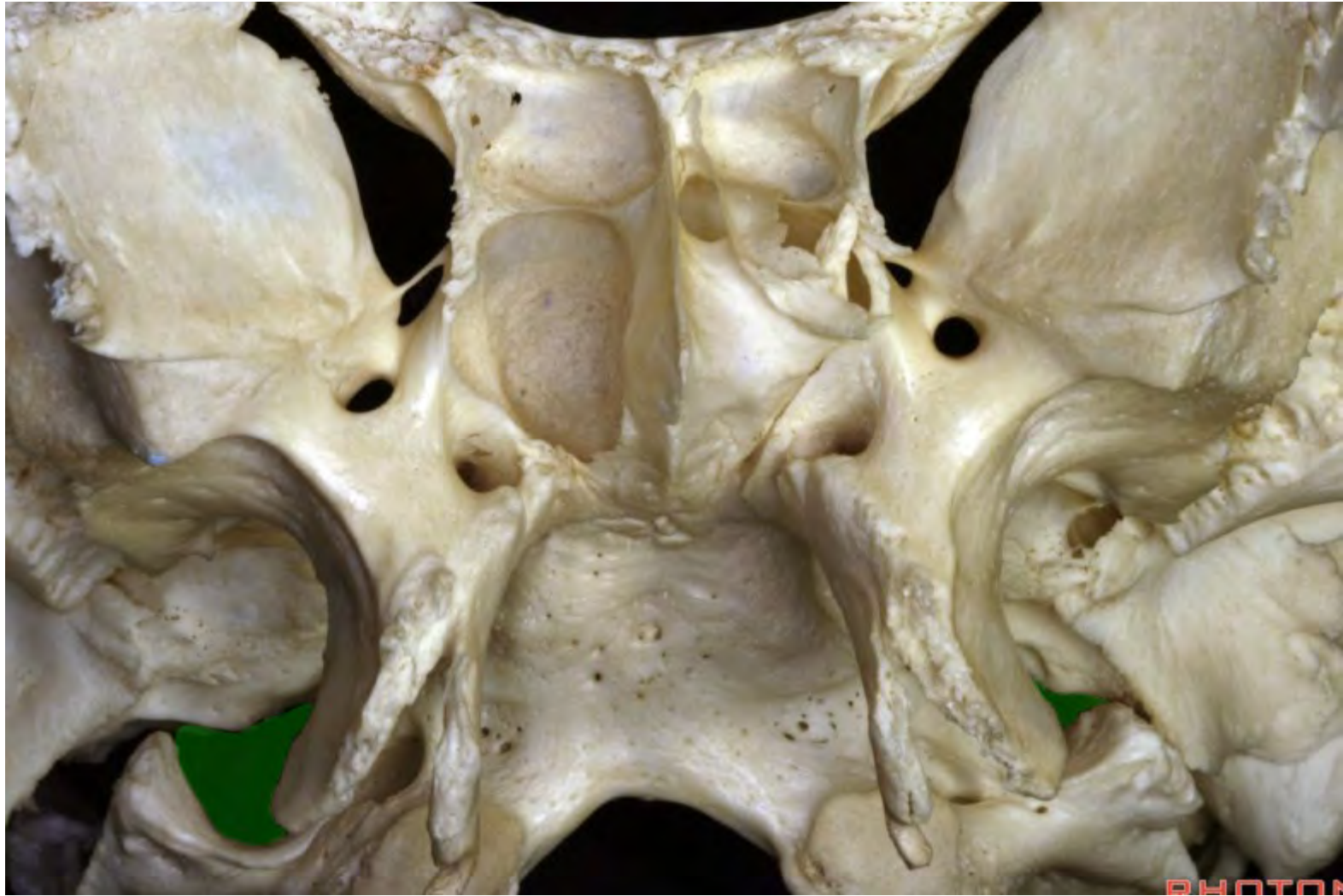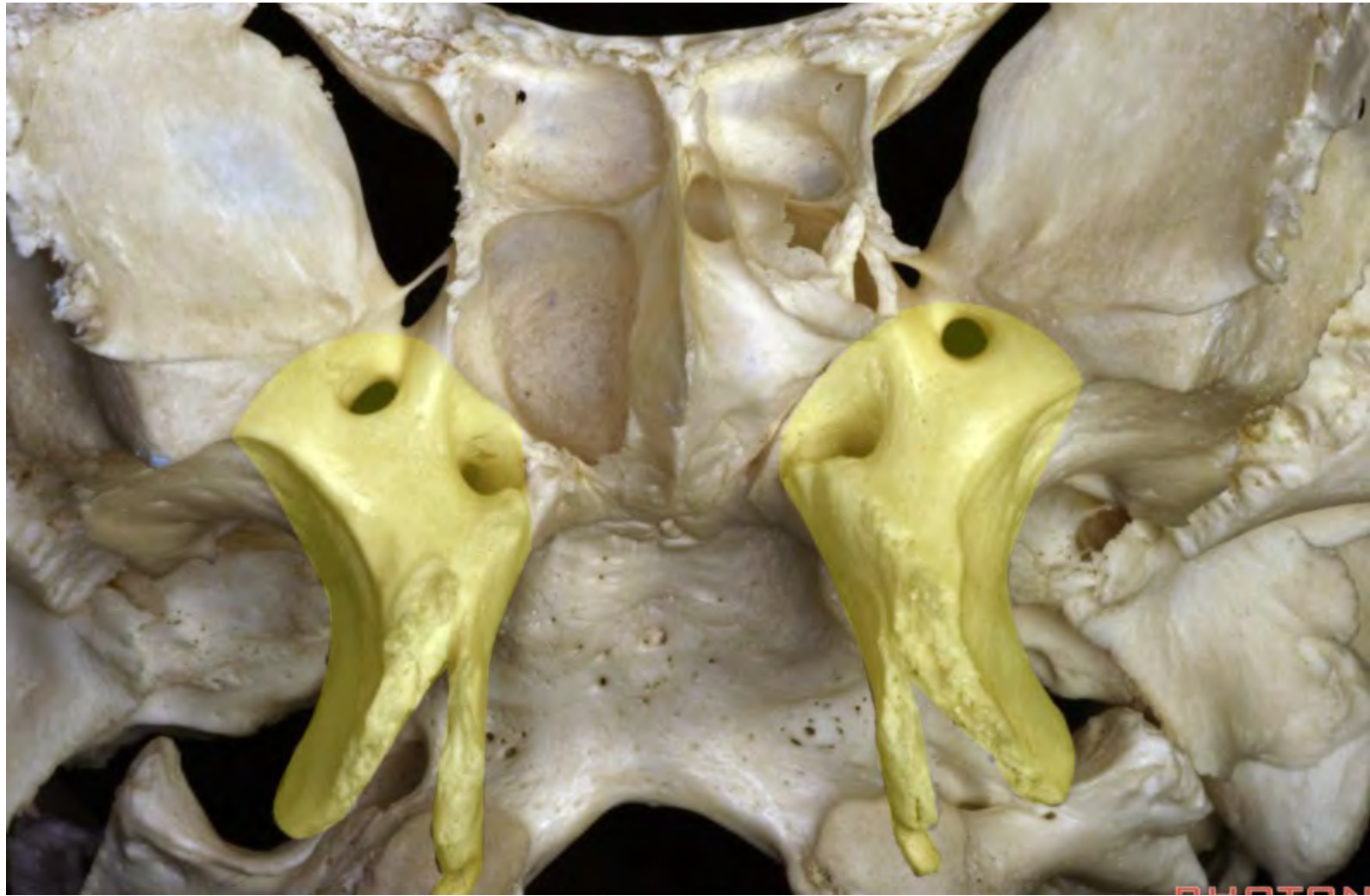




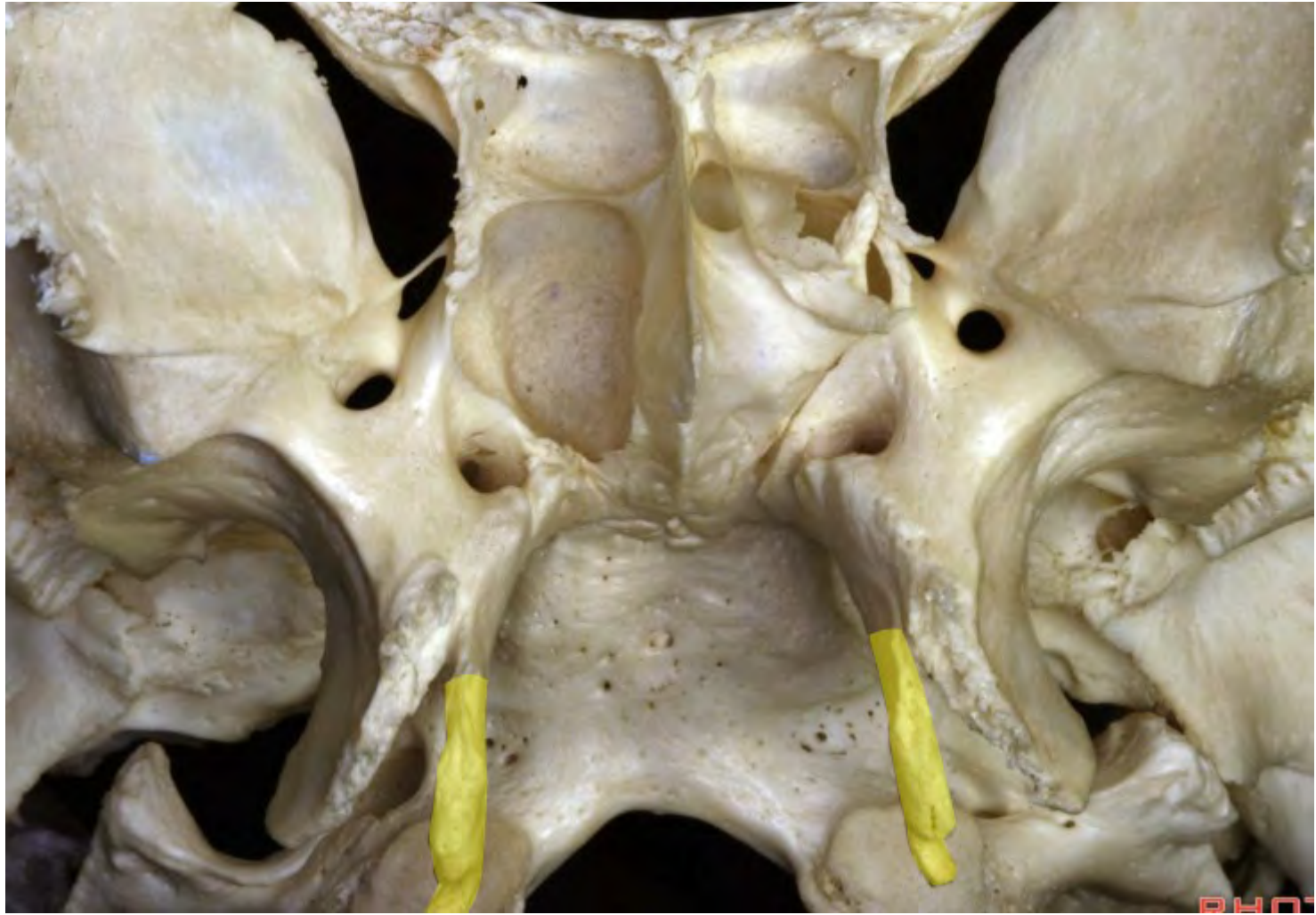


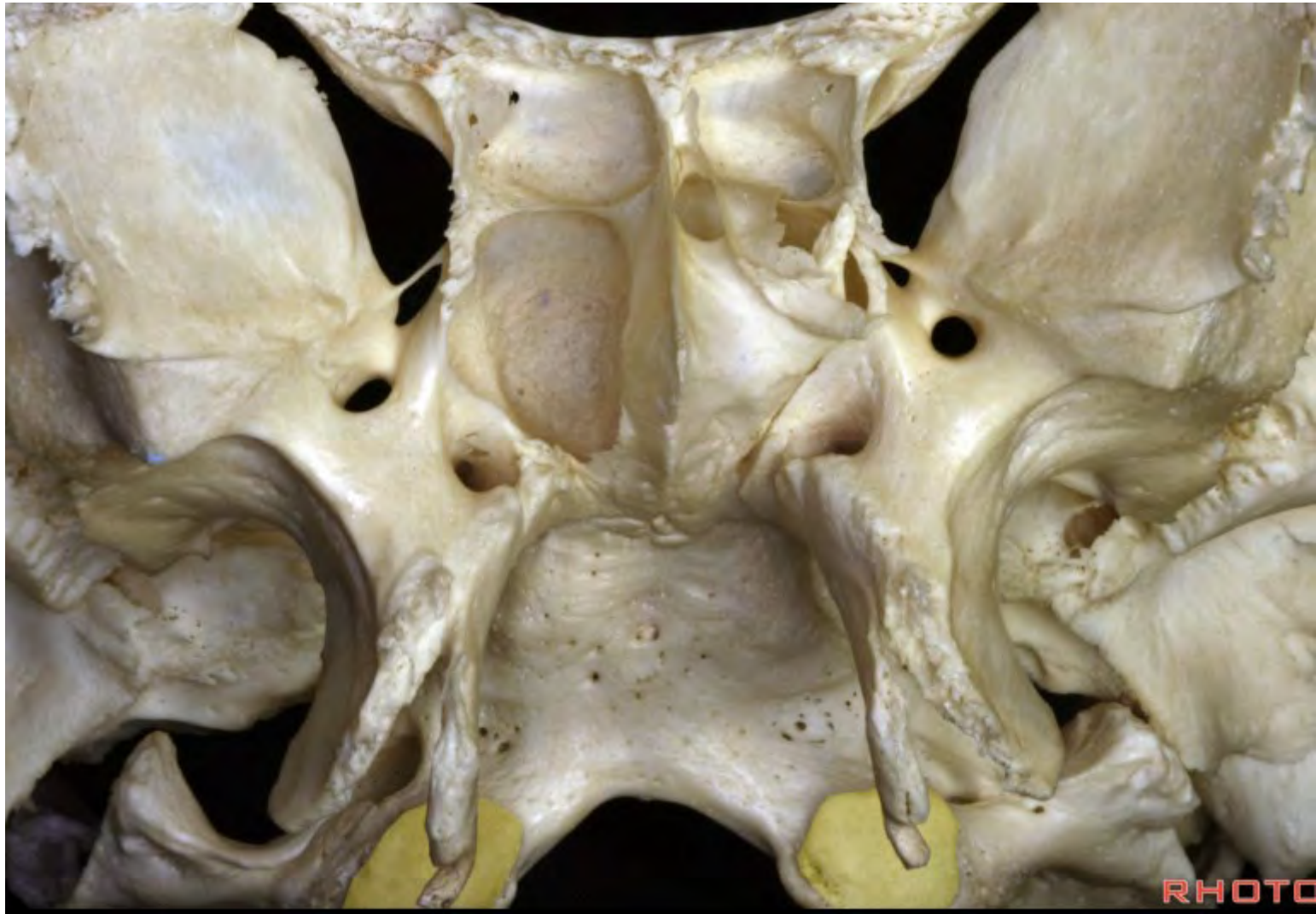RHOTO



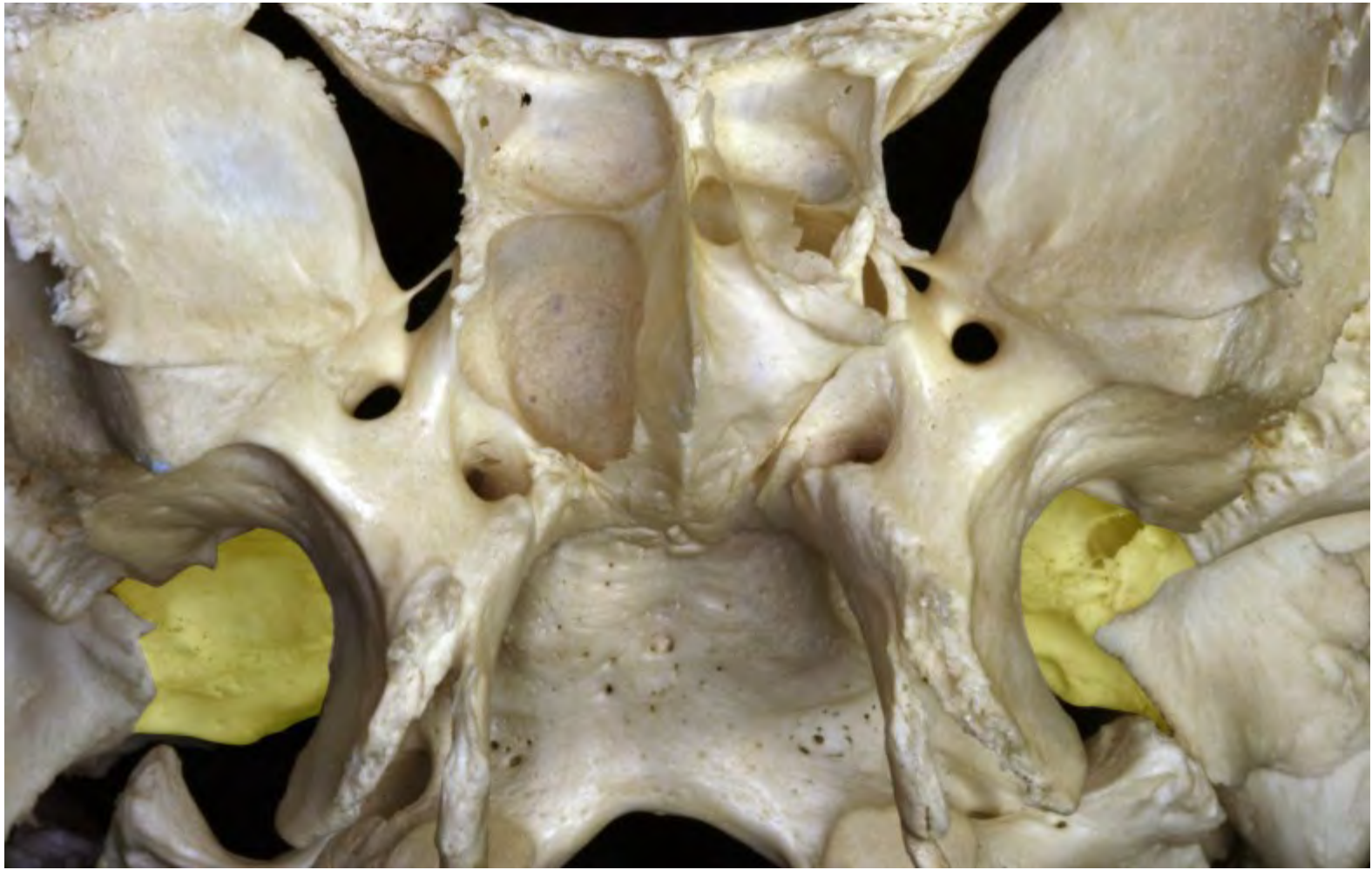

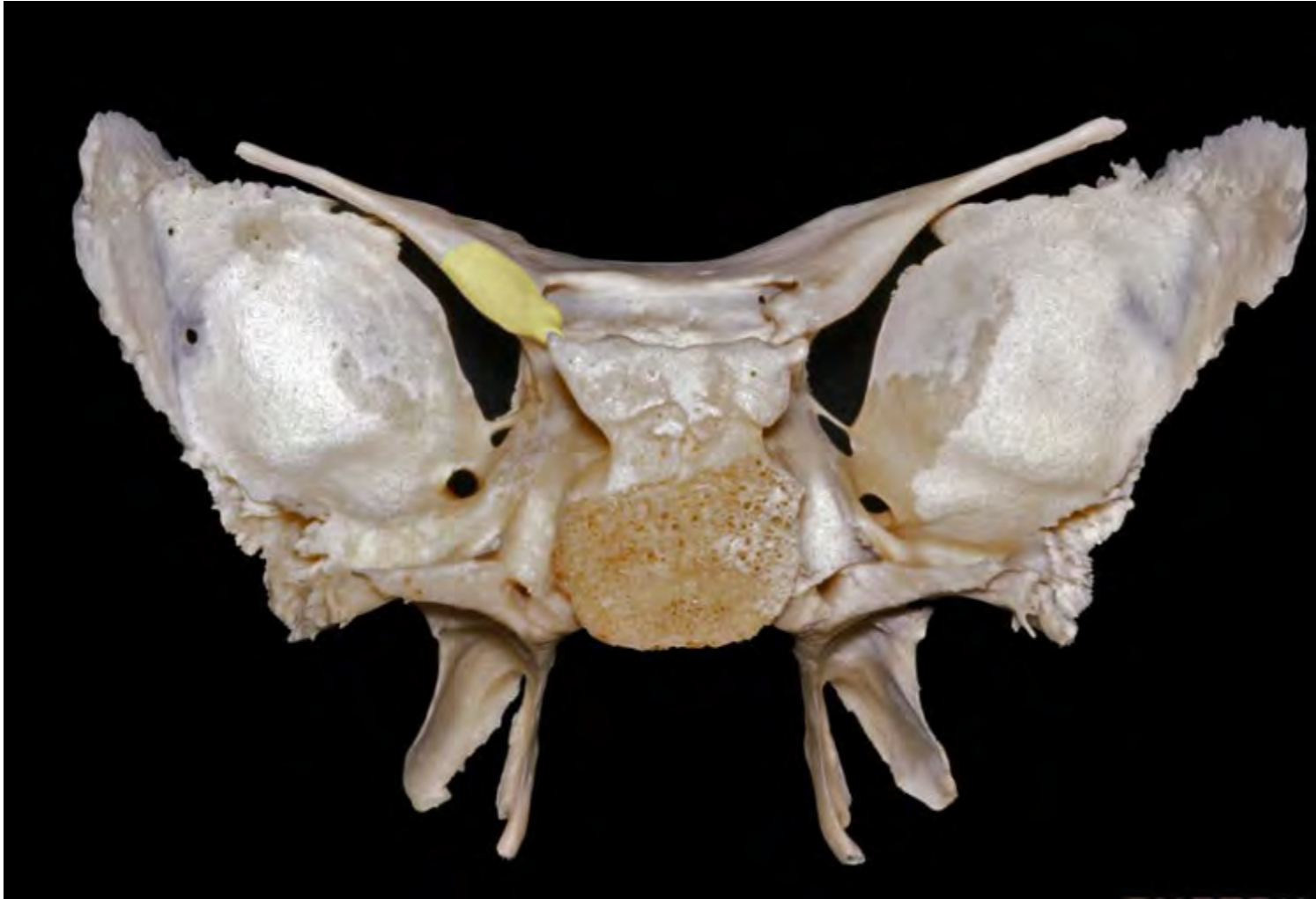PHOTON

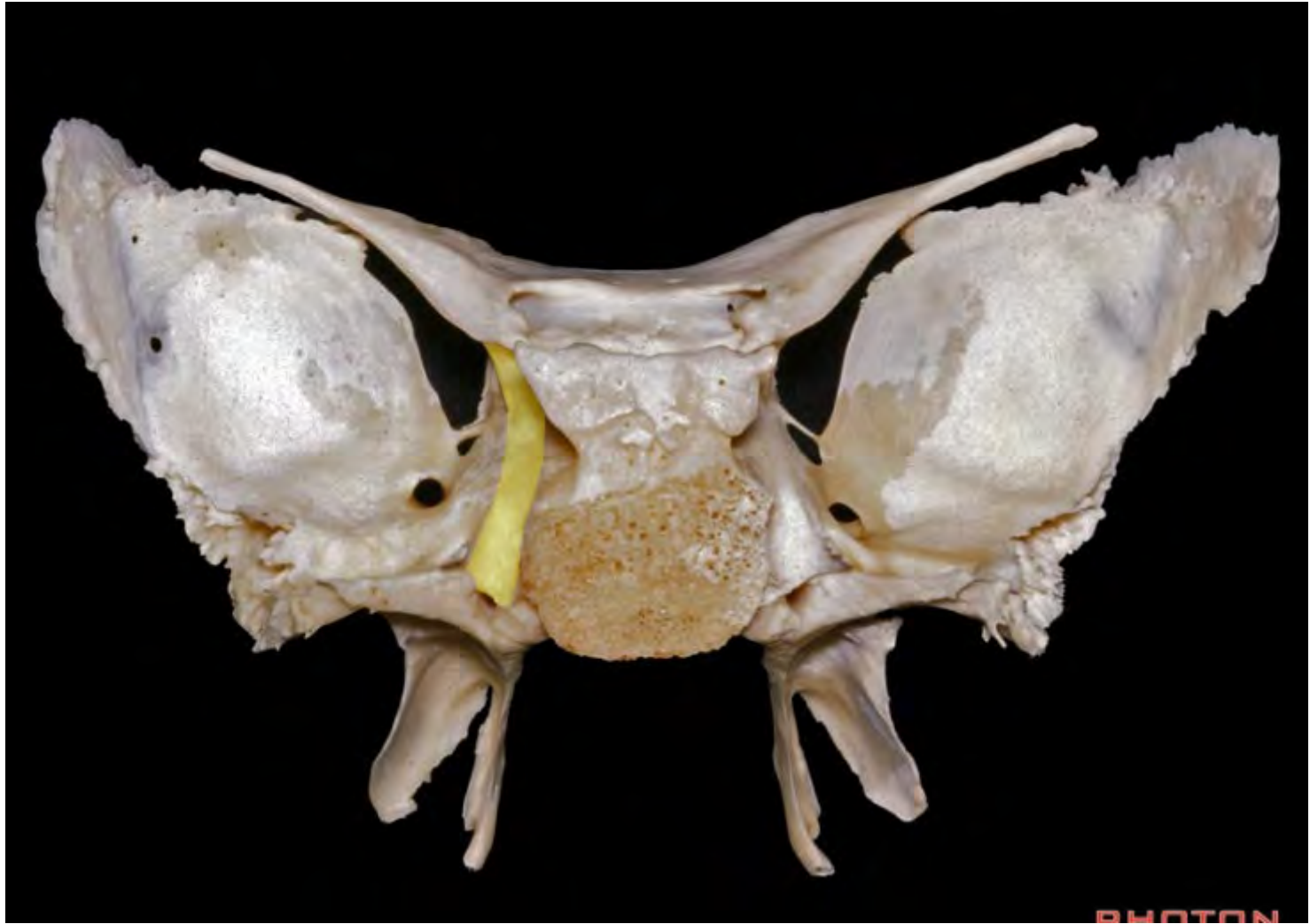


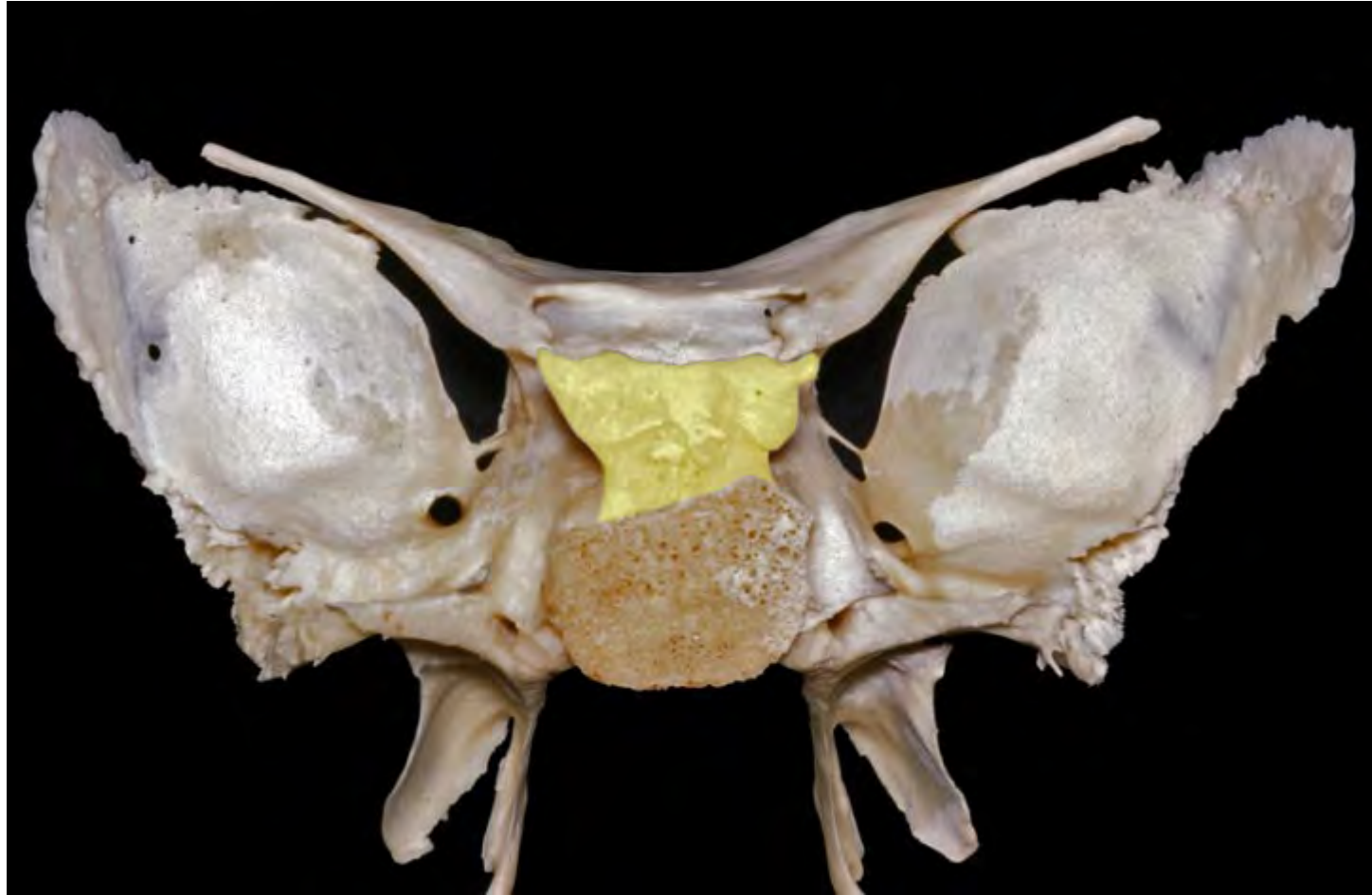


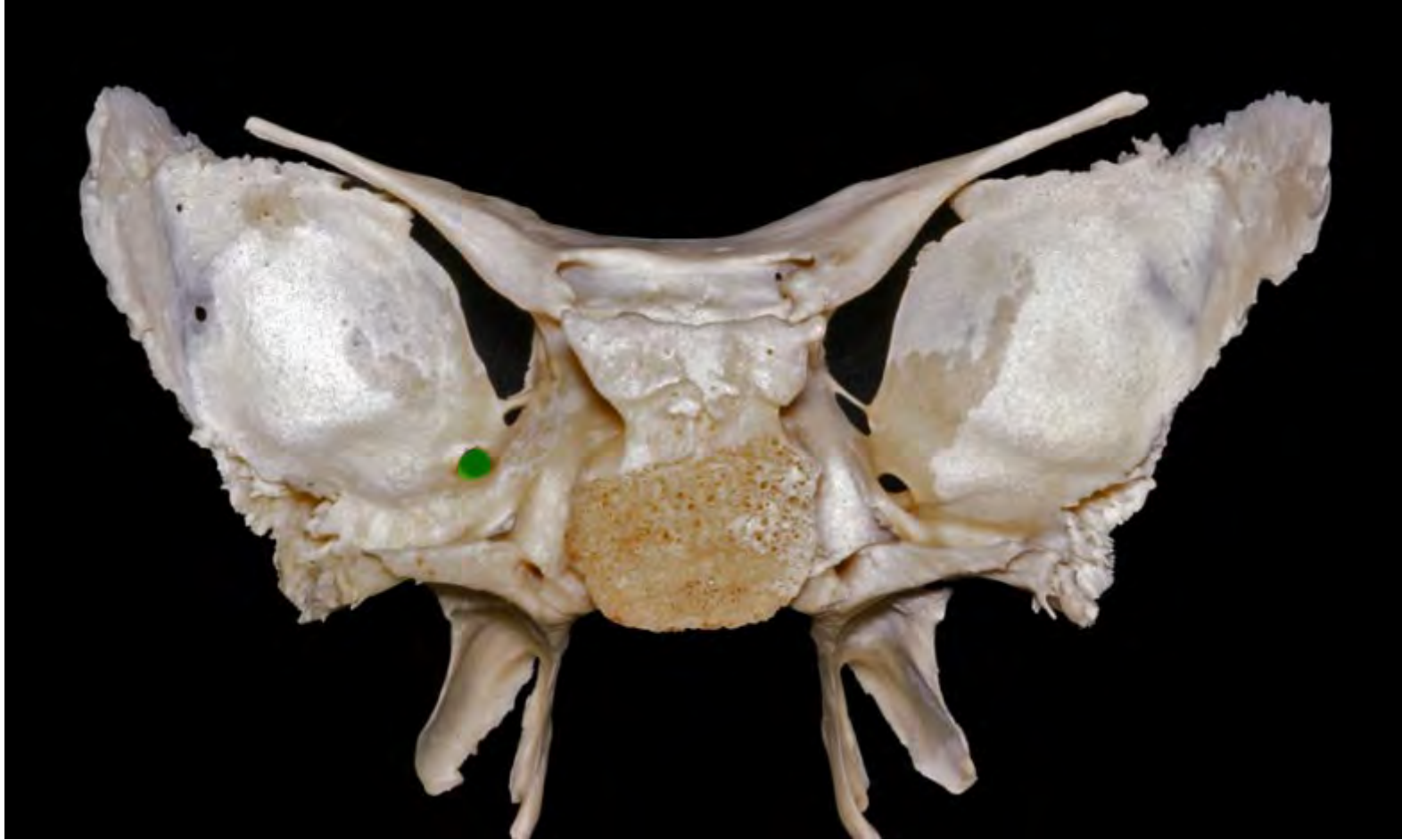


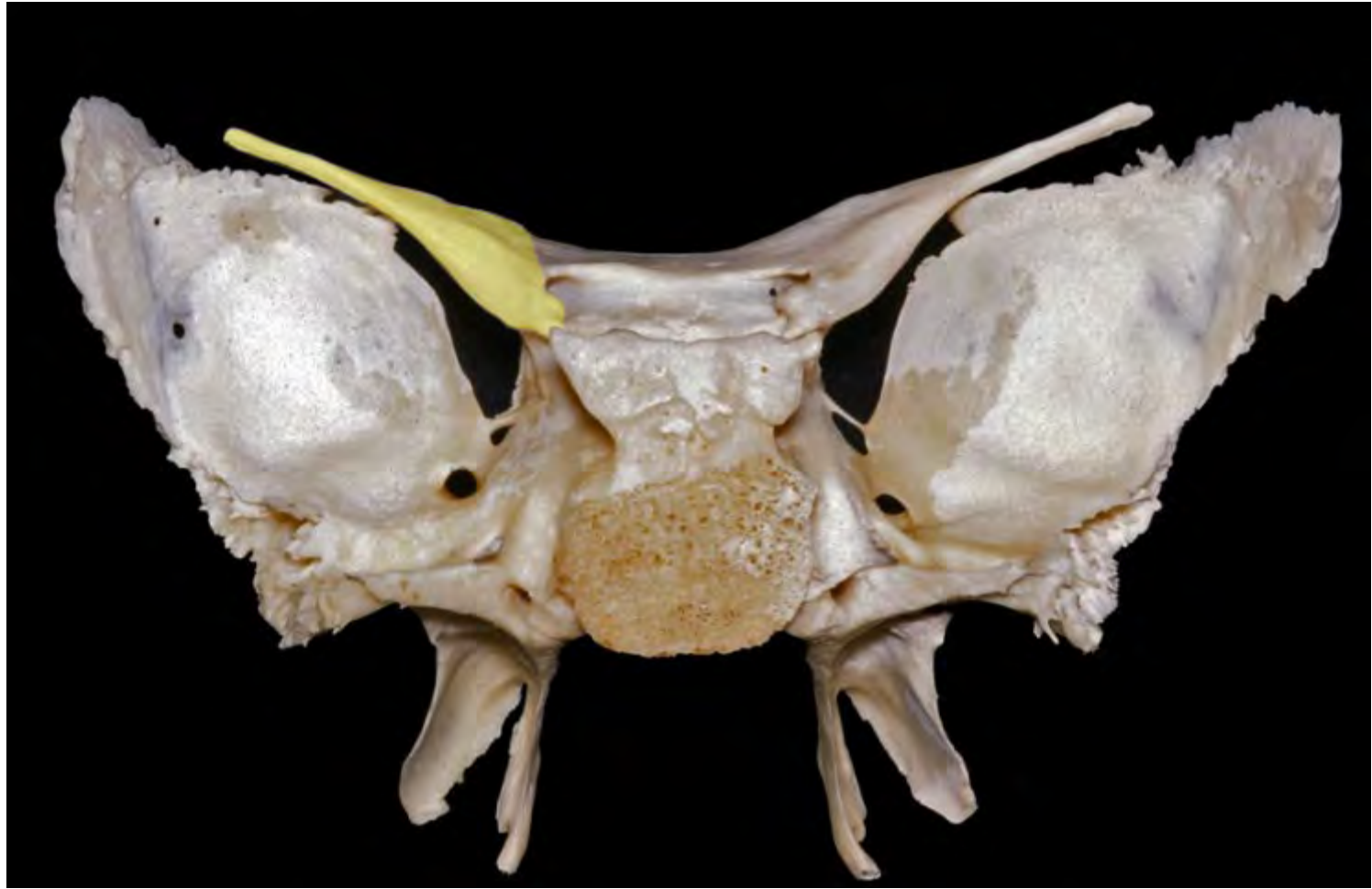


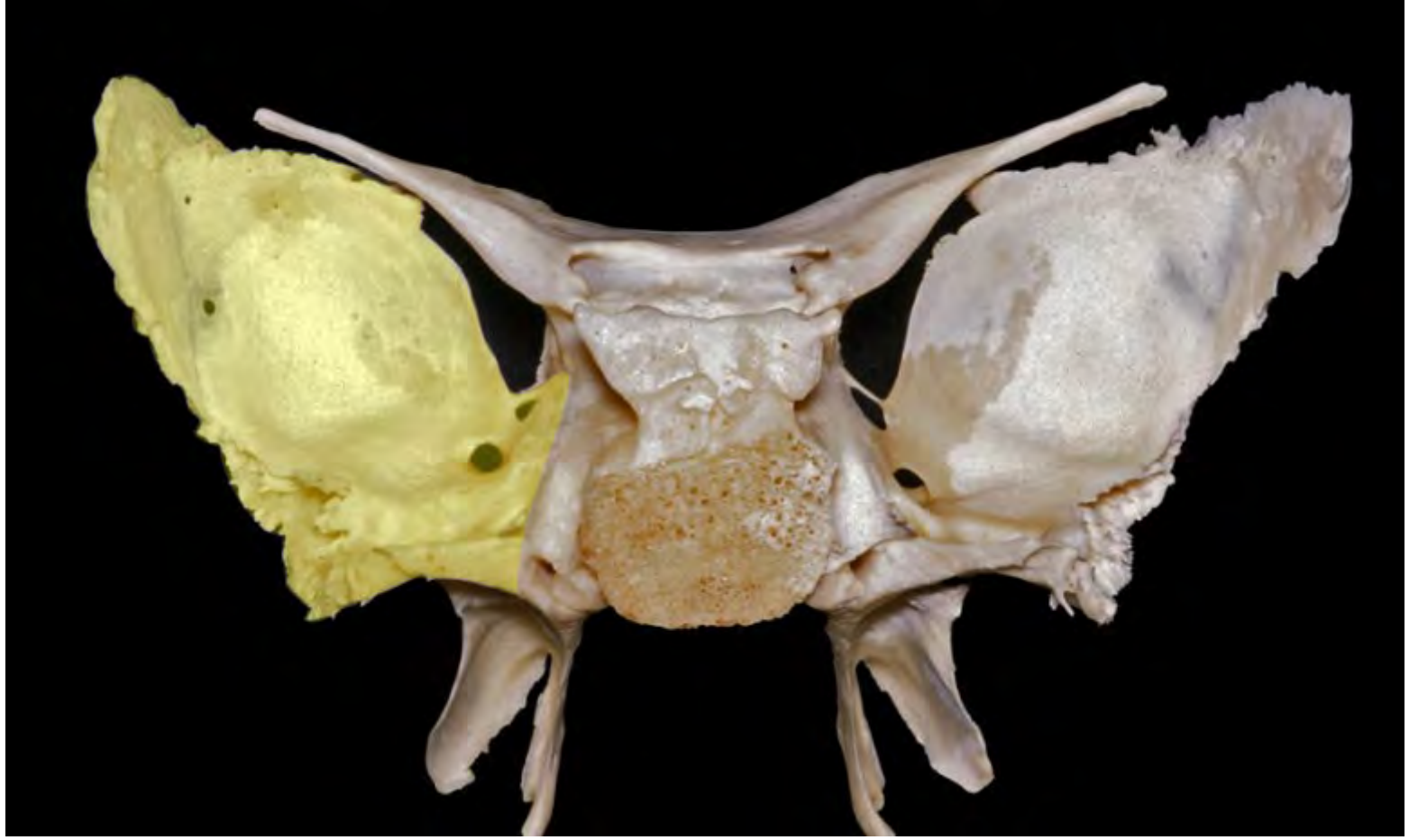


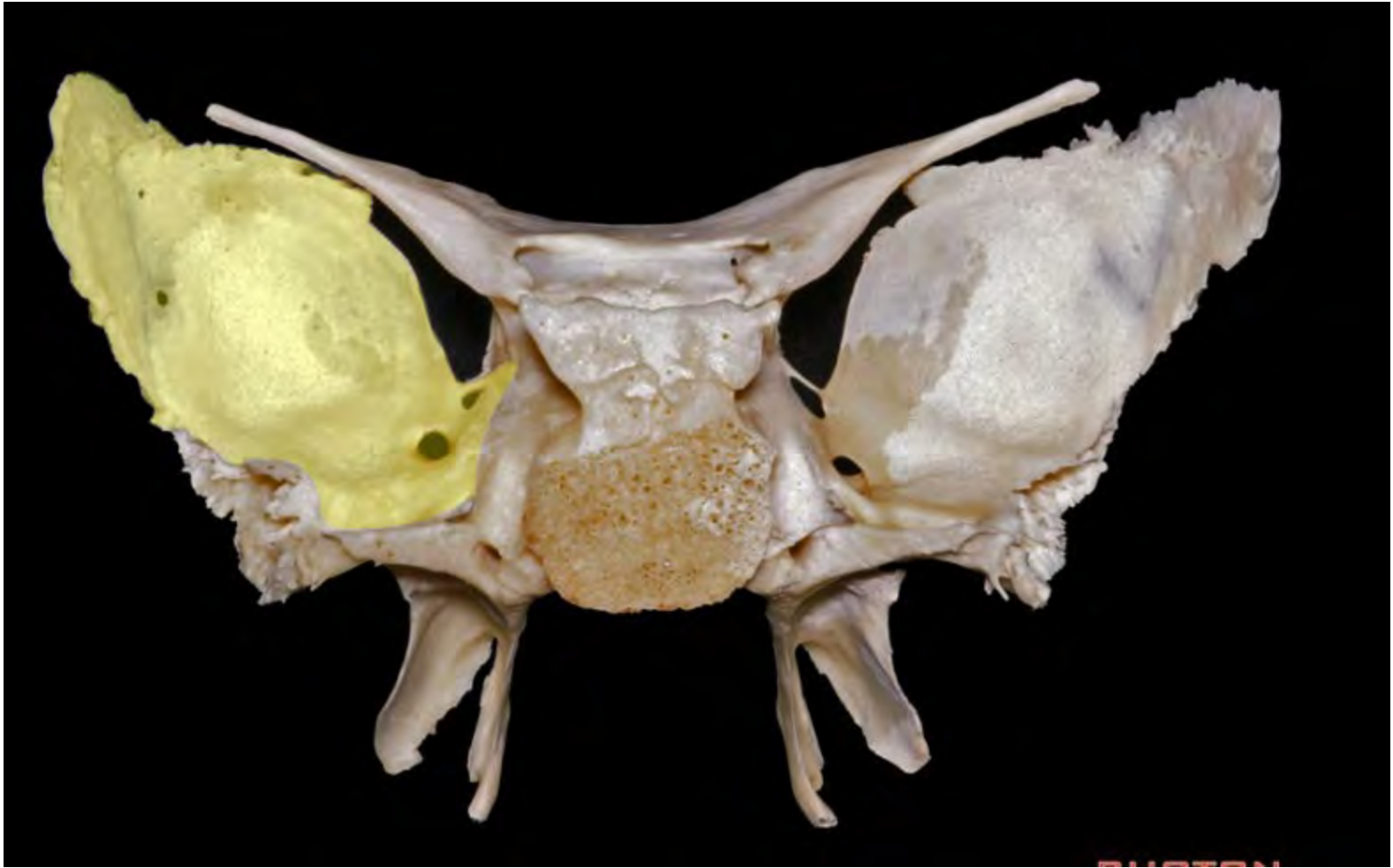




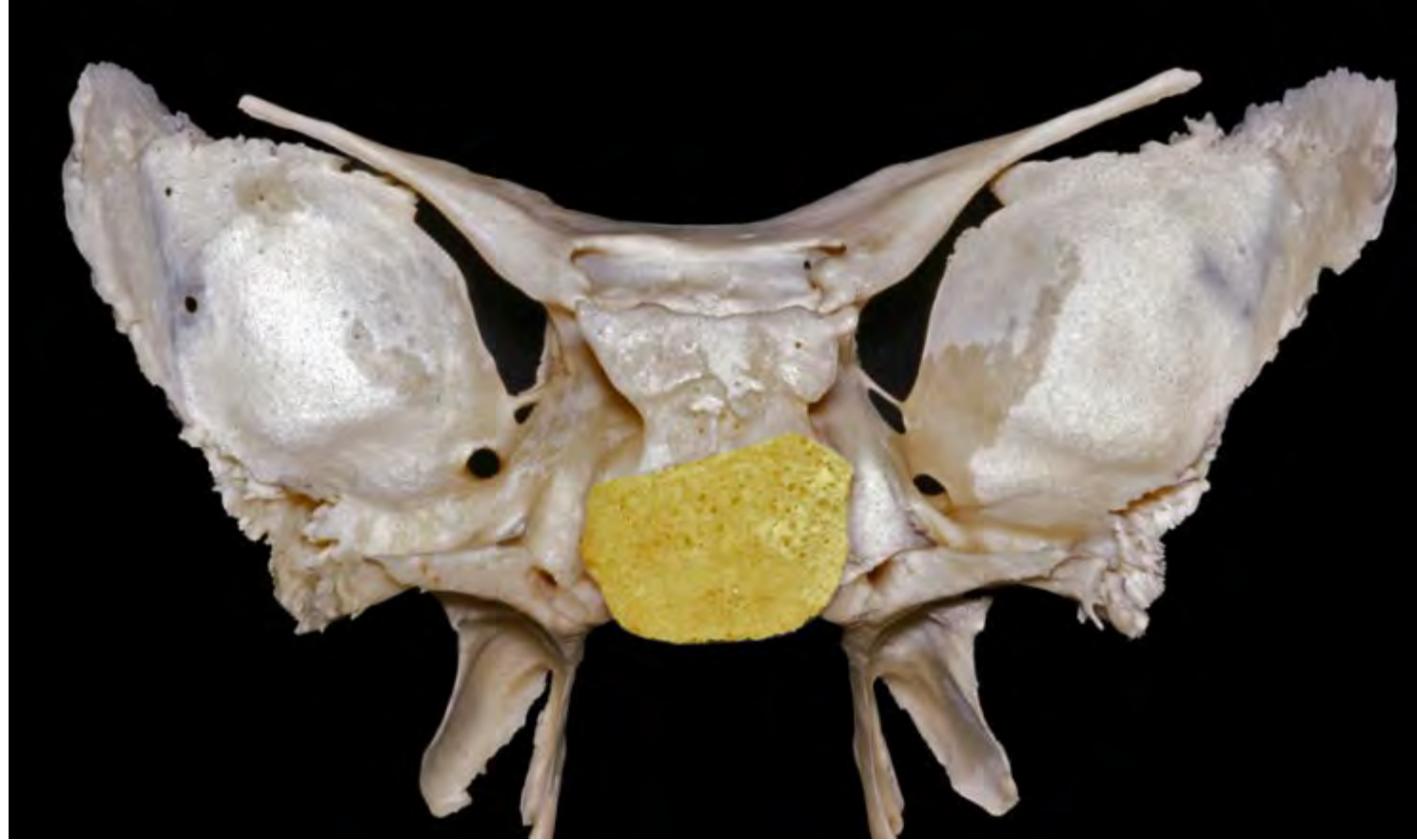
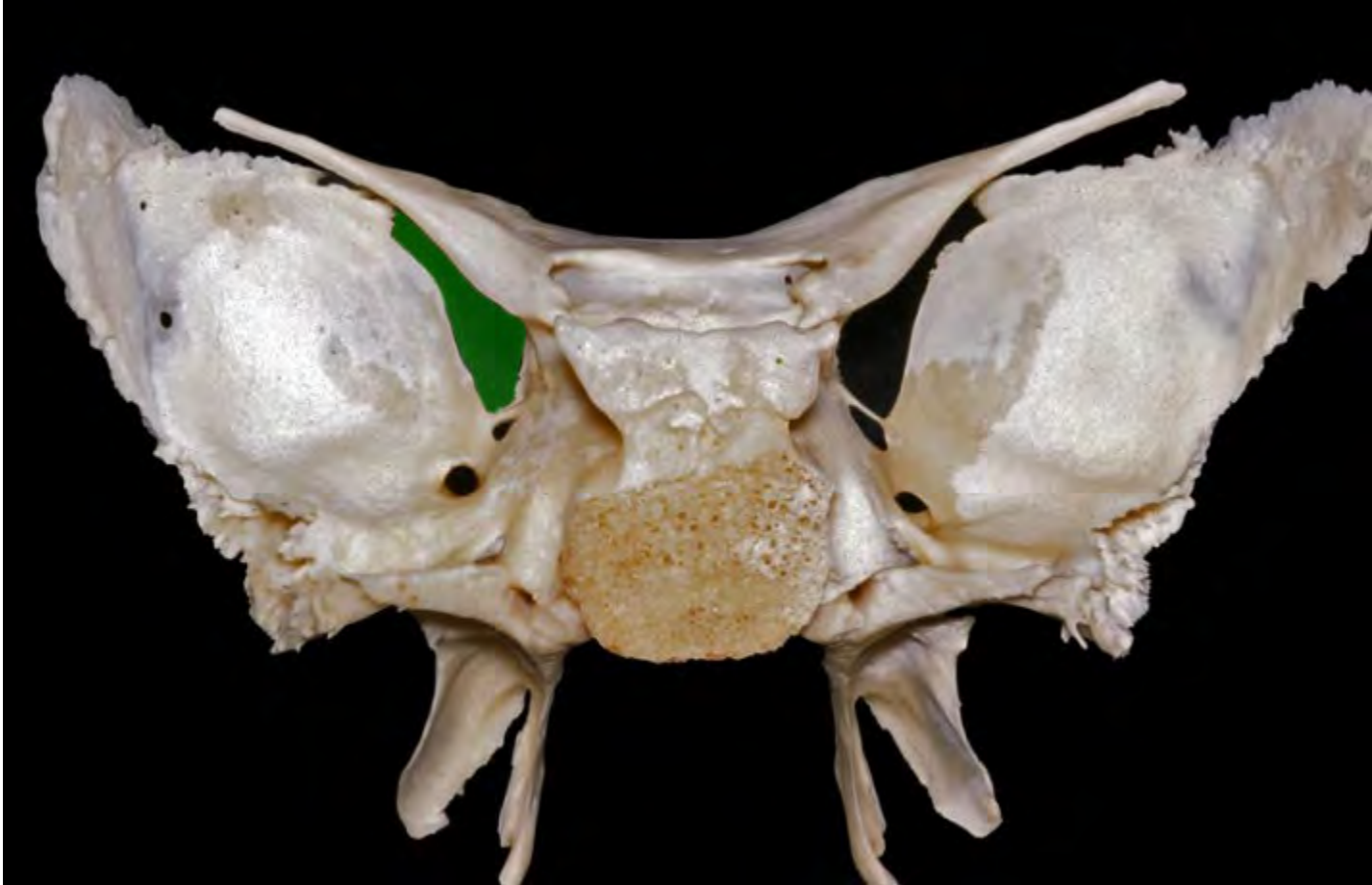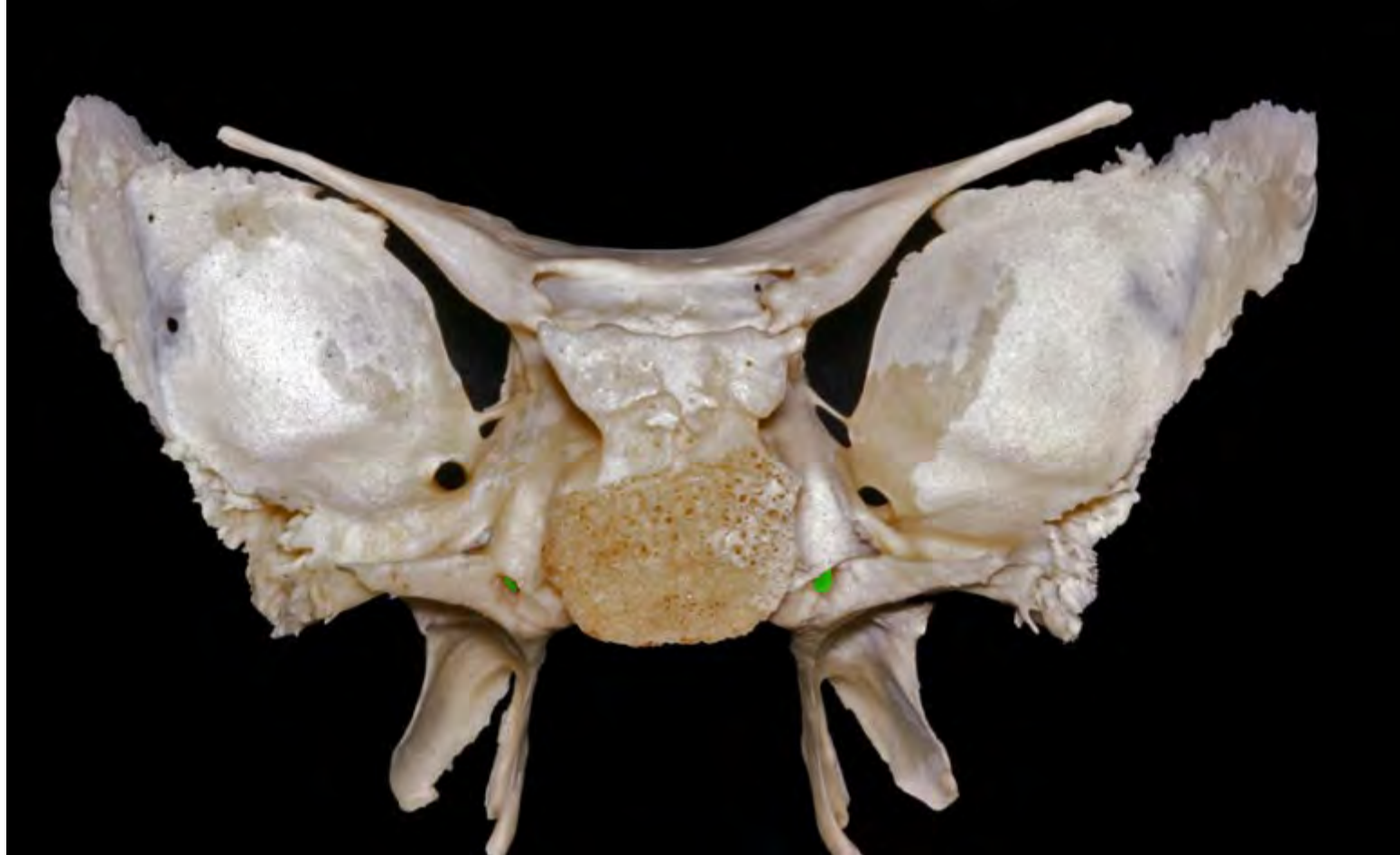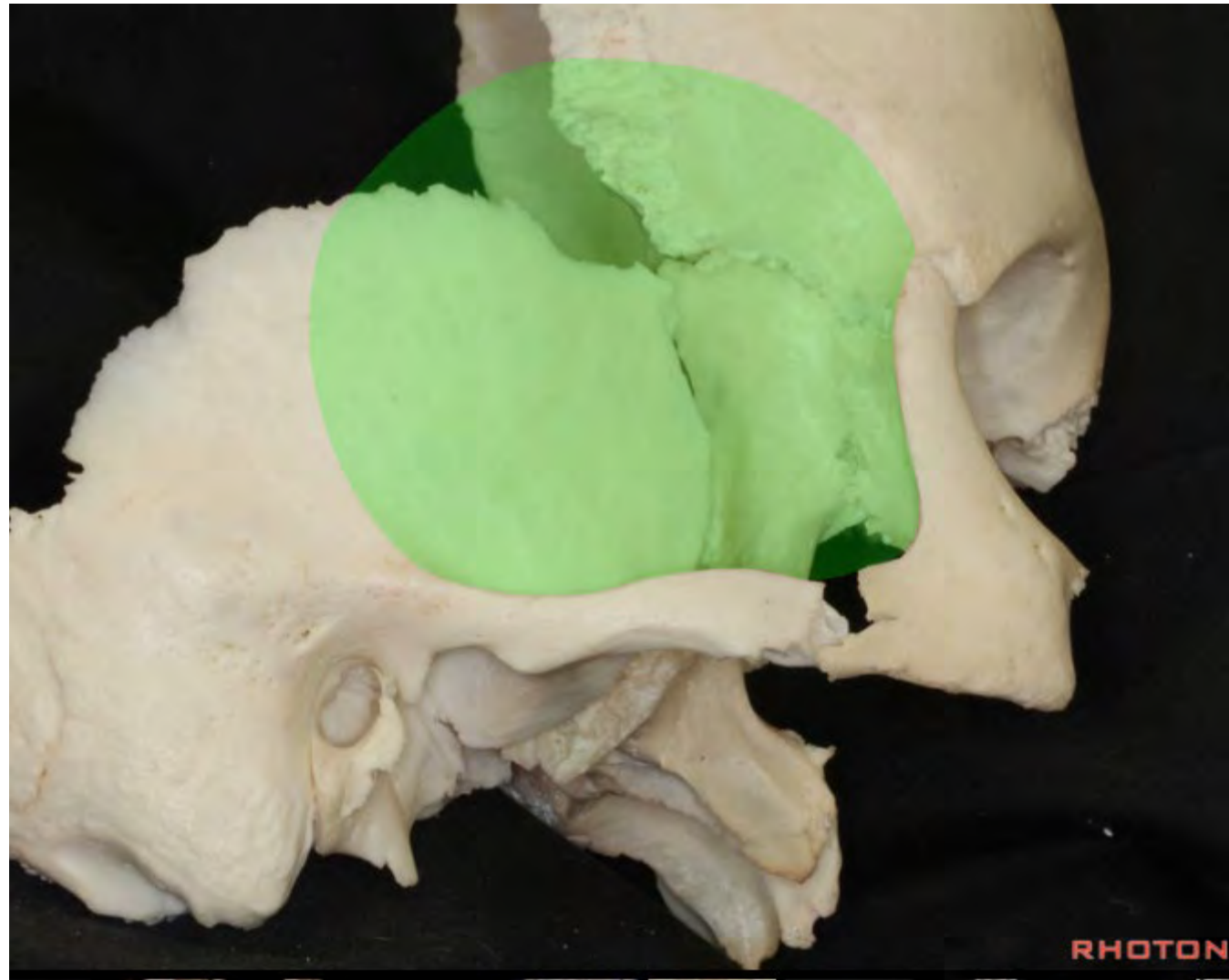




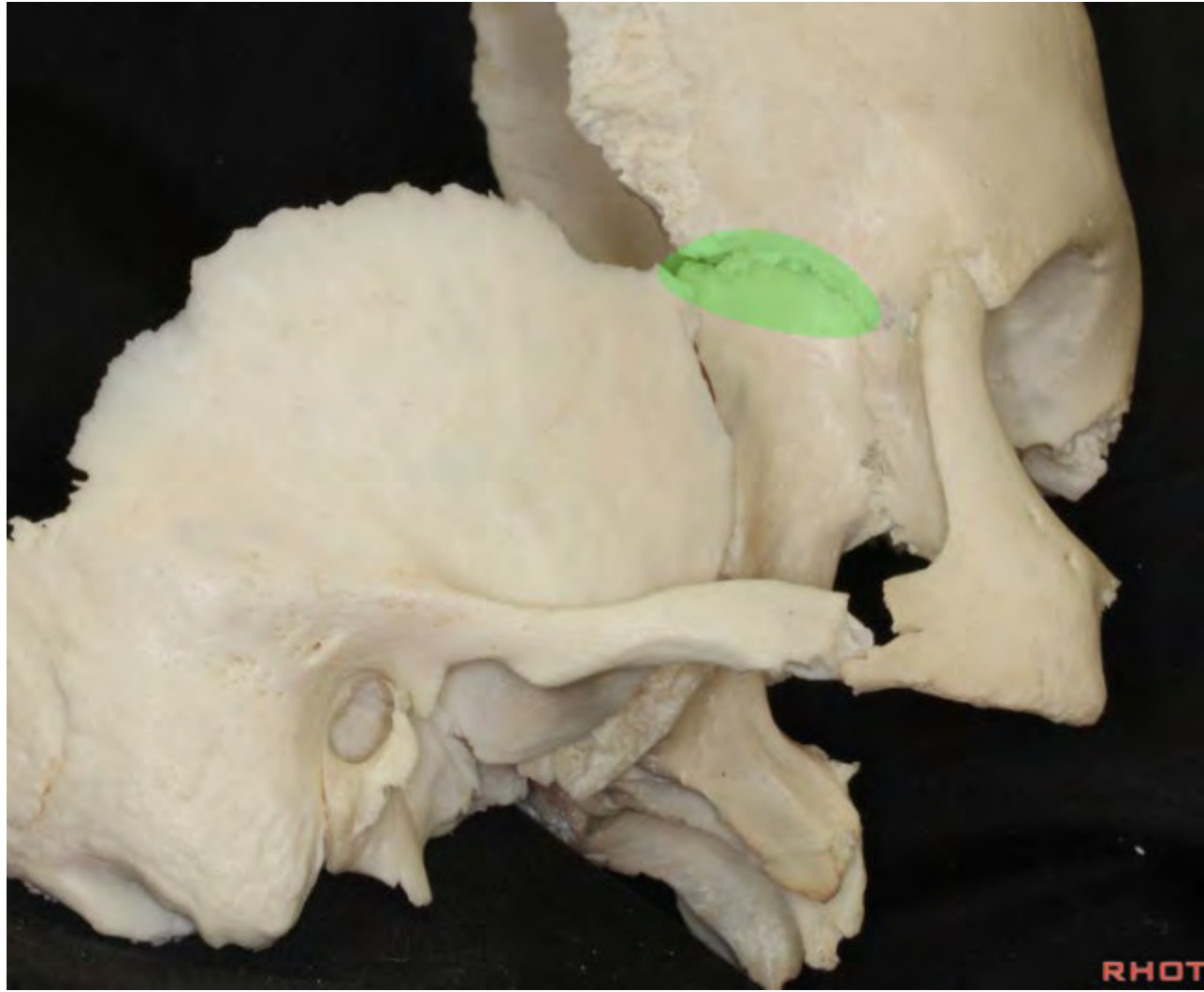


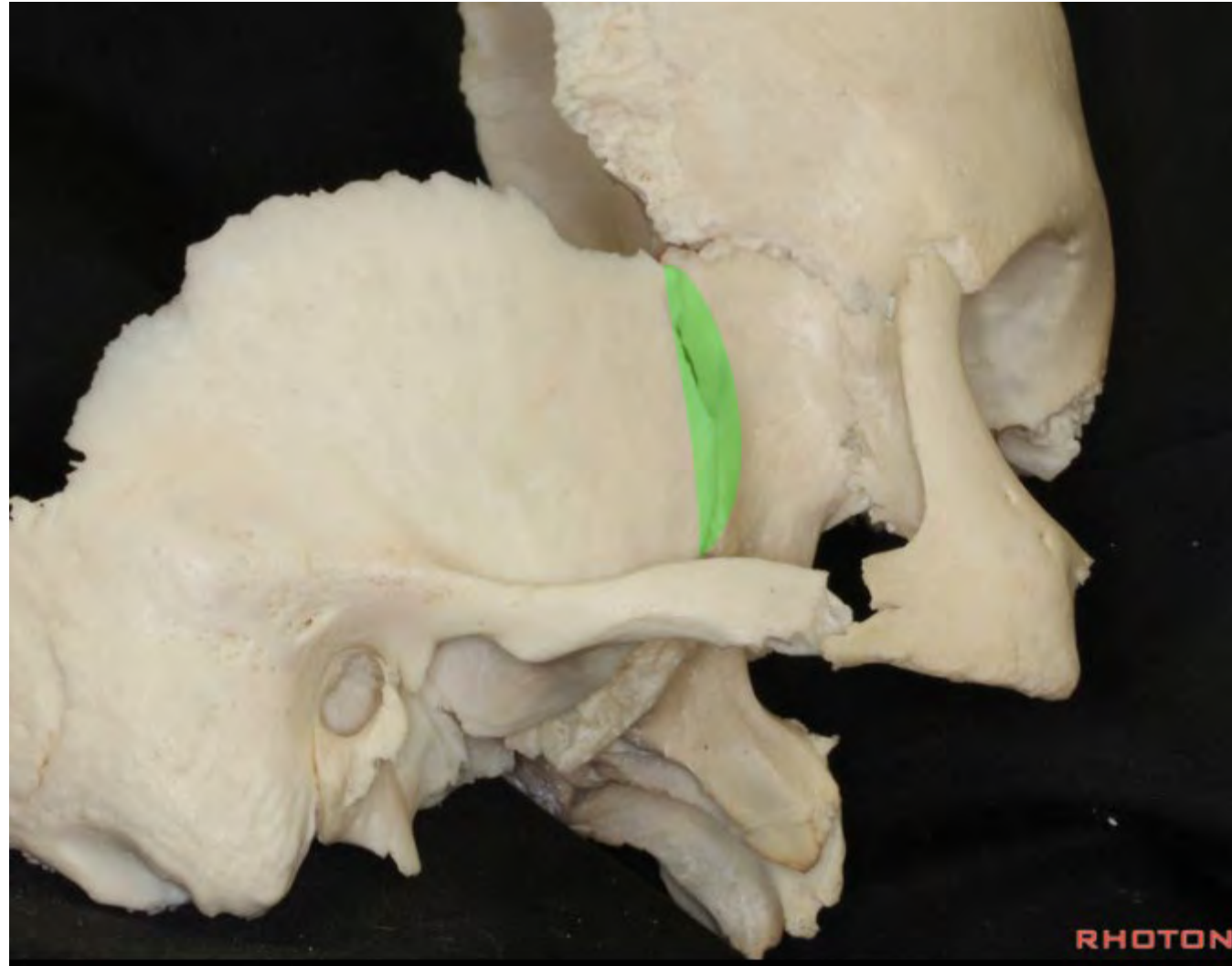


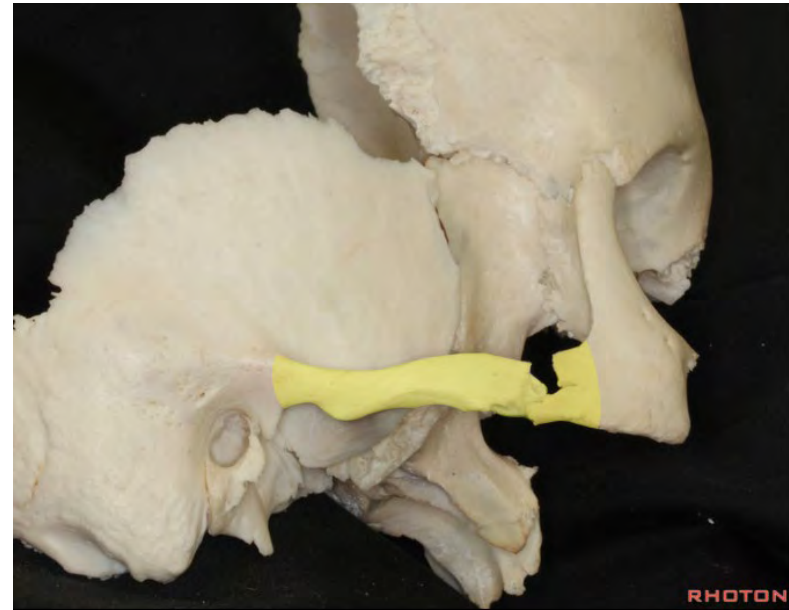
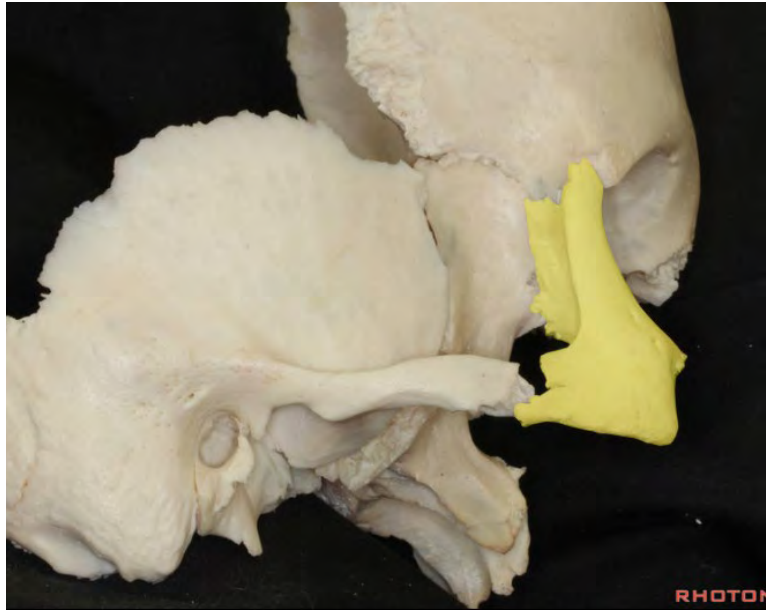


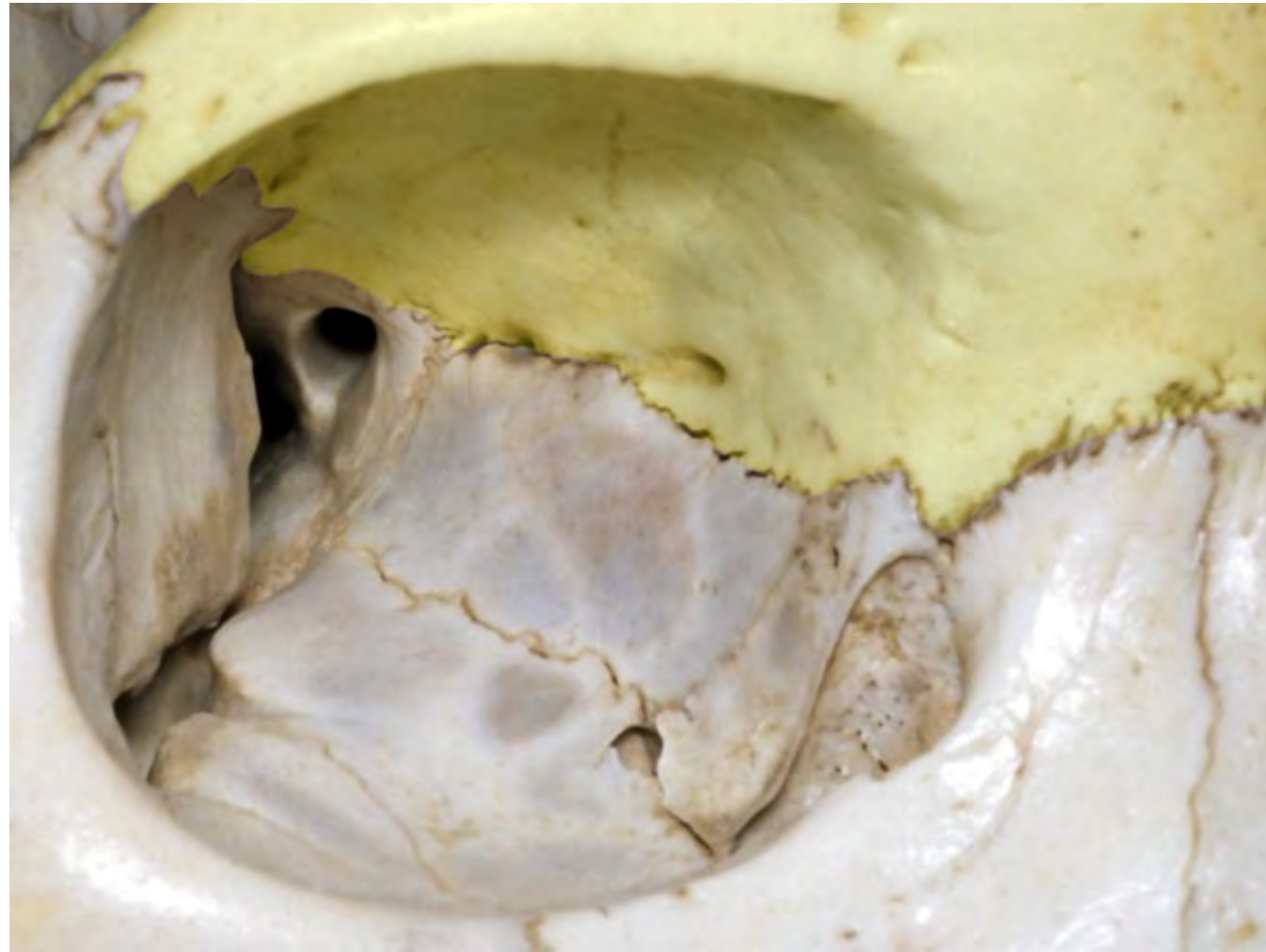


RHOTON

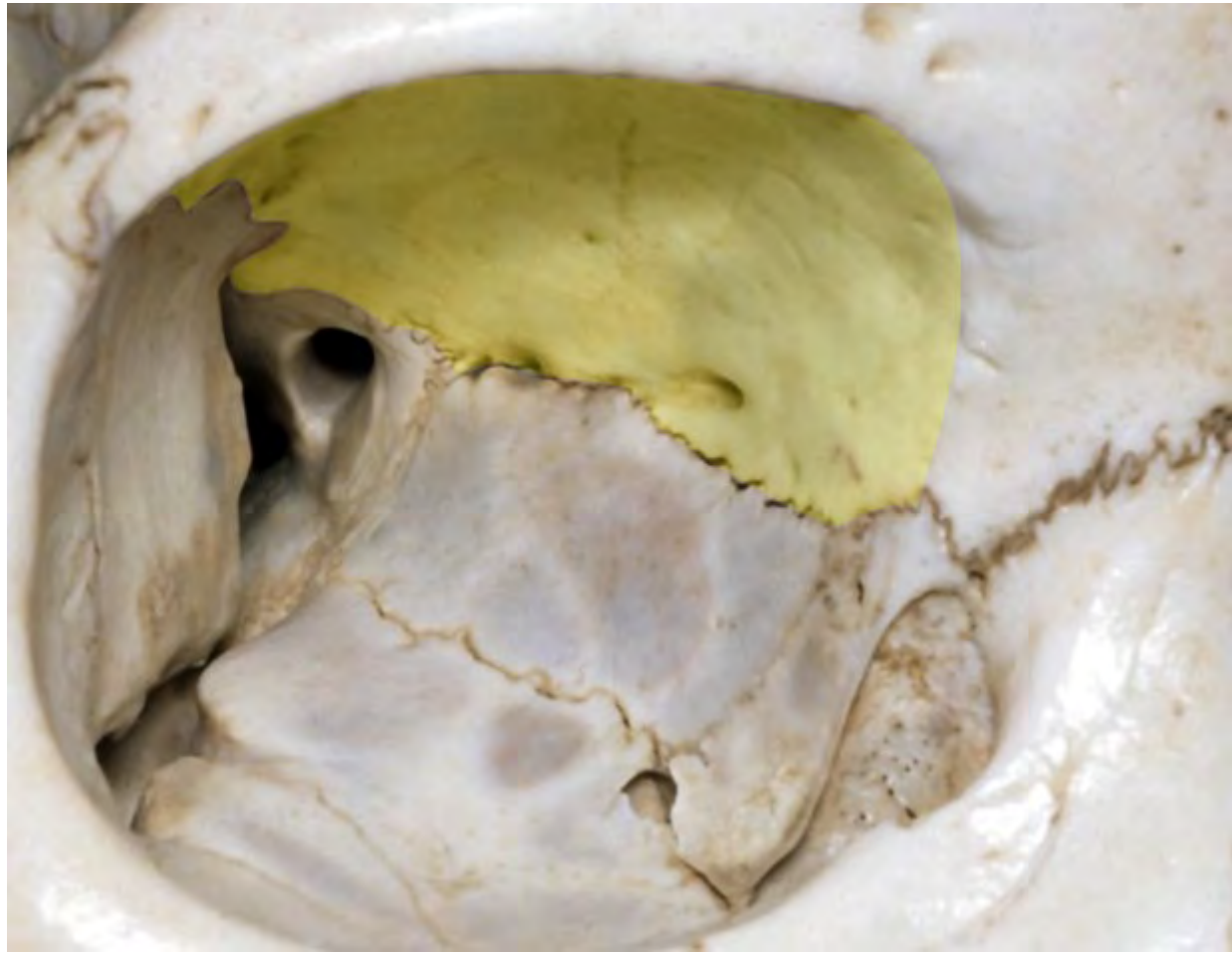


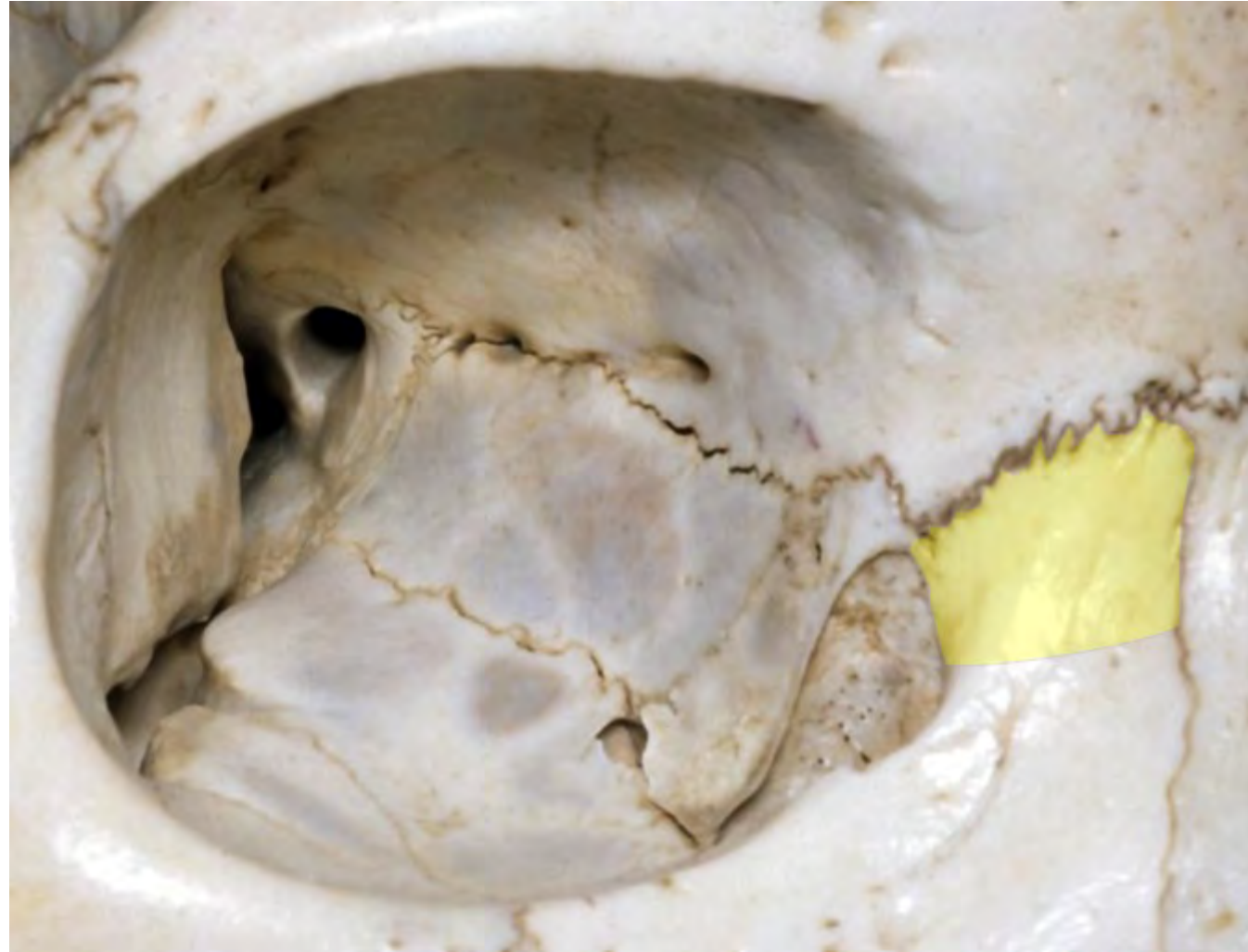


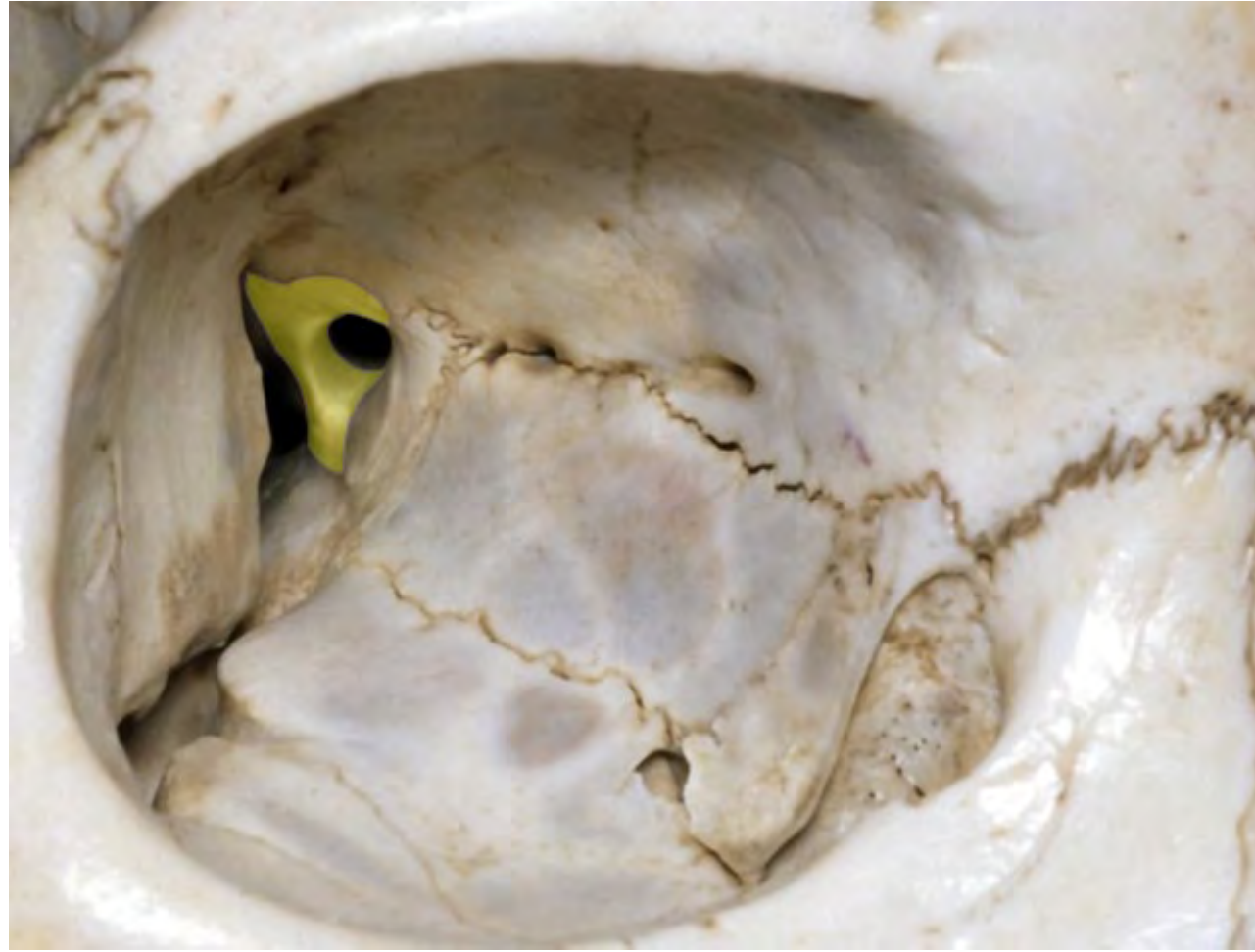


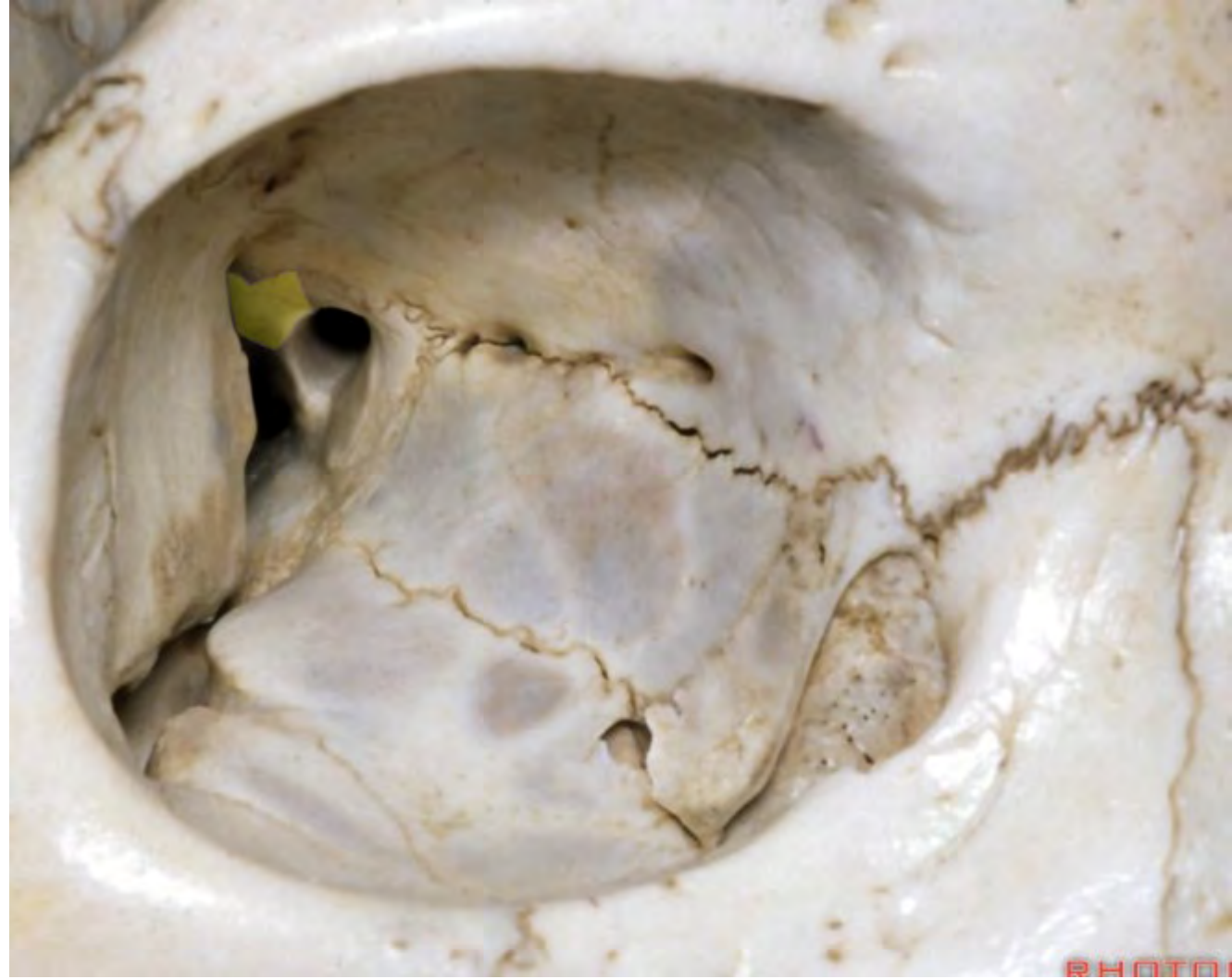


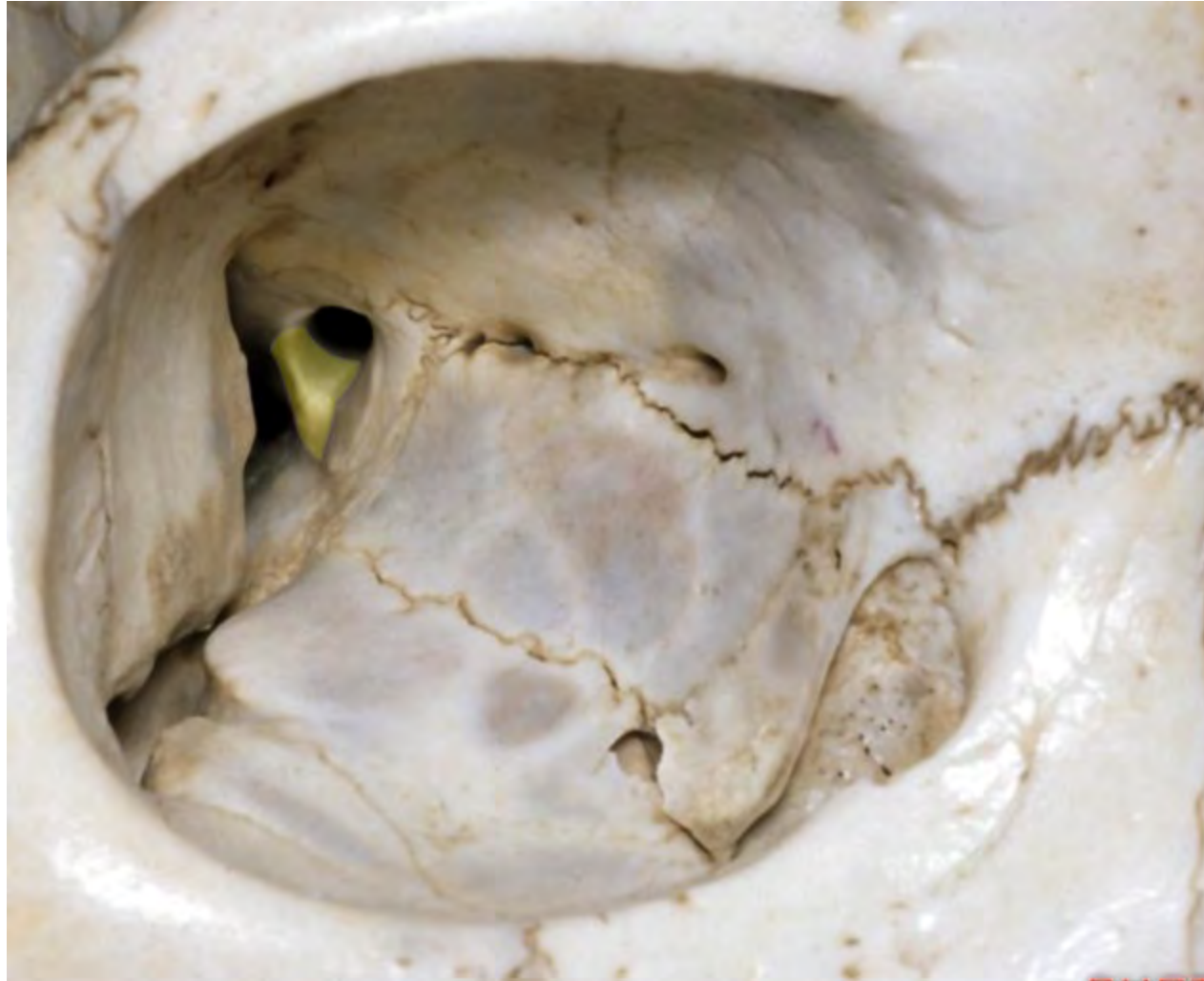

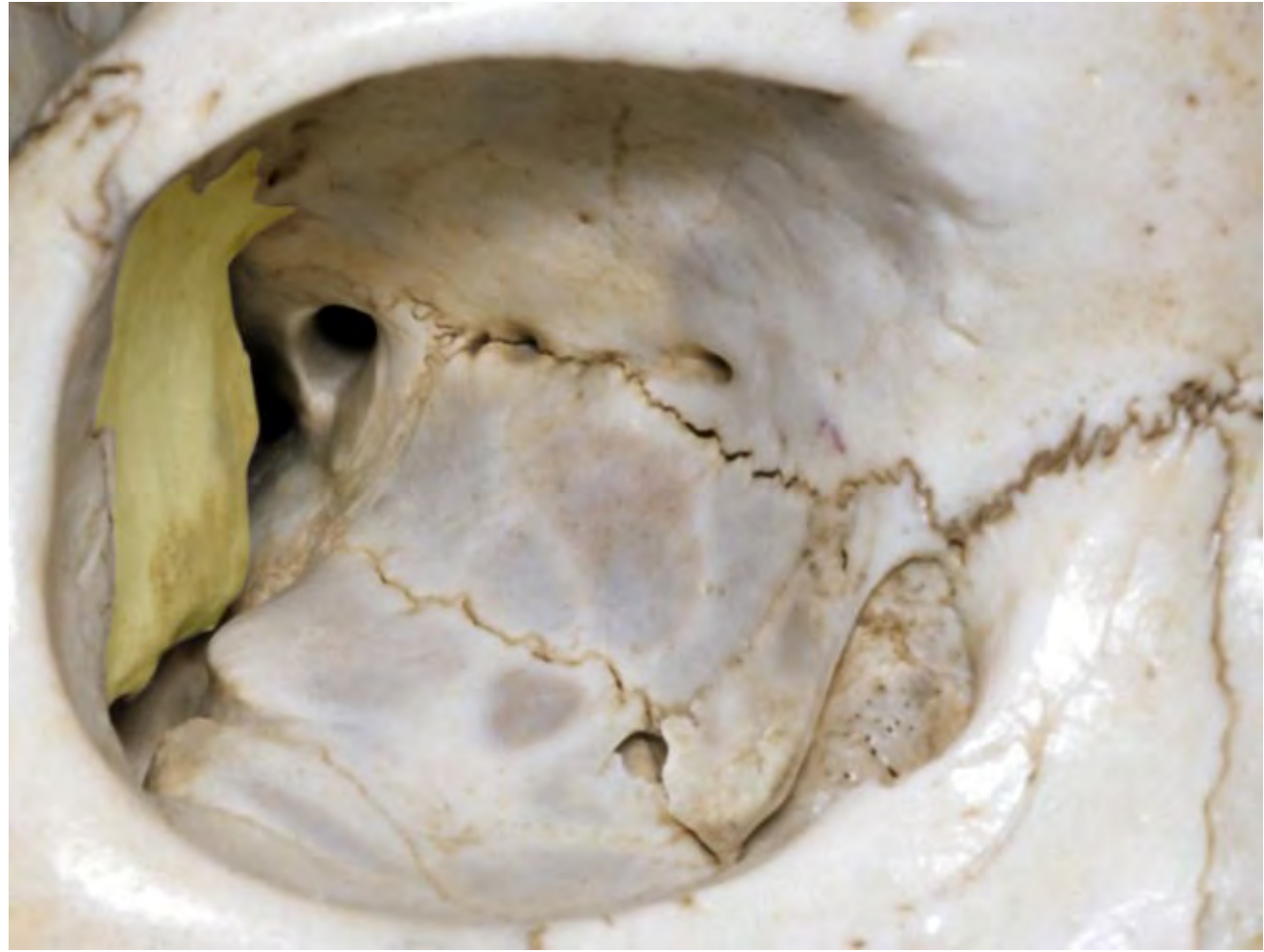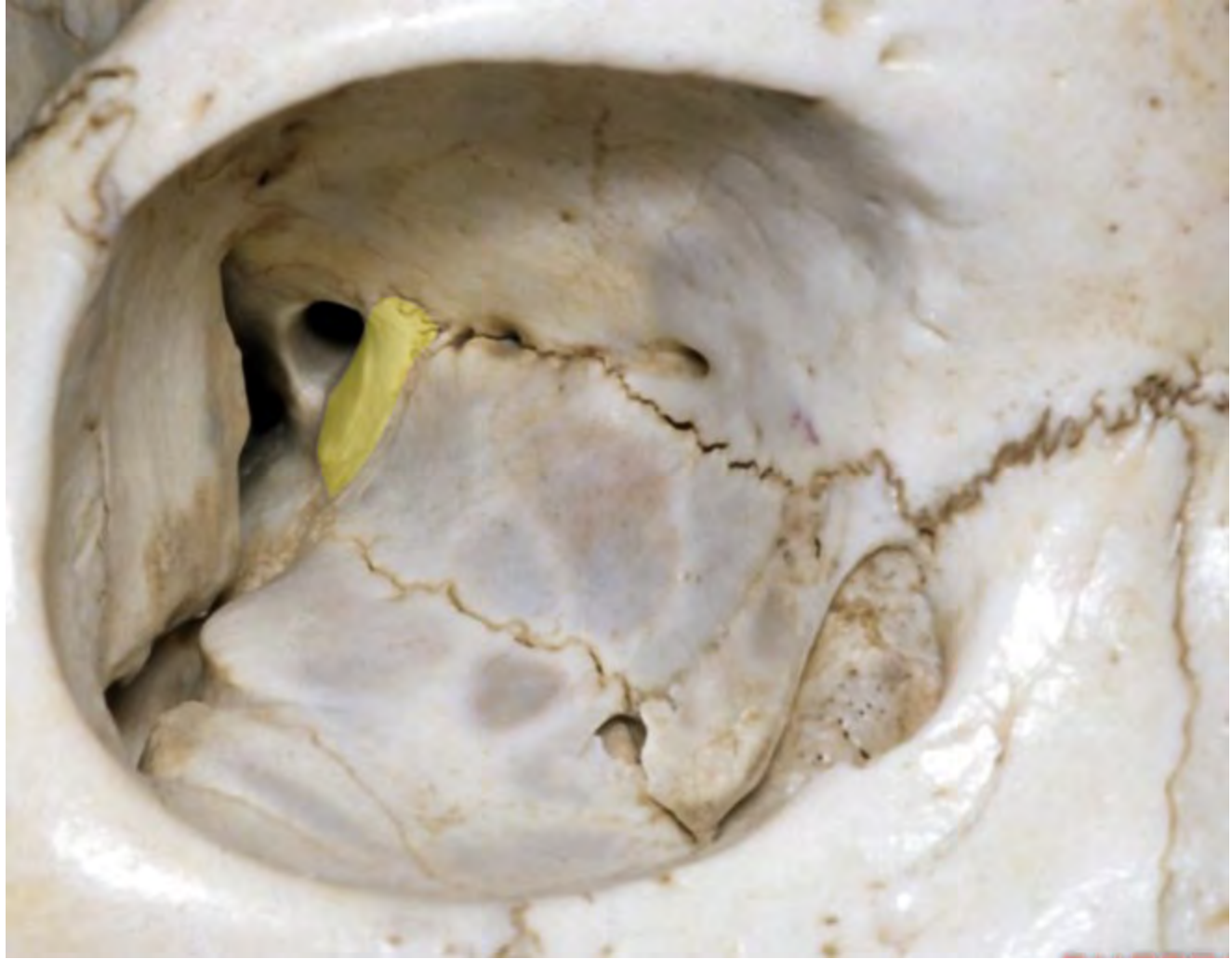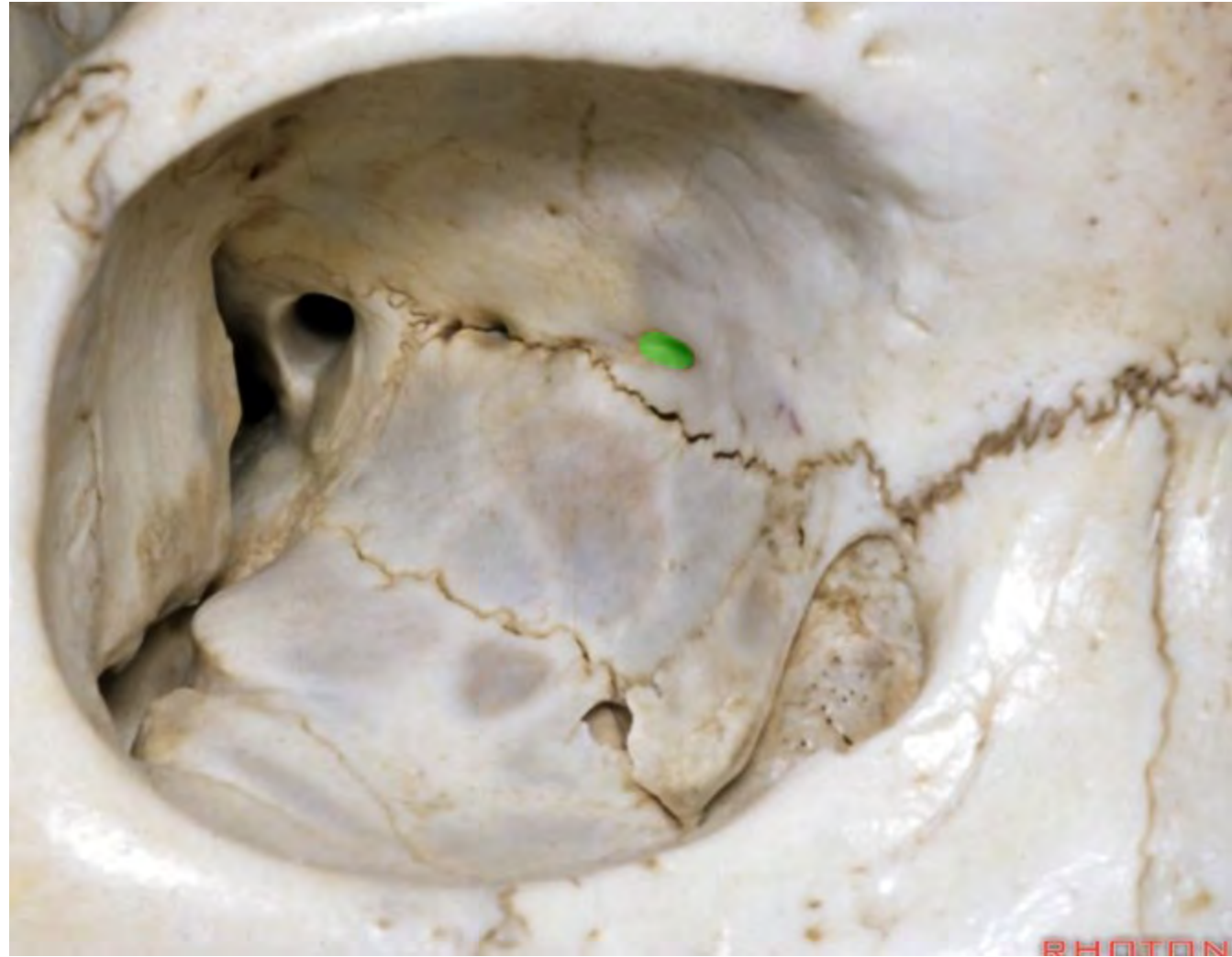




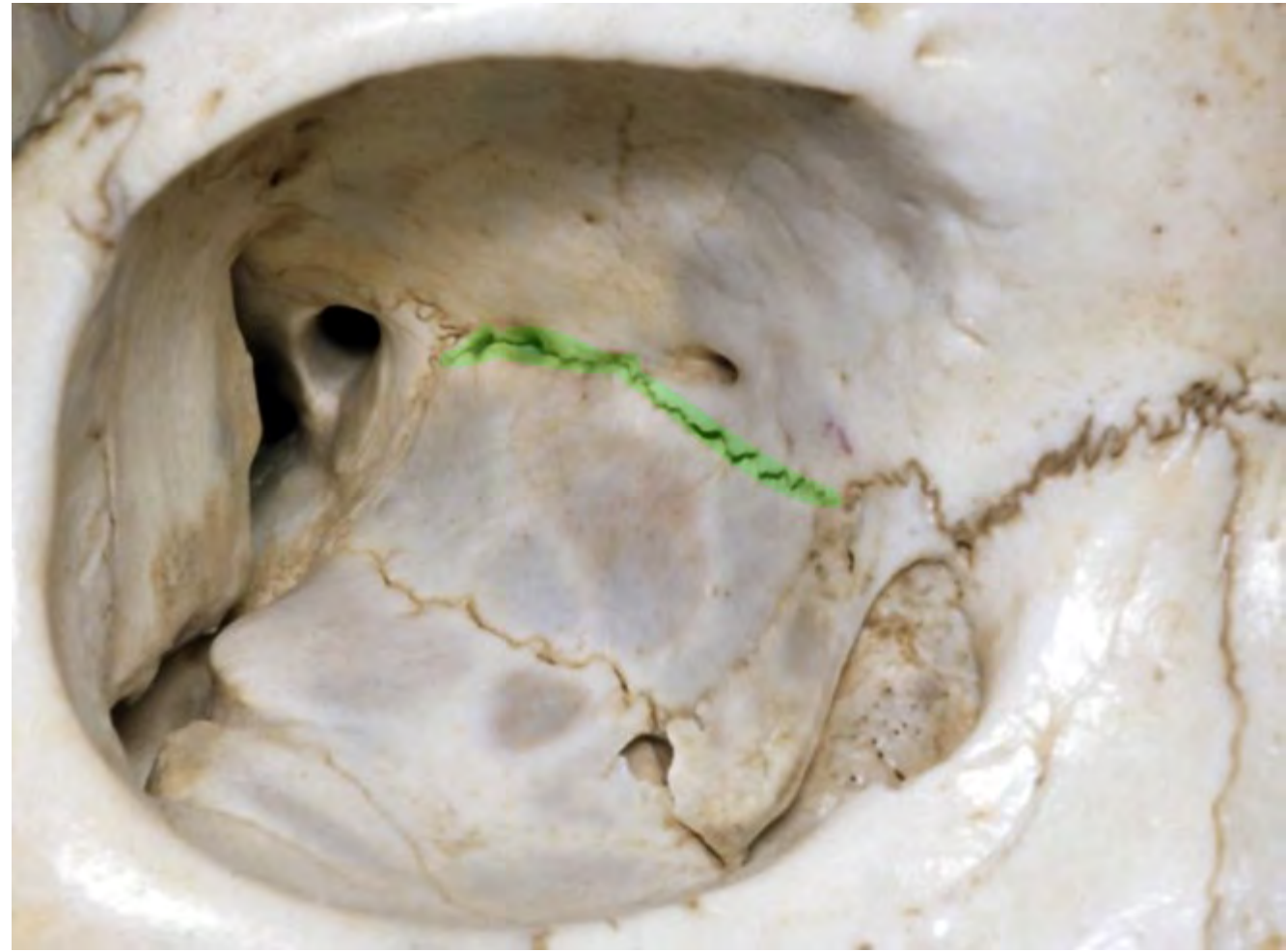


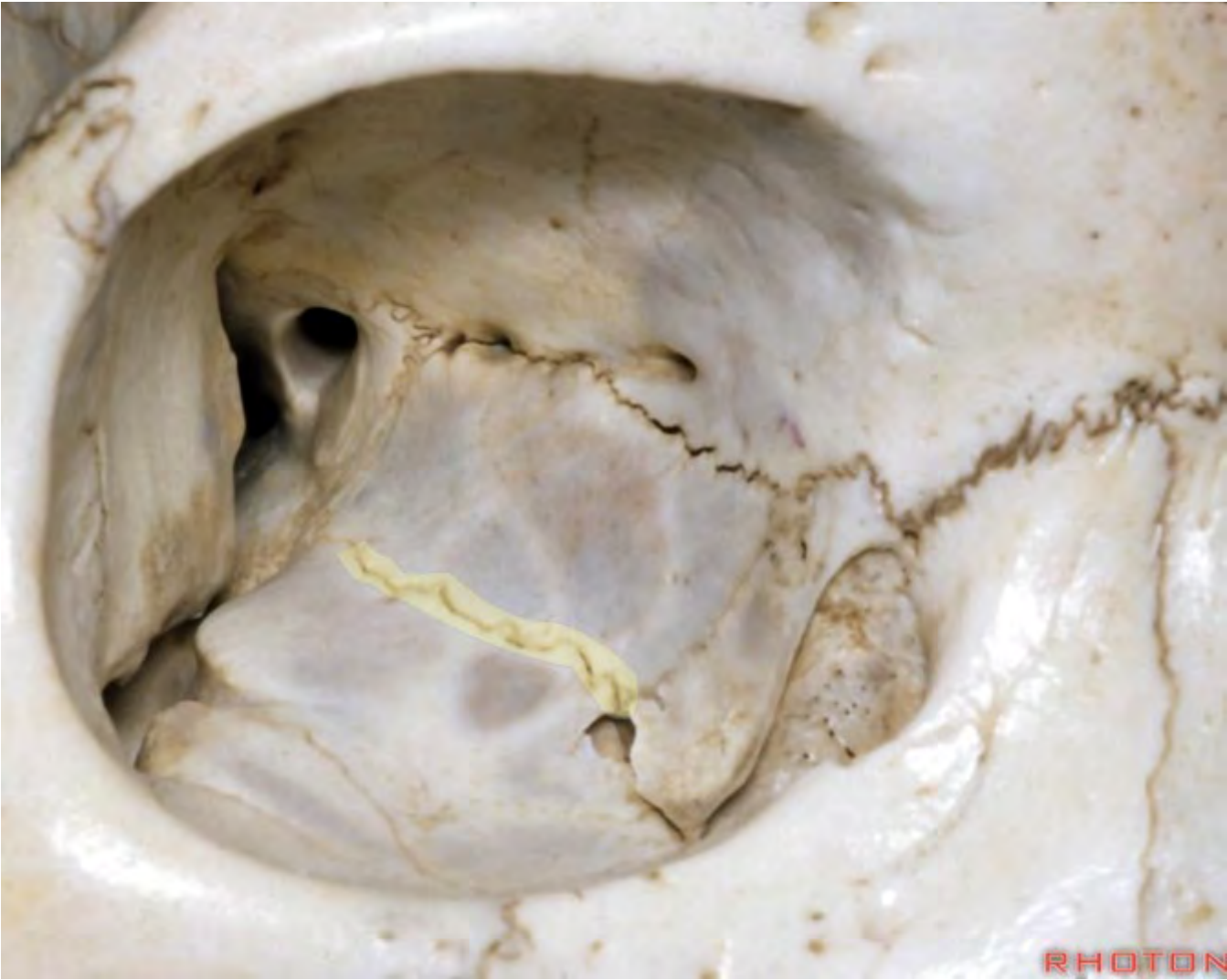




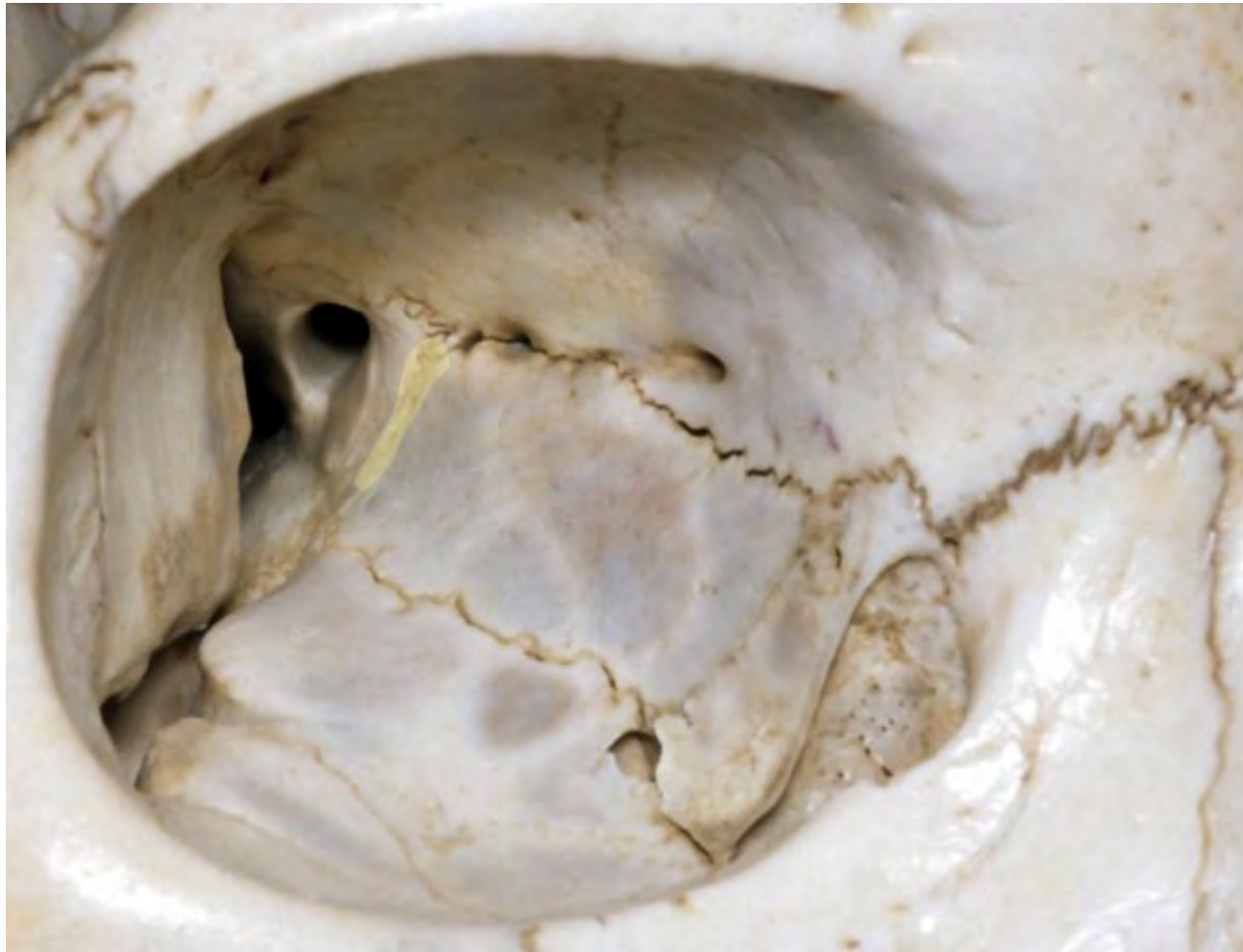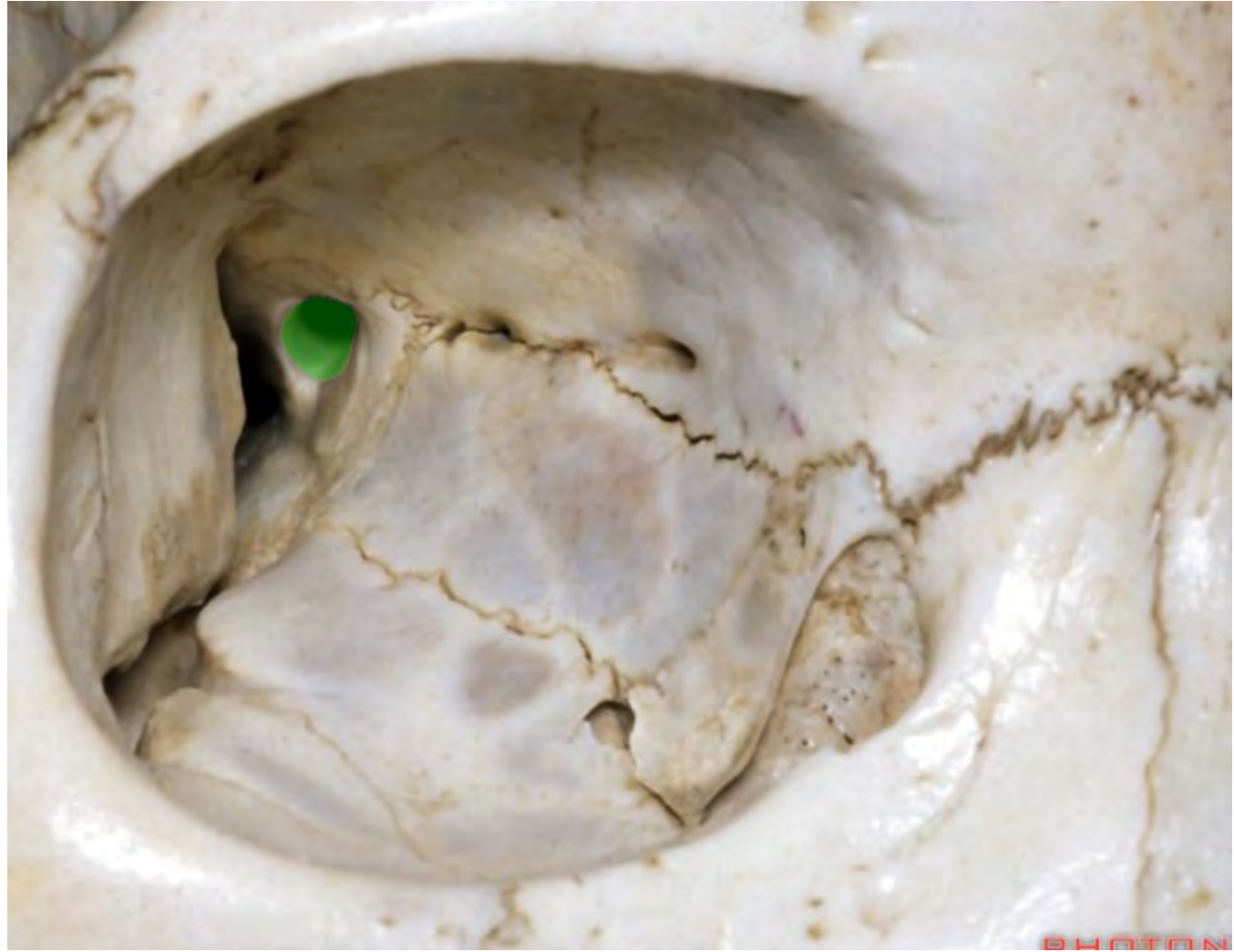


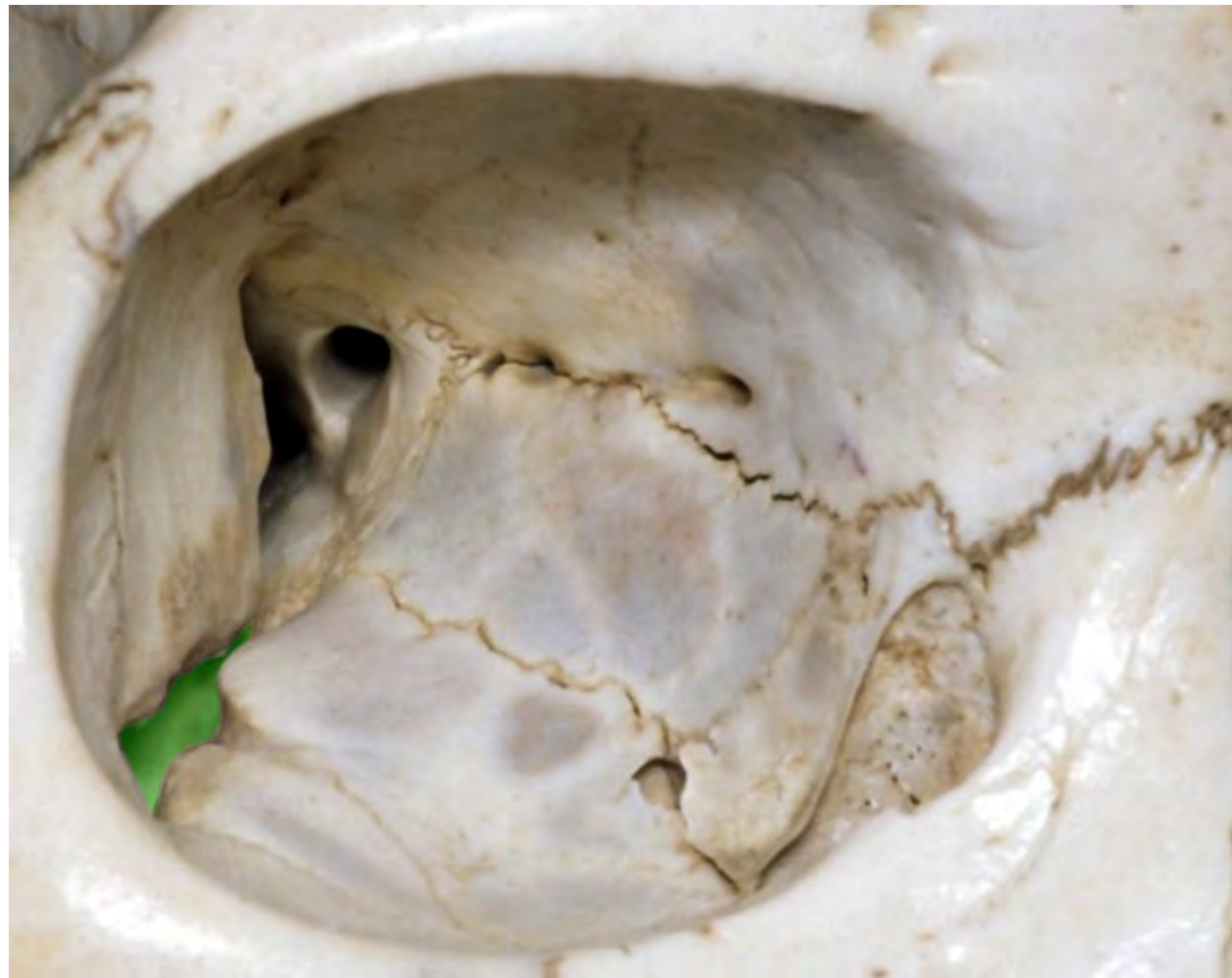


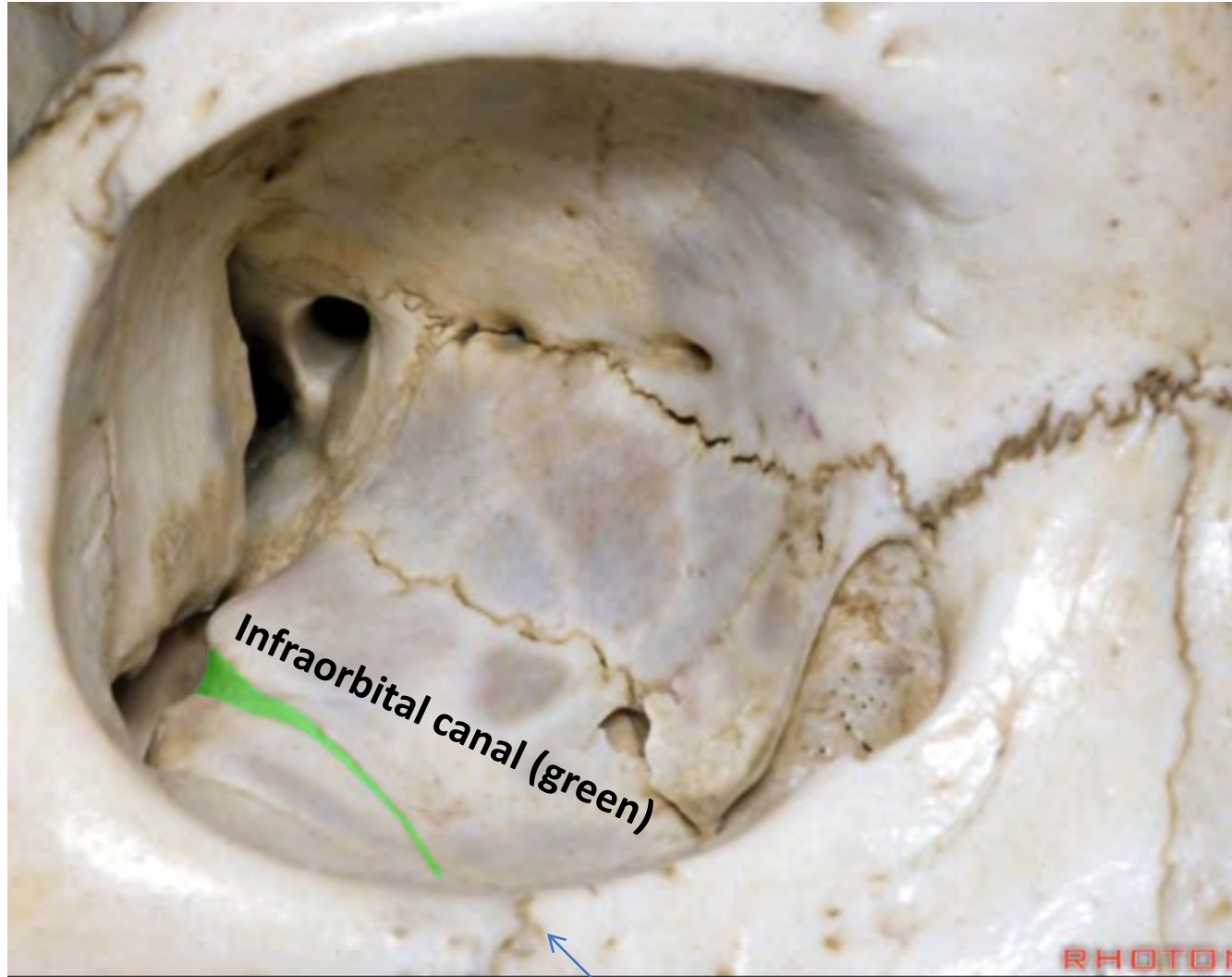










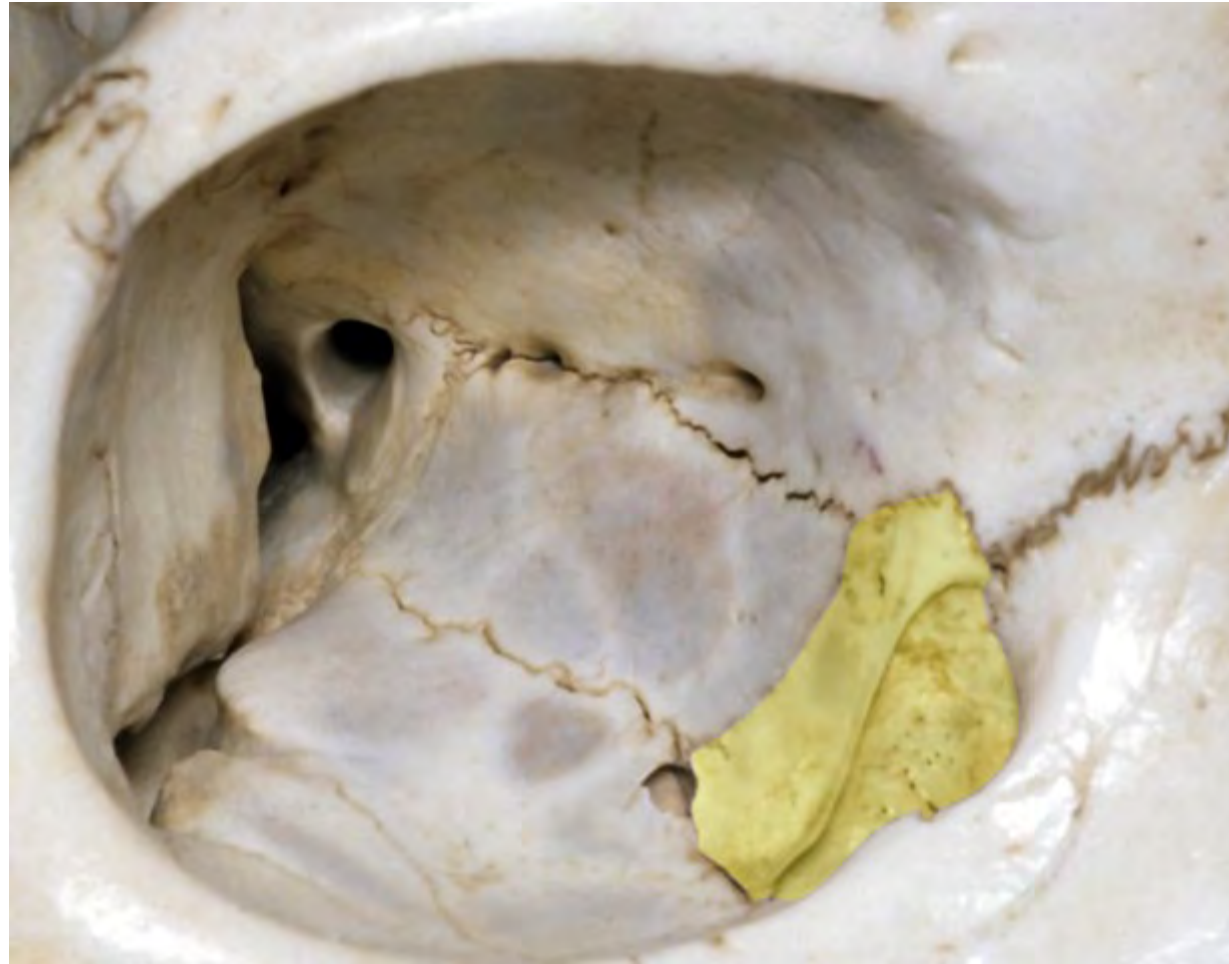


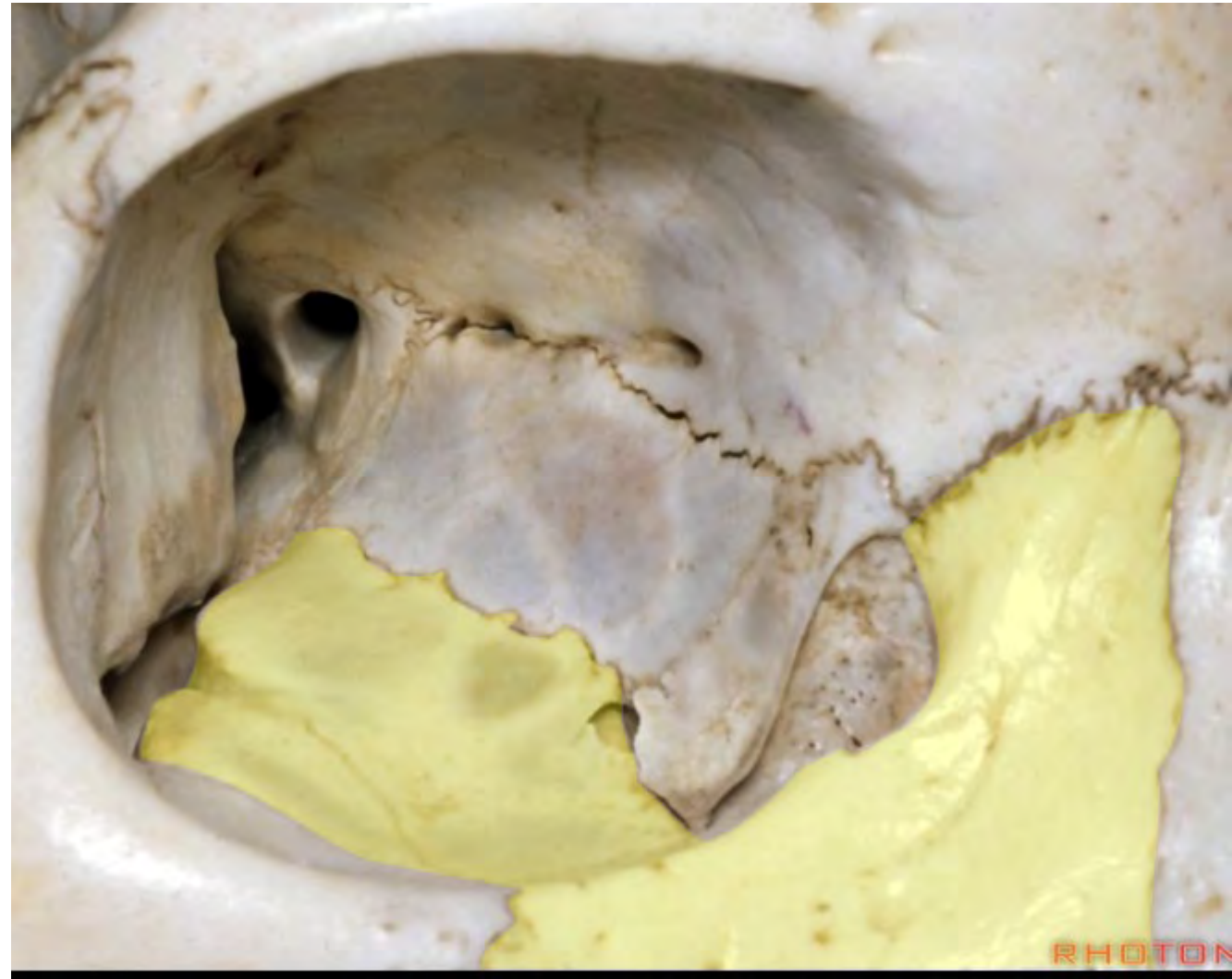
Infraorbital canal (green)



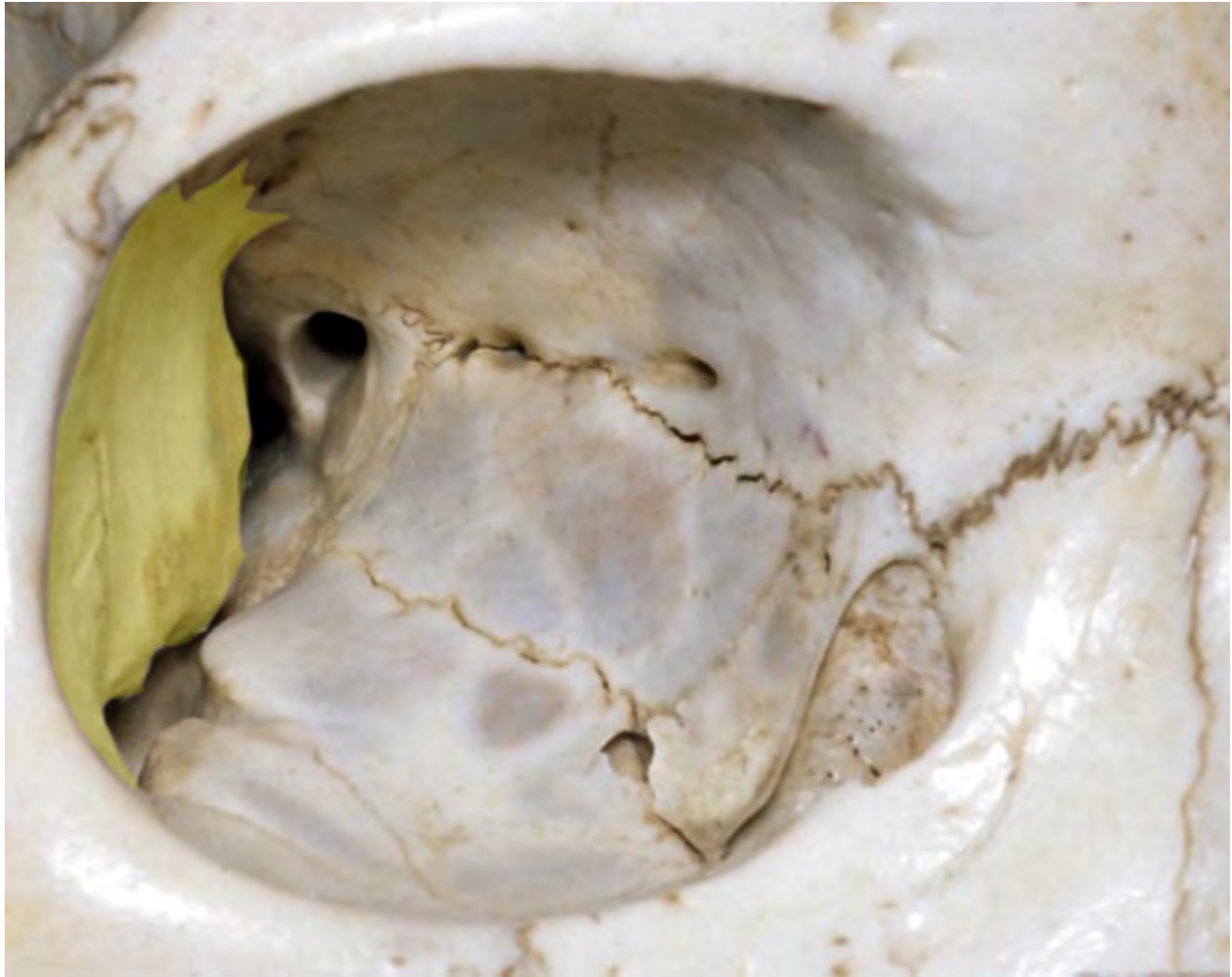Infraorbital foramen (arrow)

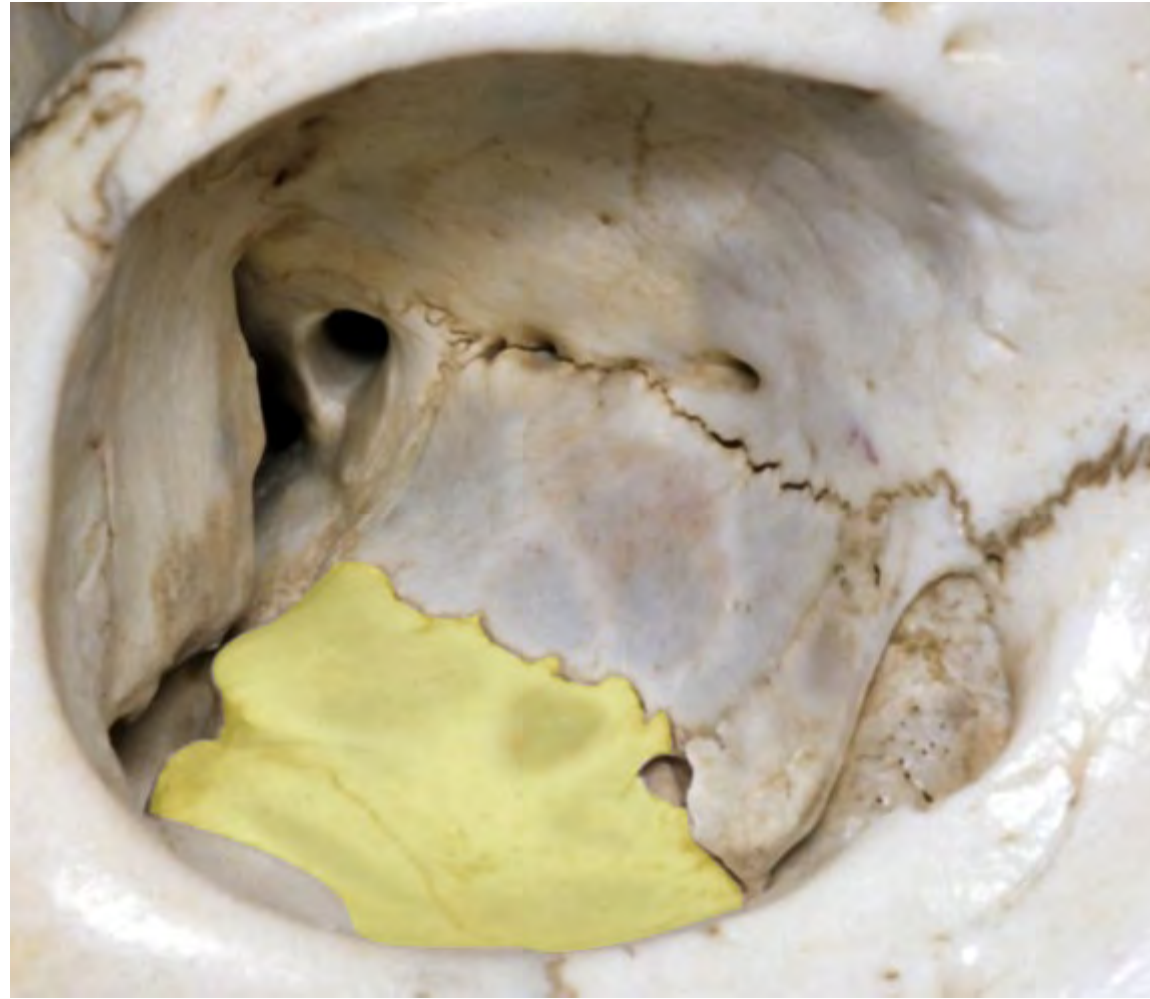RHOTO

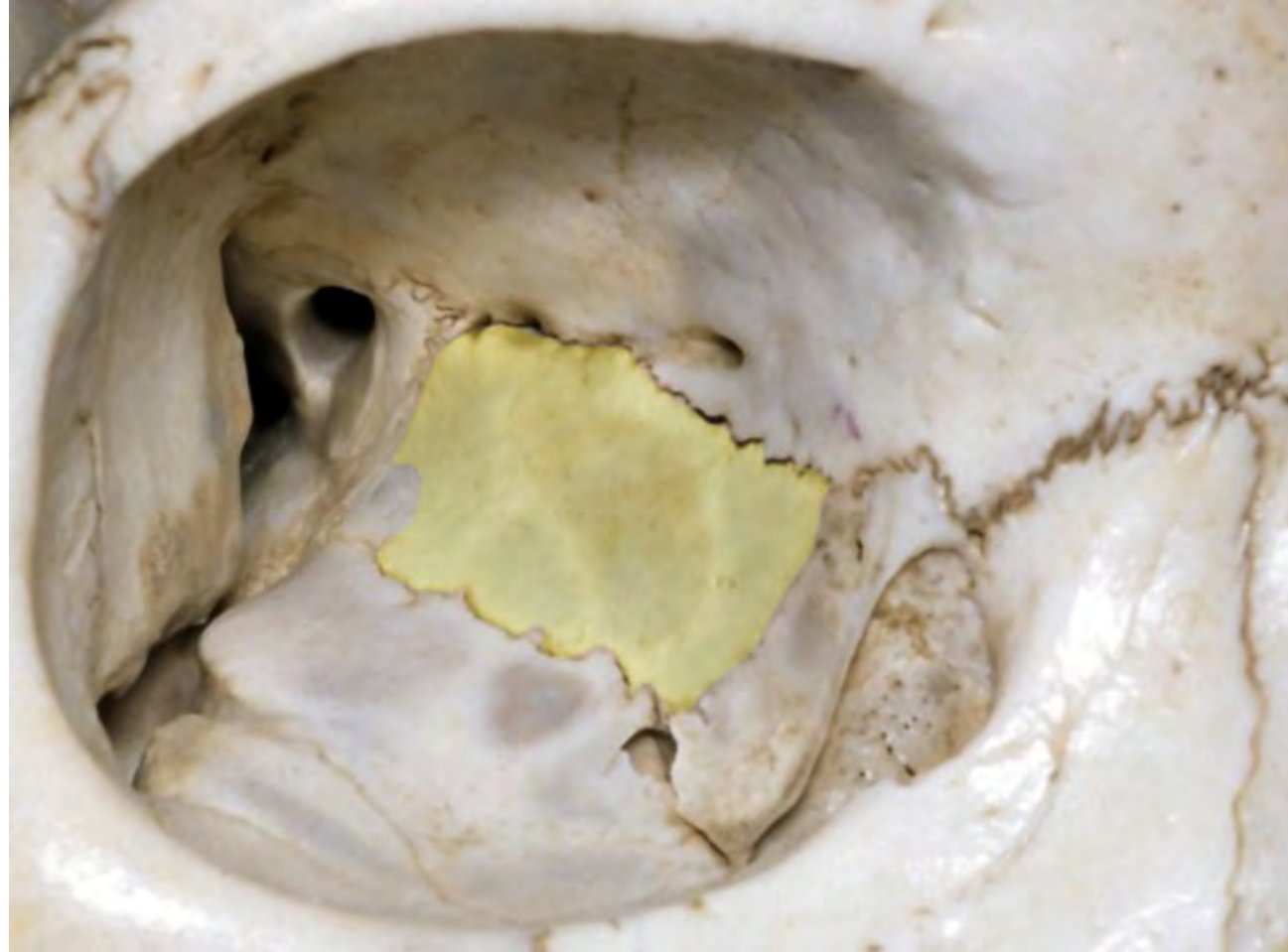


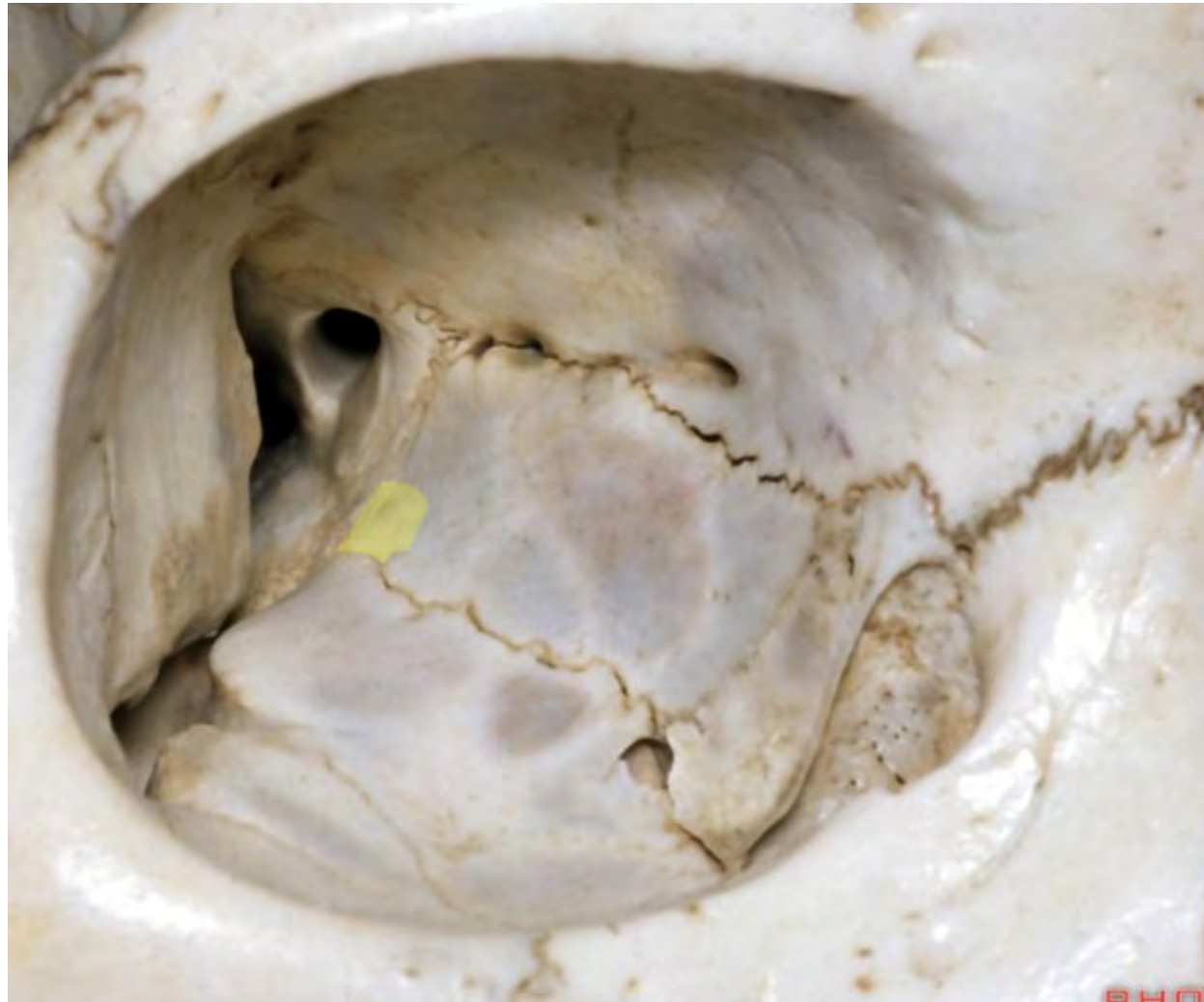


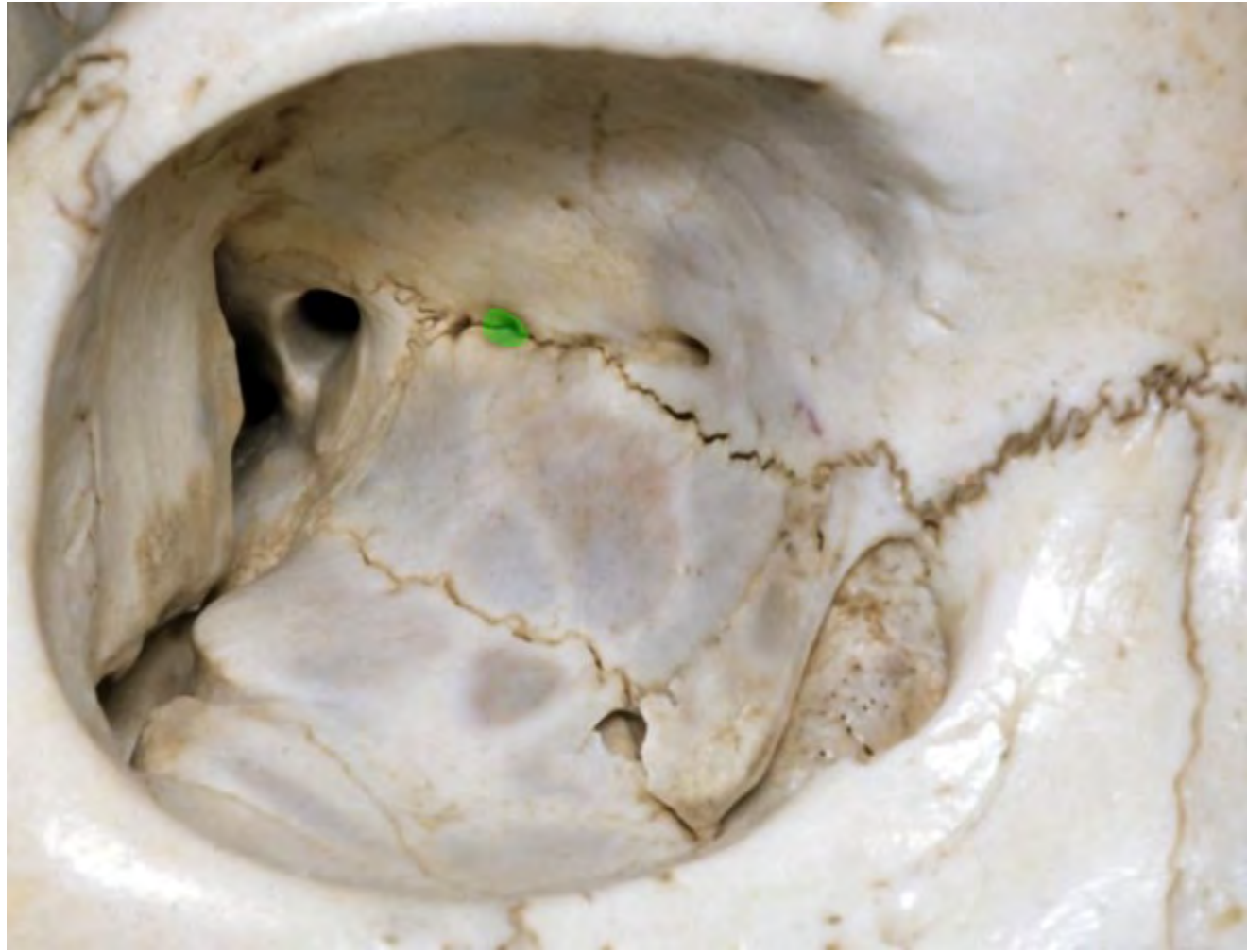


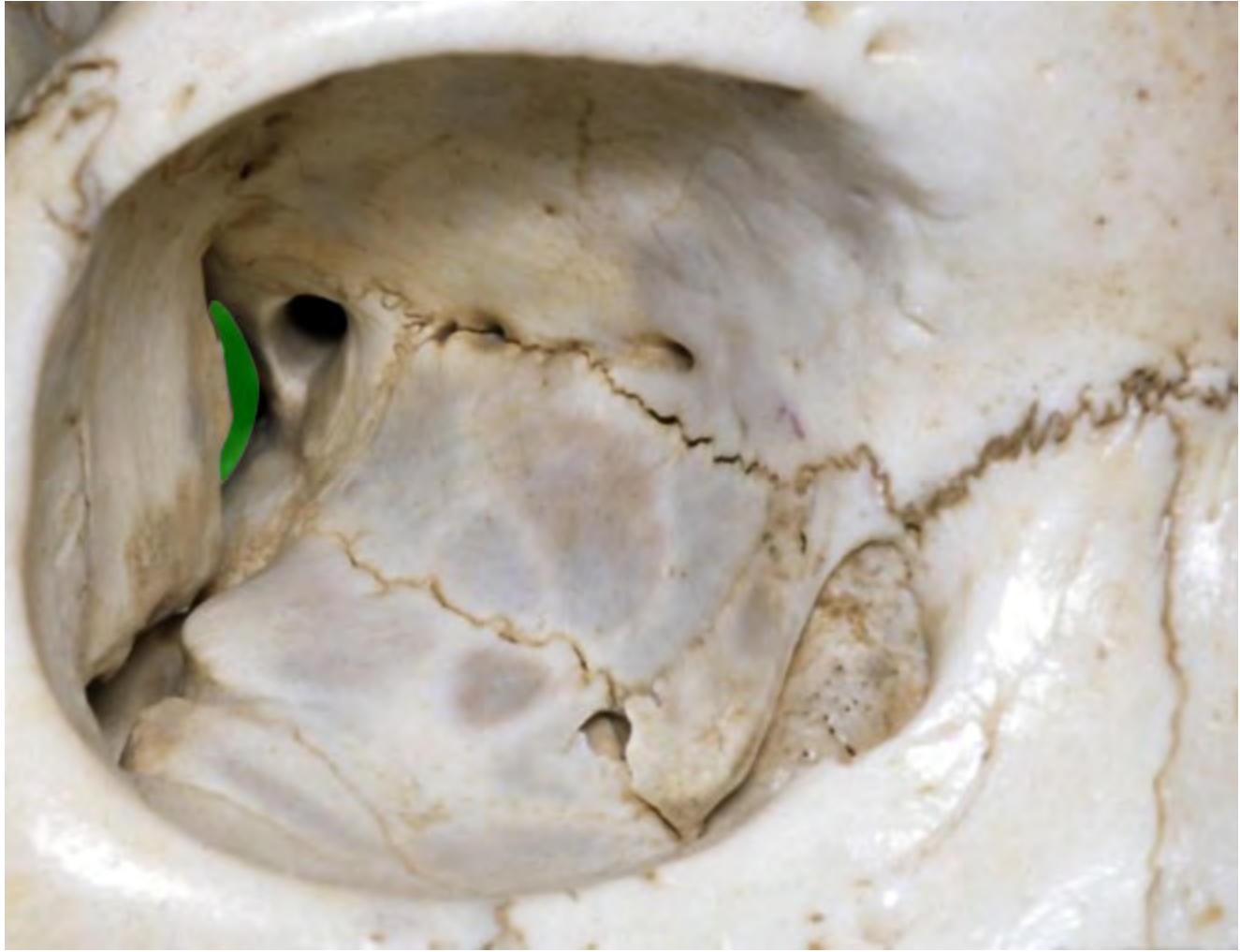




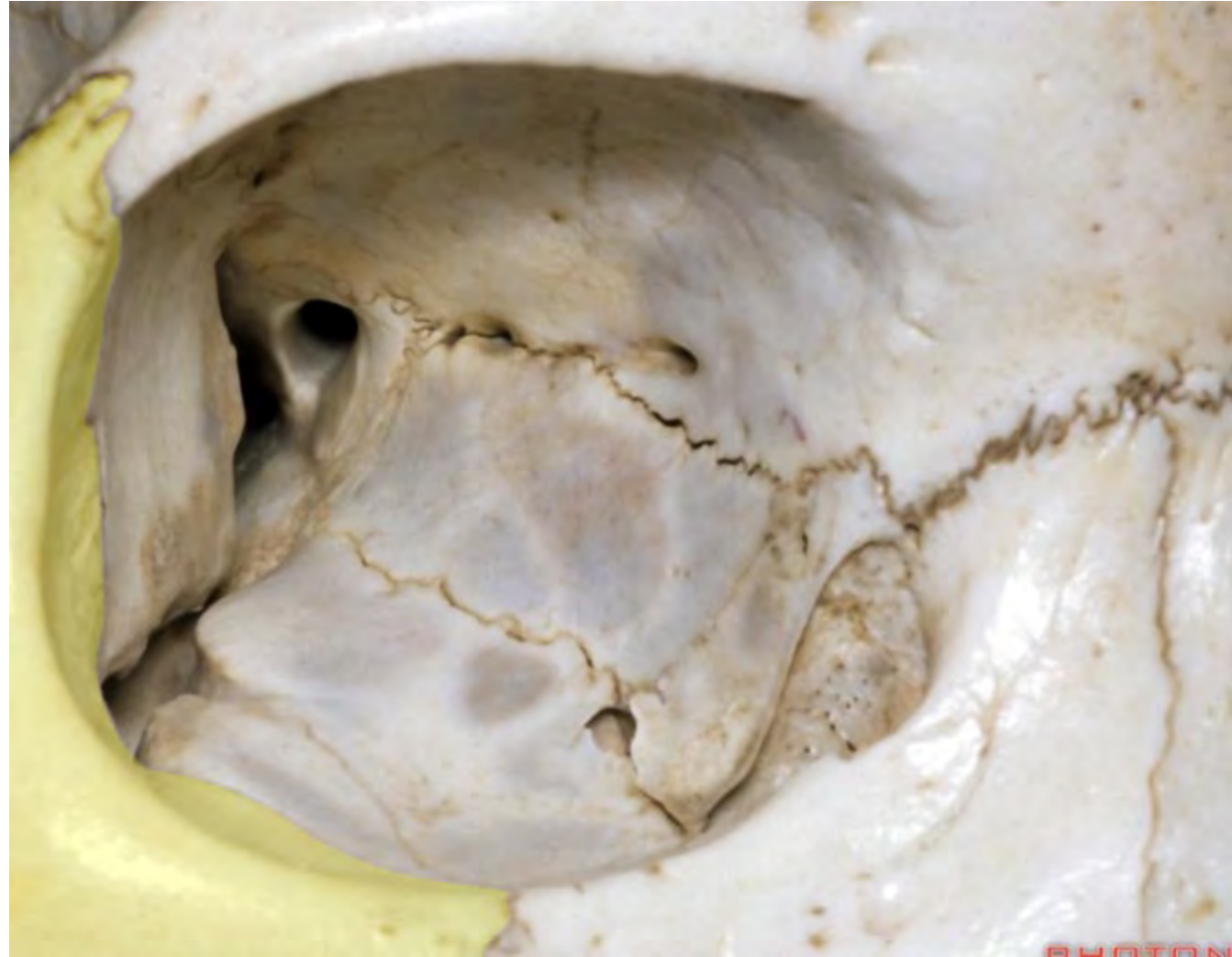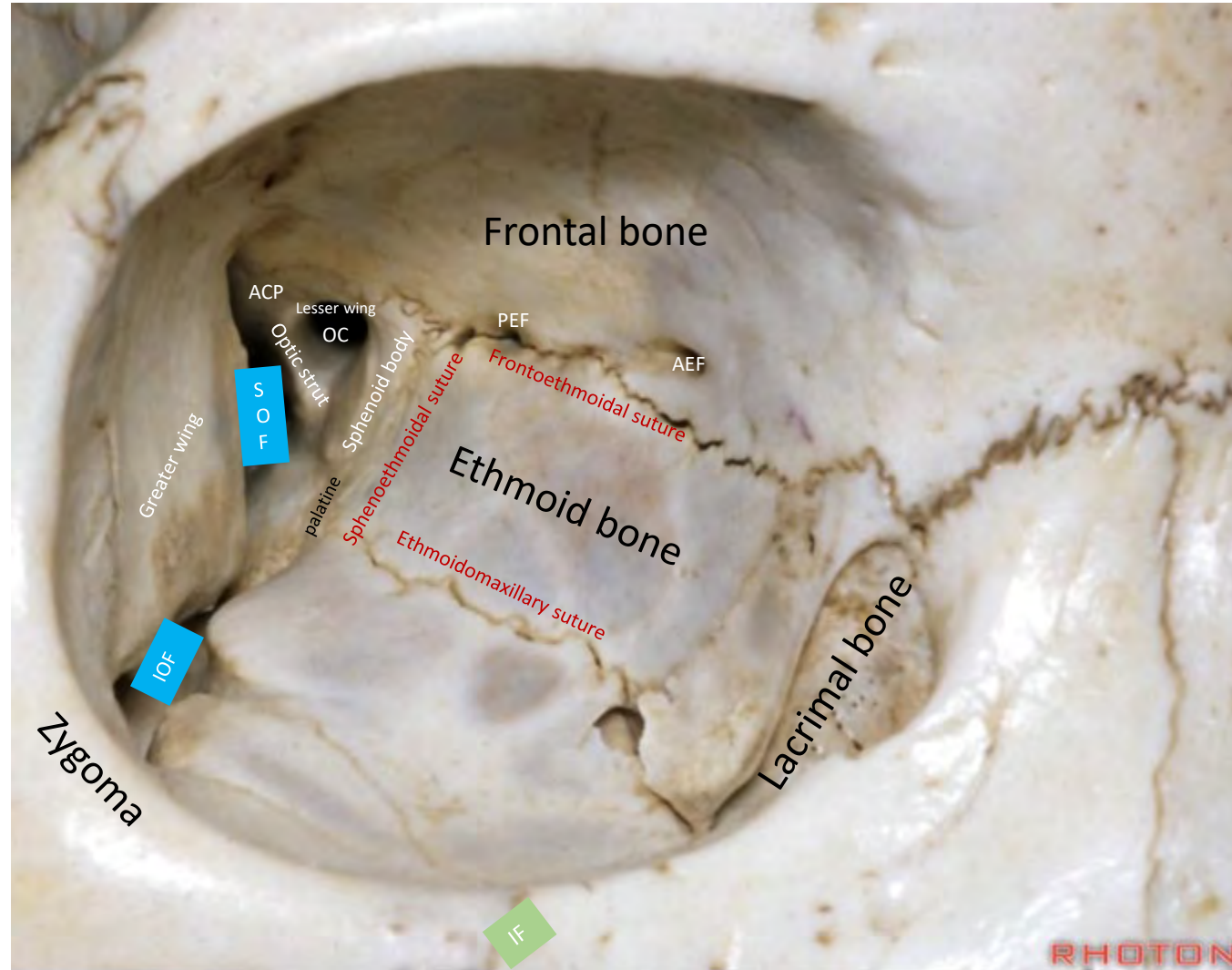


PHOTO

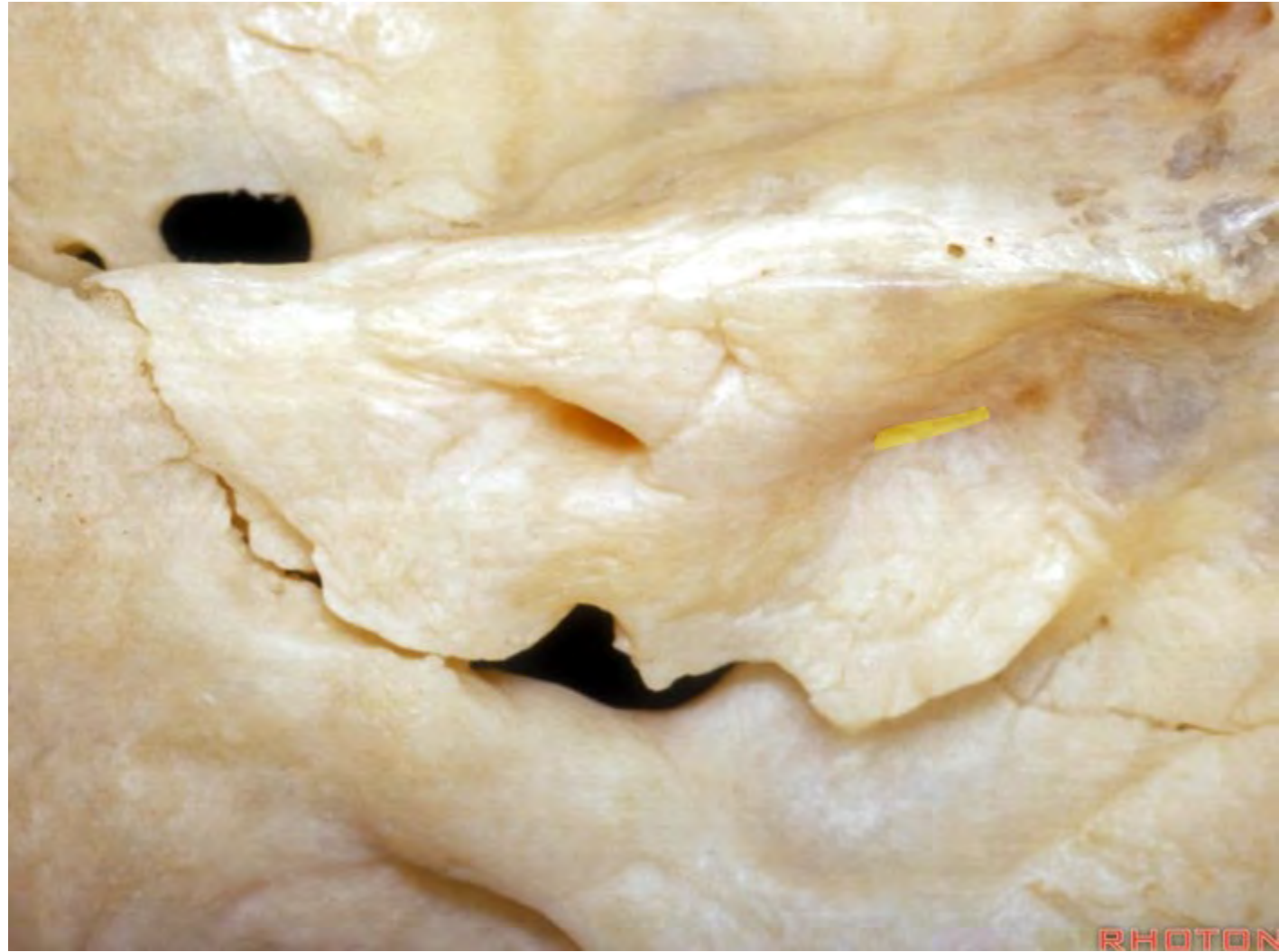


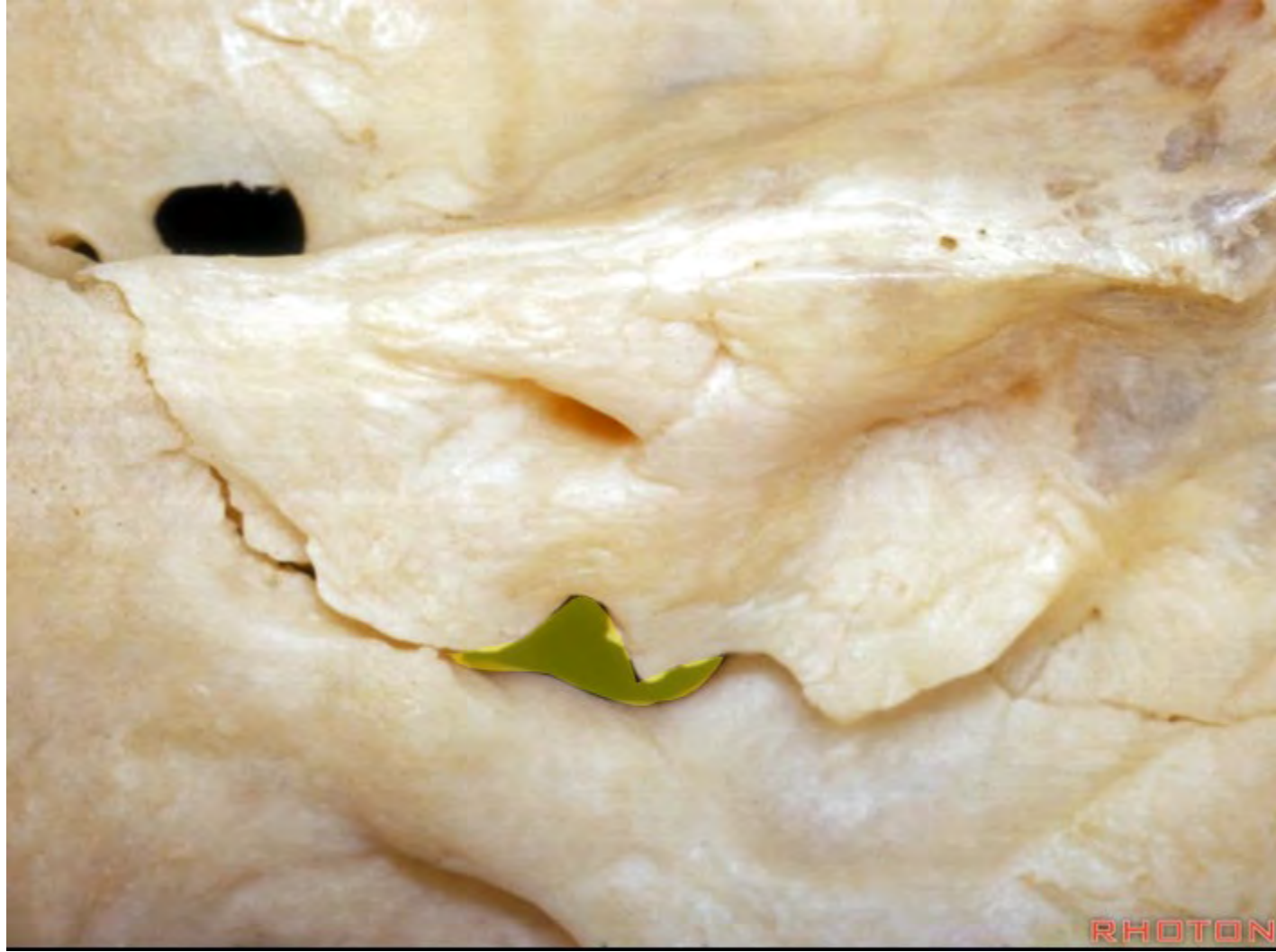
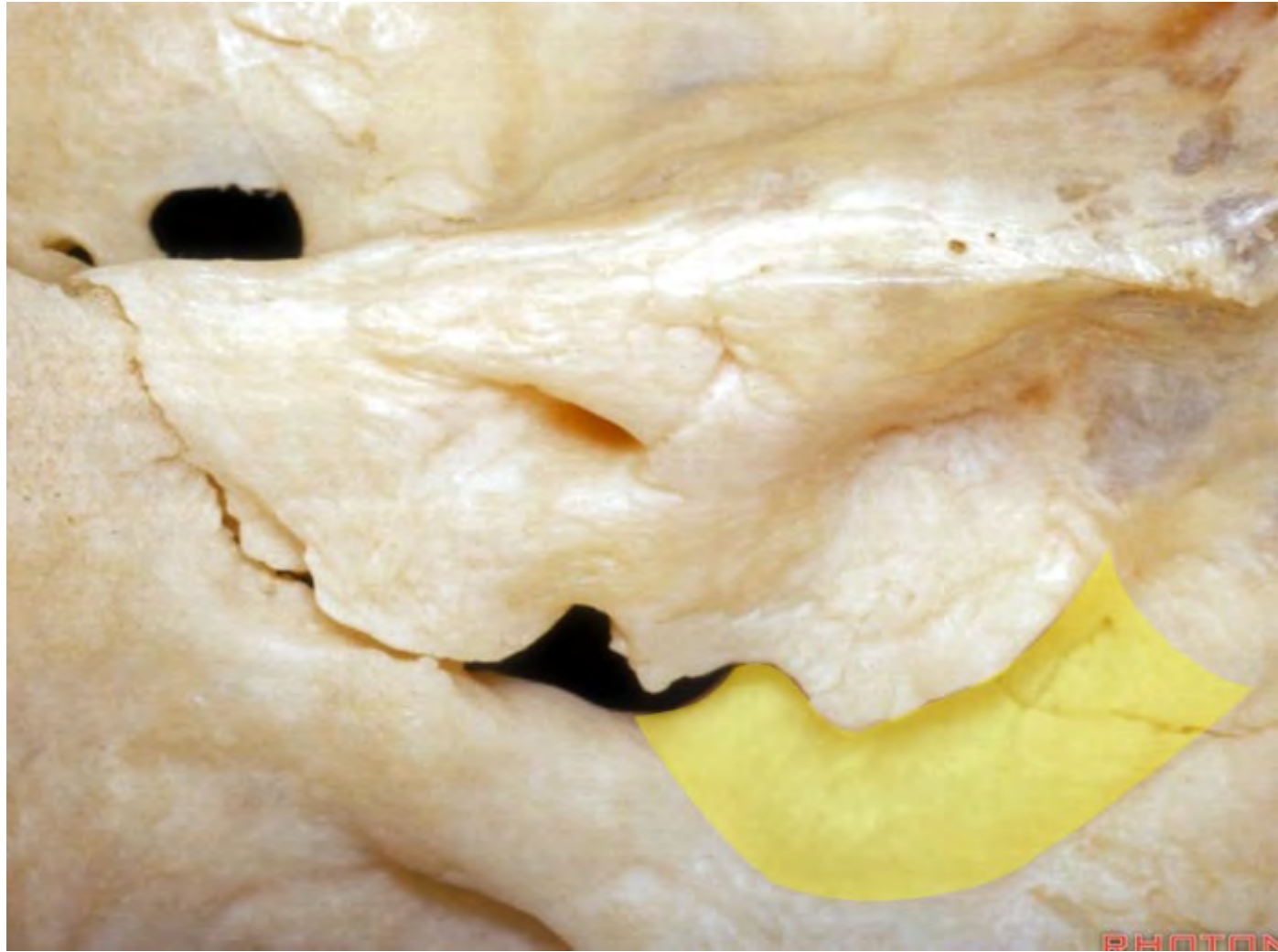


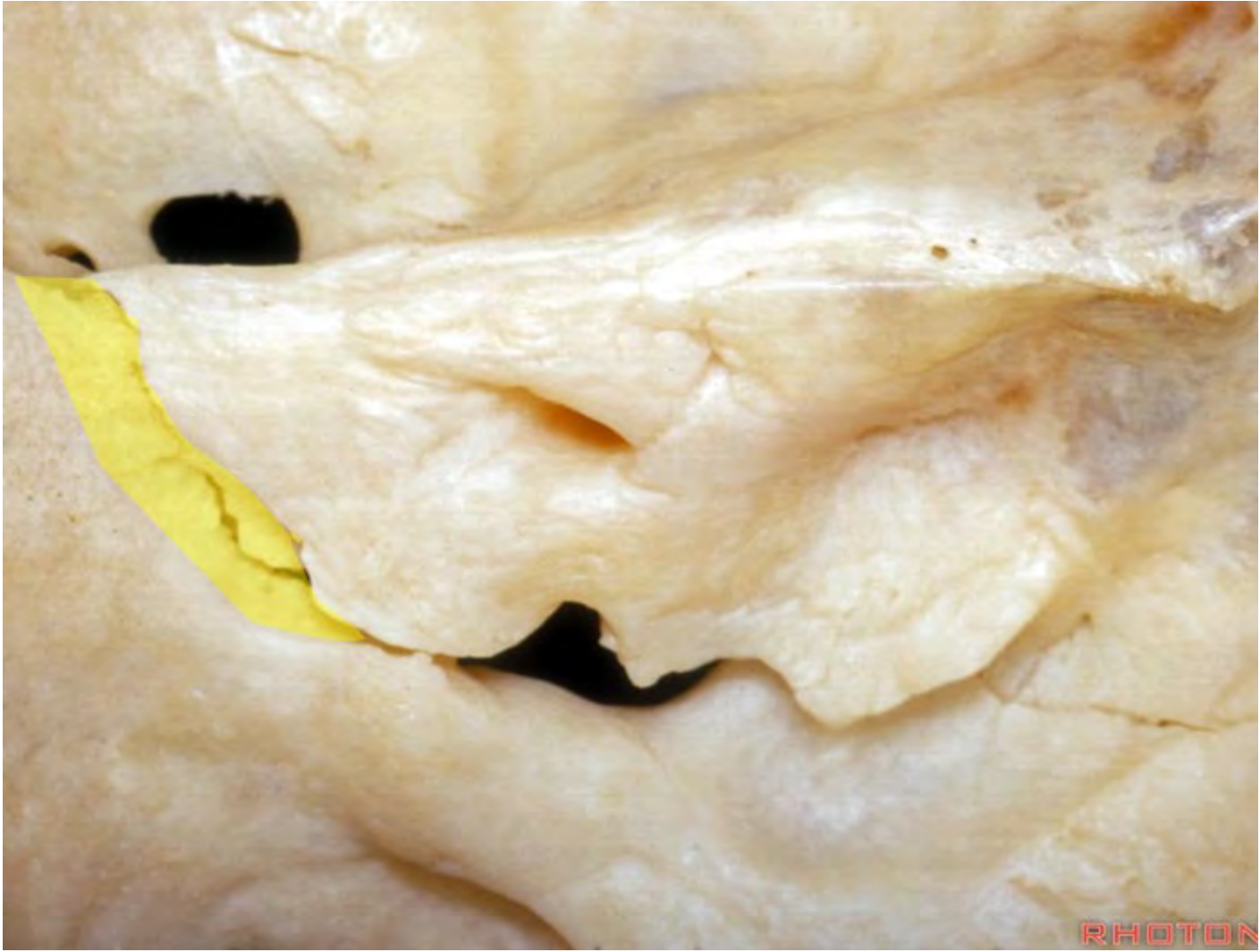


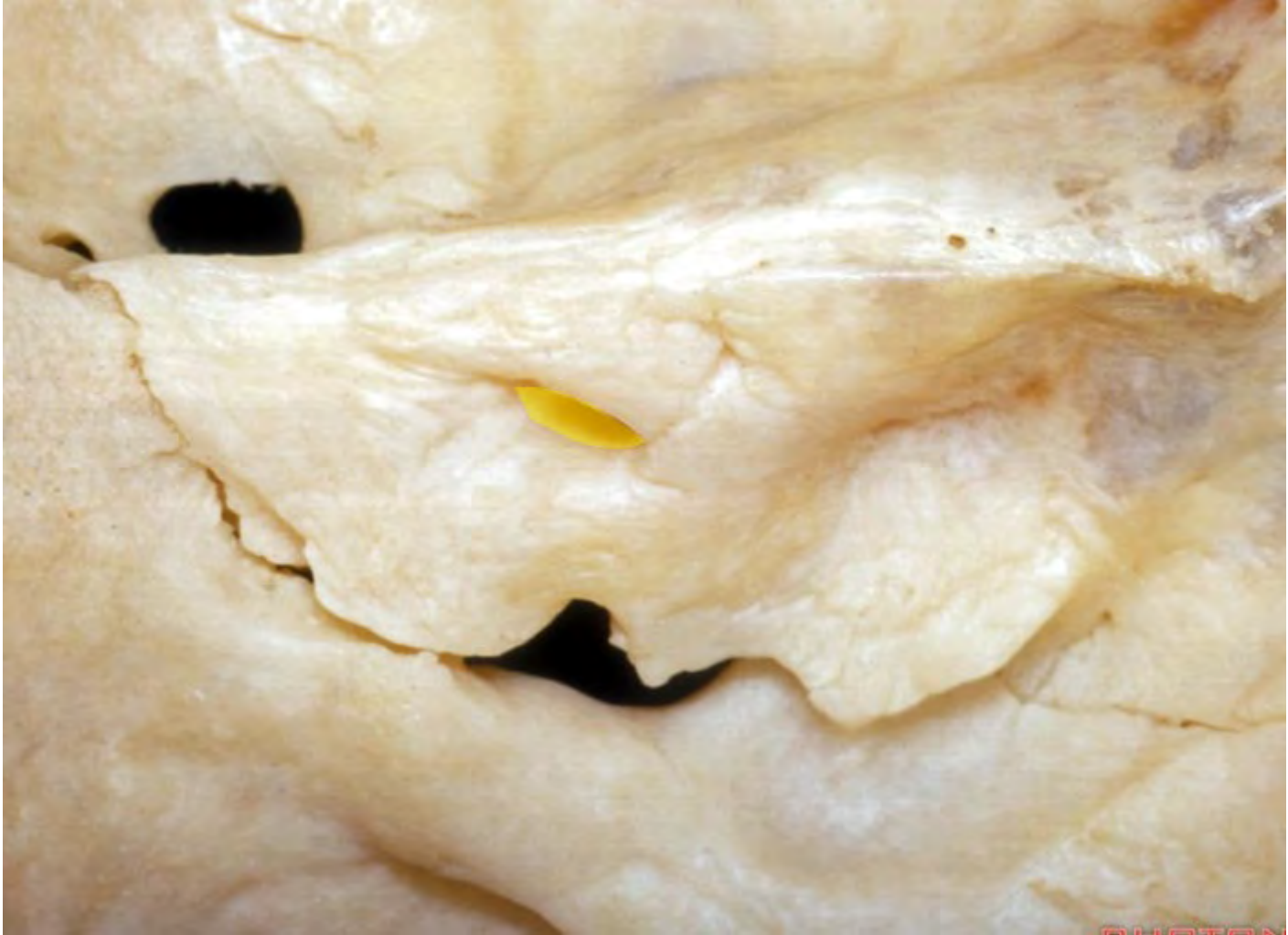




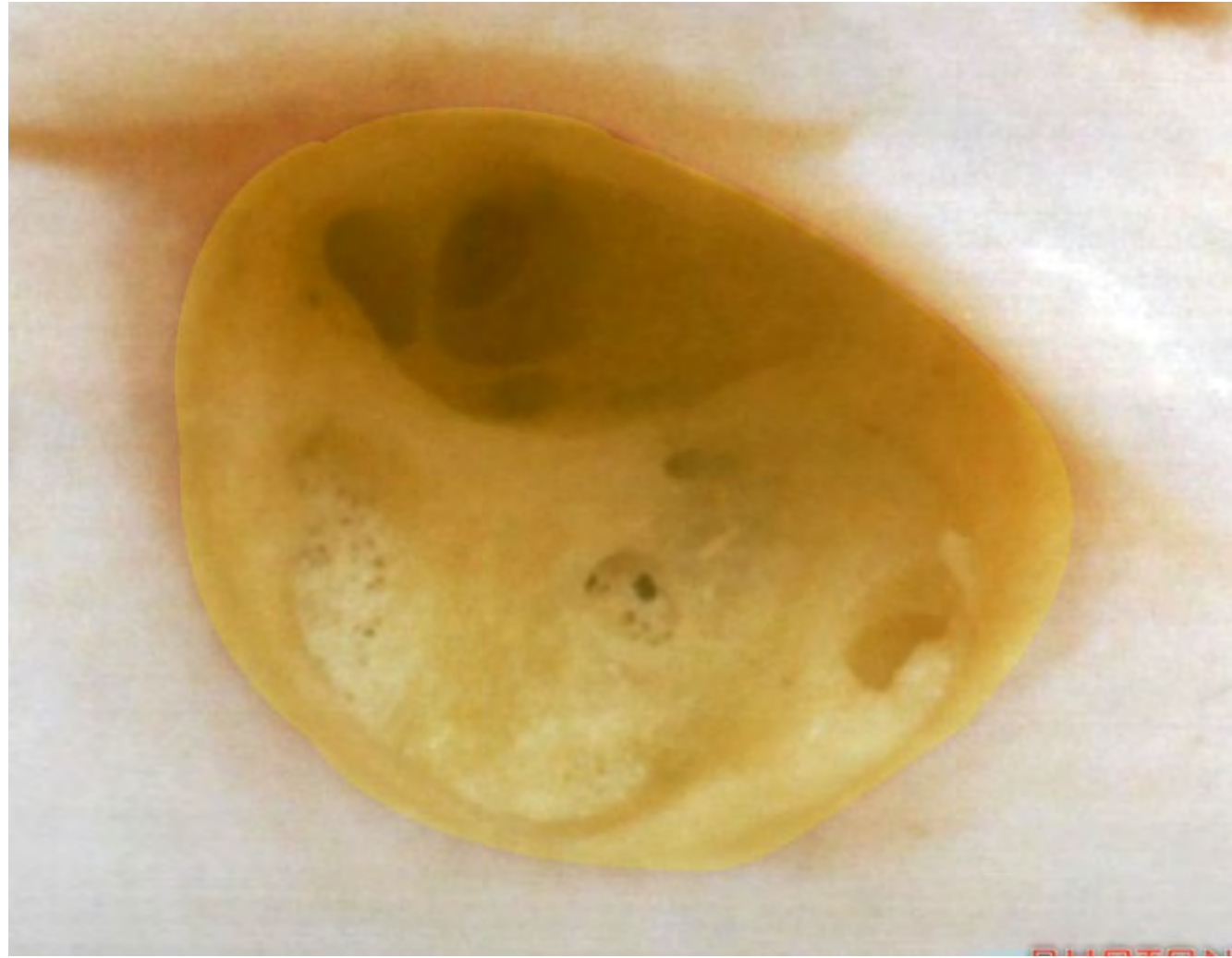


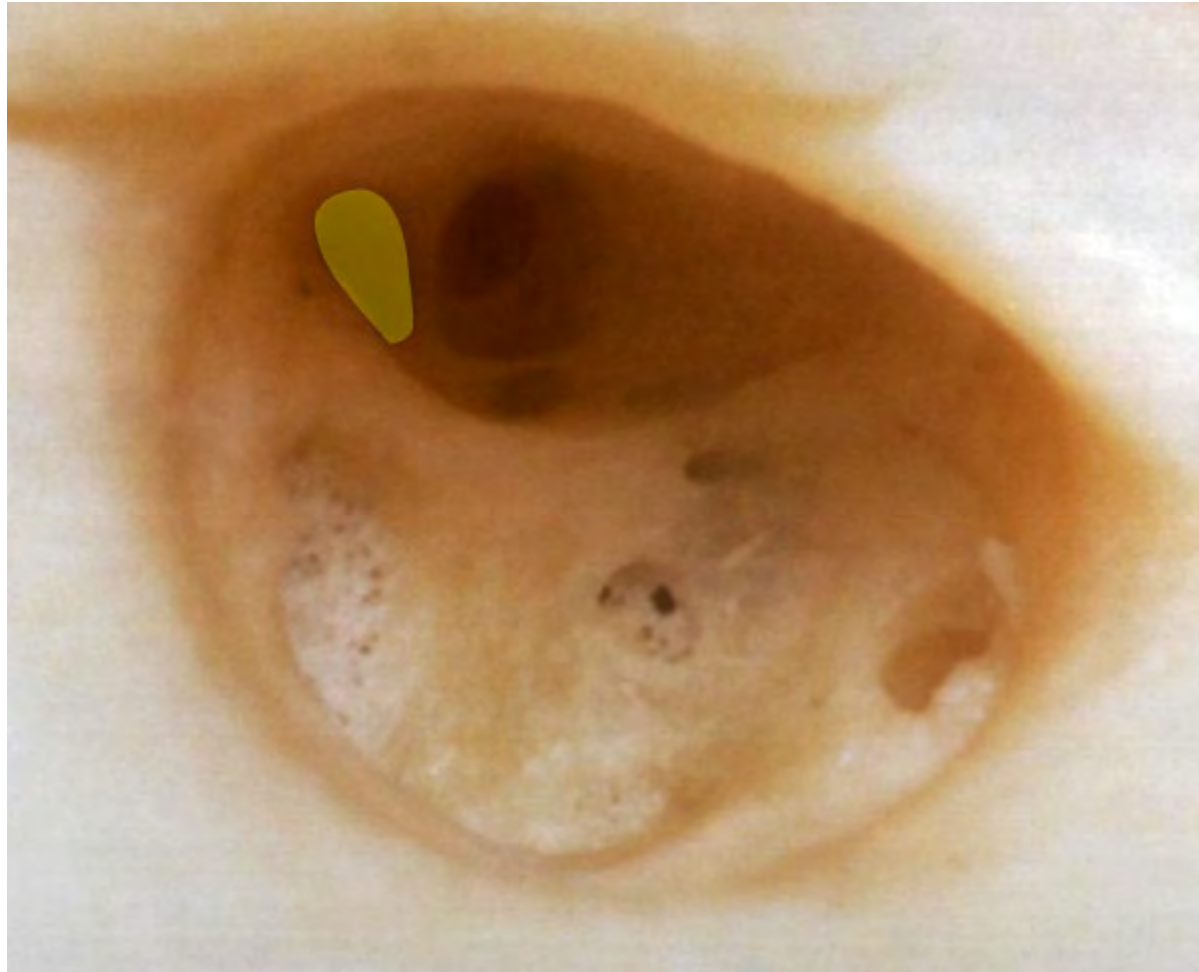


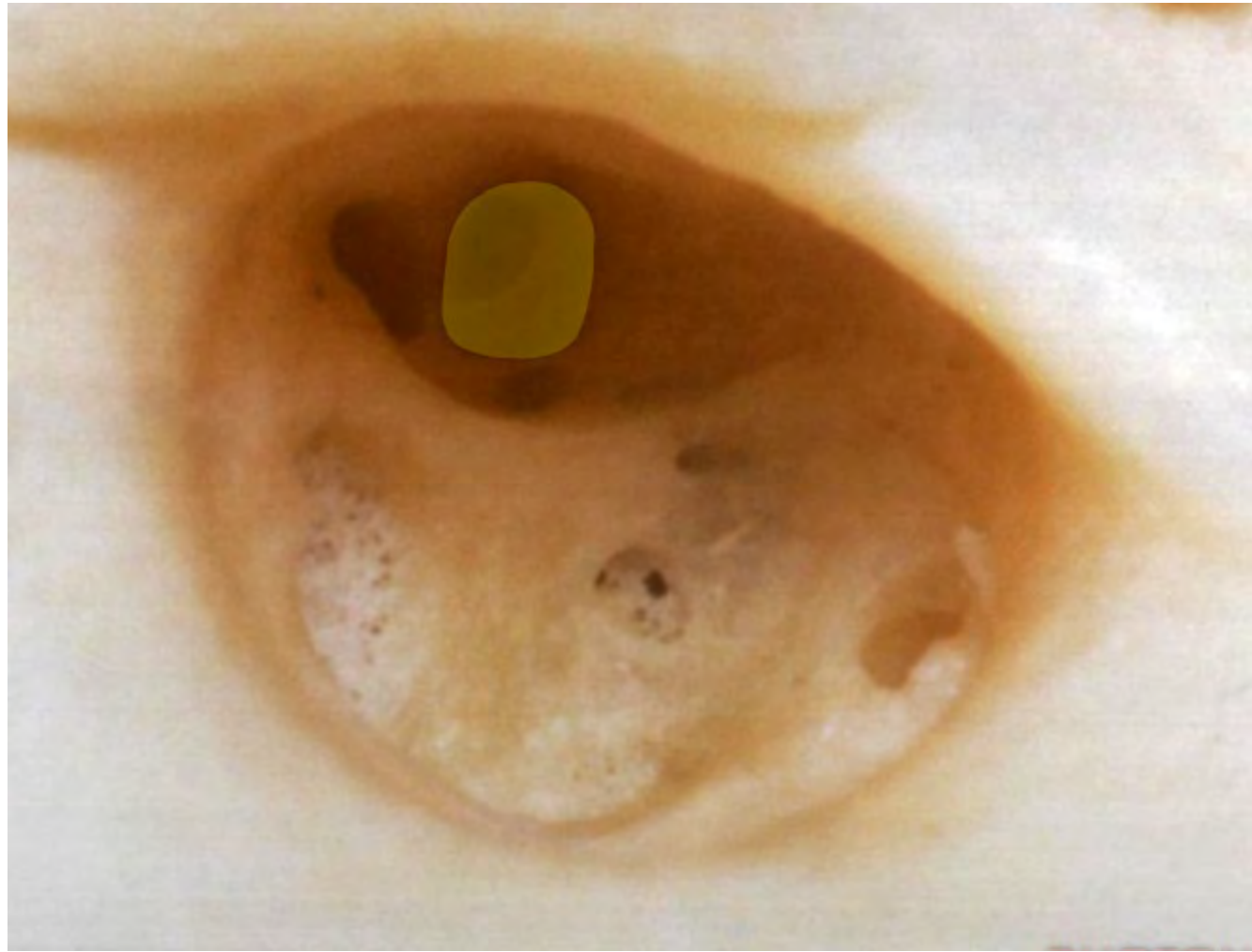

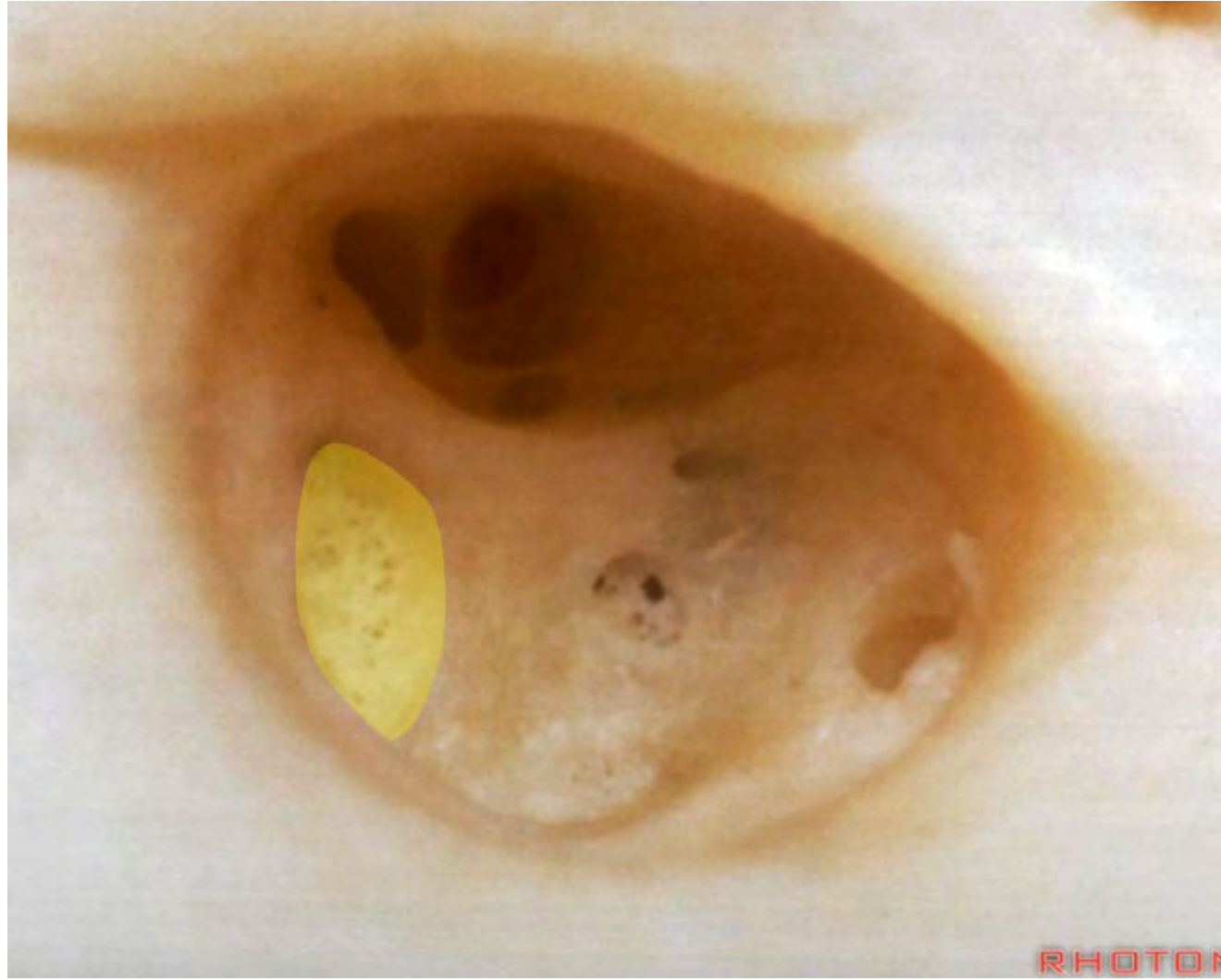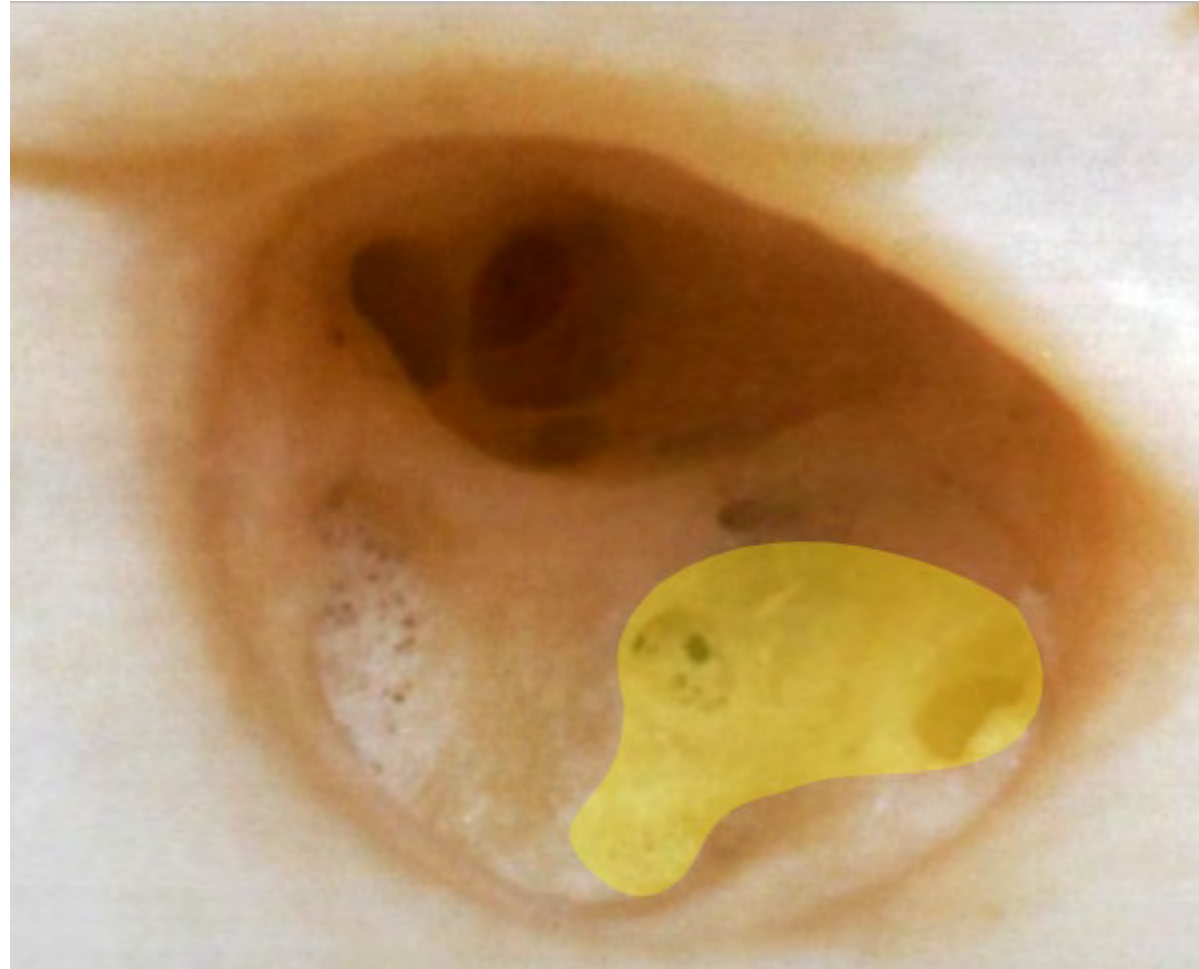


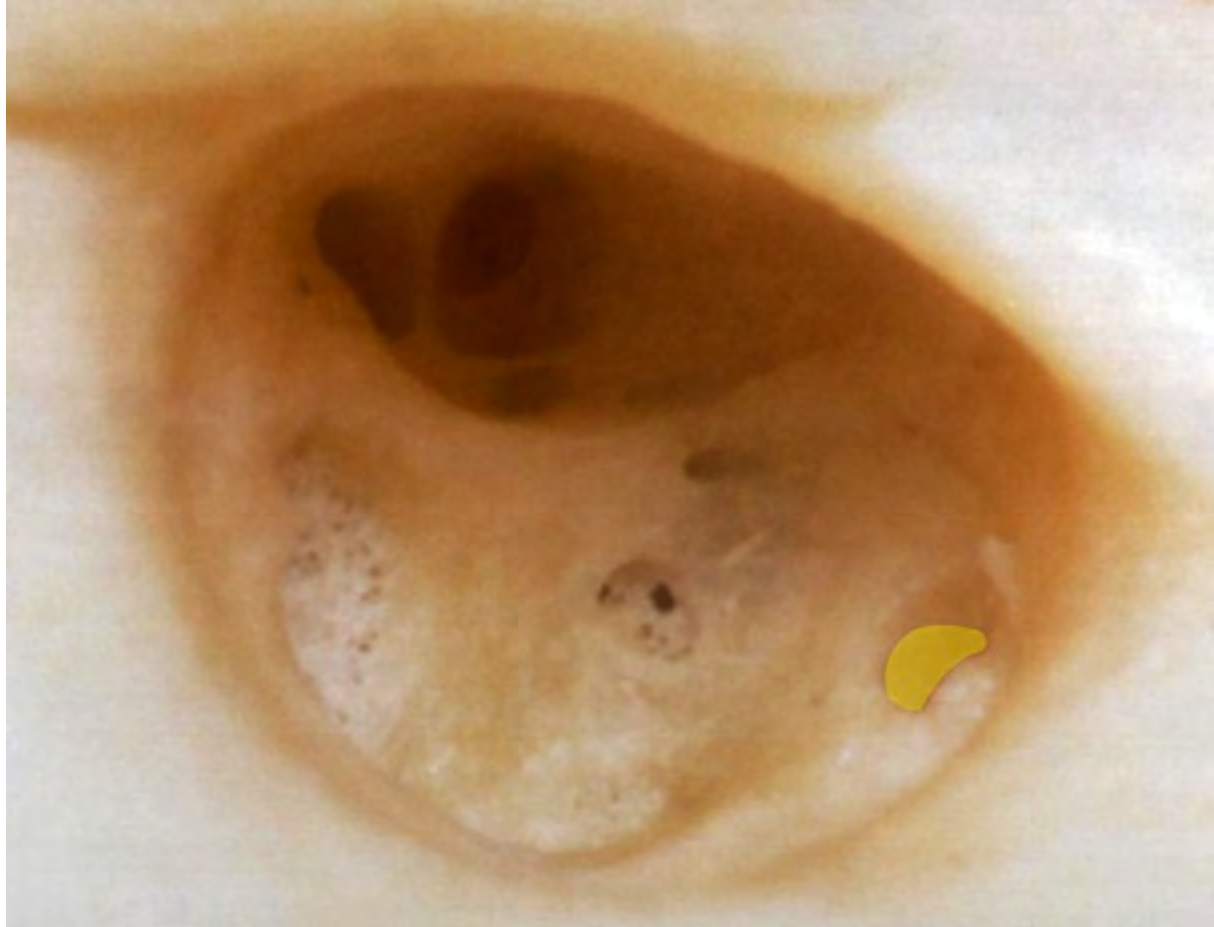




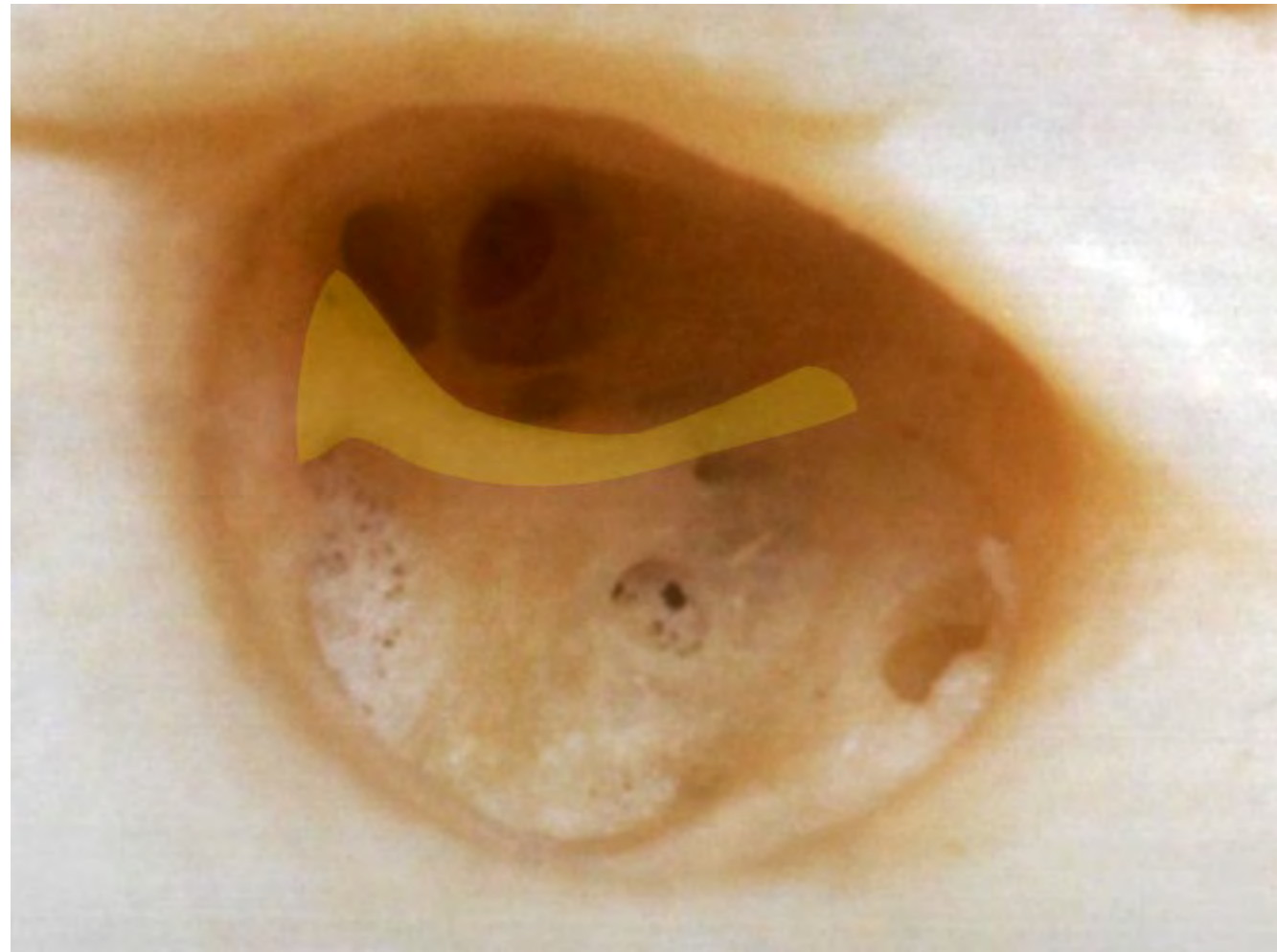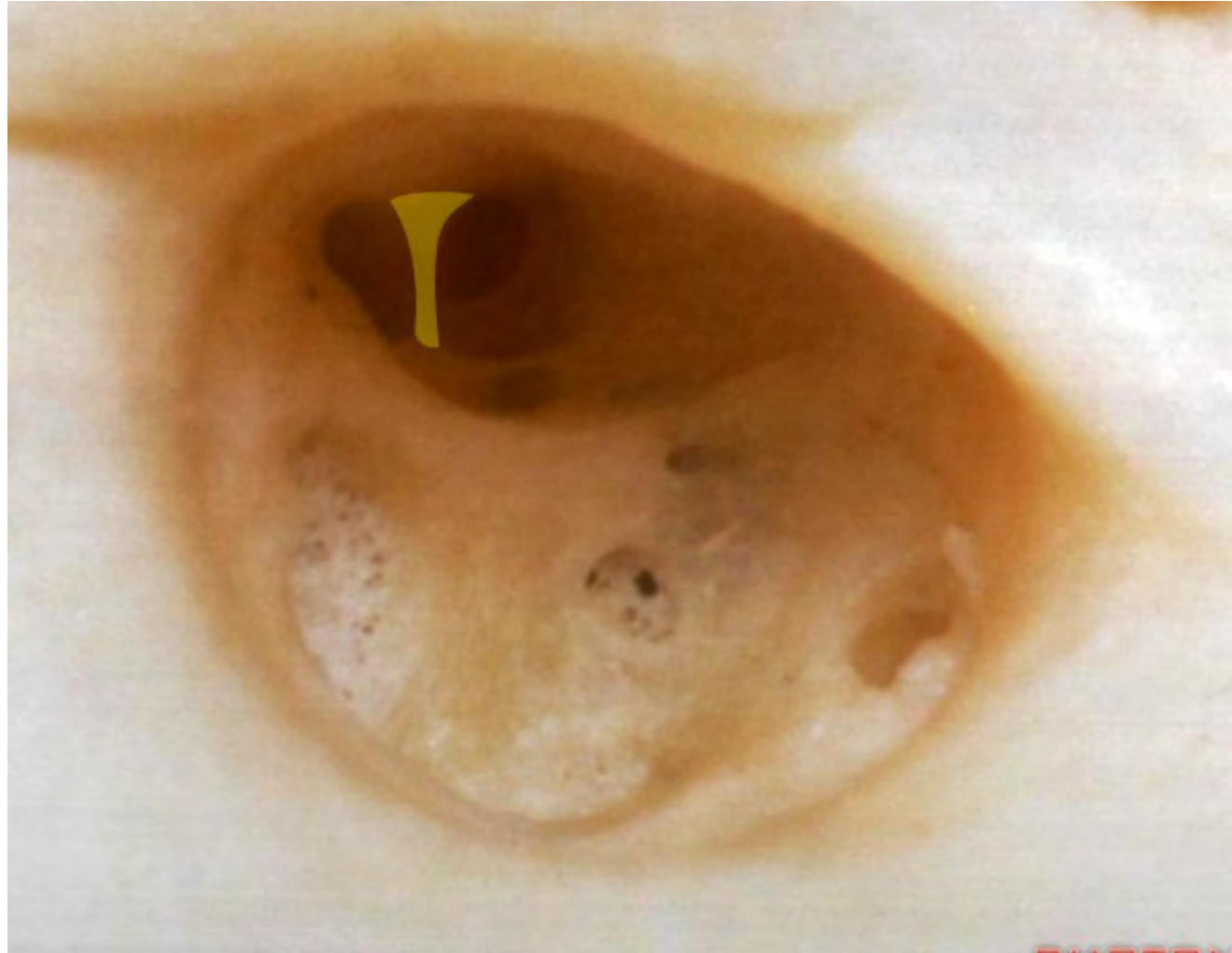


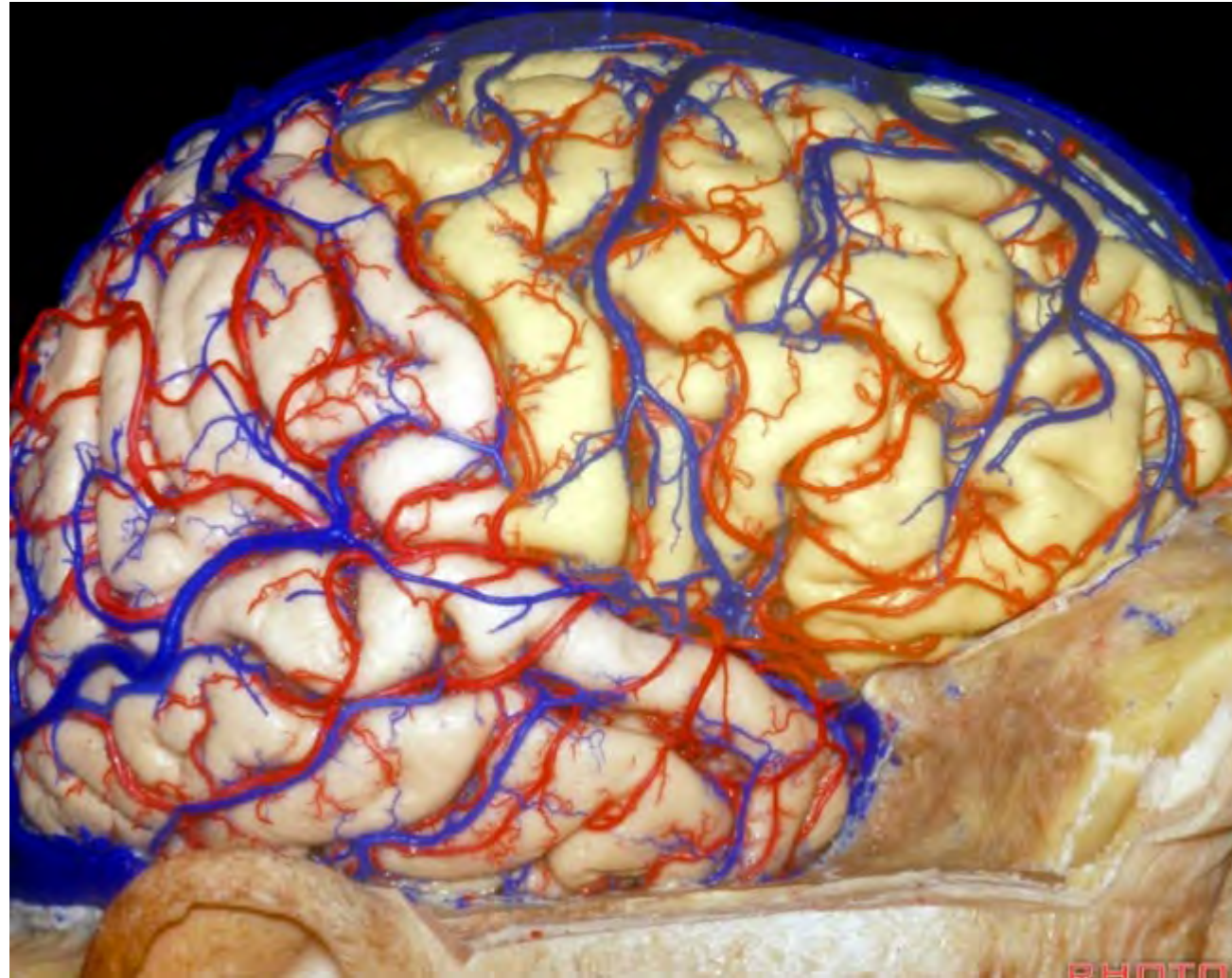


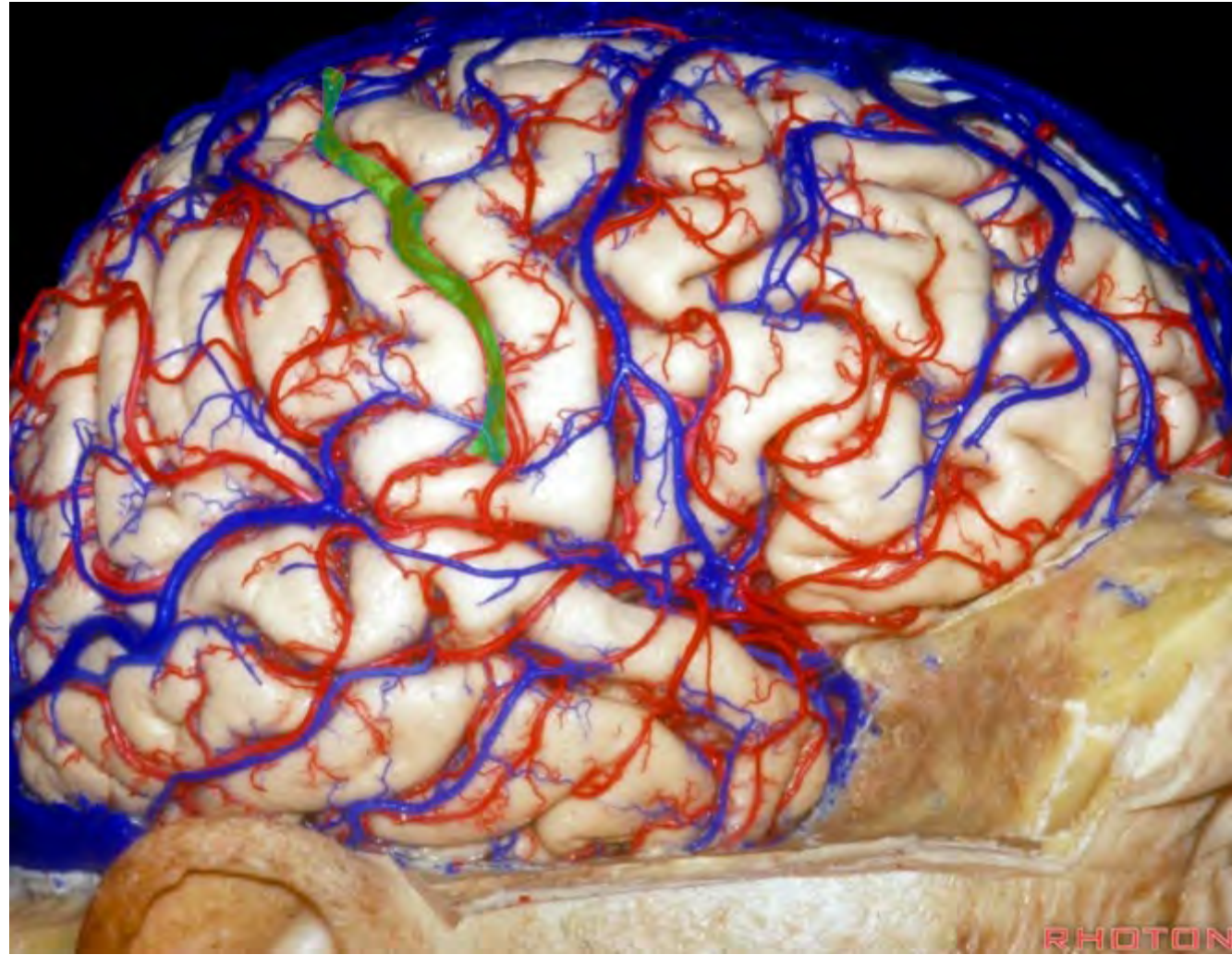


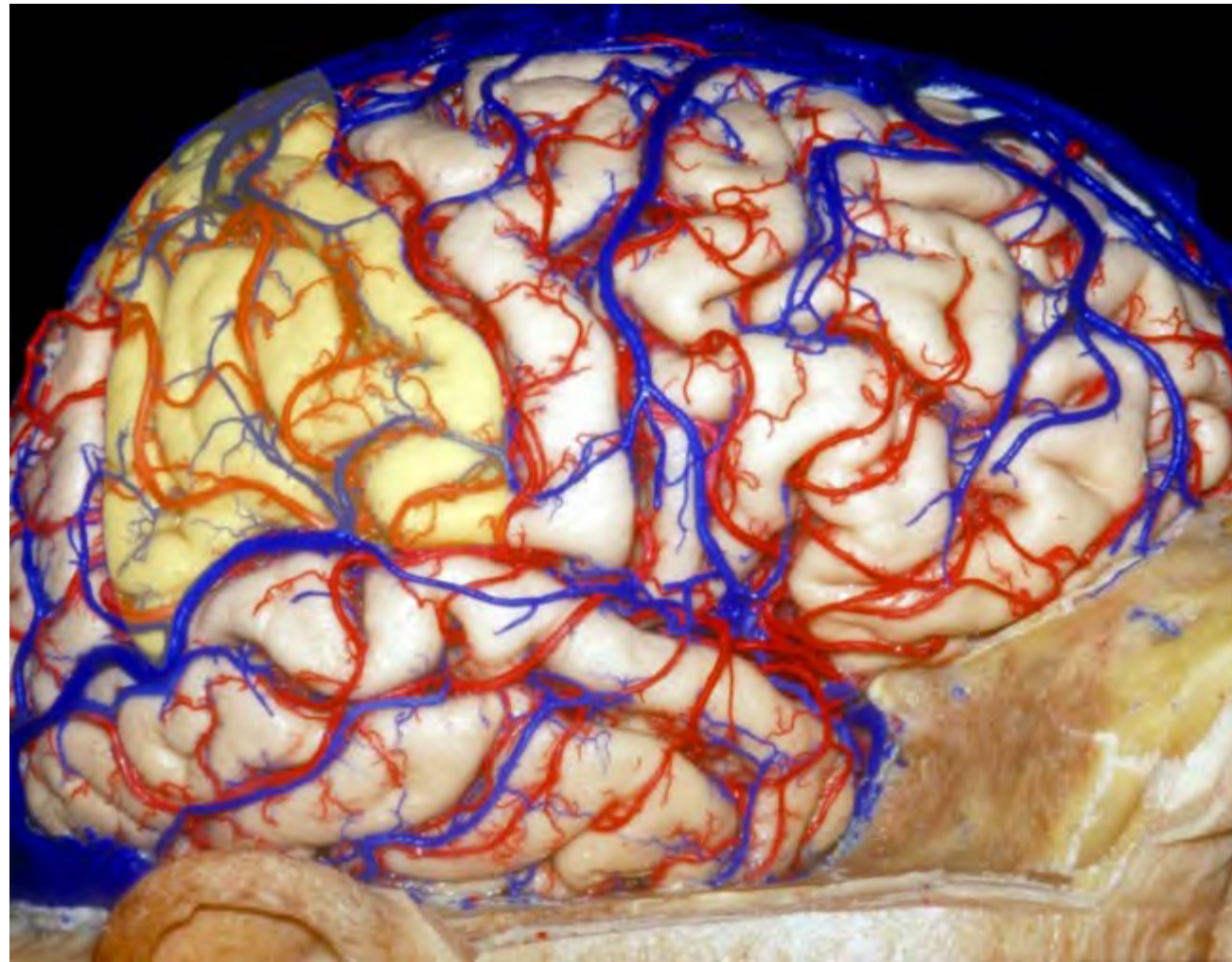




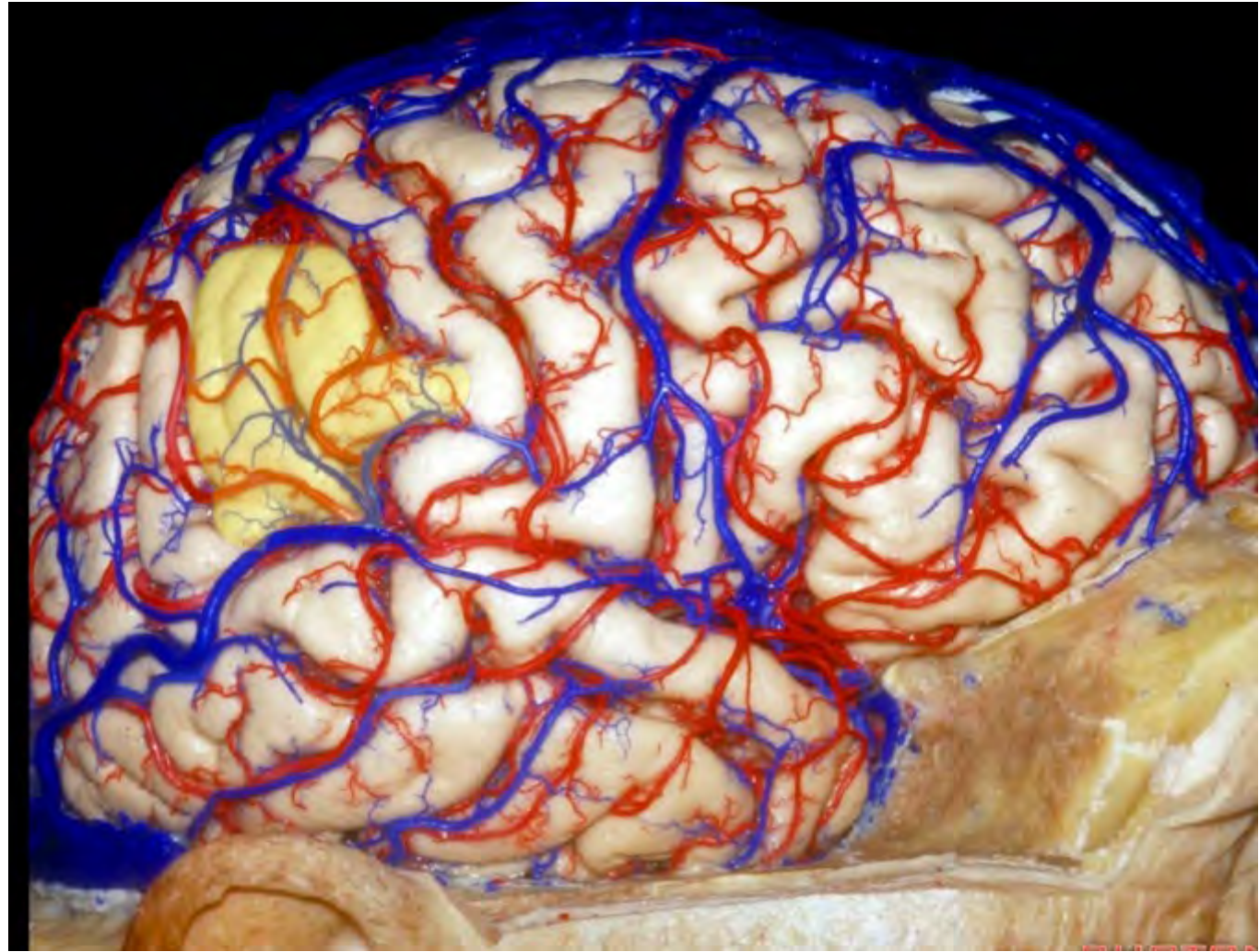


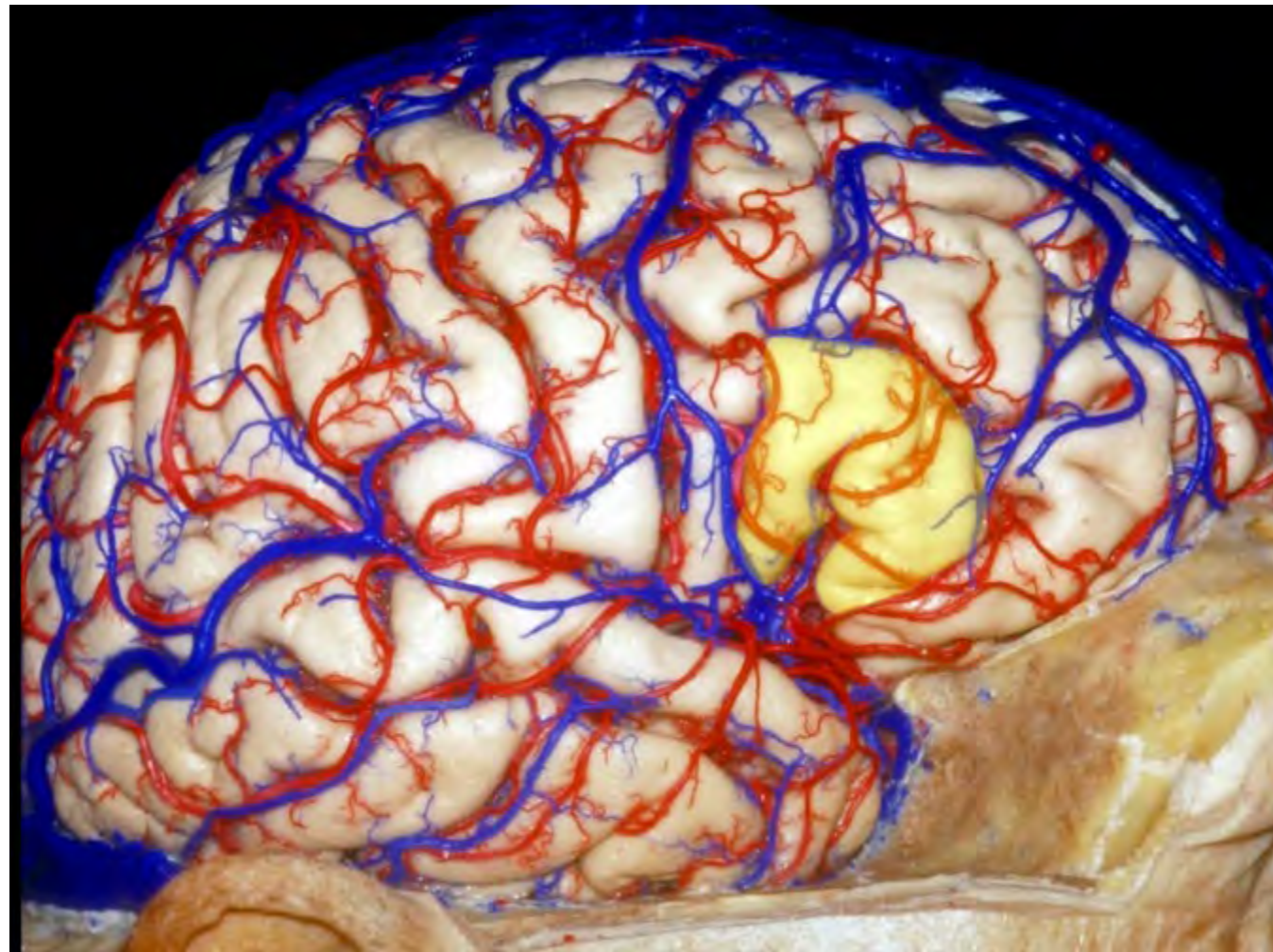


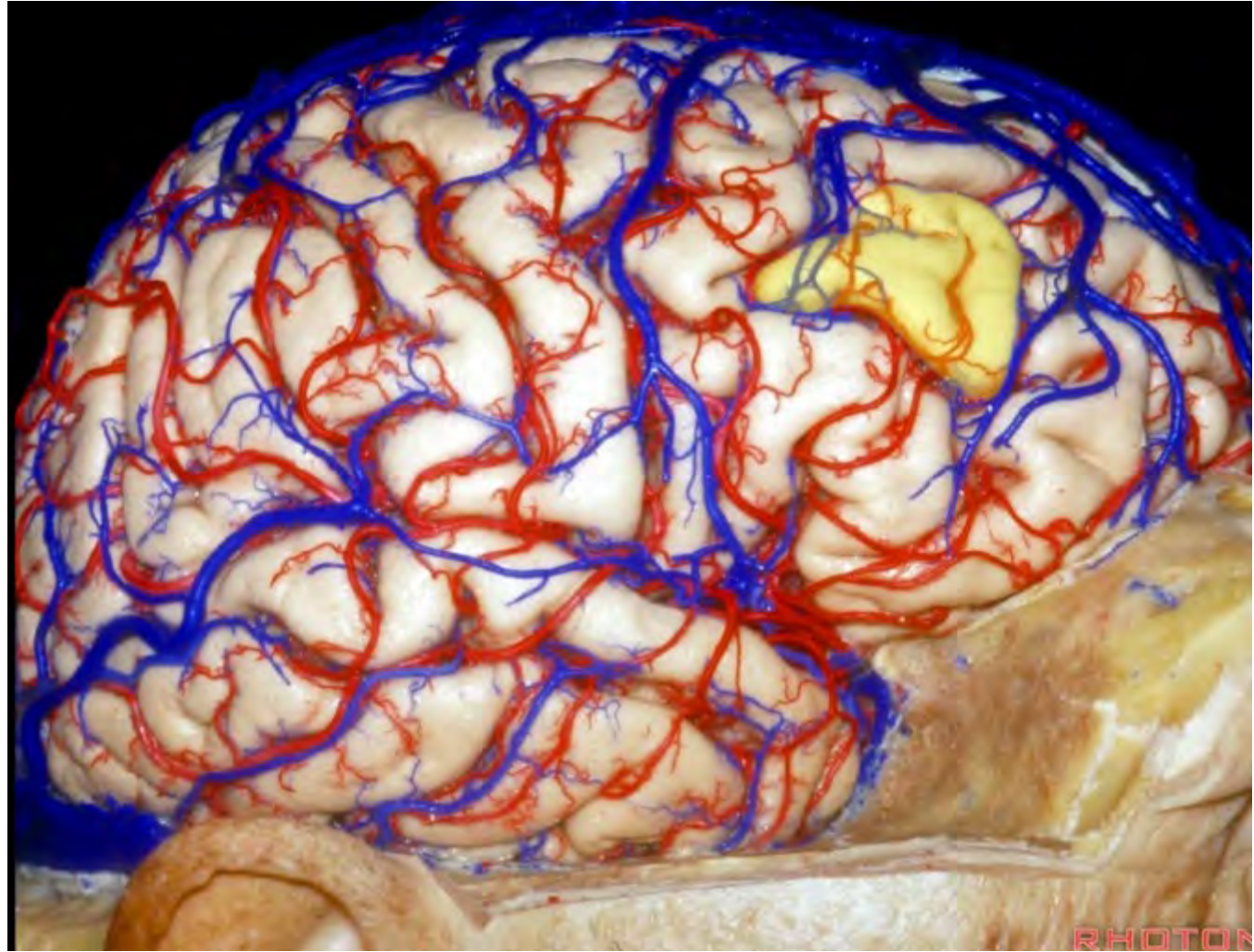


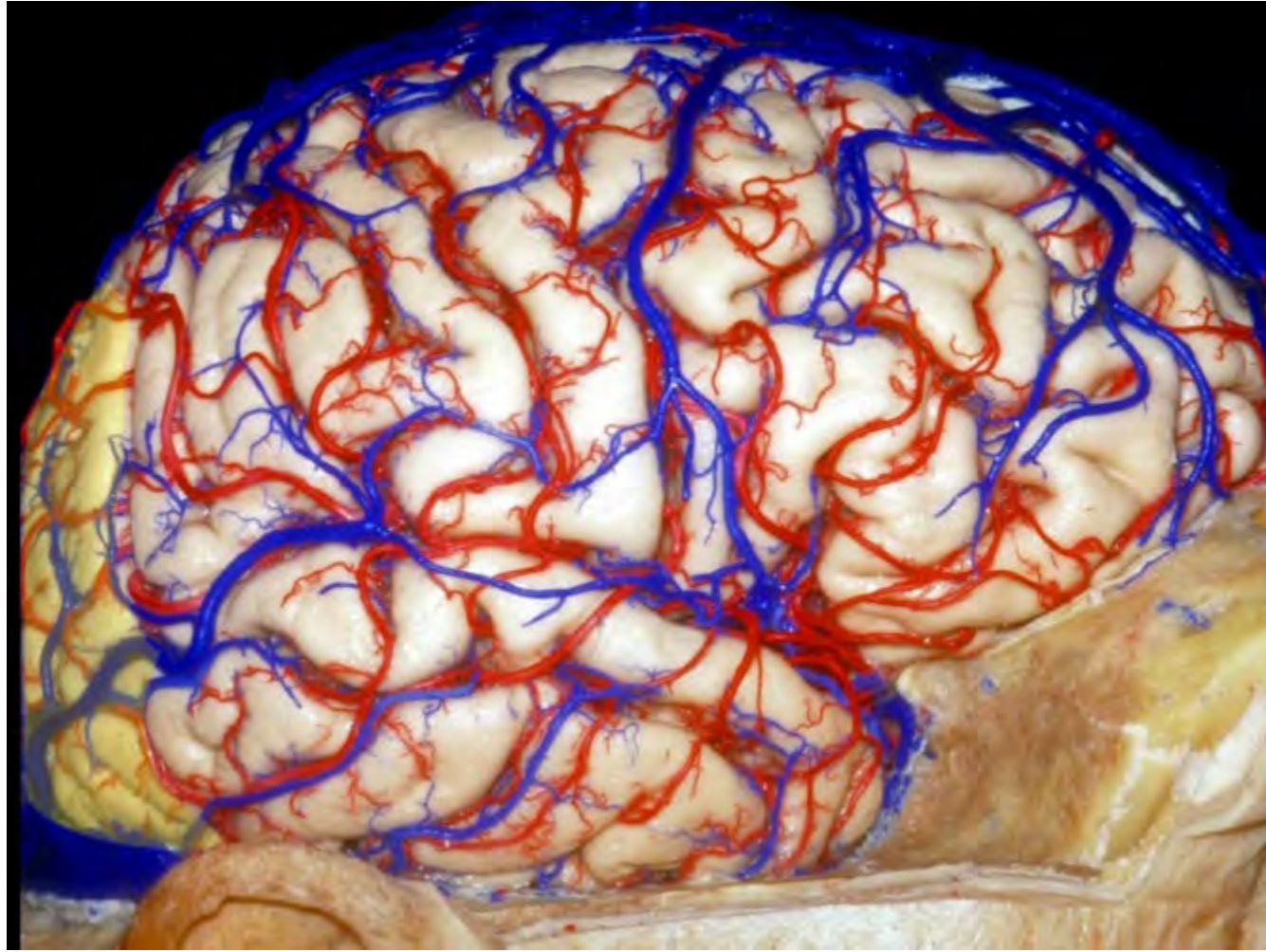


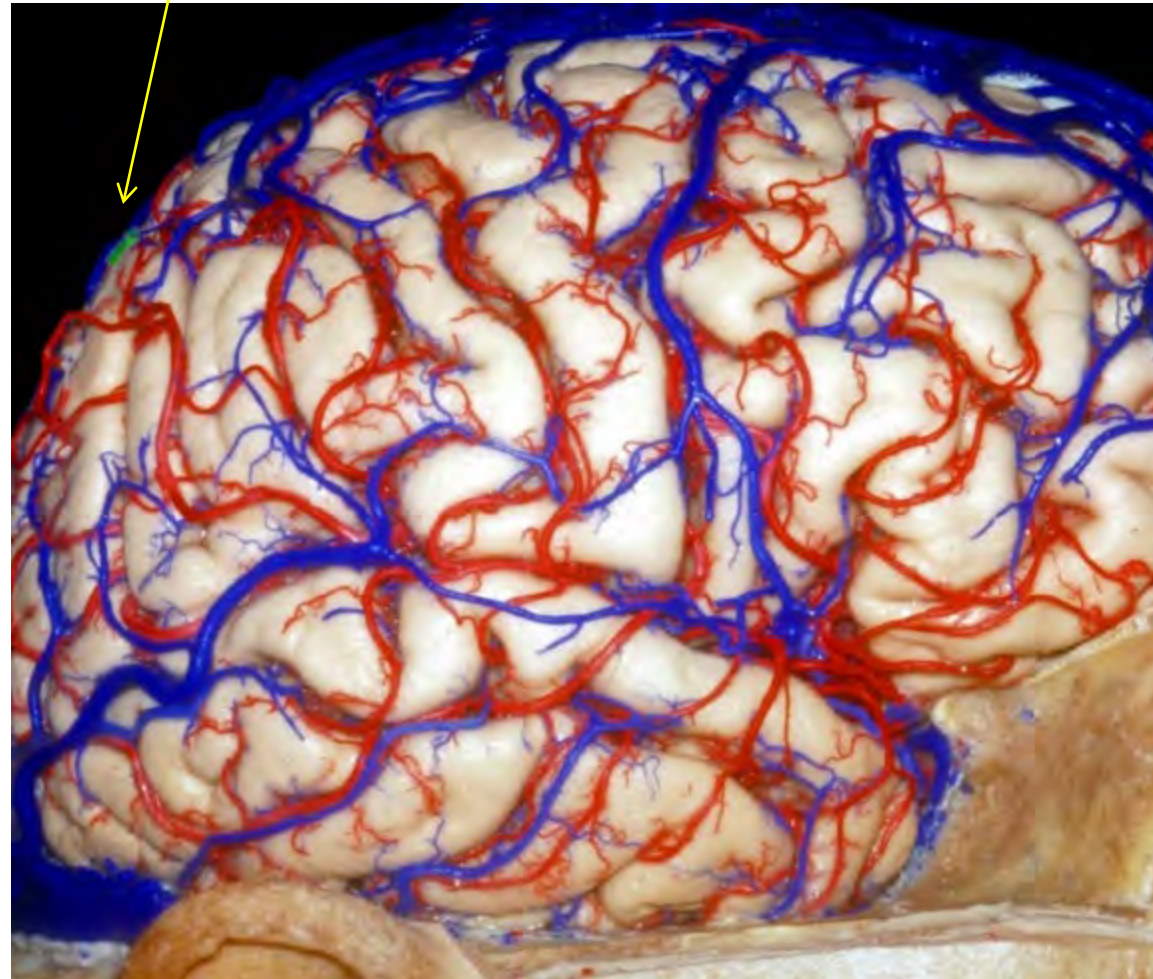


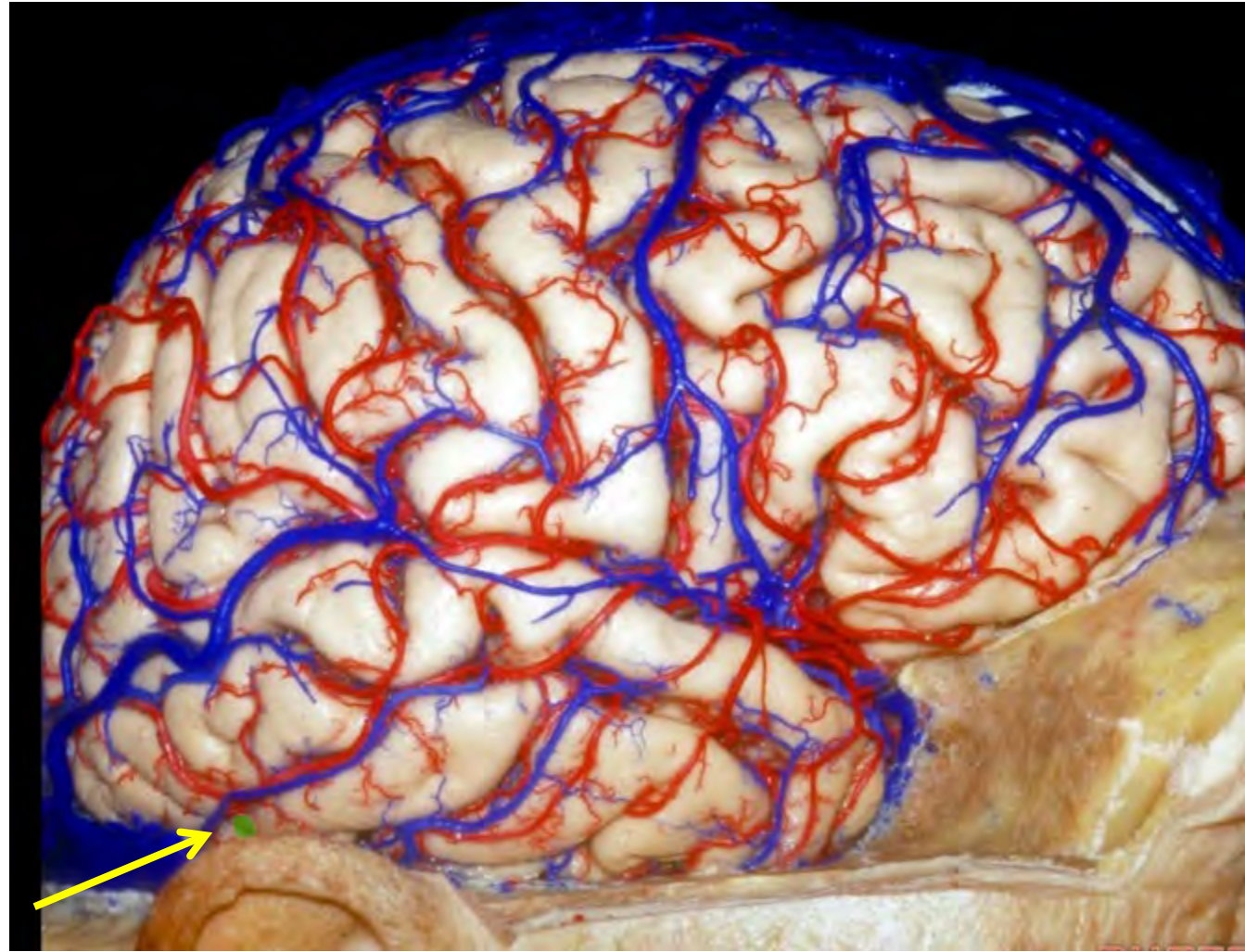


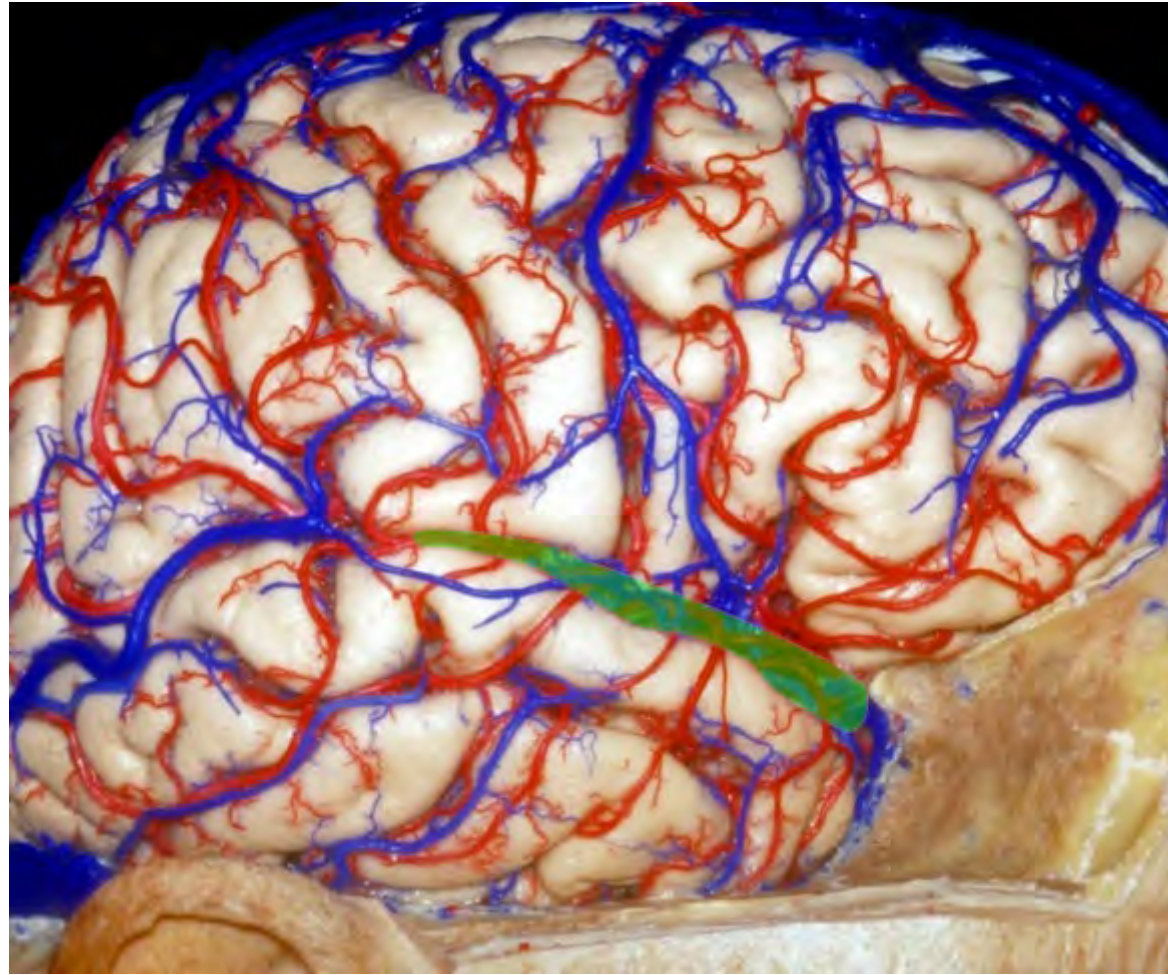


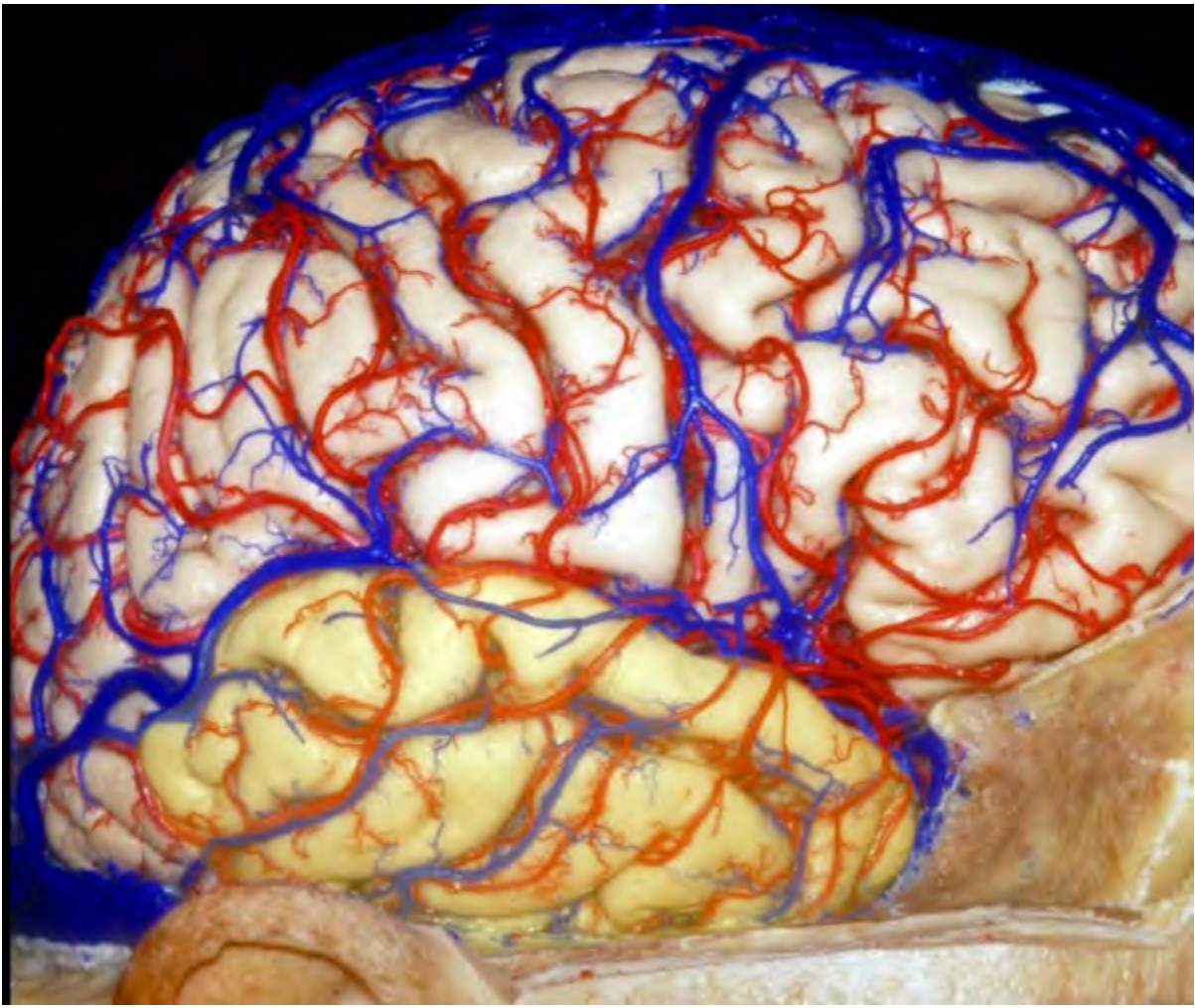




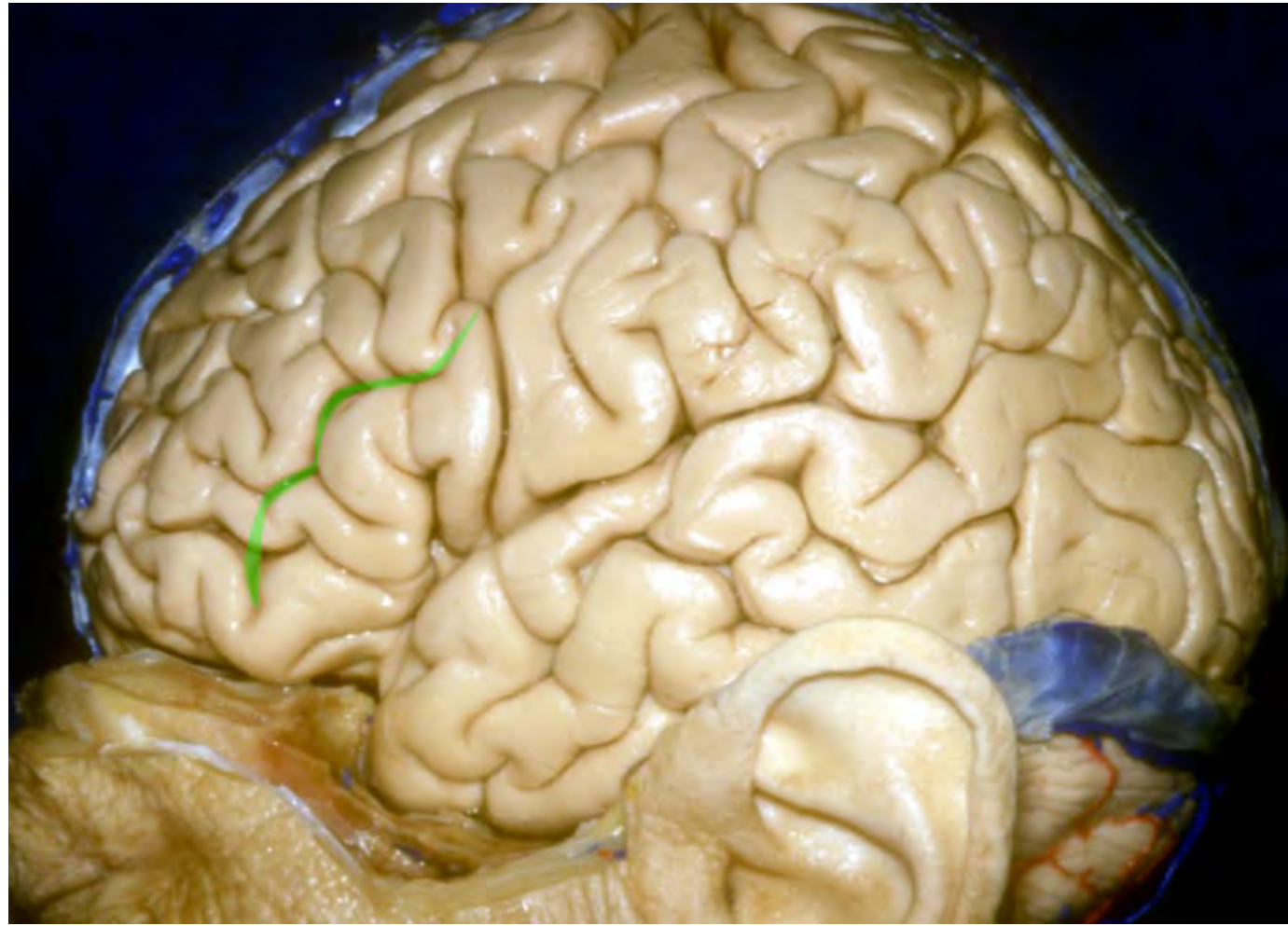




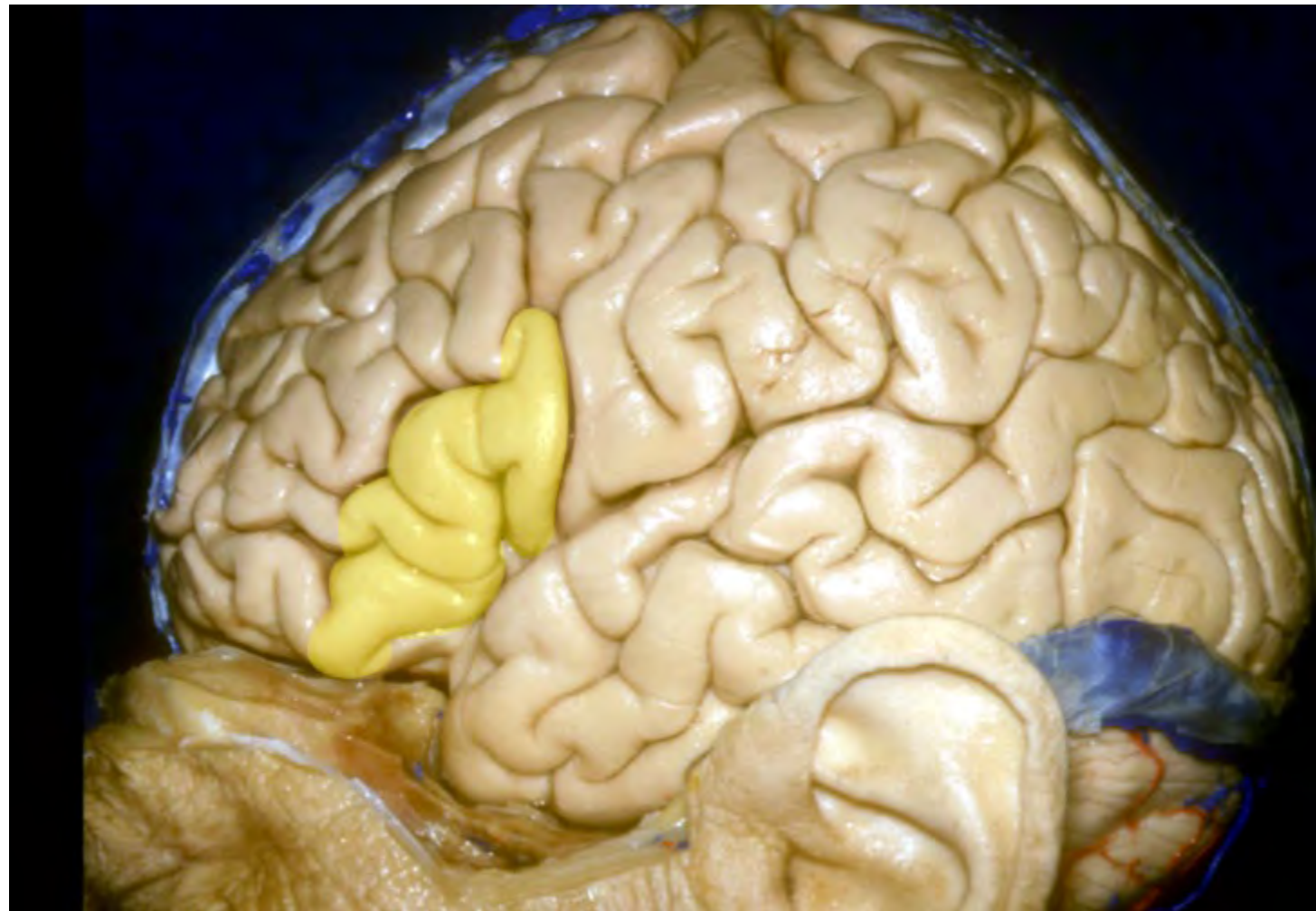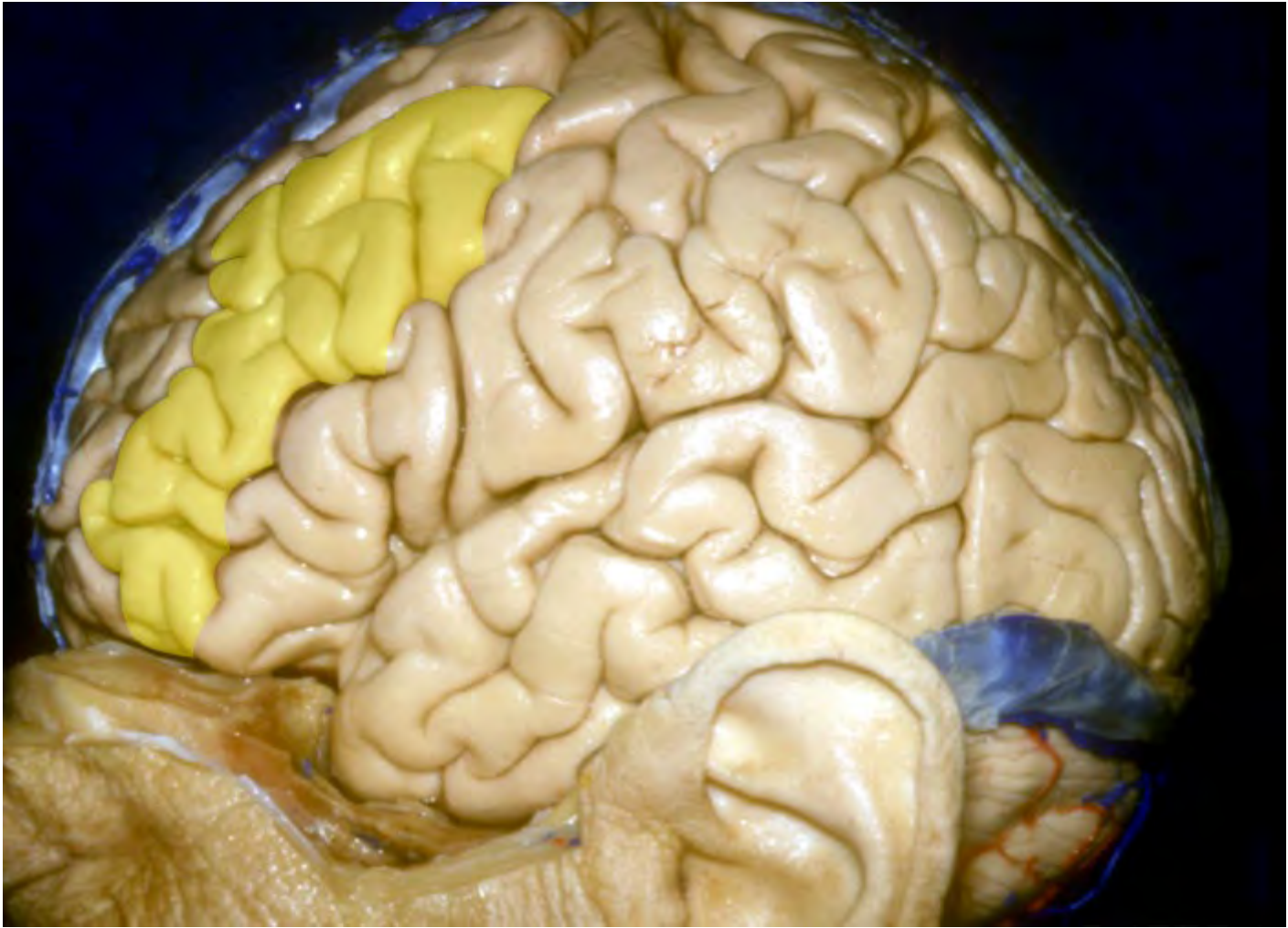


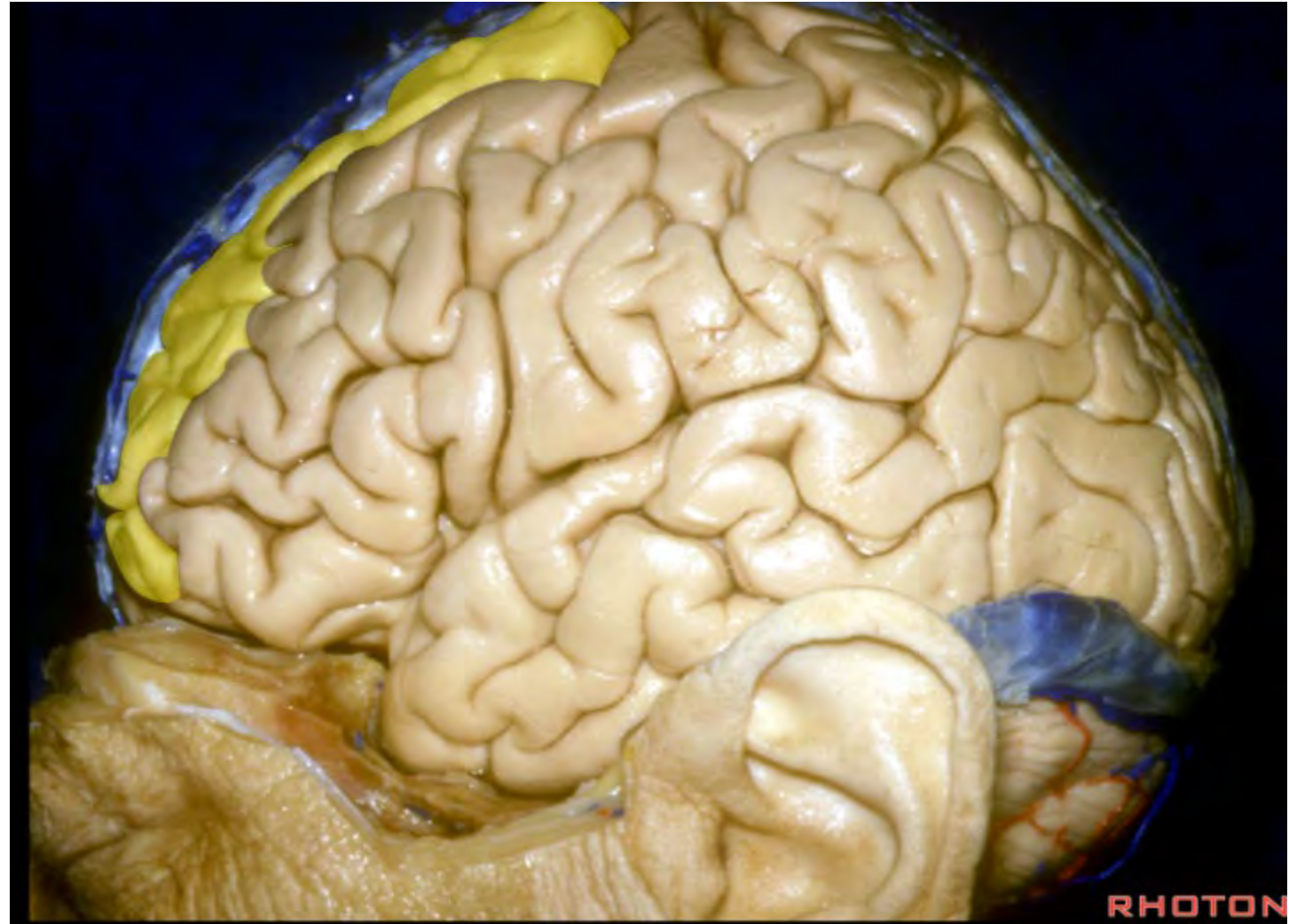




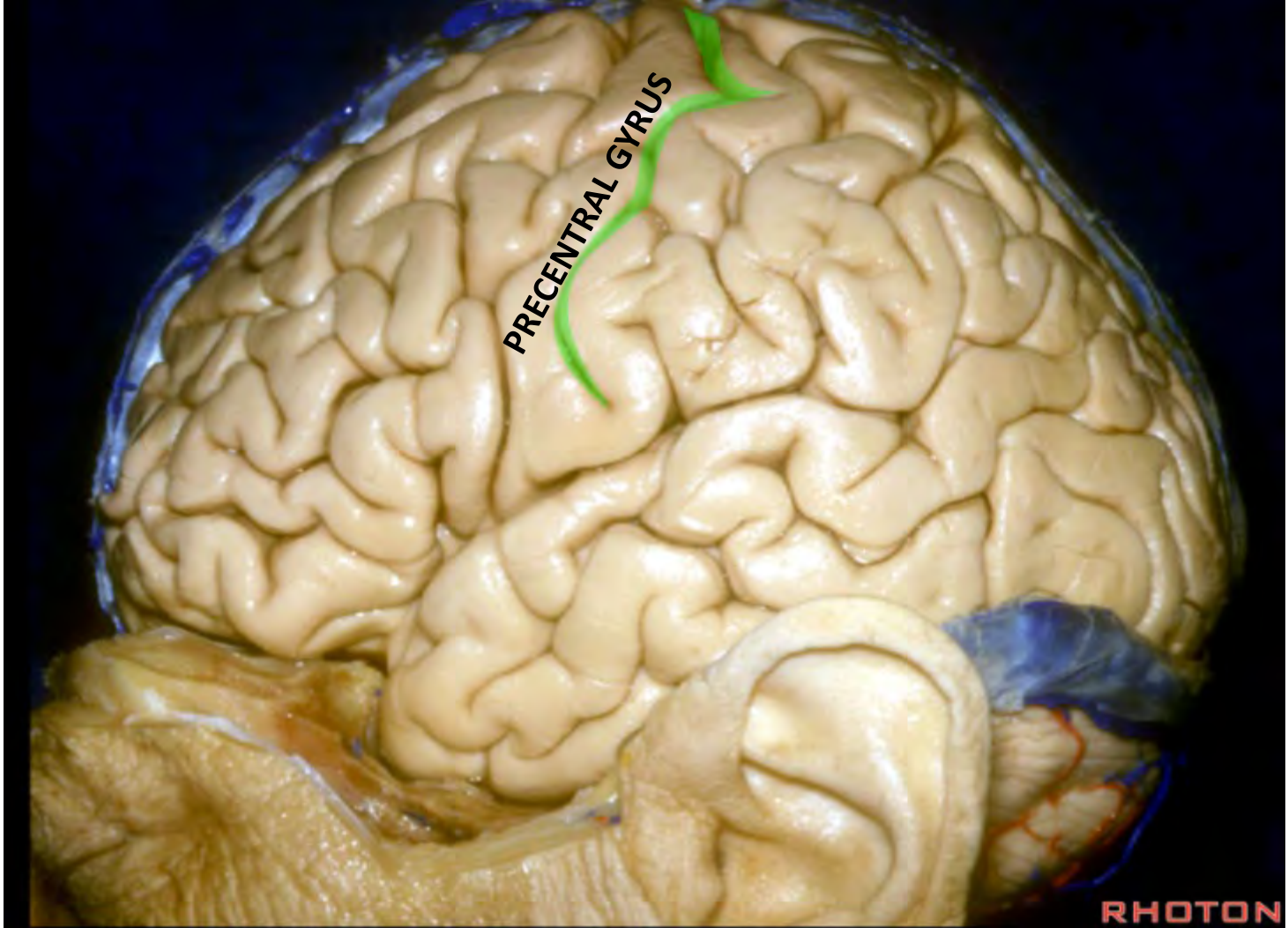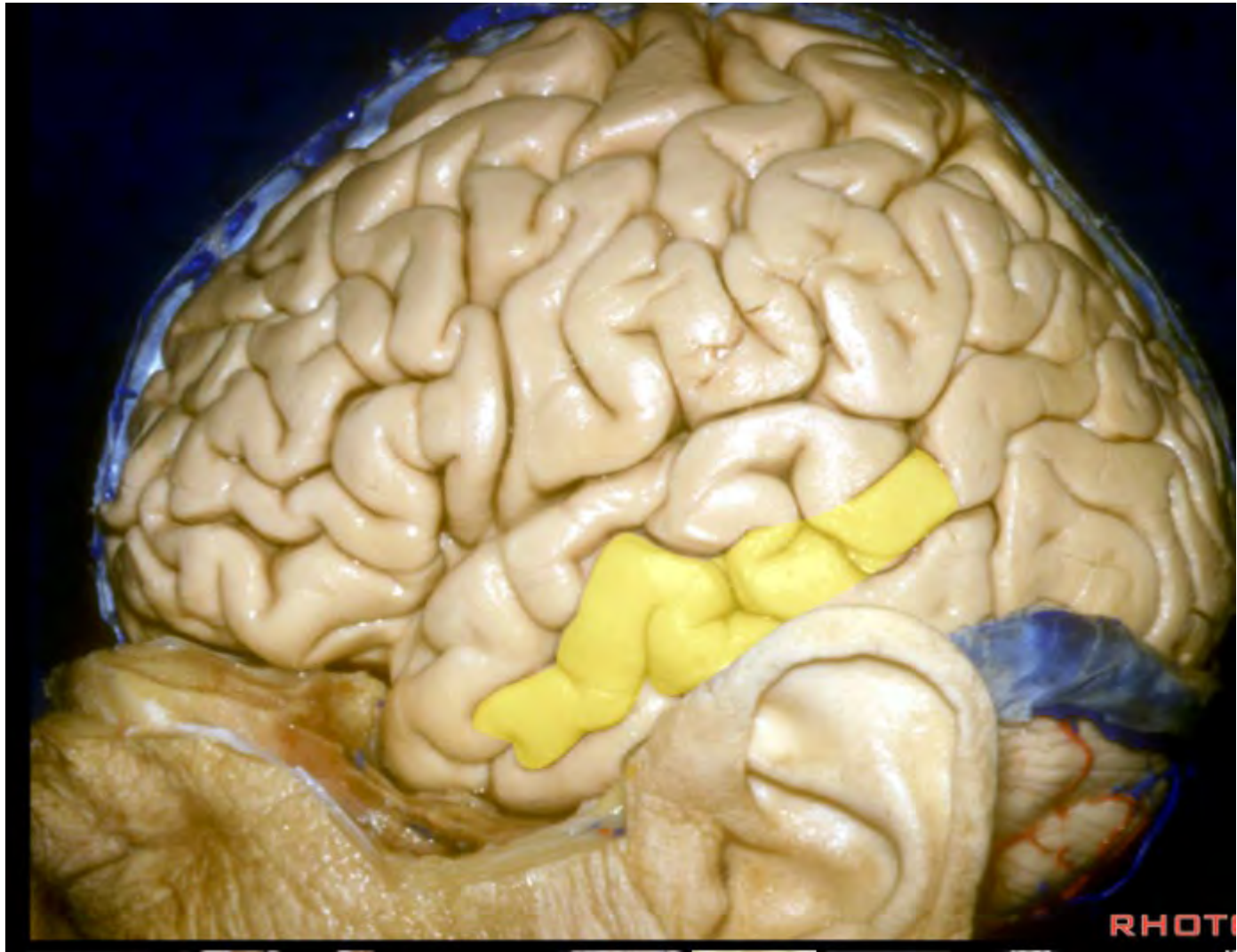


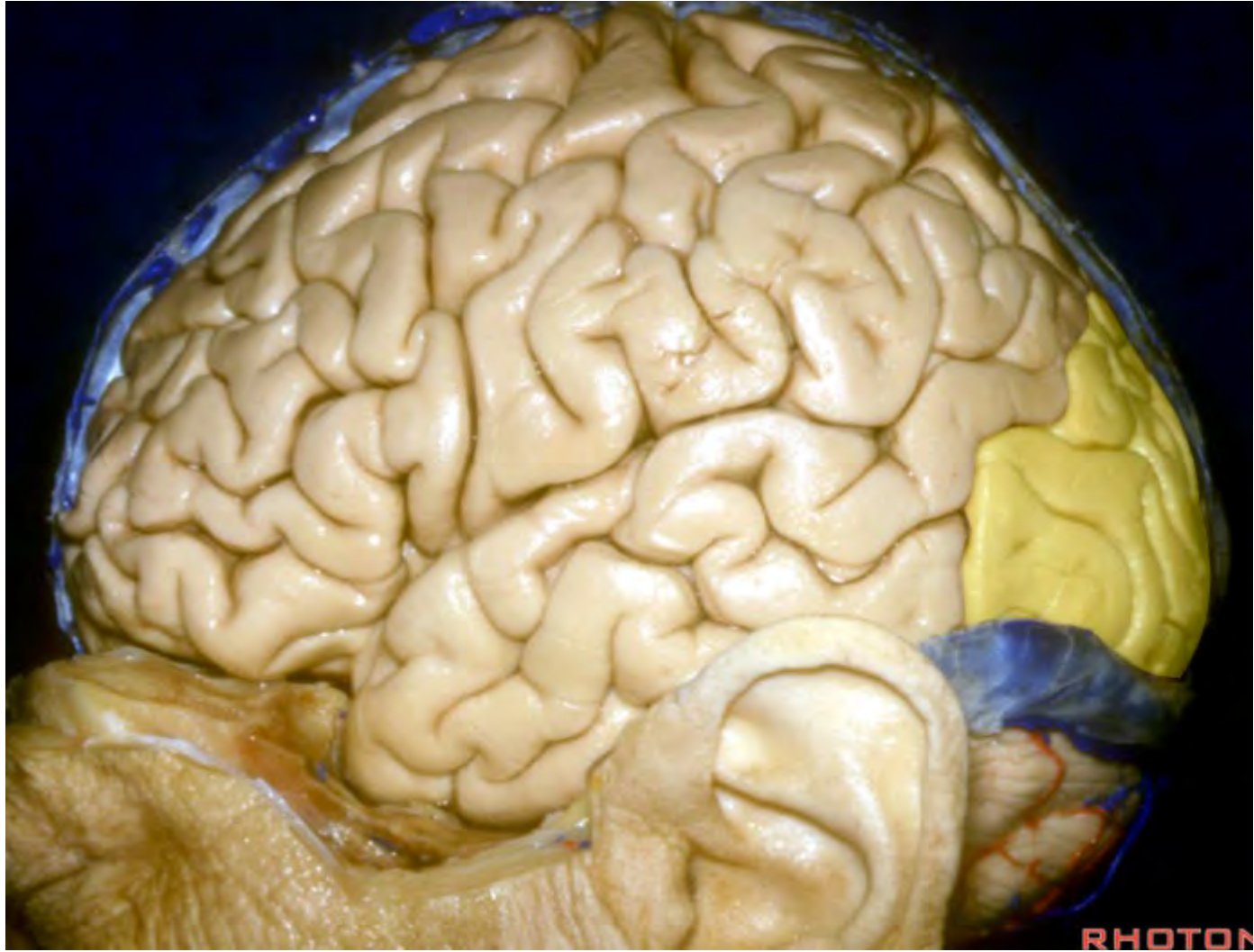






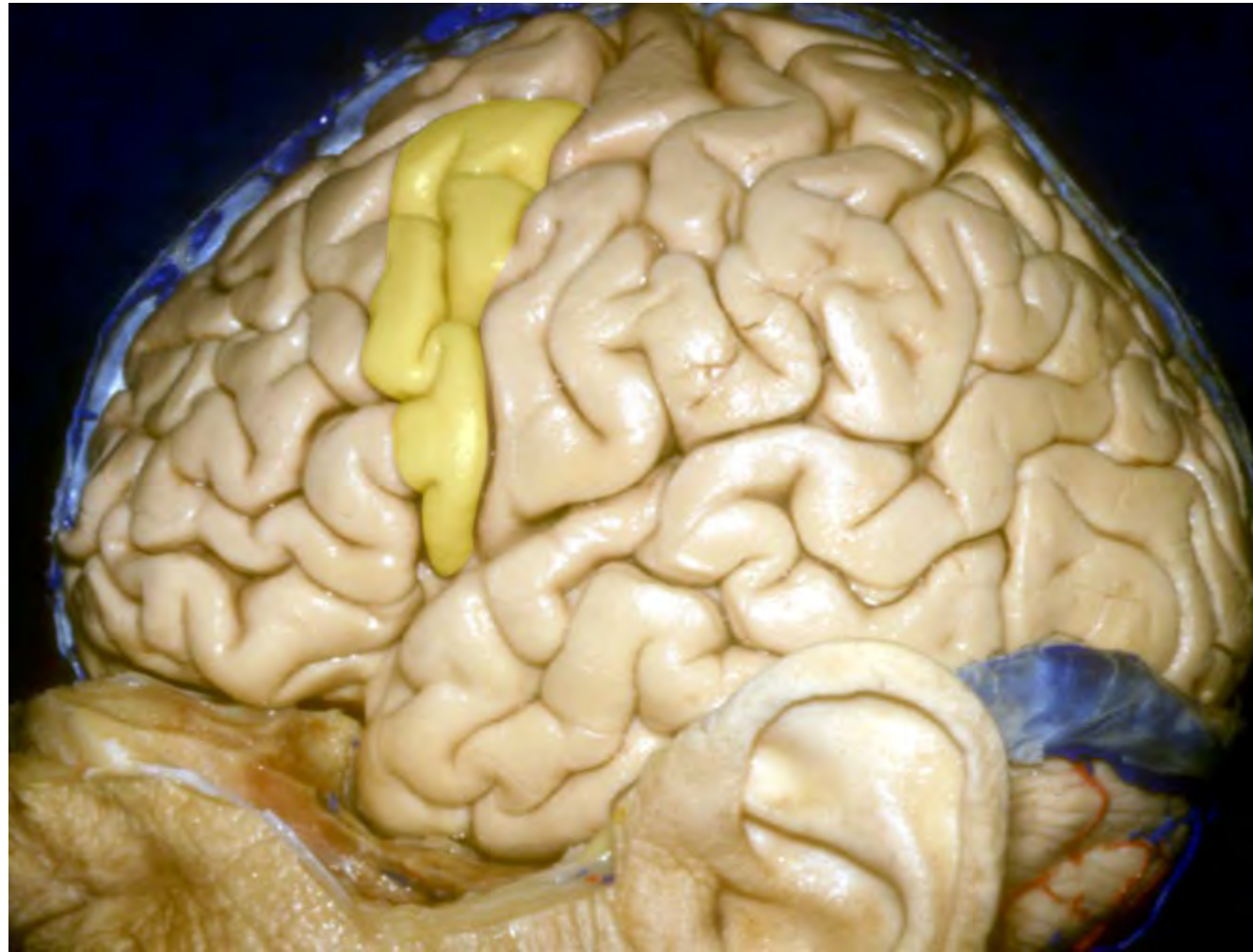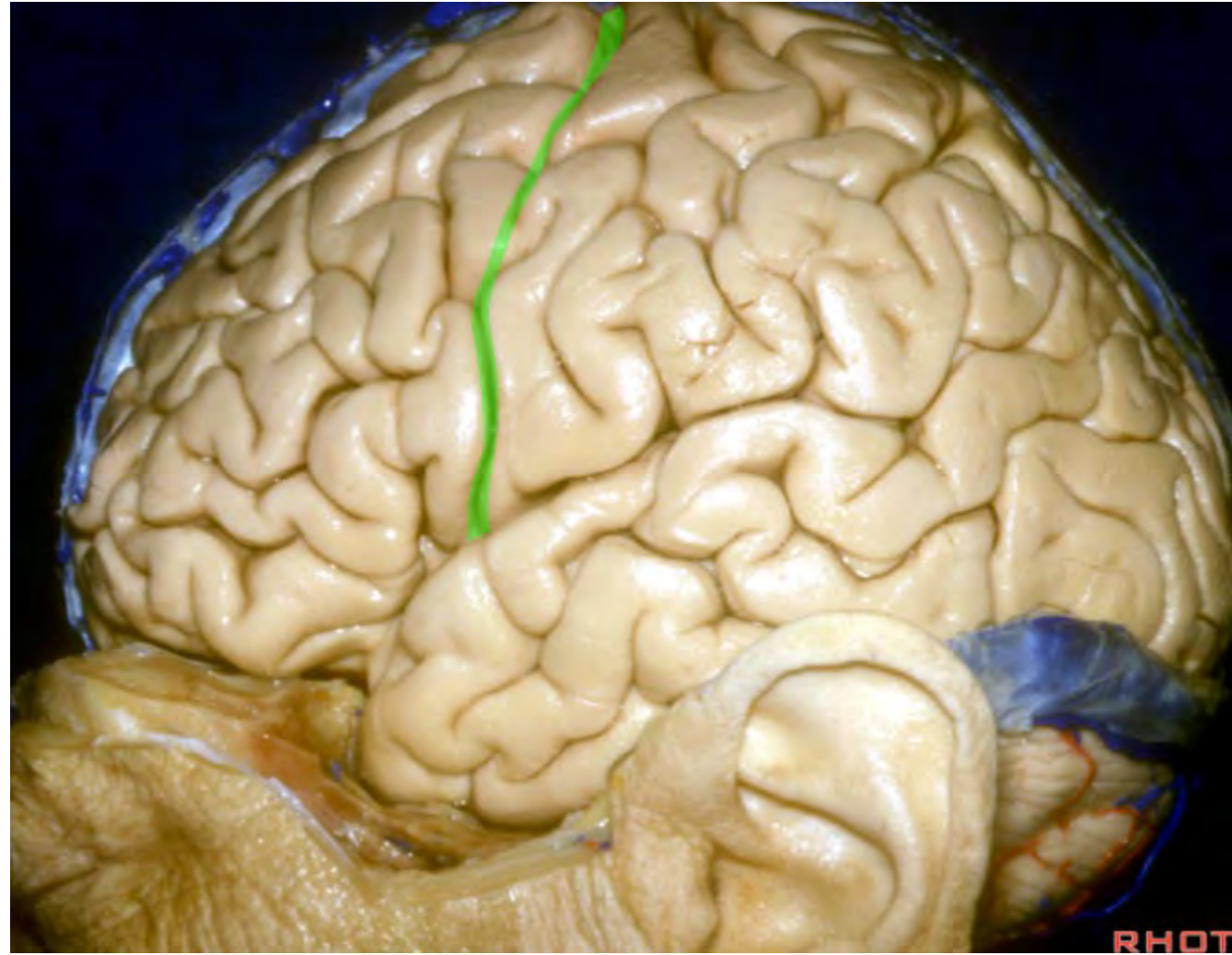




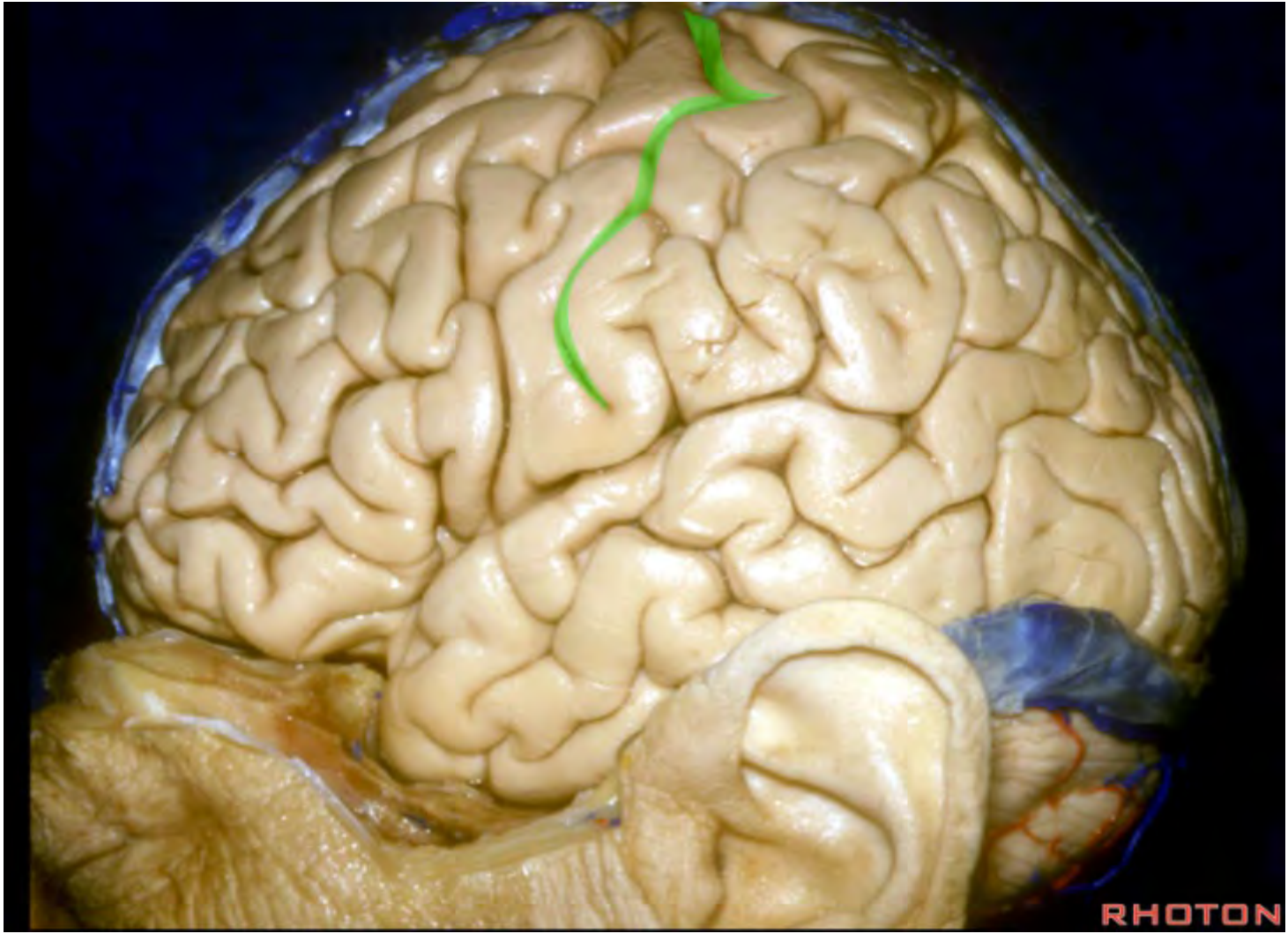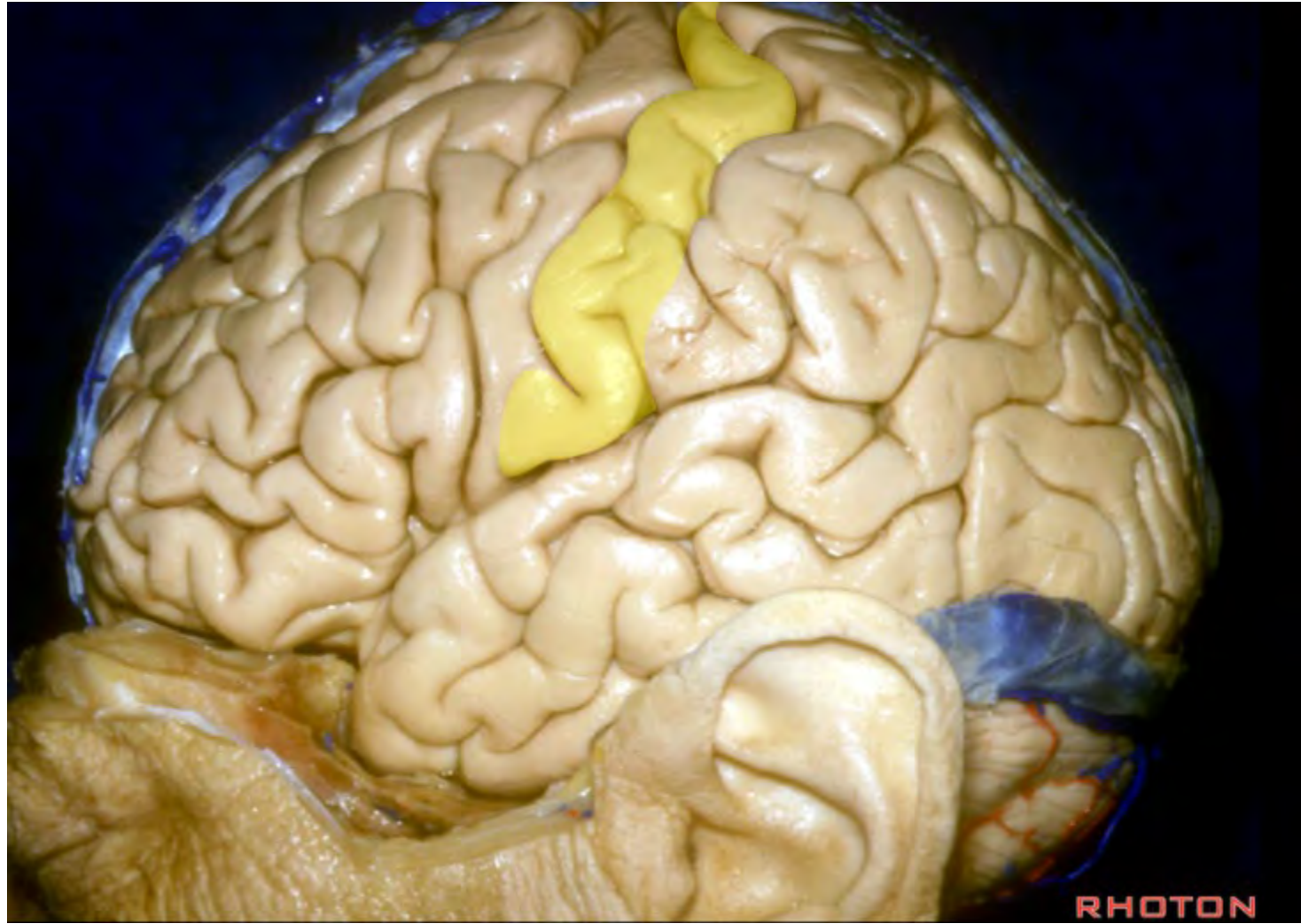






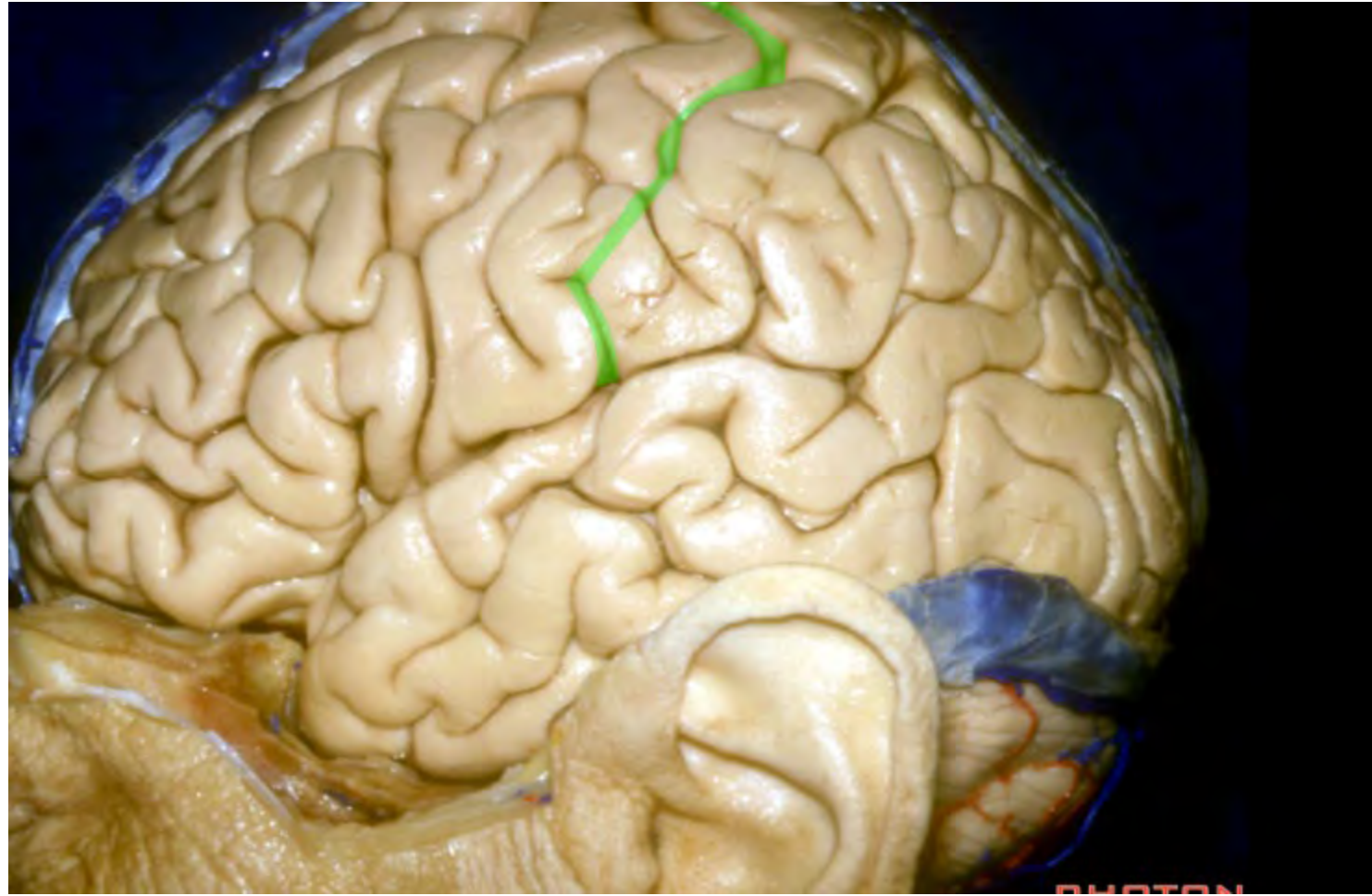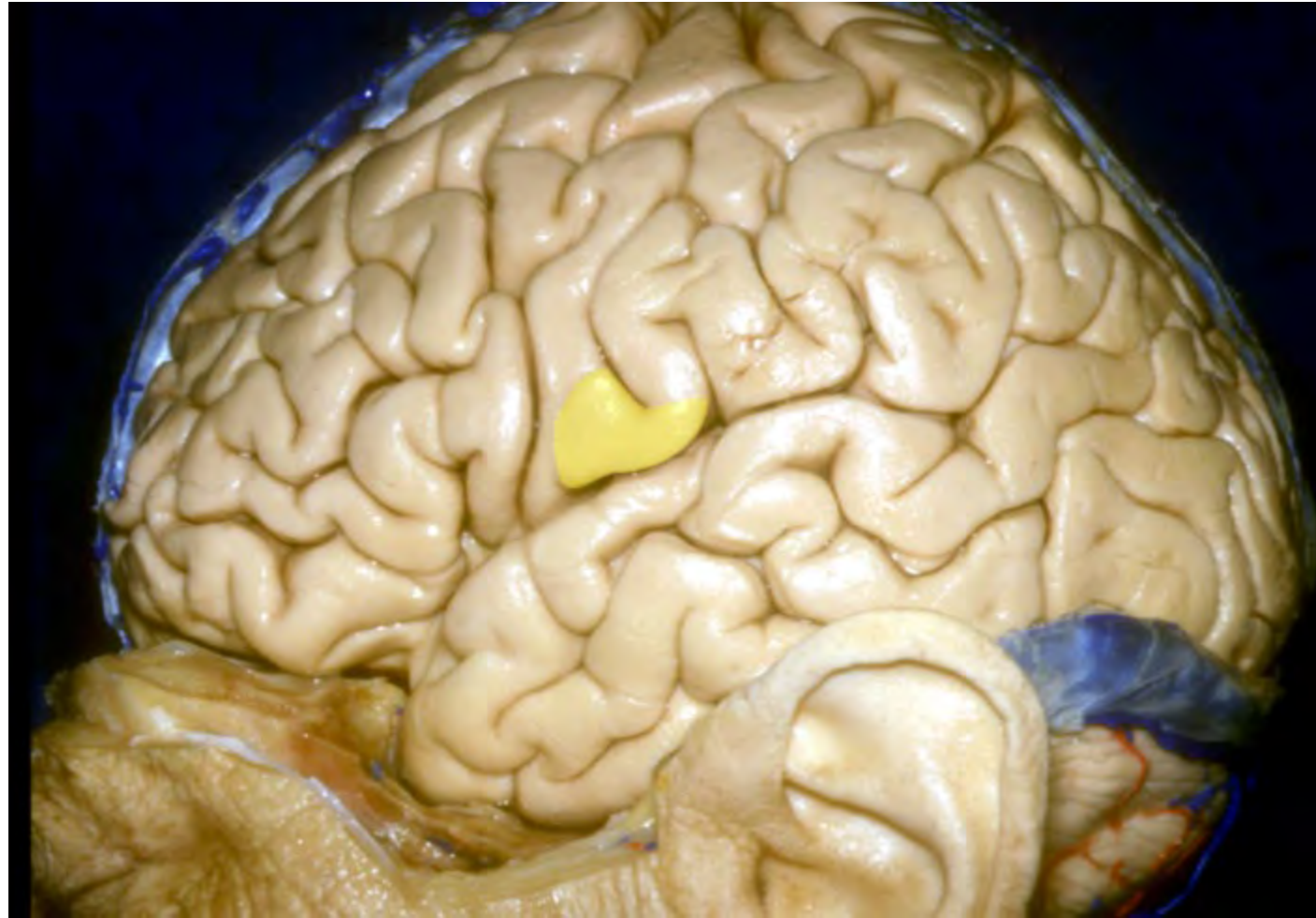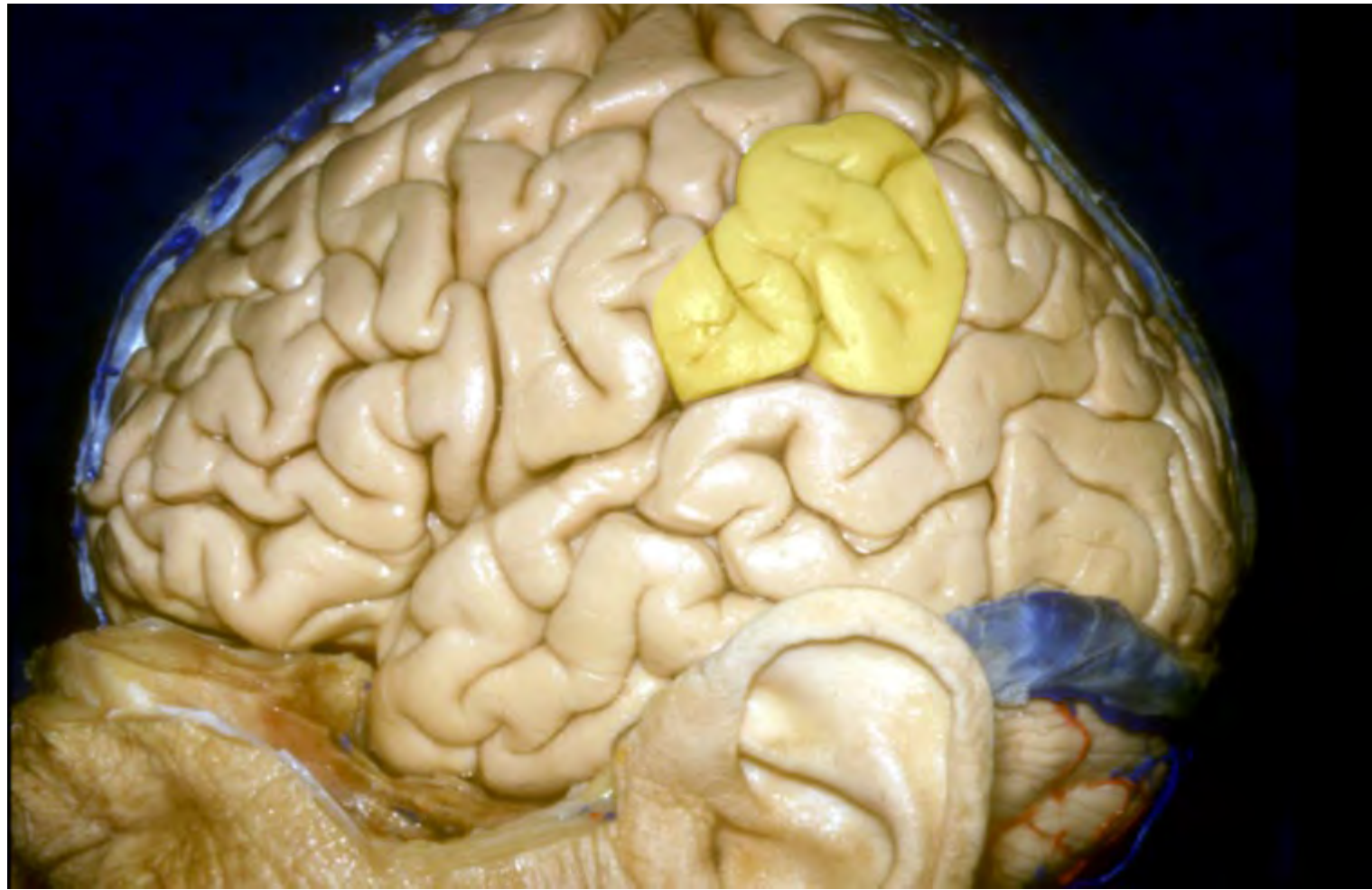


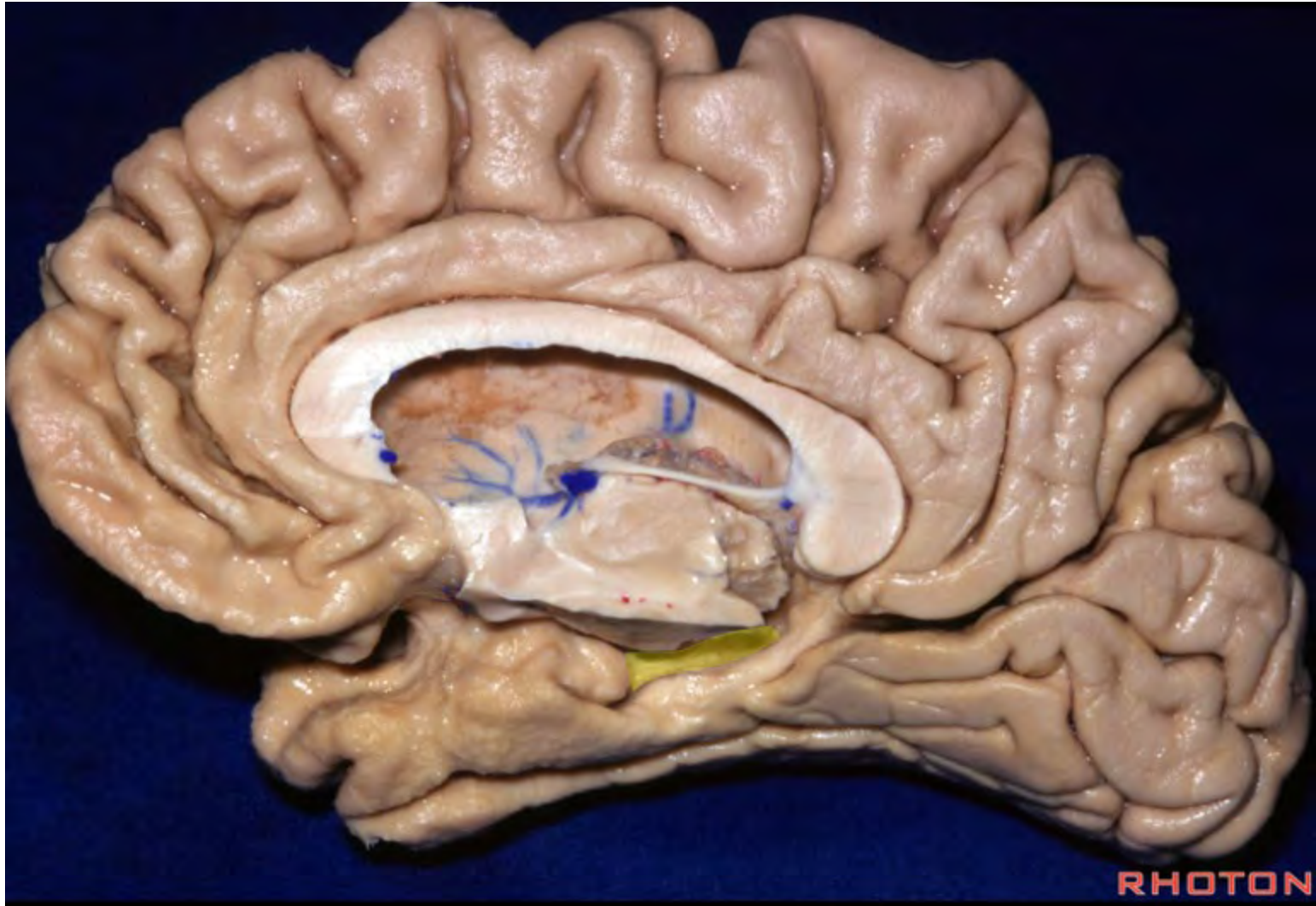


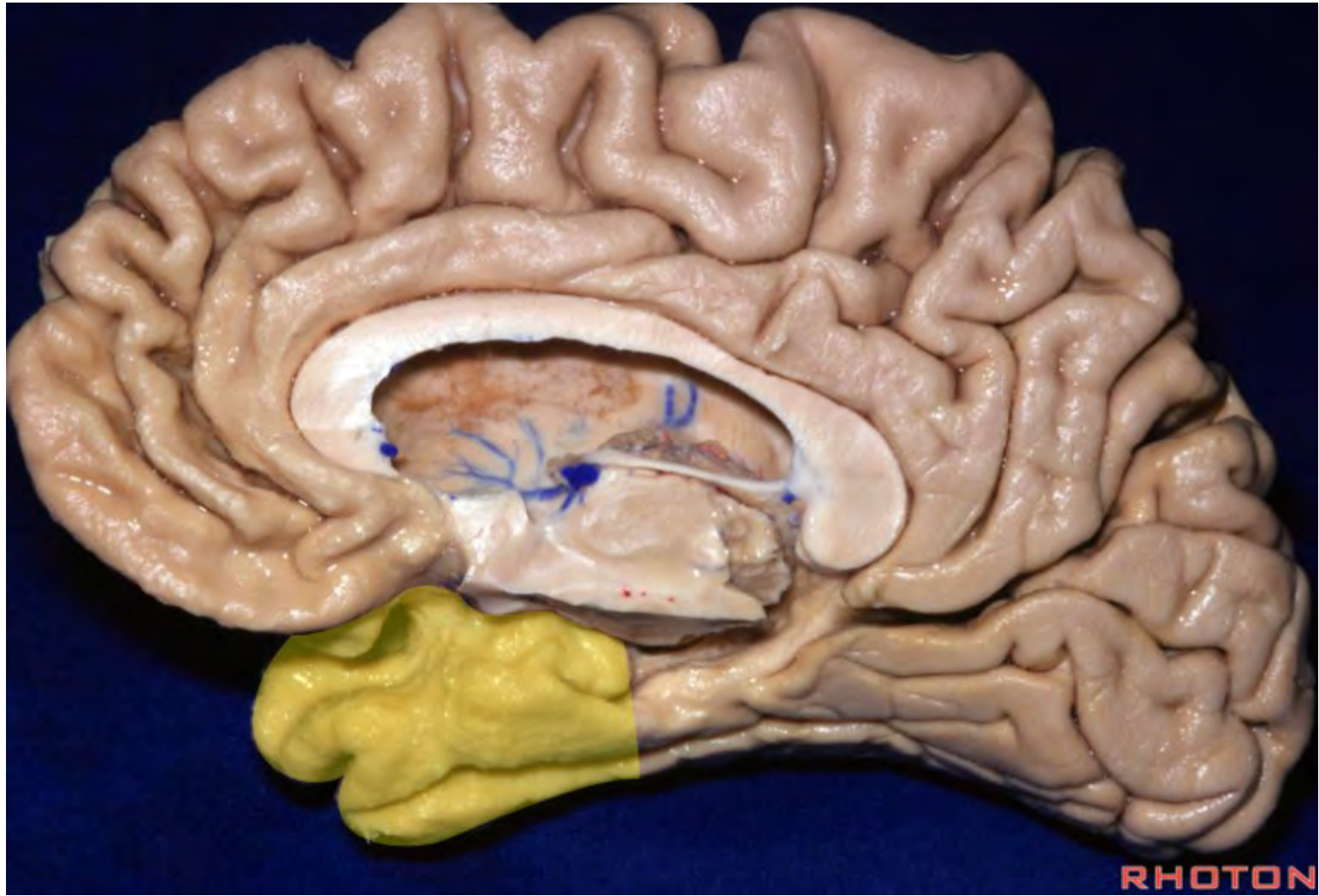




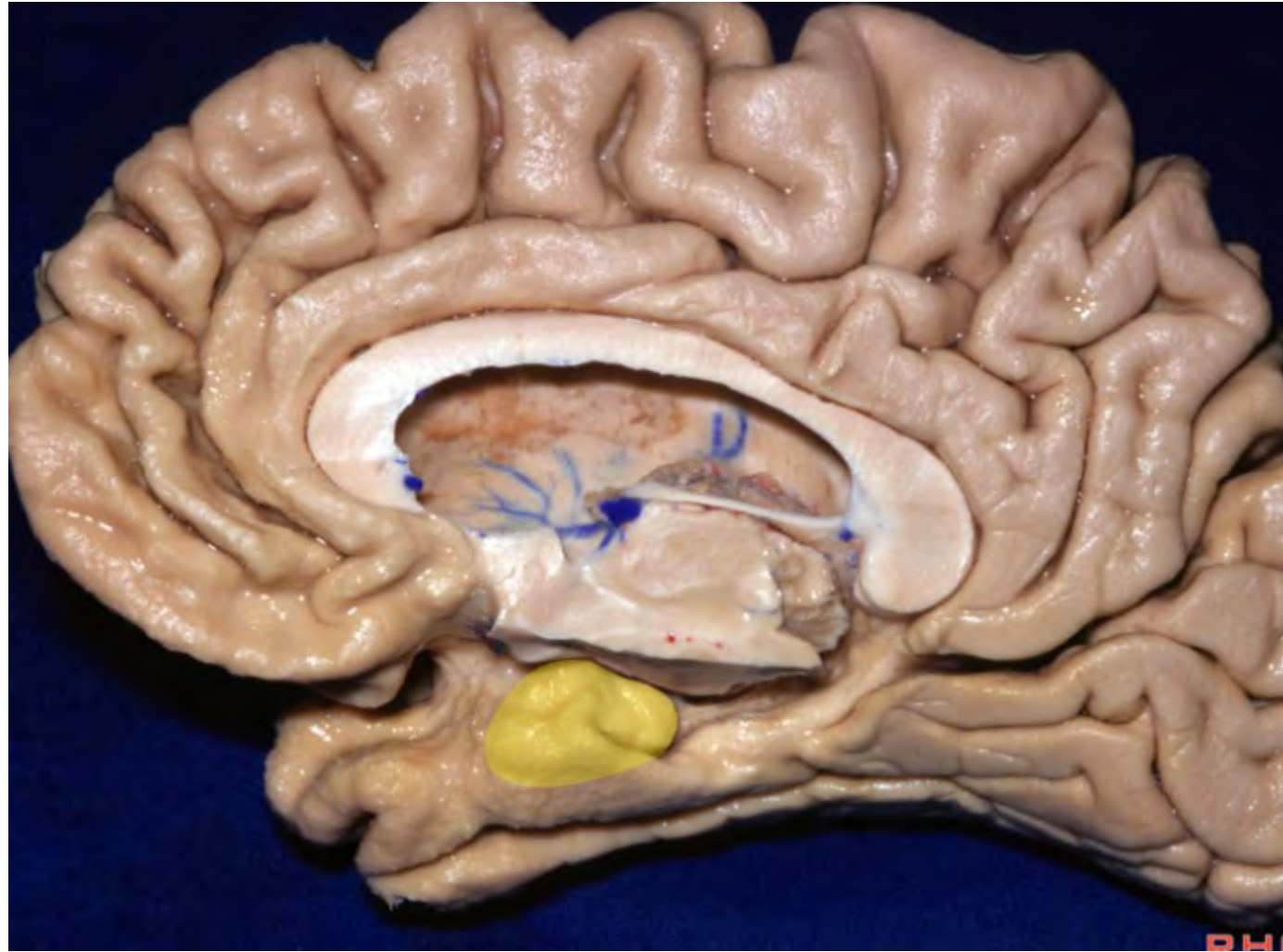


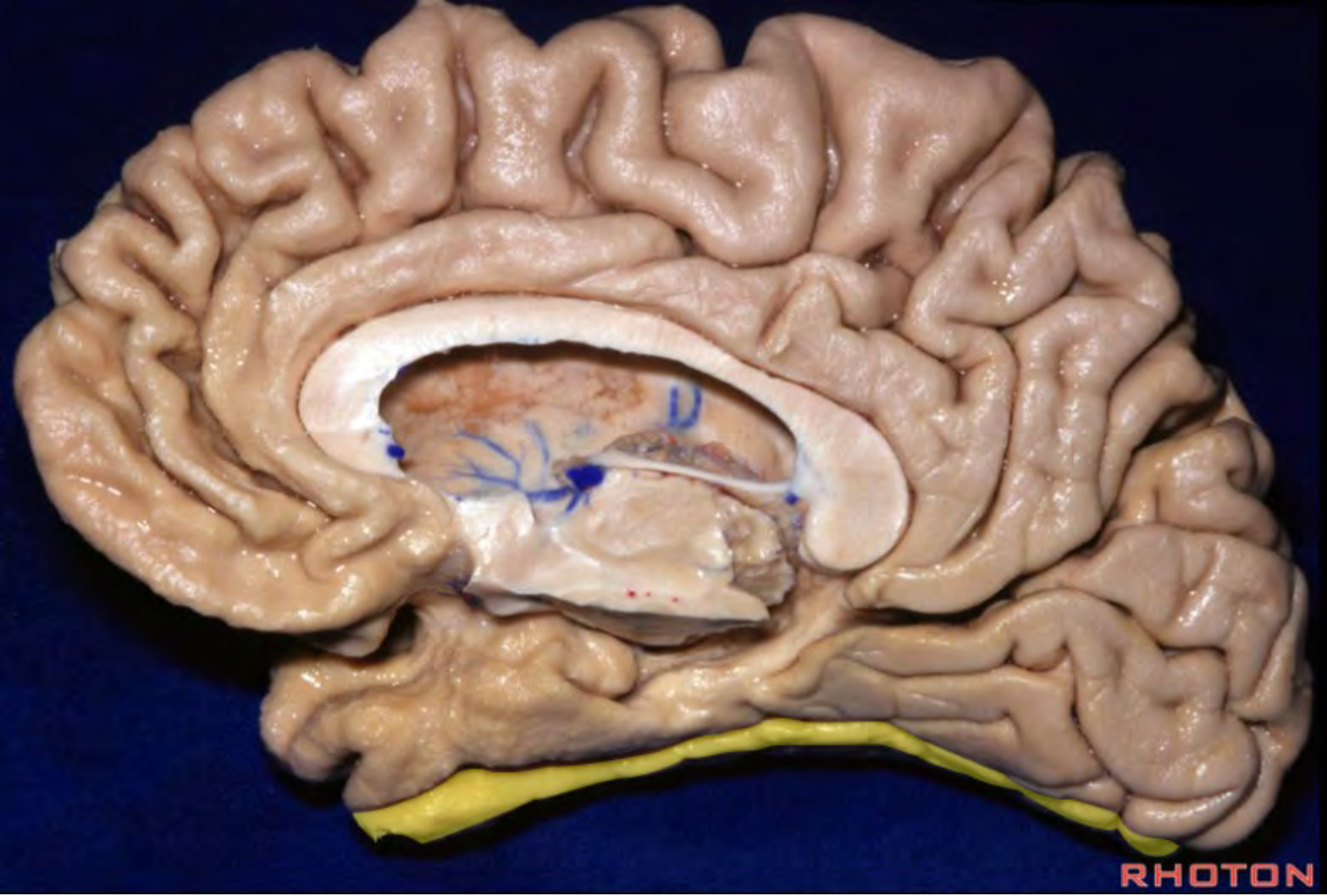


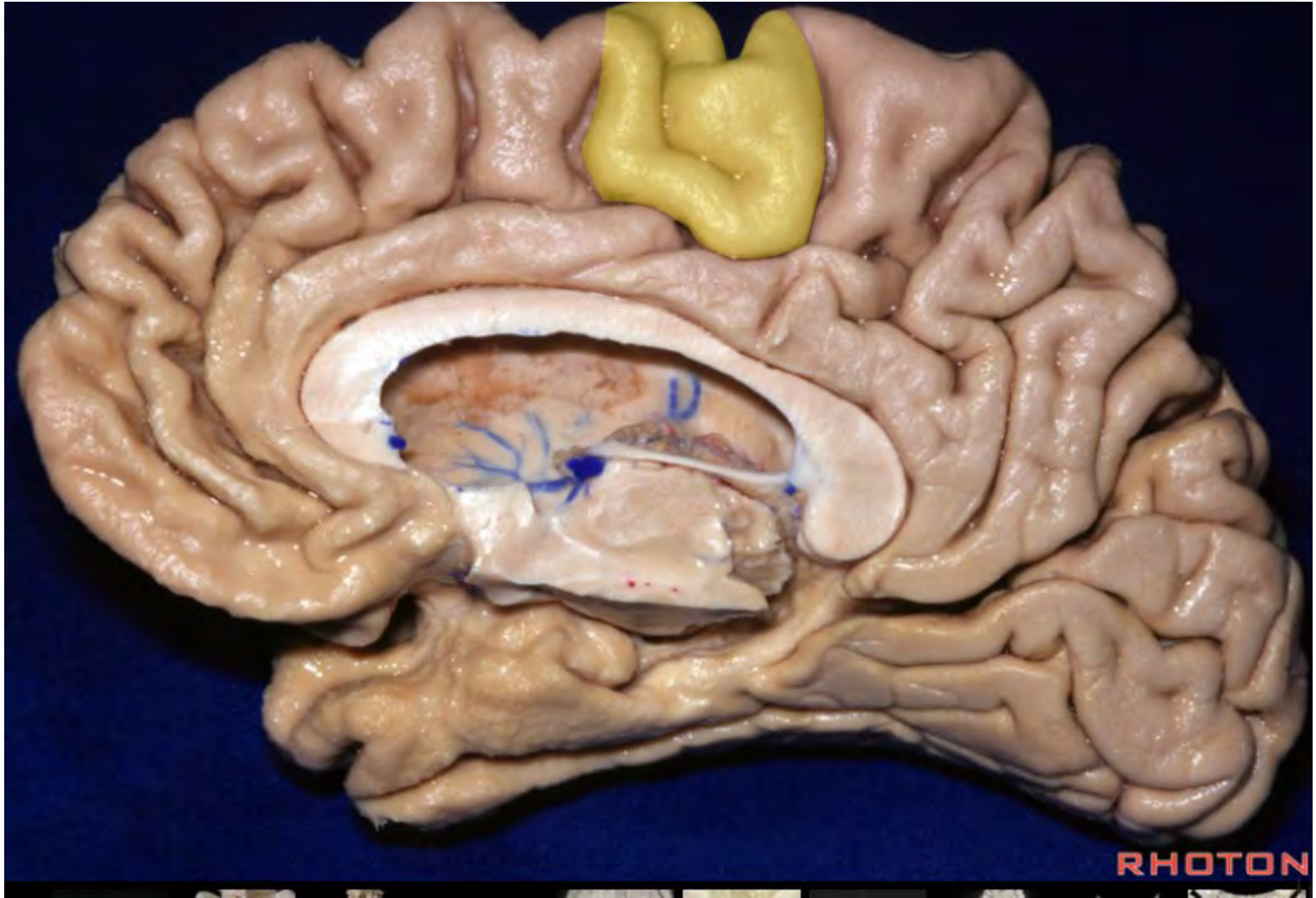


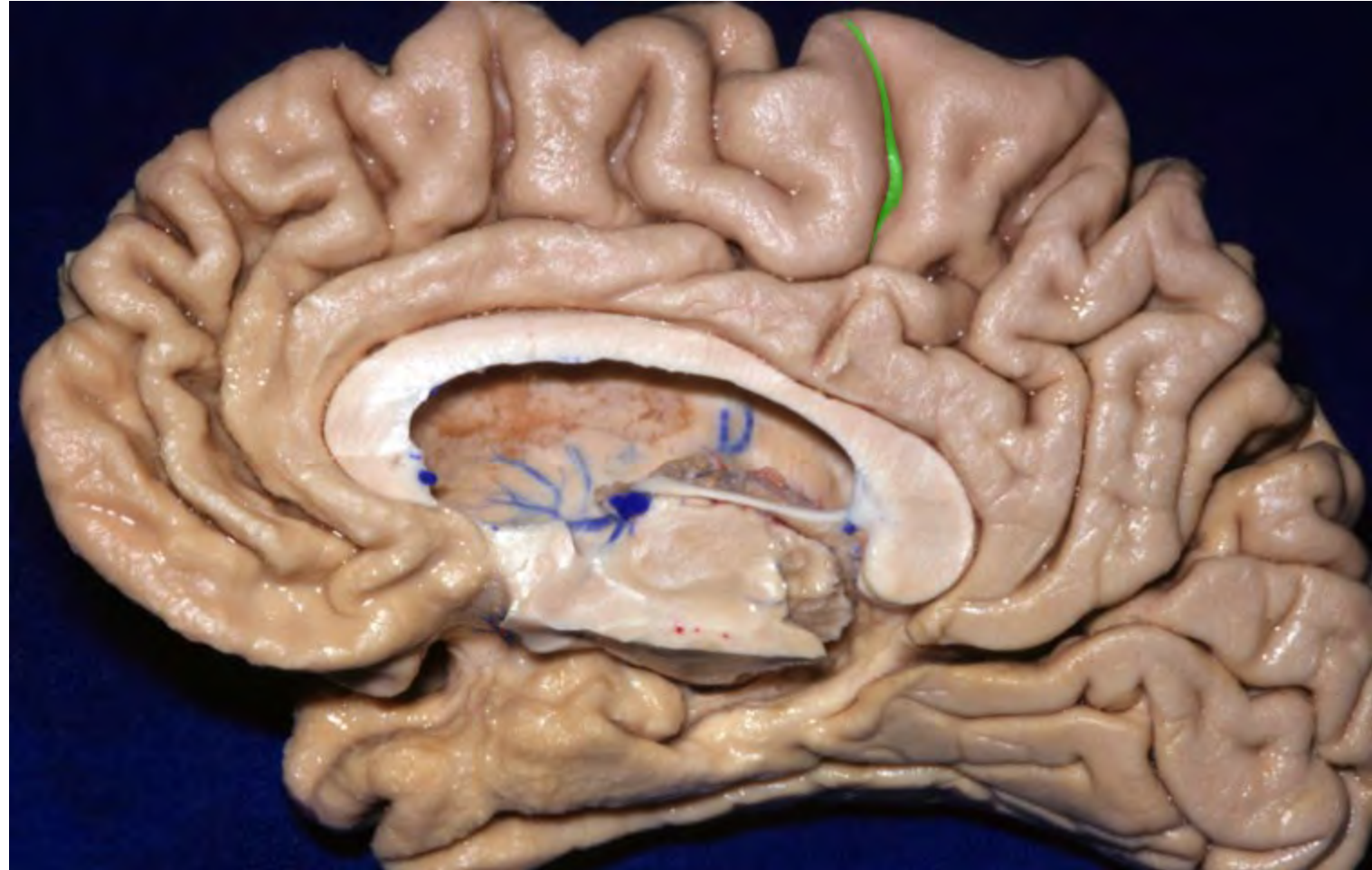


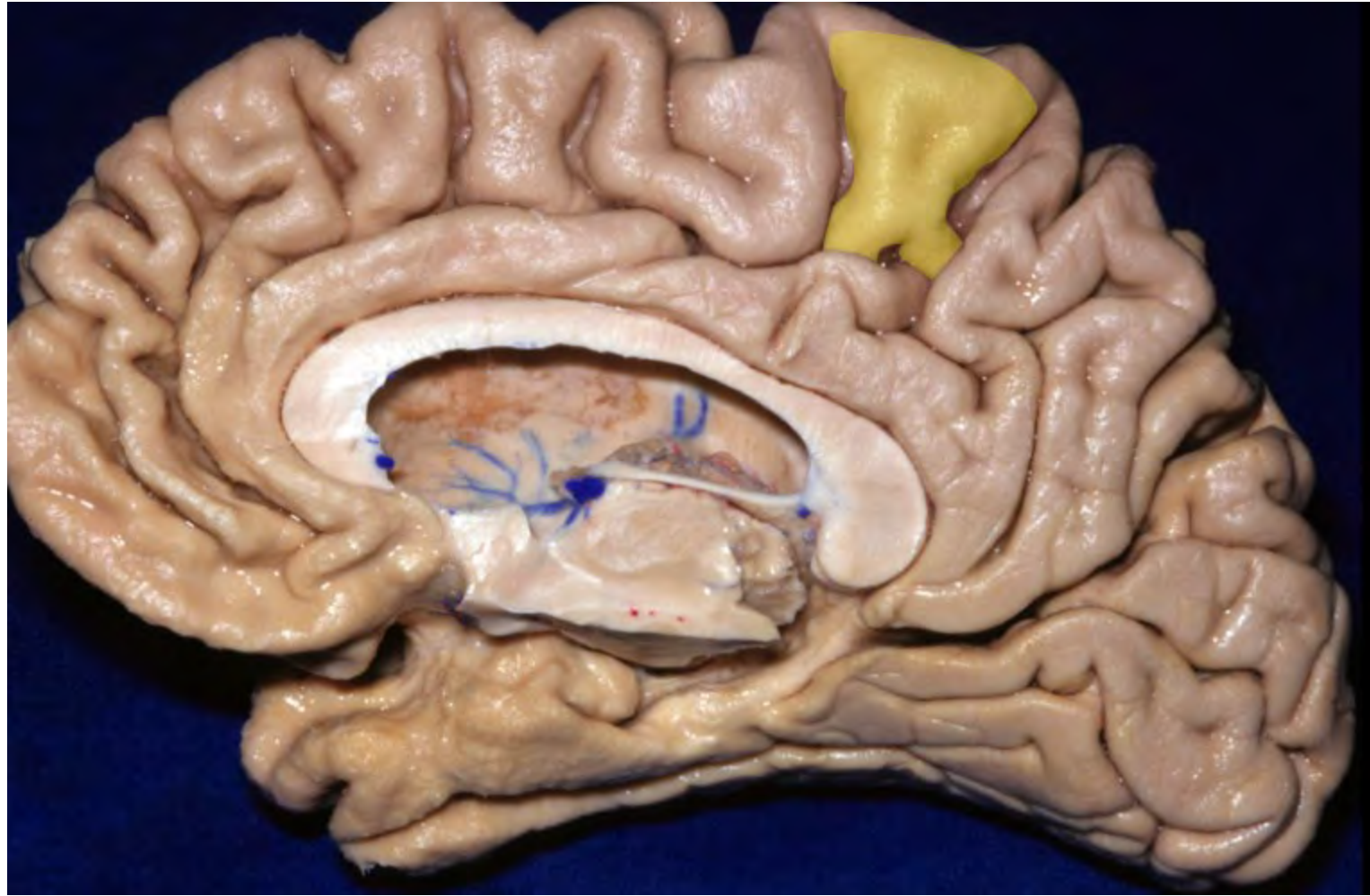


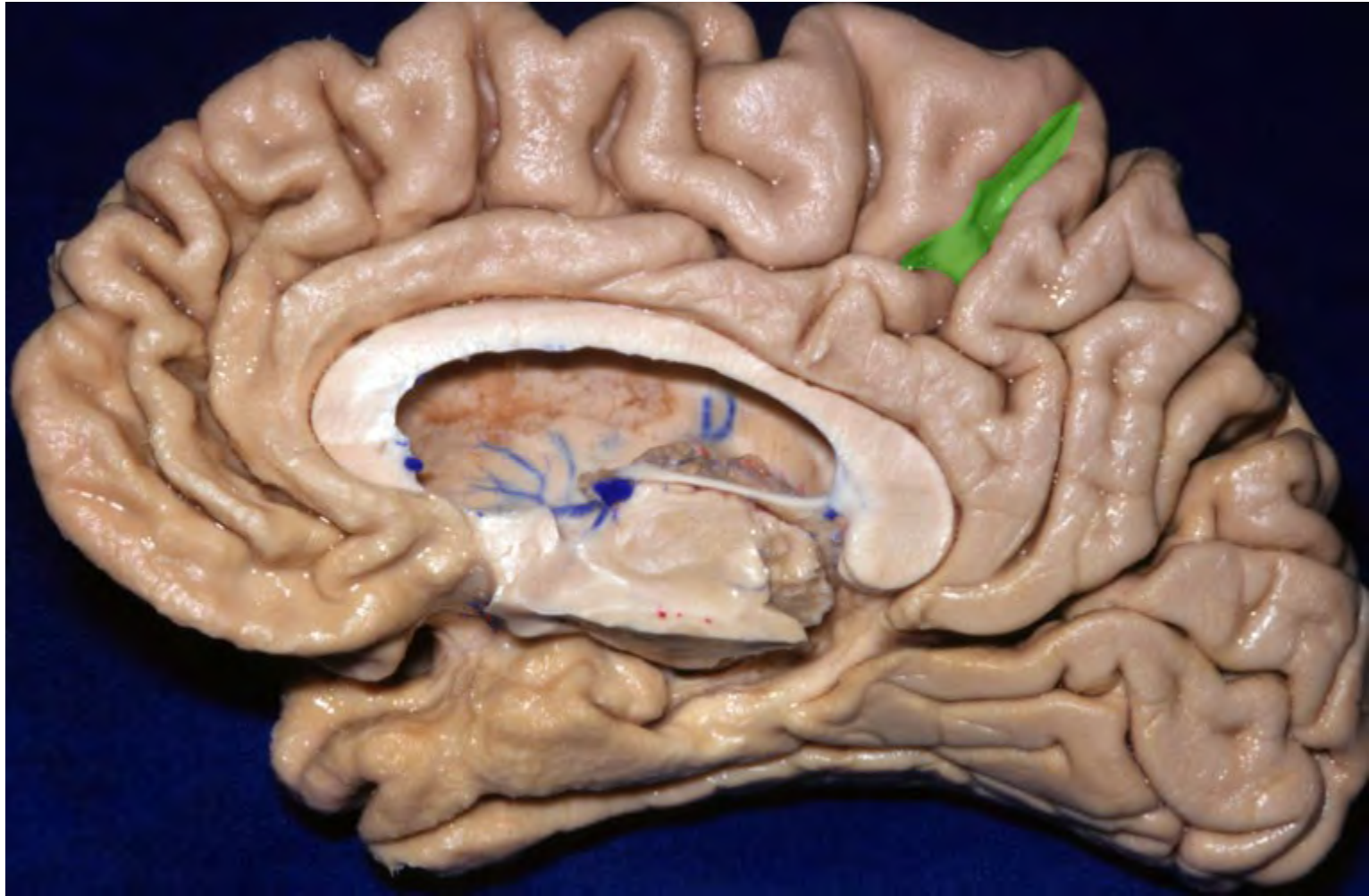


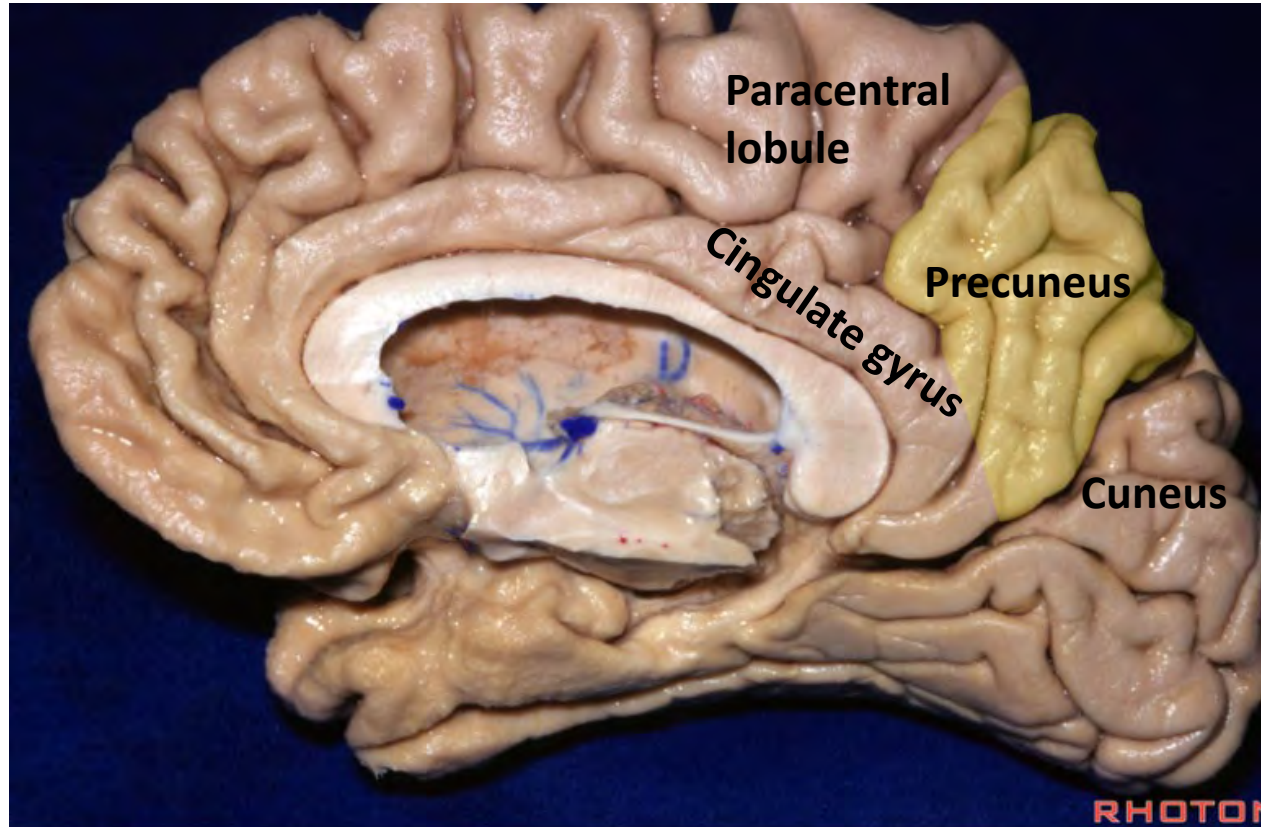






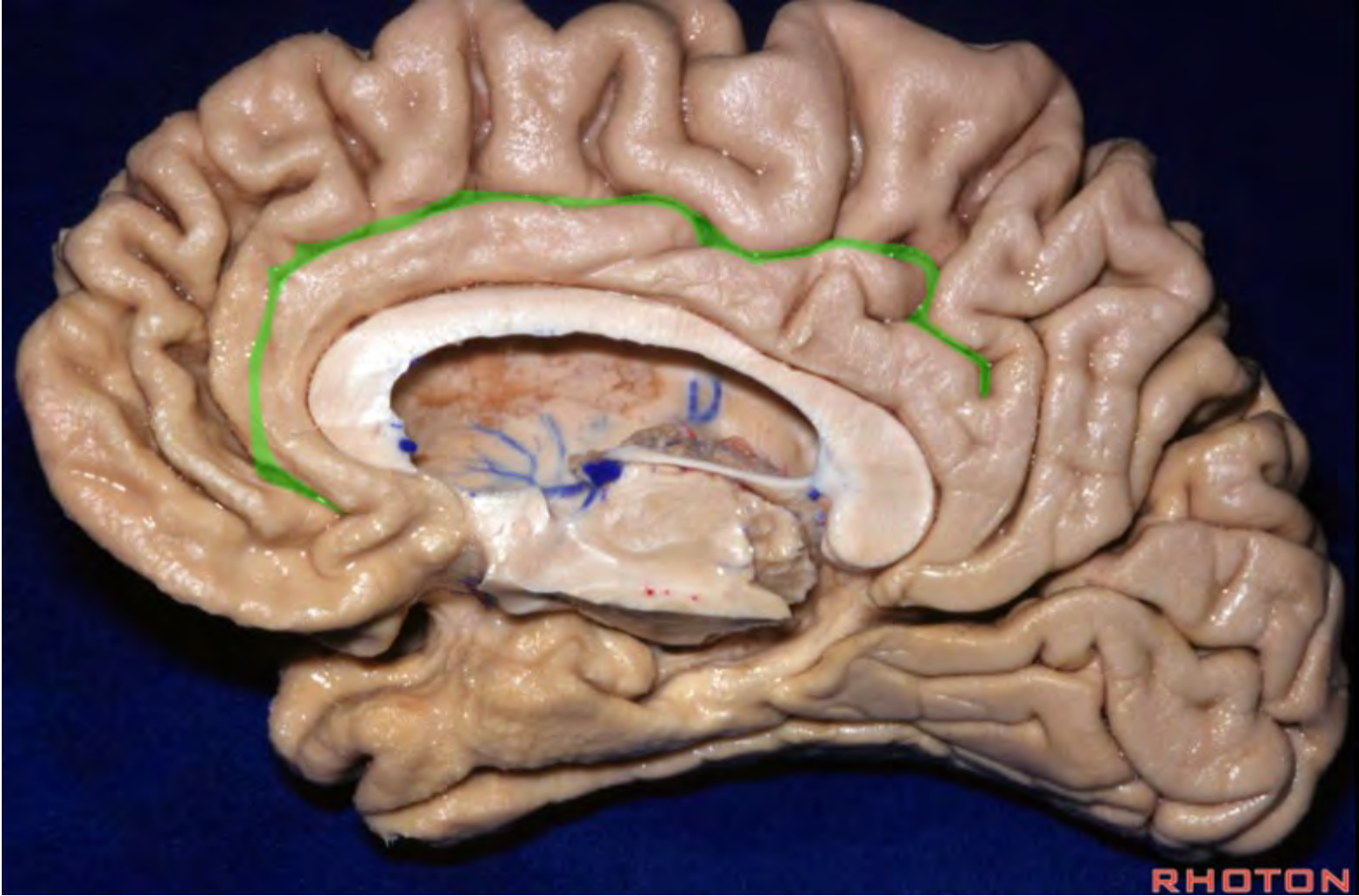




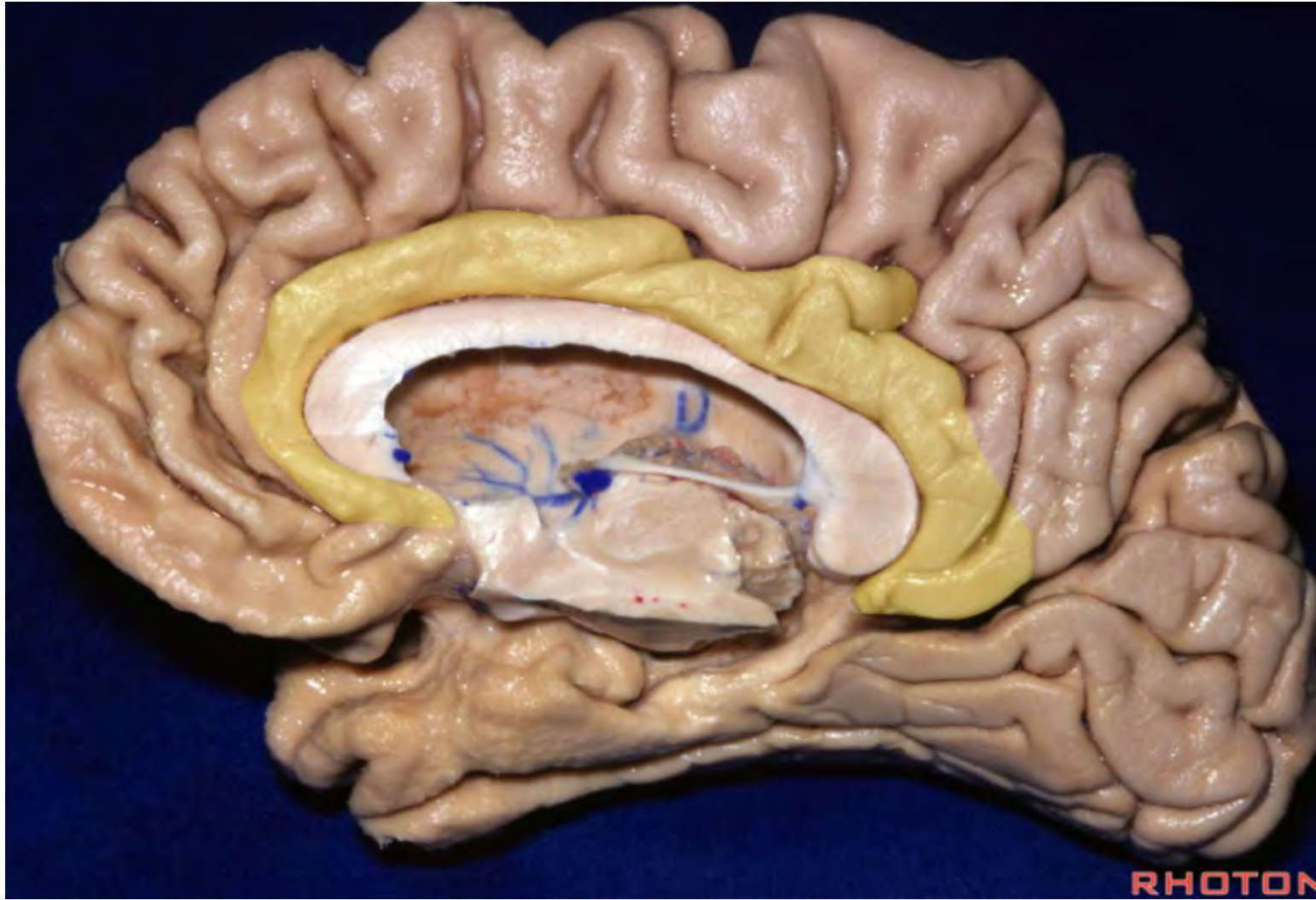


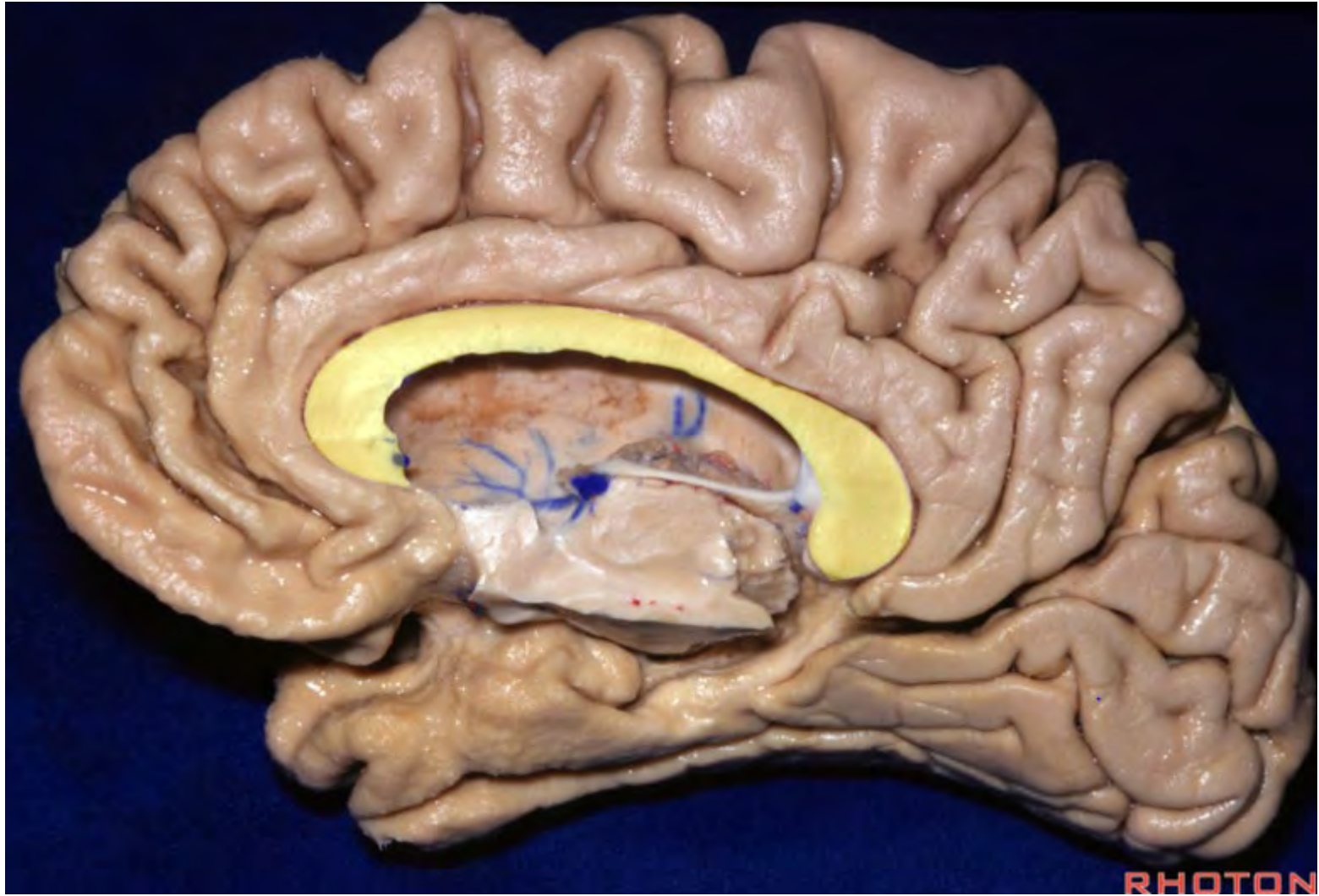
### **Precuneus**

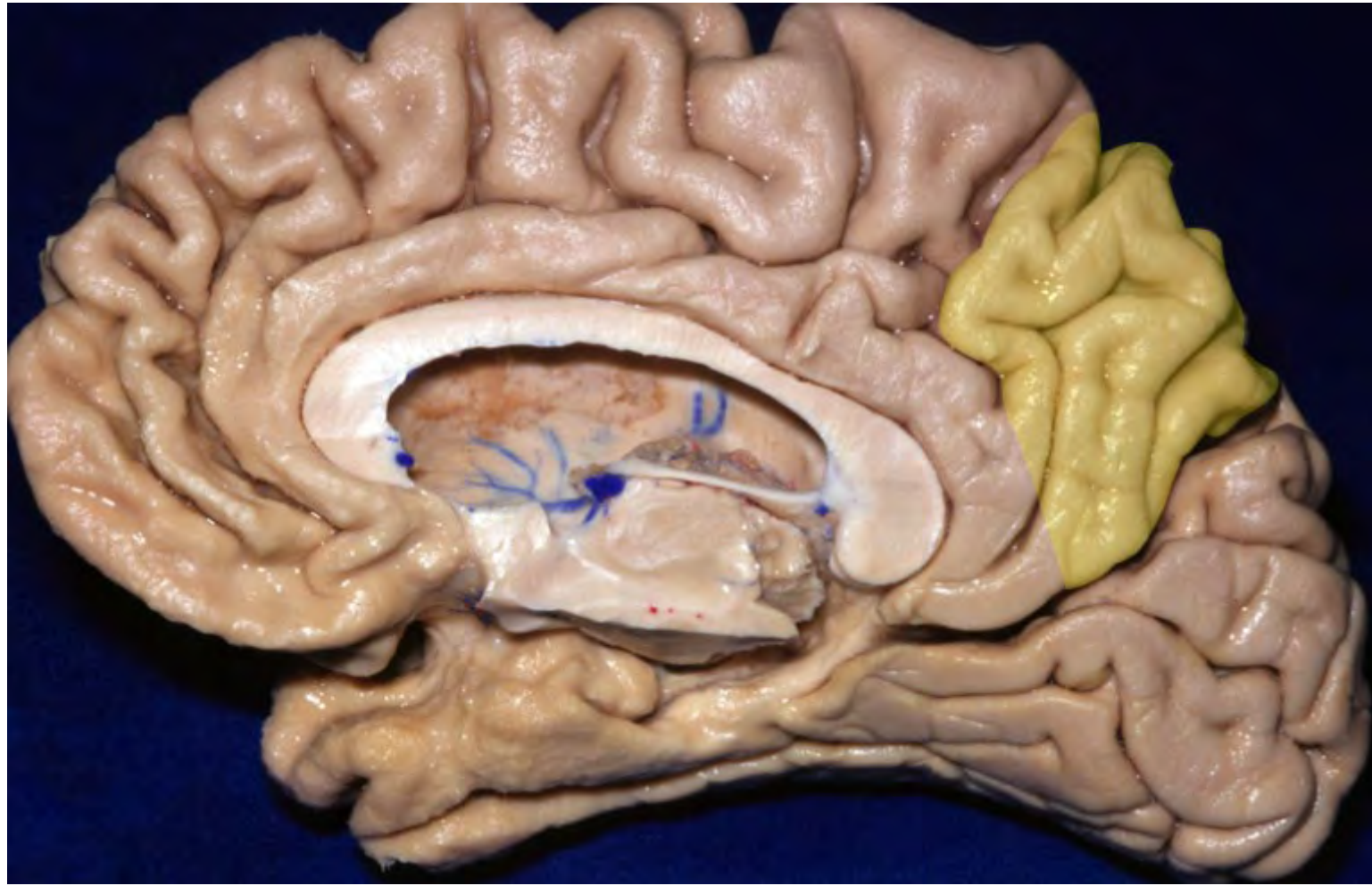
- (1) Separated from the cuneus (occipital lobe) by the medial portion of parieto-occipital sulcus
- (2) Separated from paracentral lobule (medial continuation of pre- and post-central gyri) by pars marginalis (ascending branch of the cingulate sulcus)
- (3) Separated from cingulate gyrus by subparietal sulcus

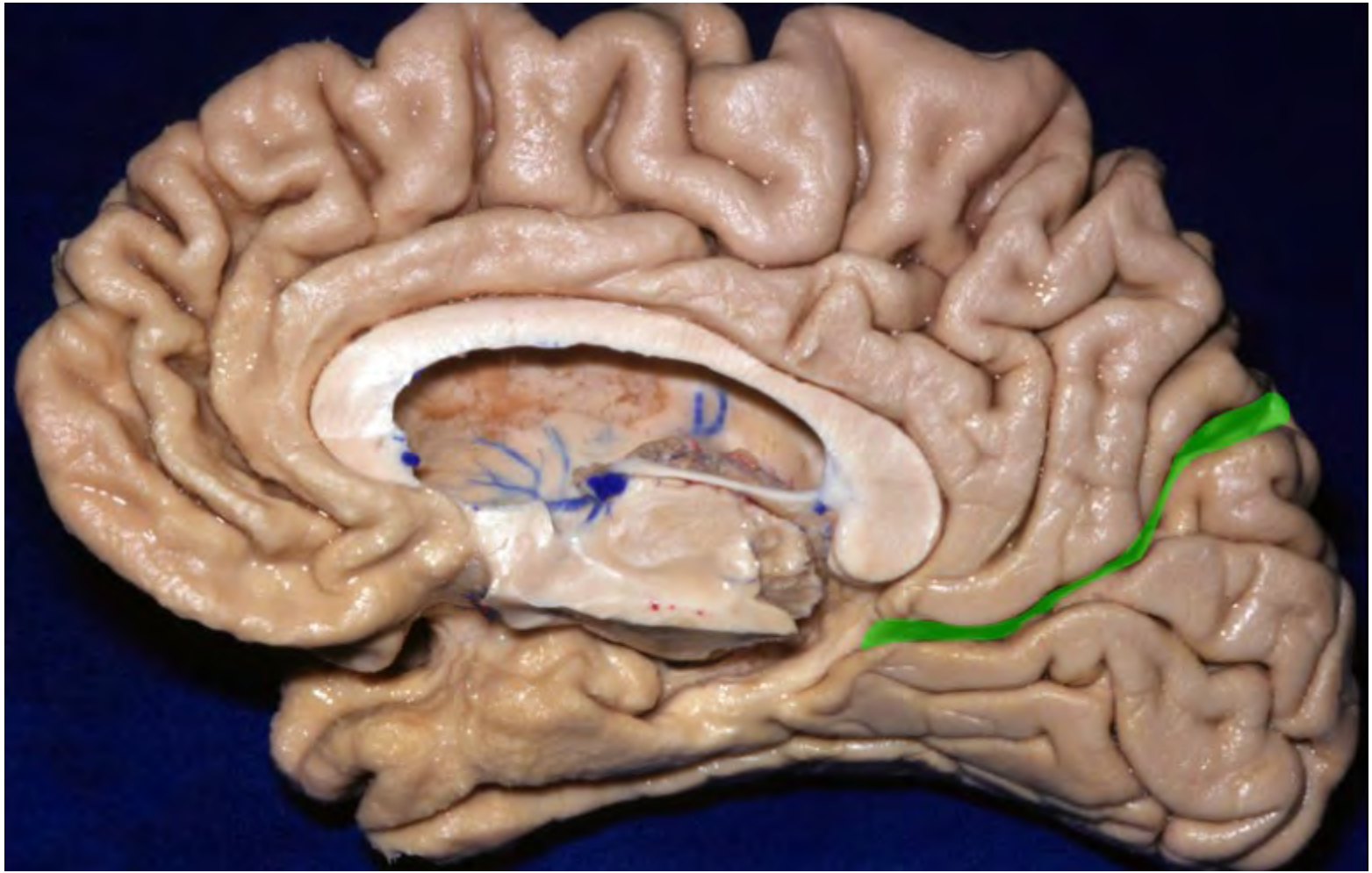


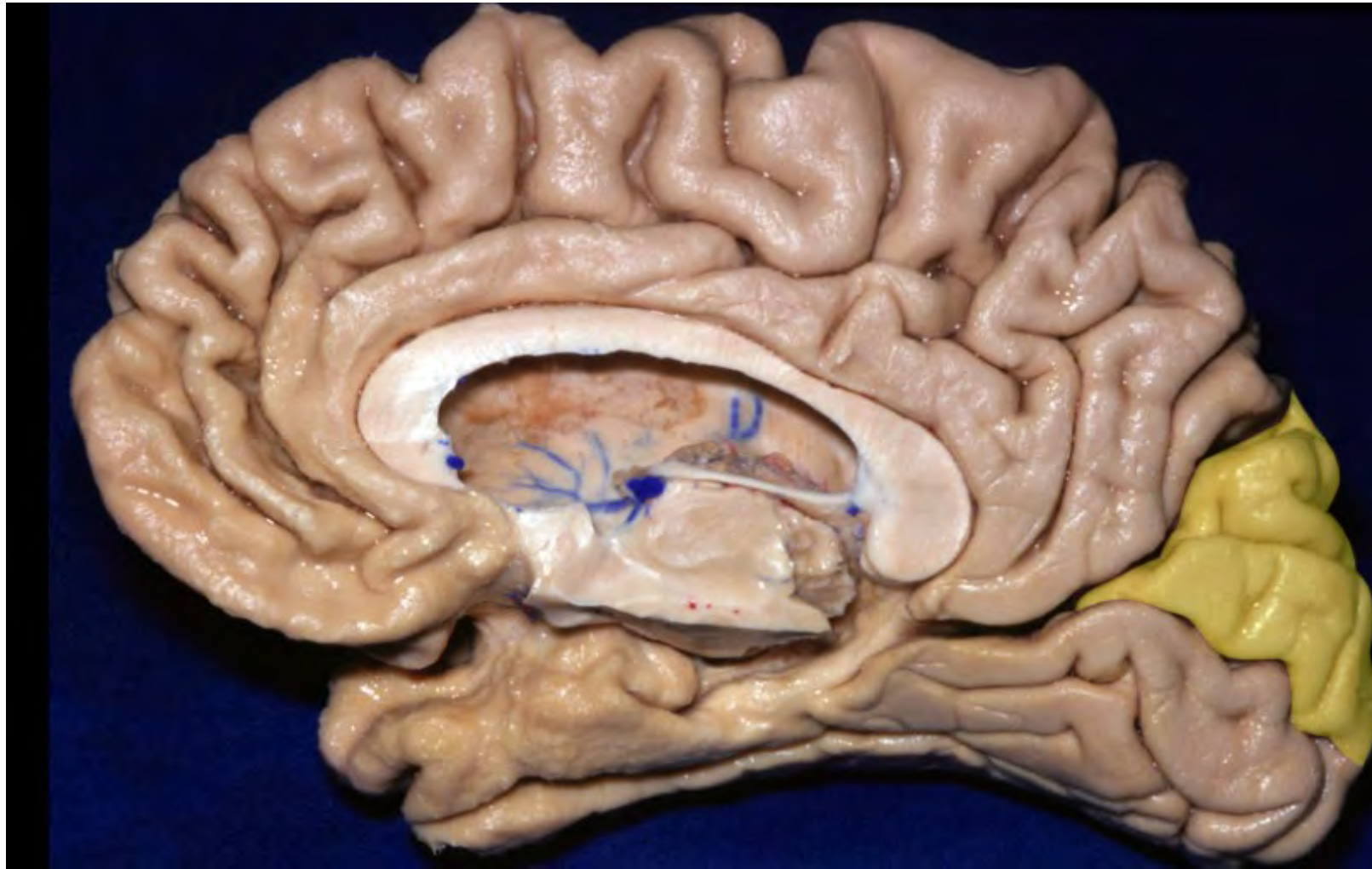


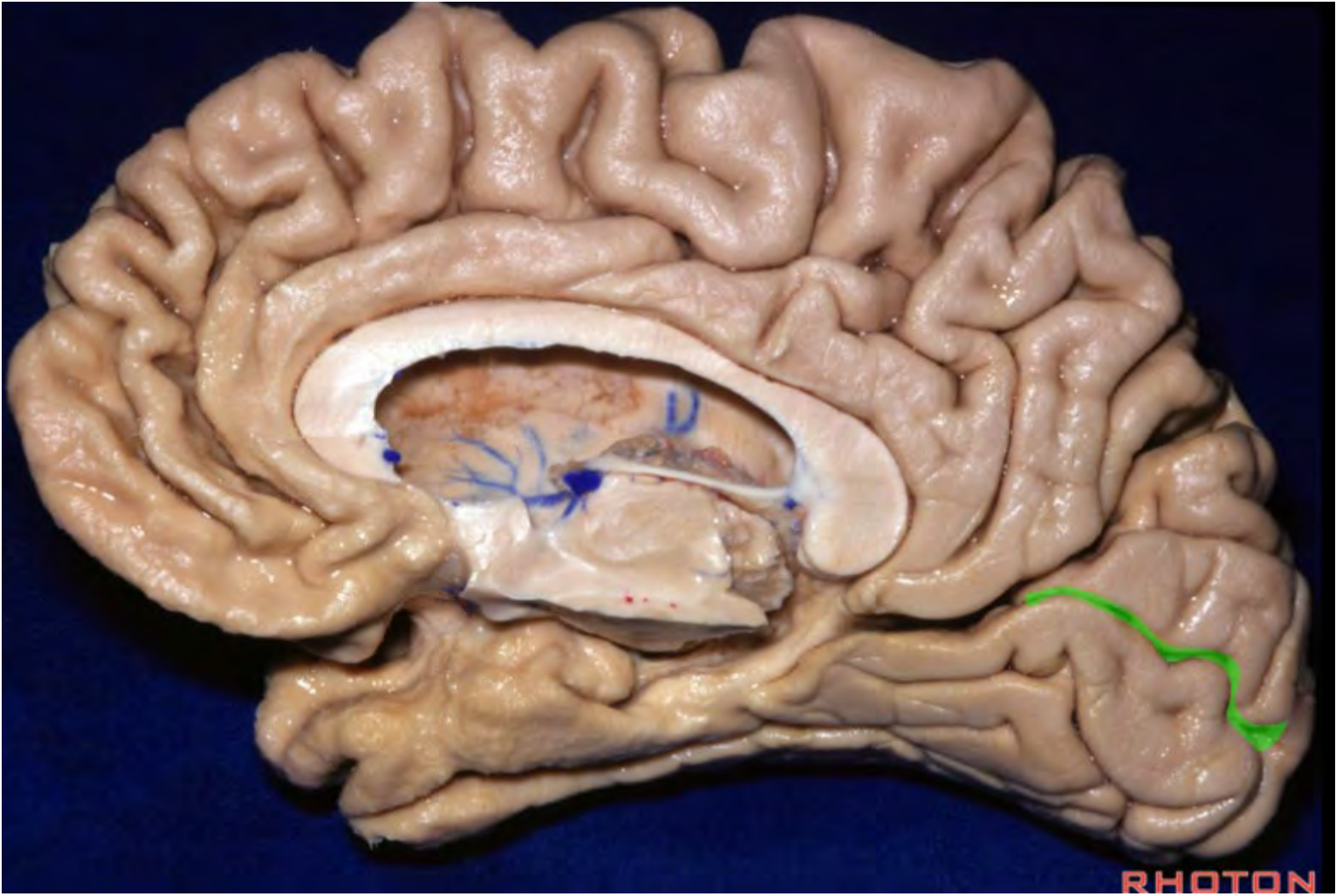


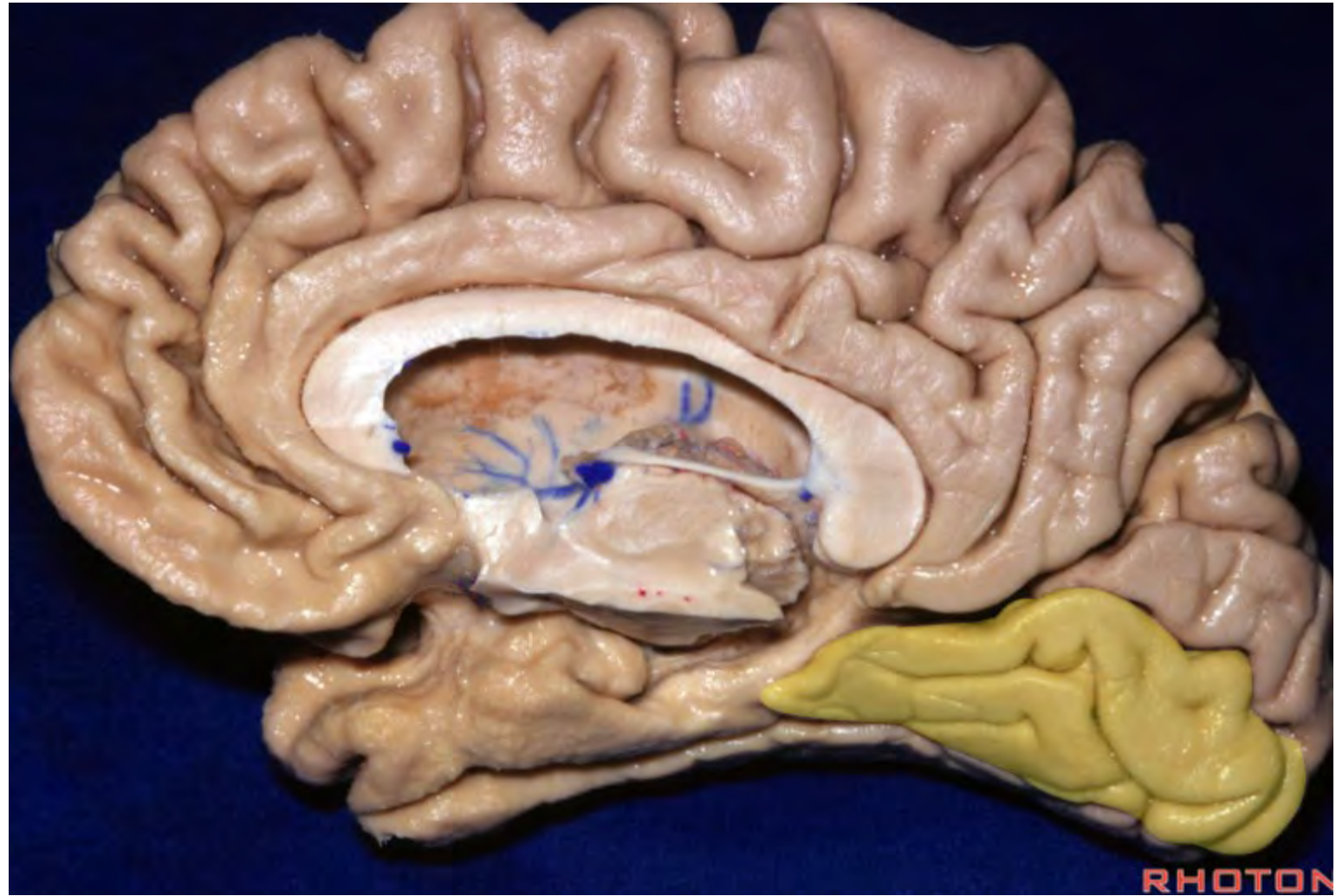


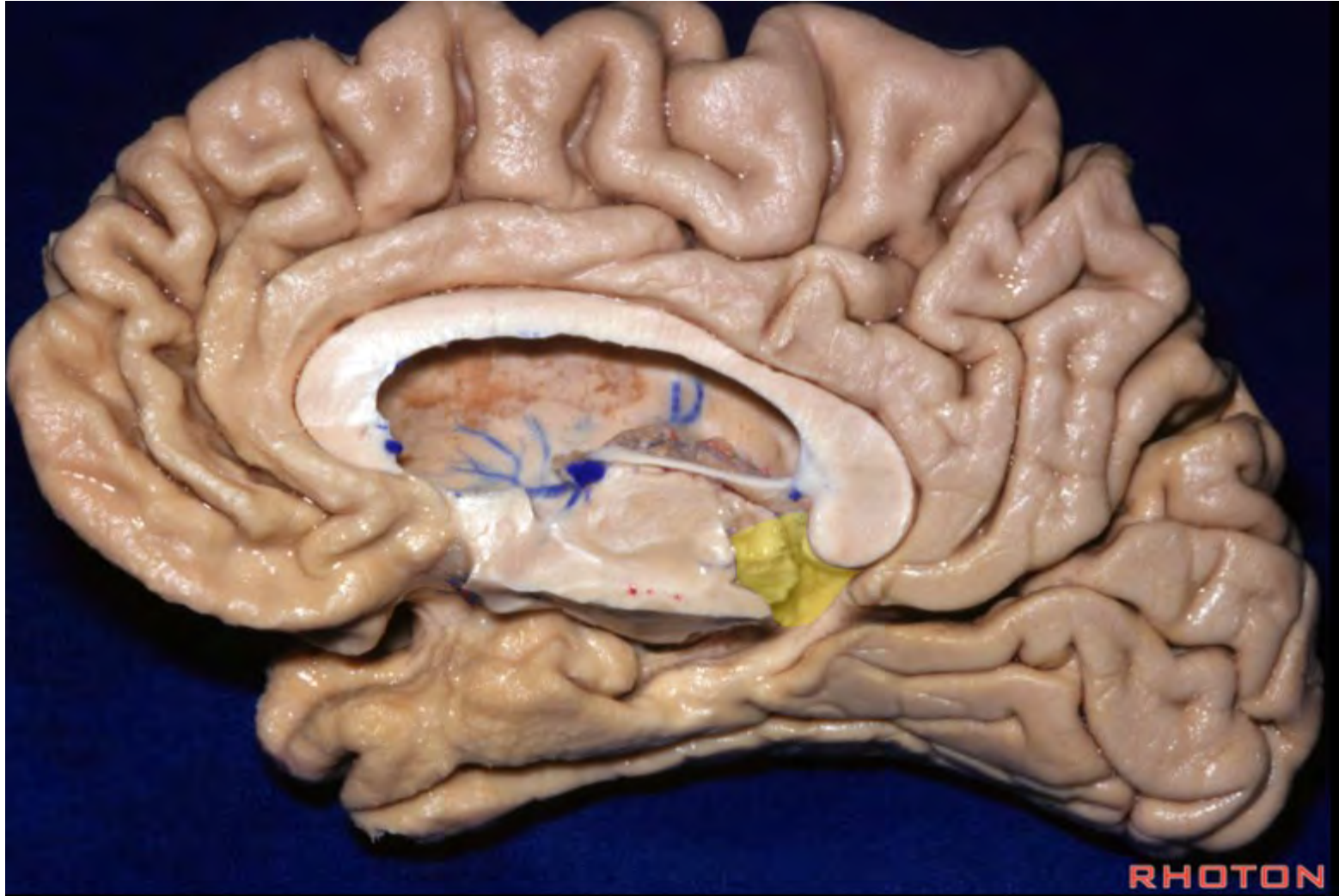




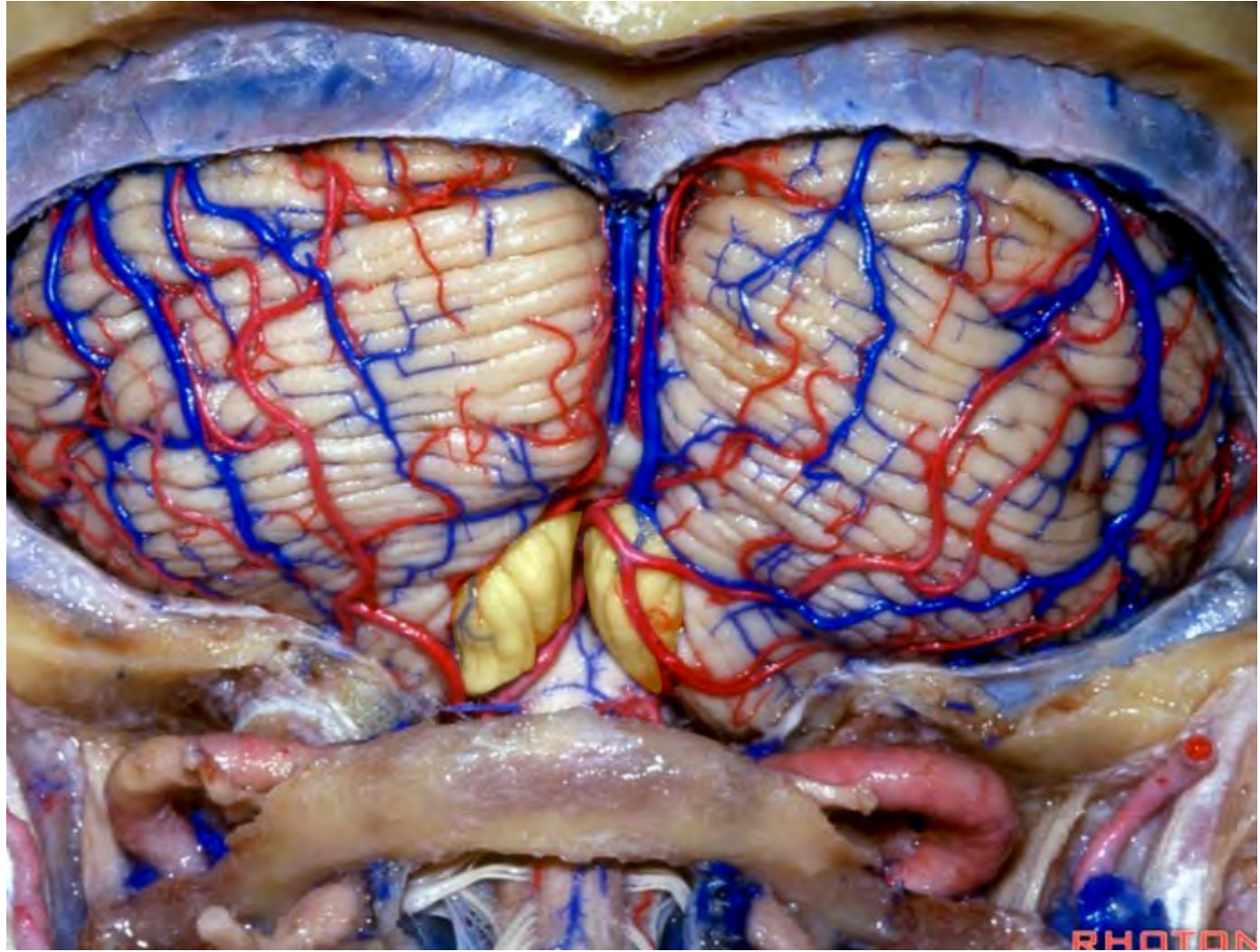


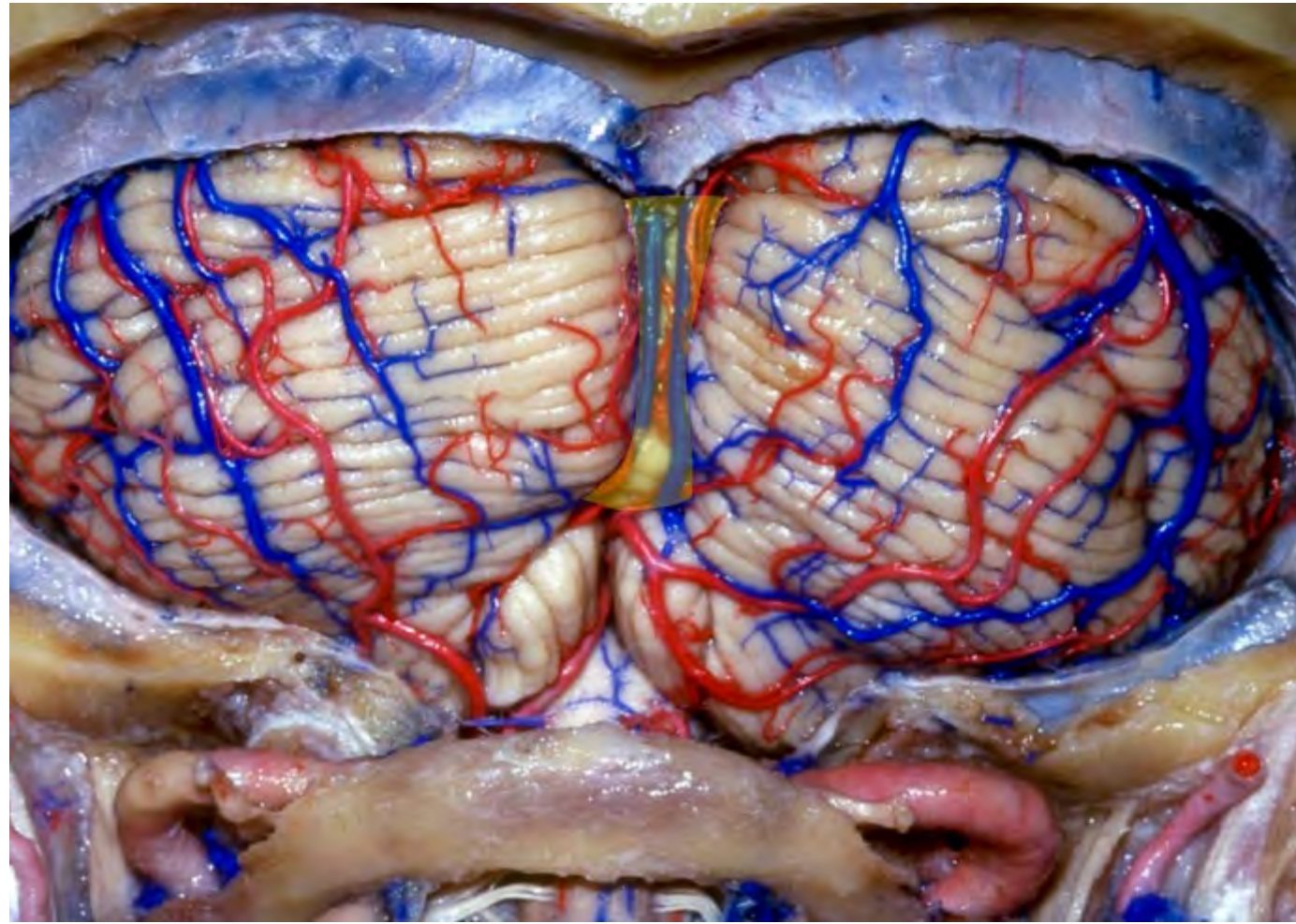


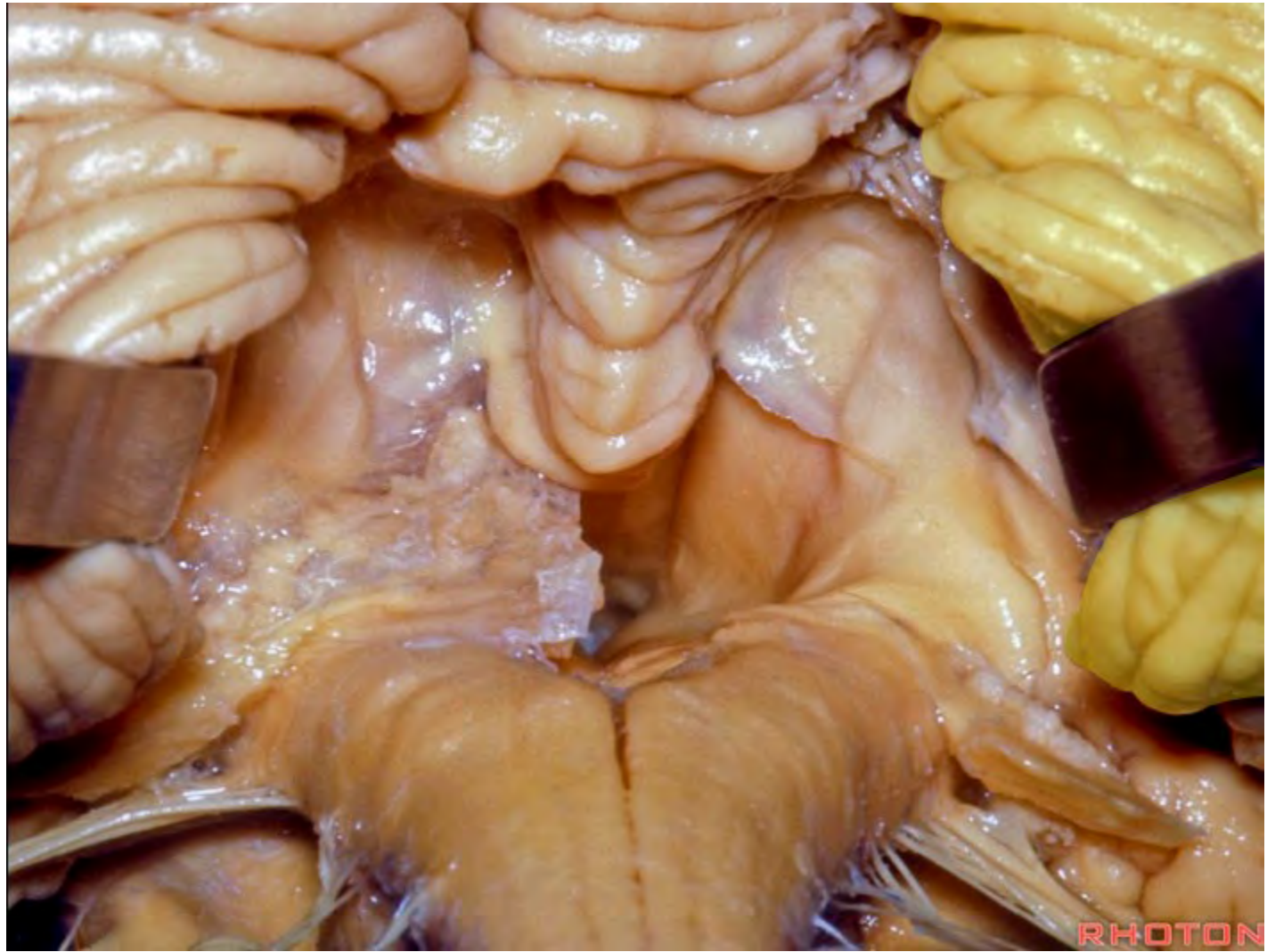

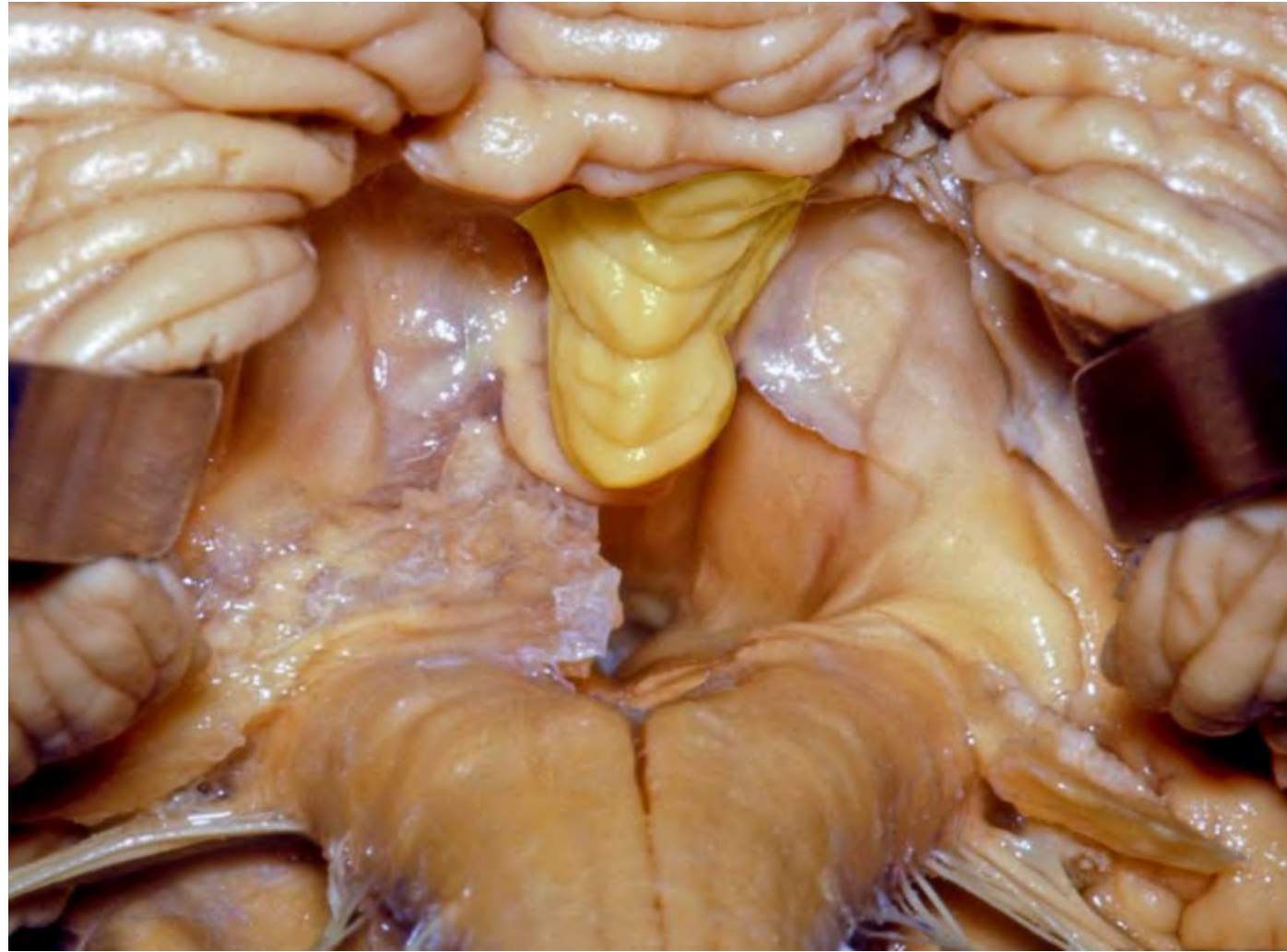


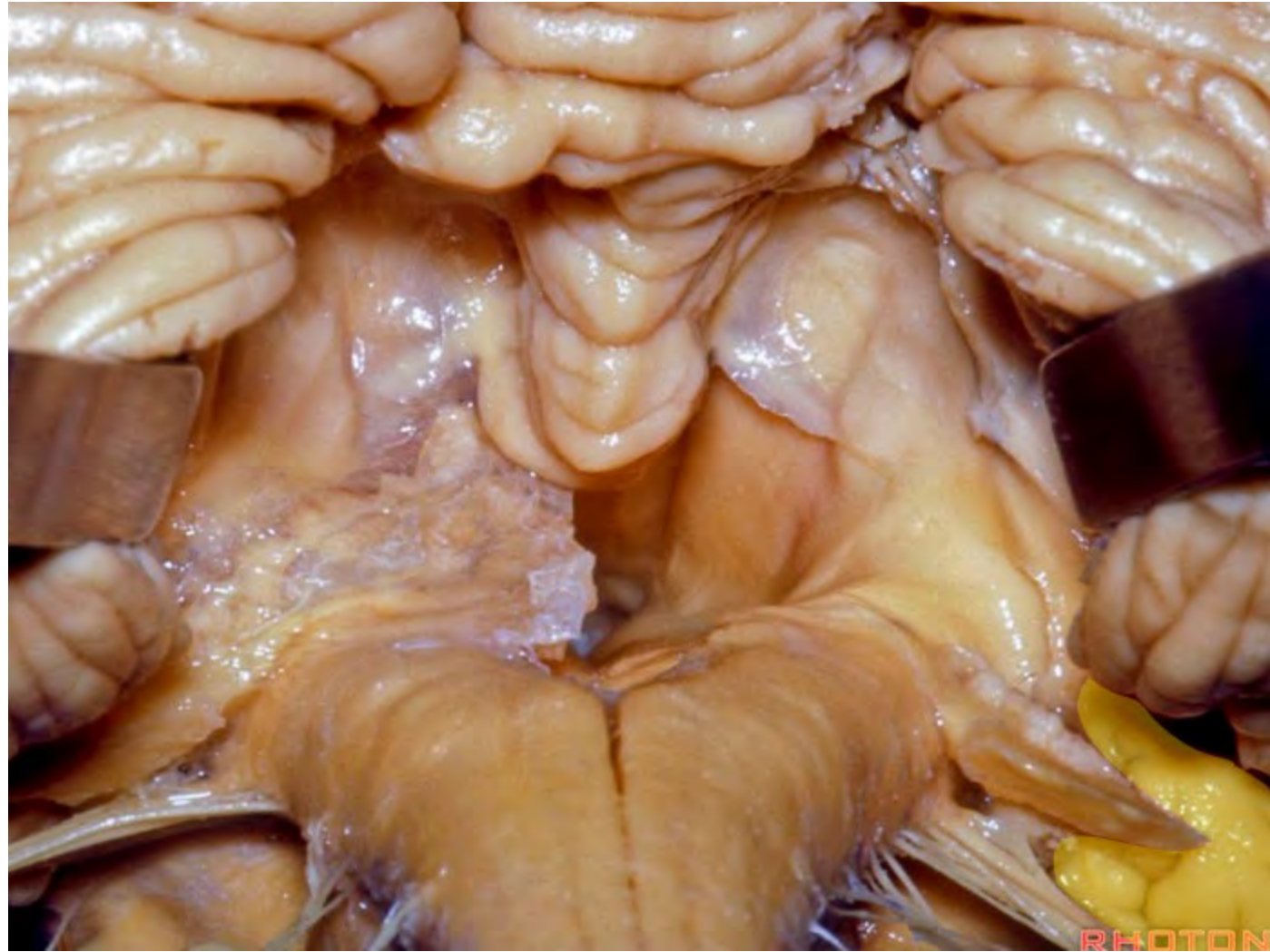


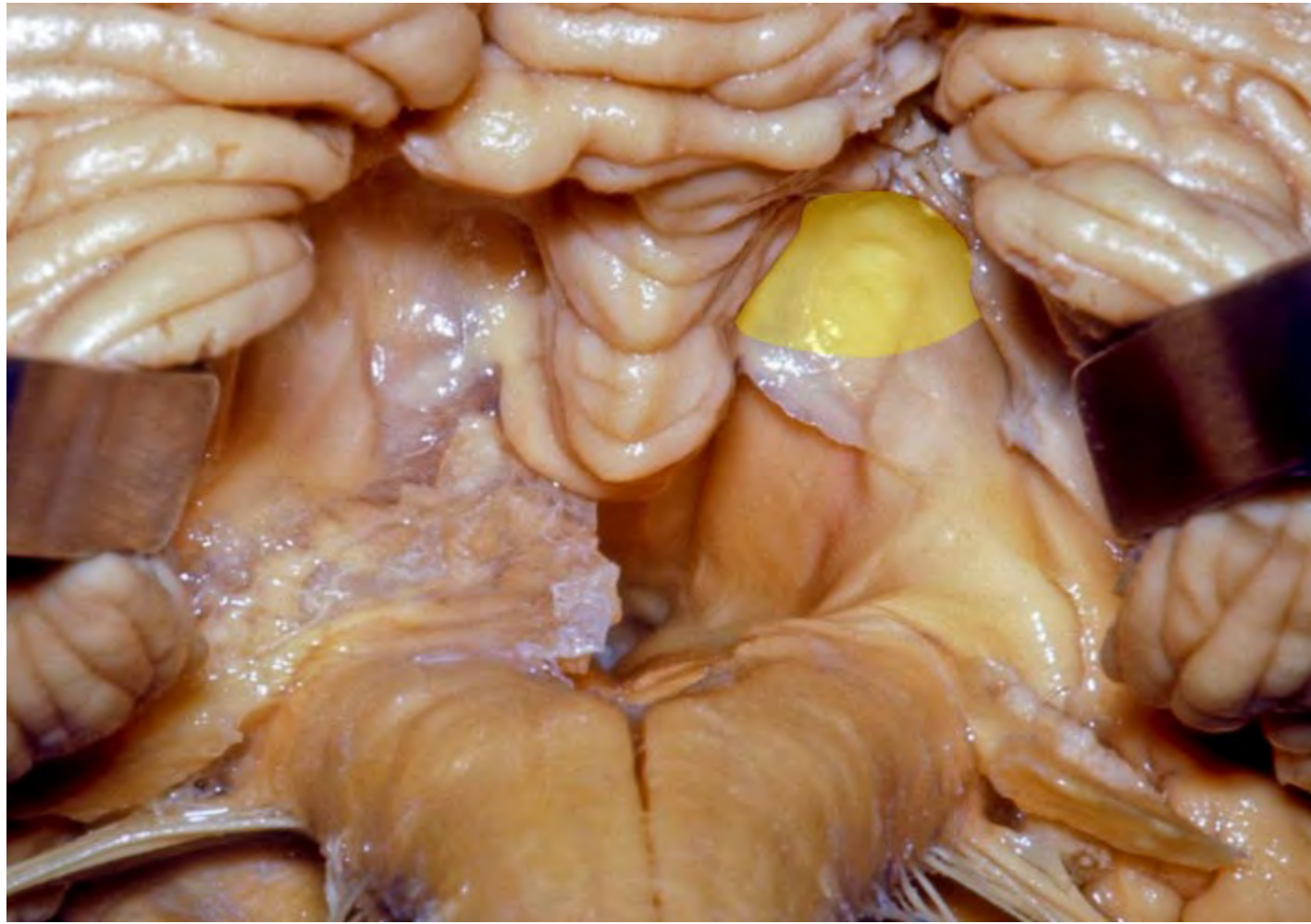



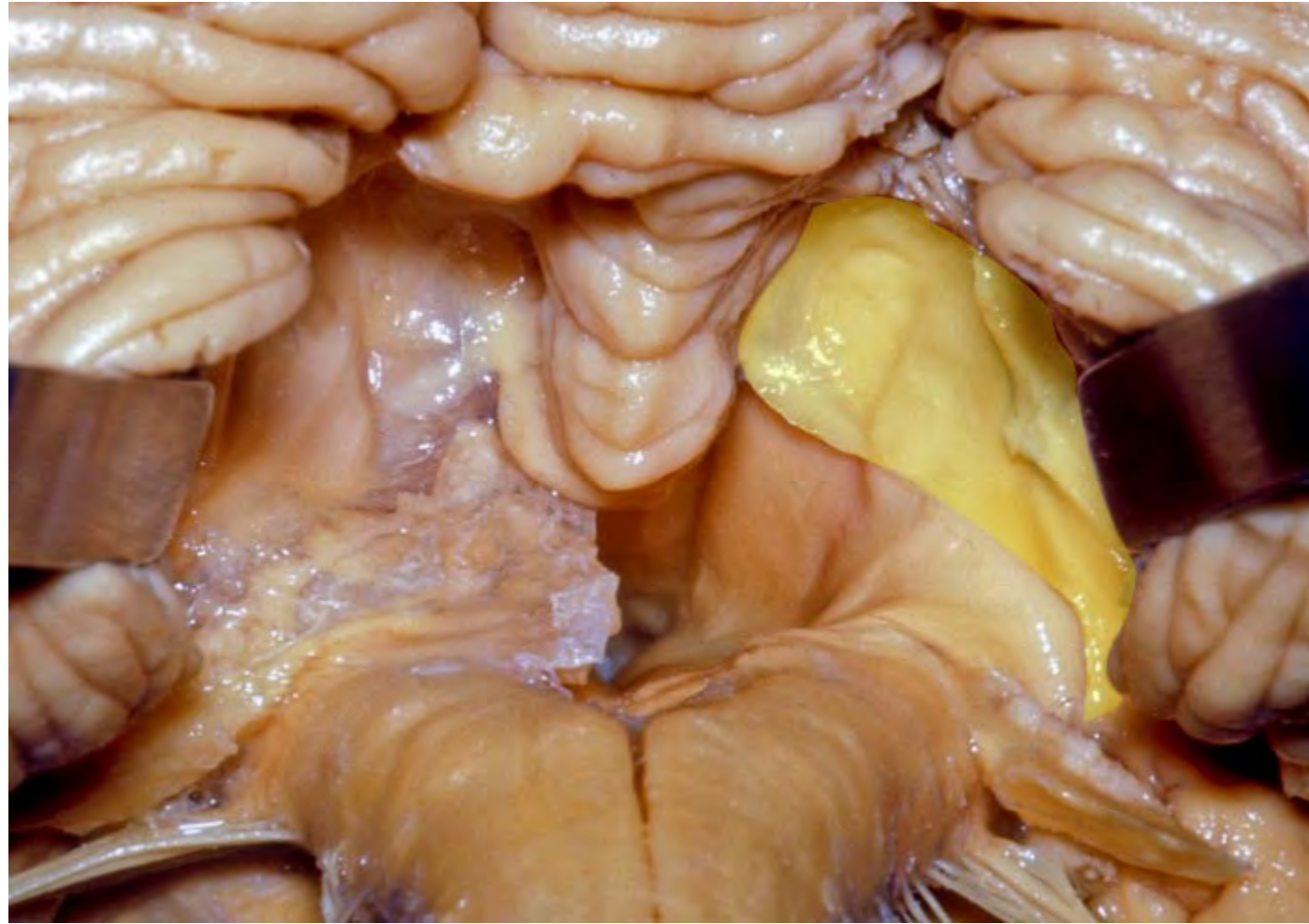


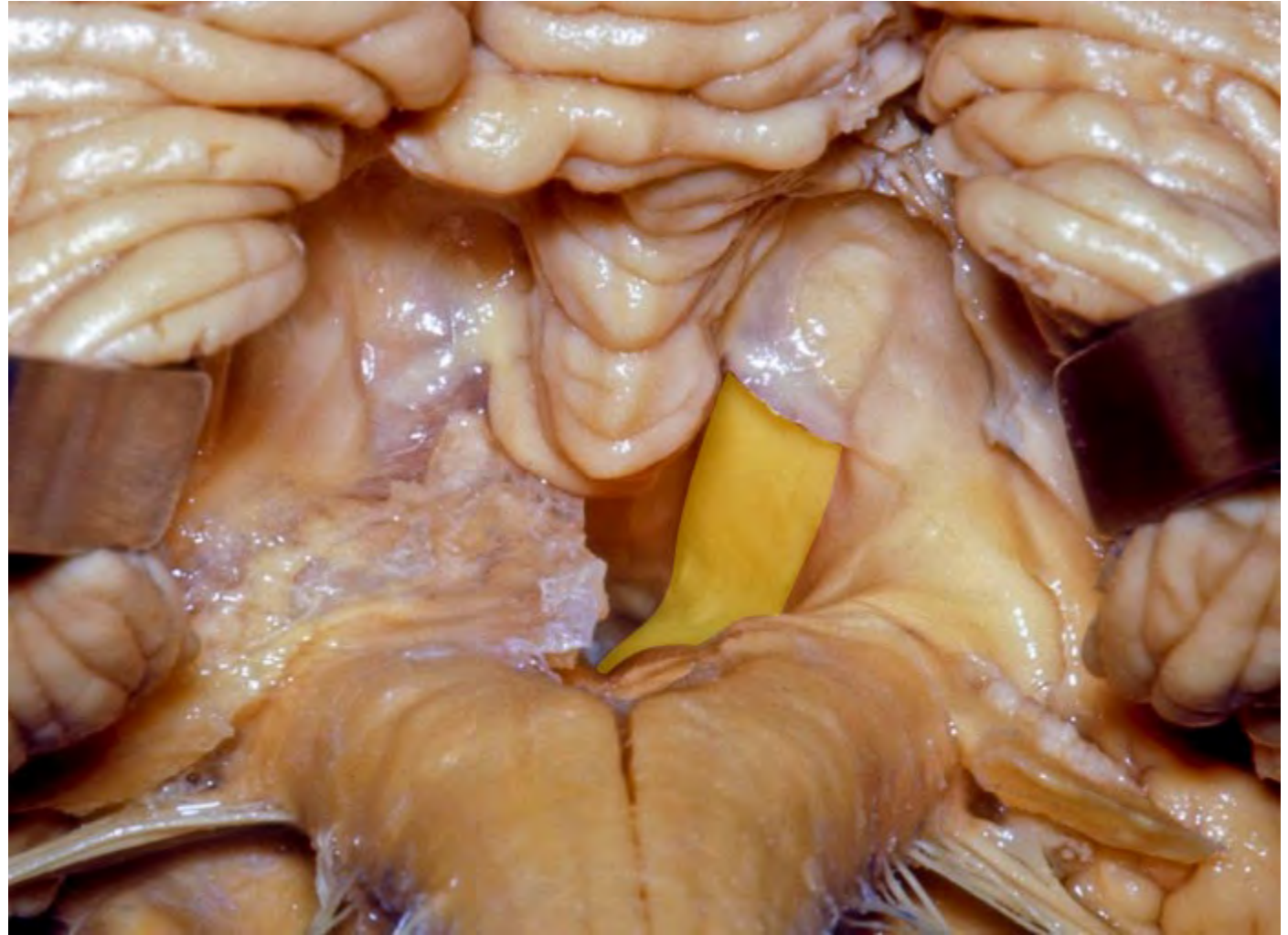




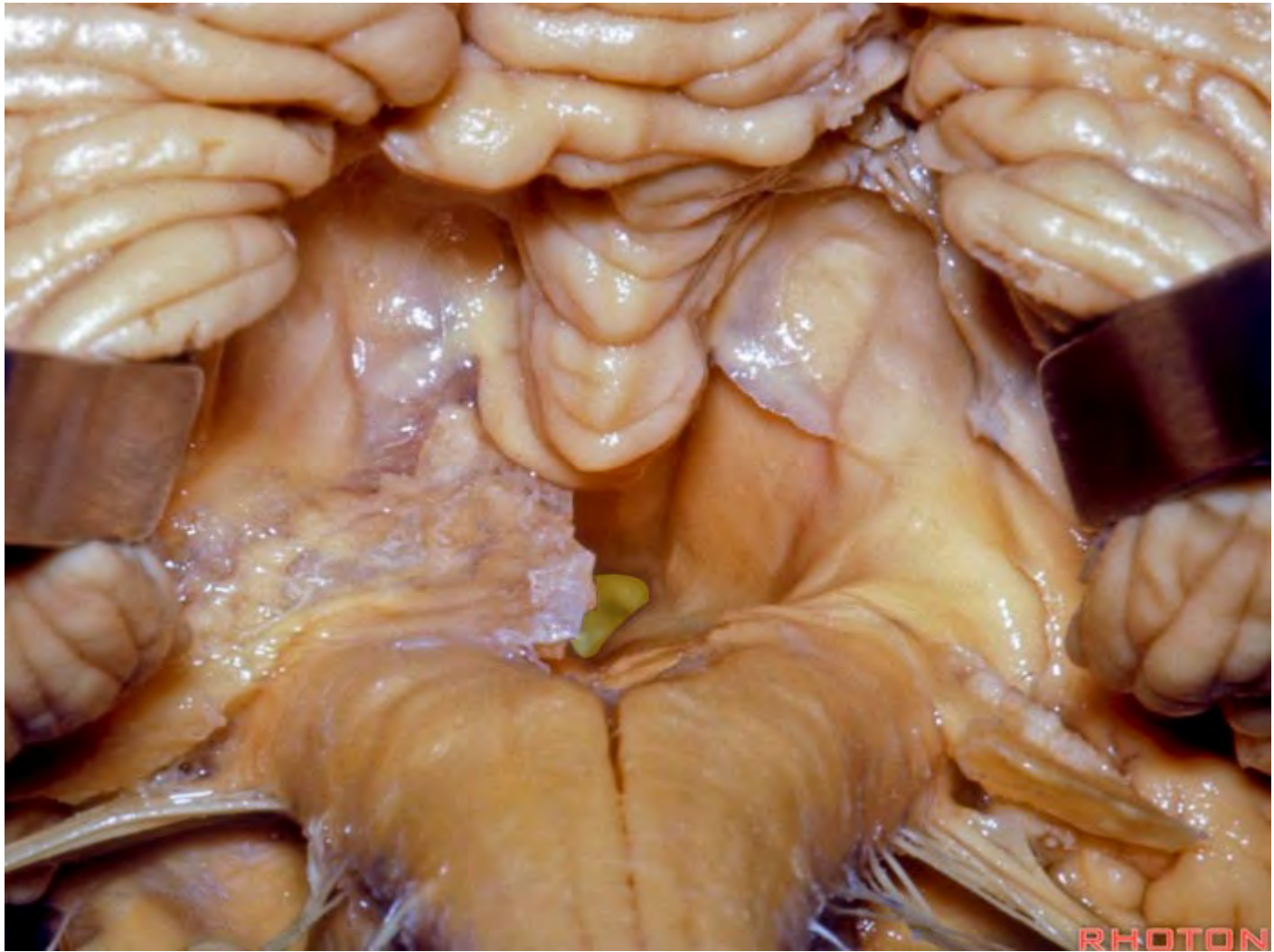
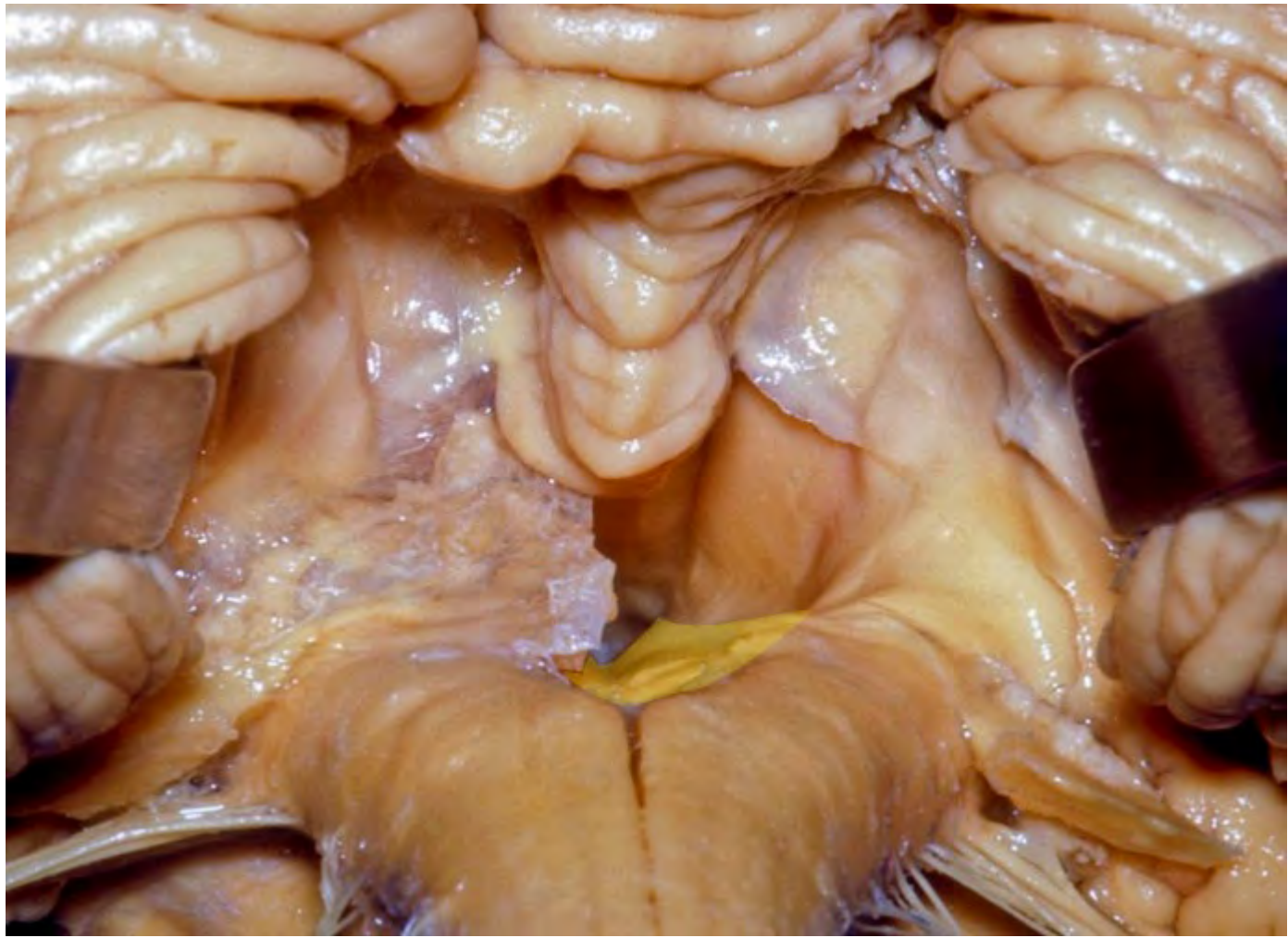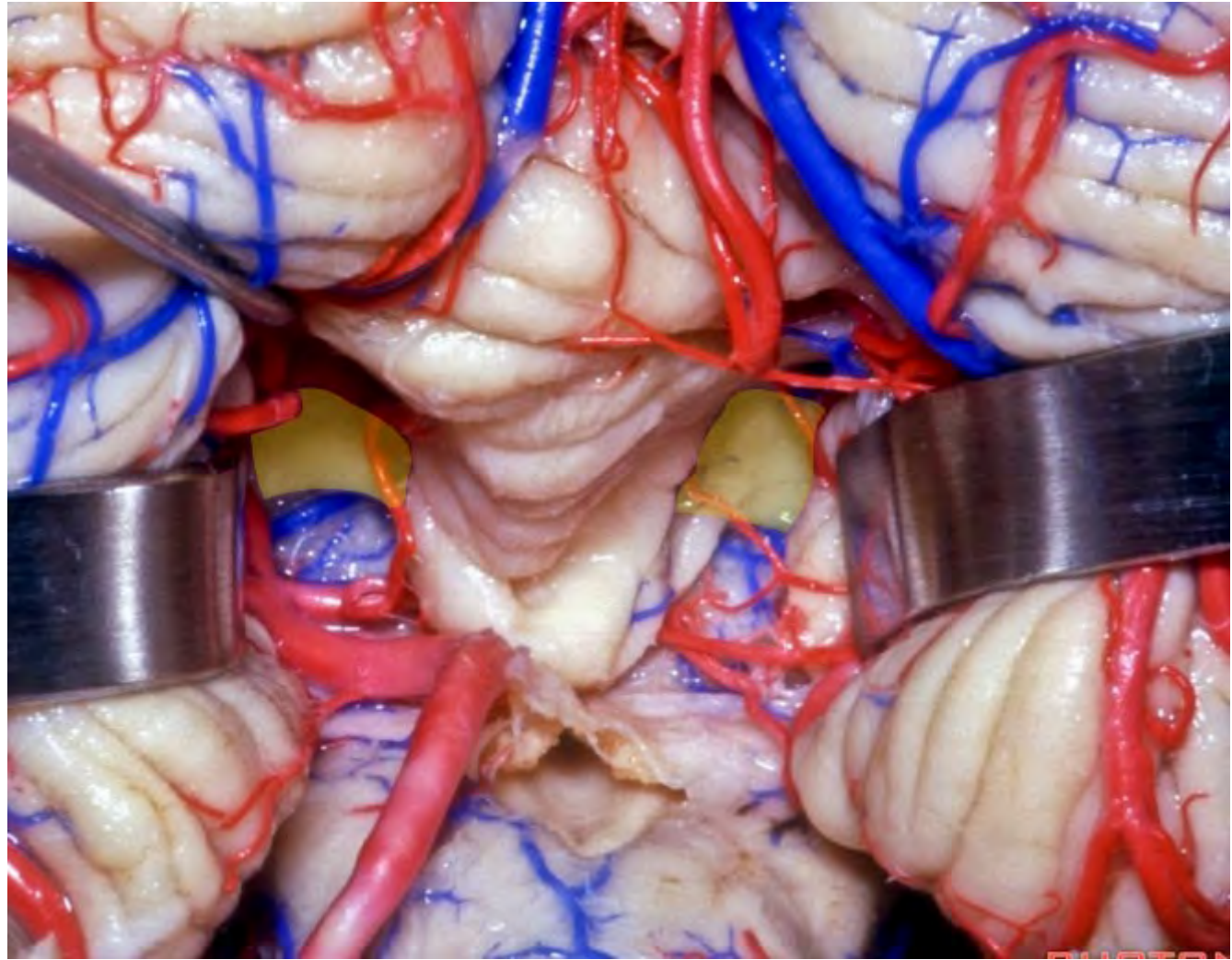


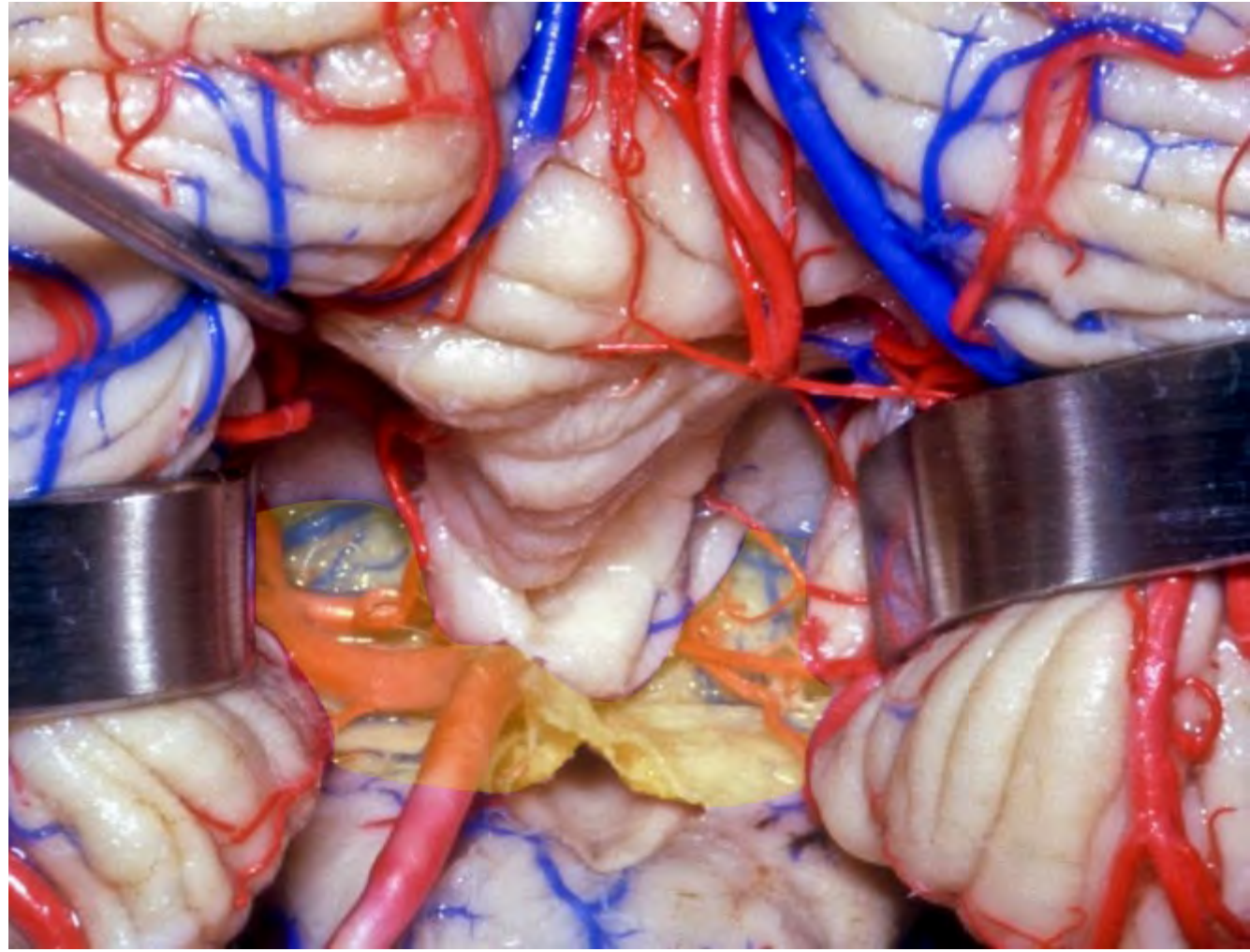


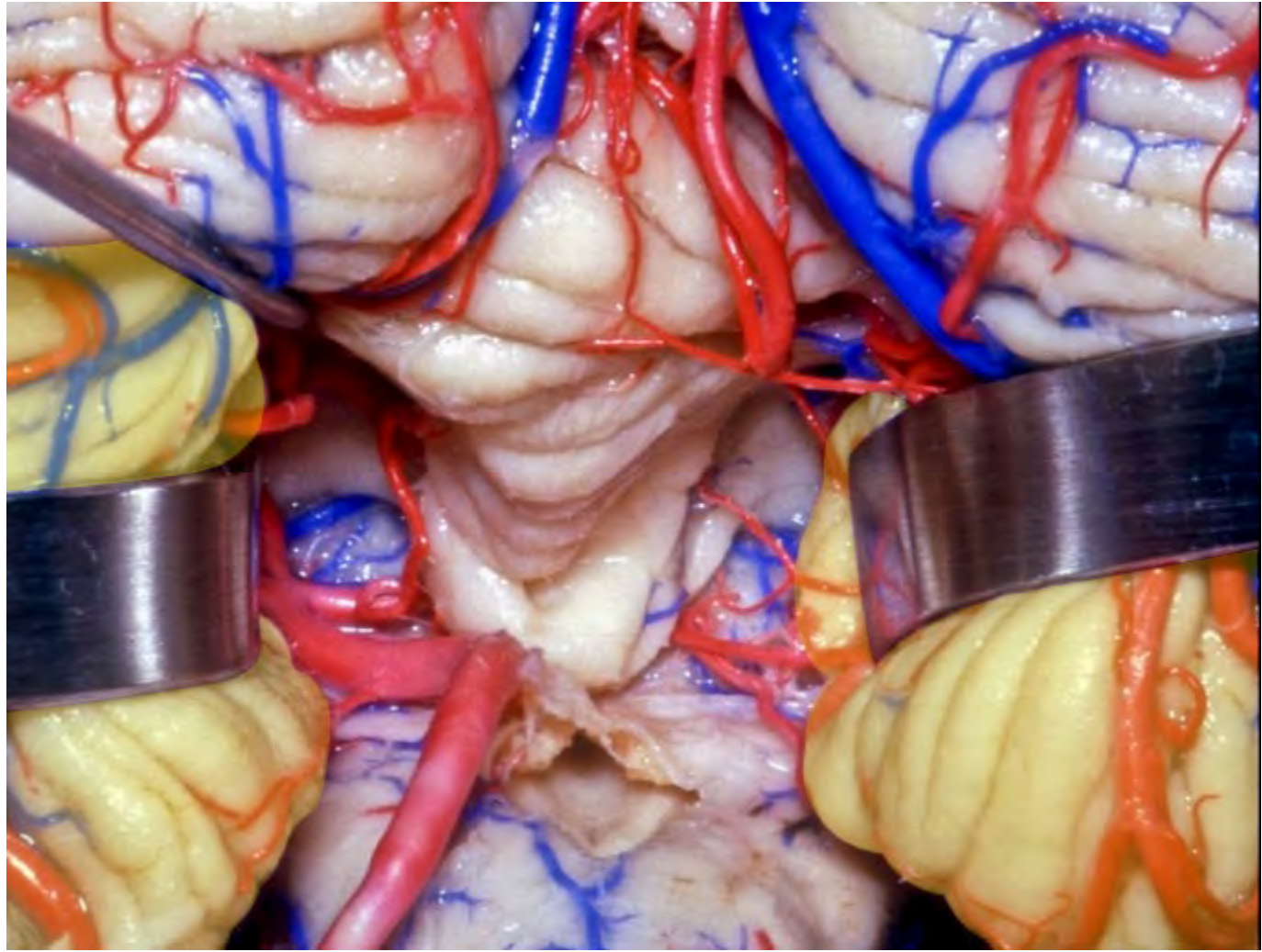


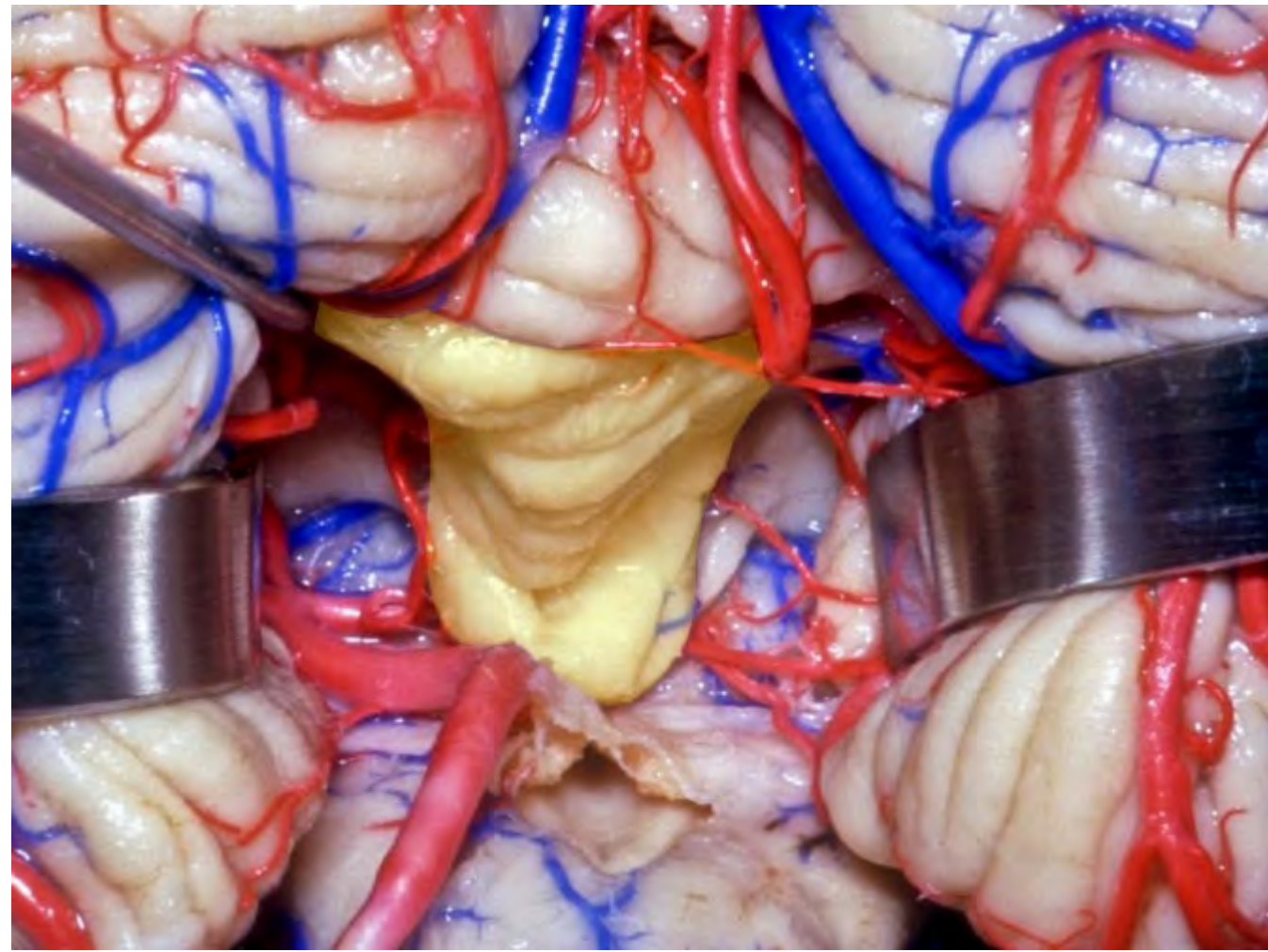




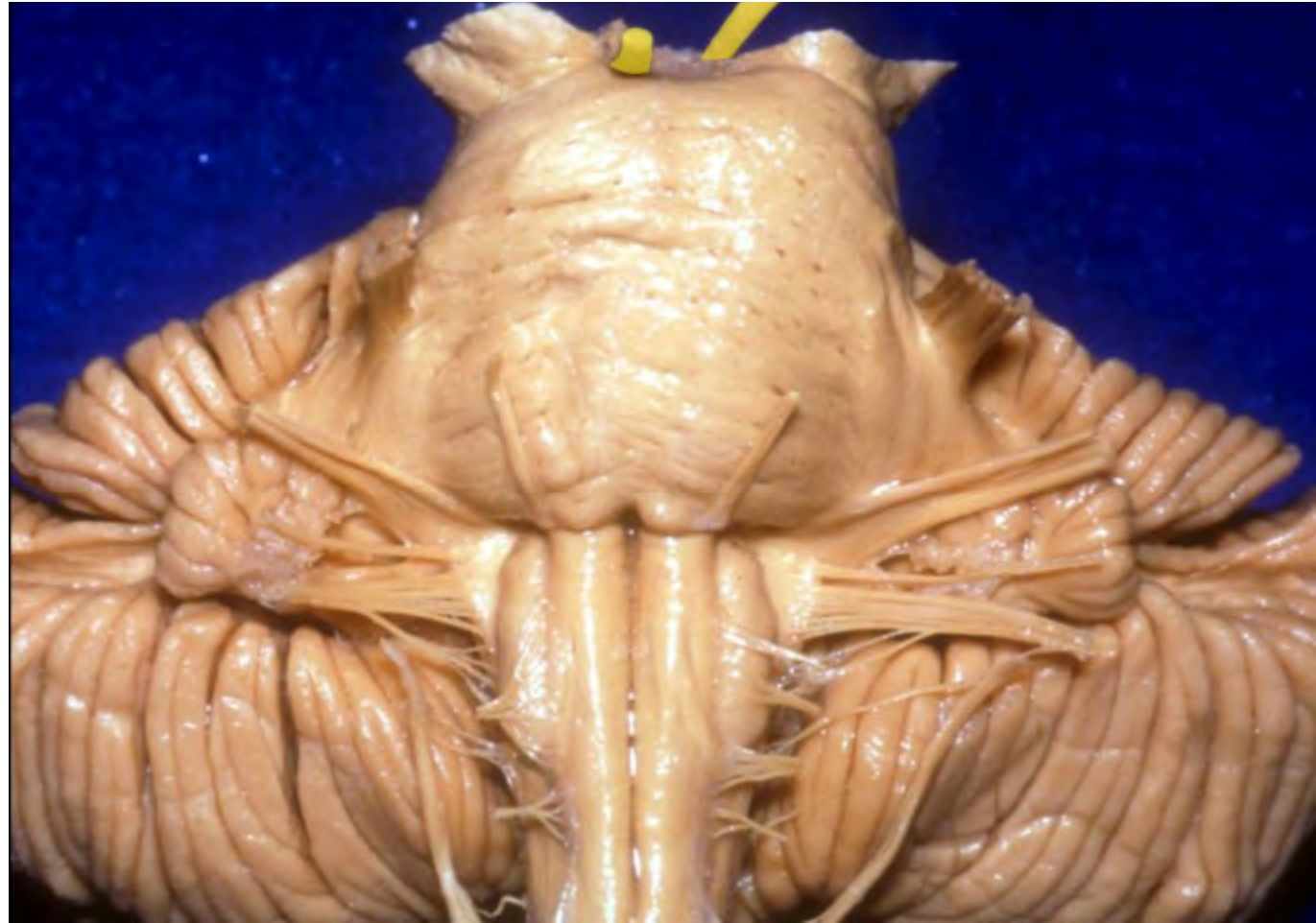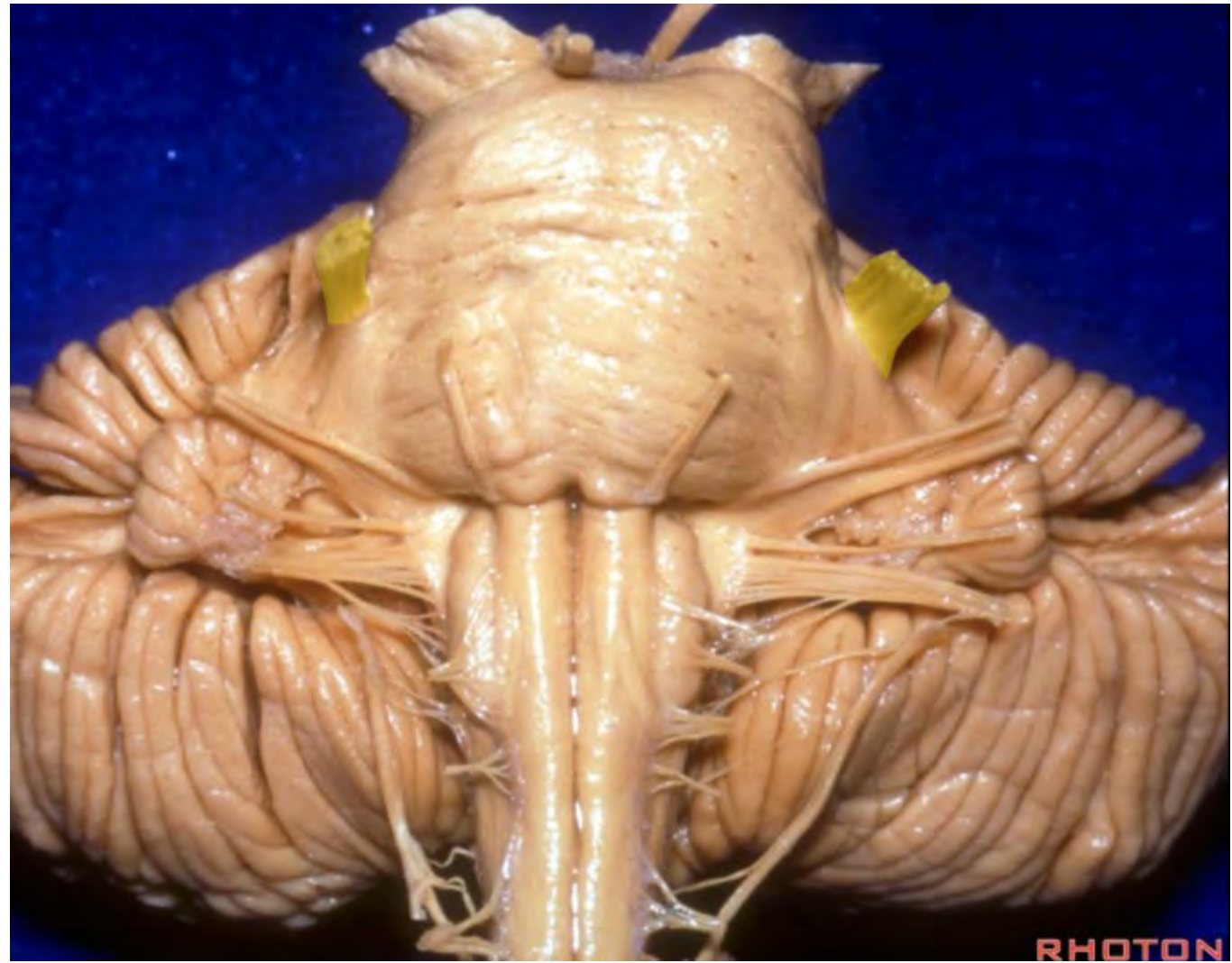




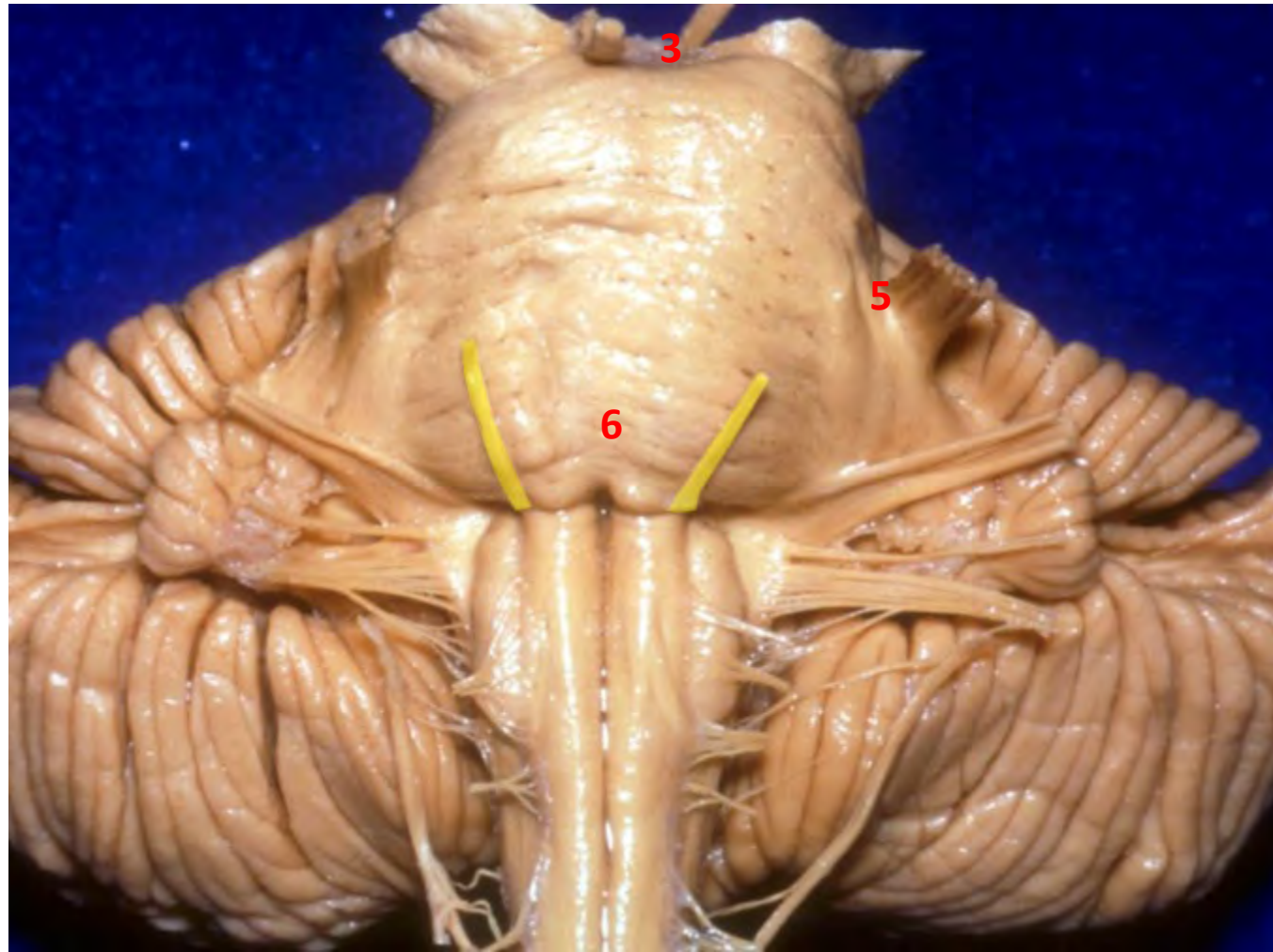


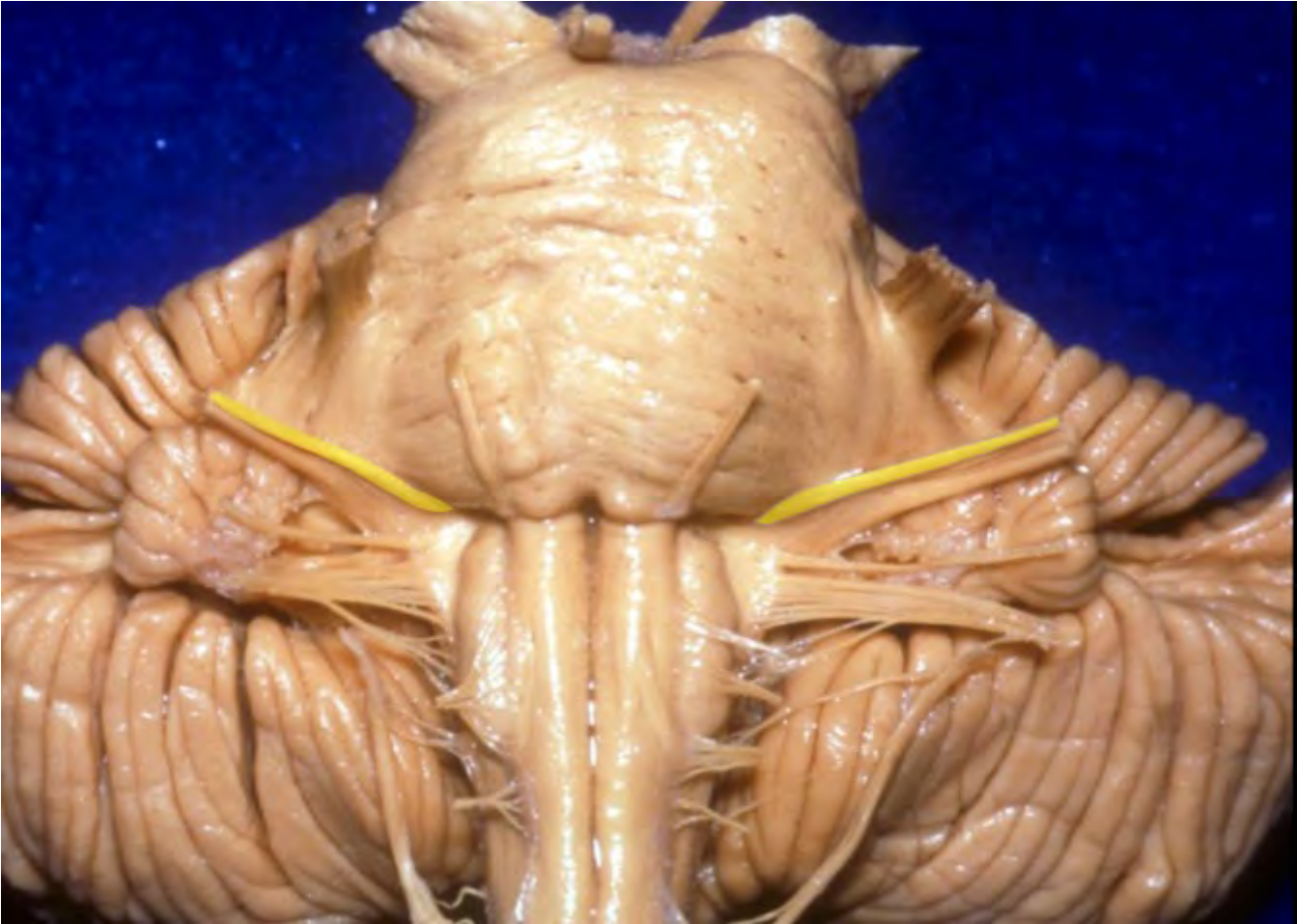




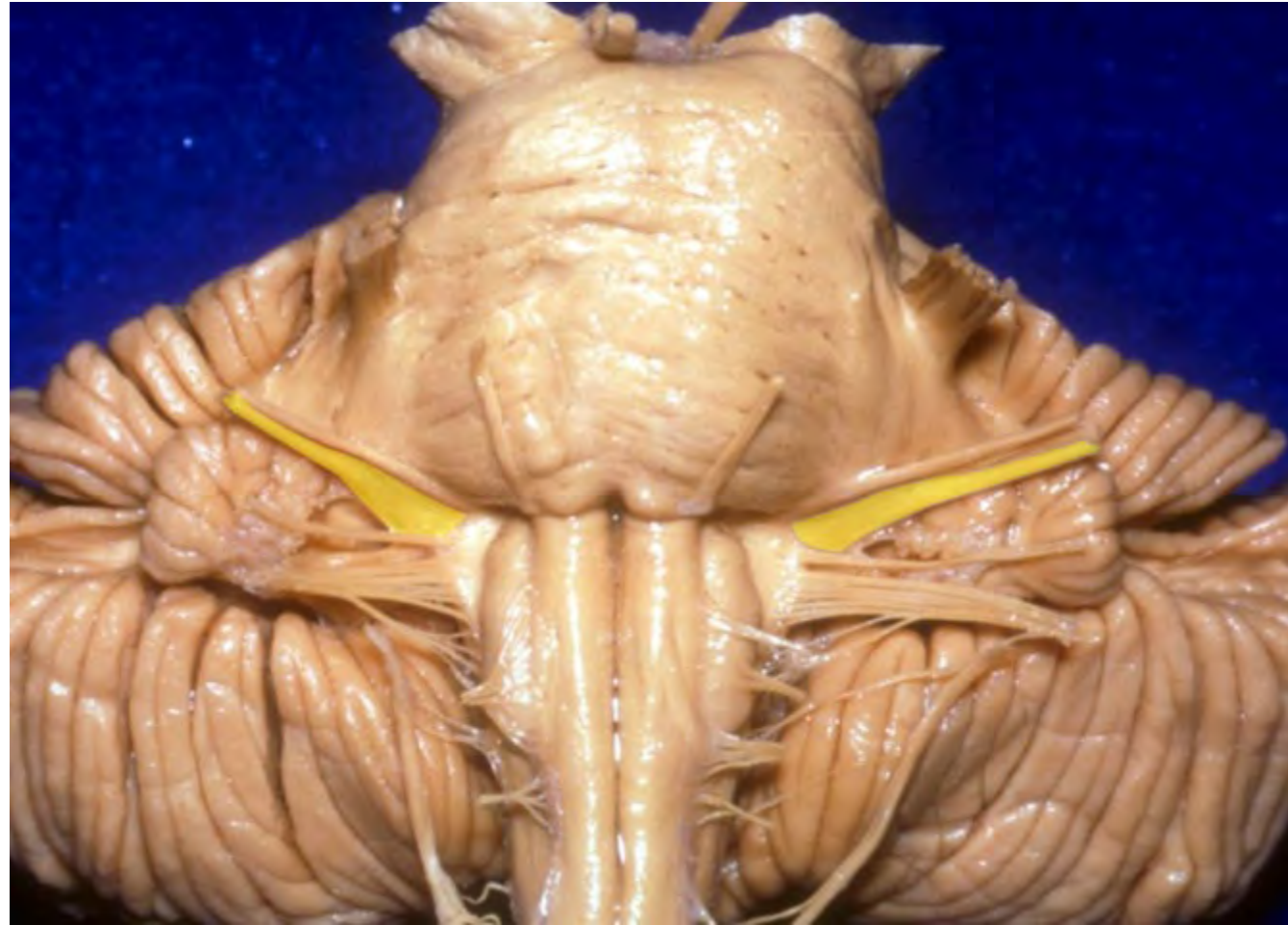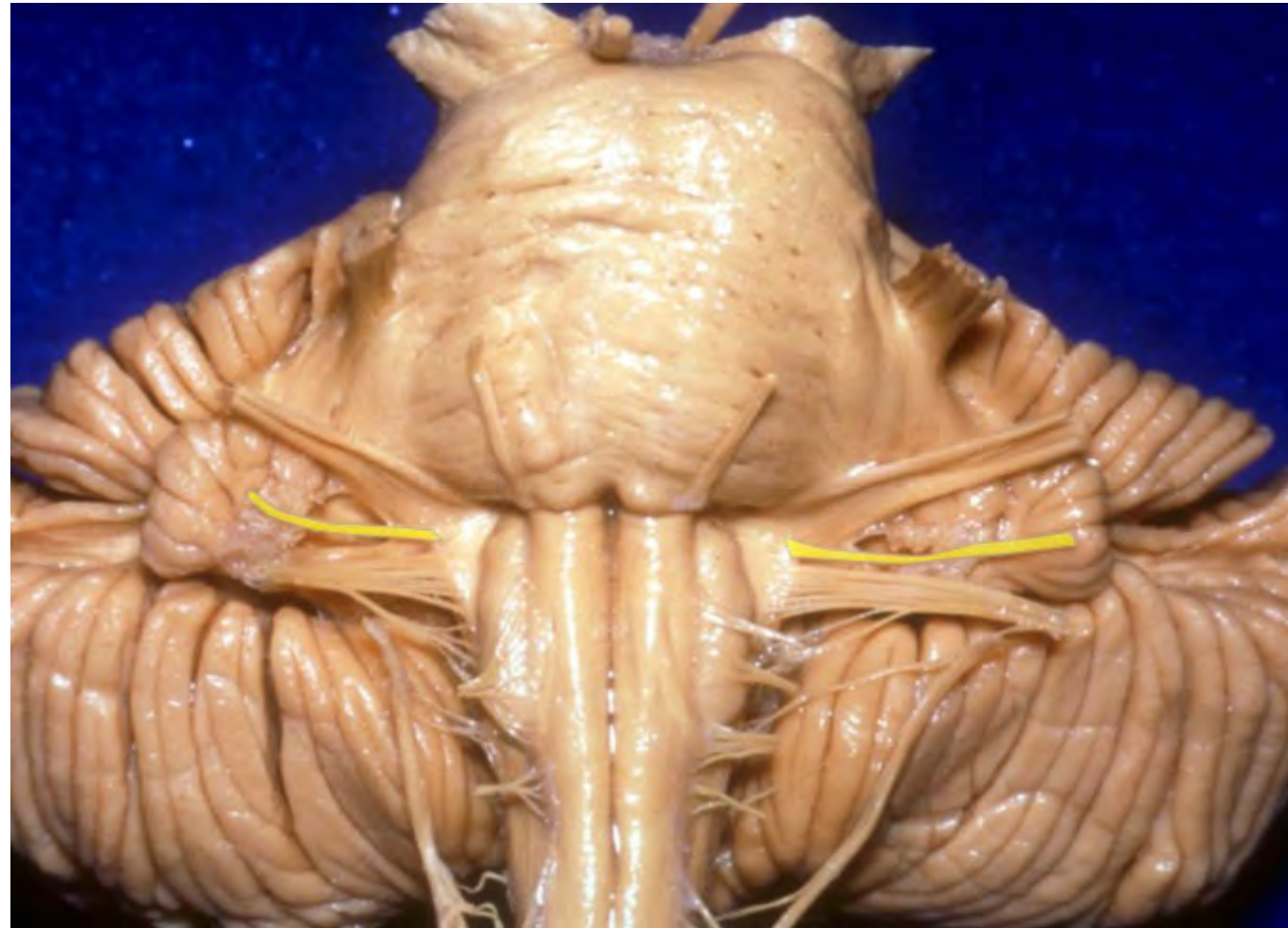


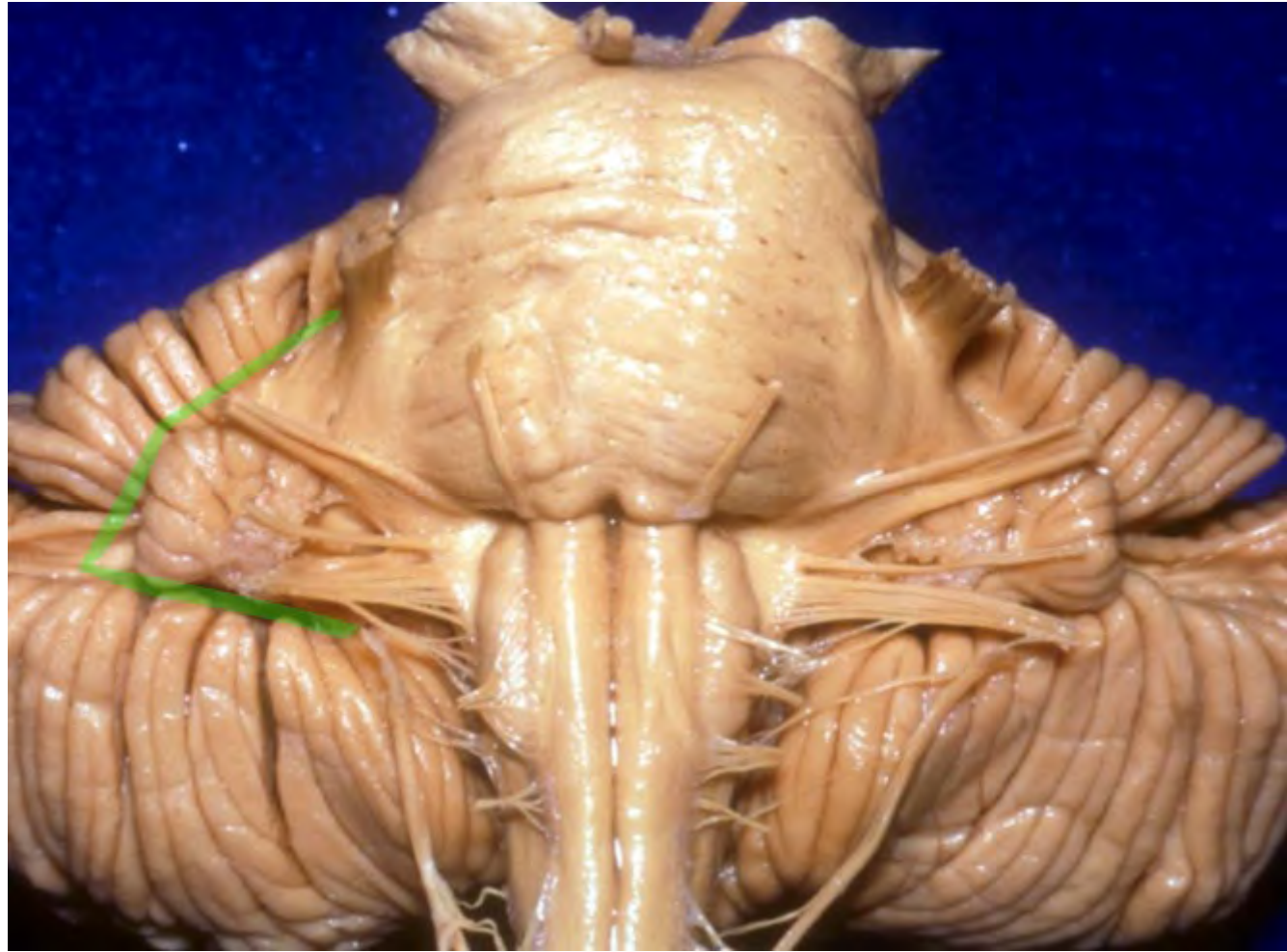


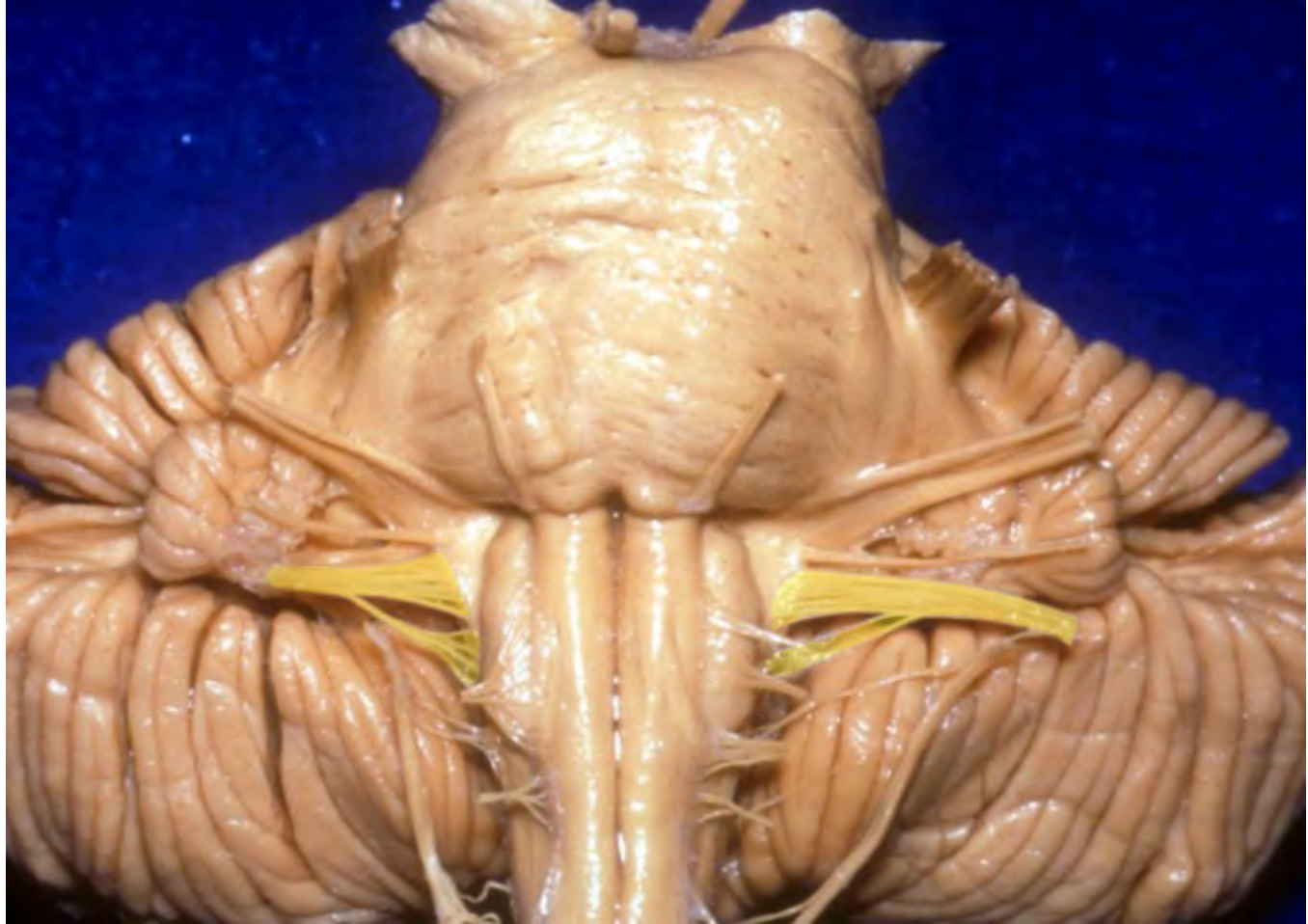


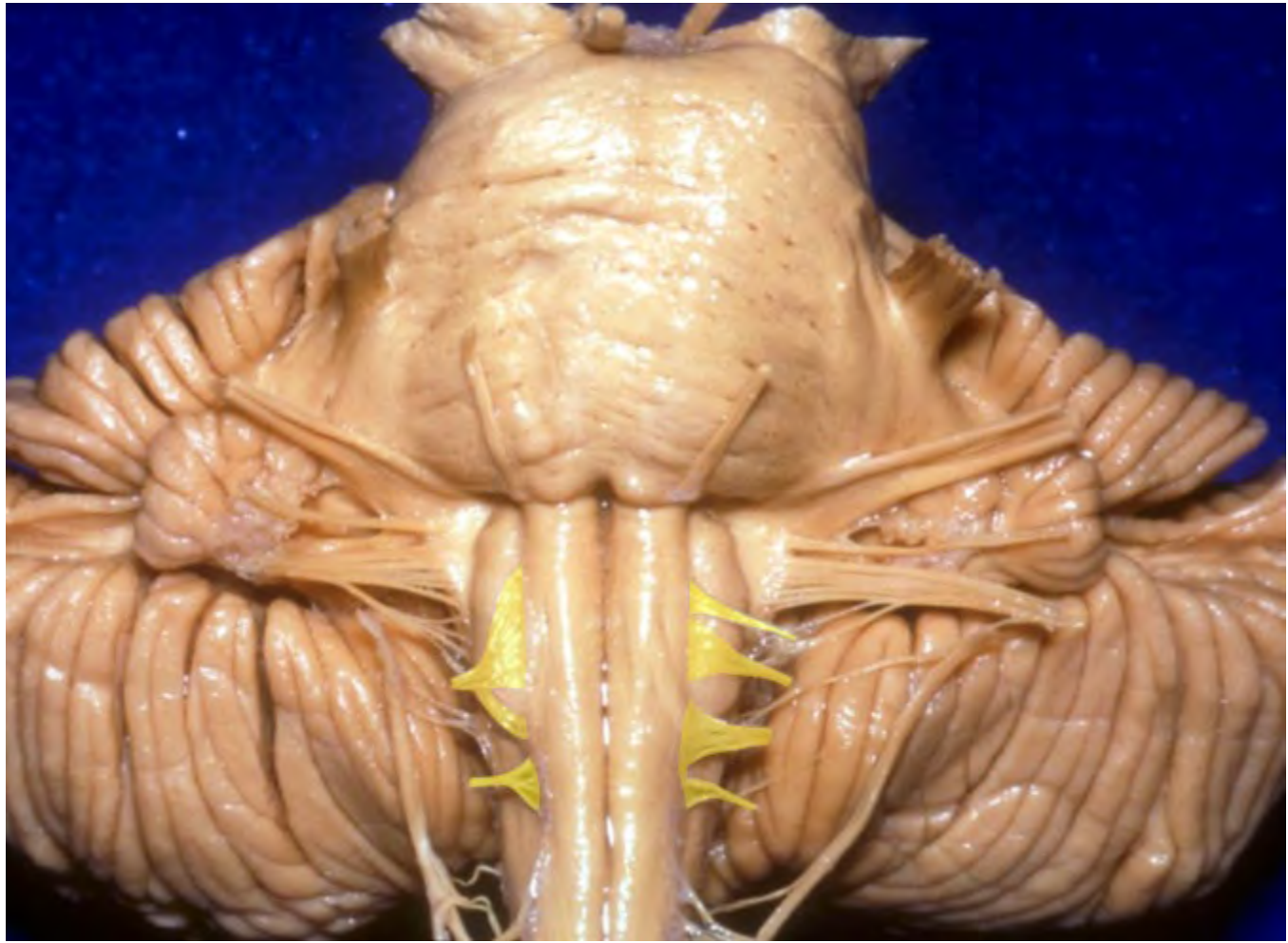


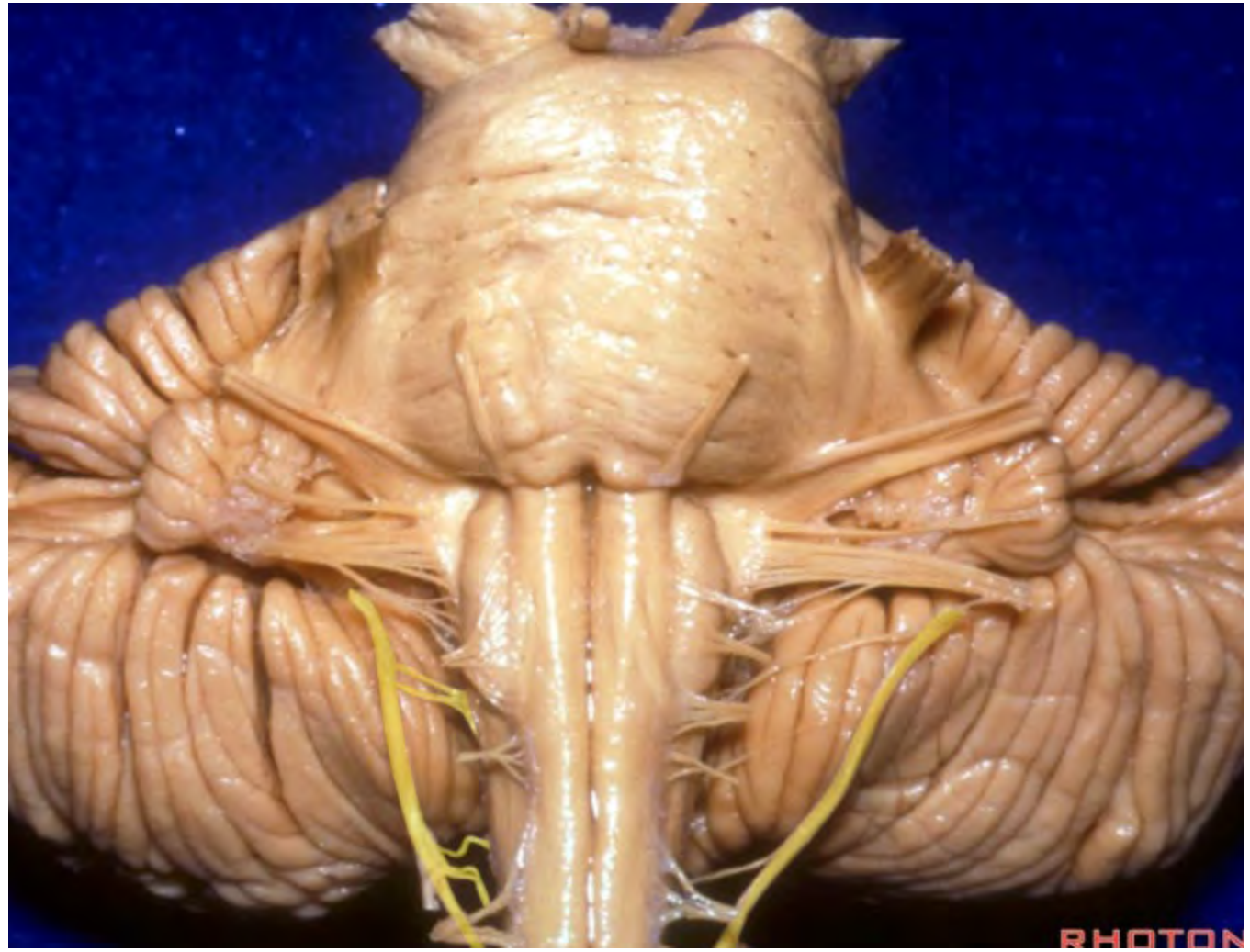




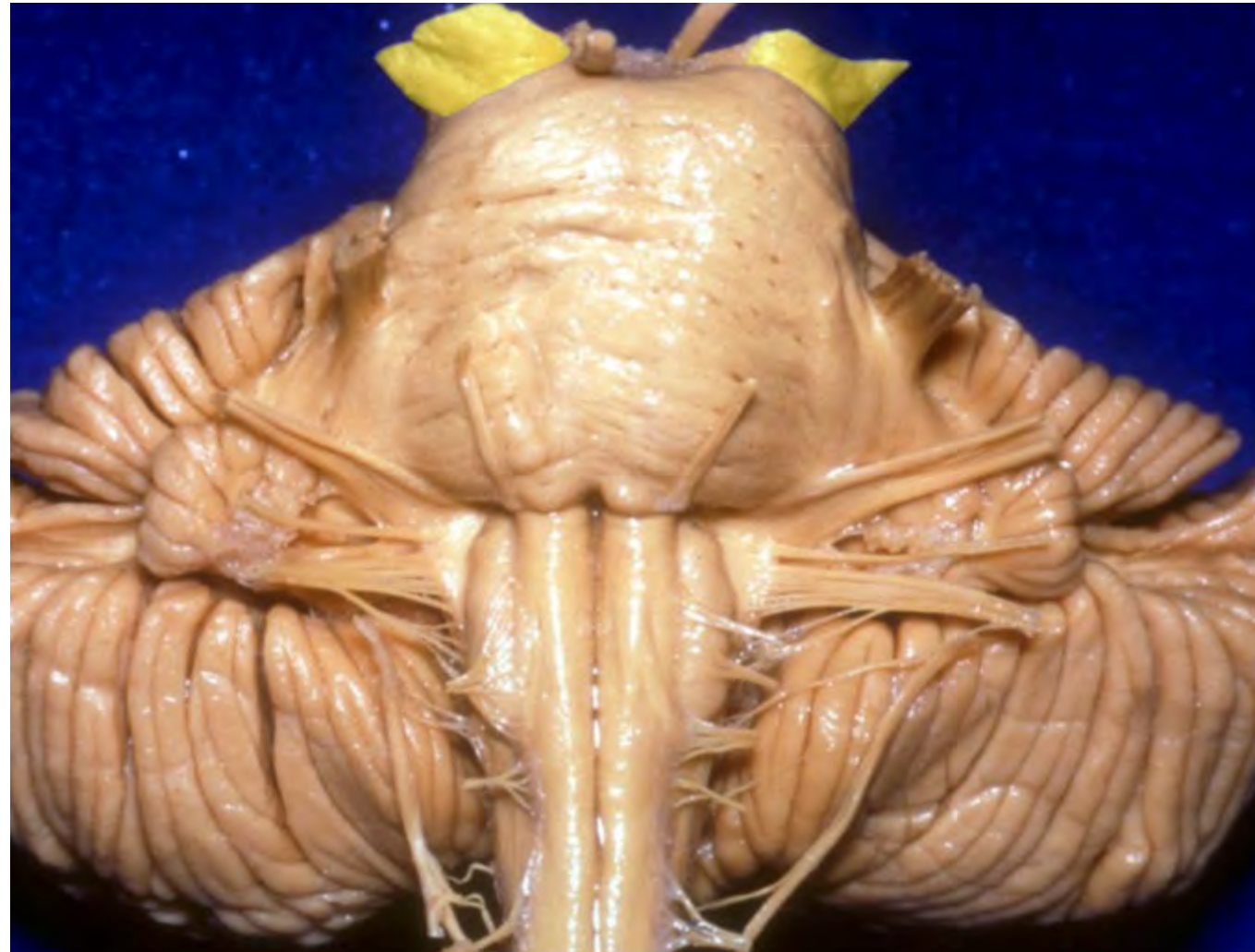


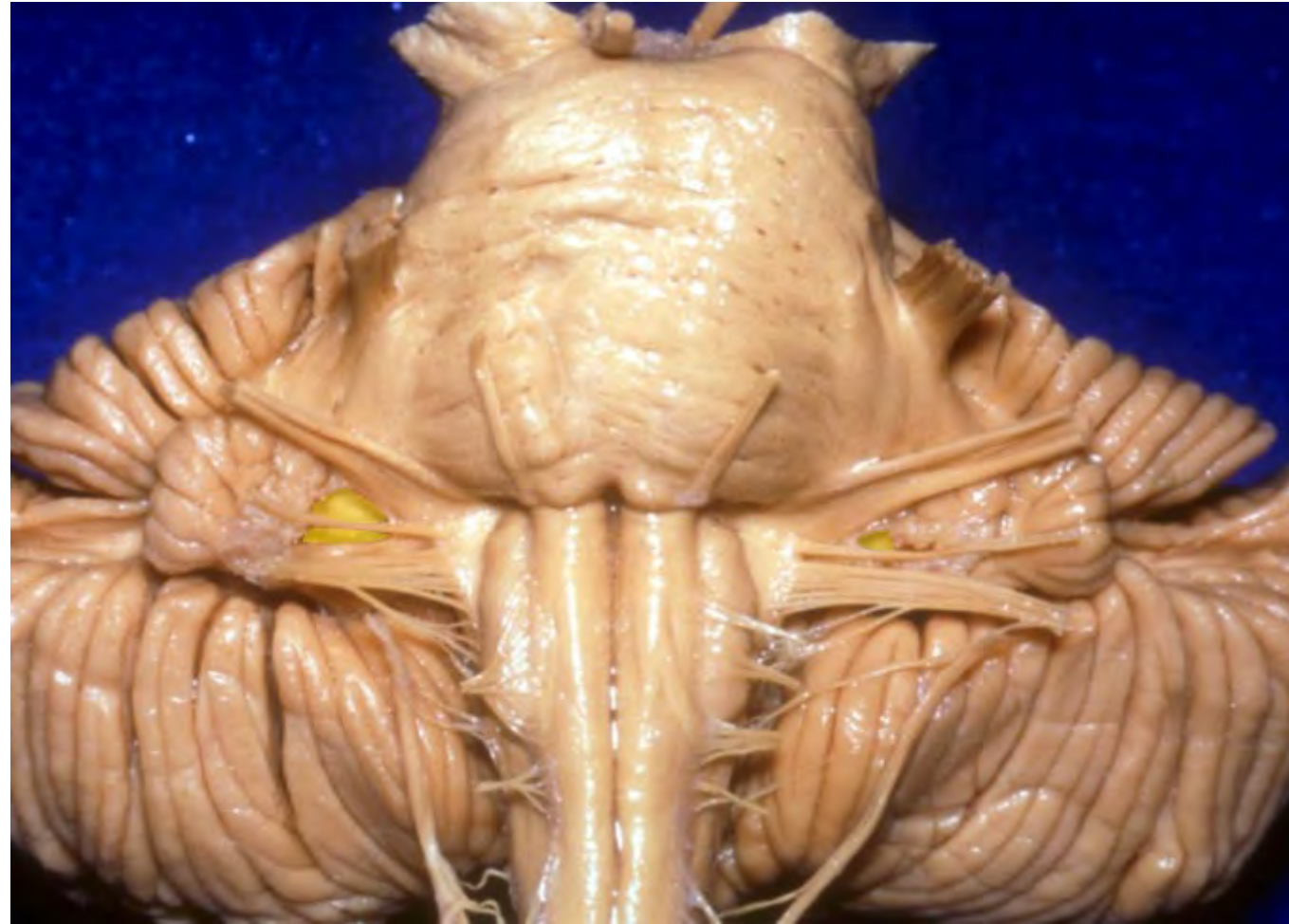


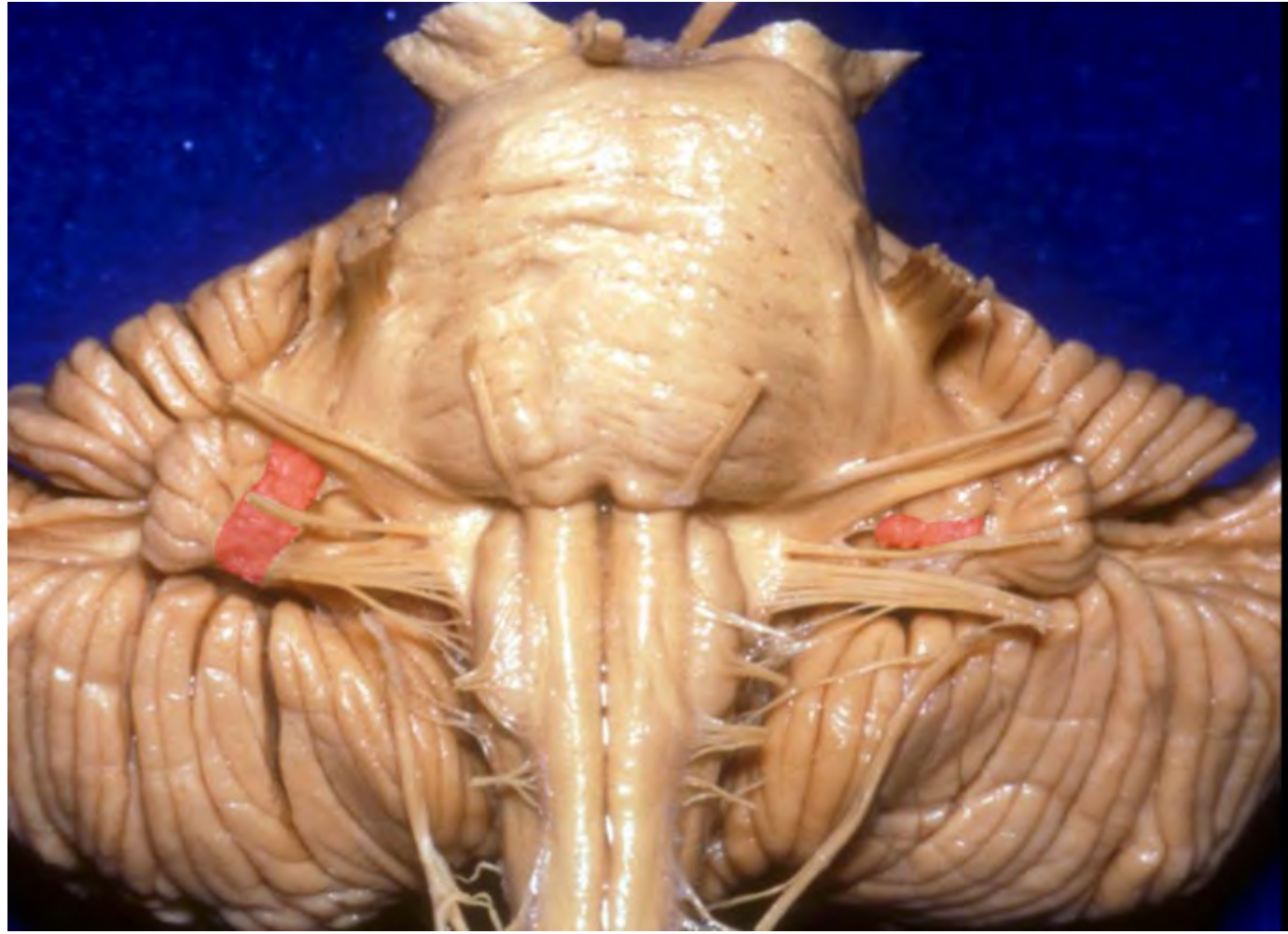


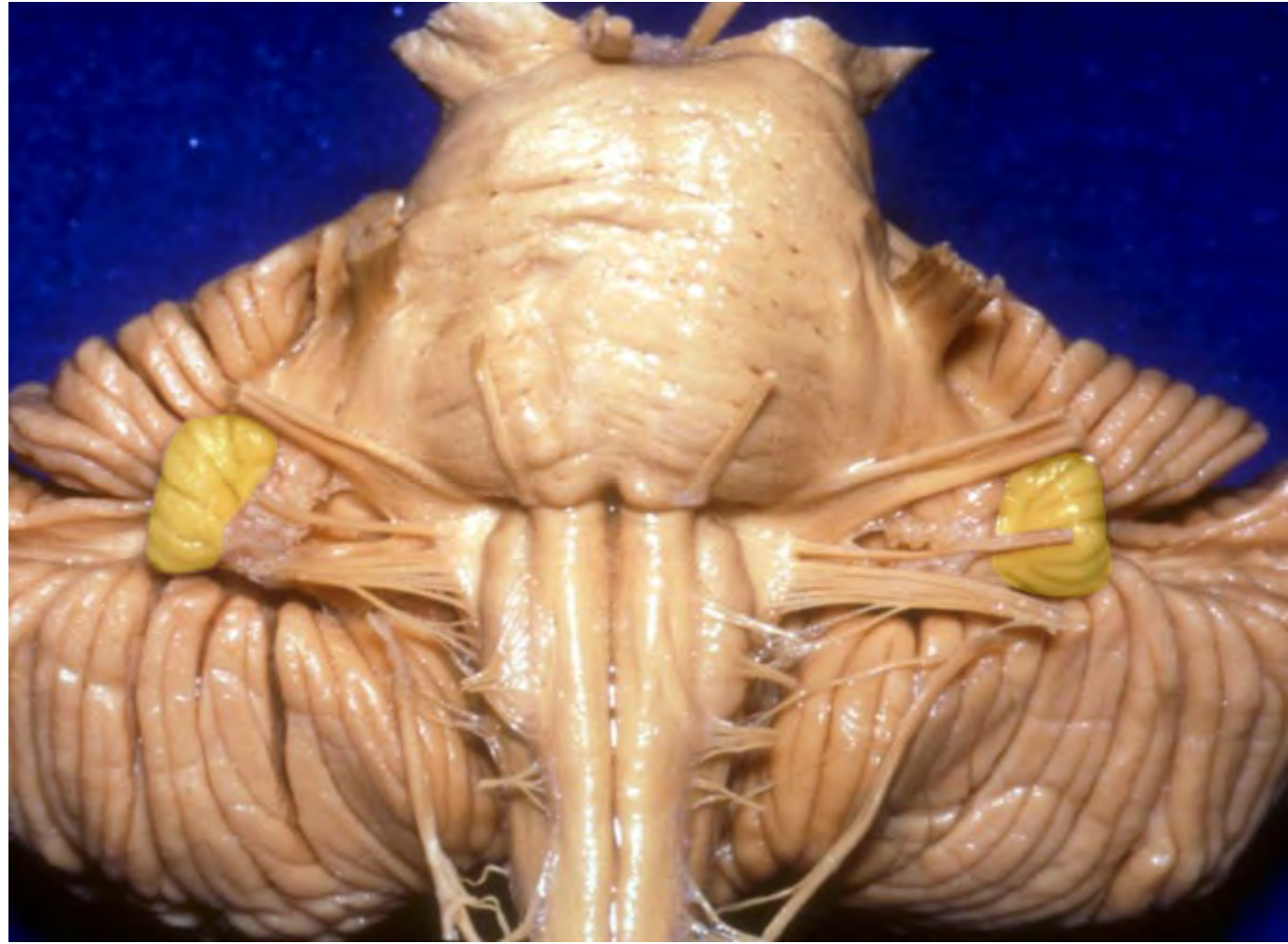


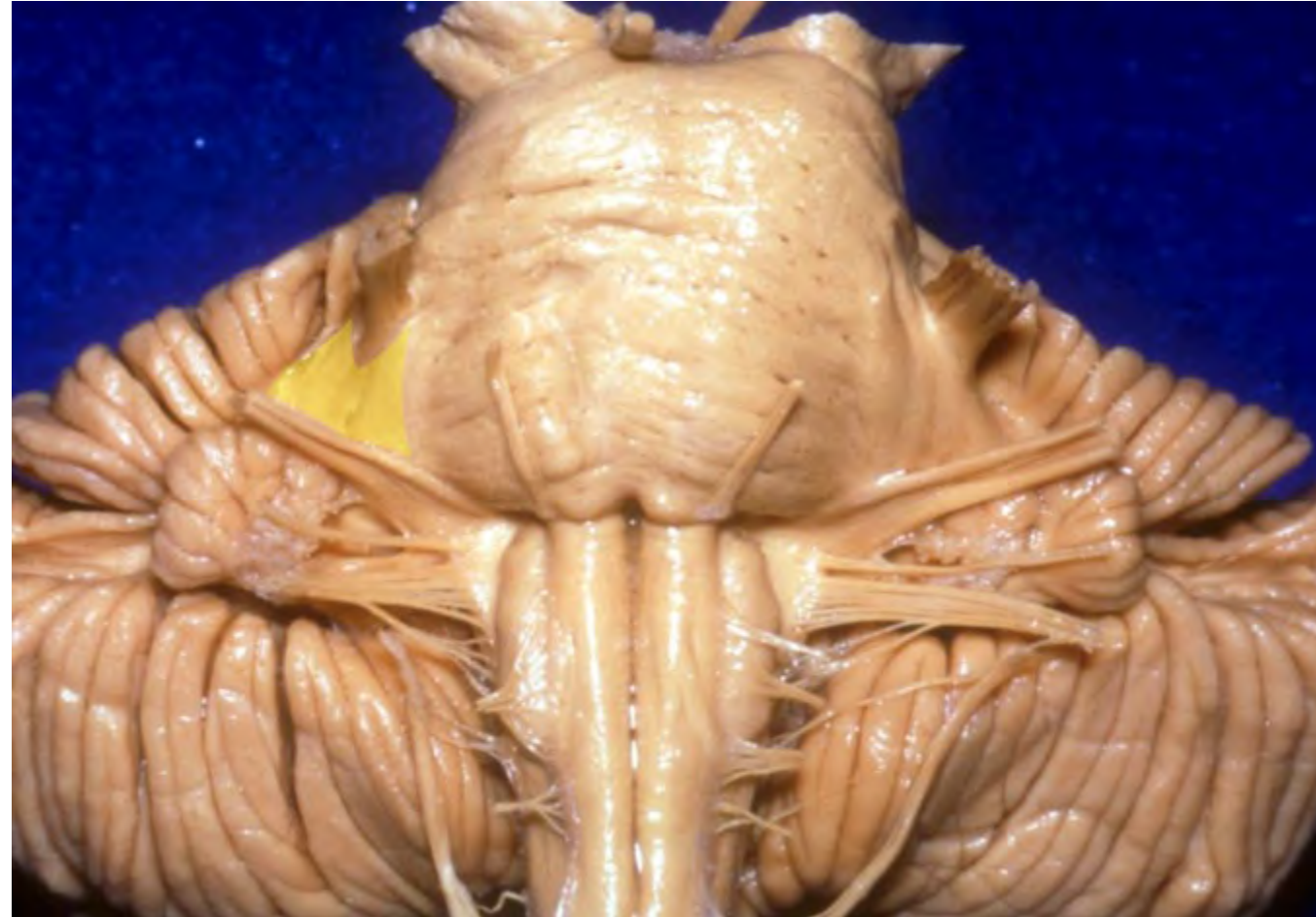


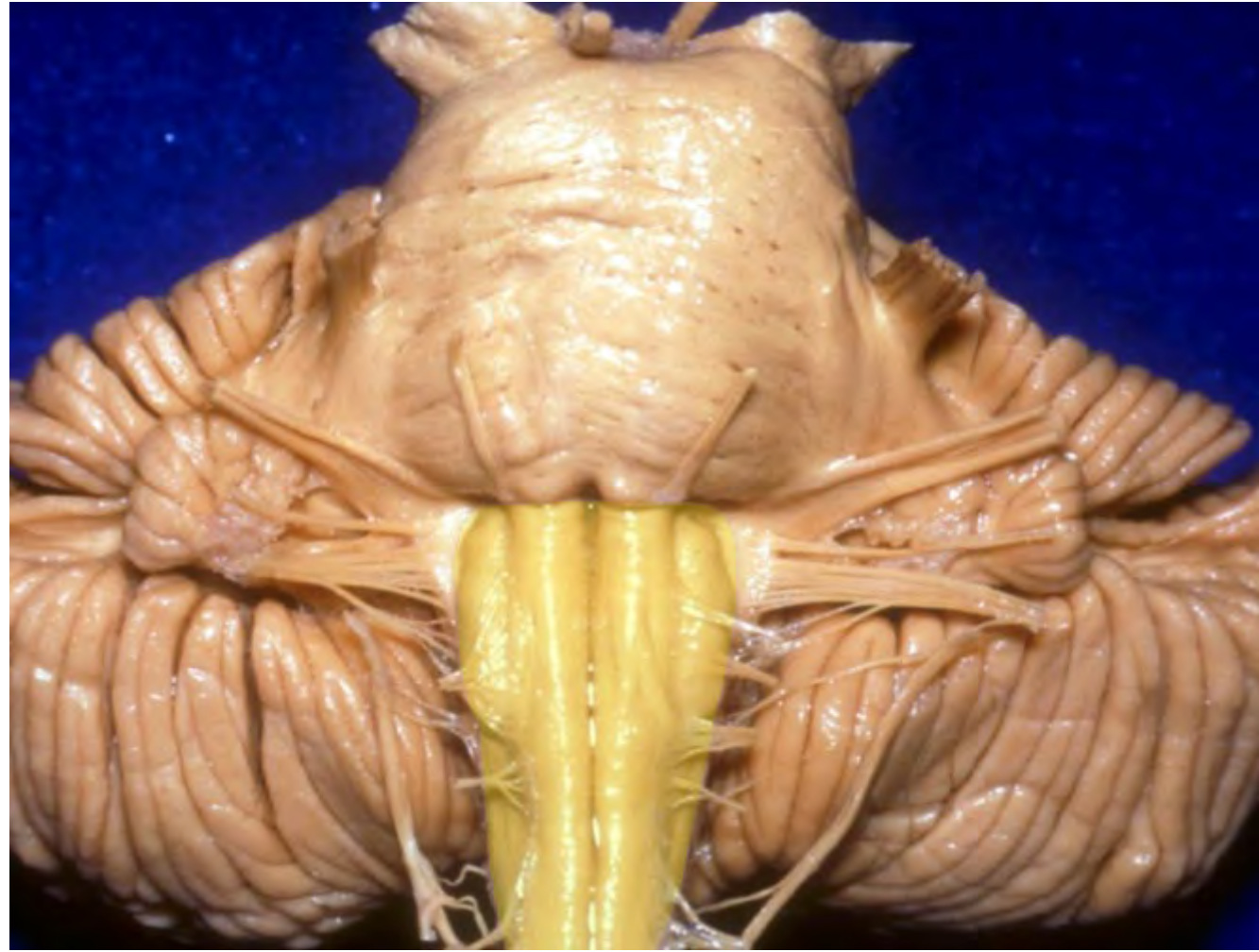


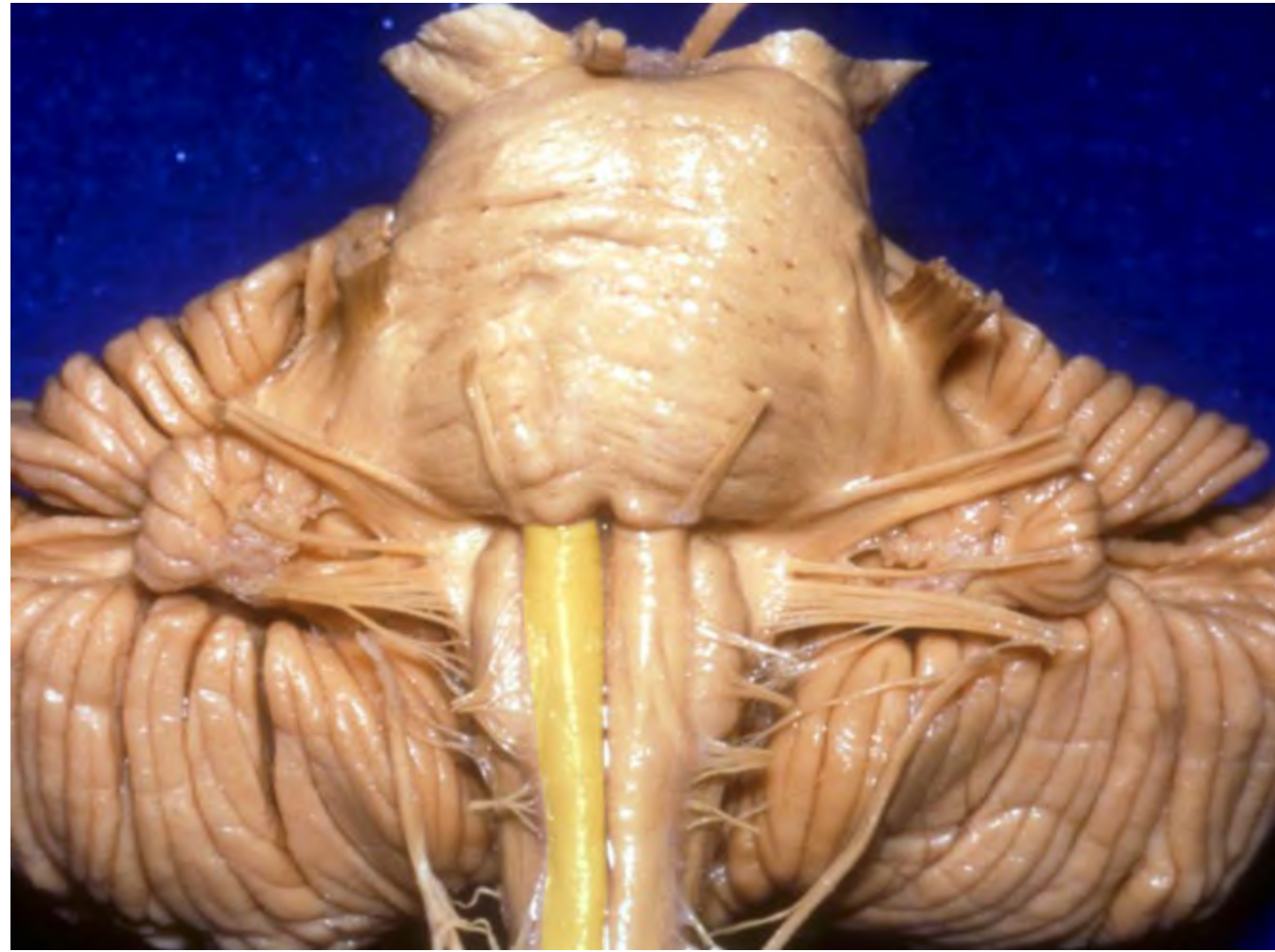






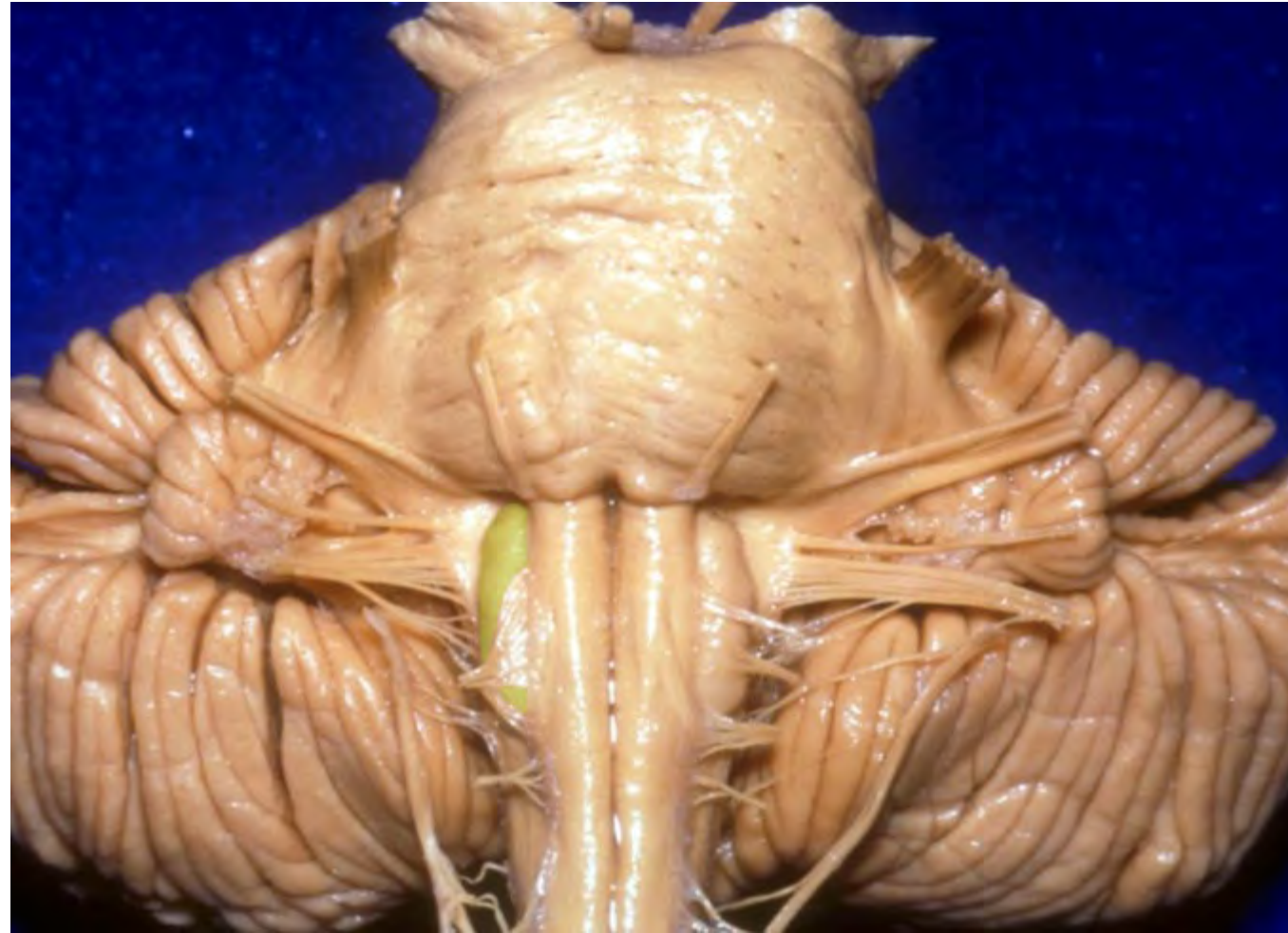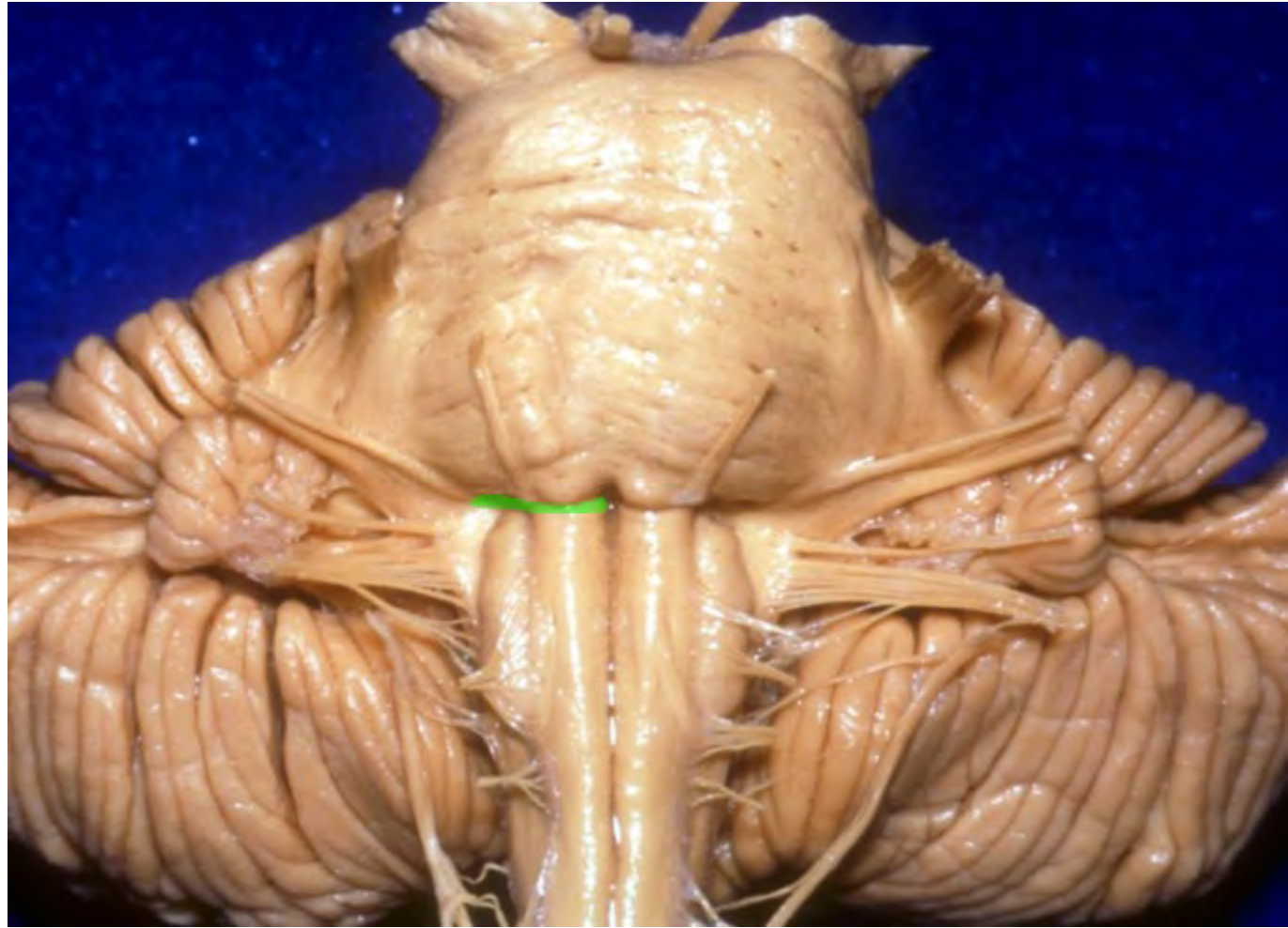


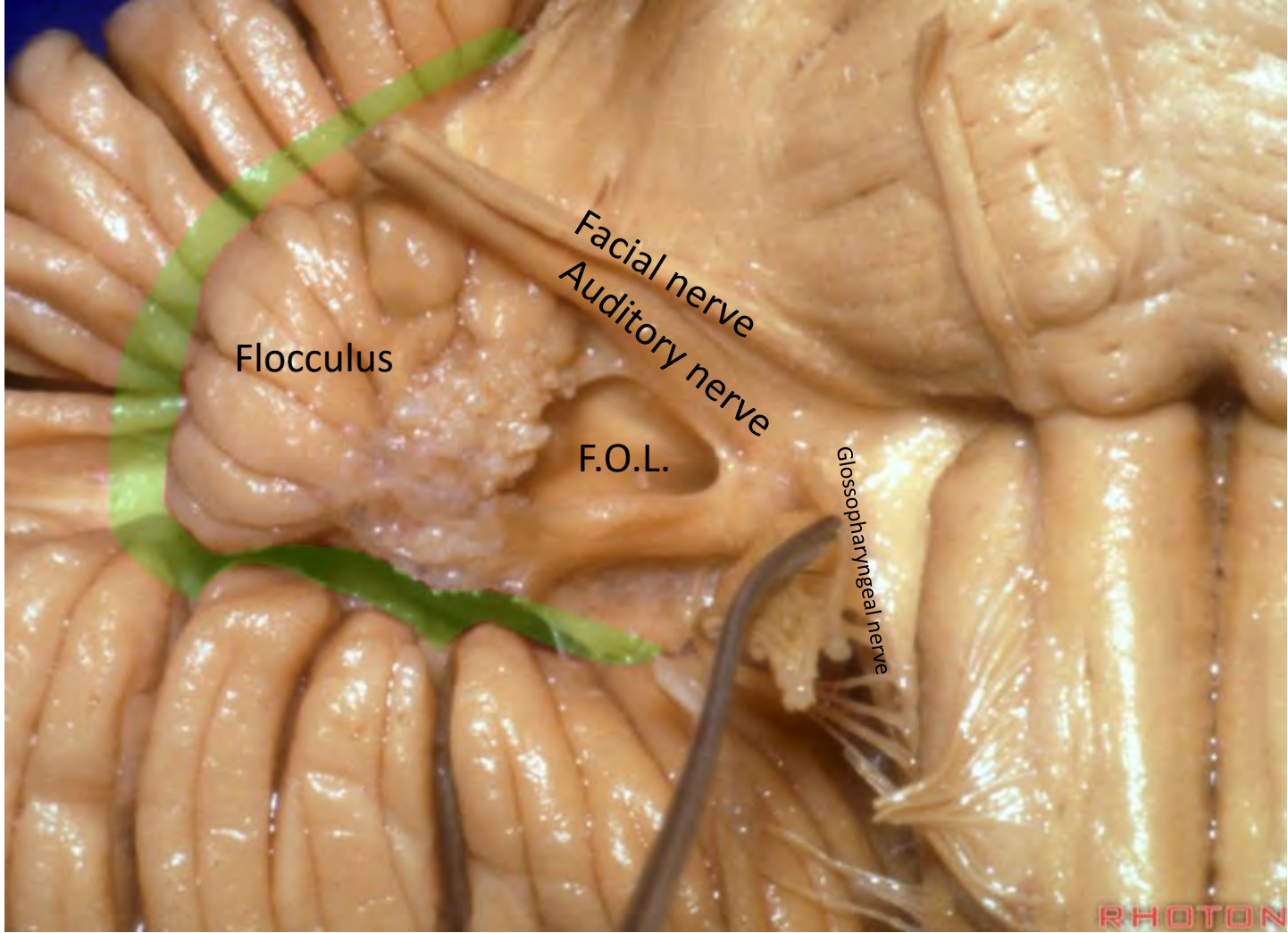








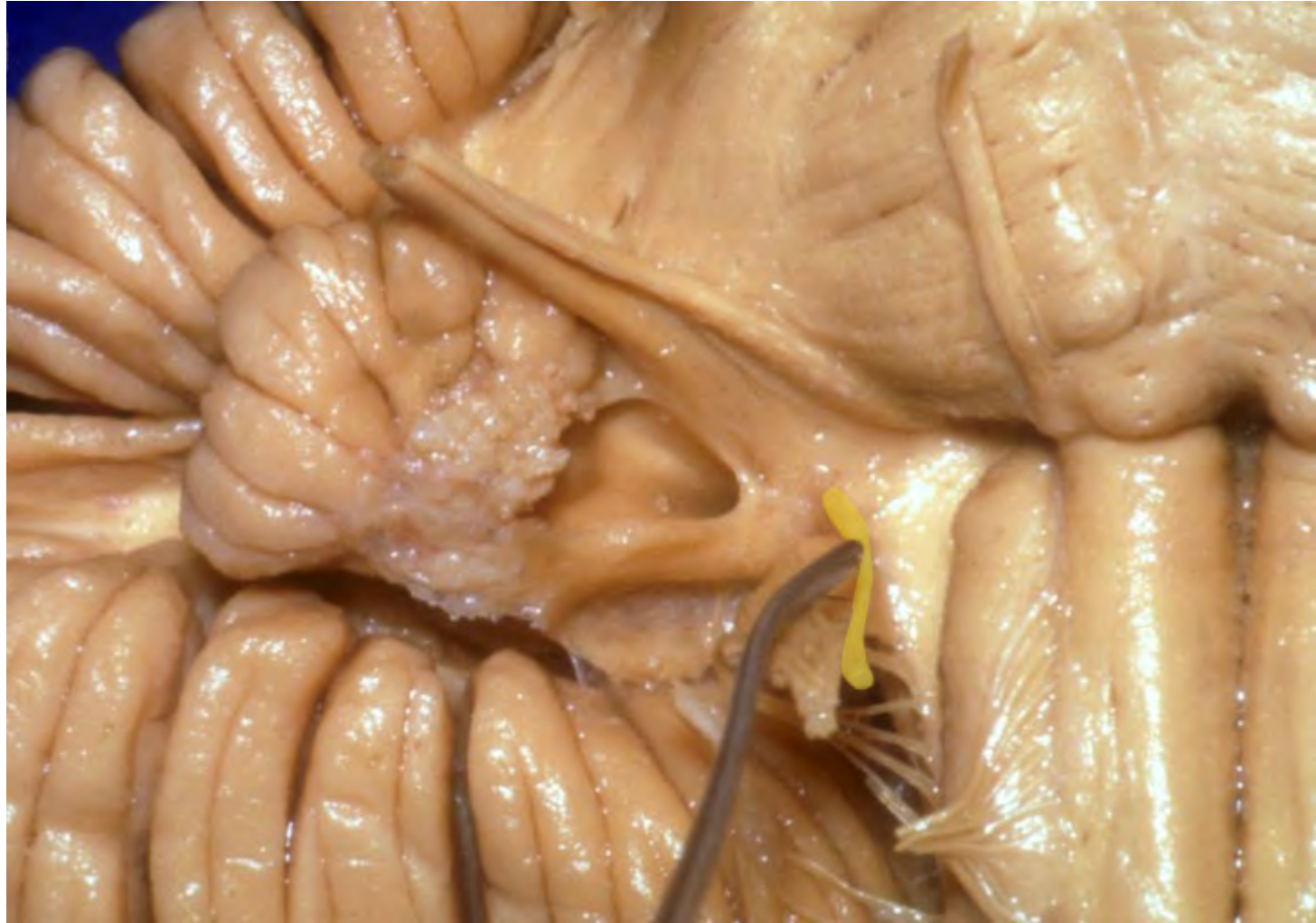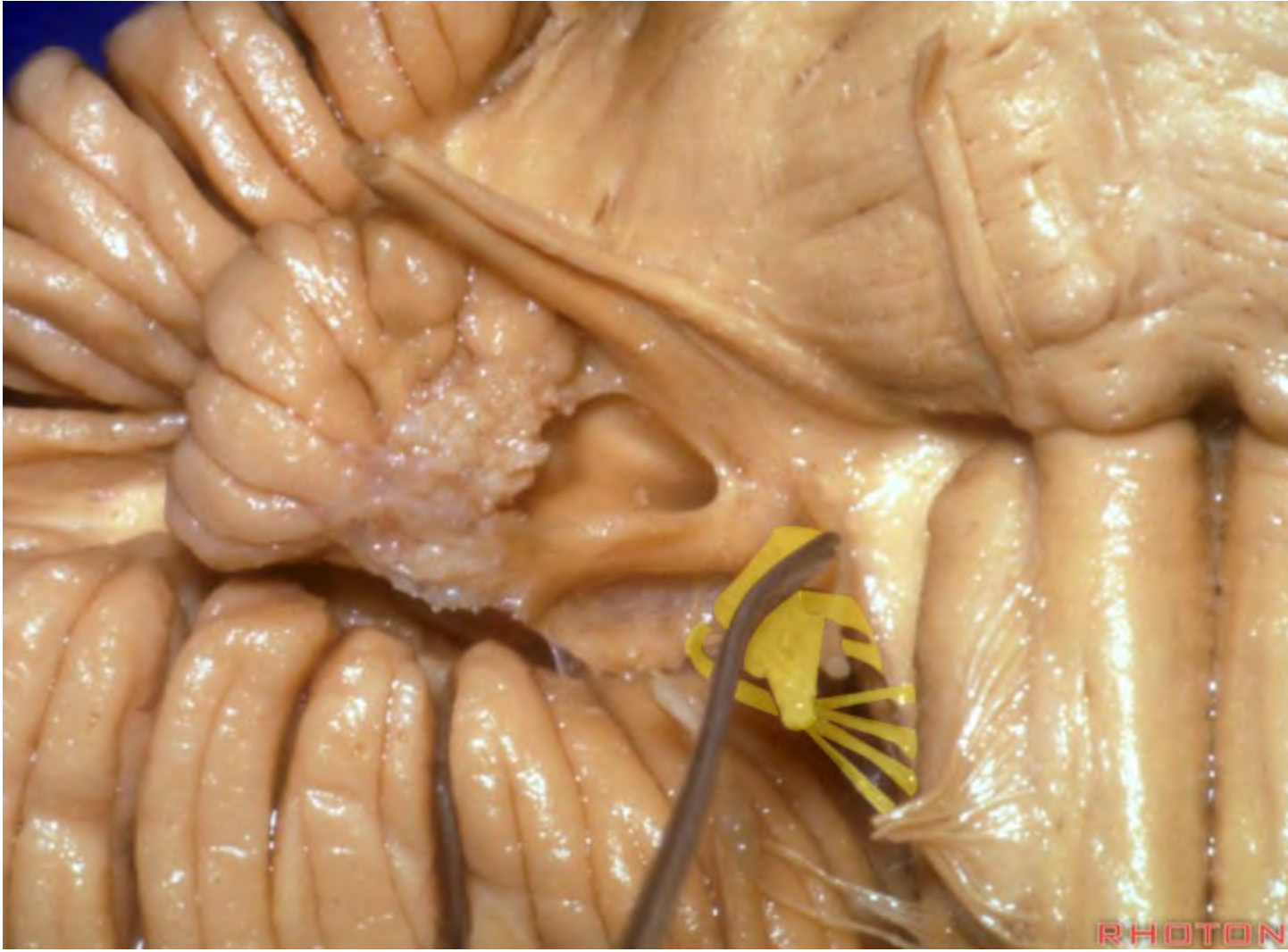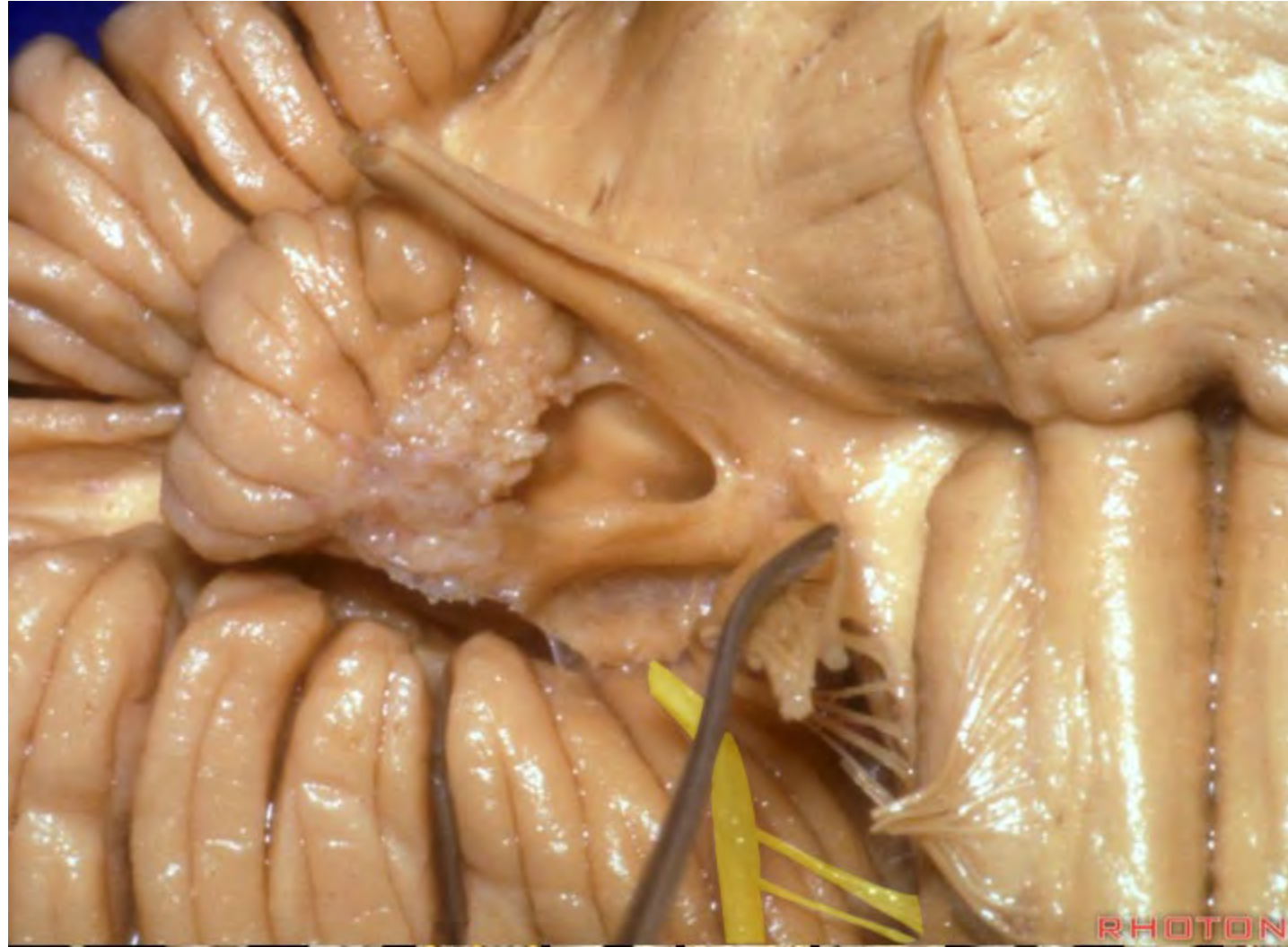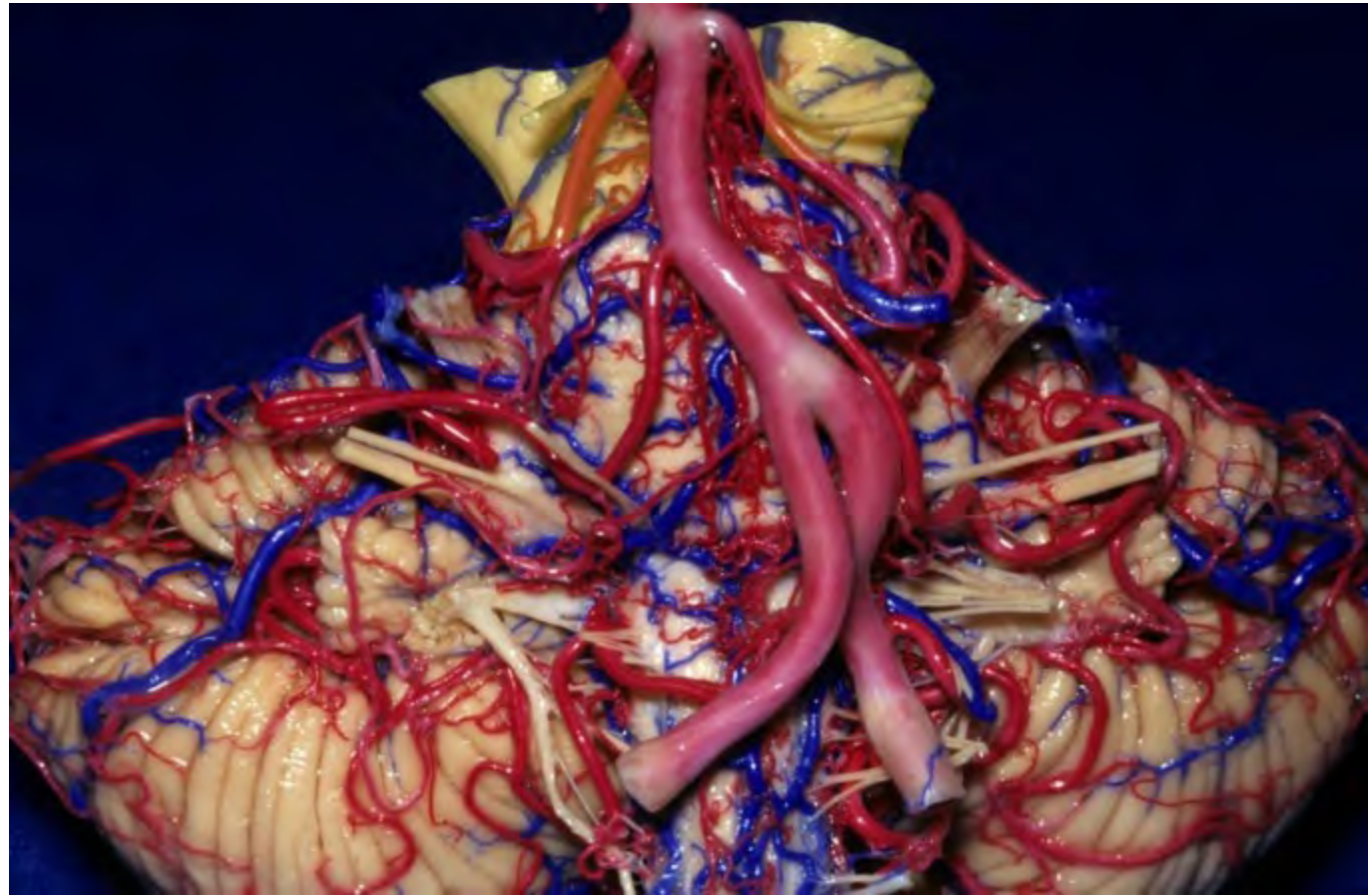


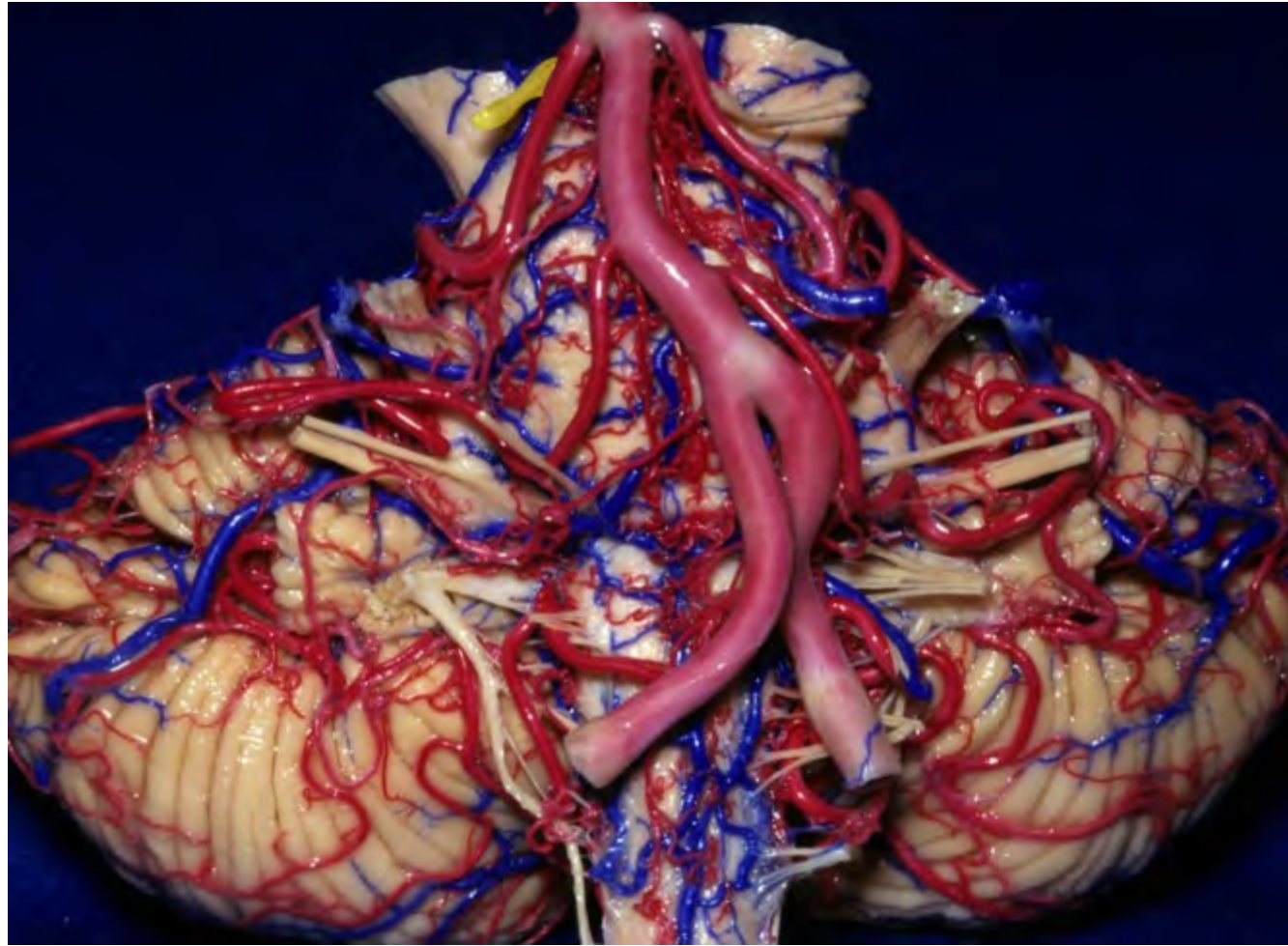


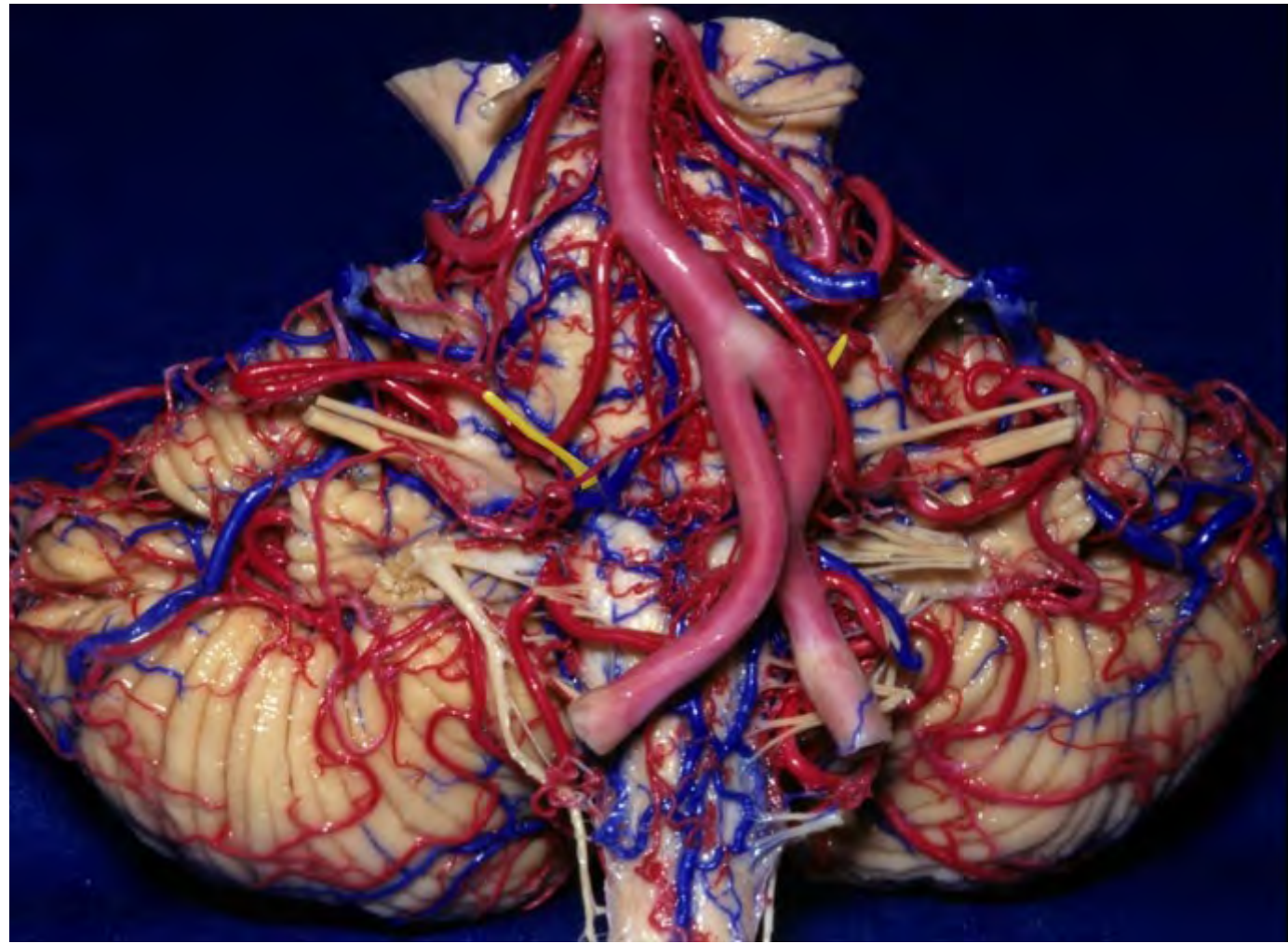




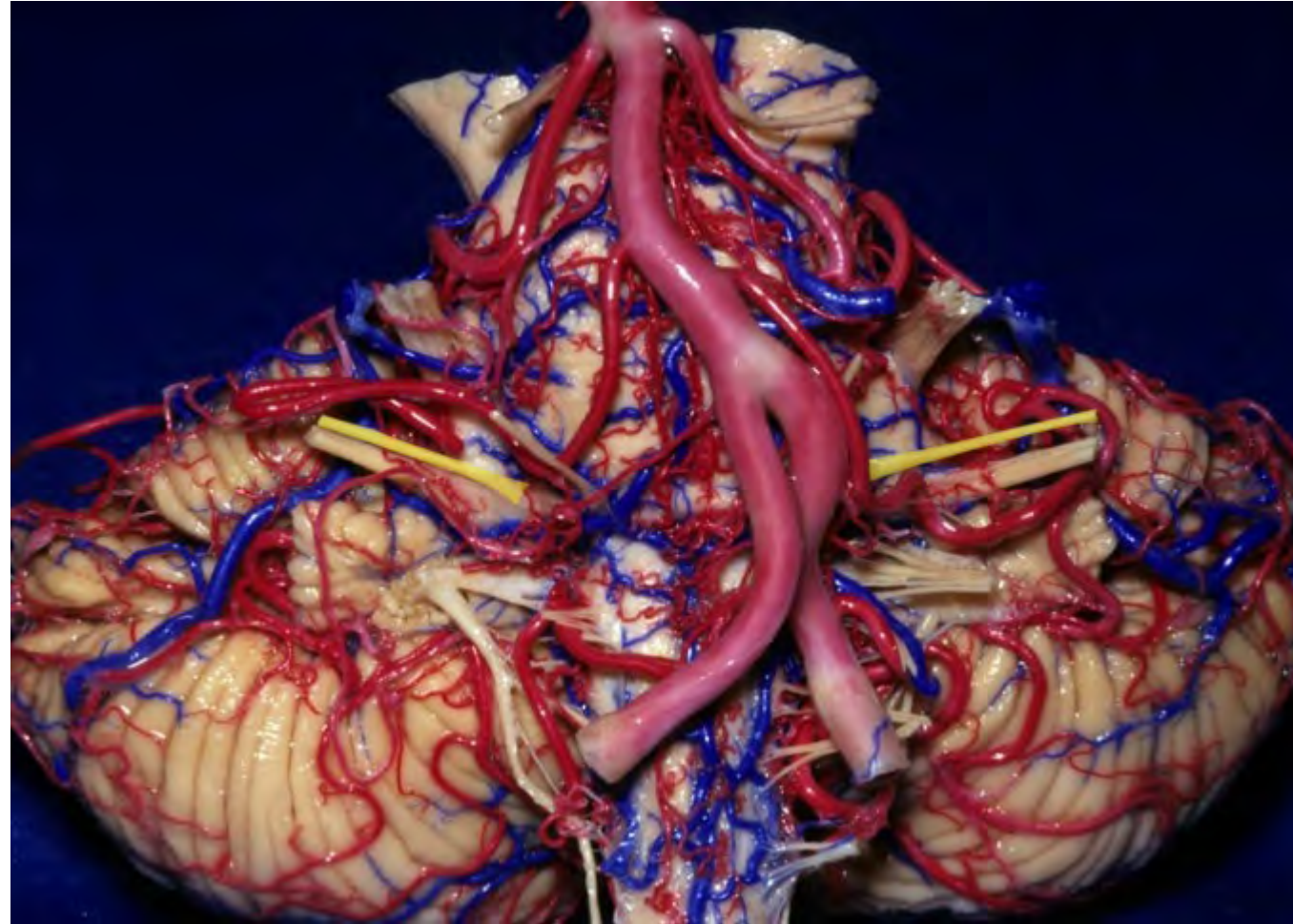


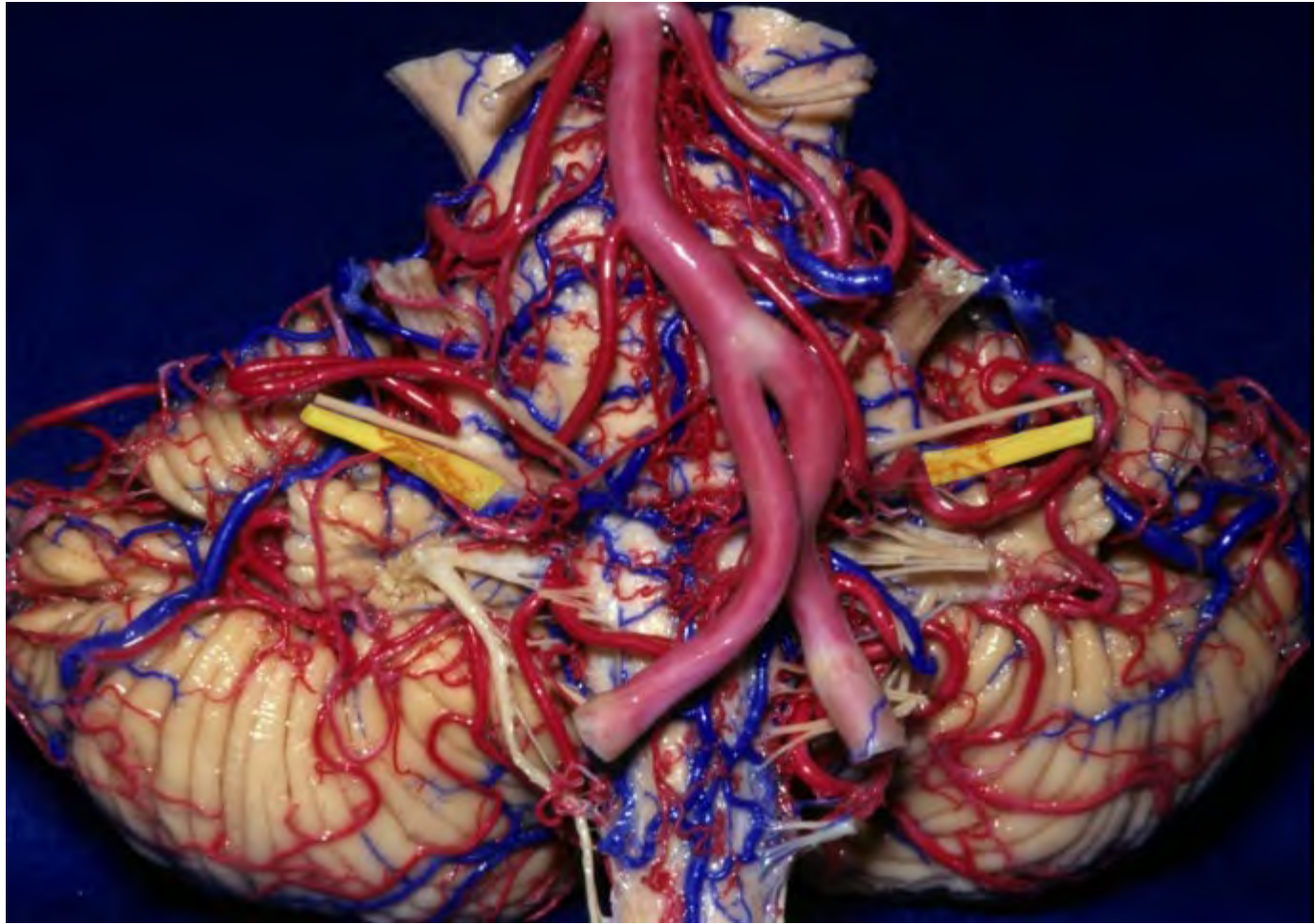


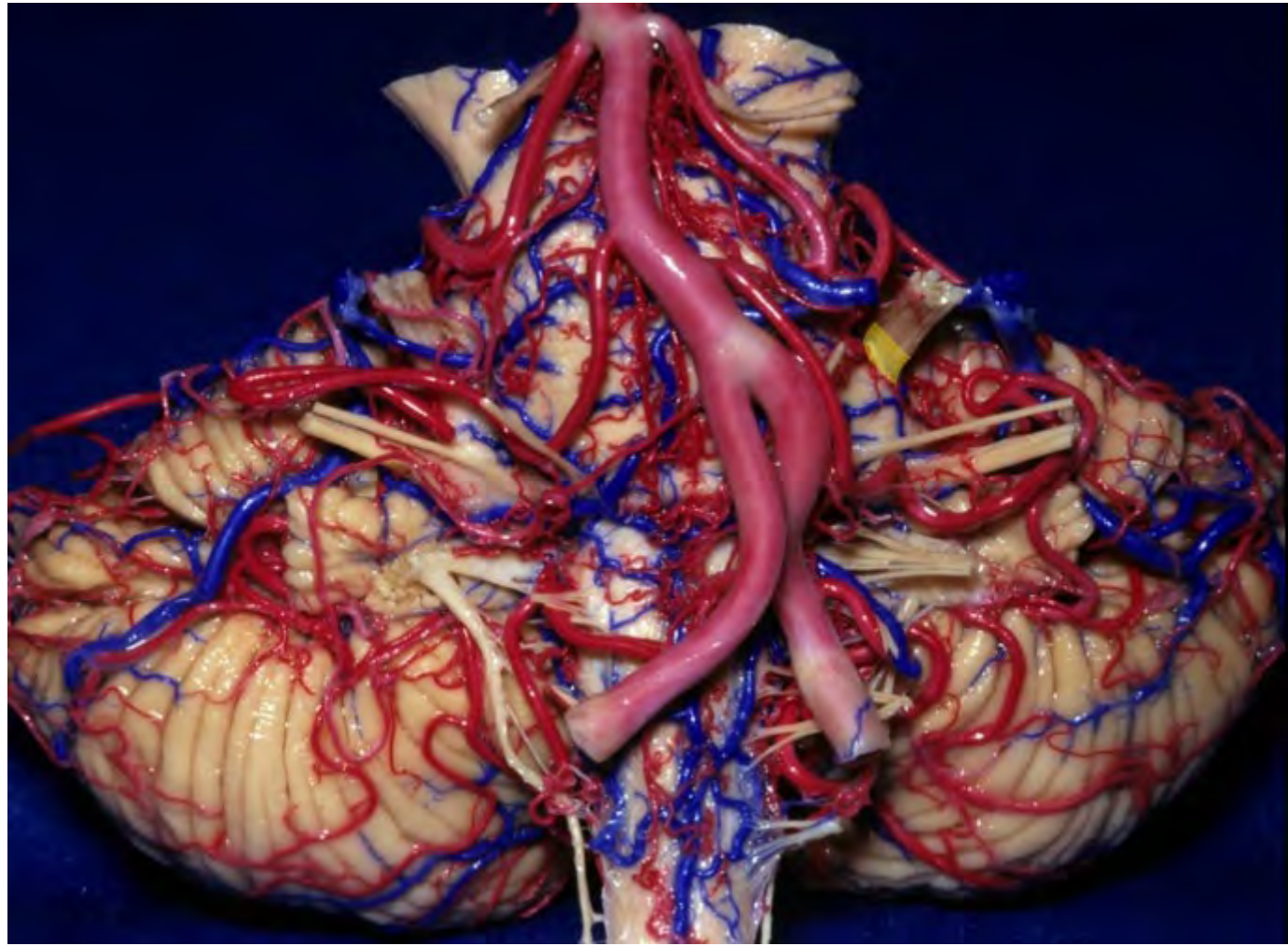


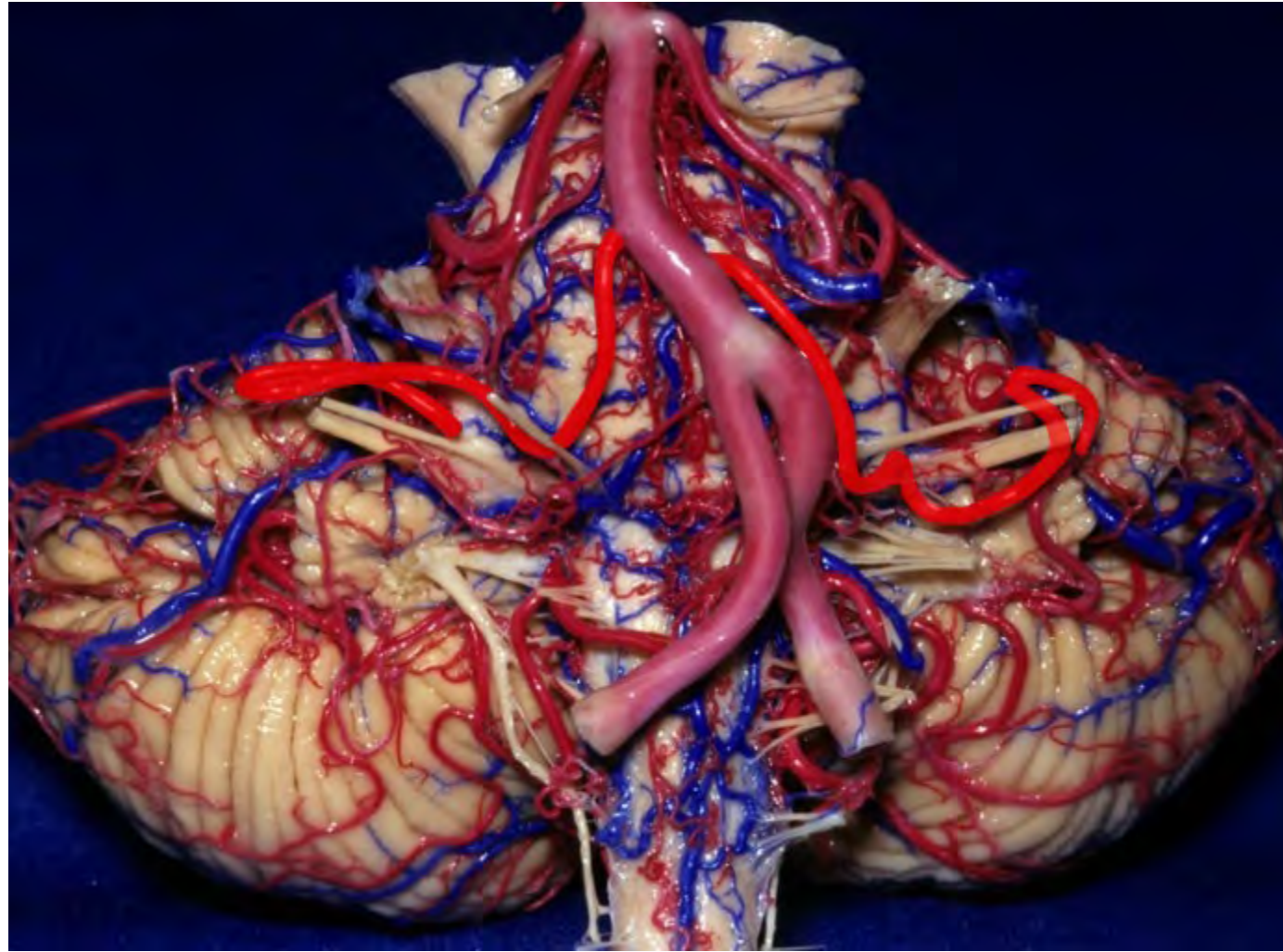


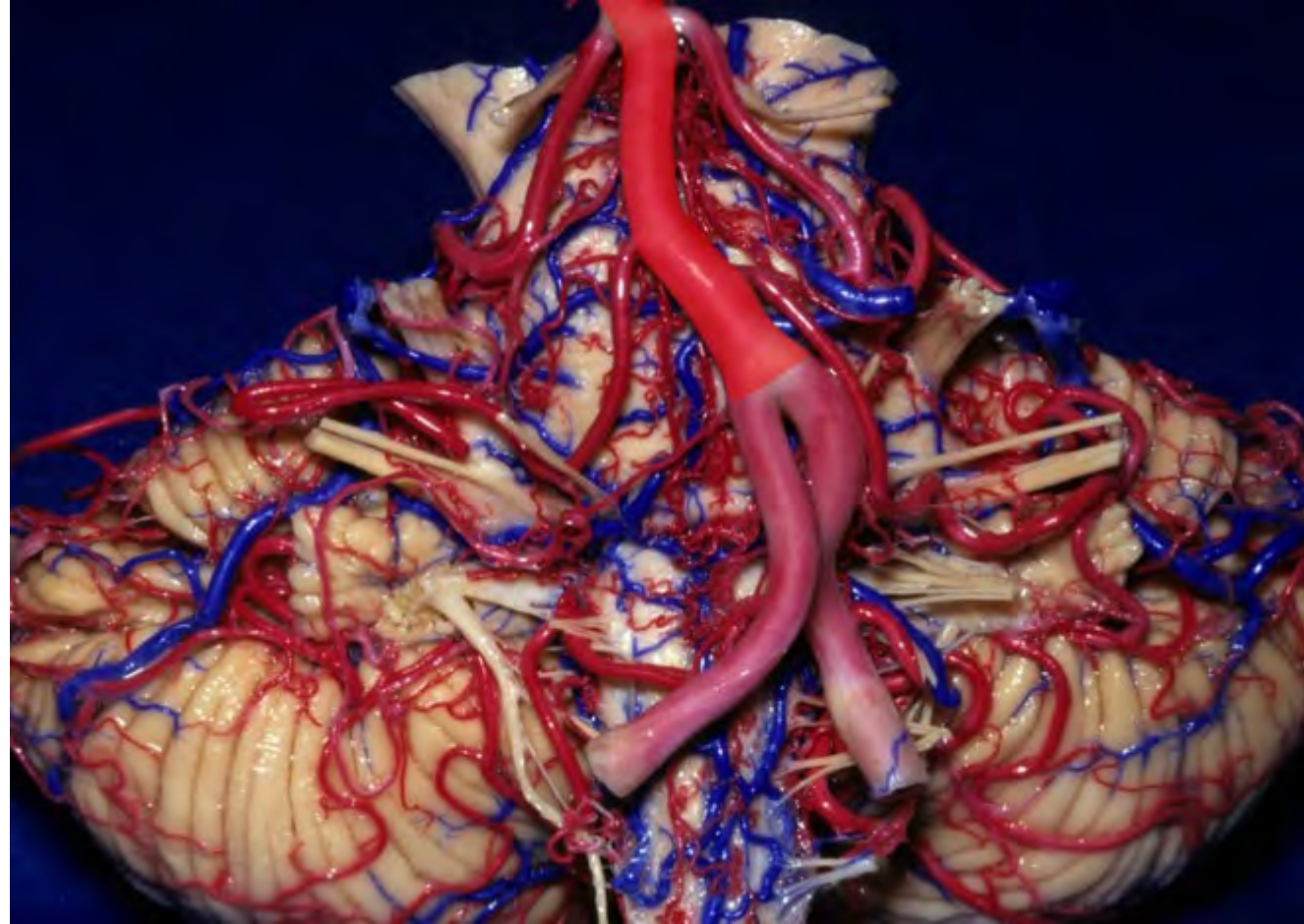


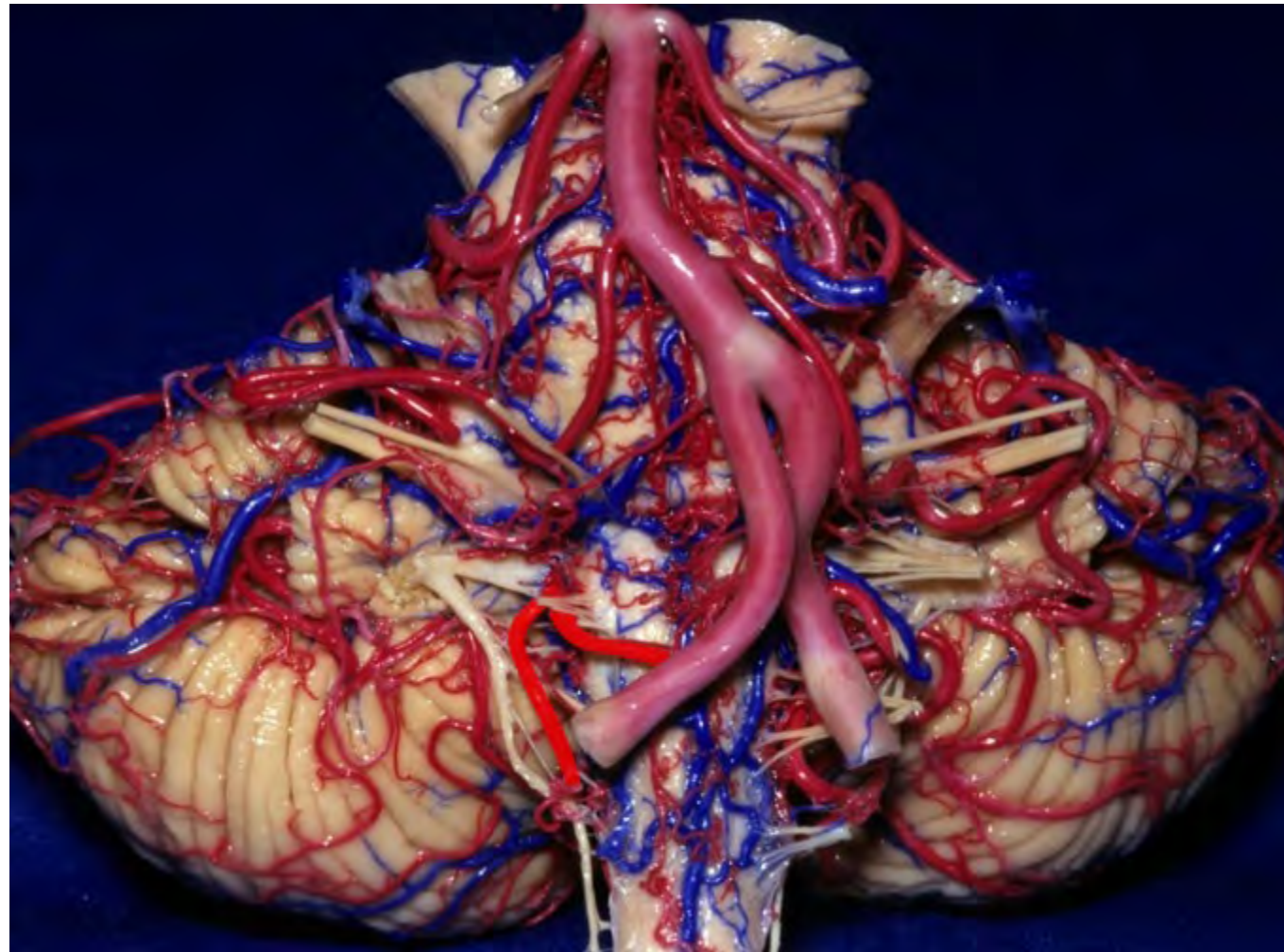


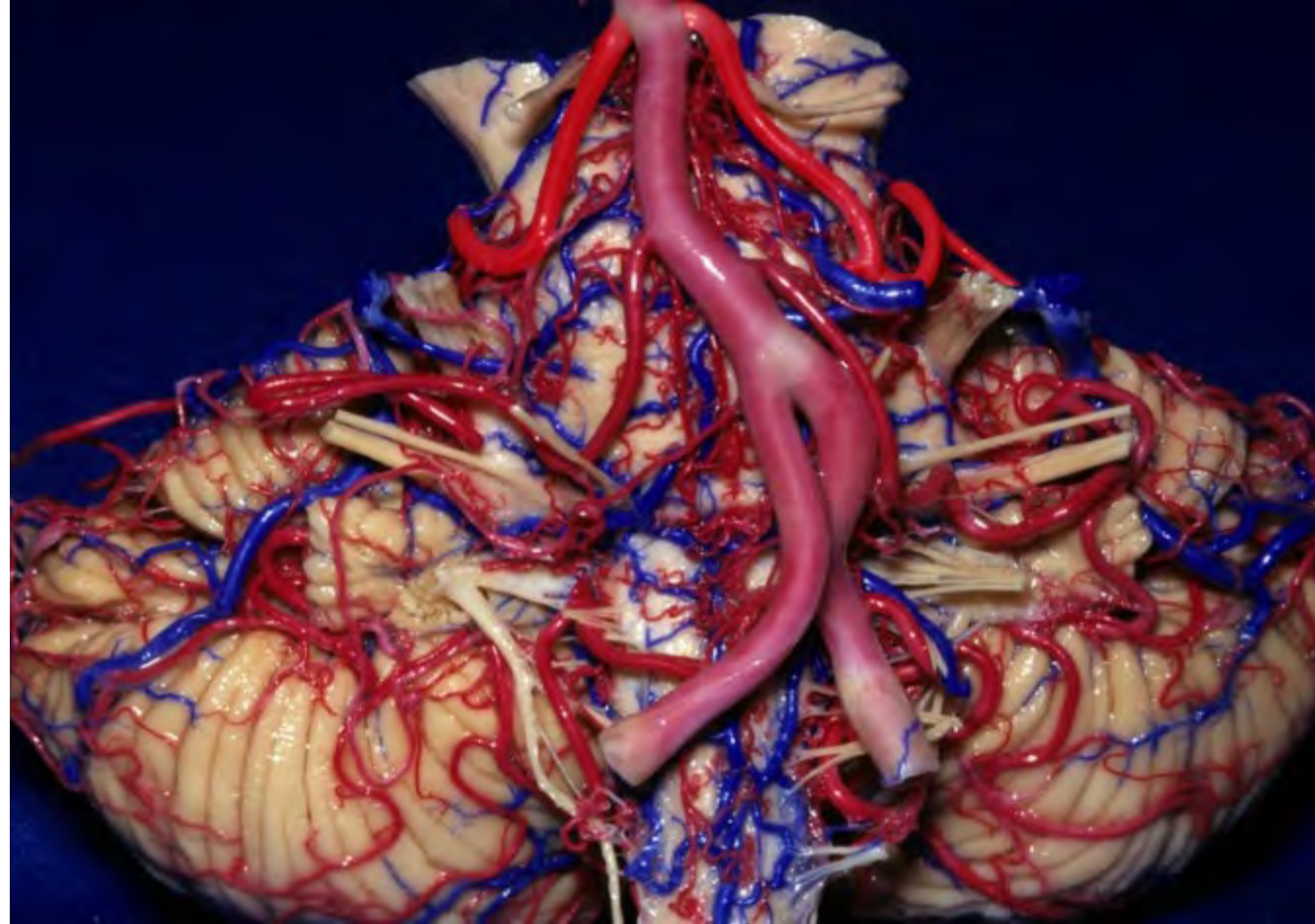


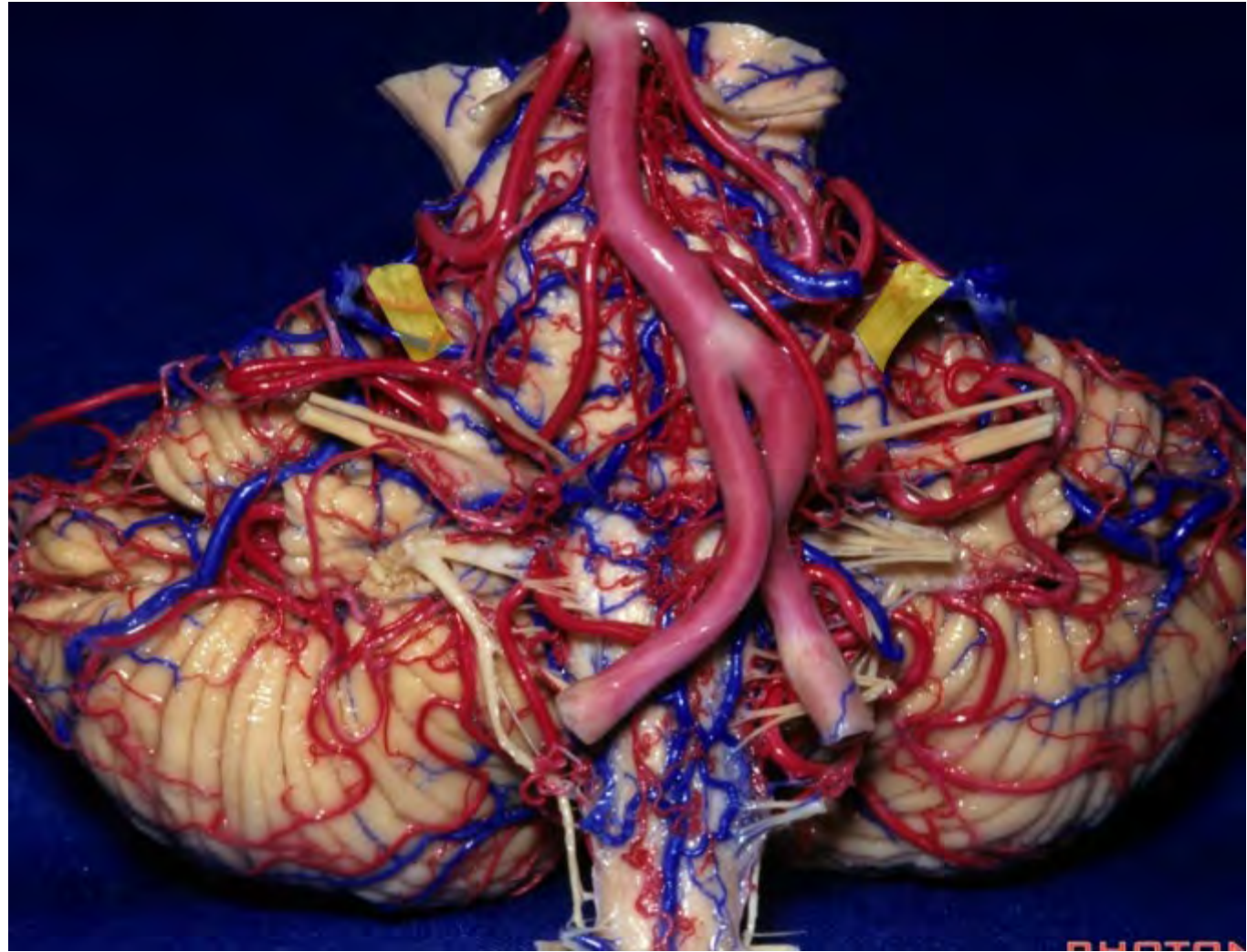




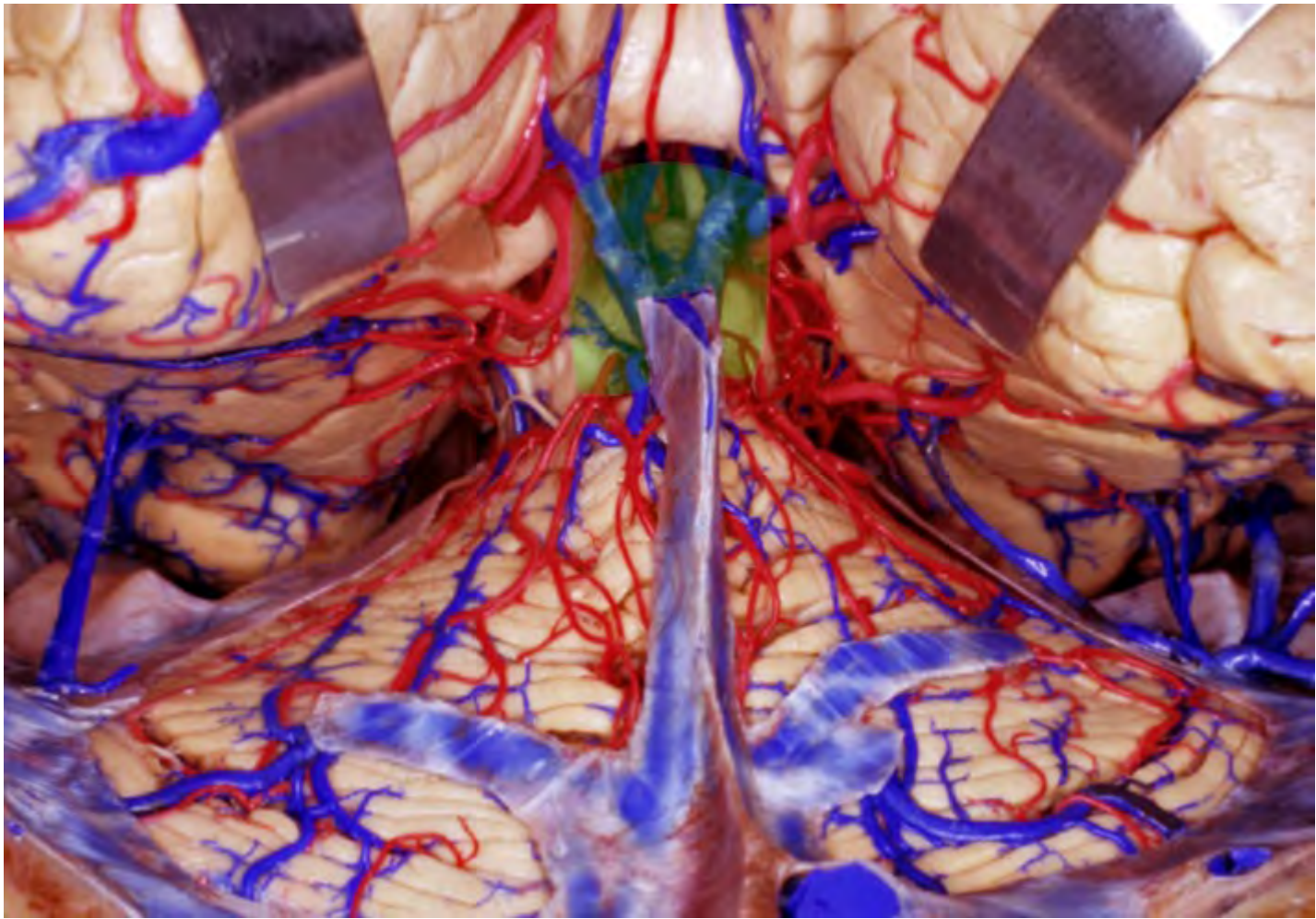


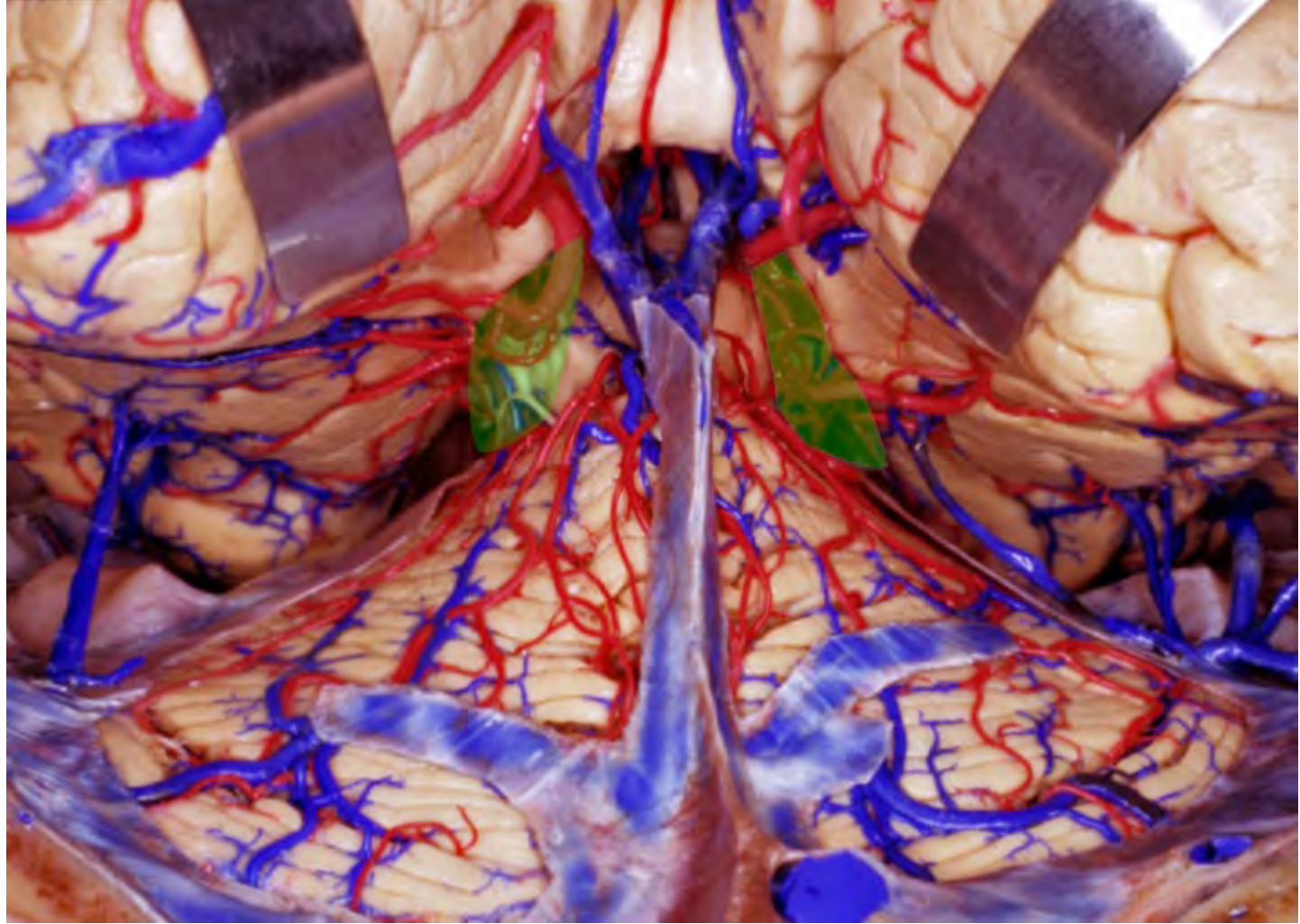


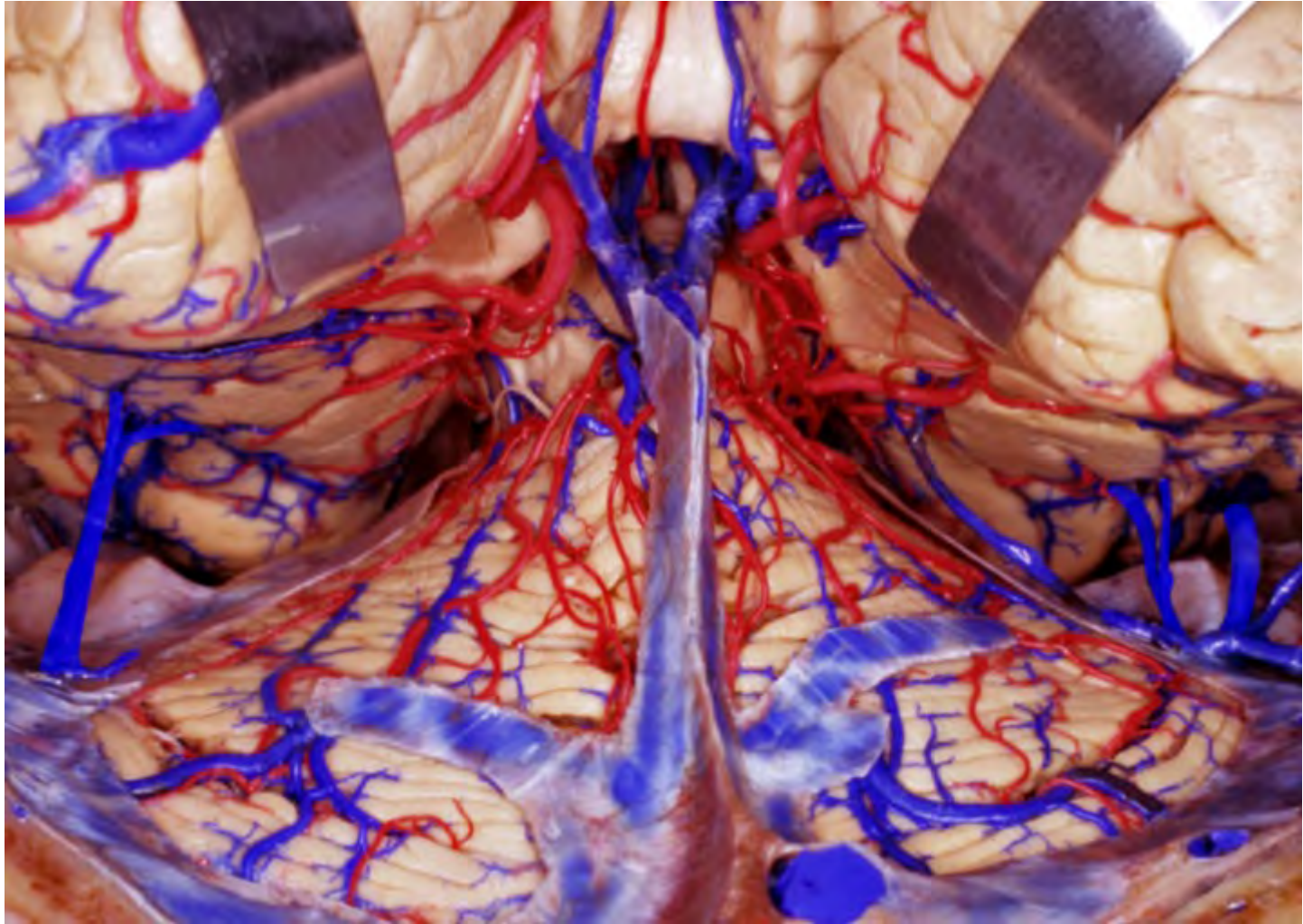


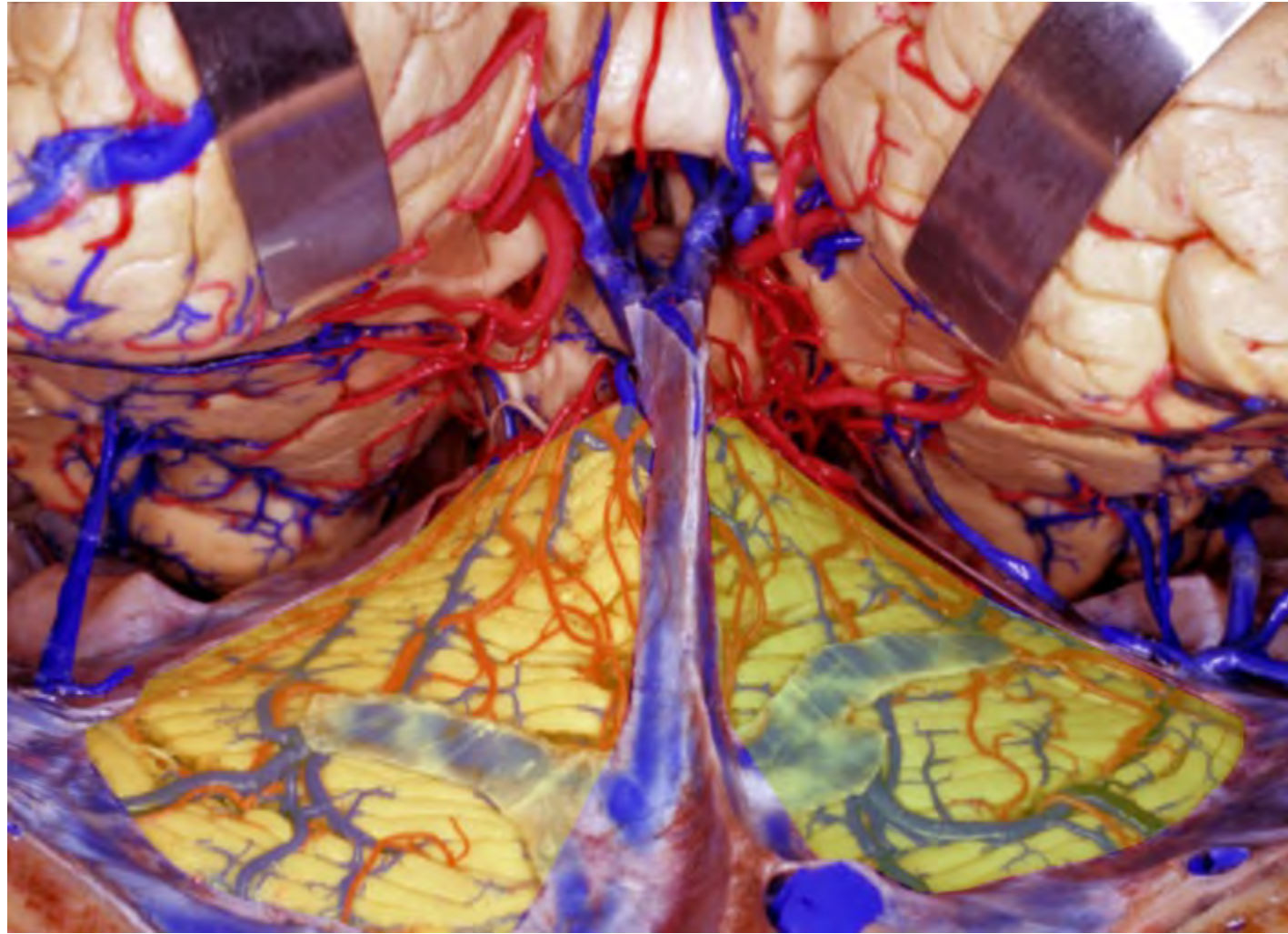


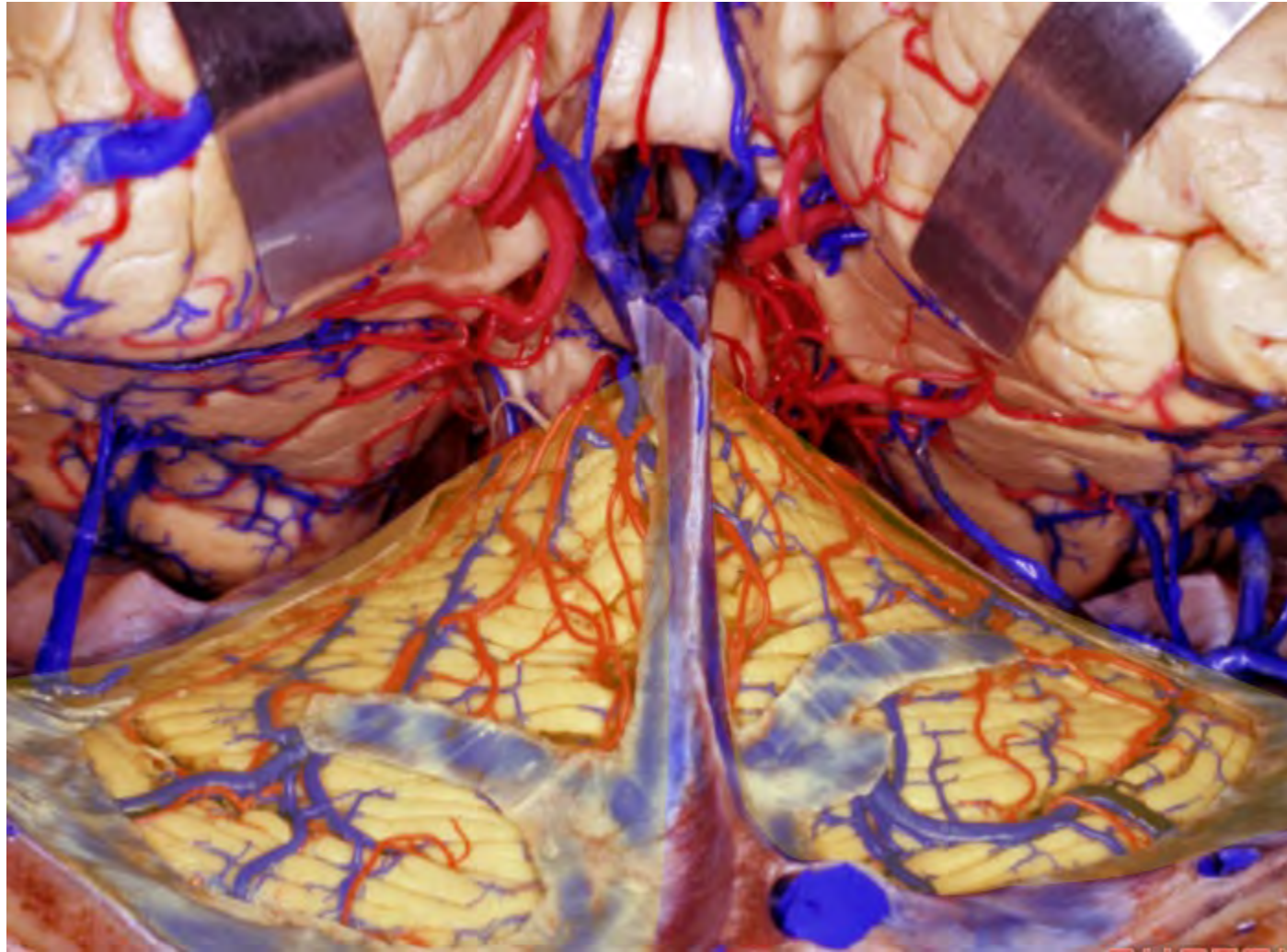


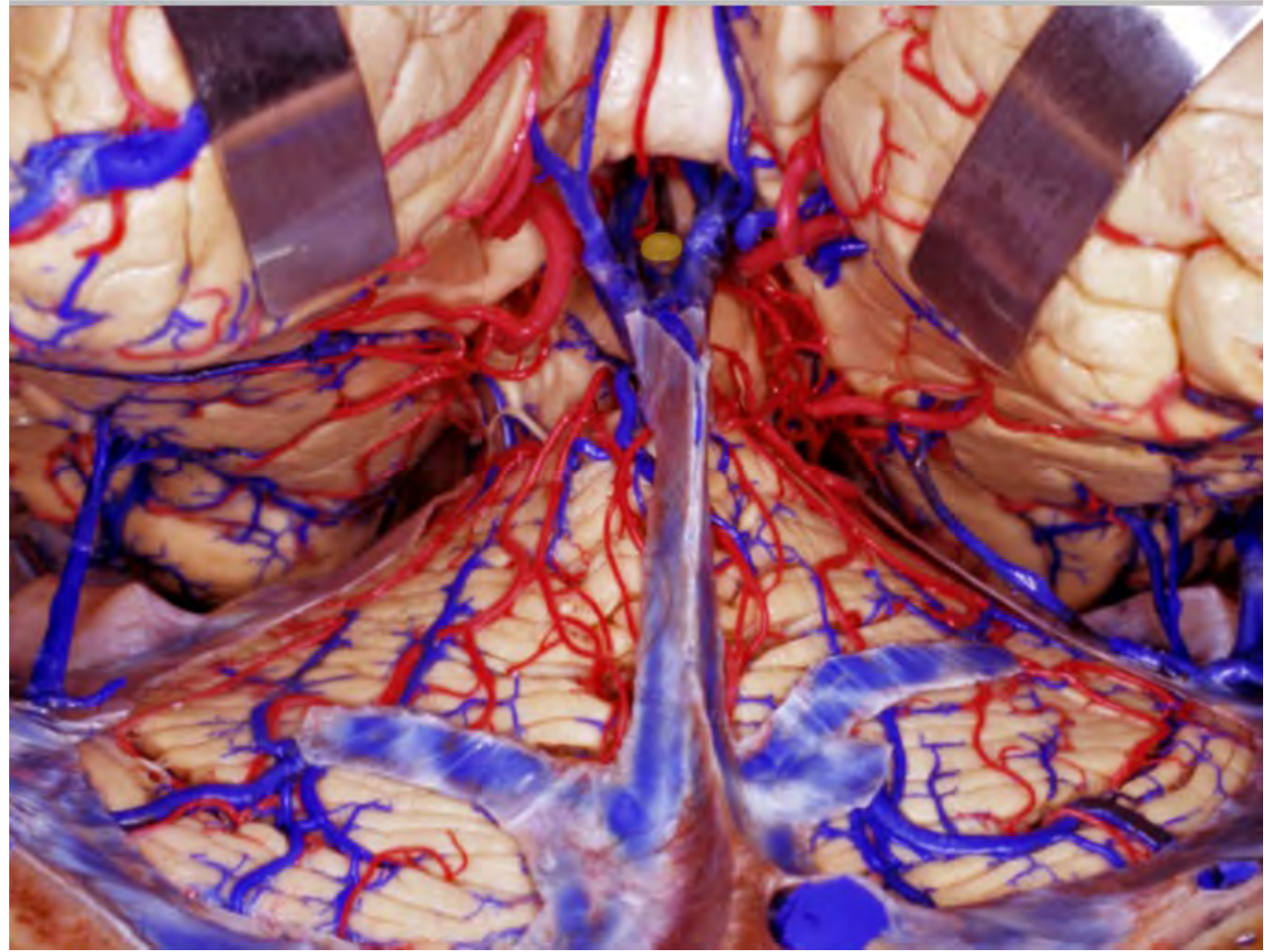


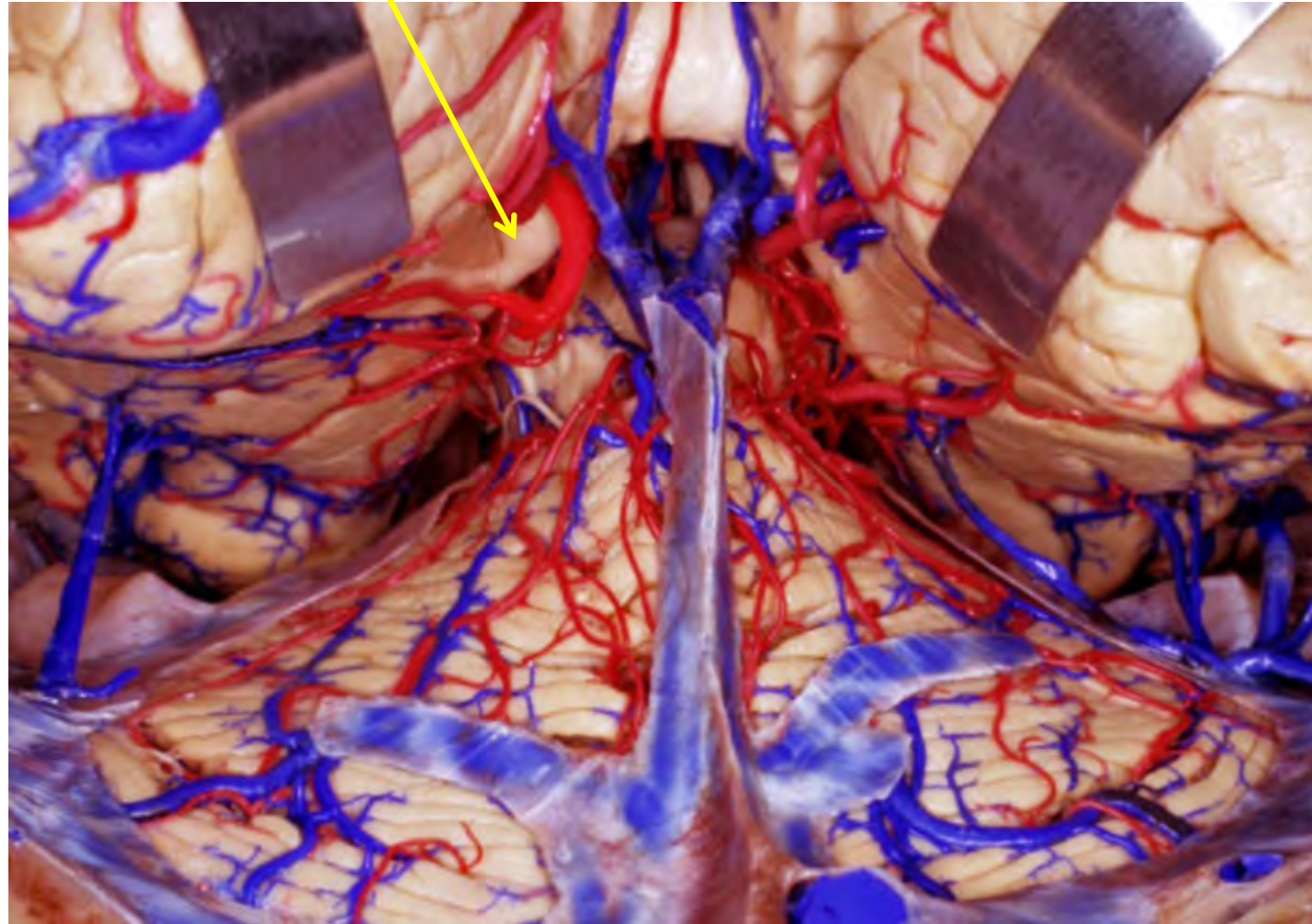


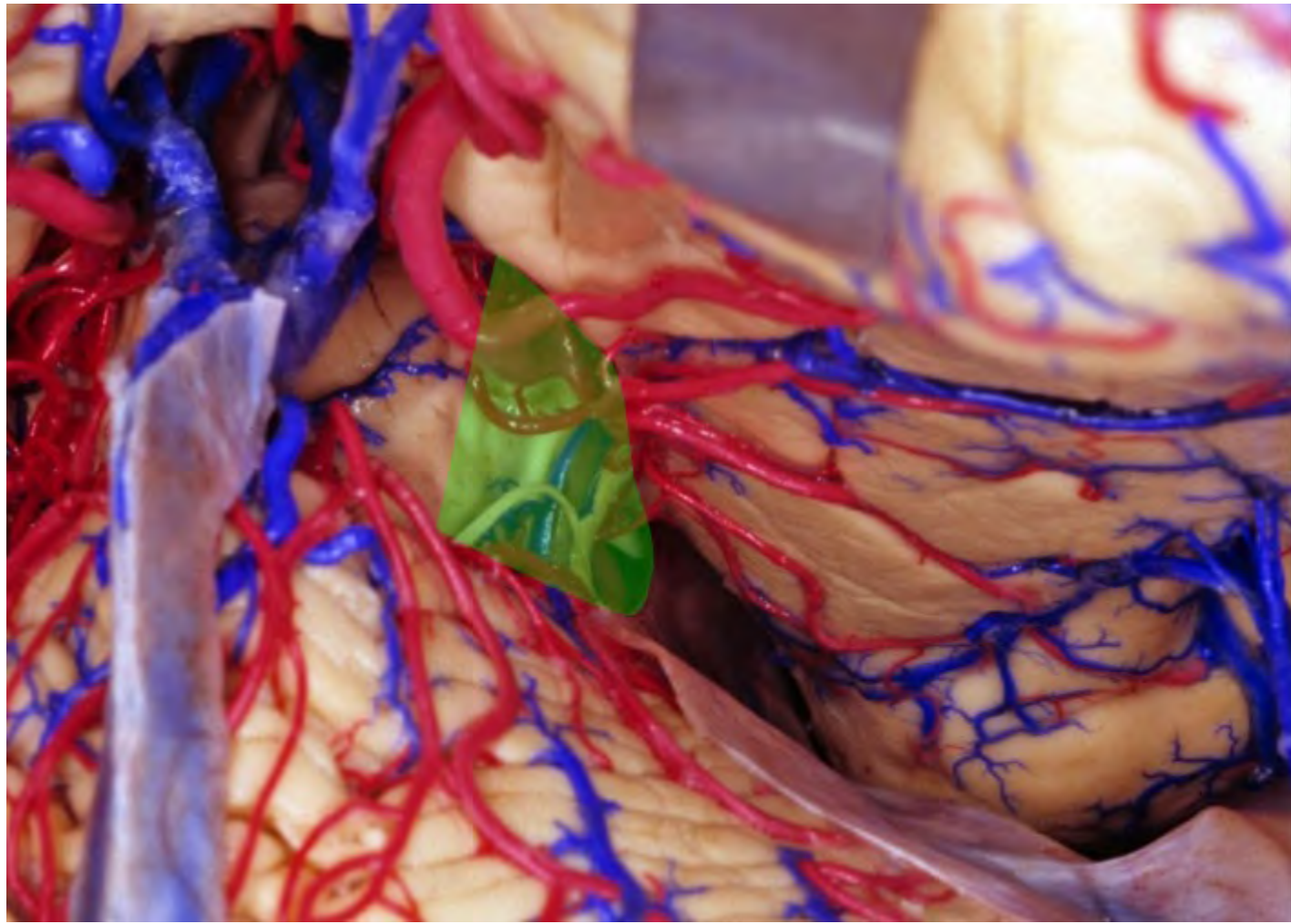




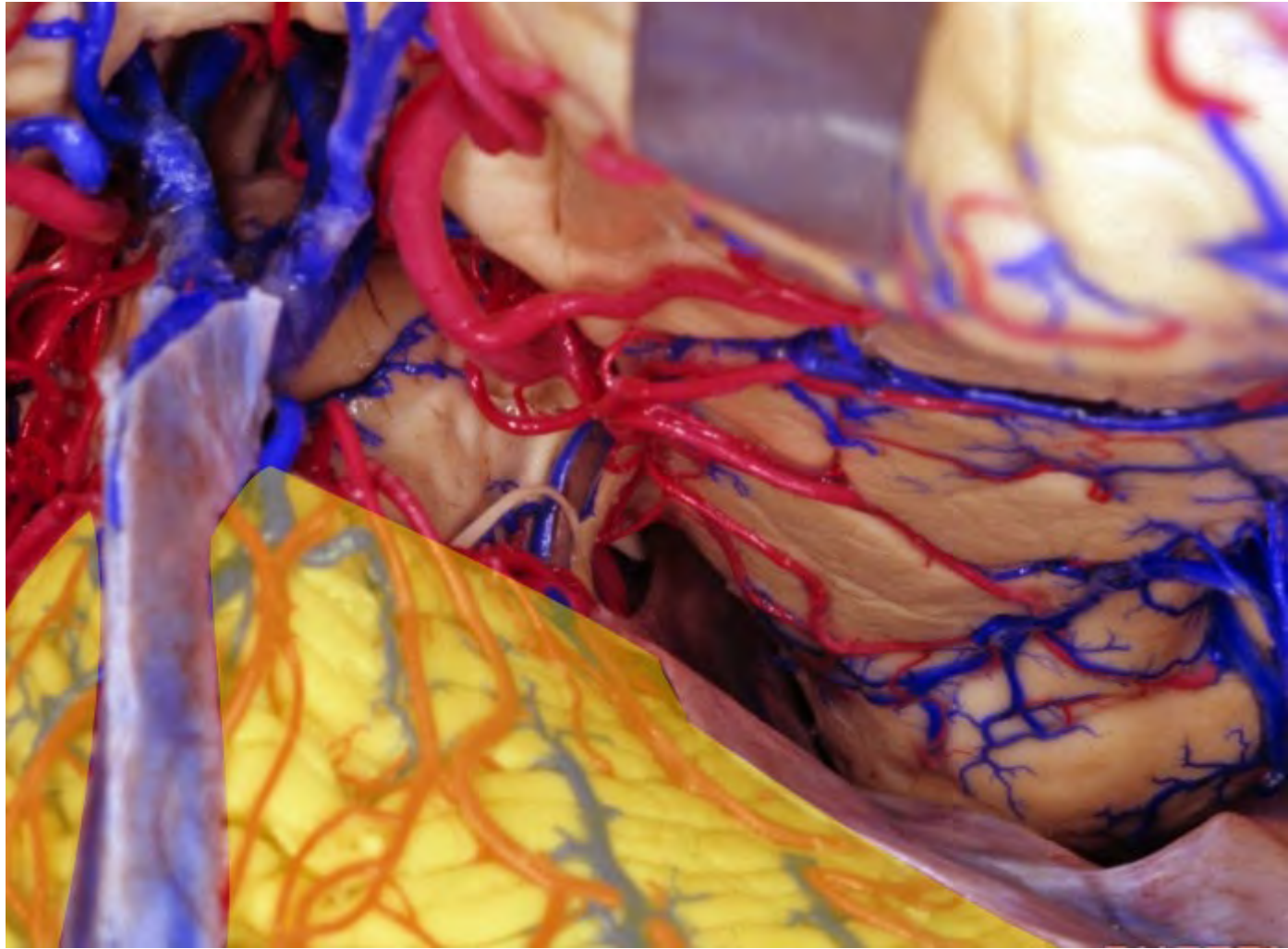




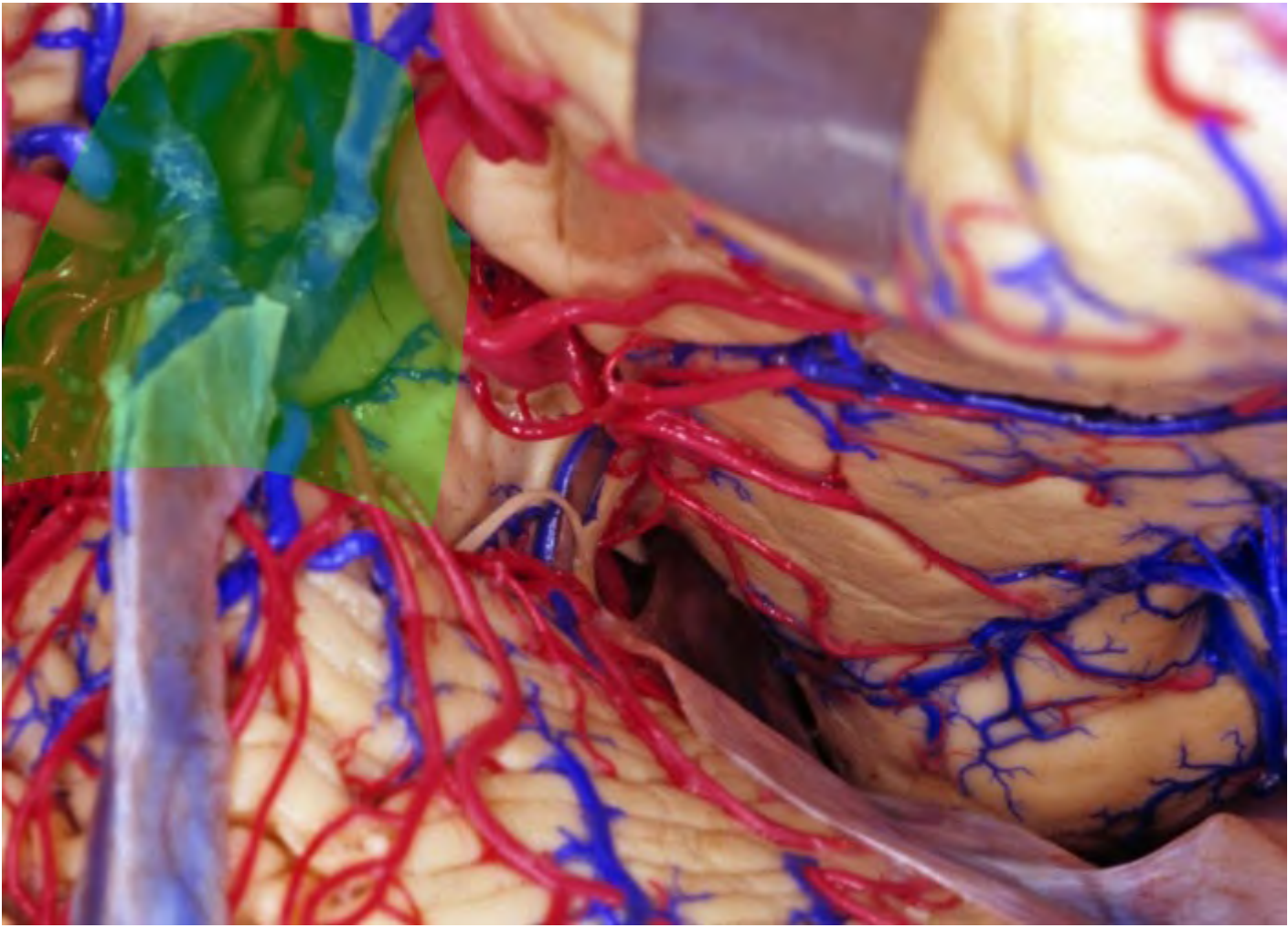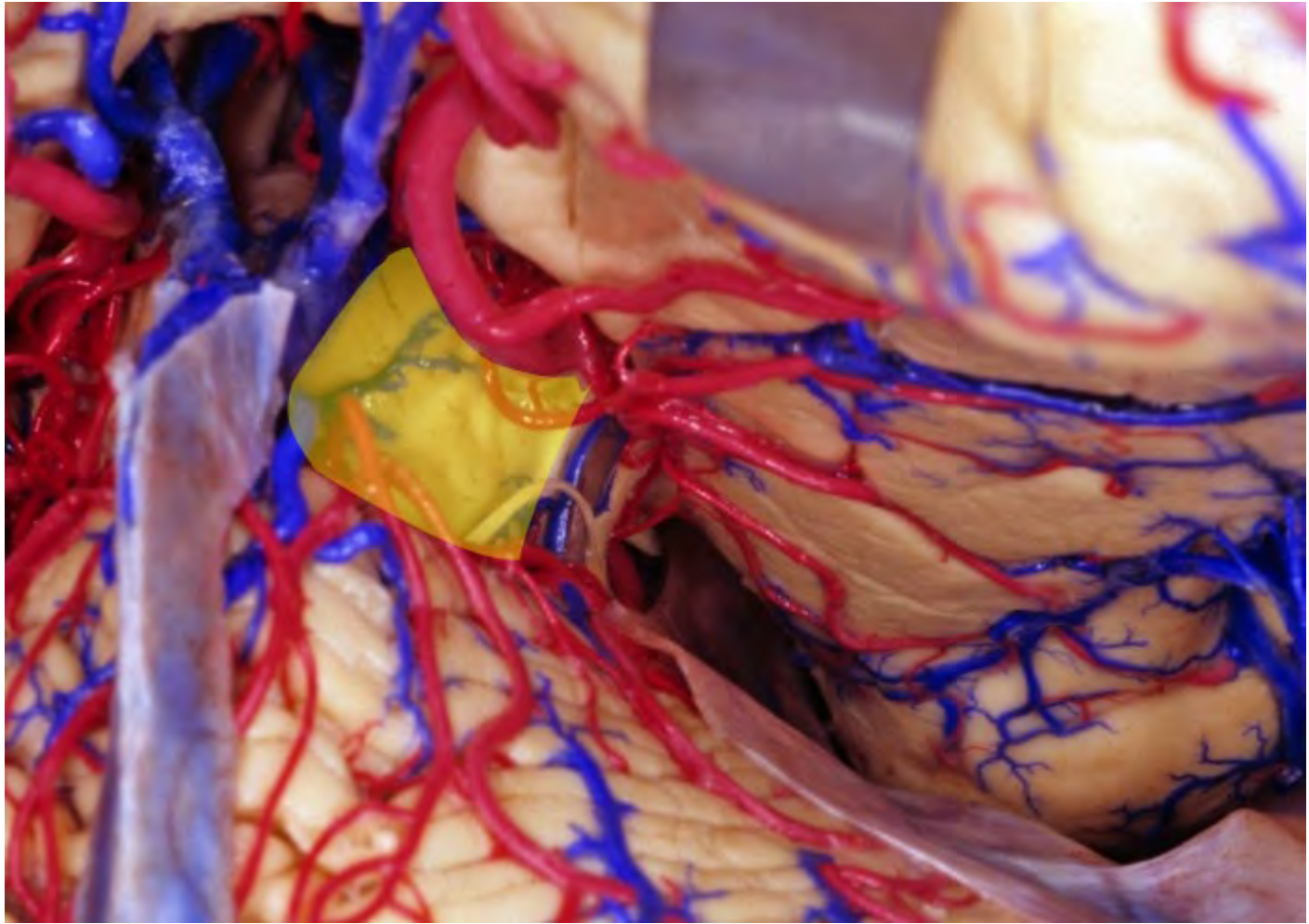


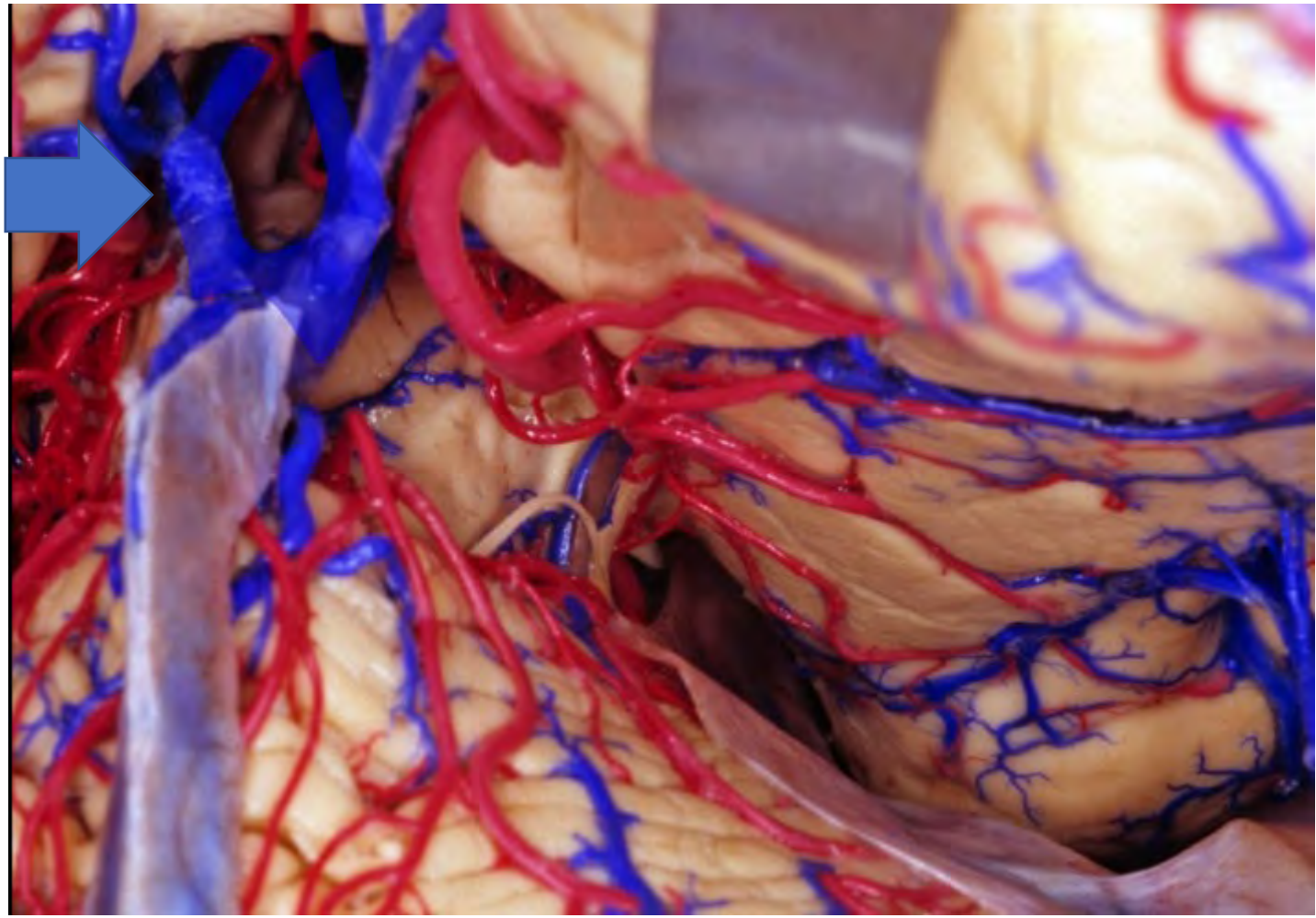


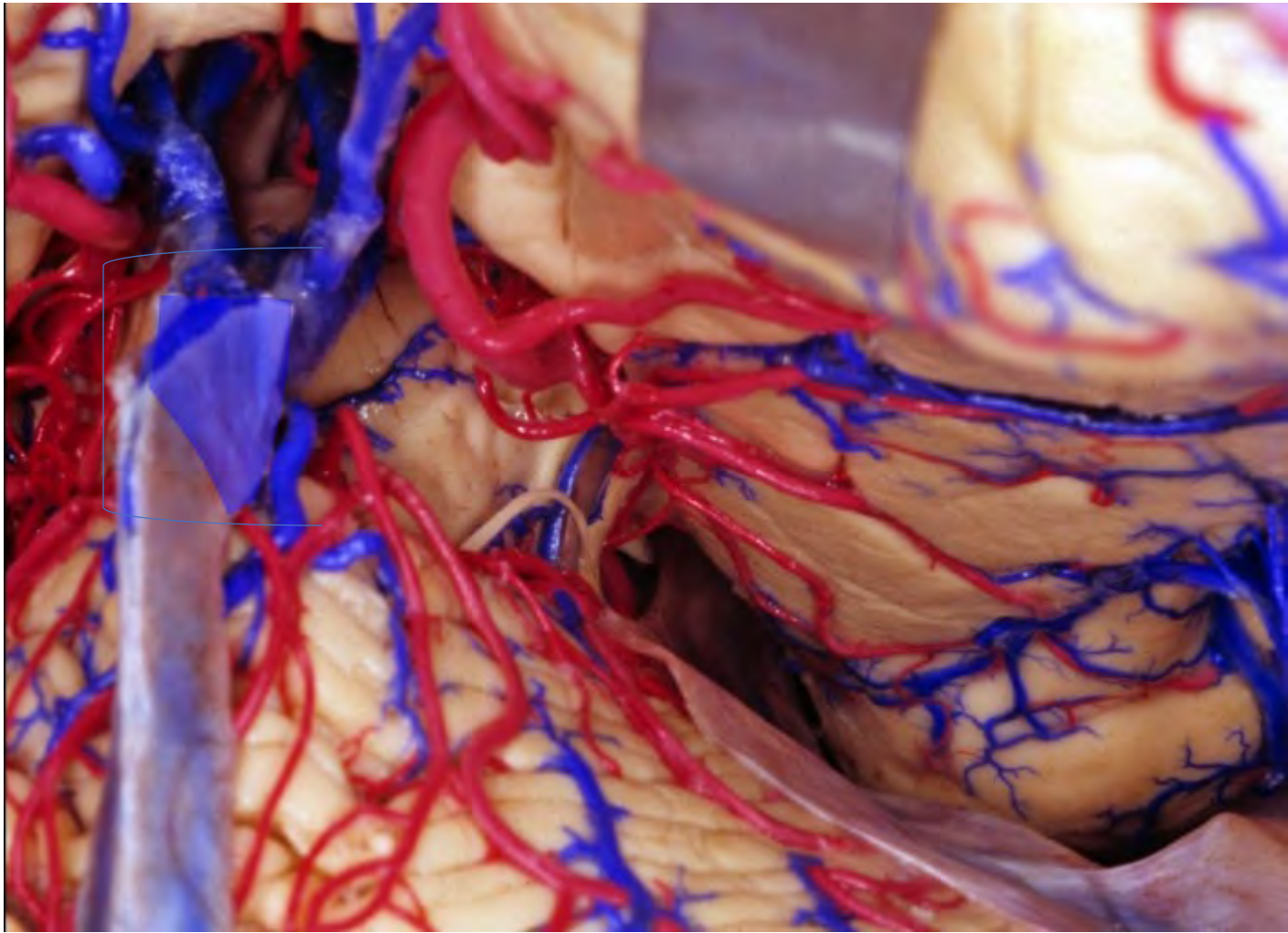


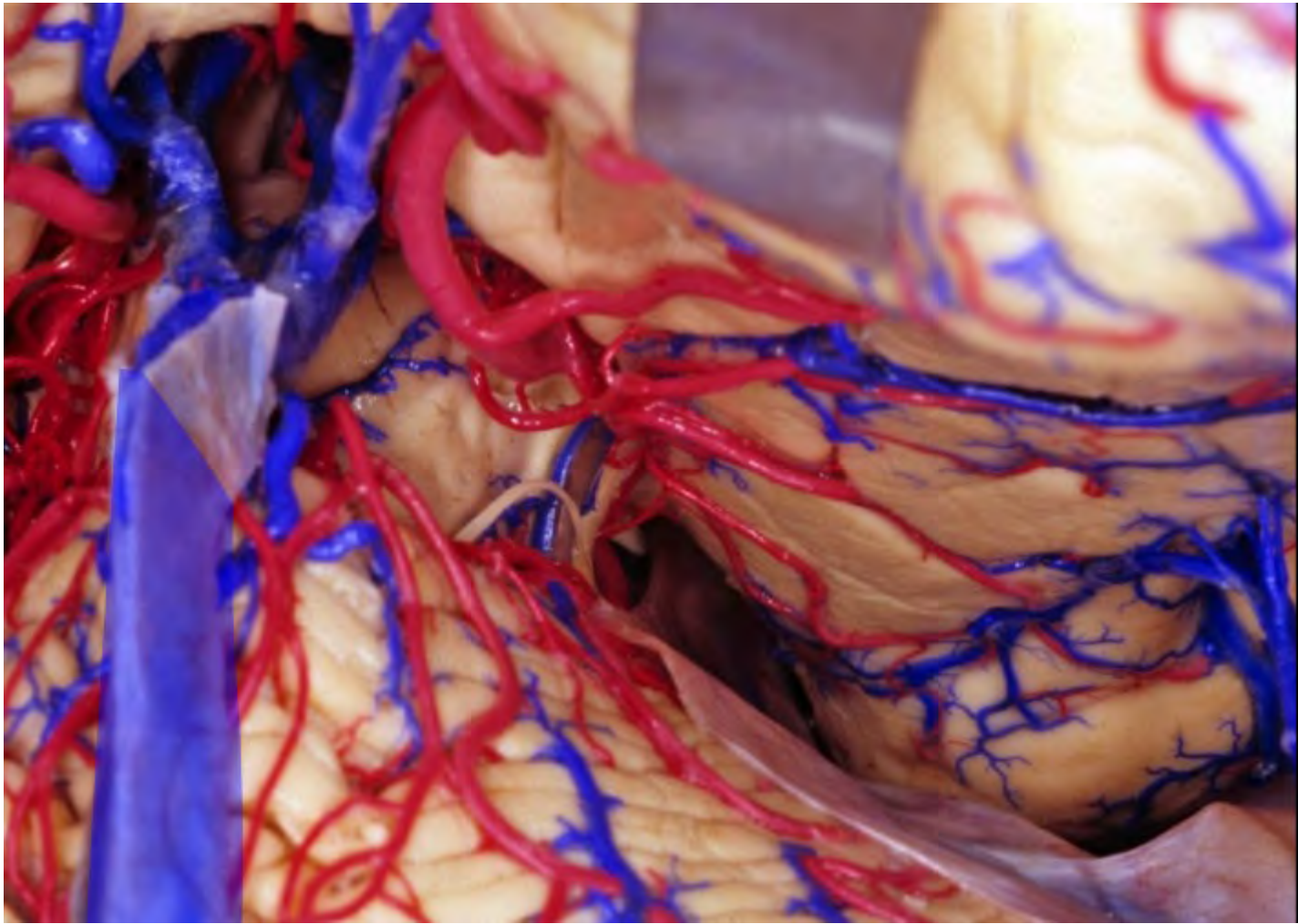


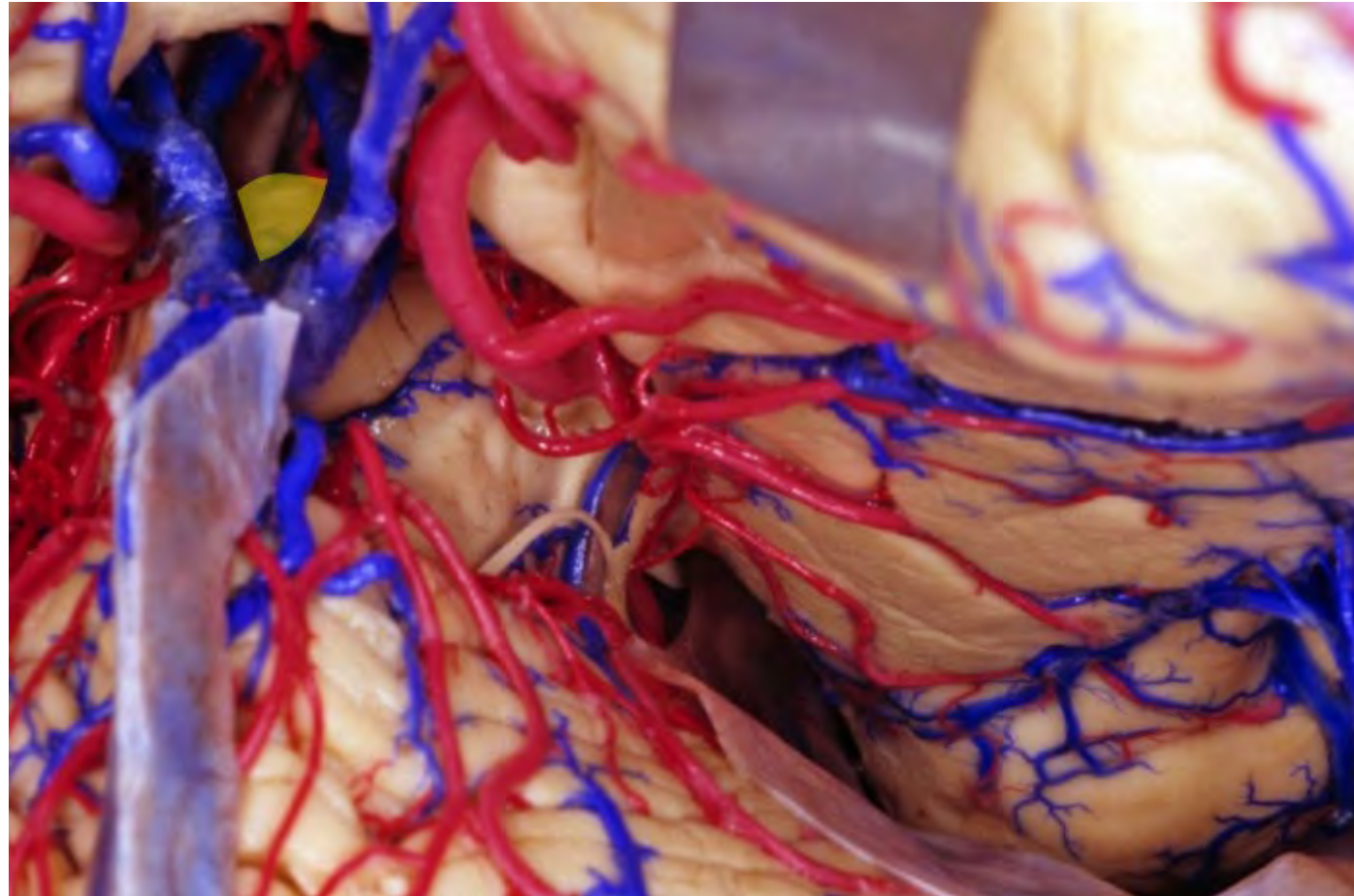


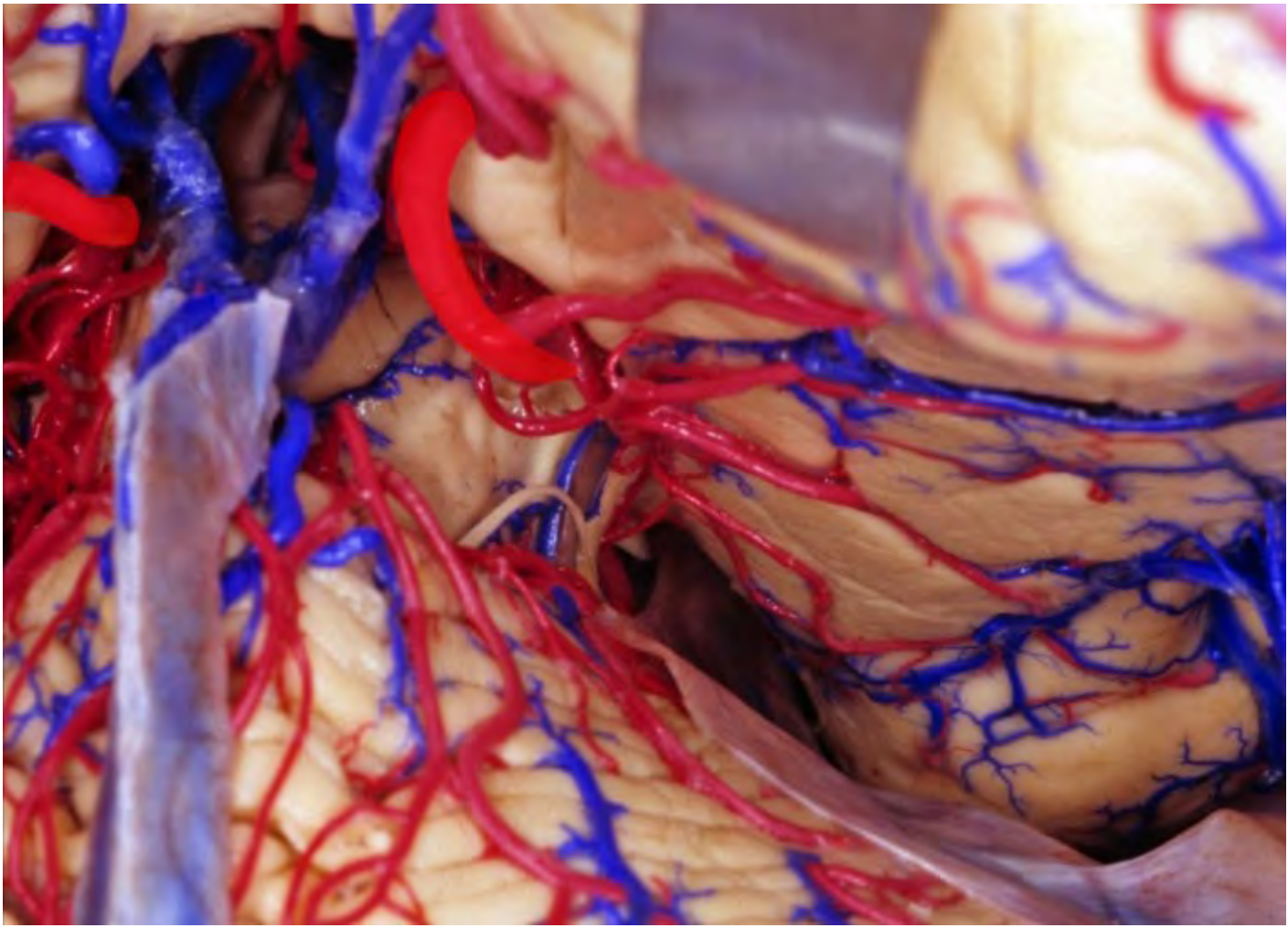




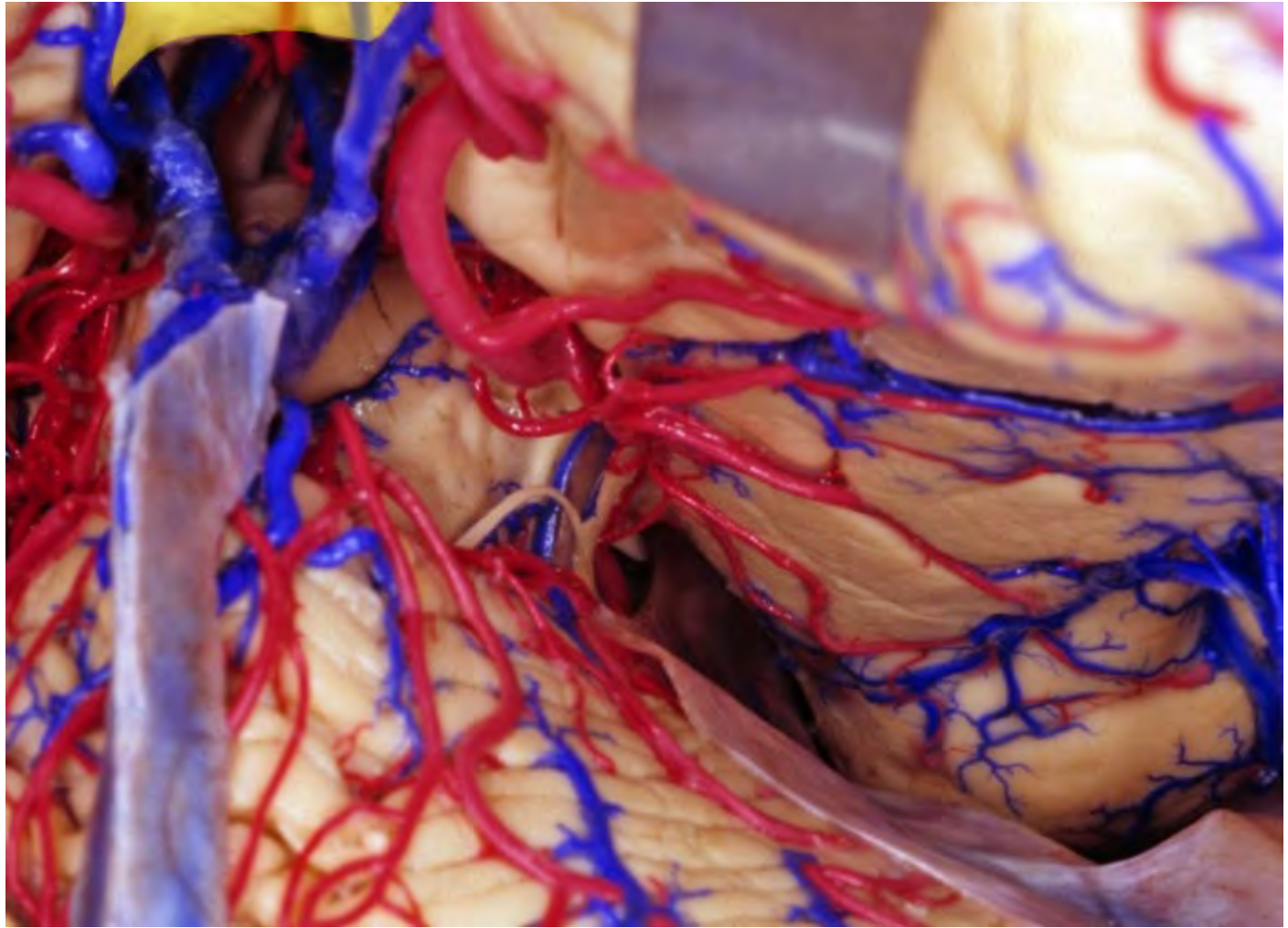


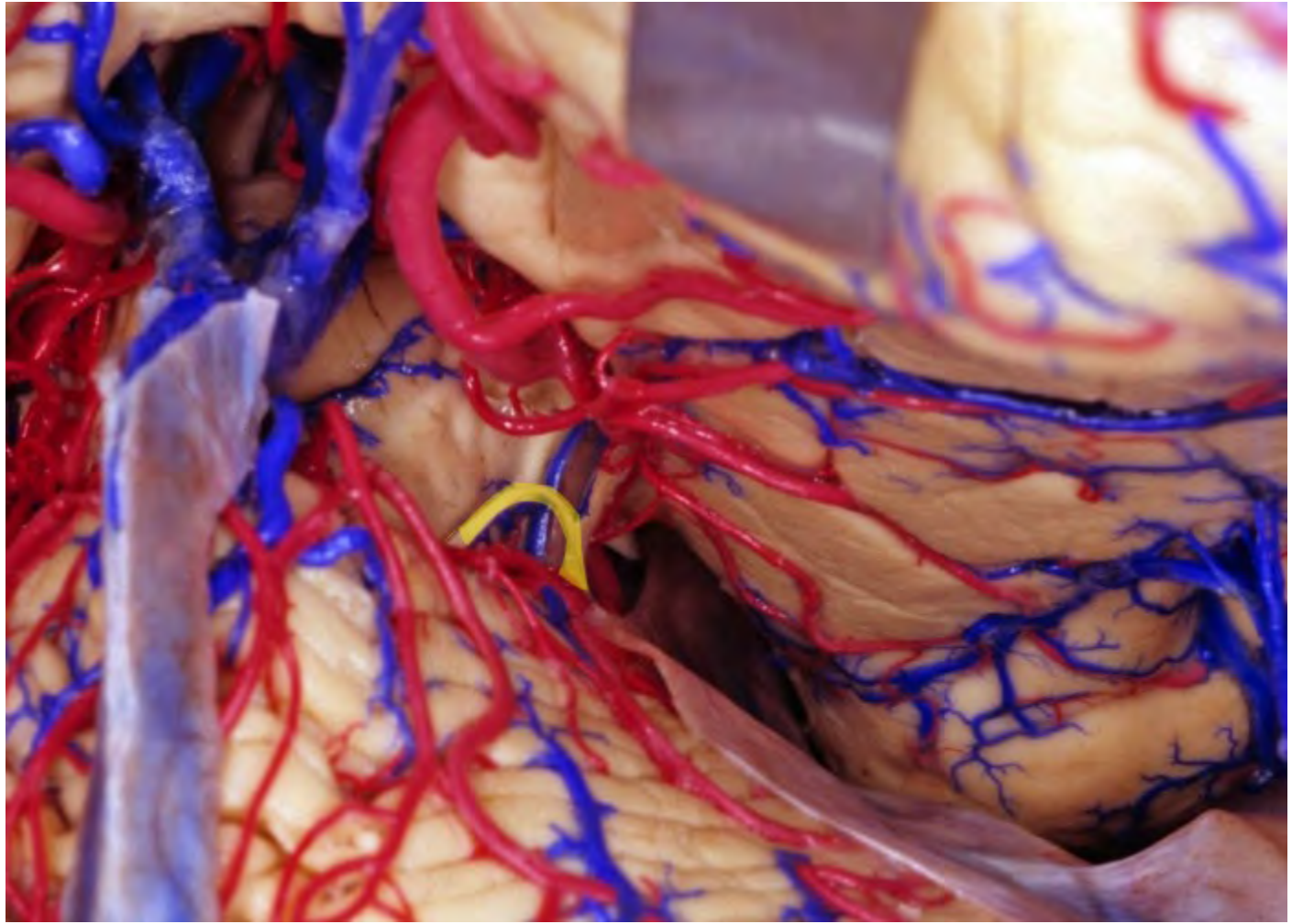


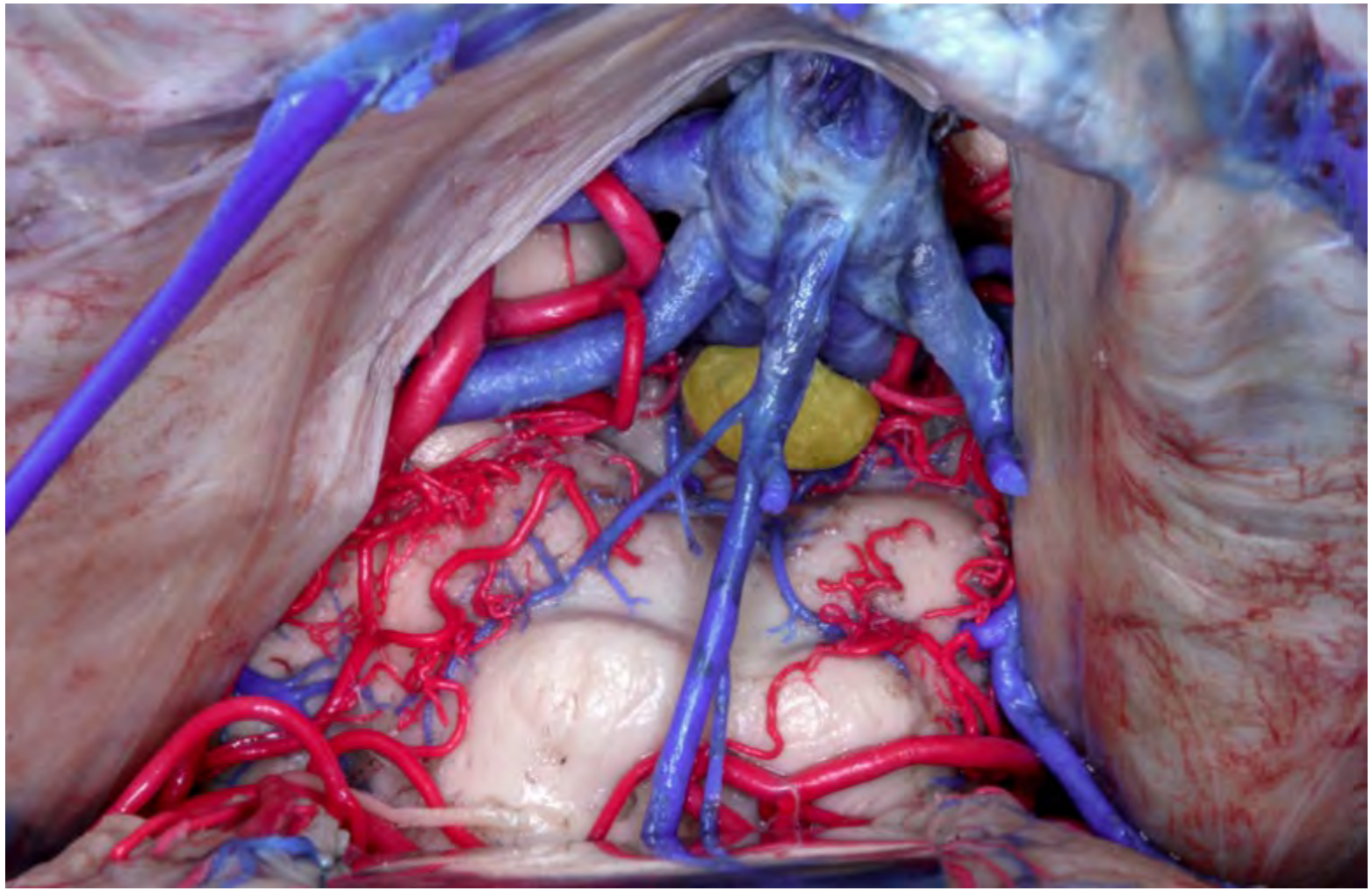


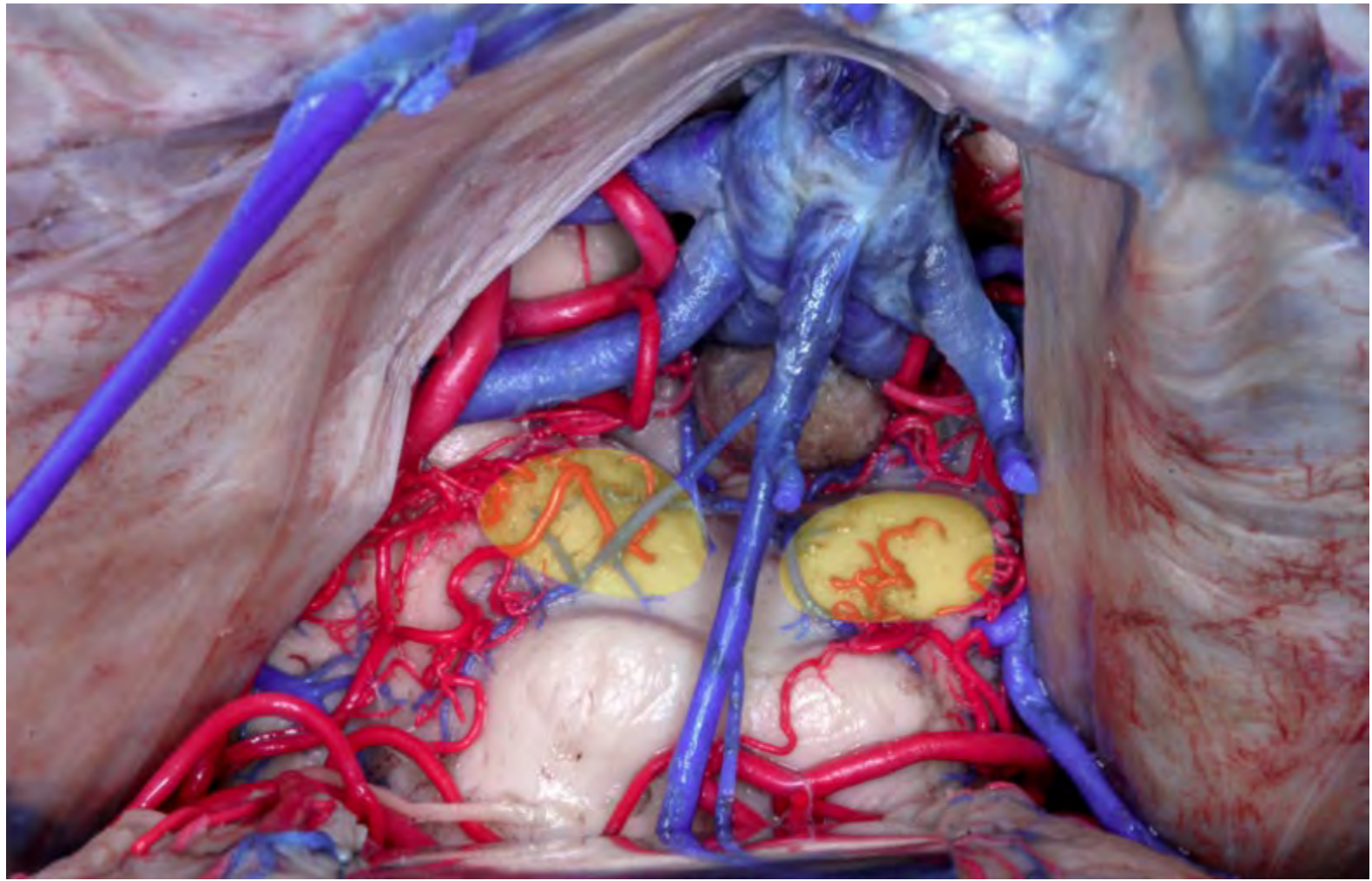


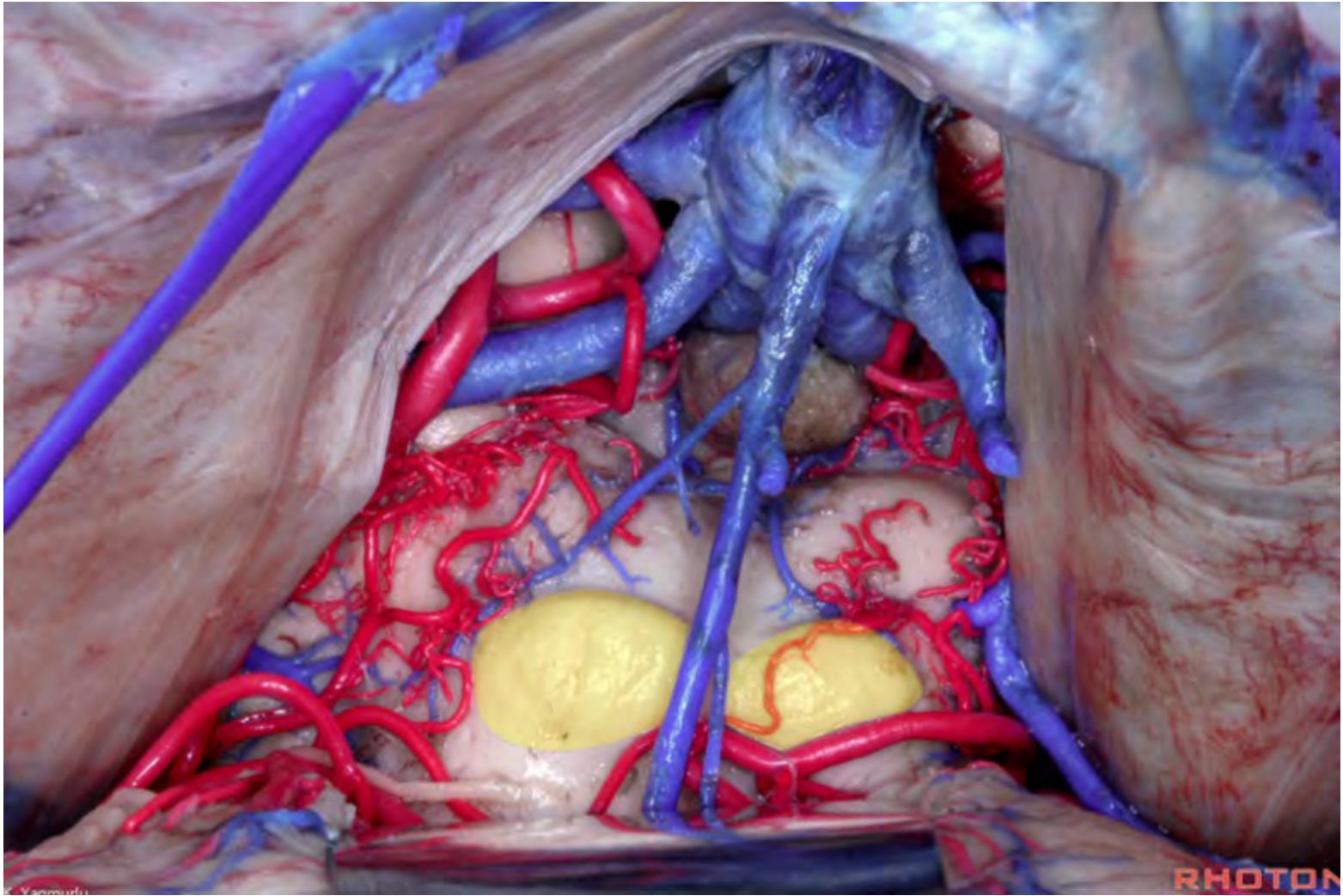


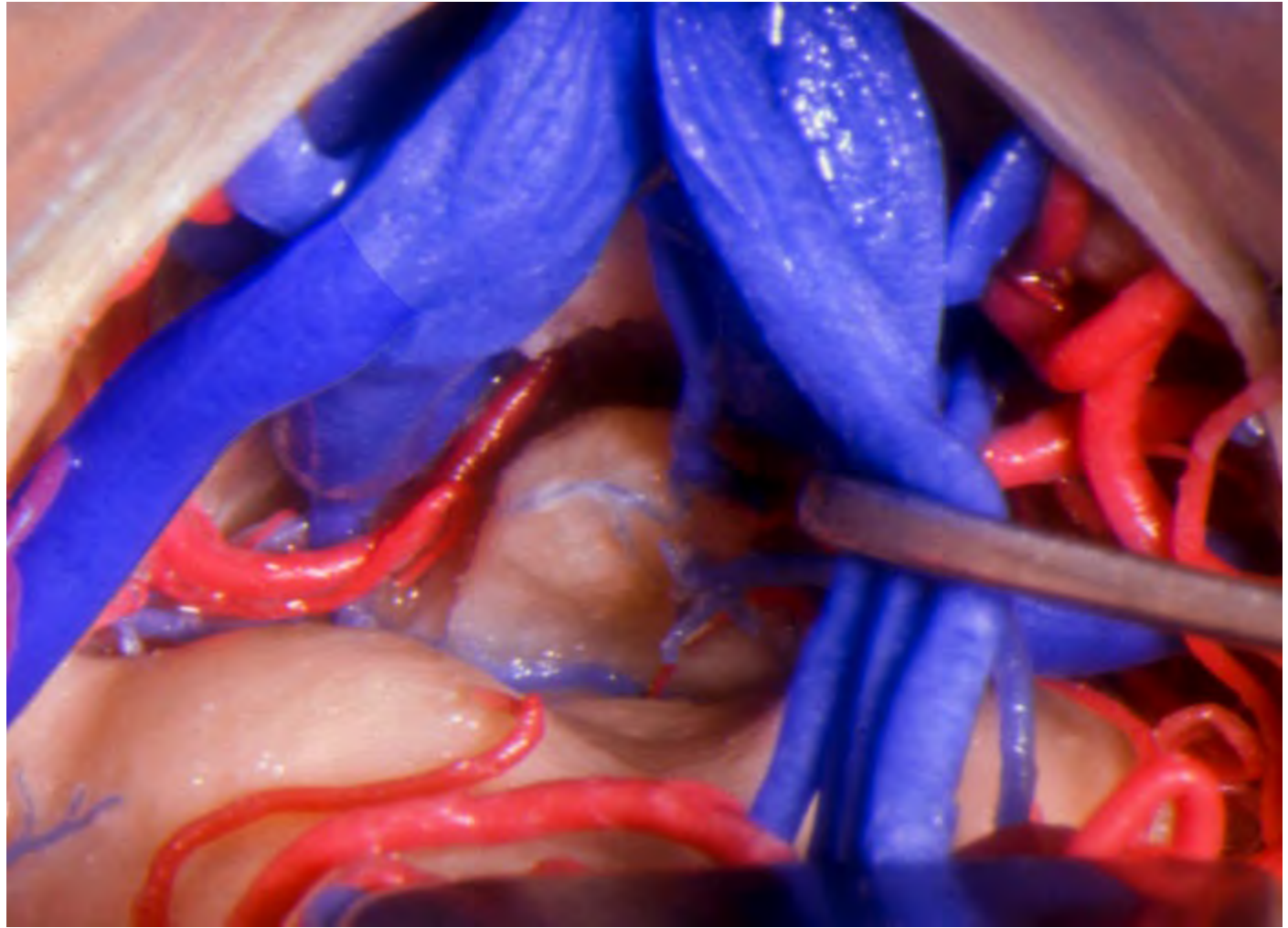


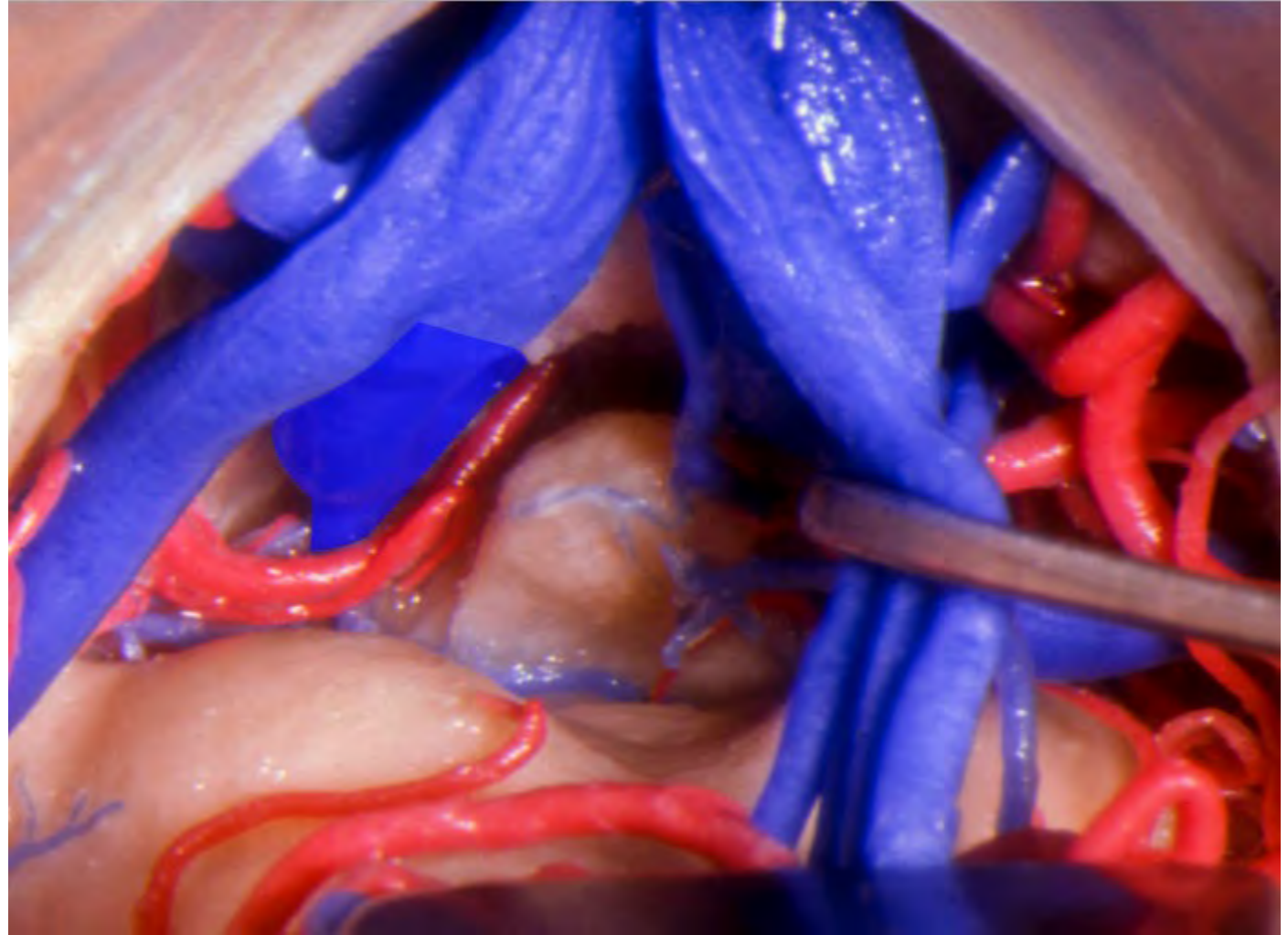


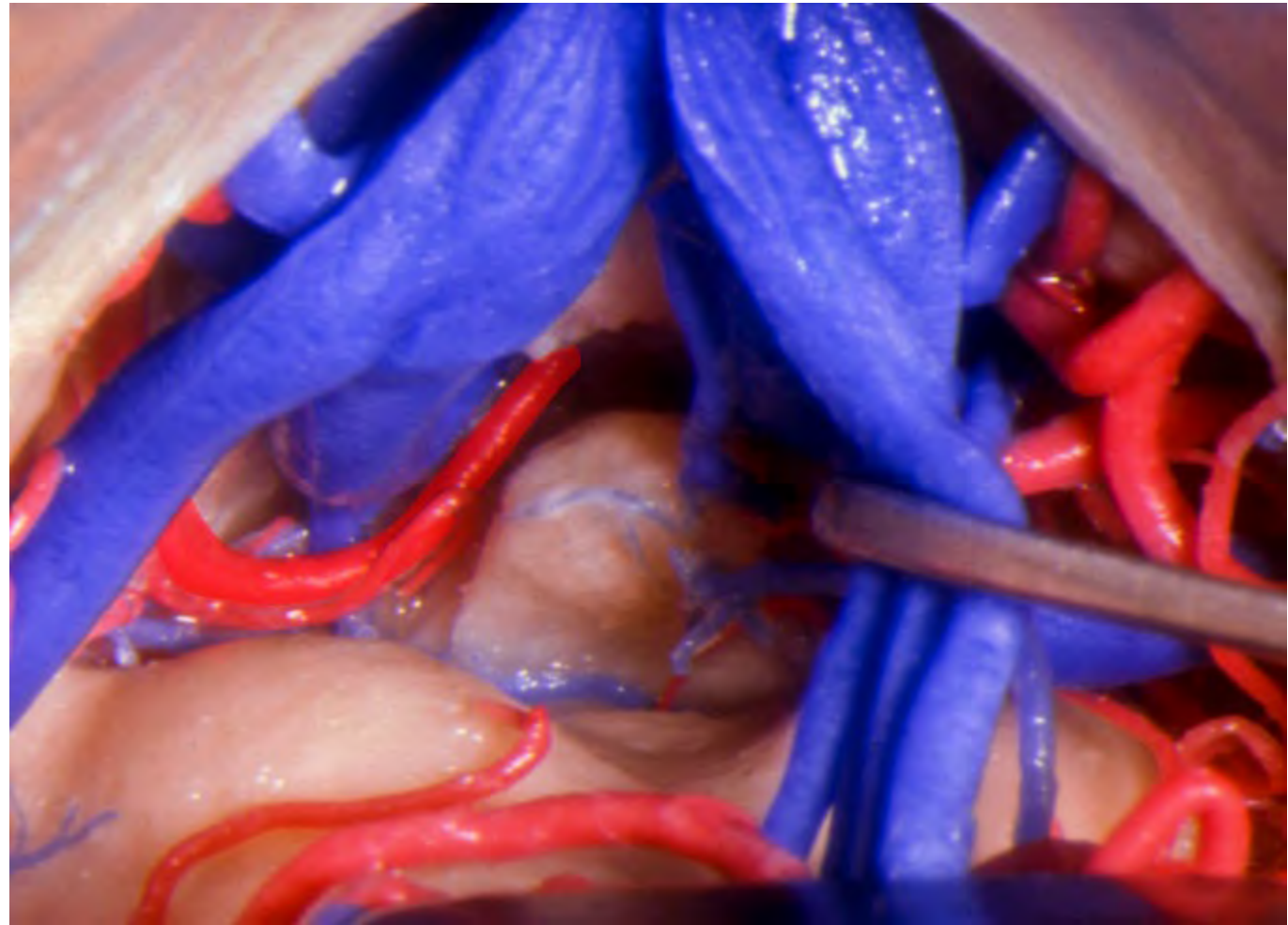




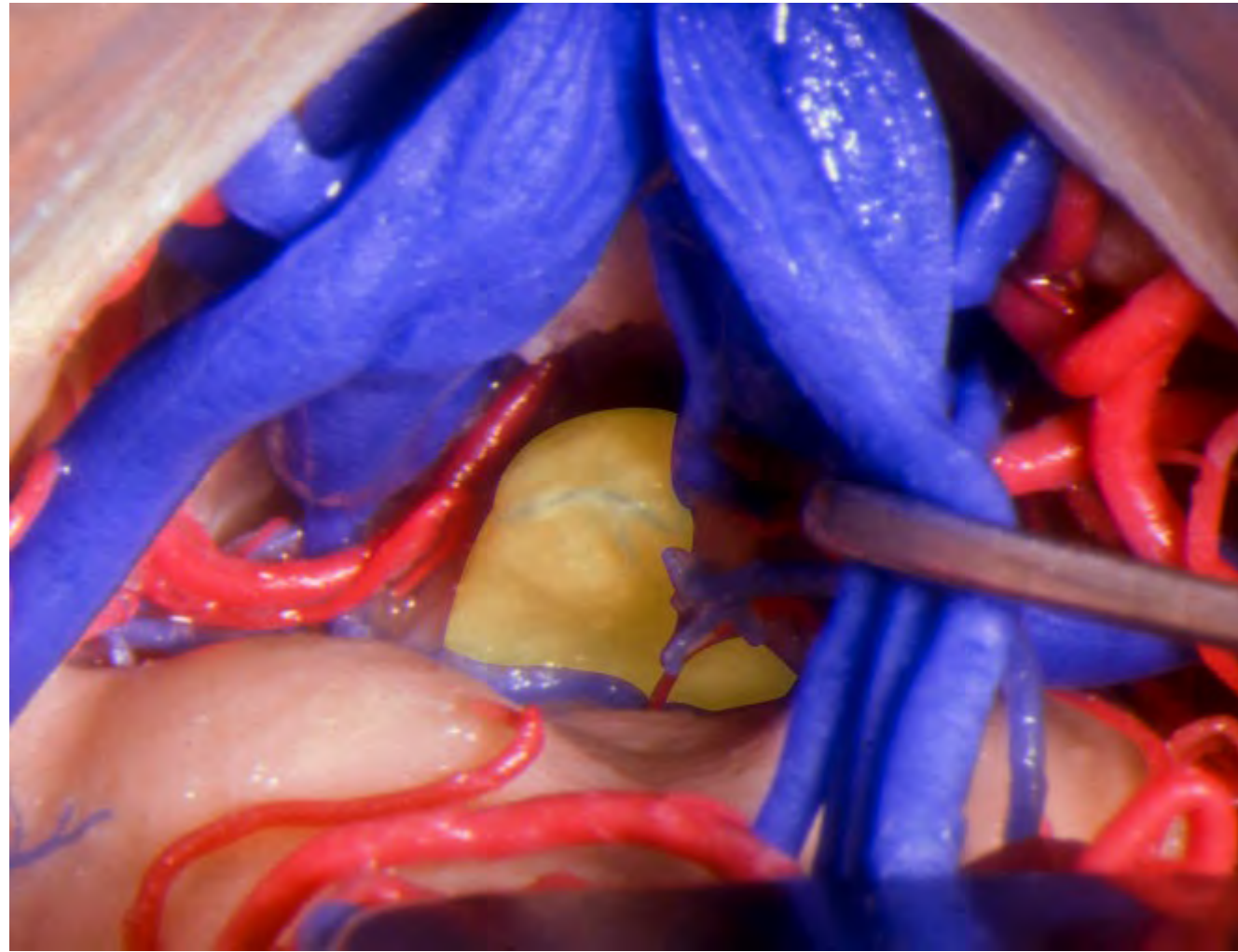


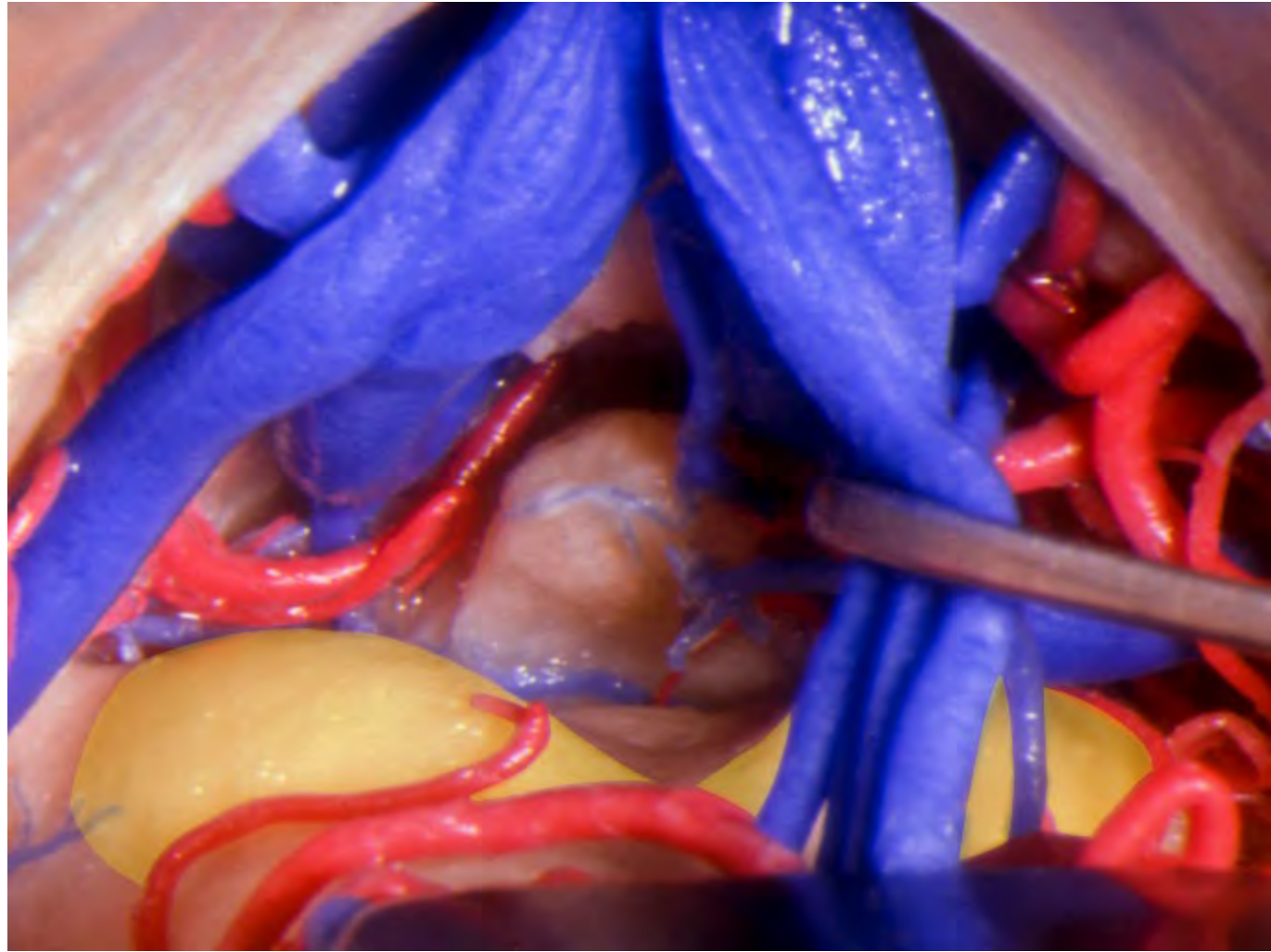


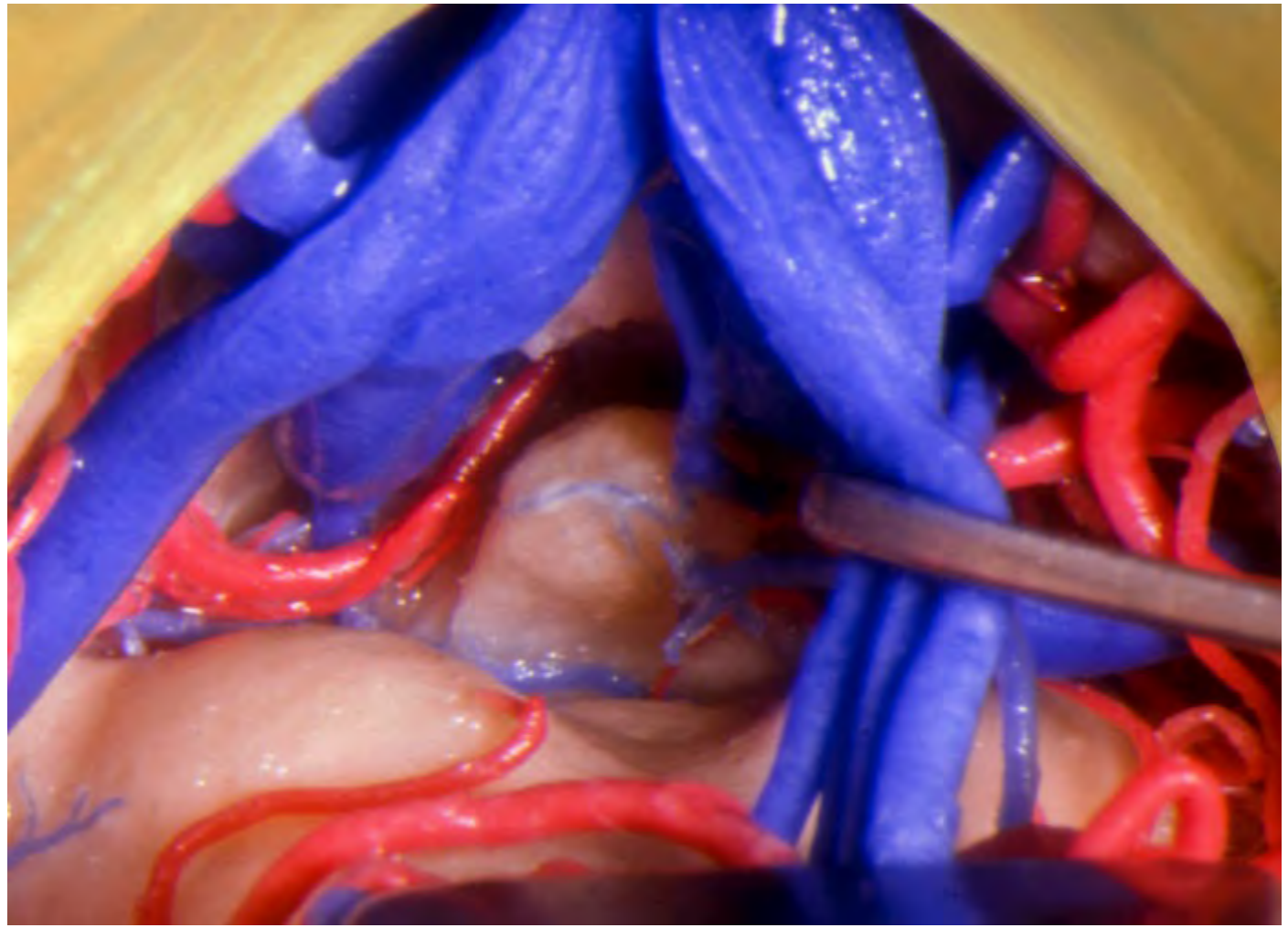


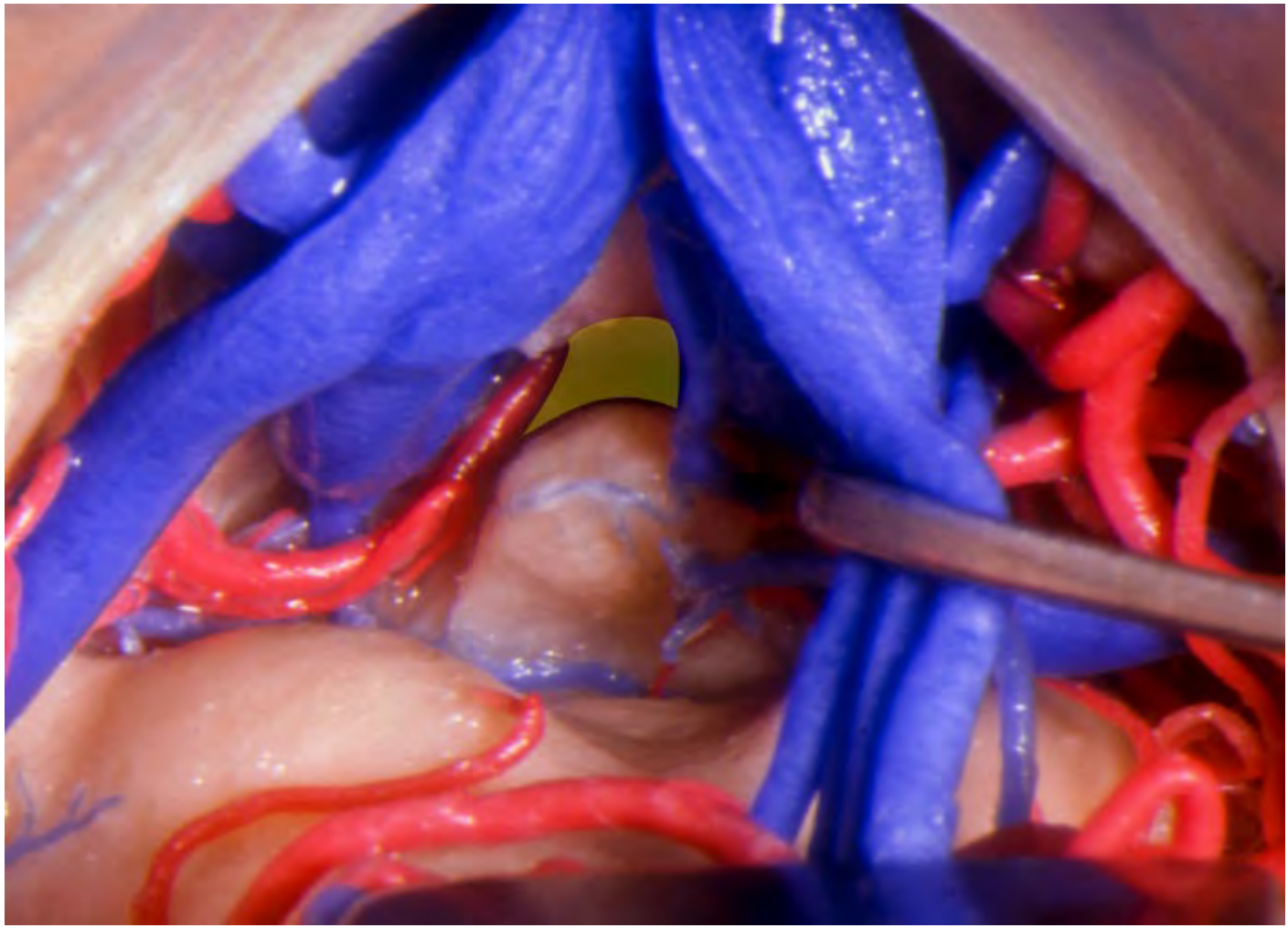


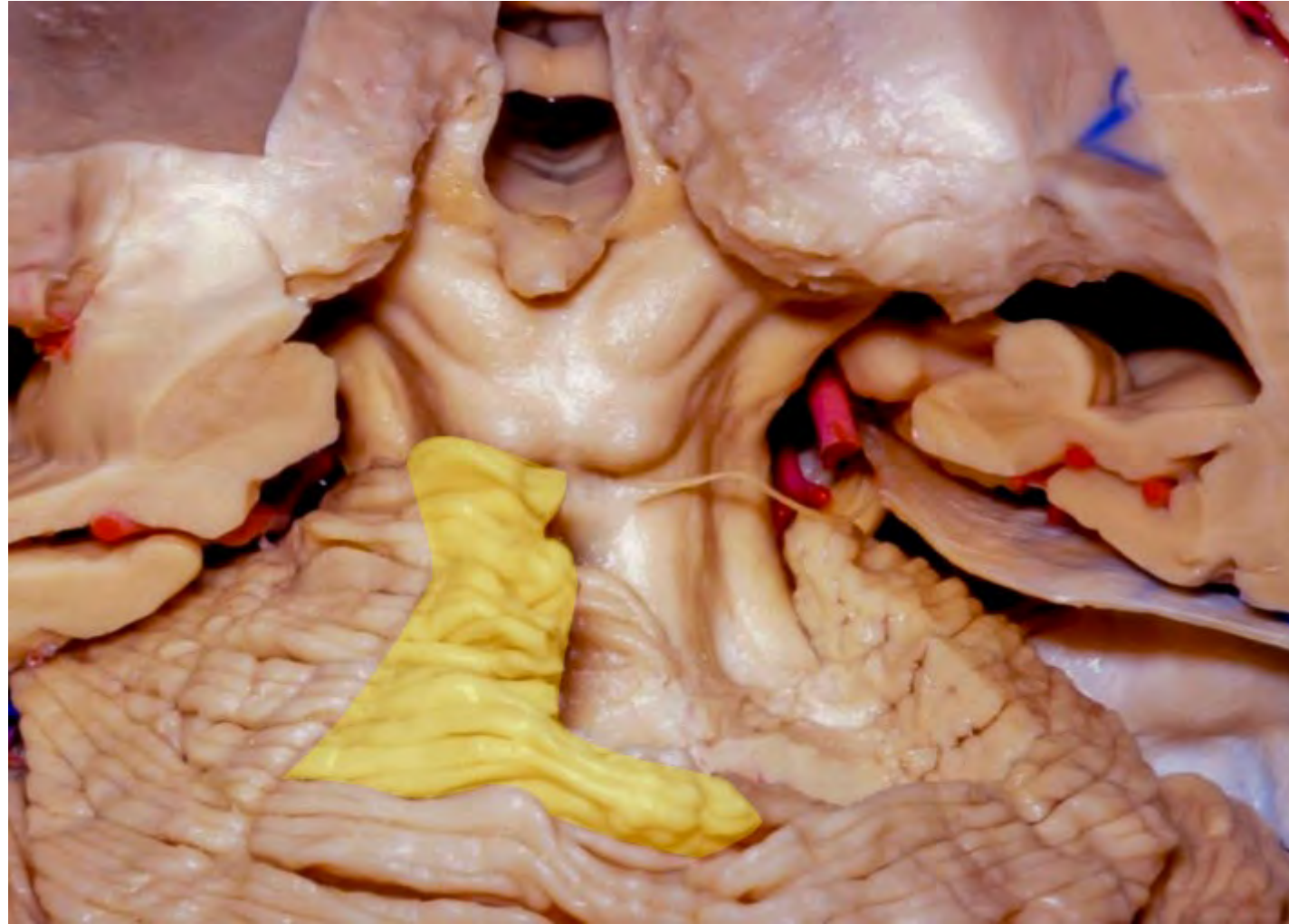


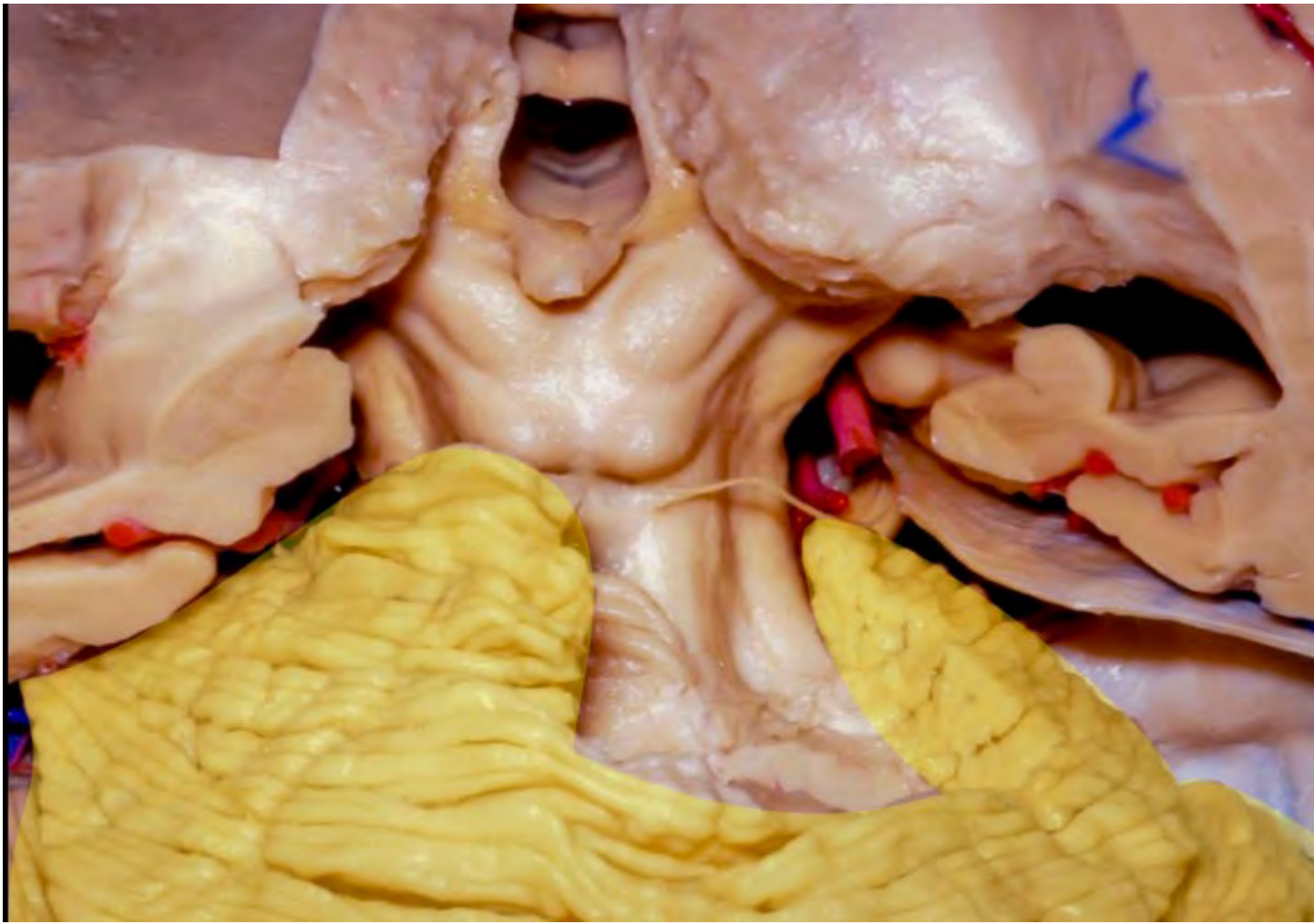


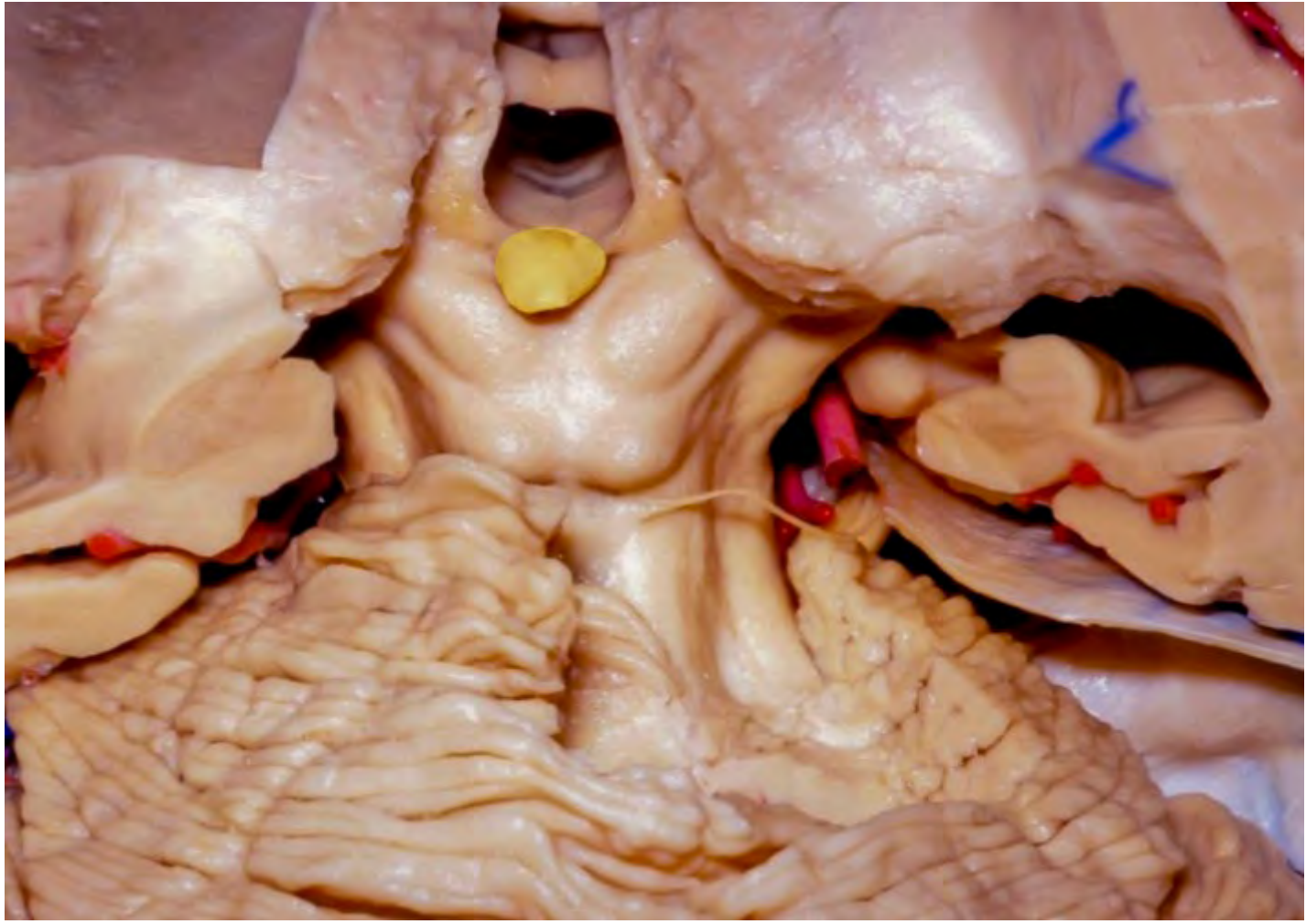


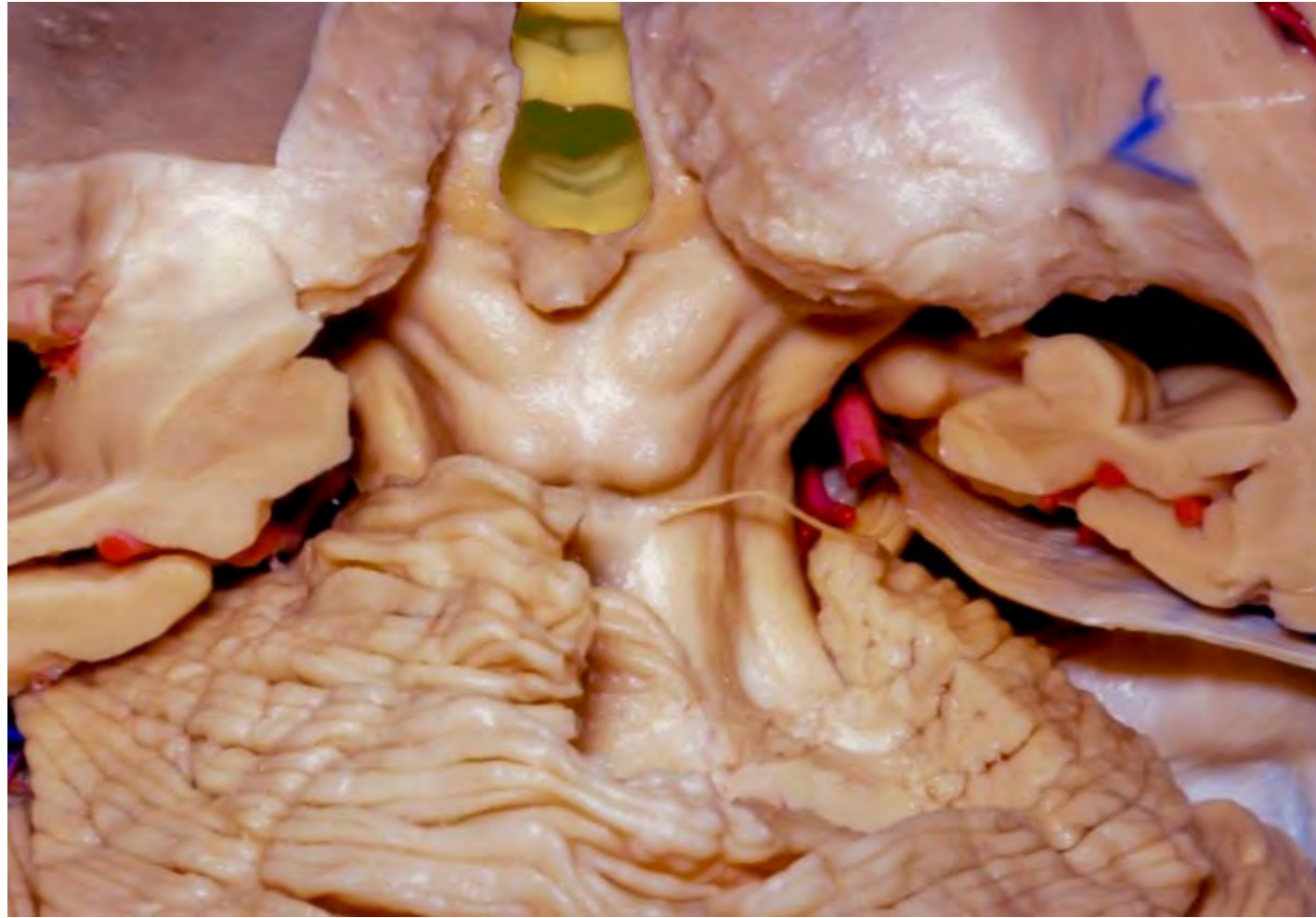




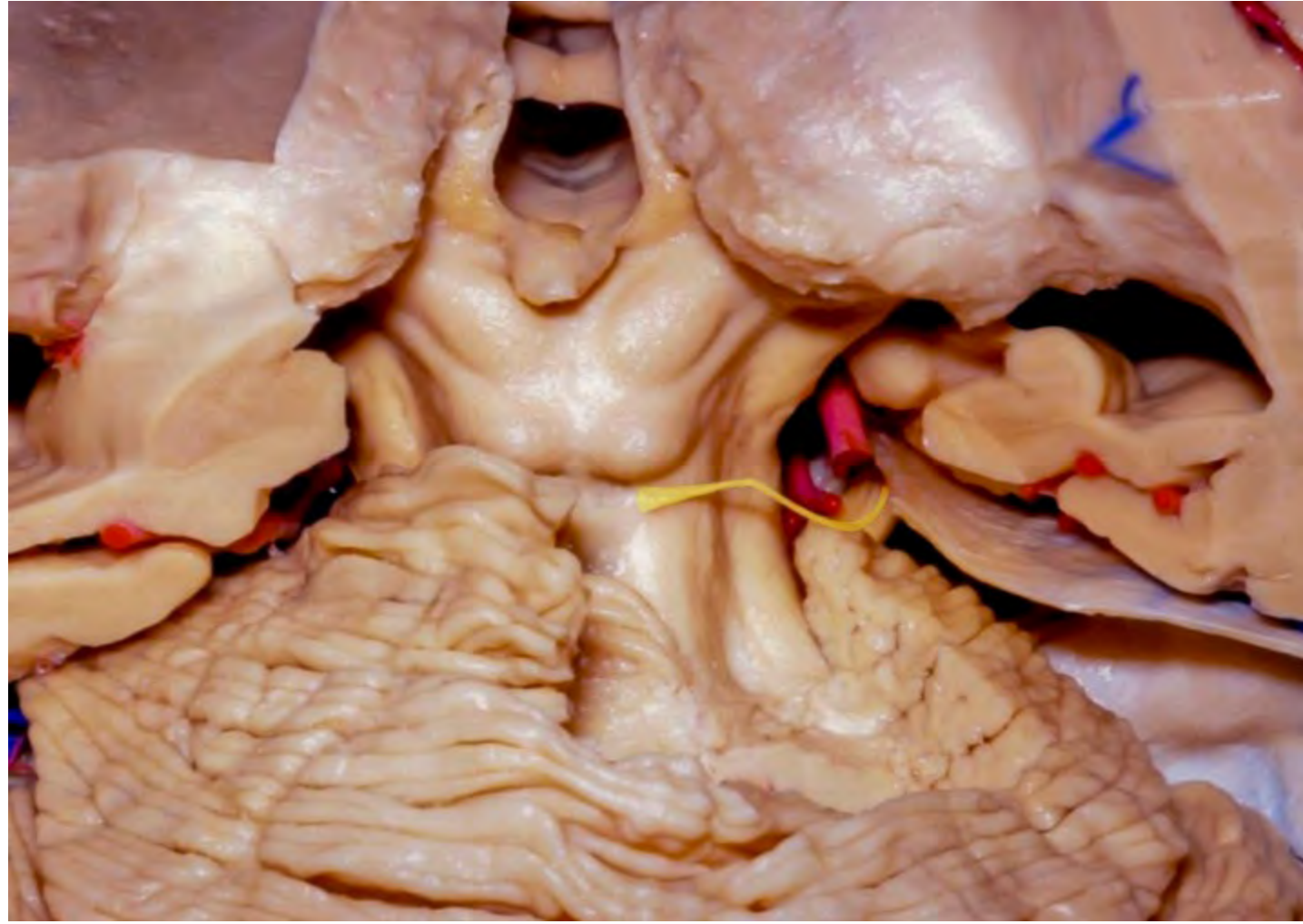


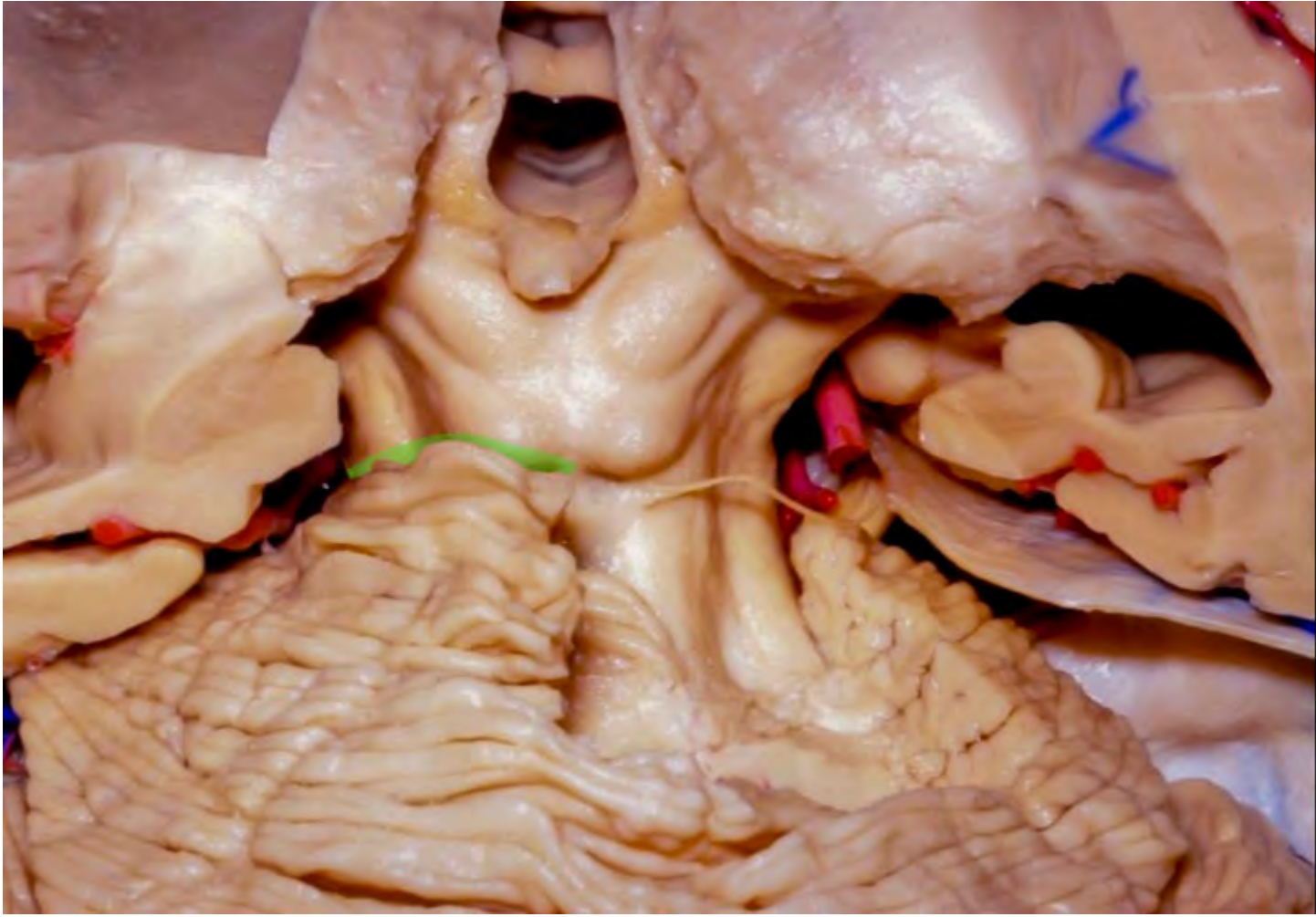


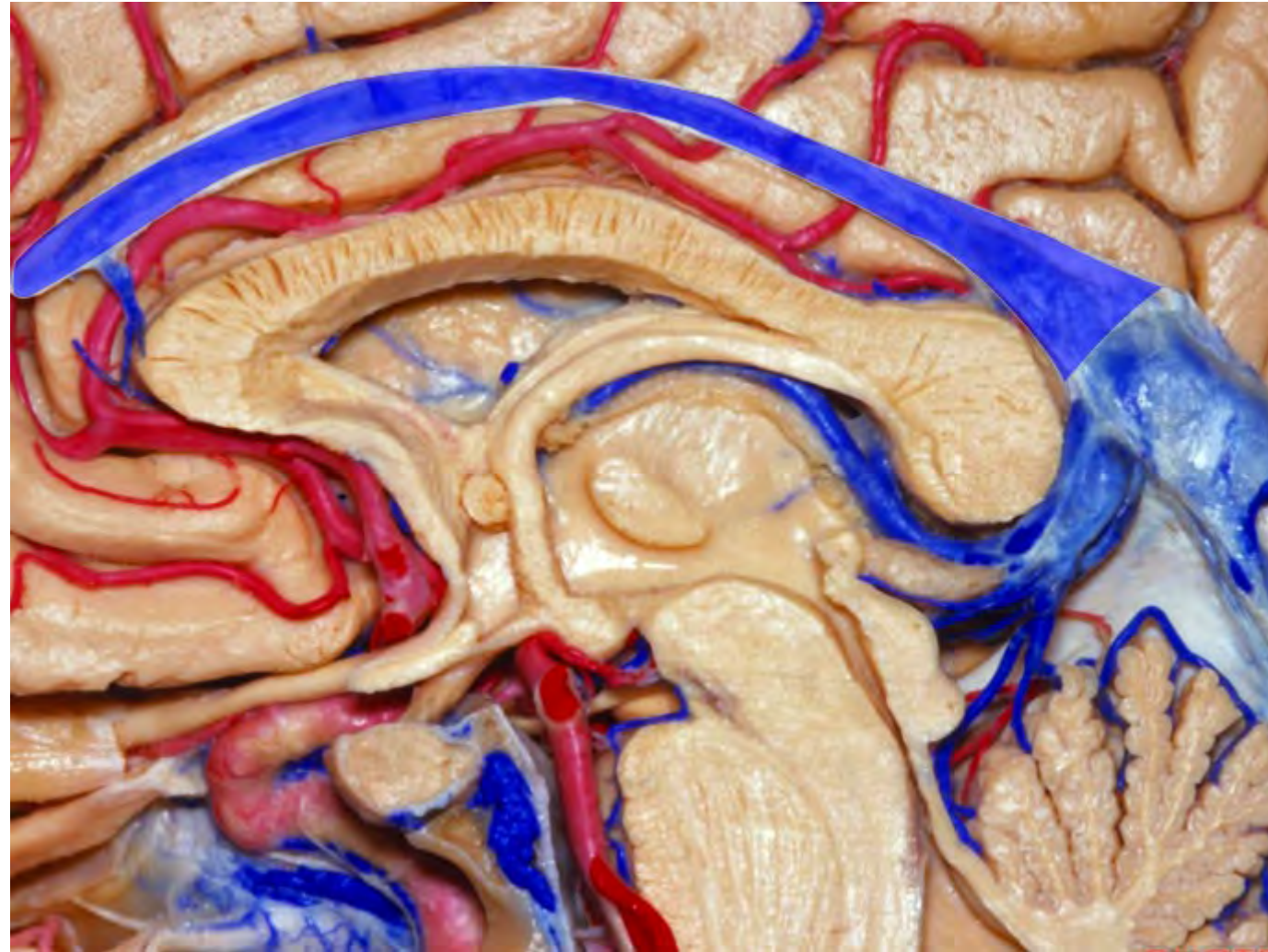


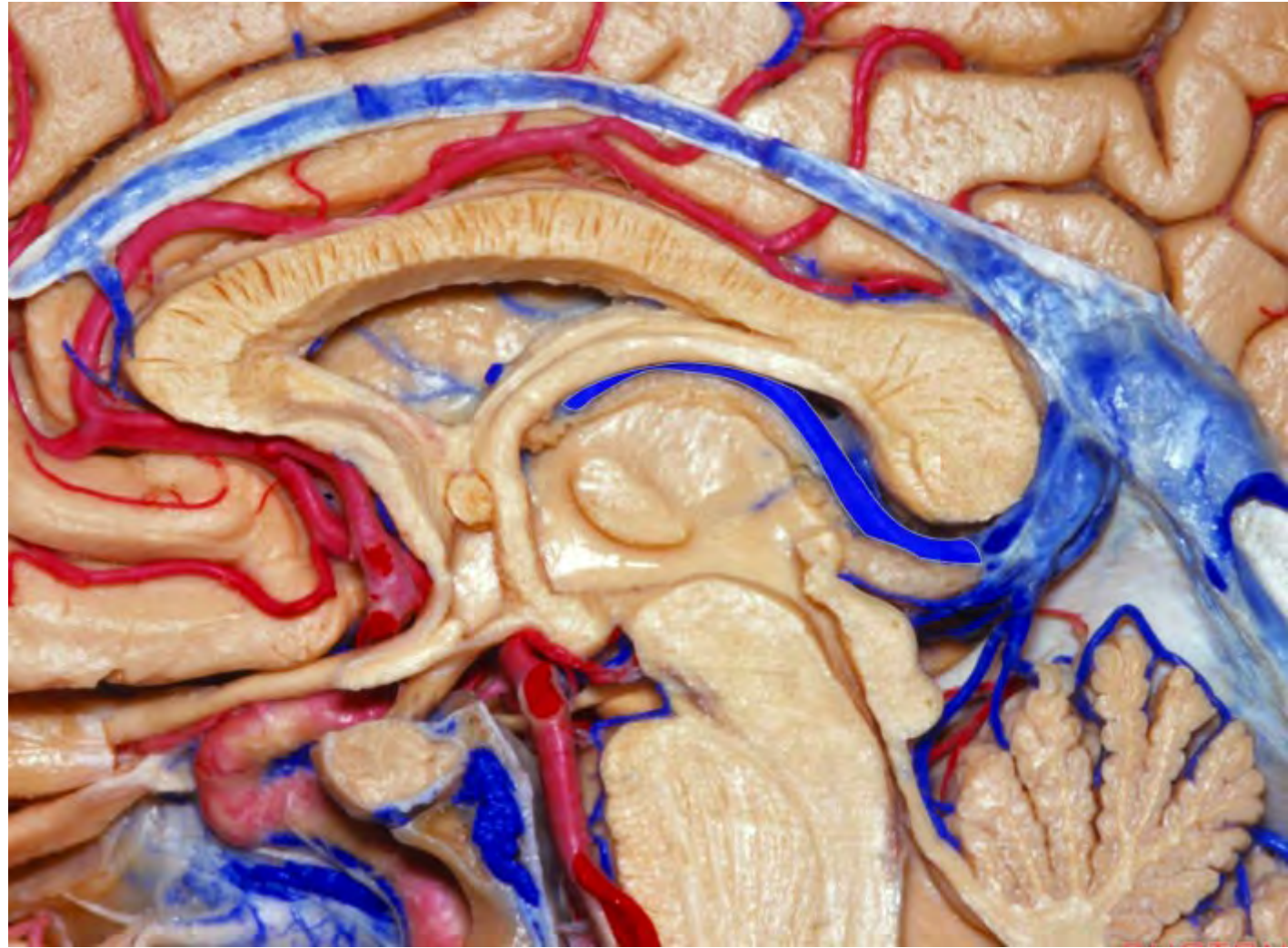


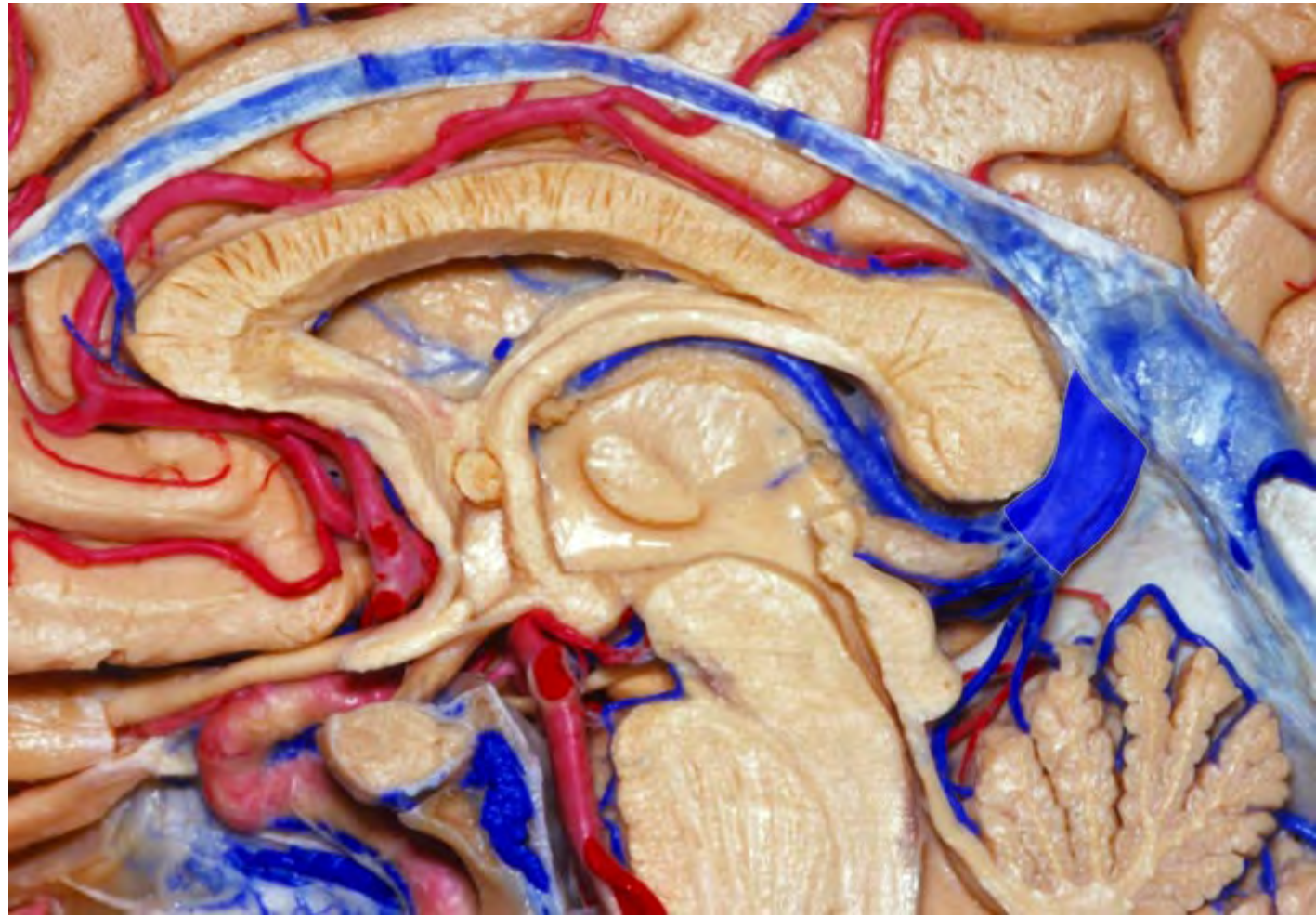


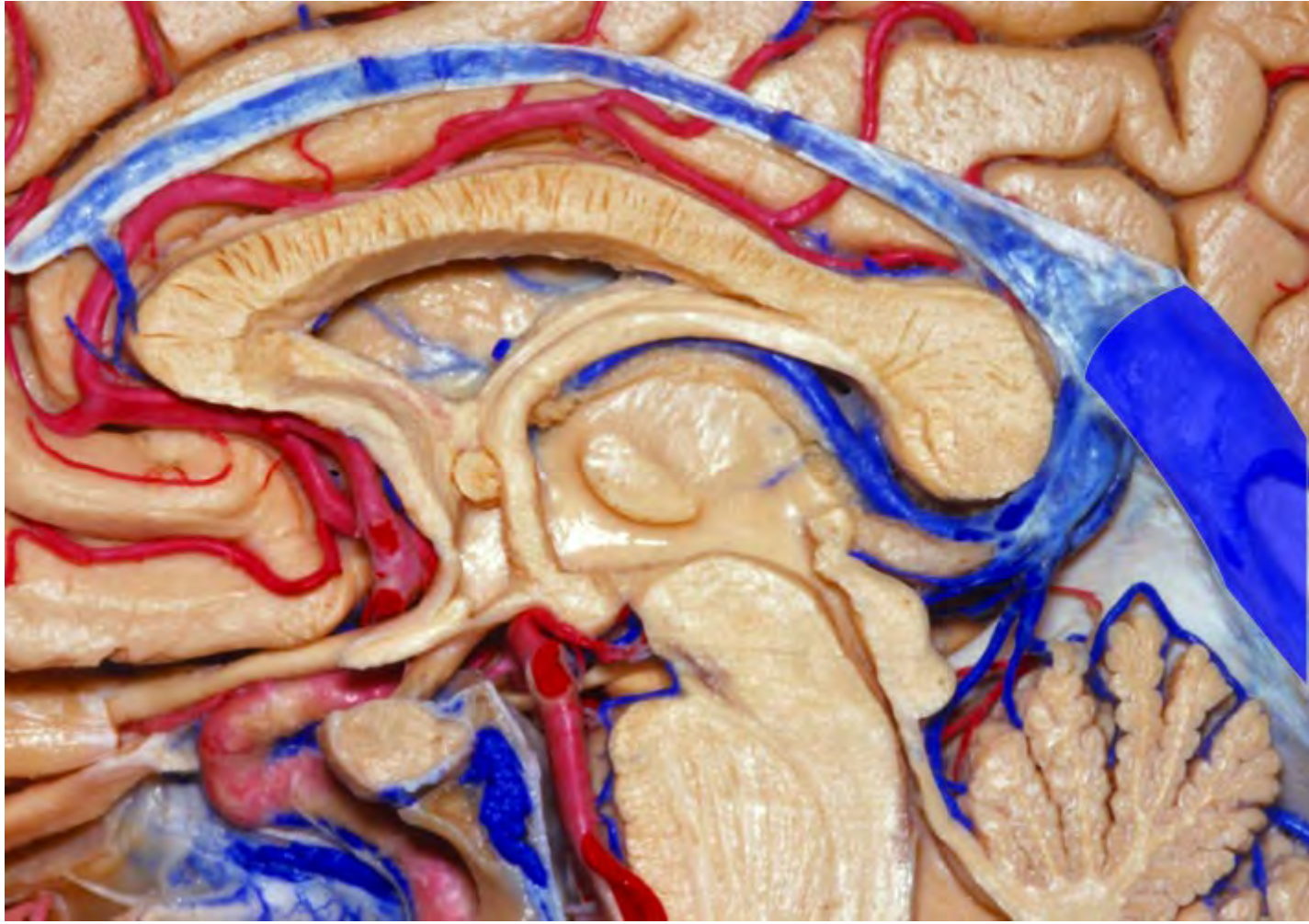


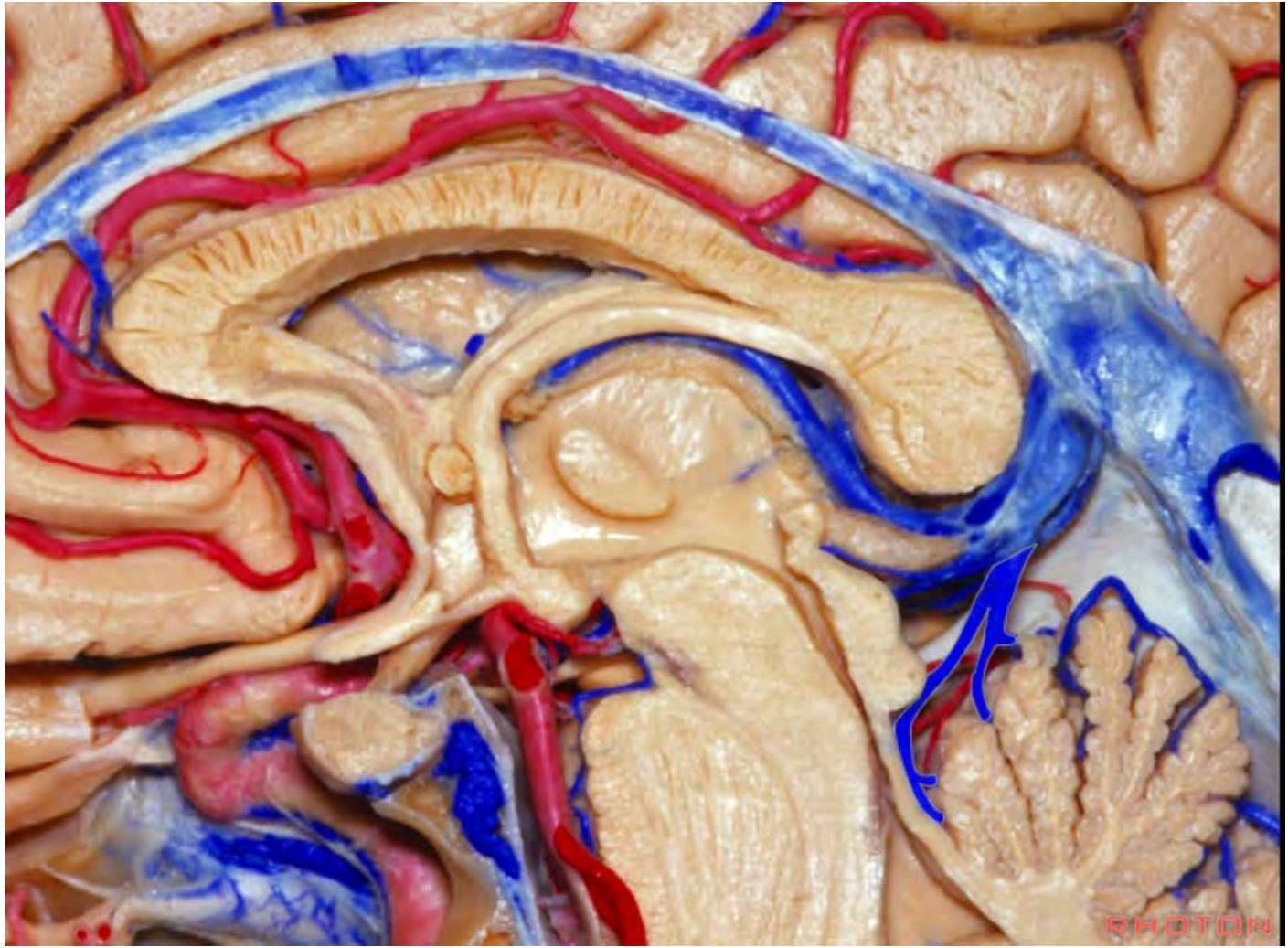


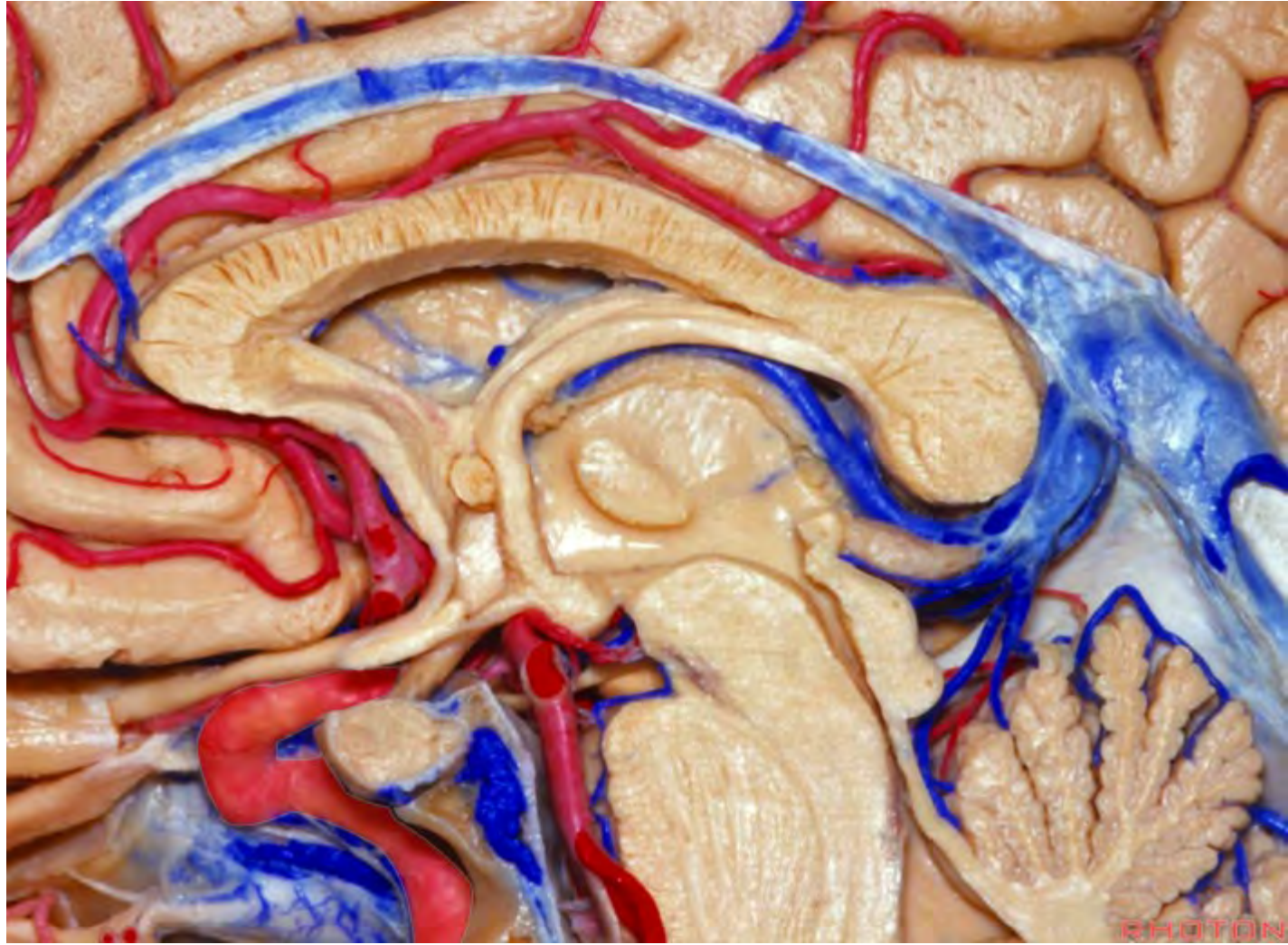






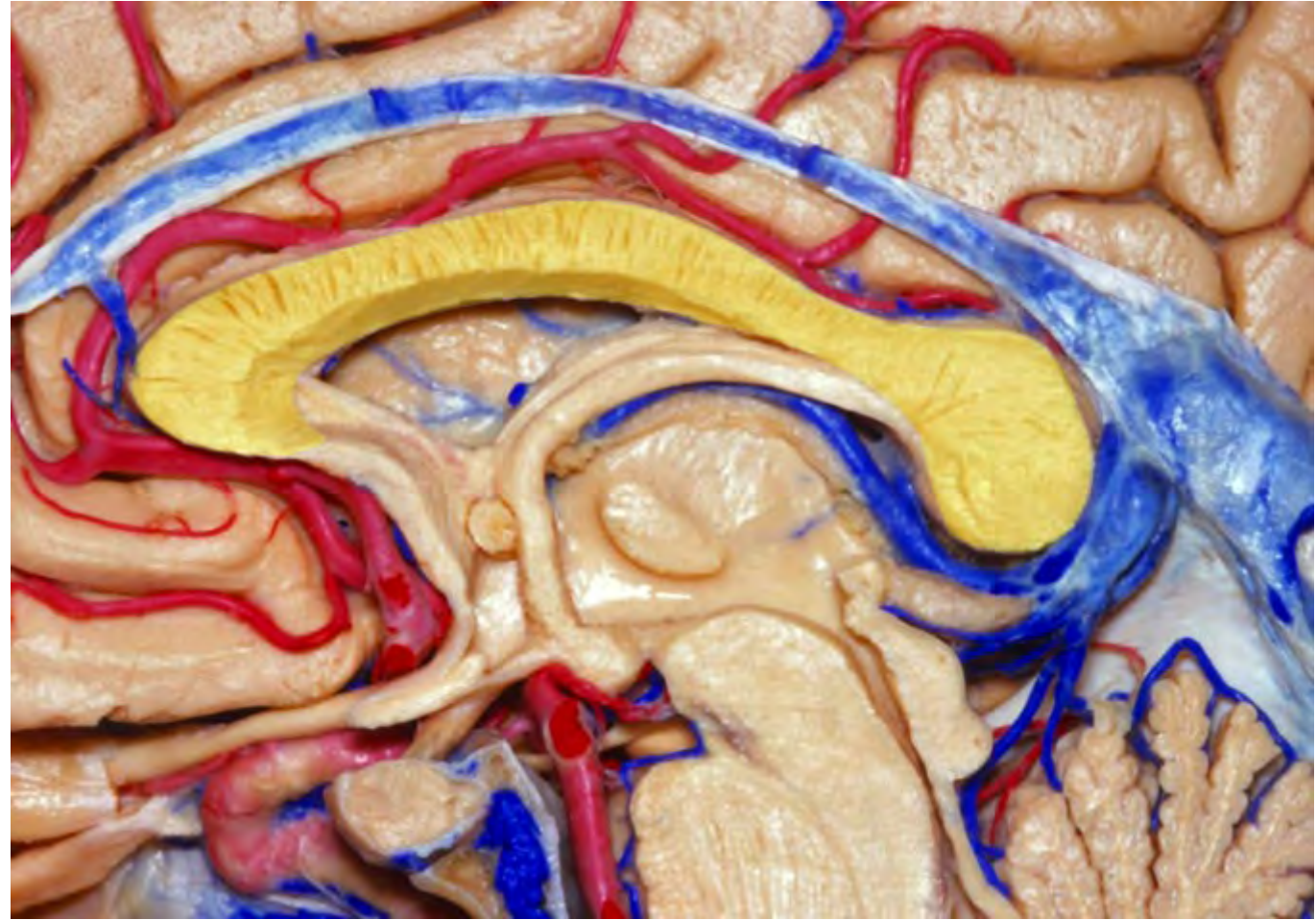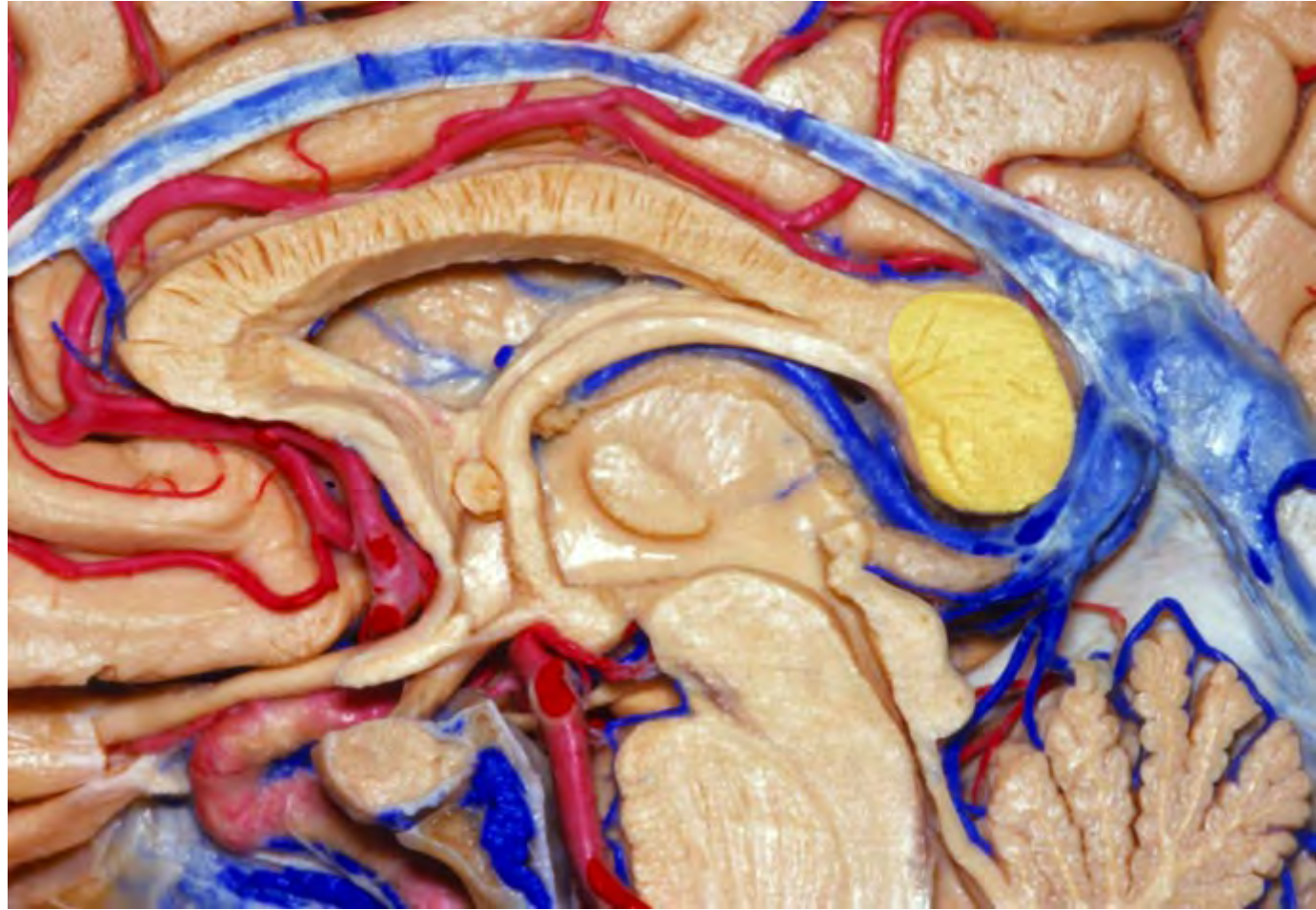


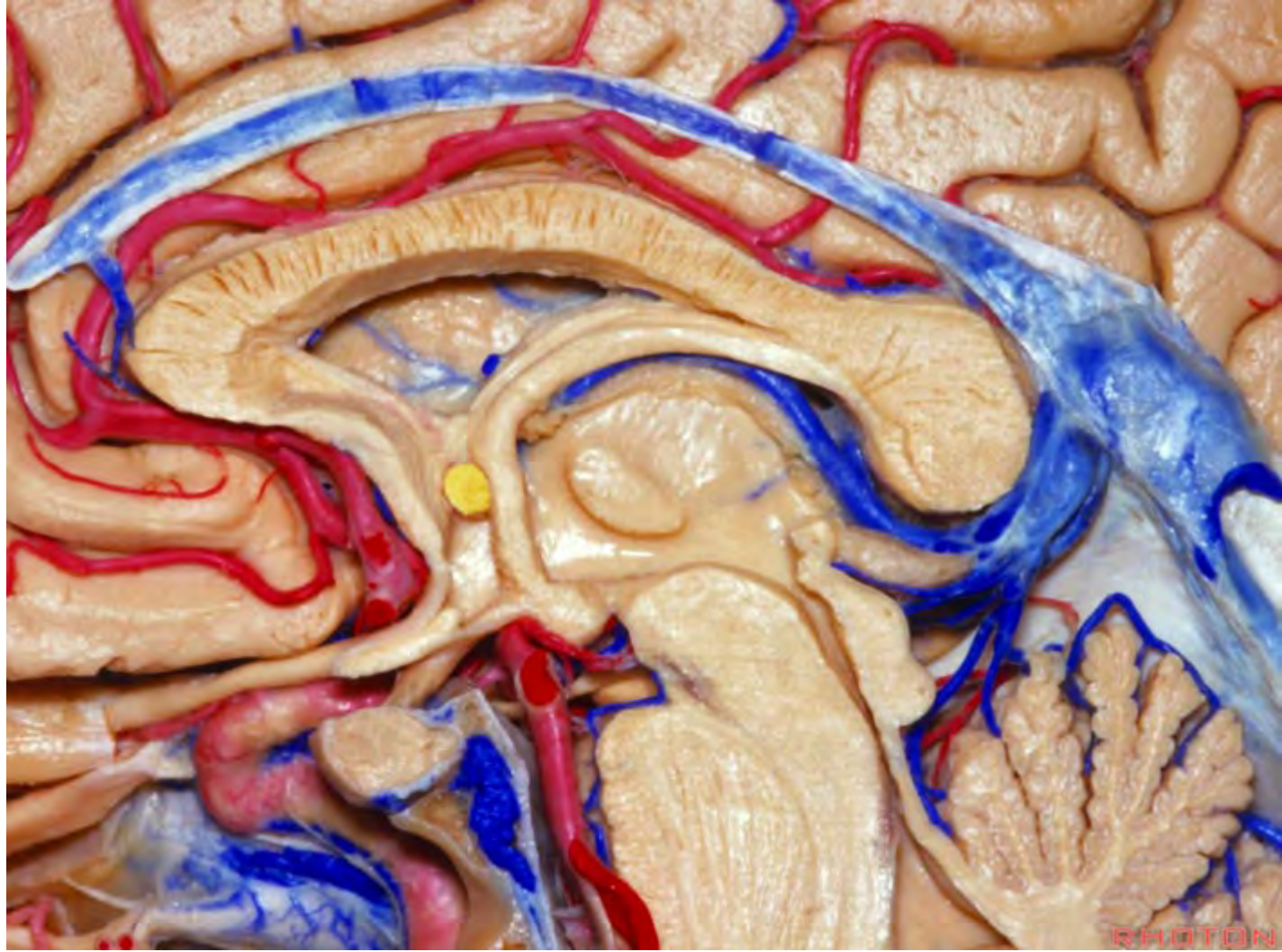


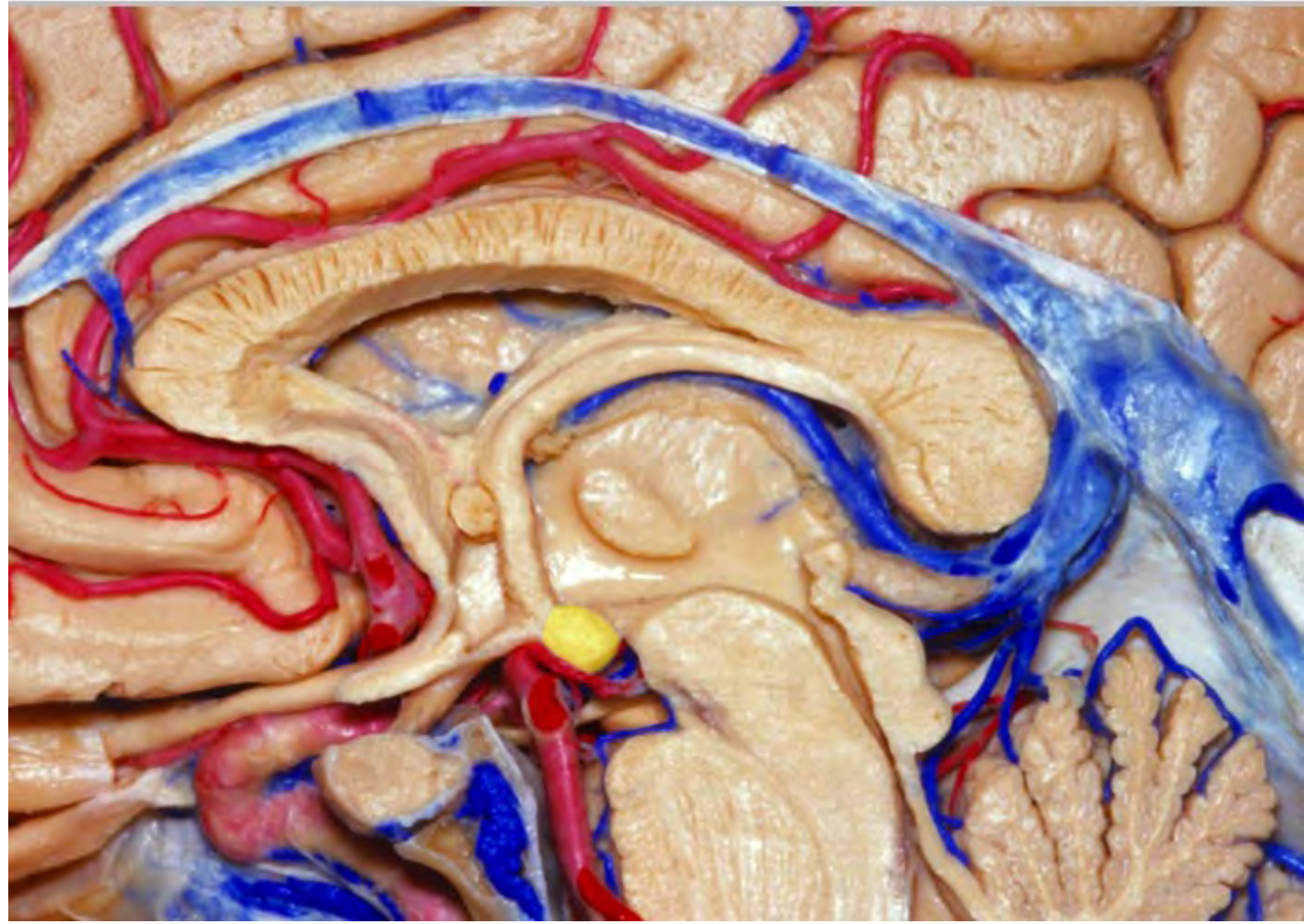


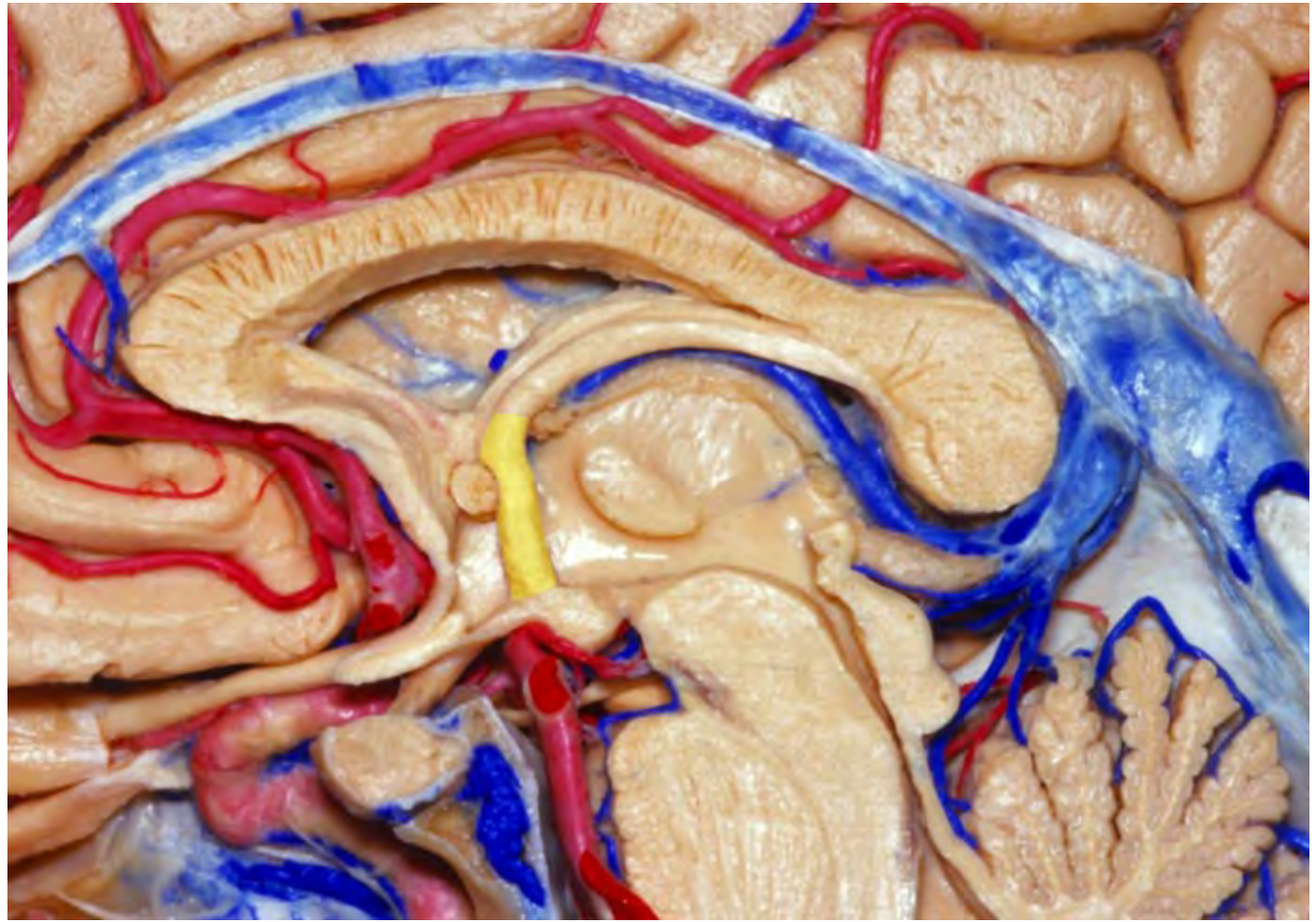


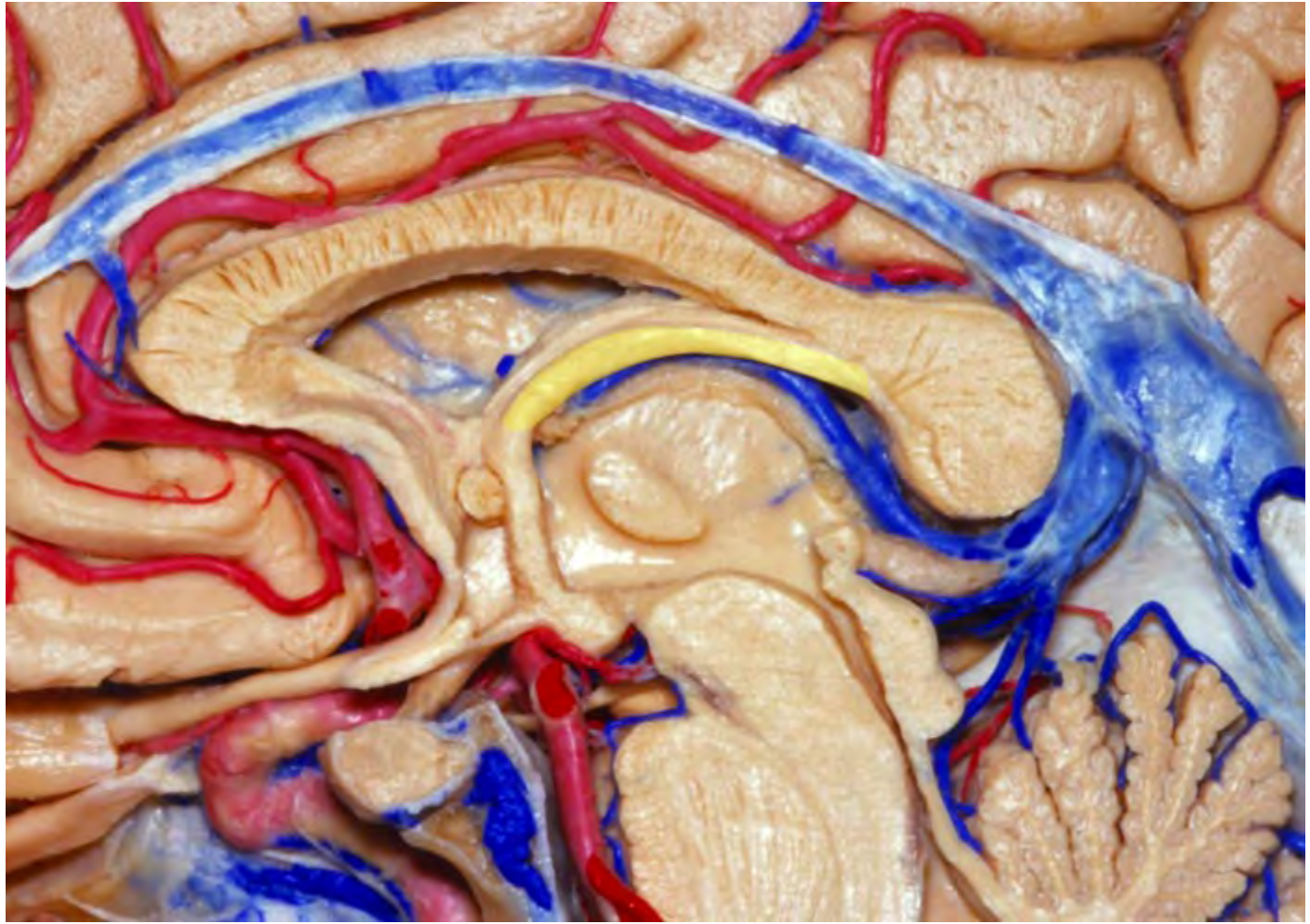


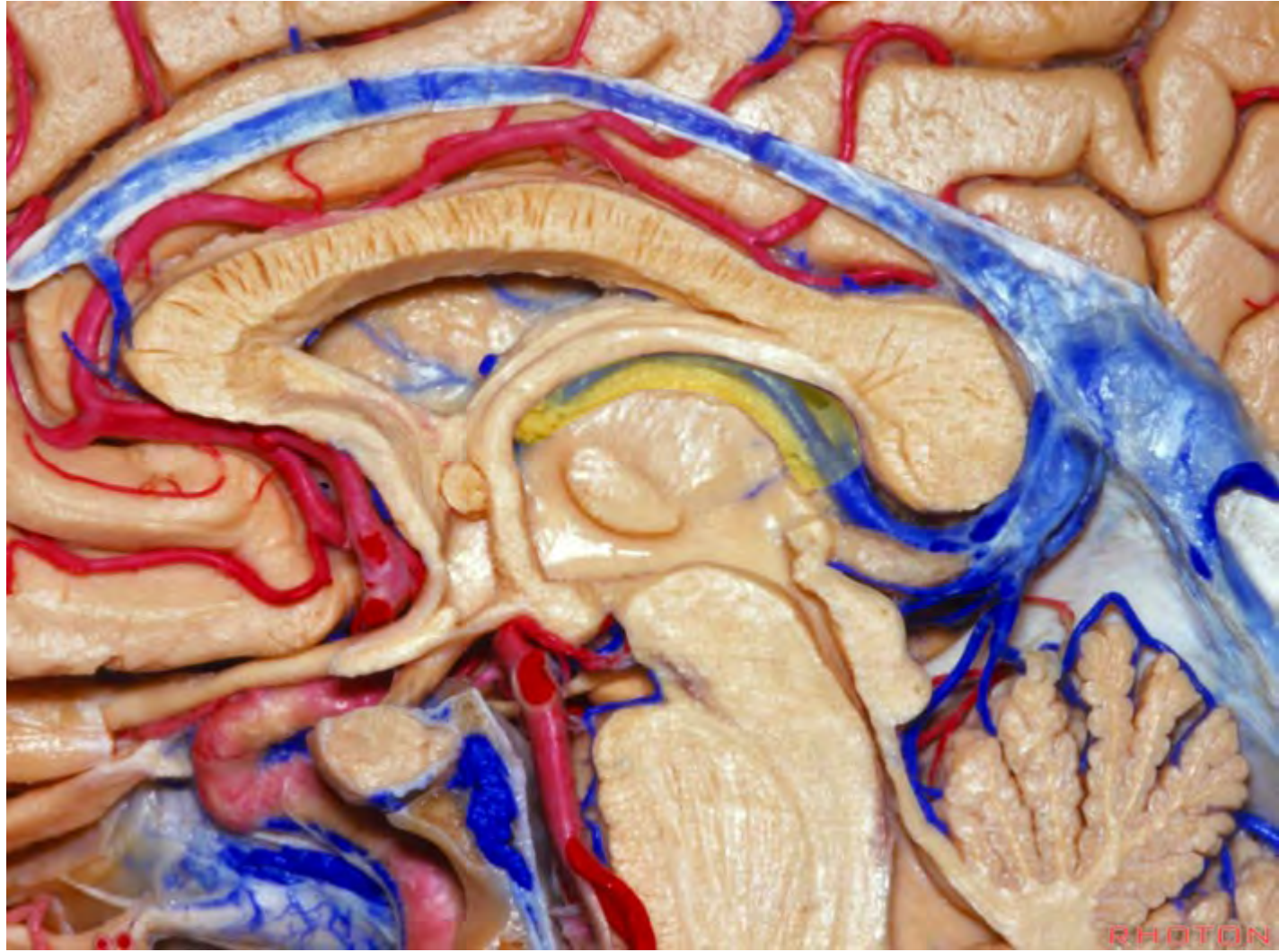


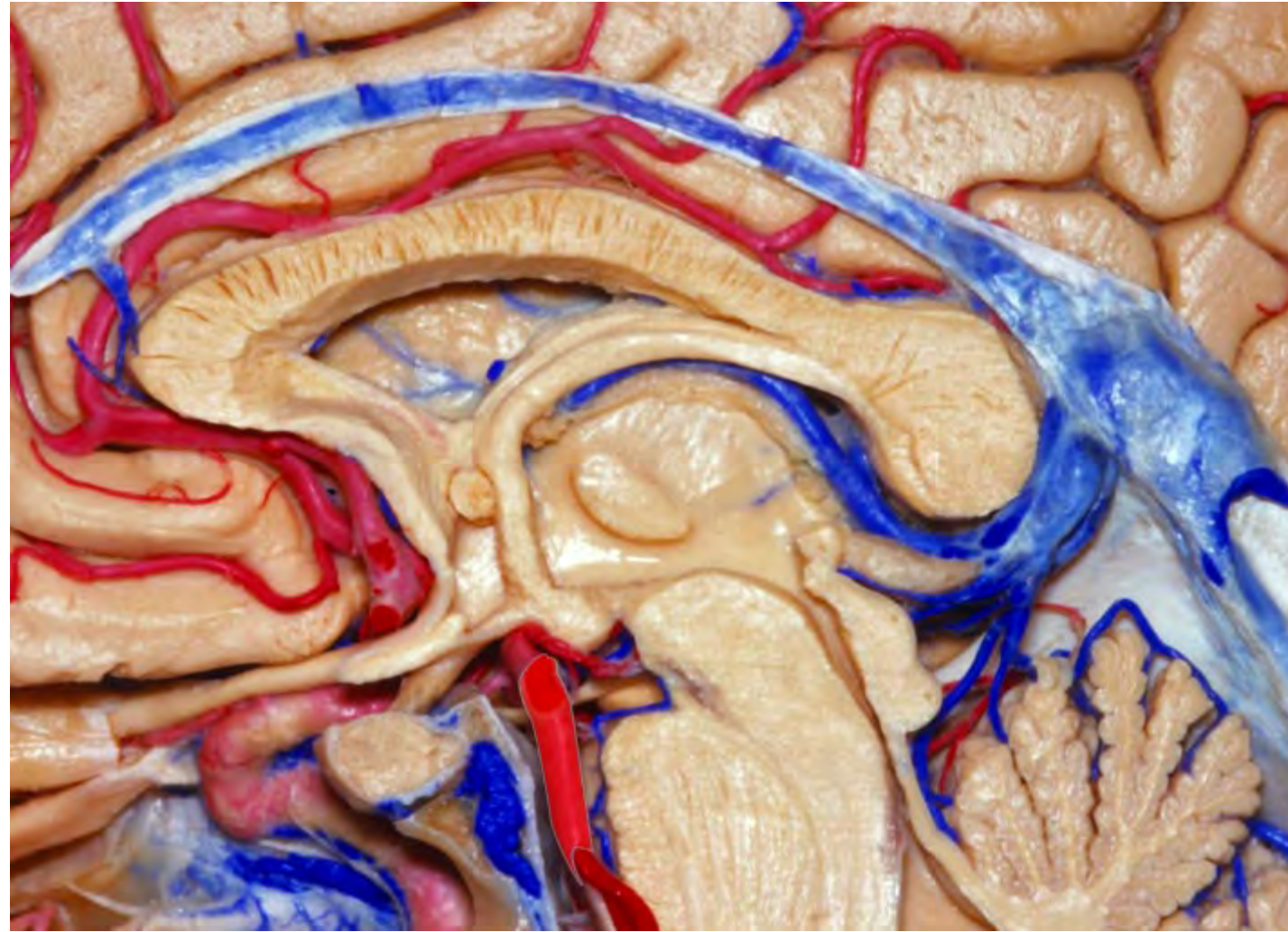




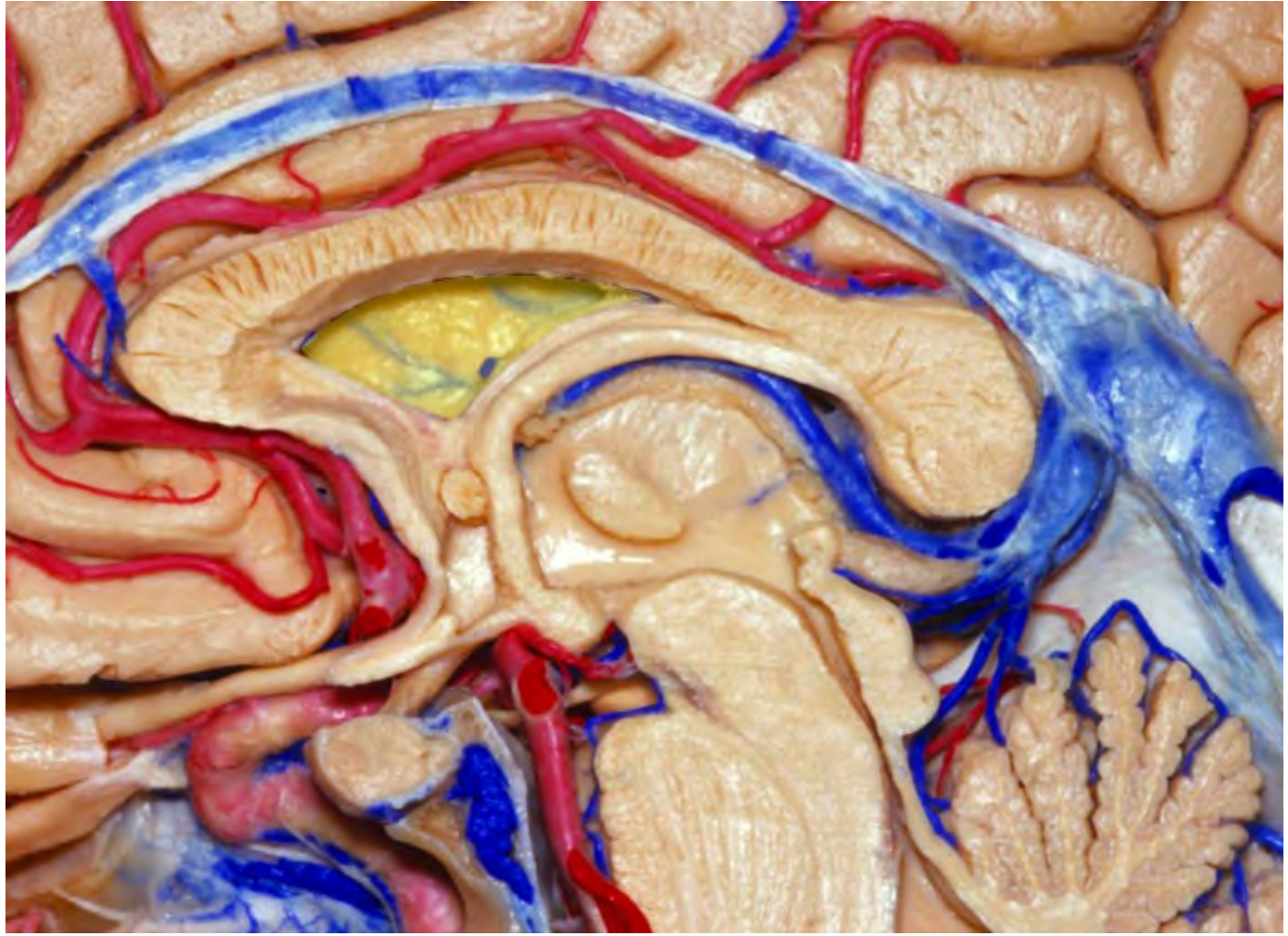


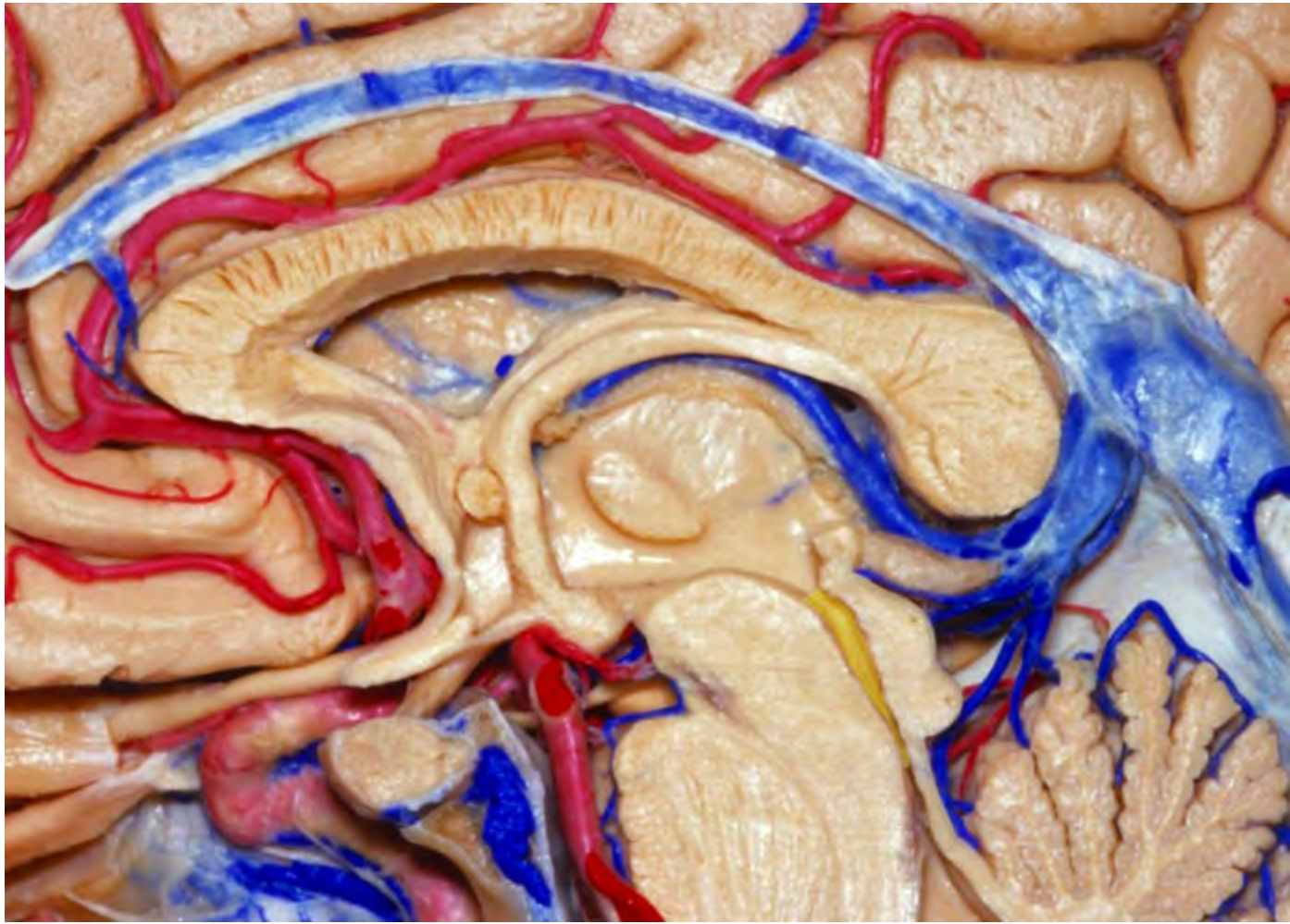


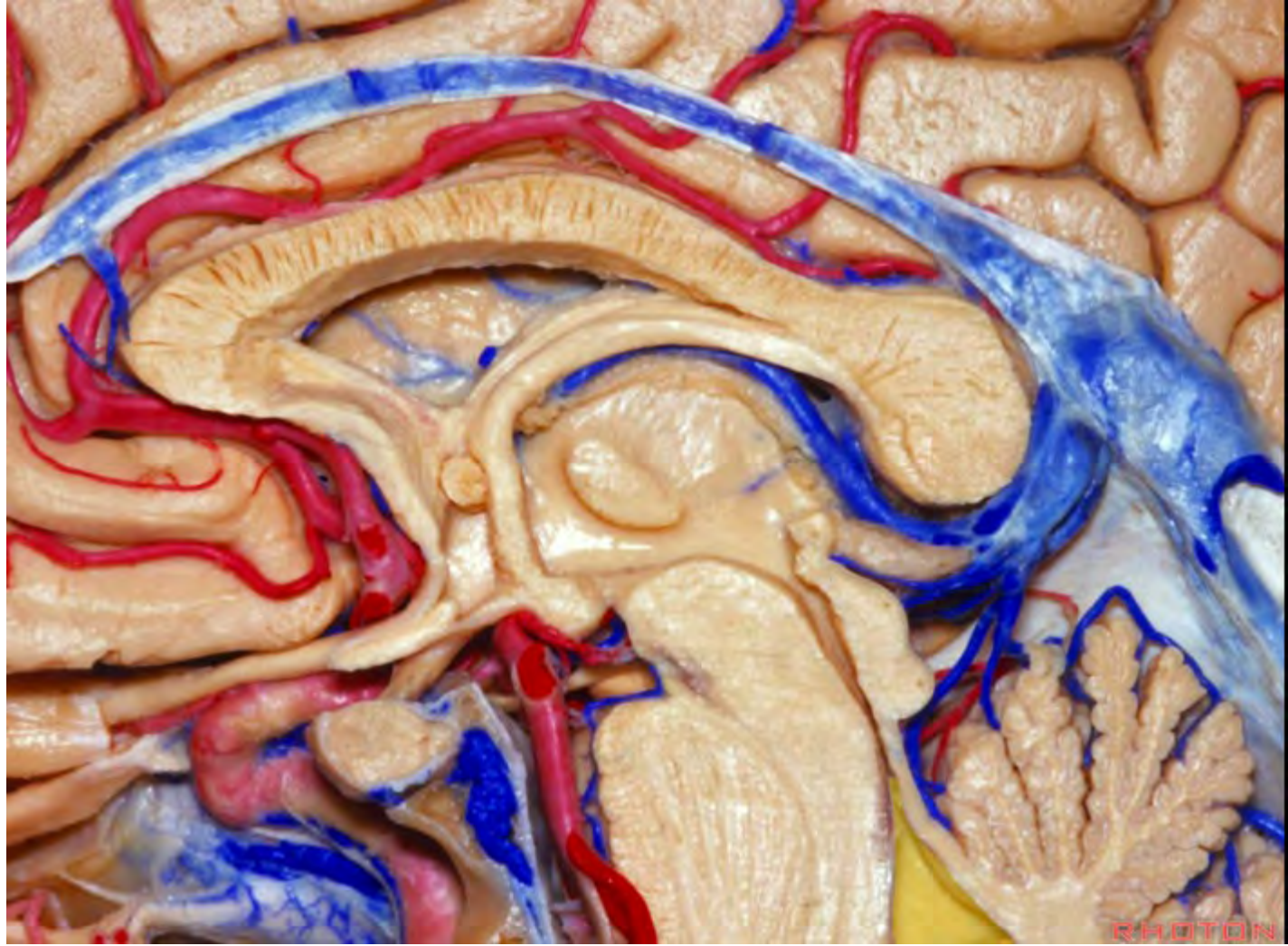


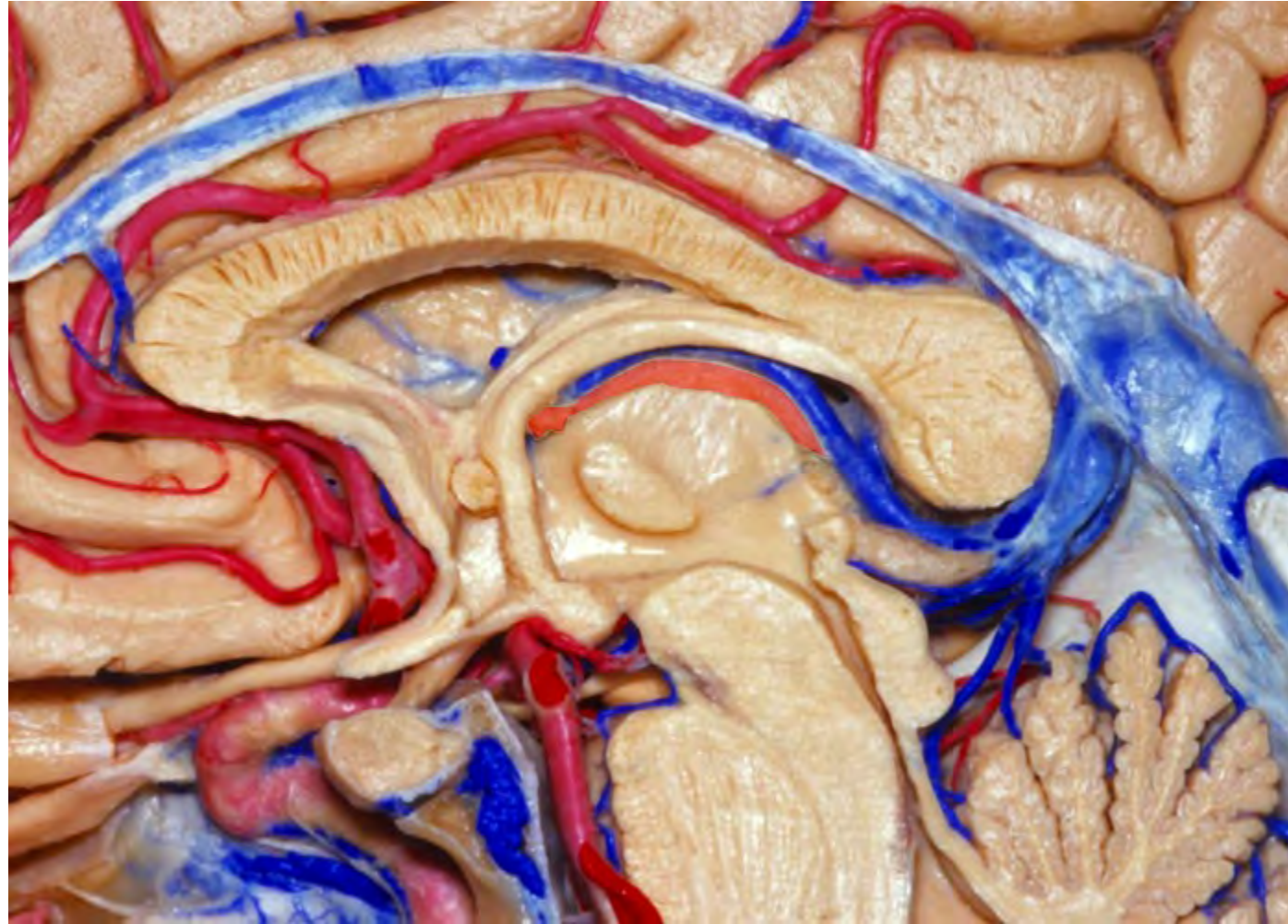


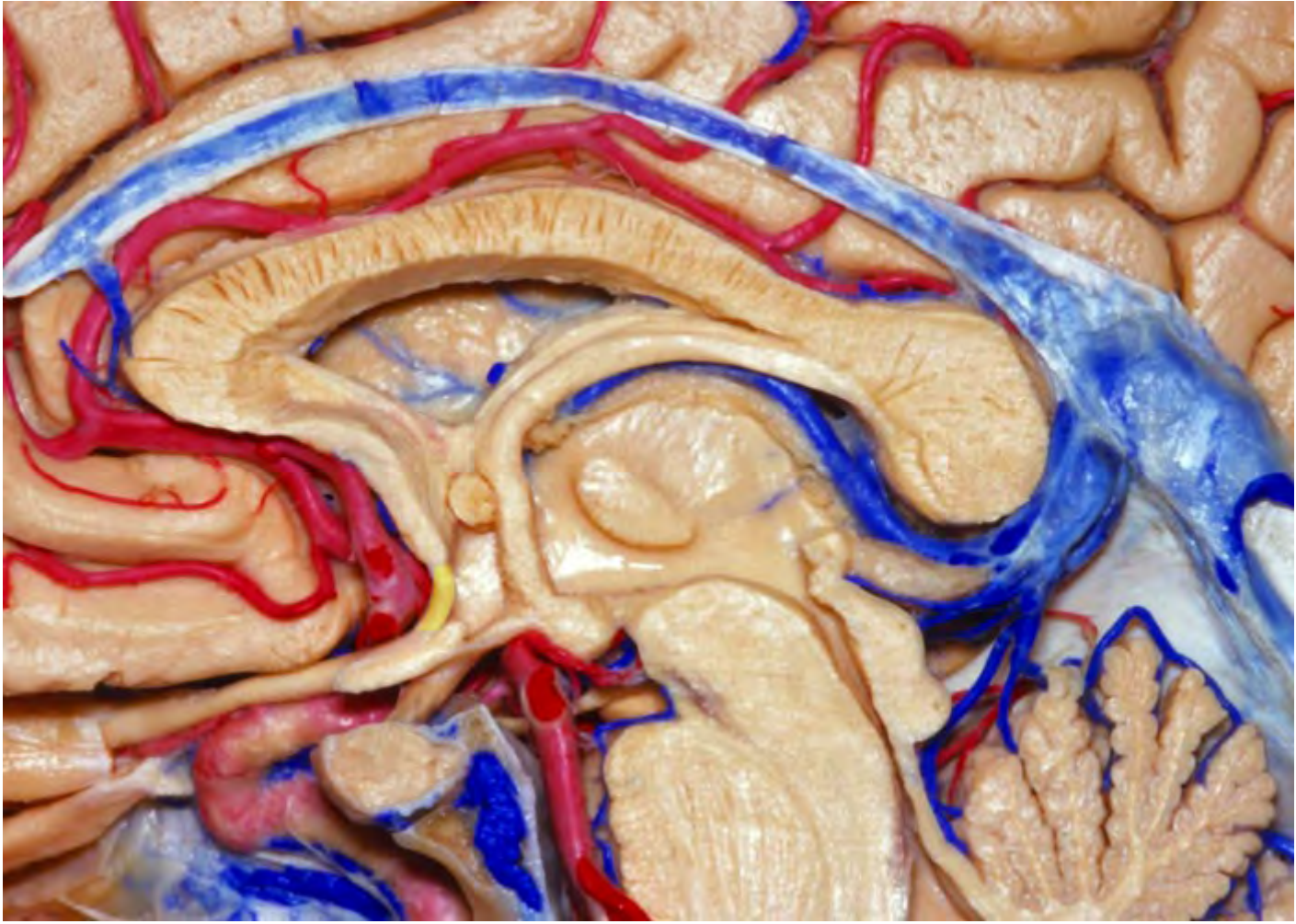


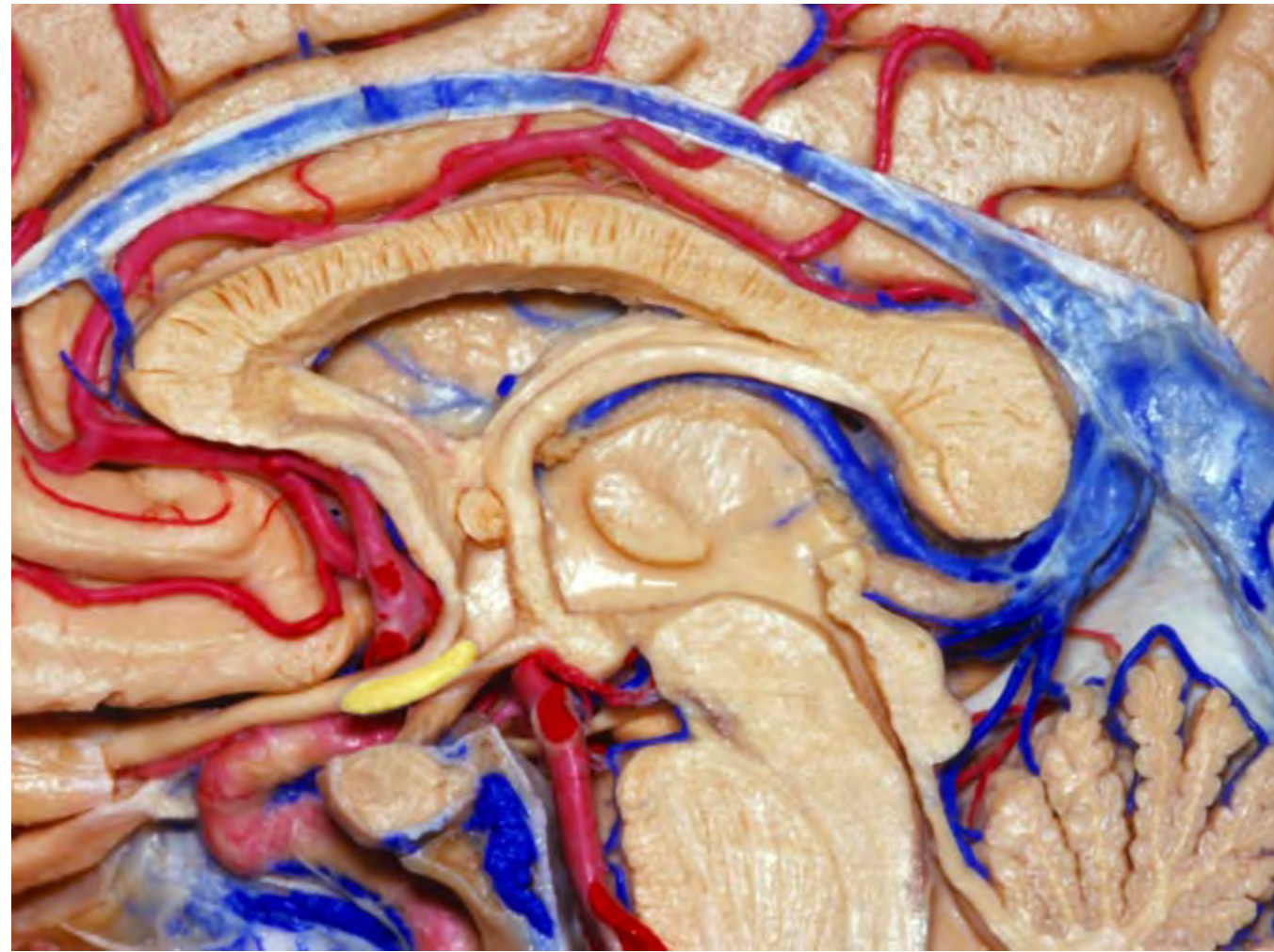


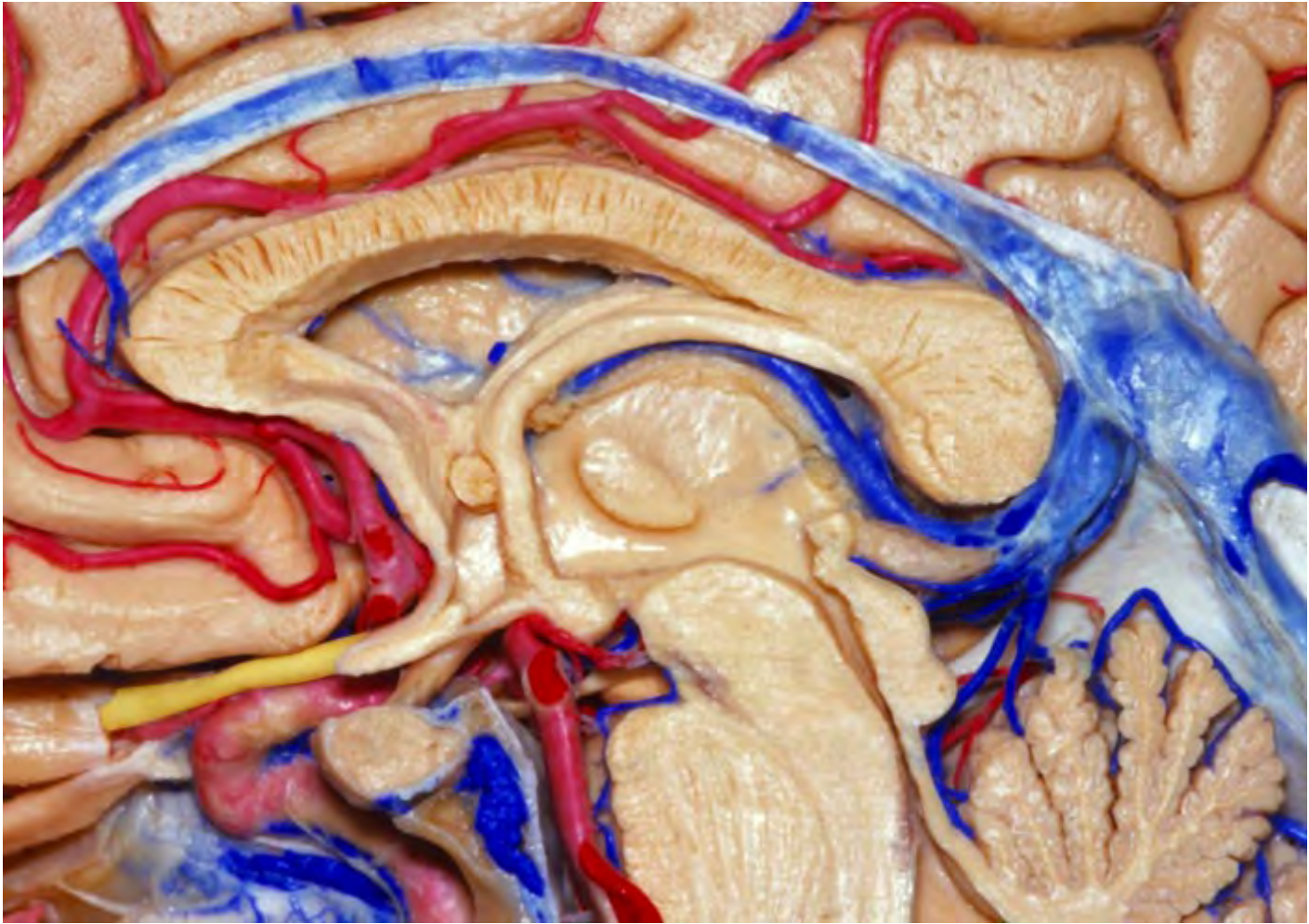


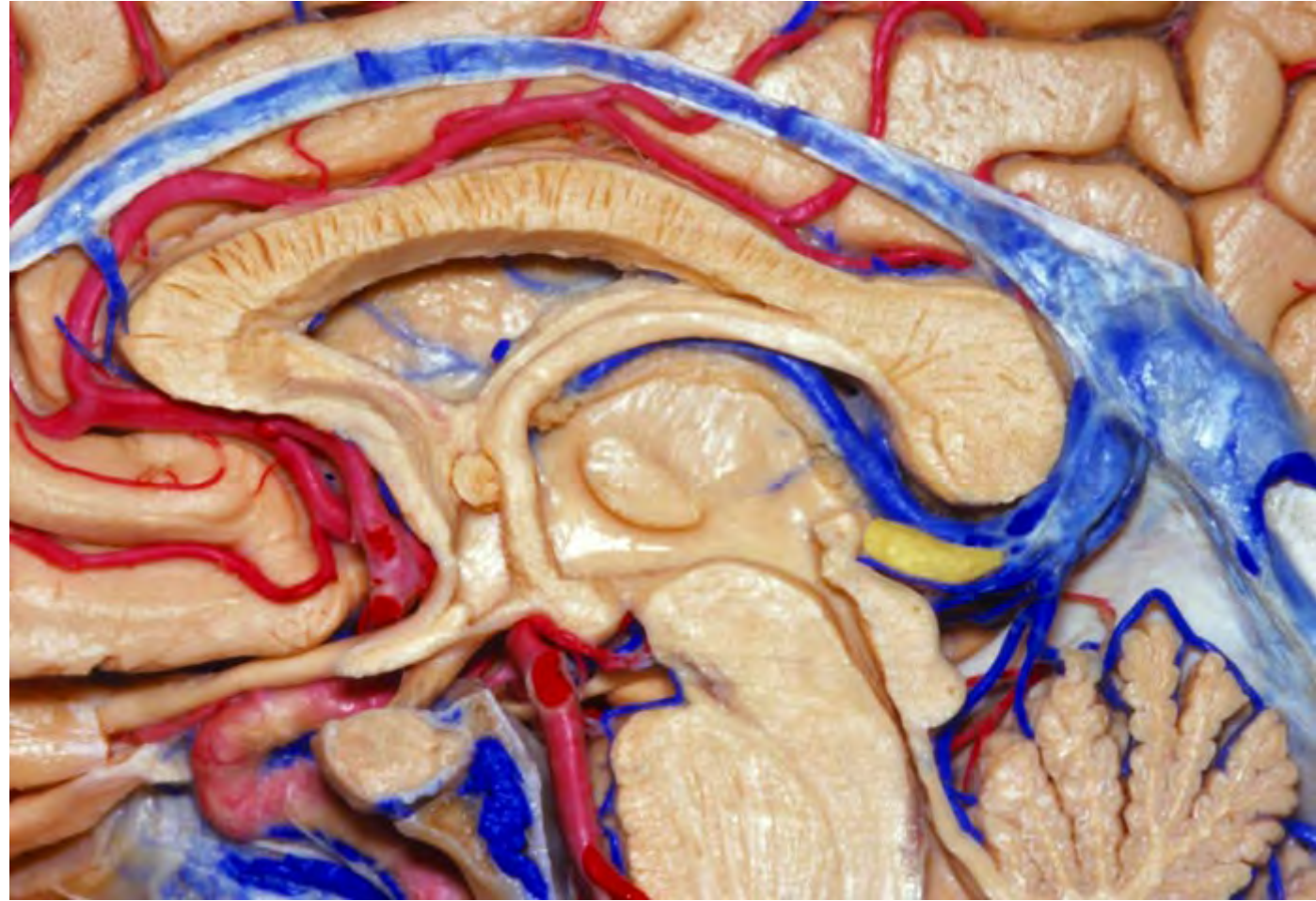




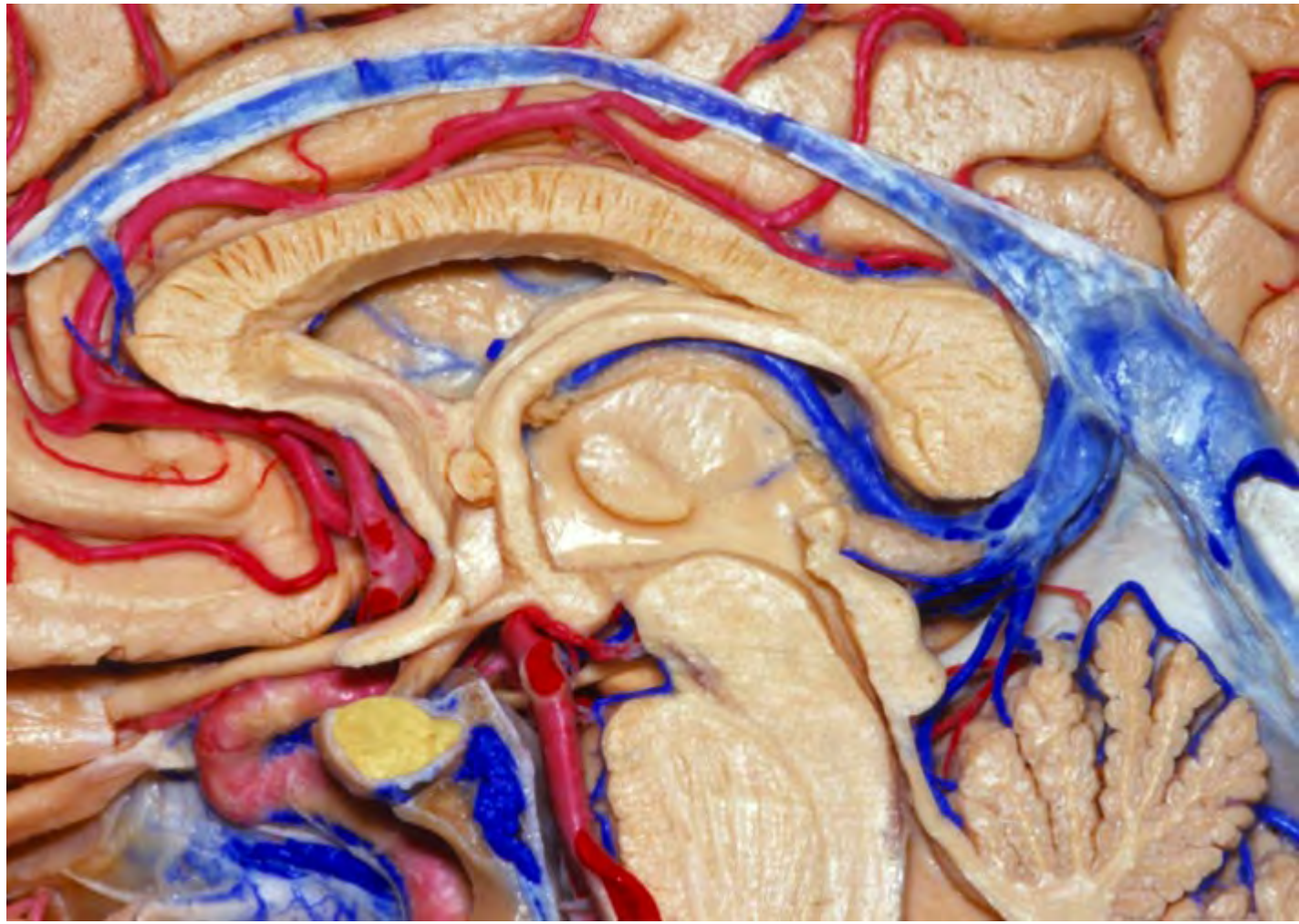


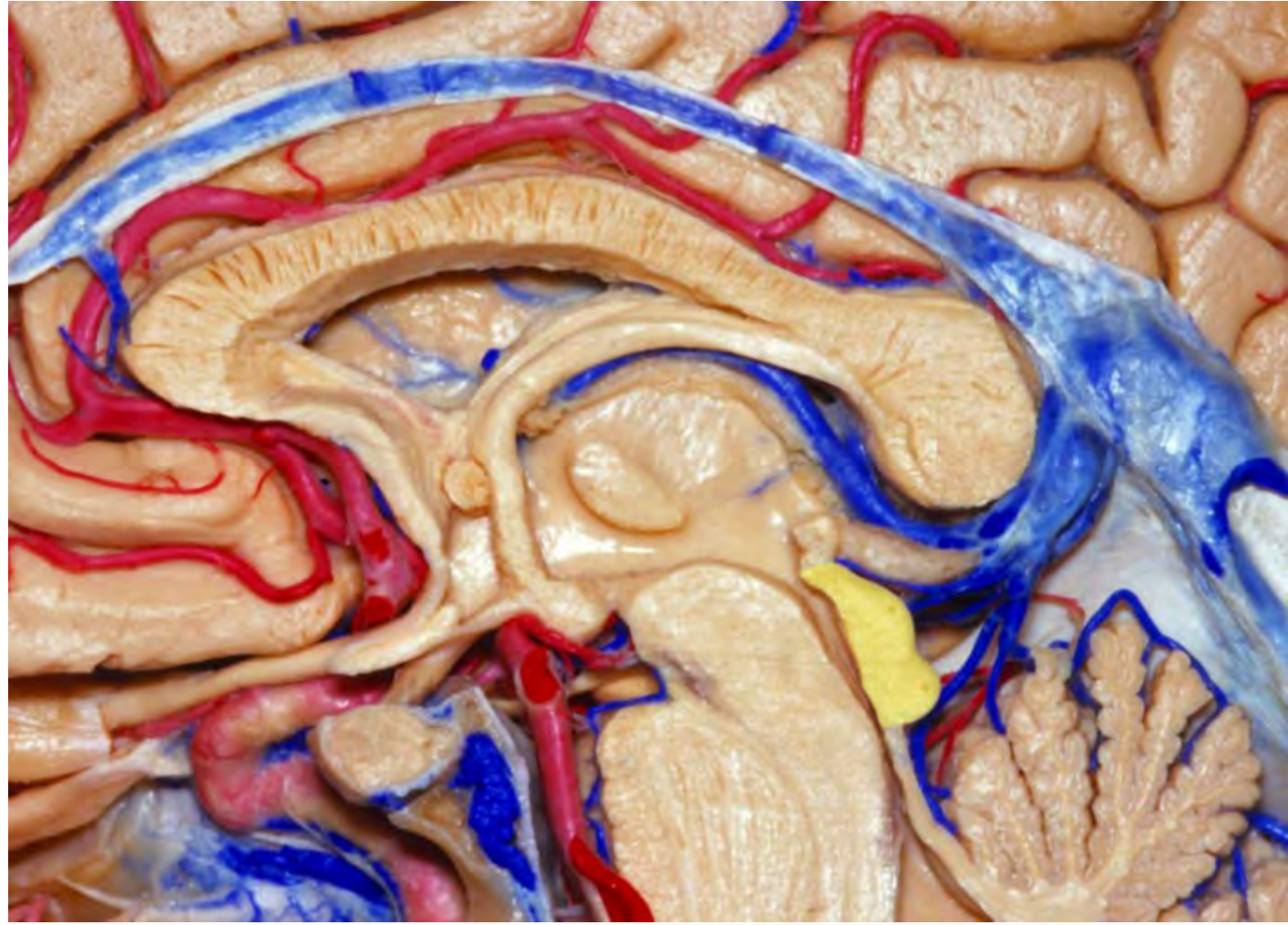


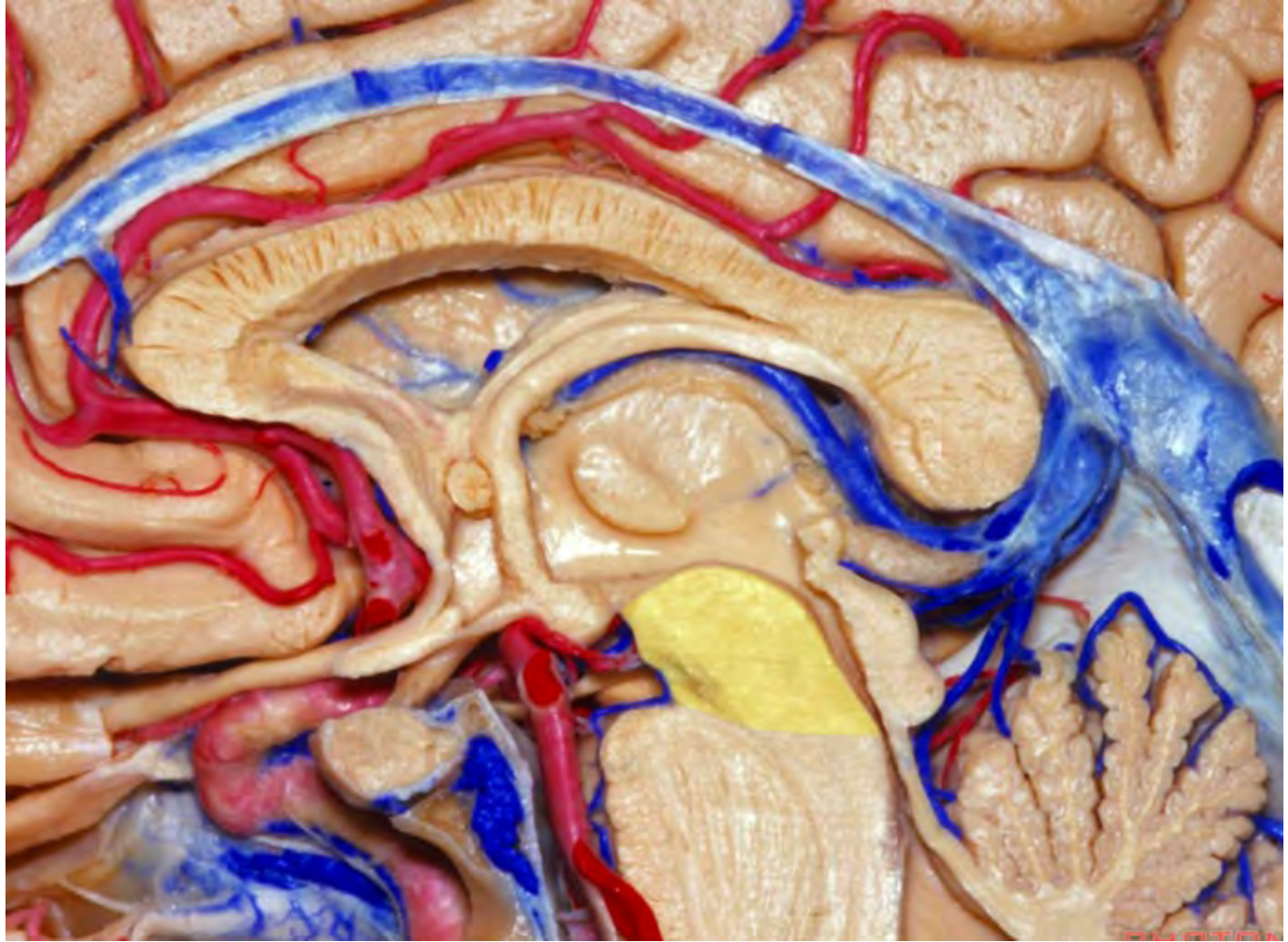




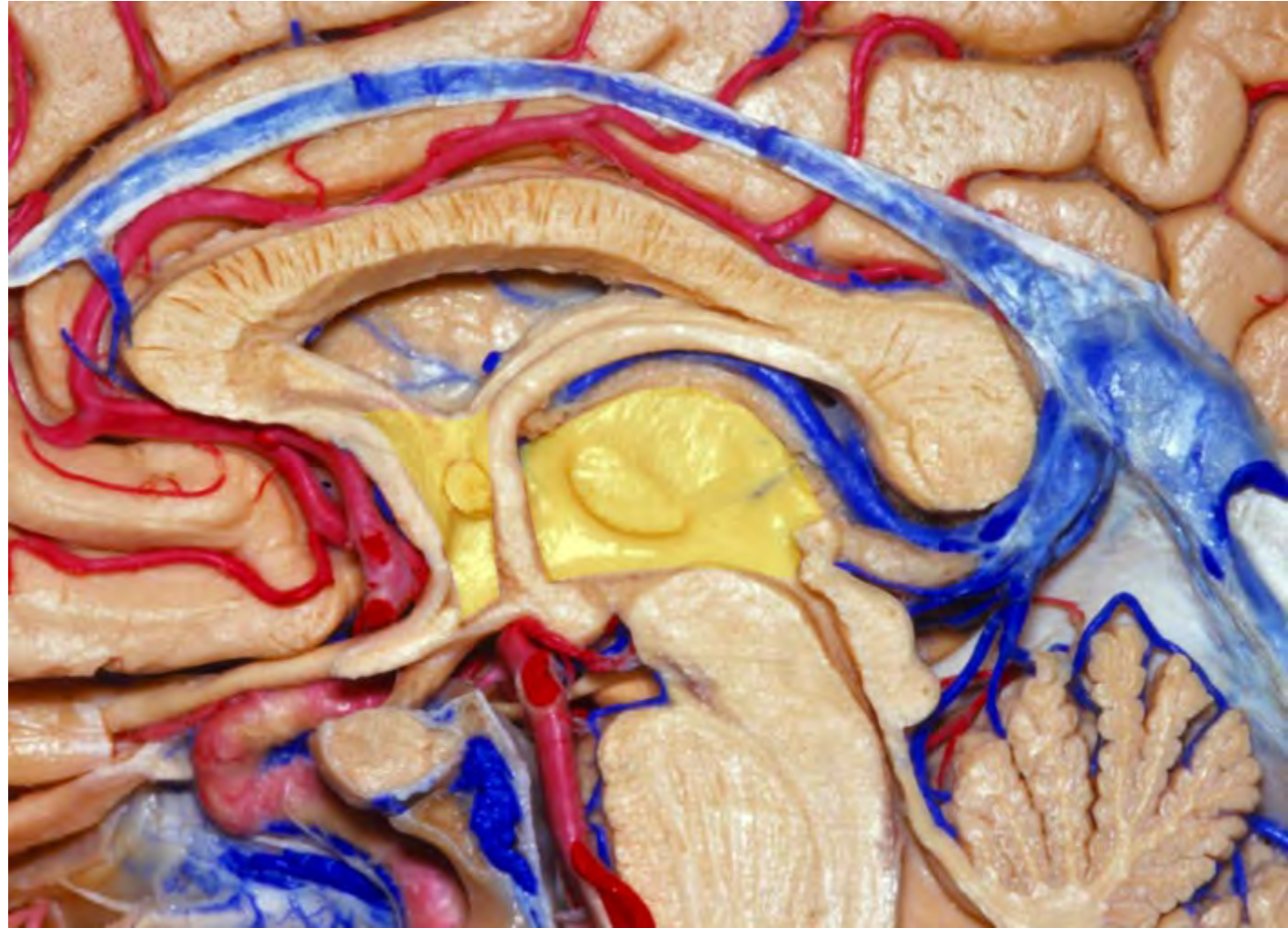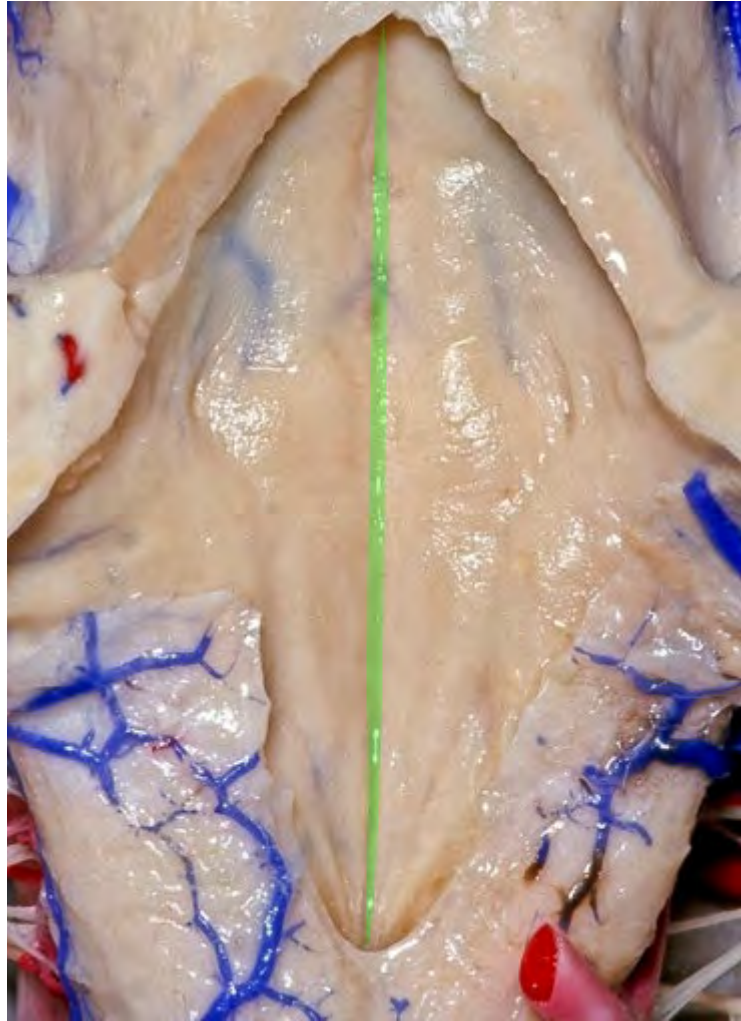
















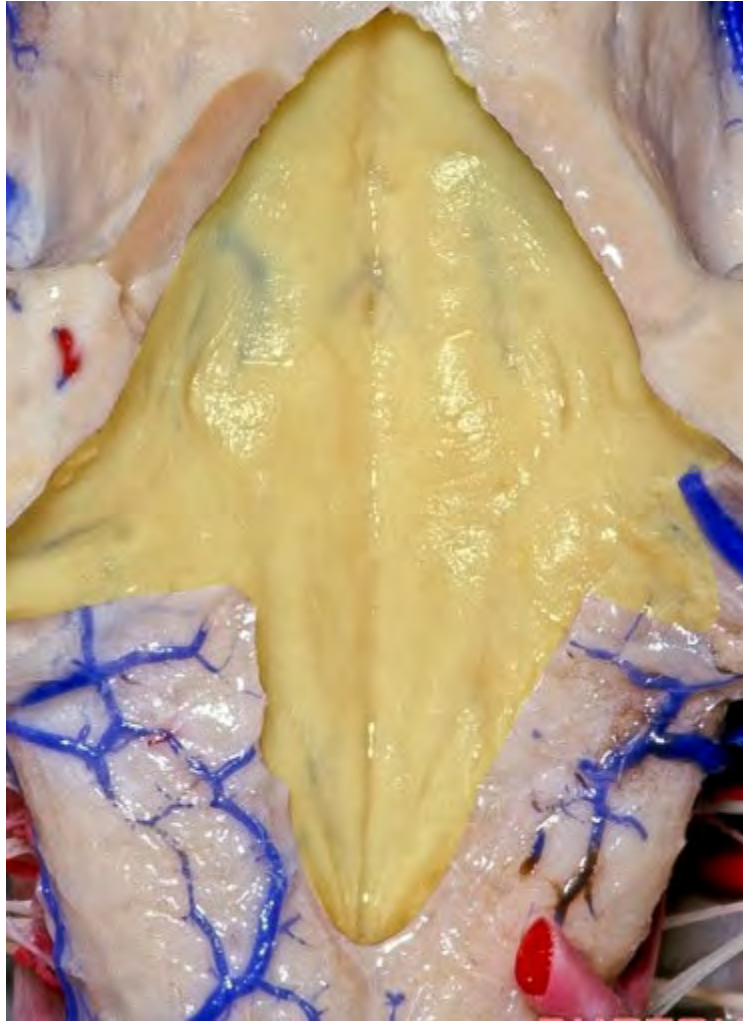

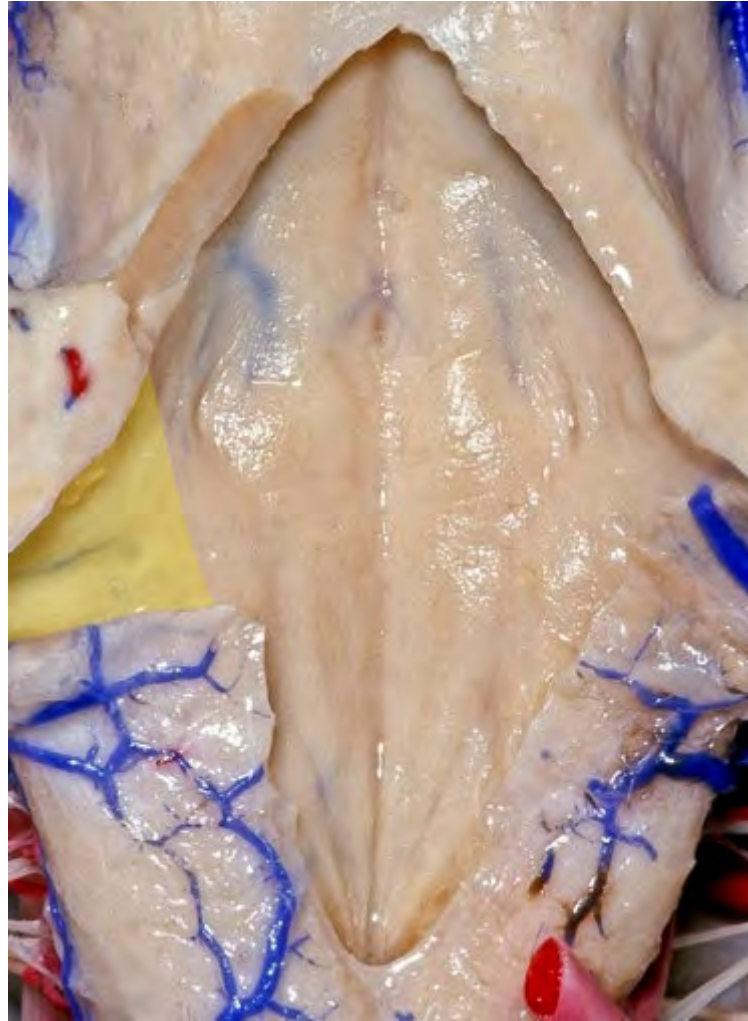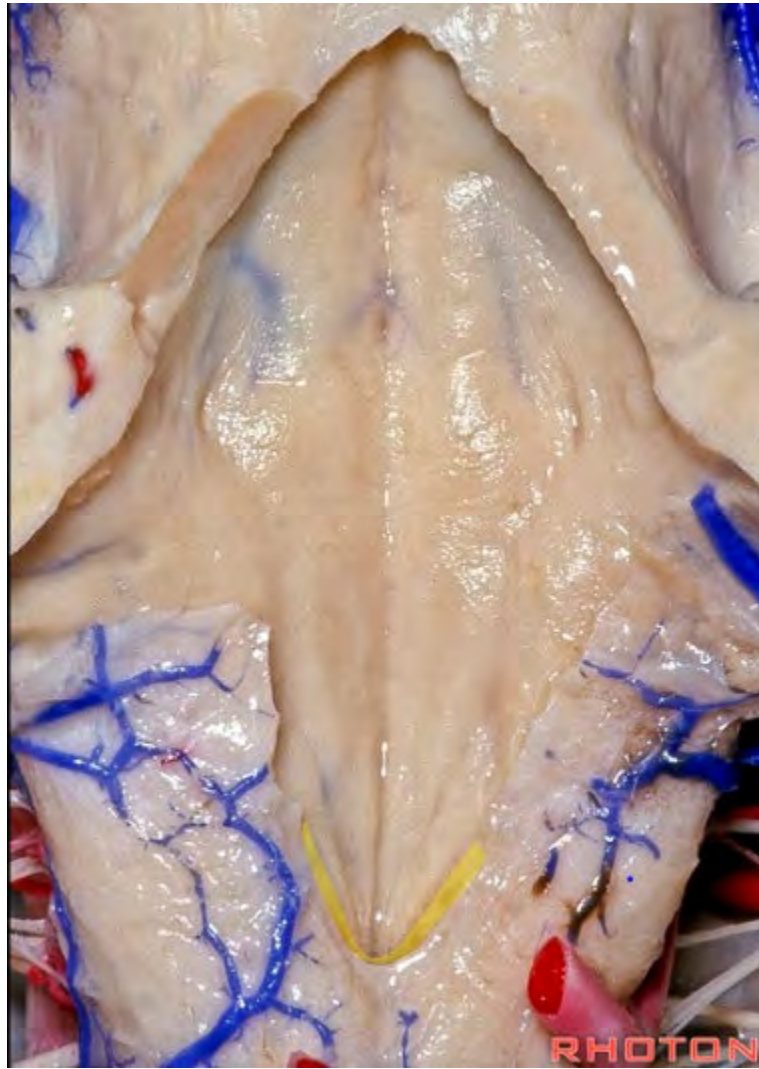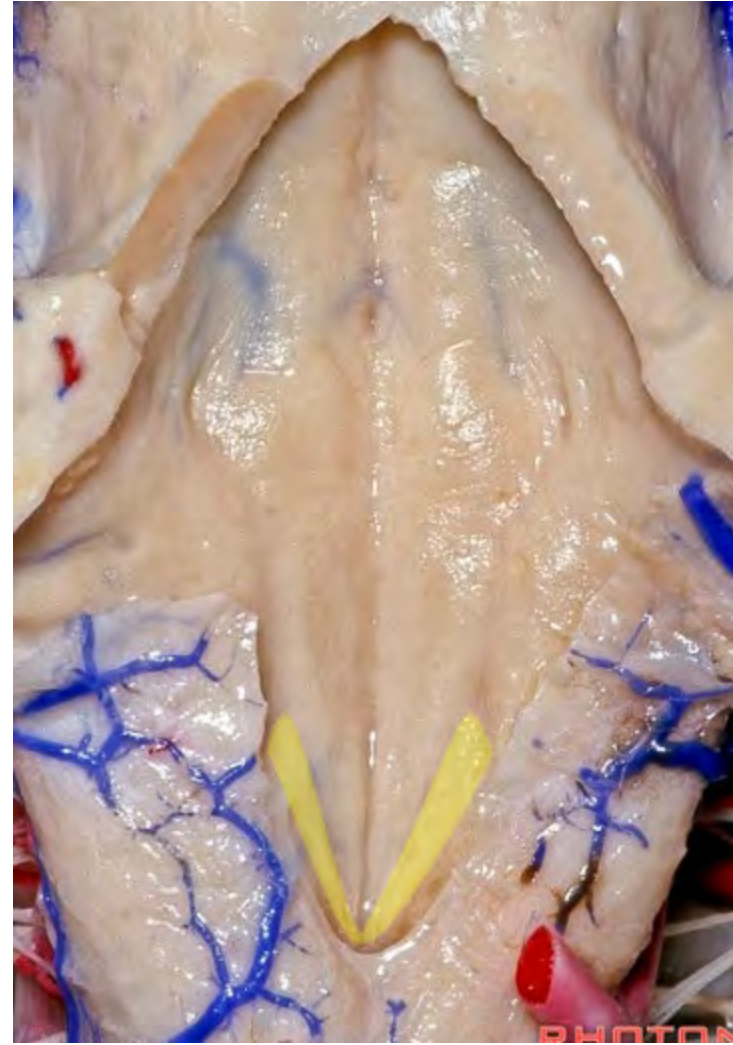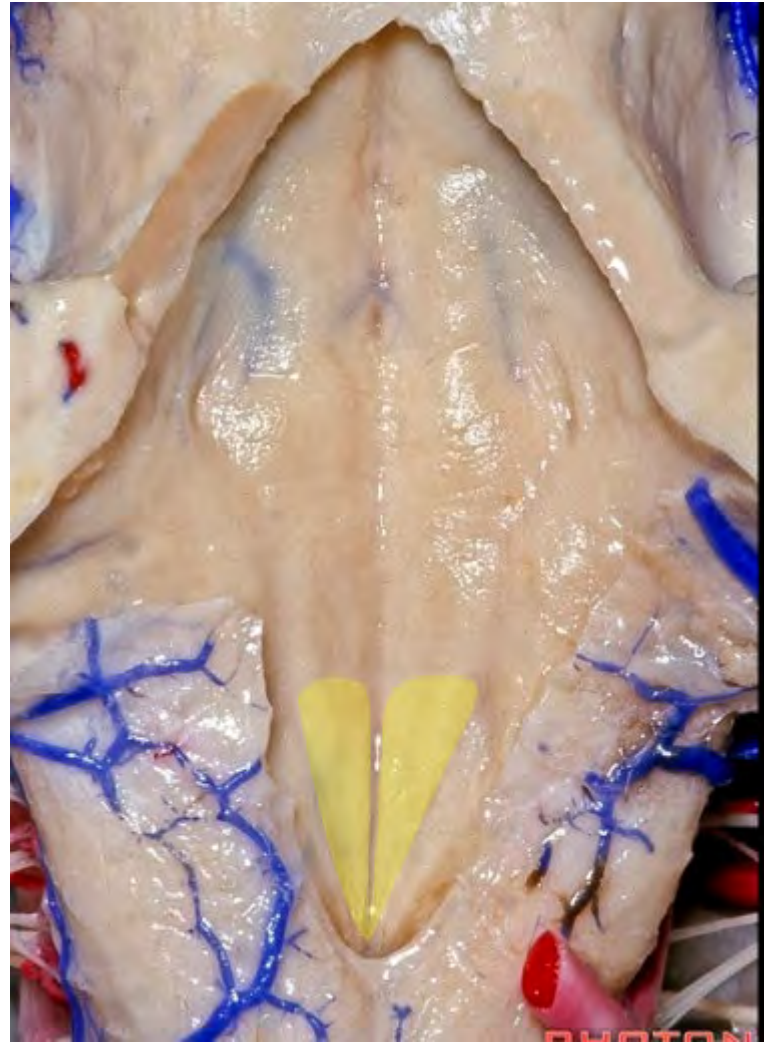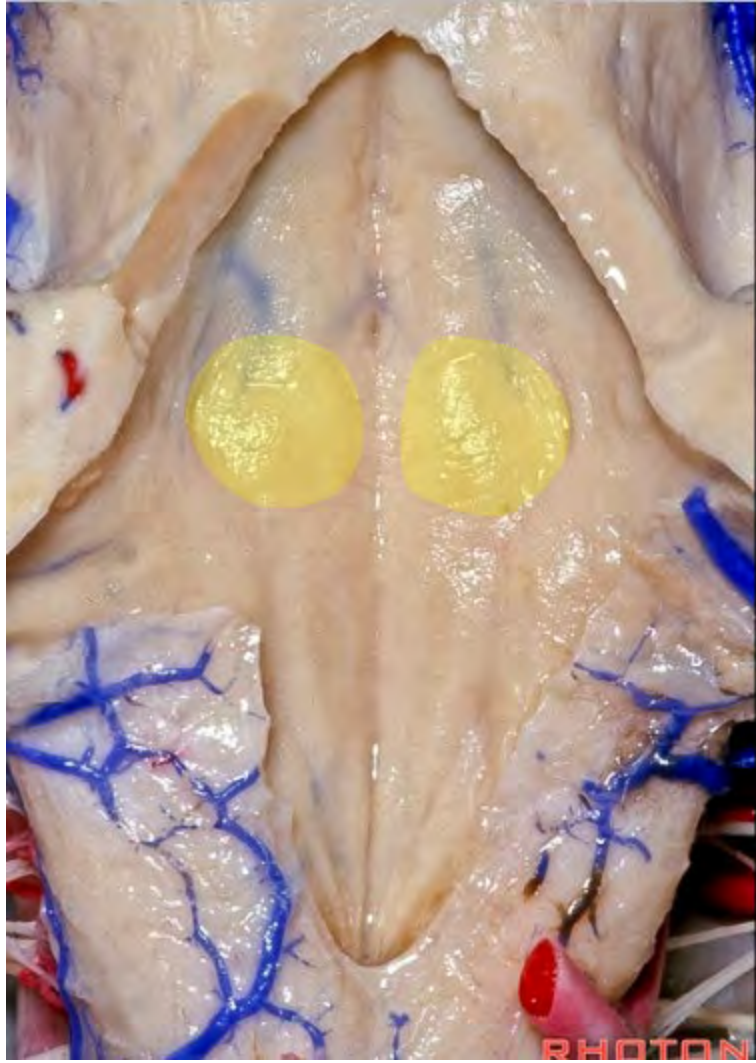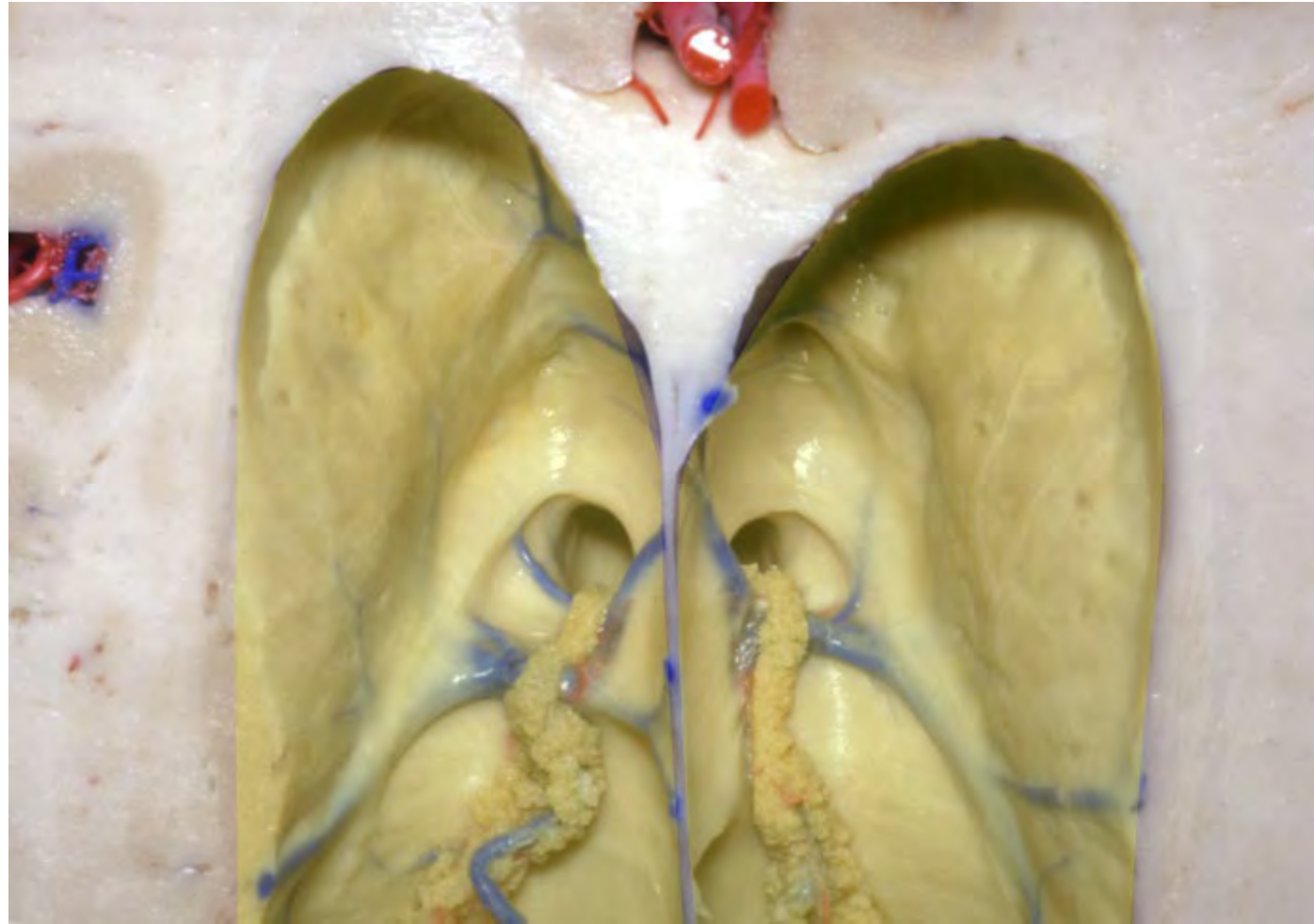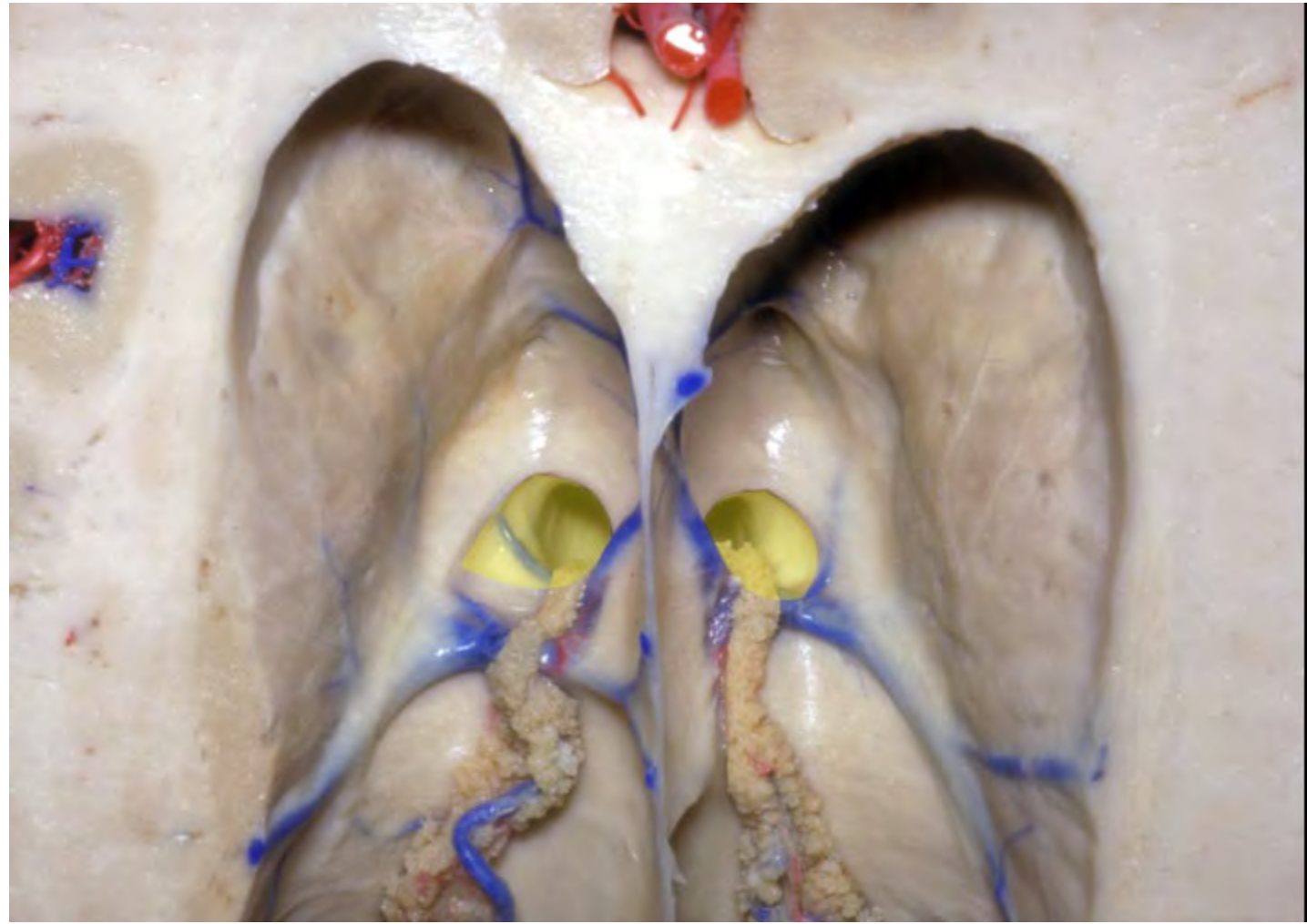


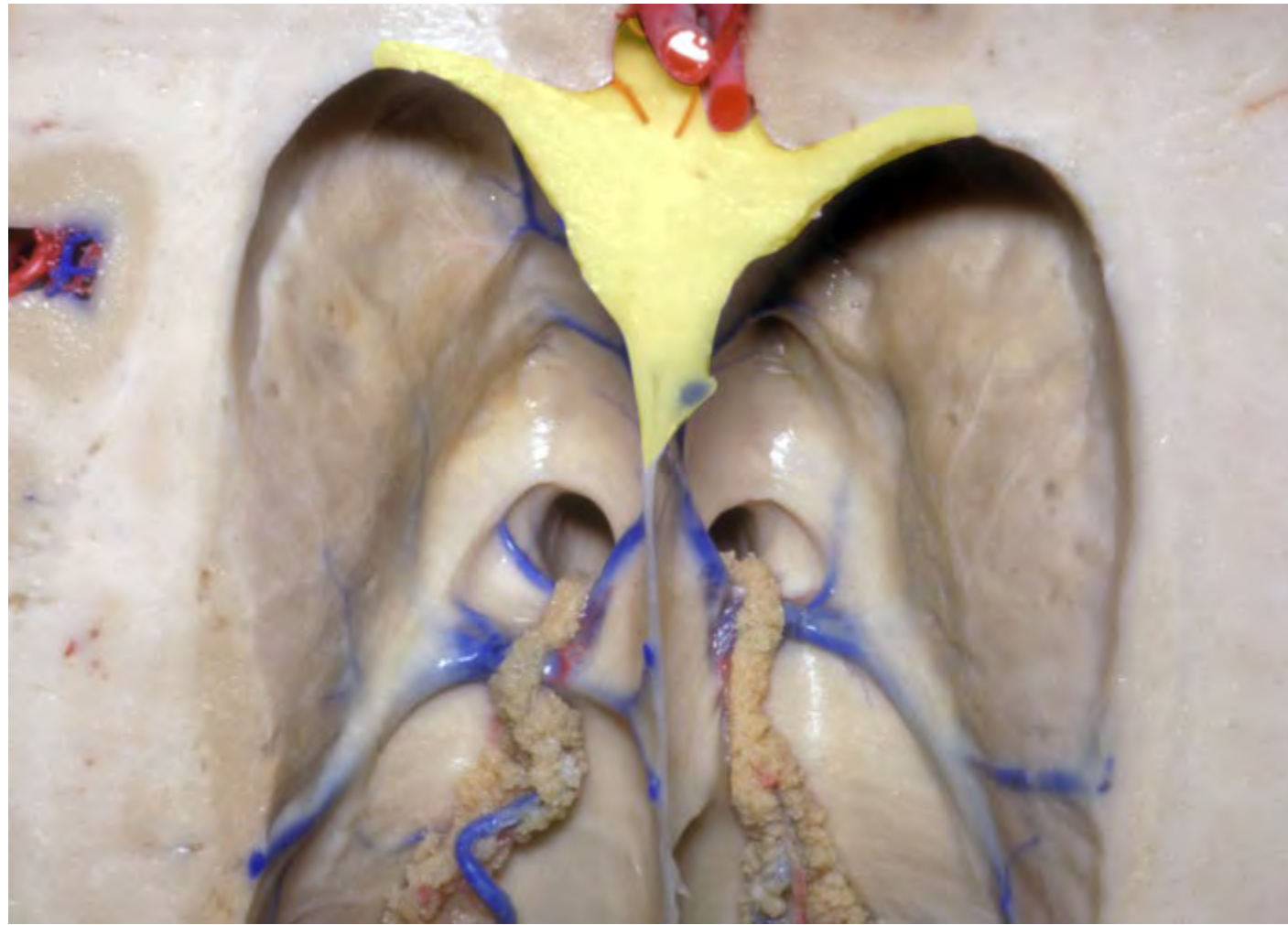










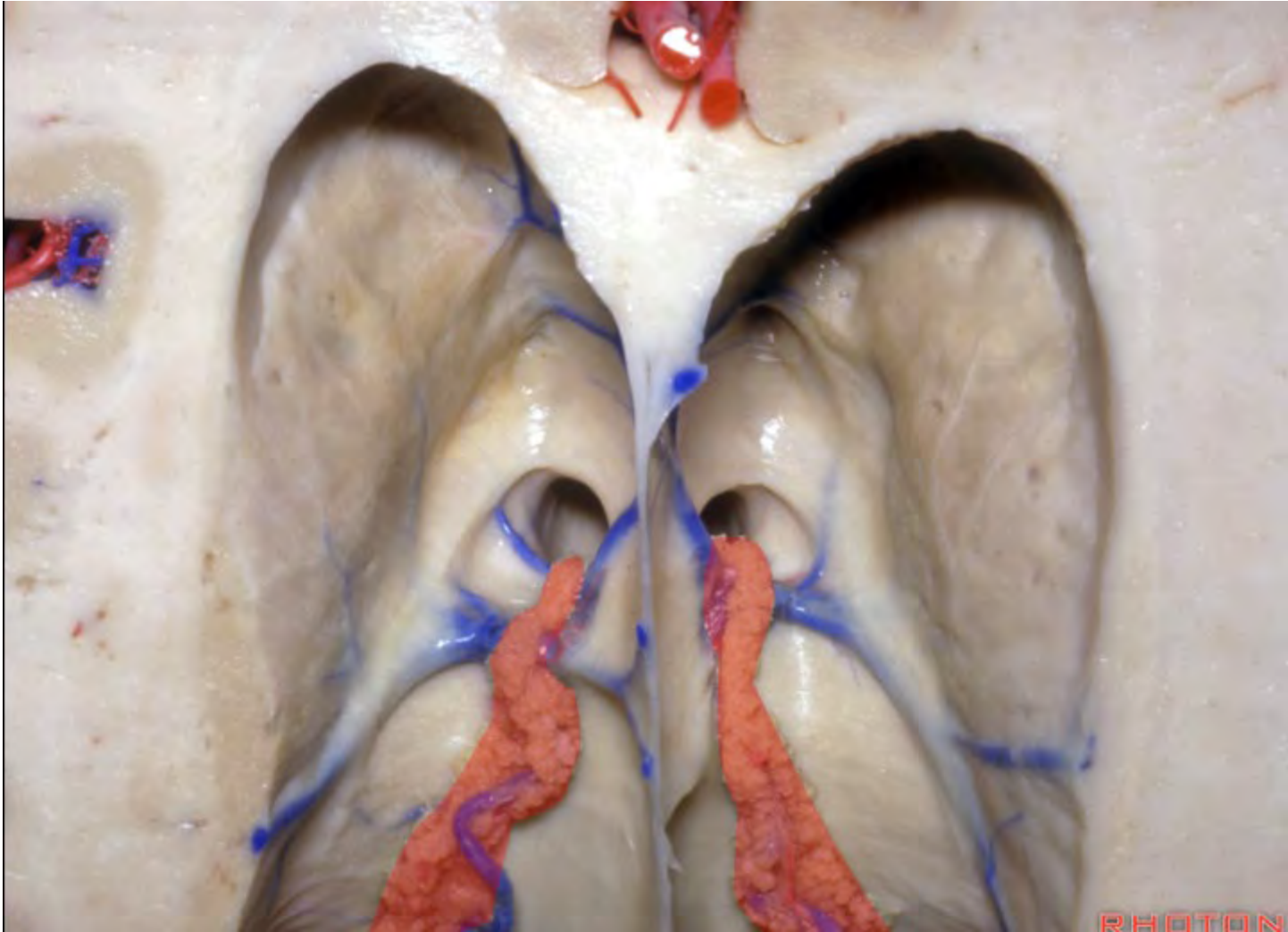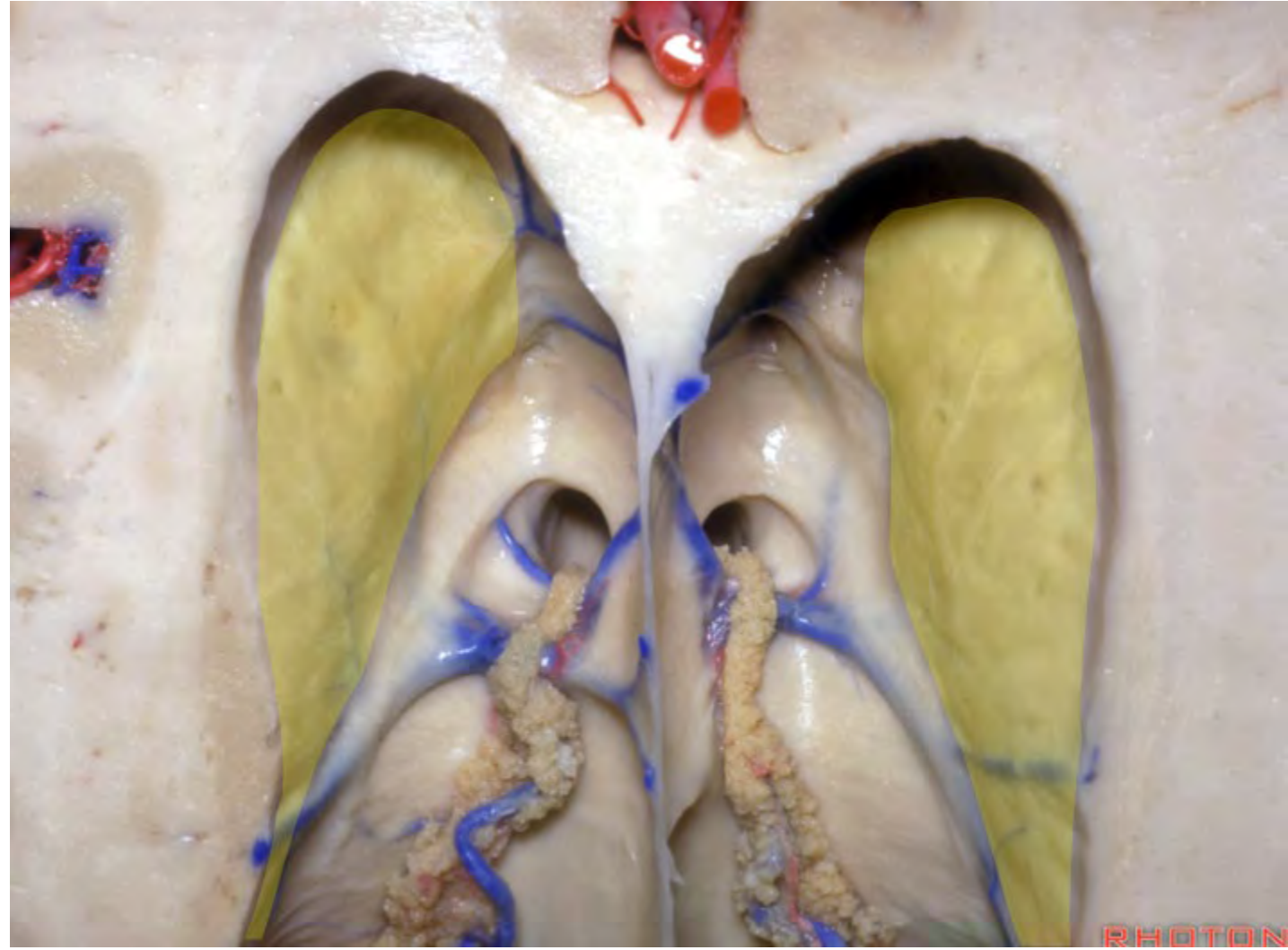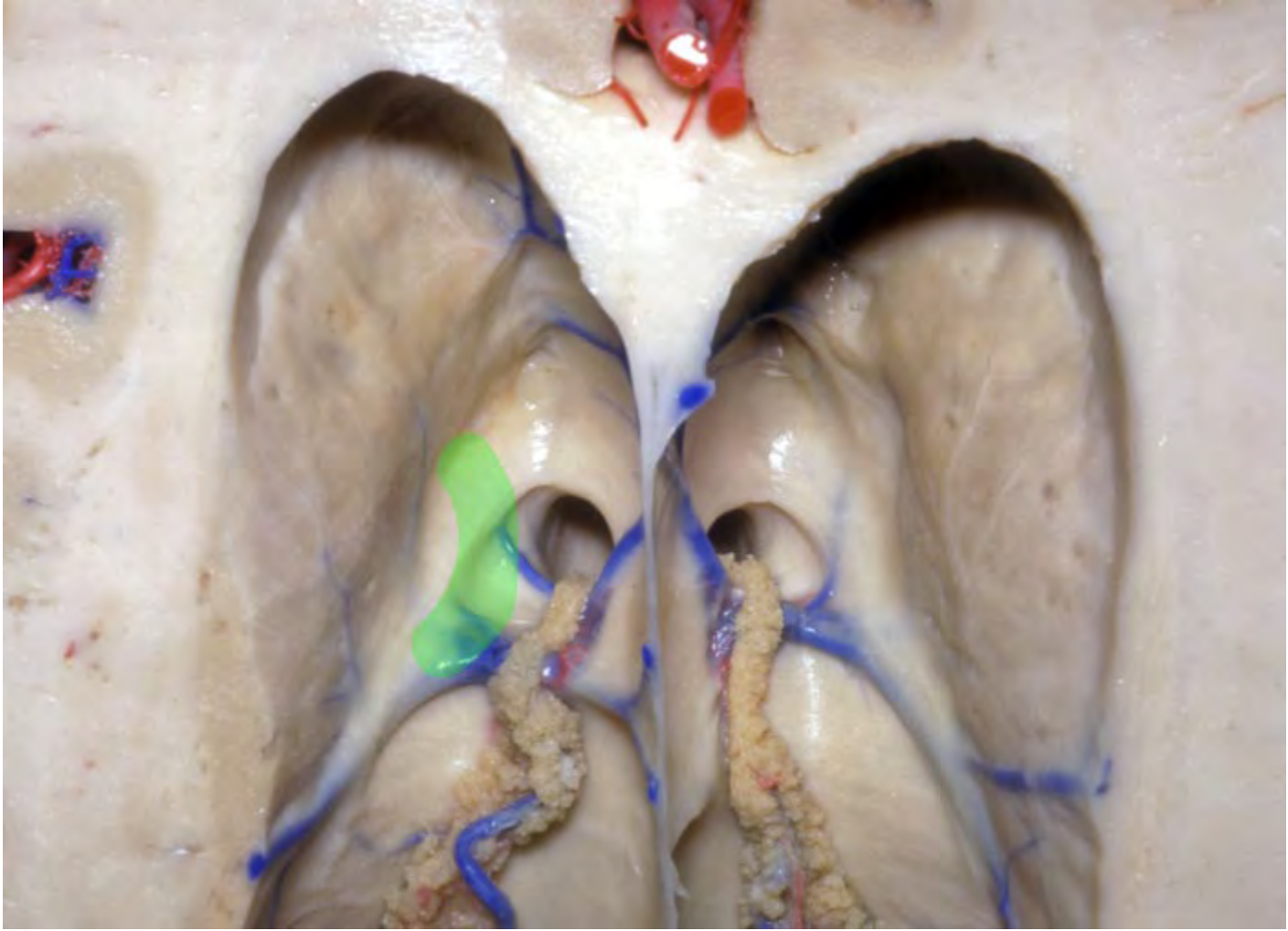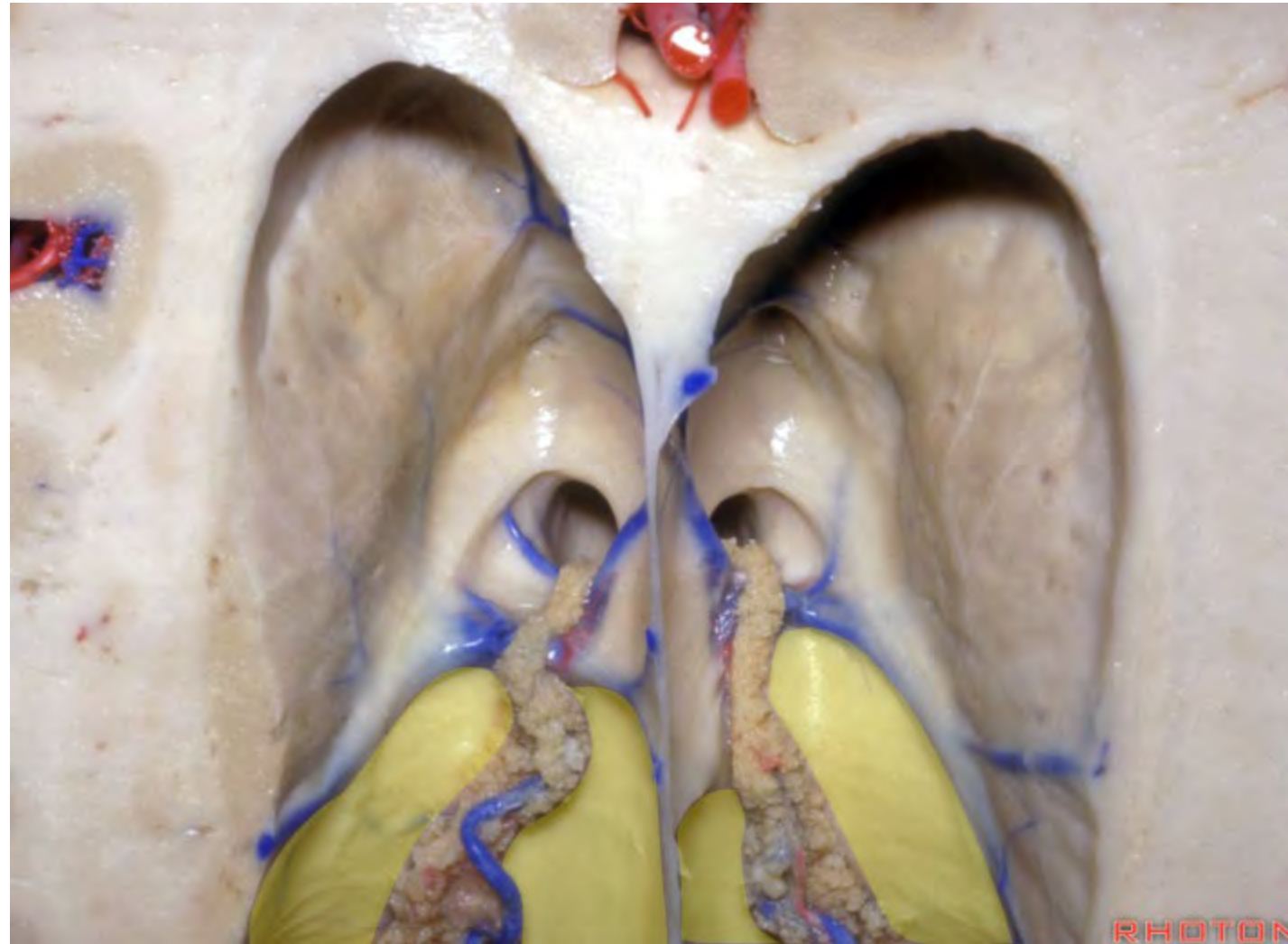




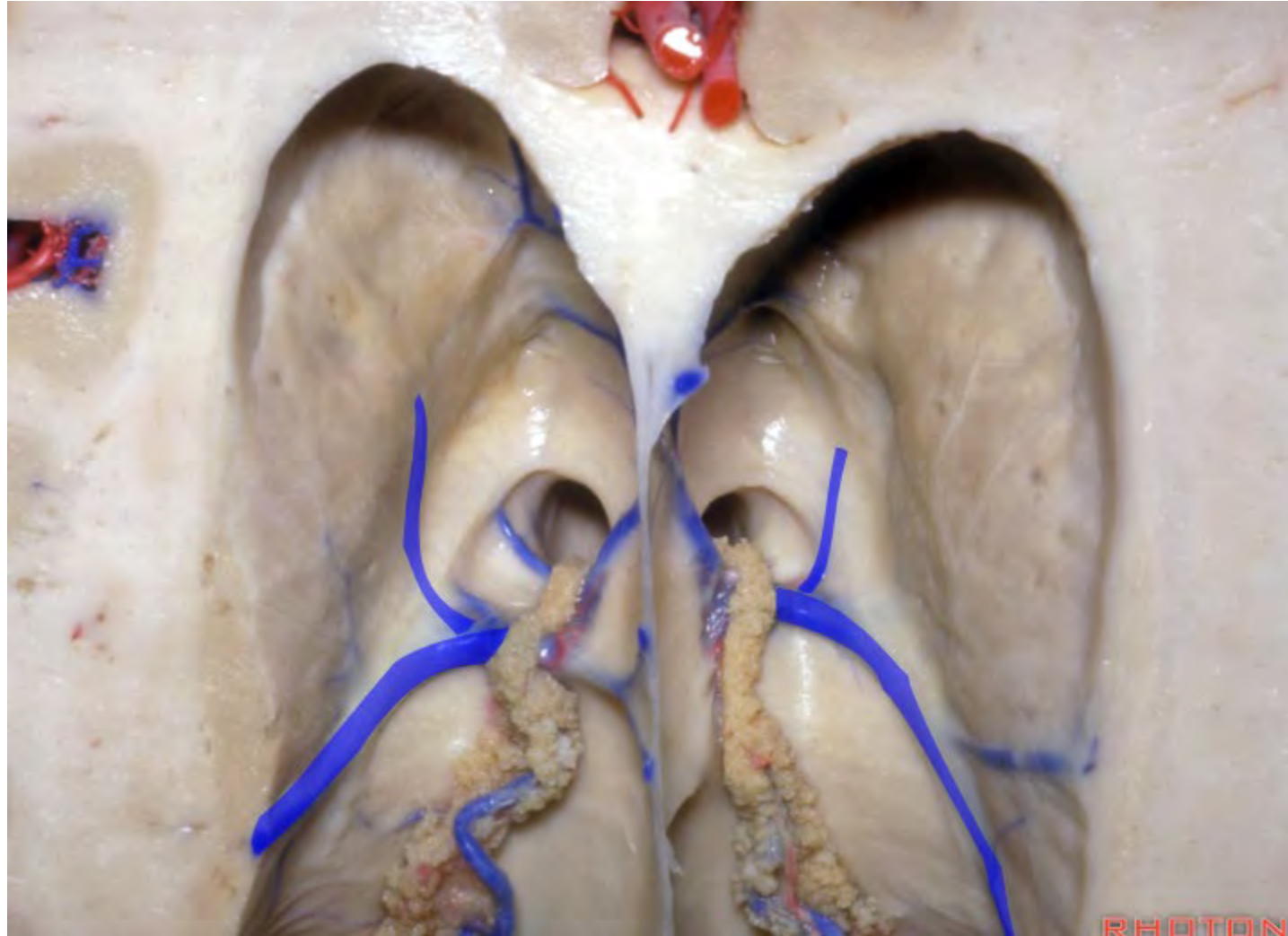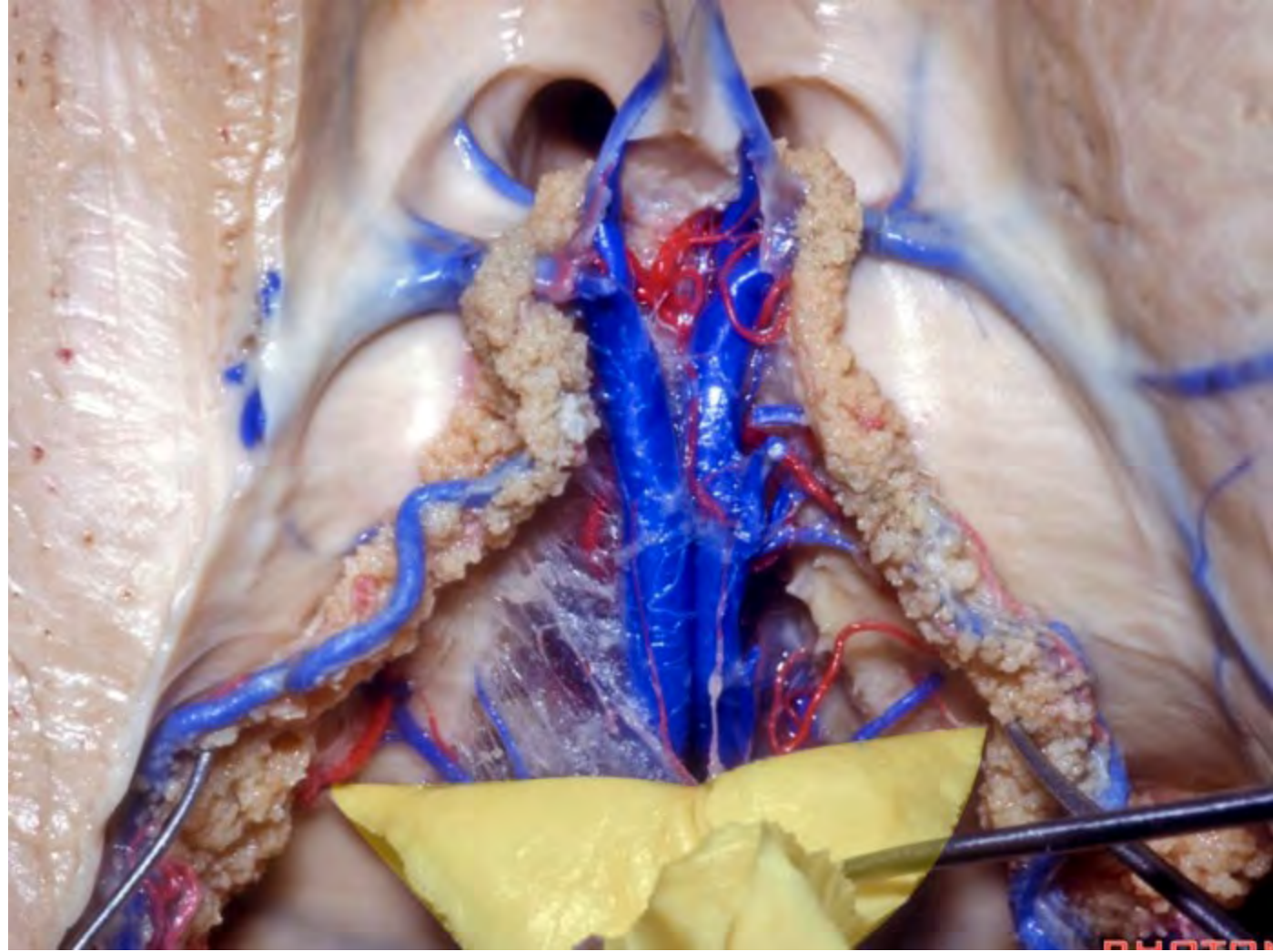


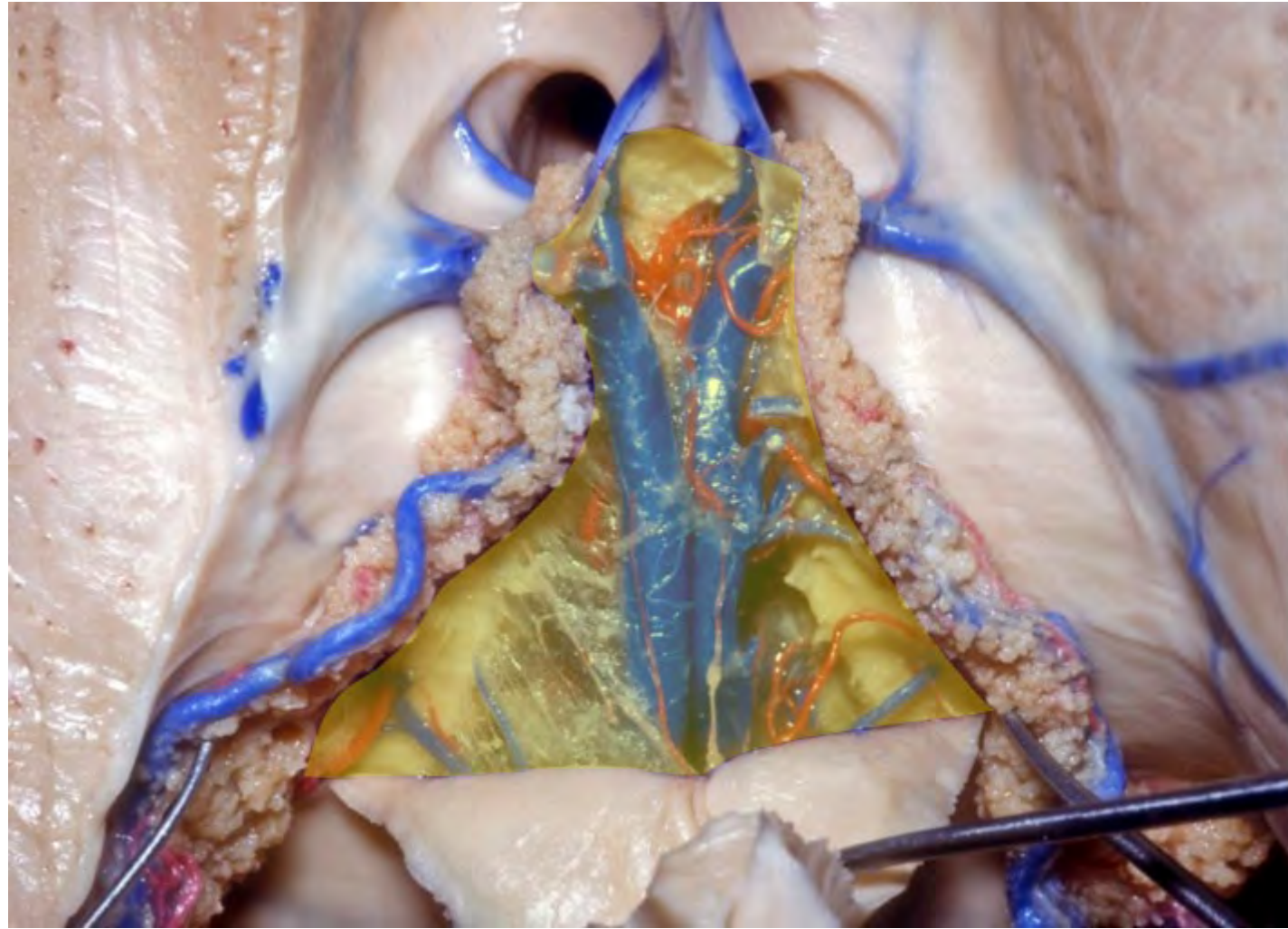


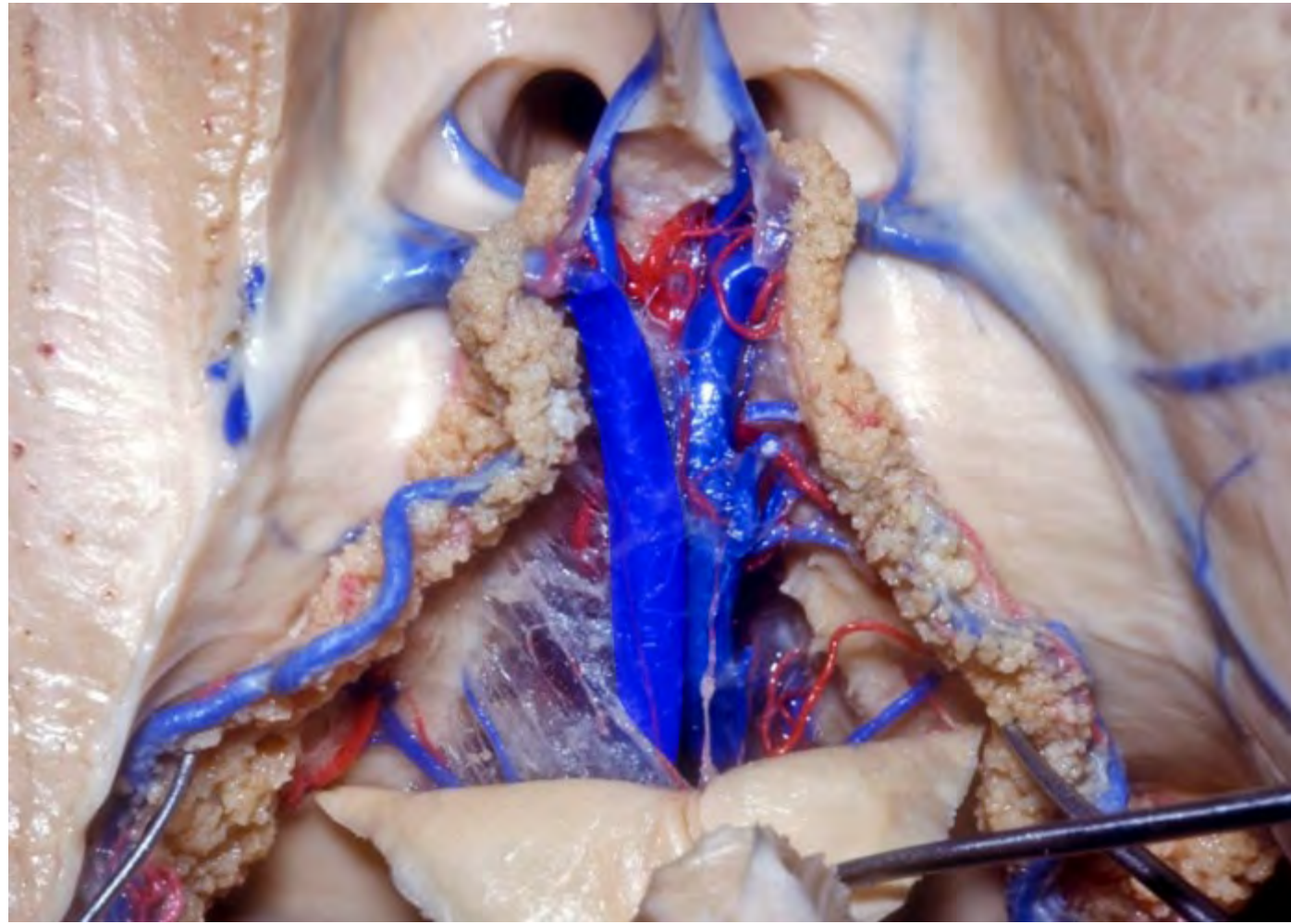


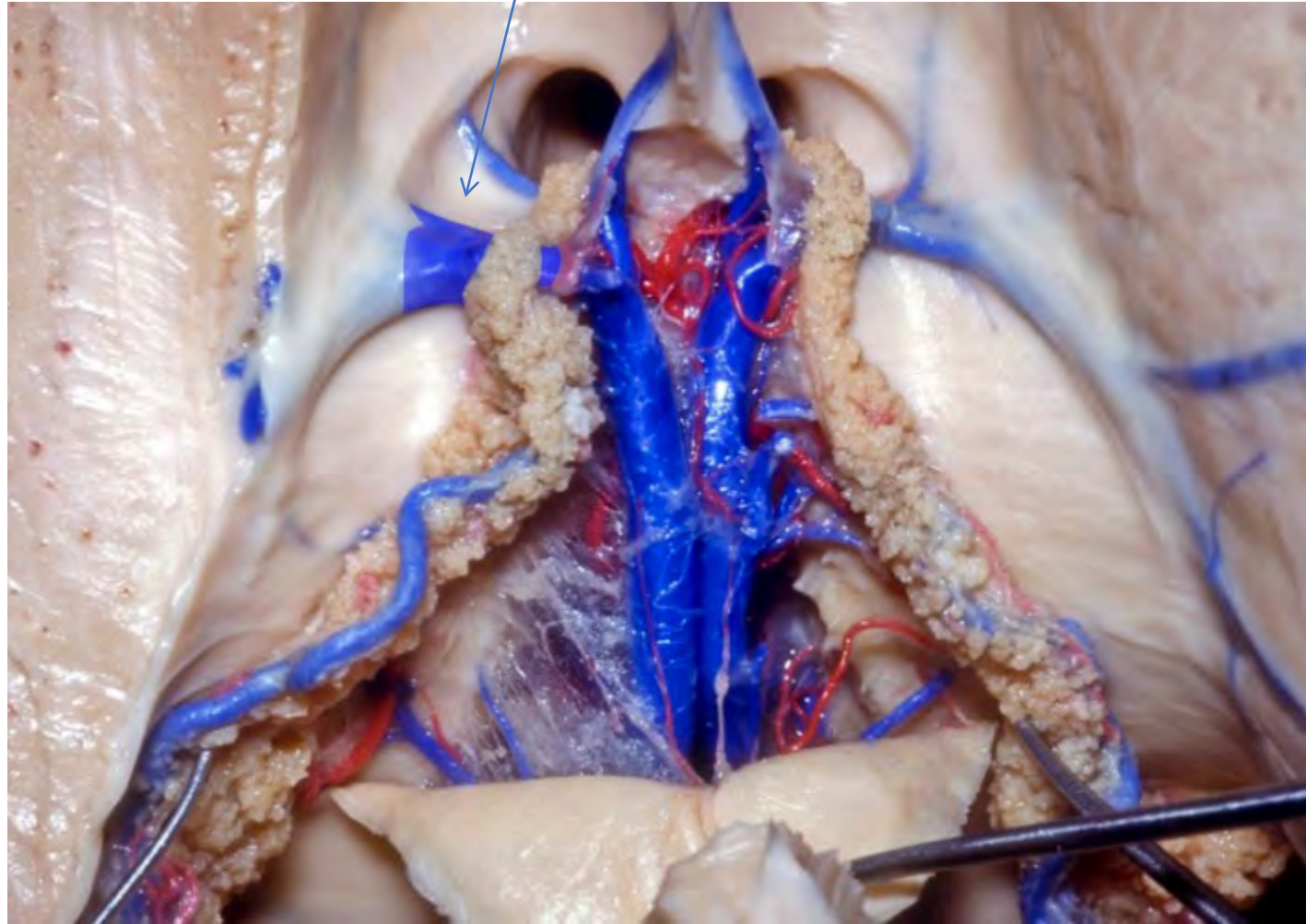


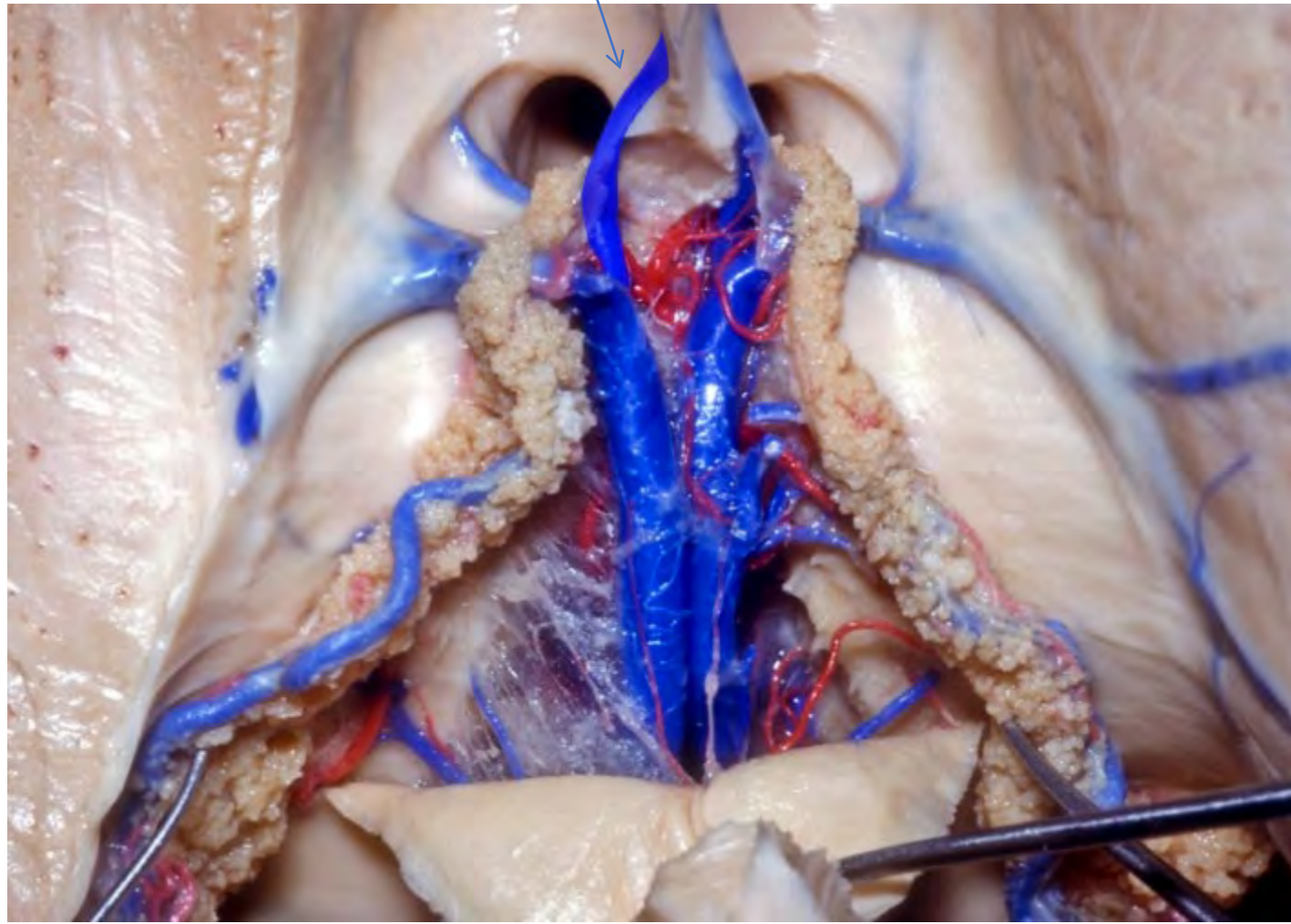




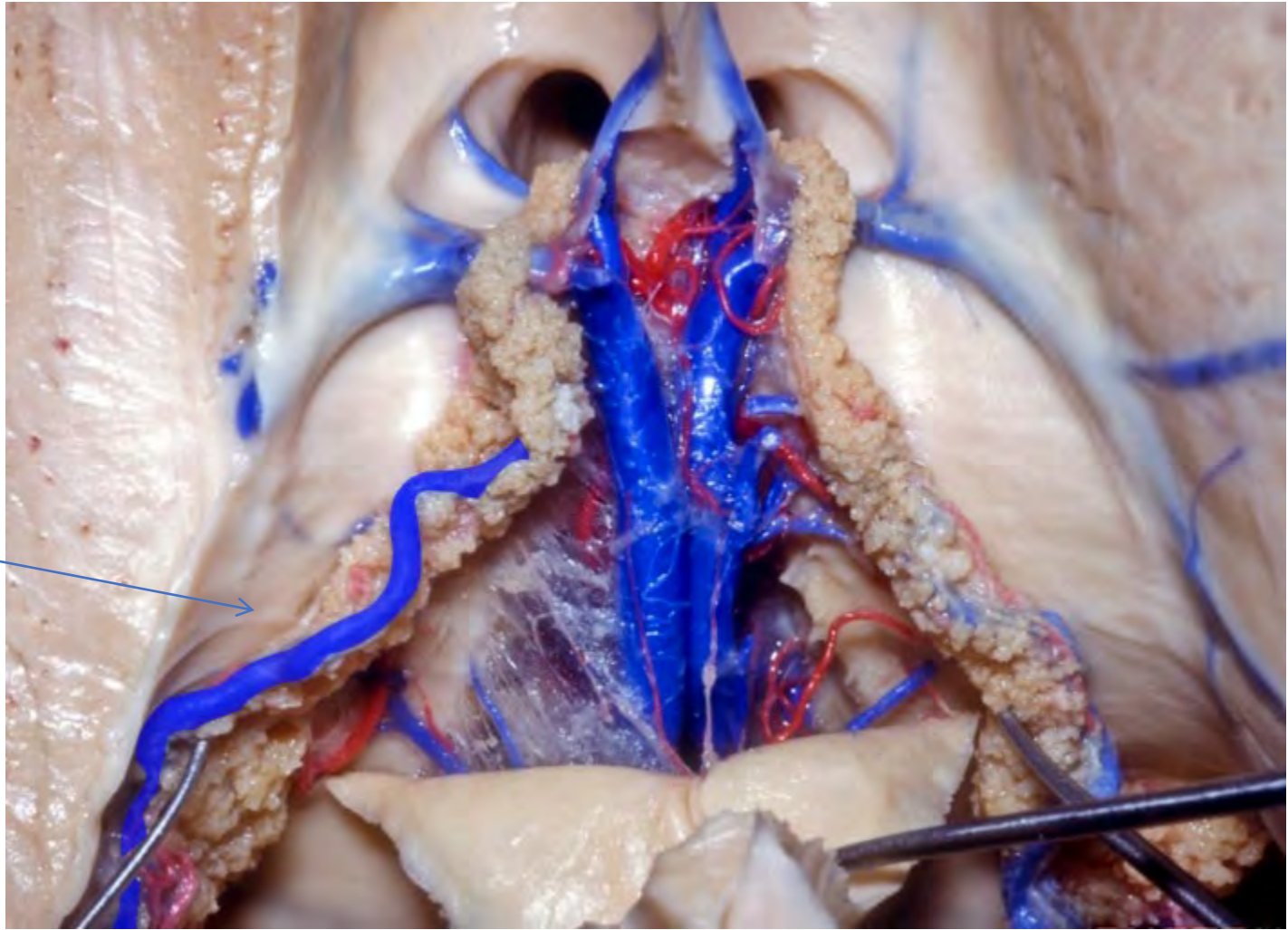


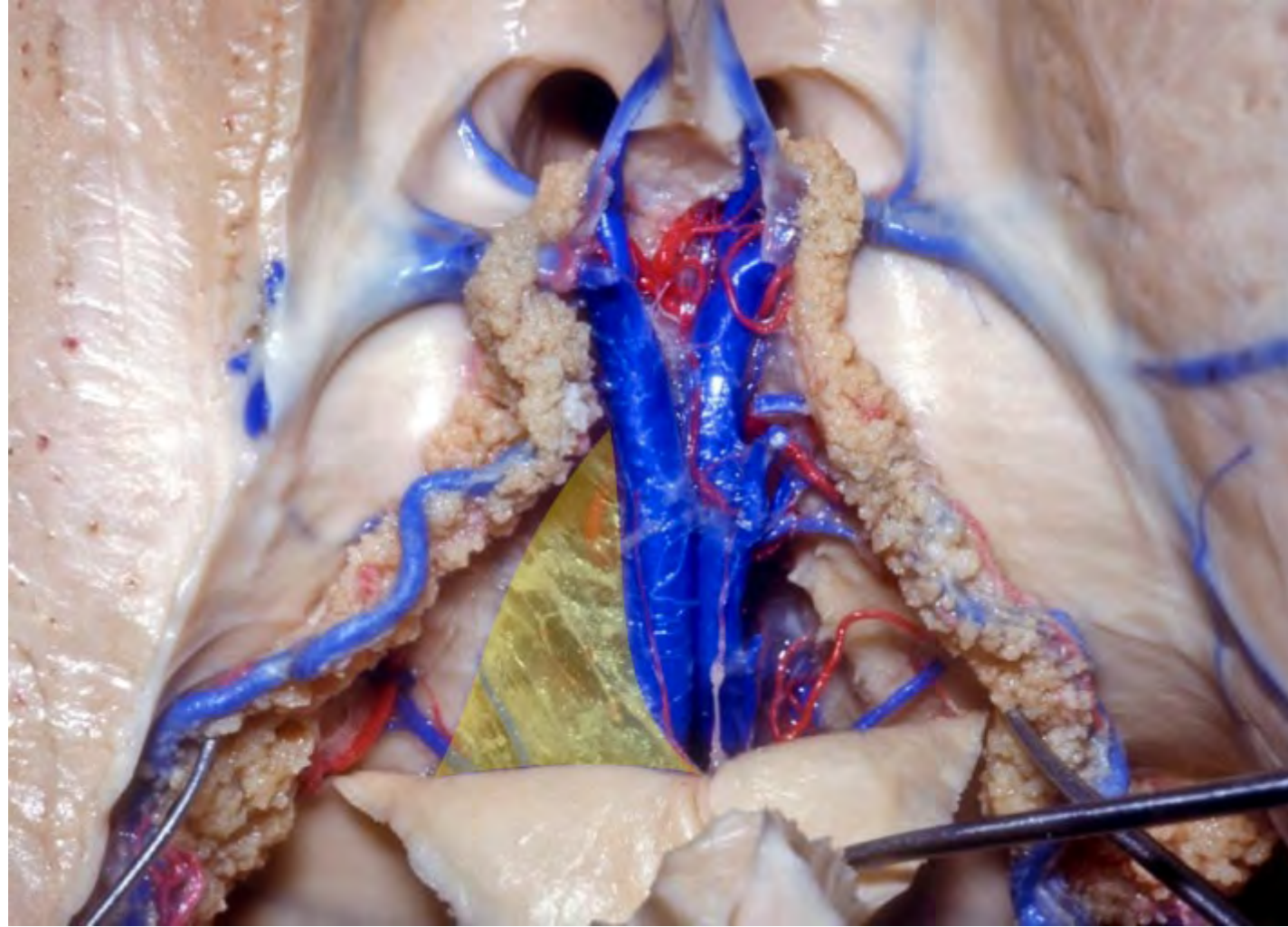


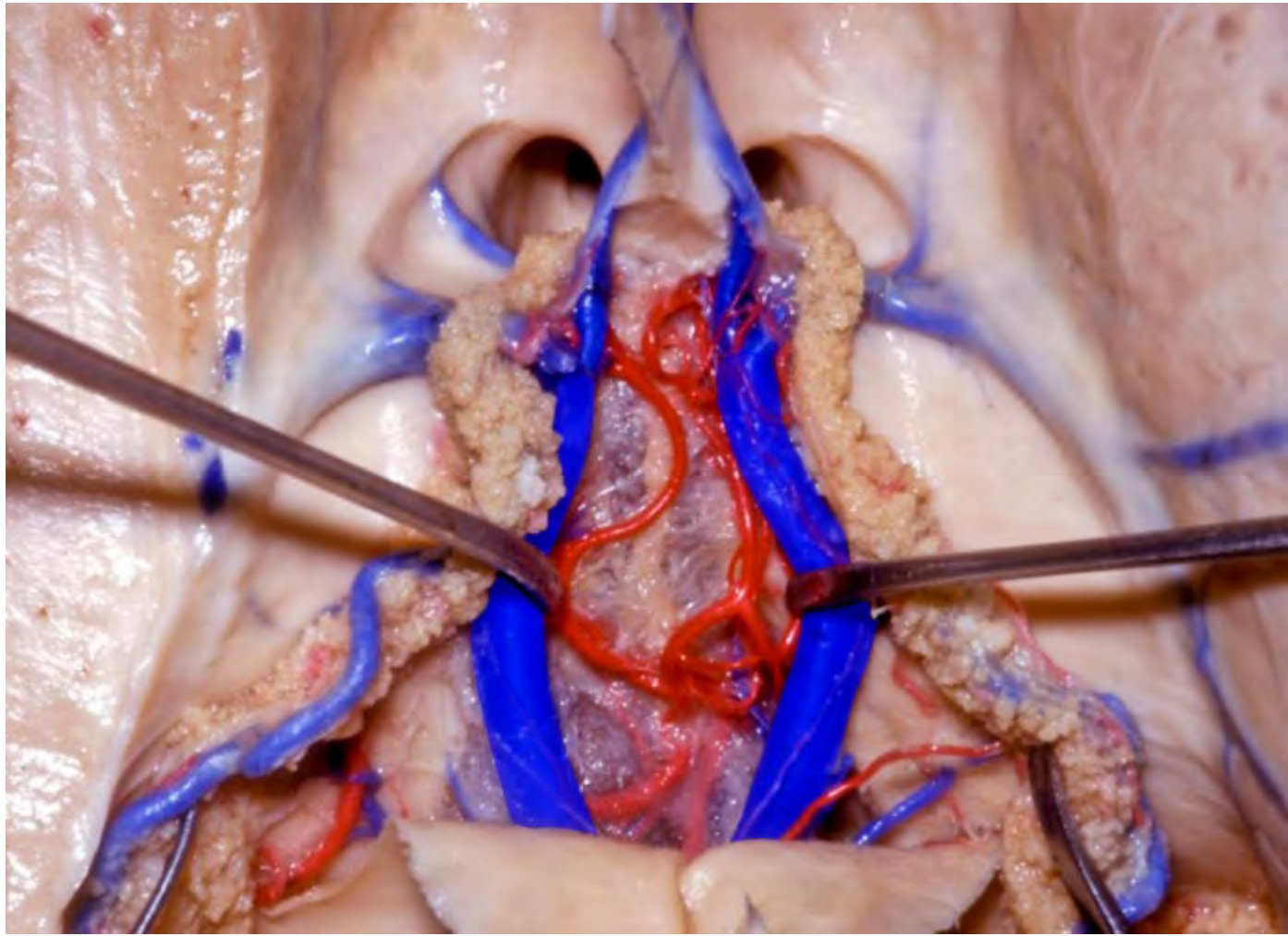


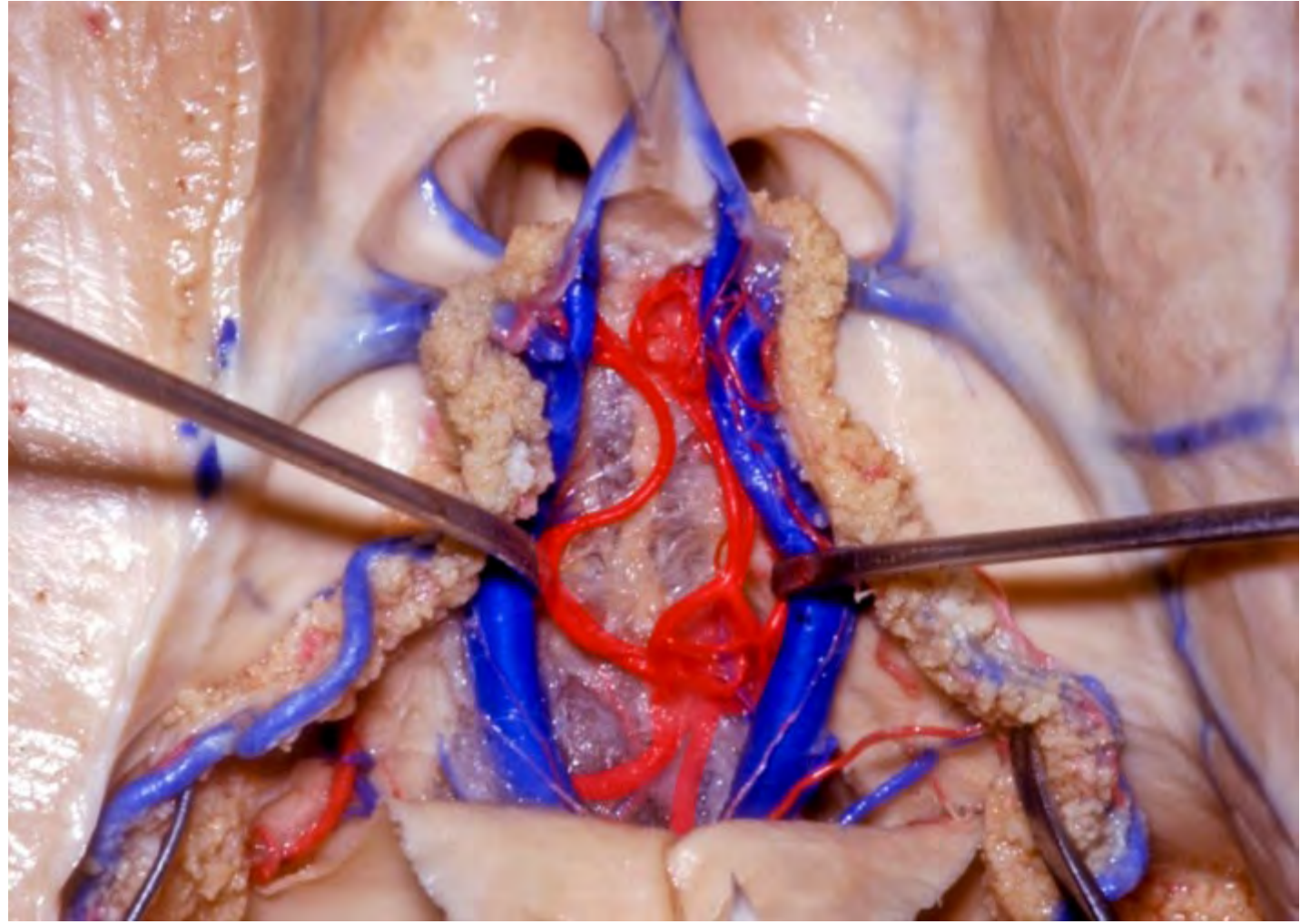


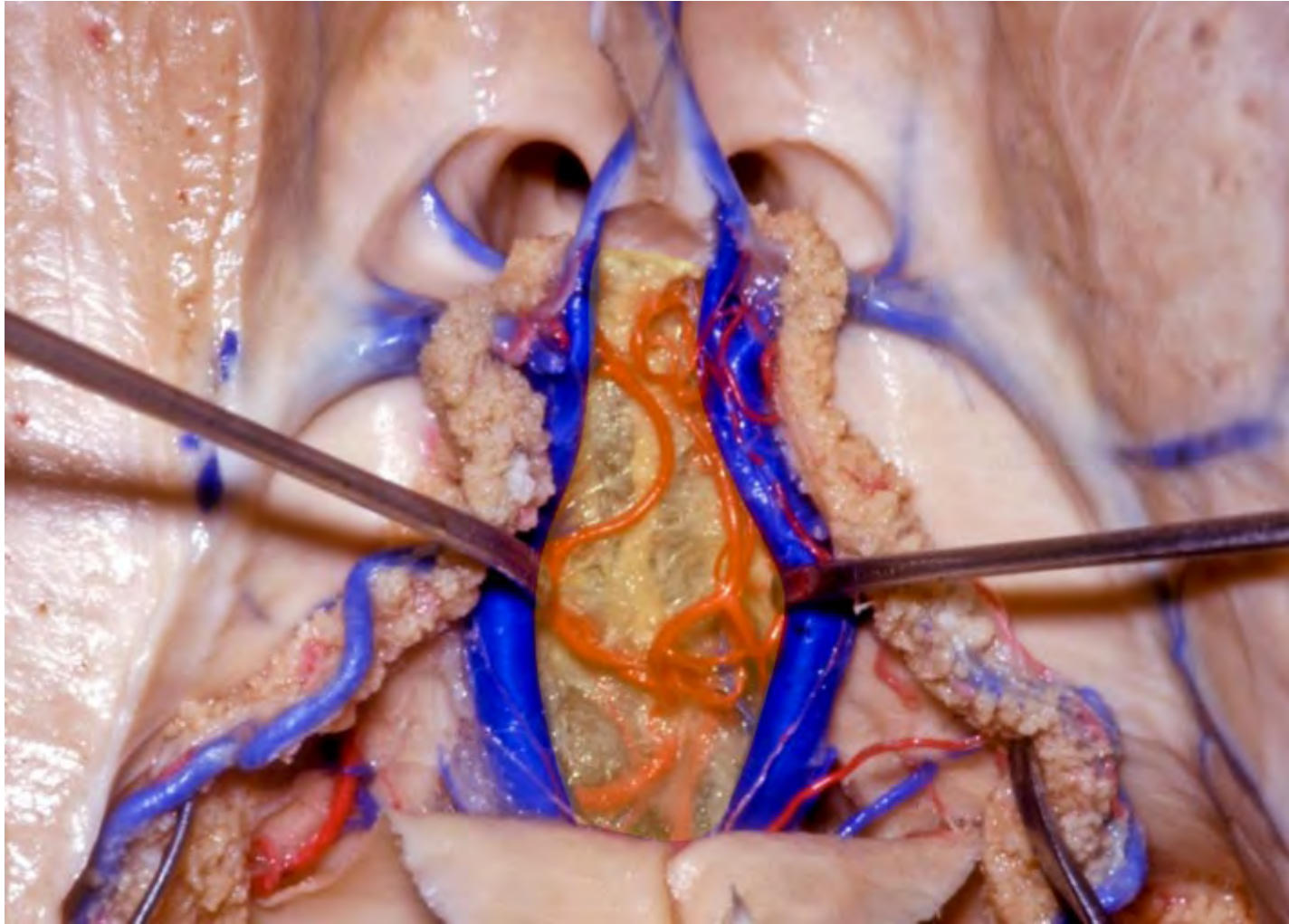


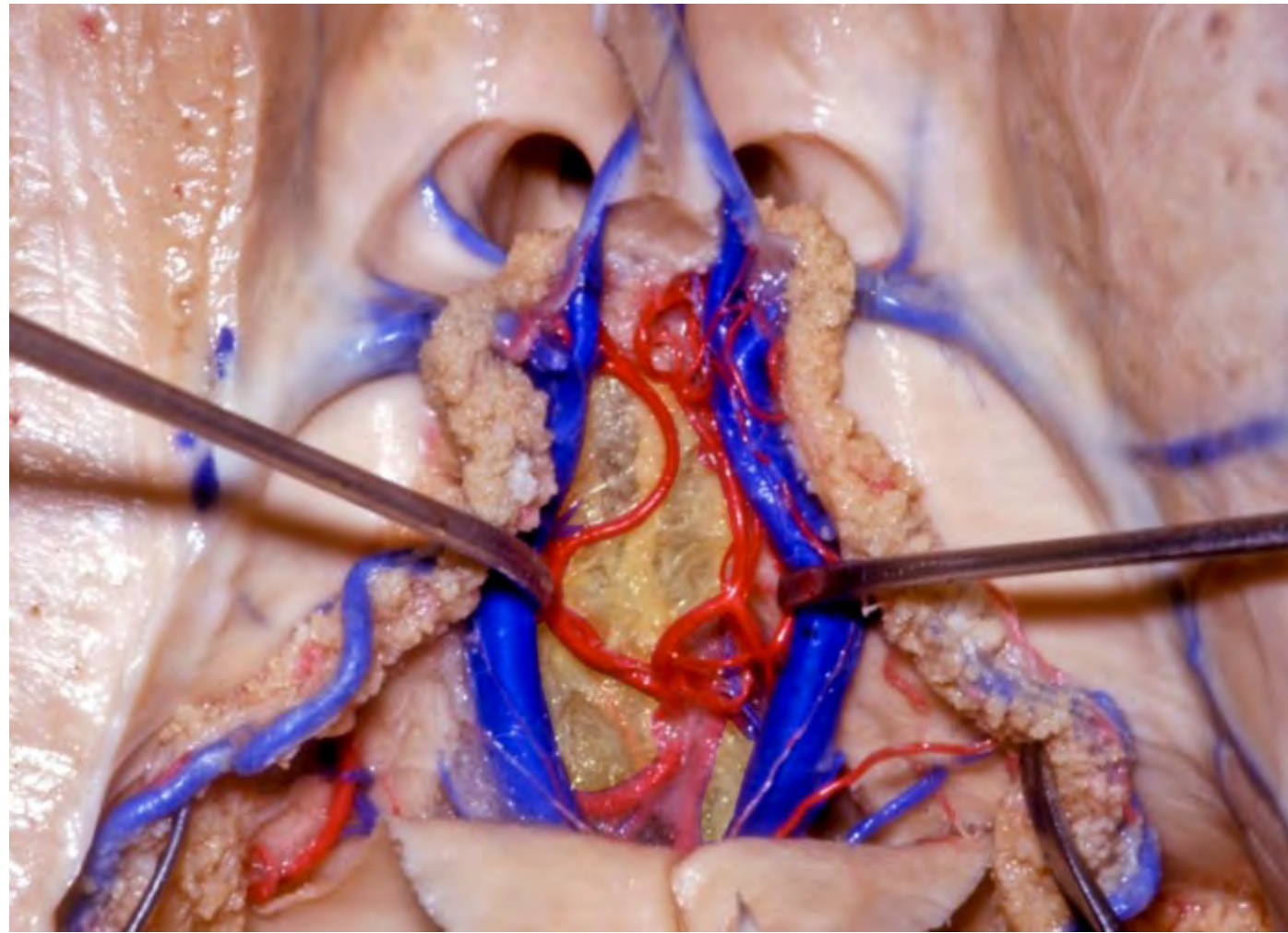


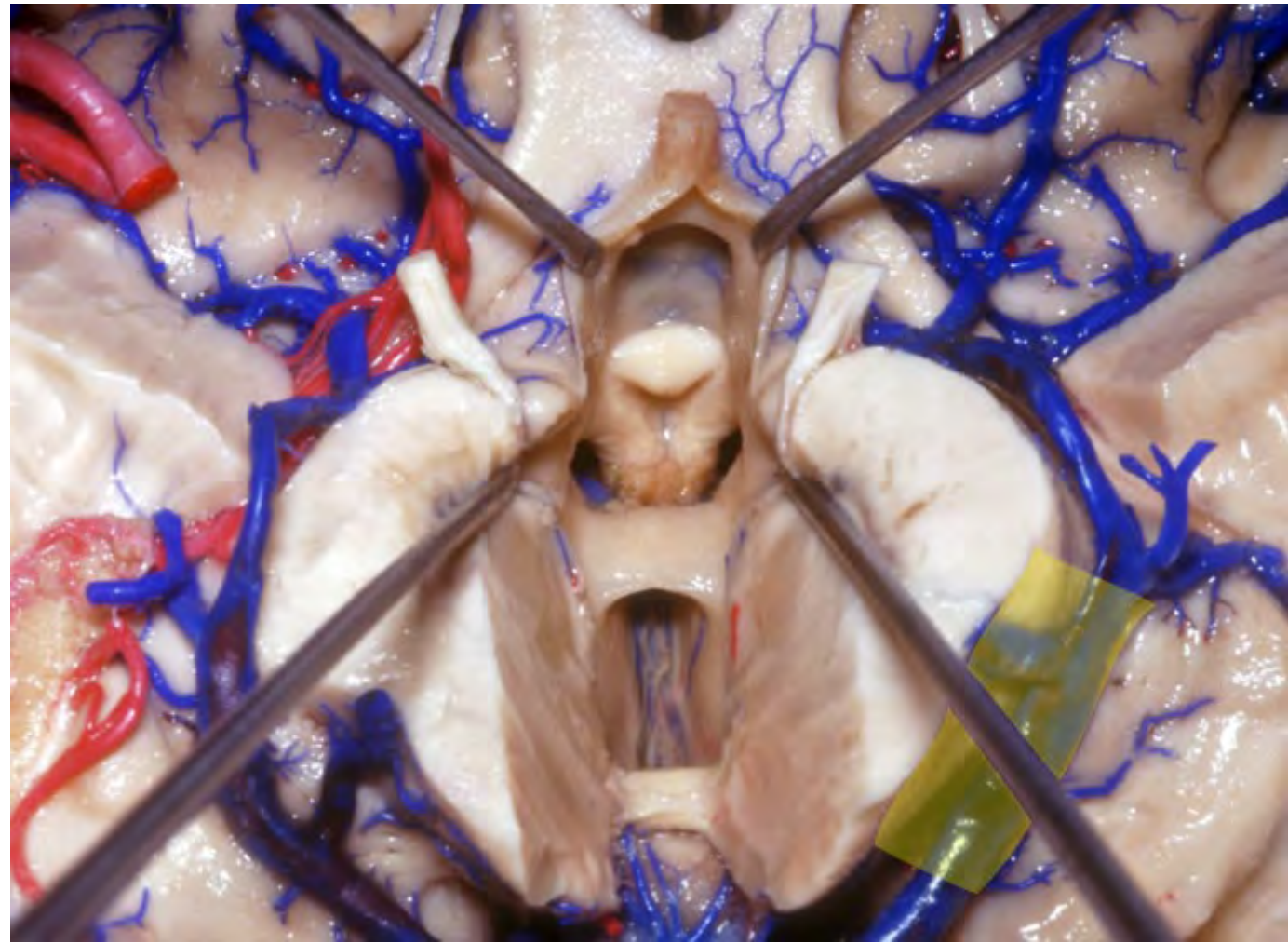


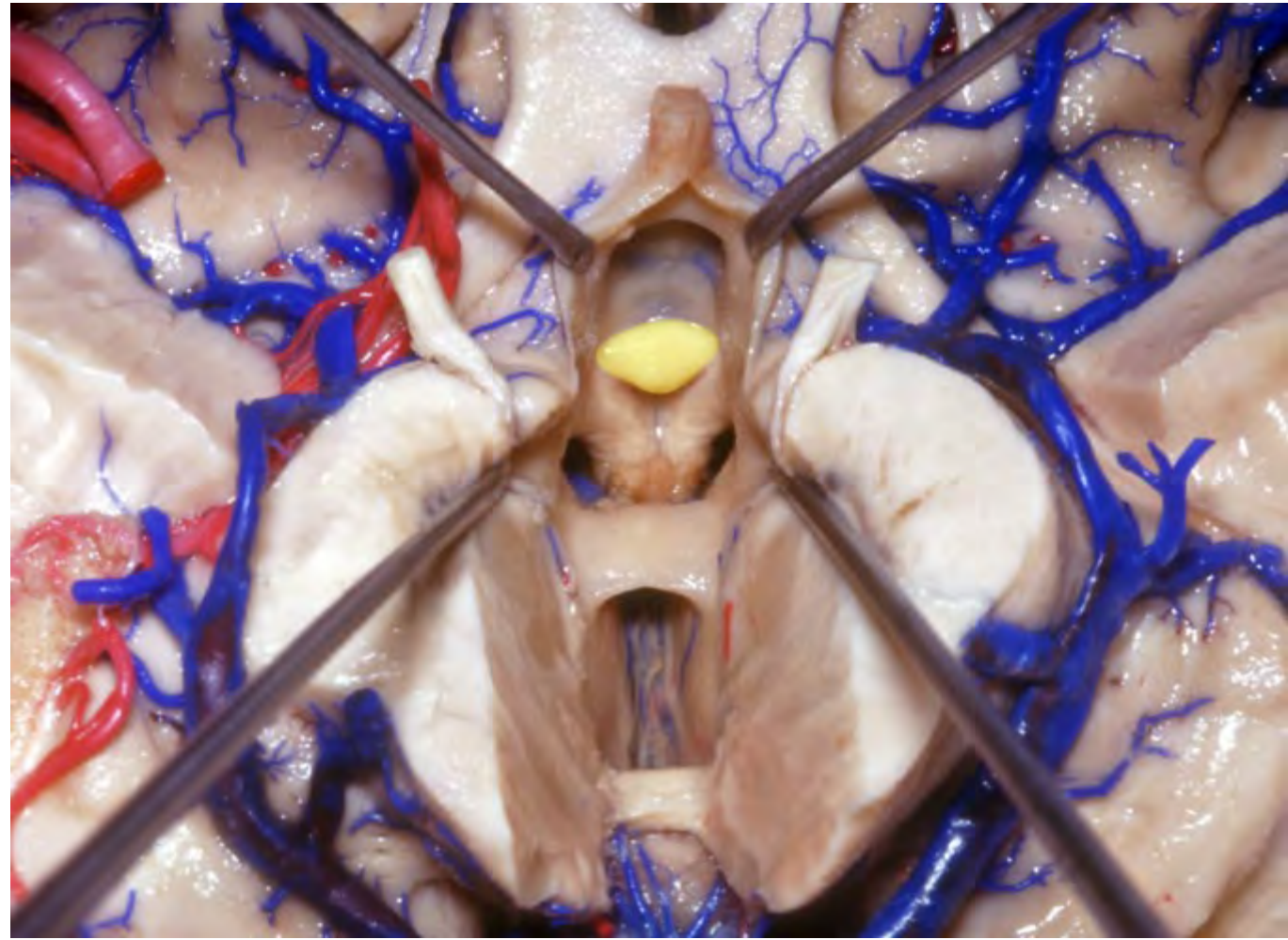








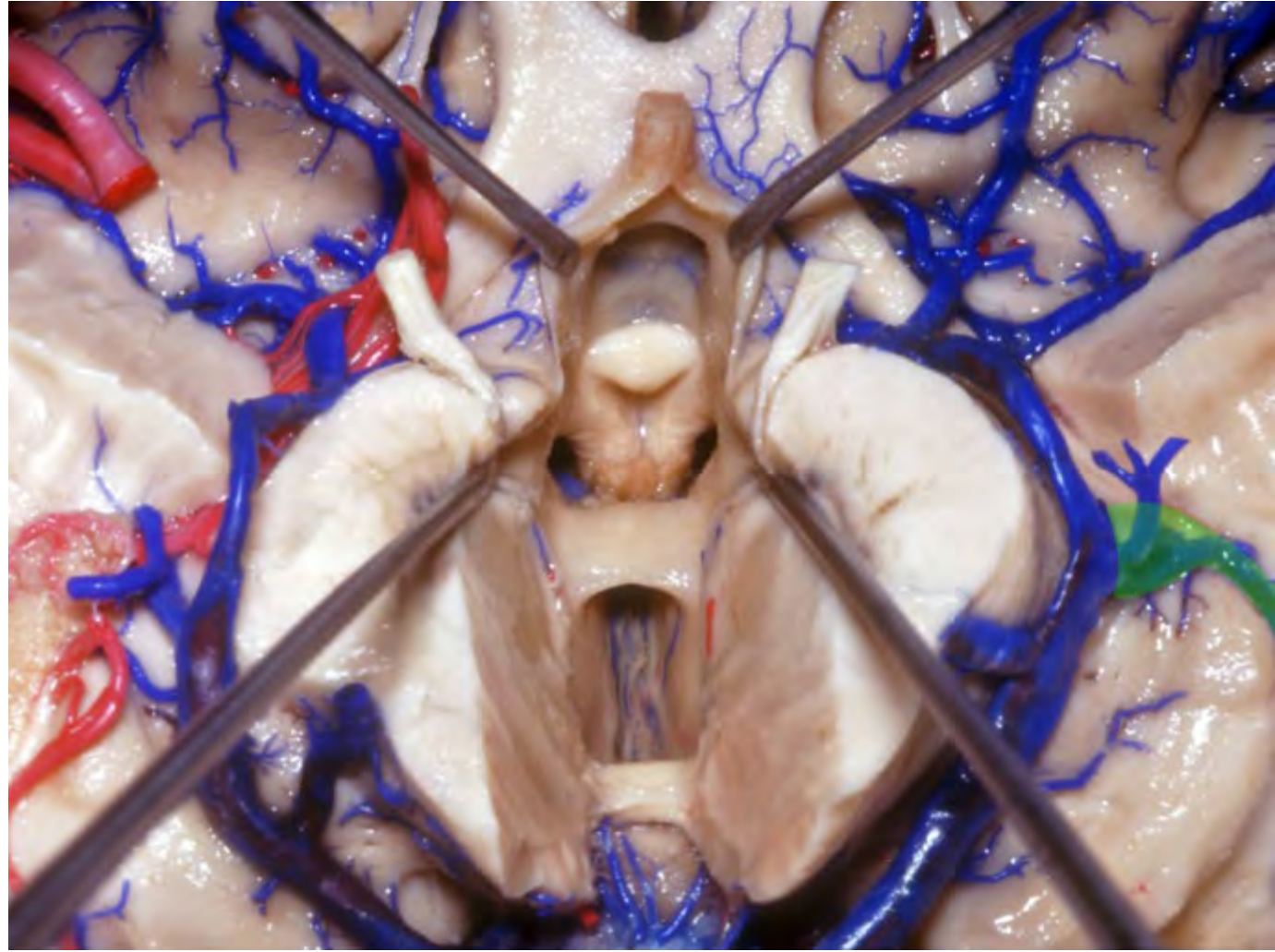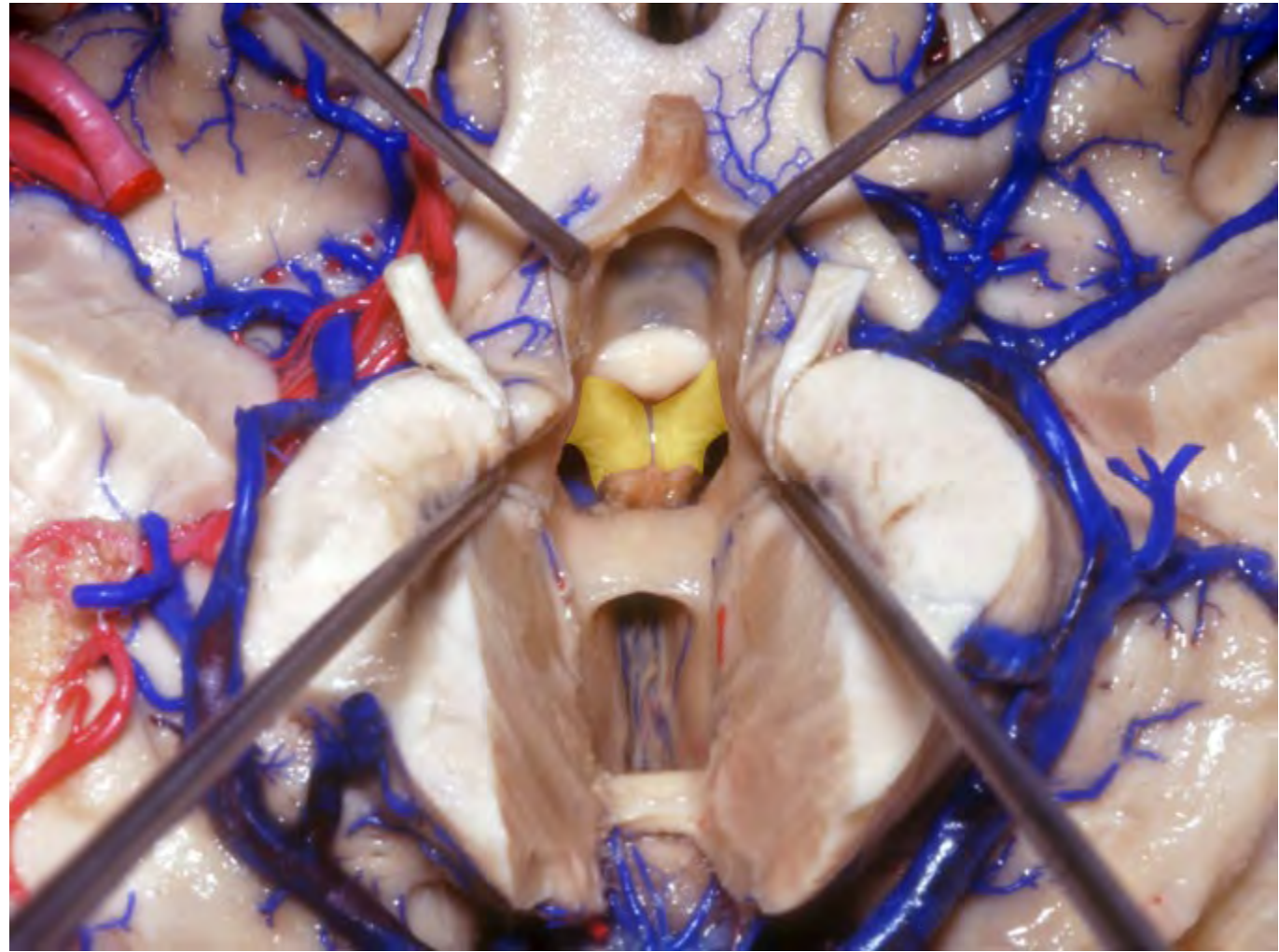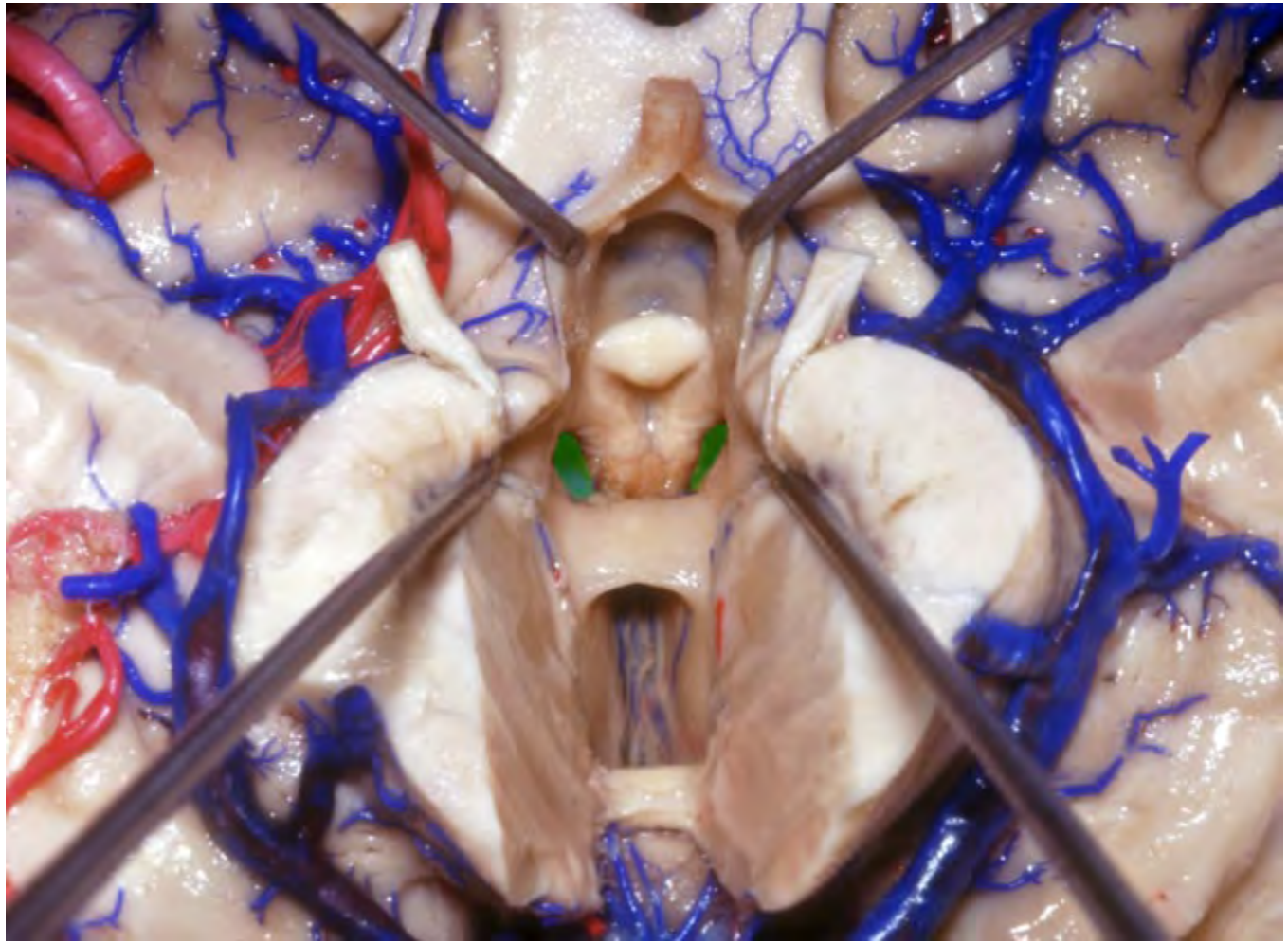


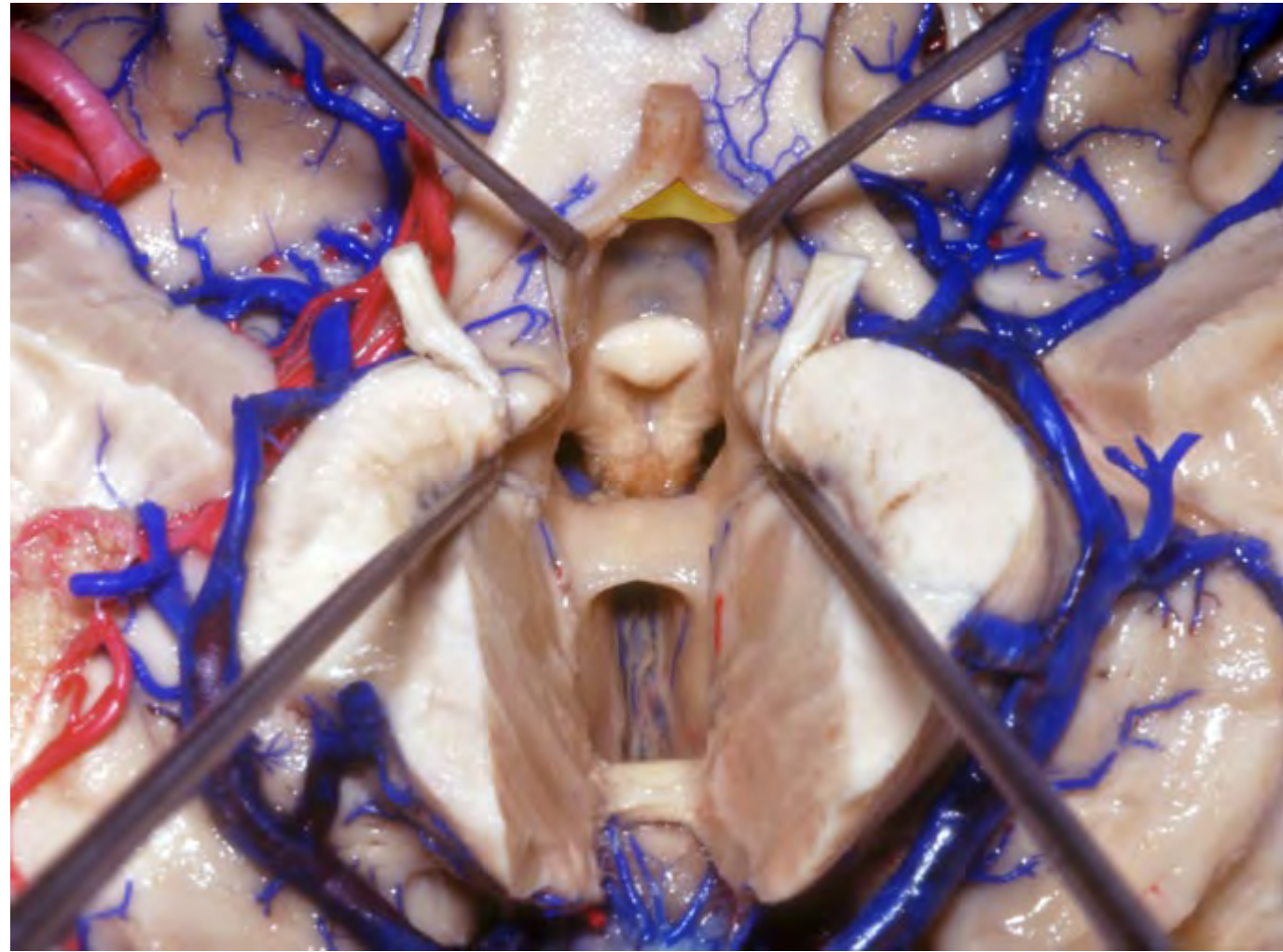


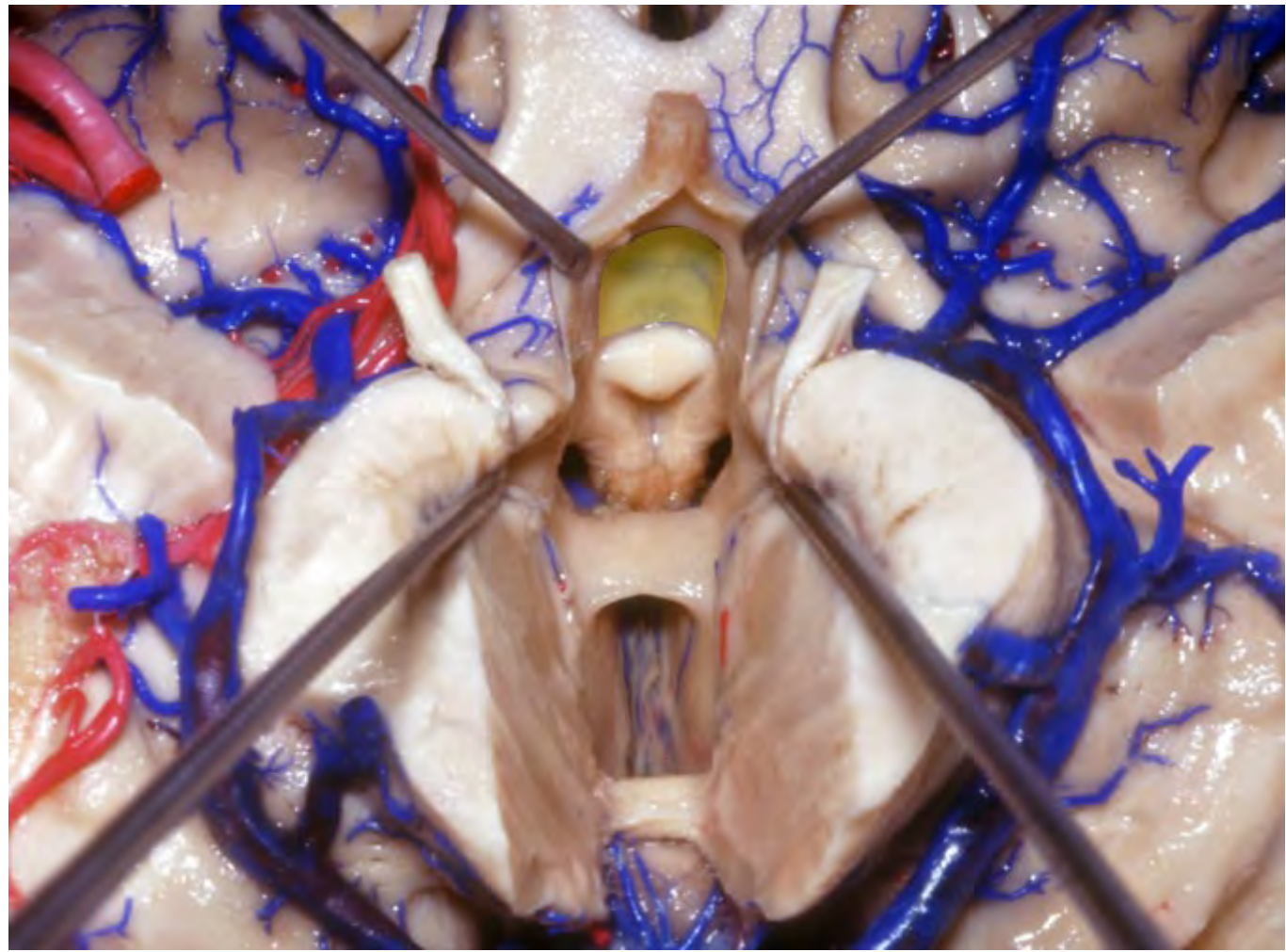


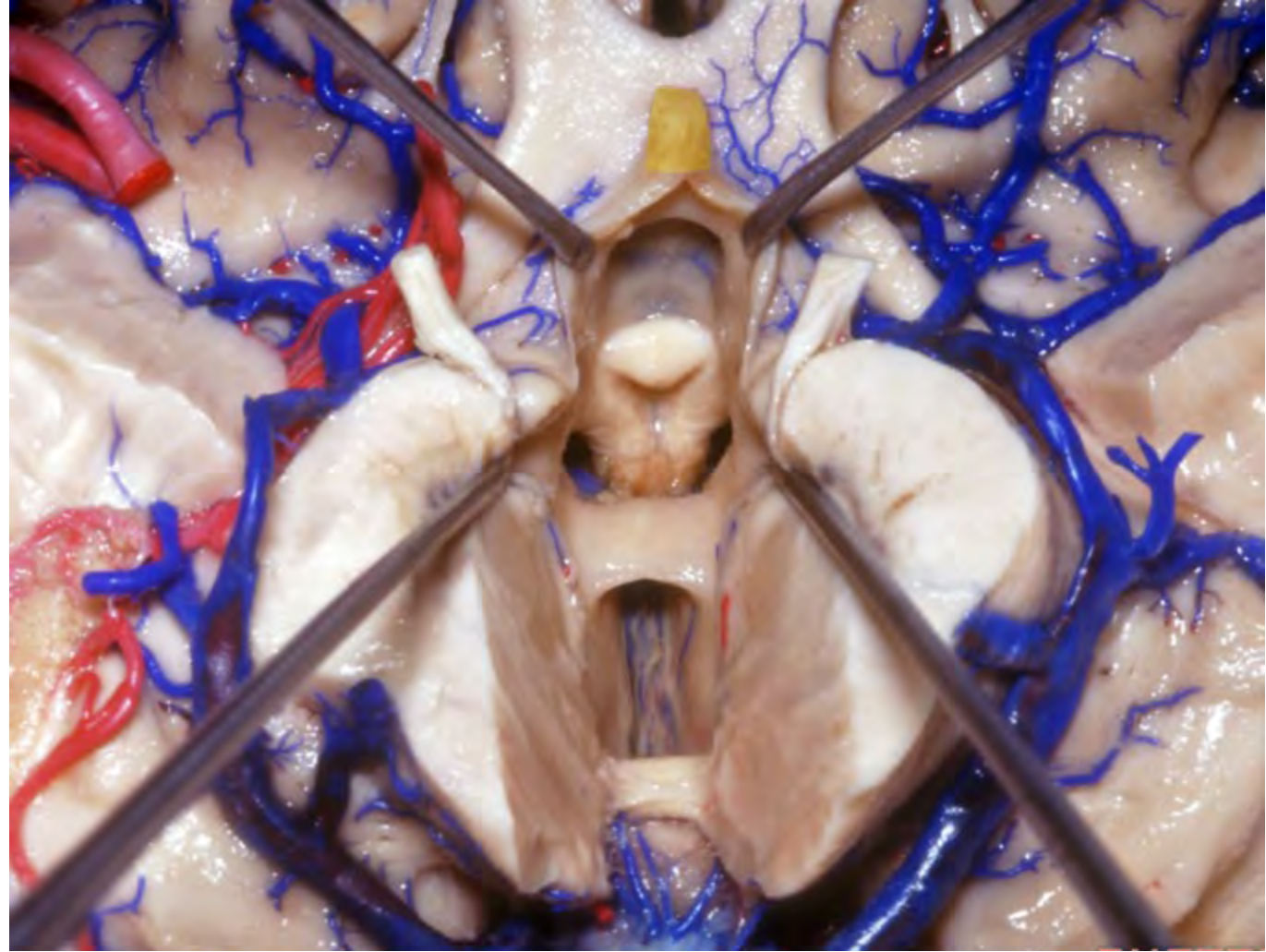


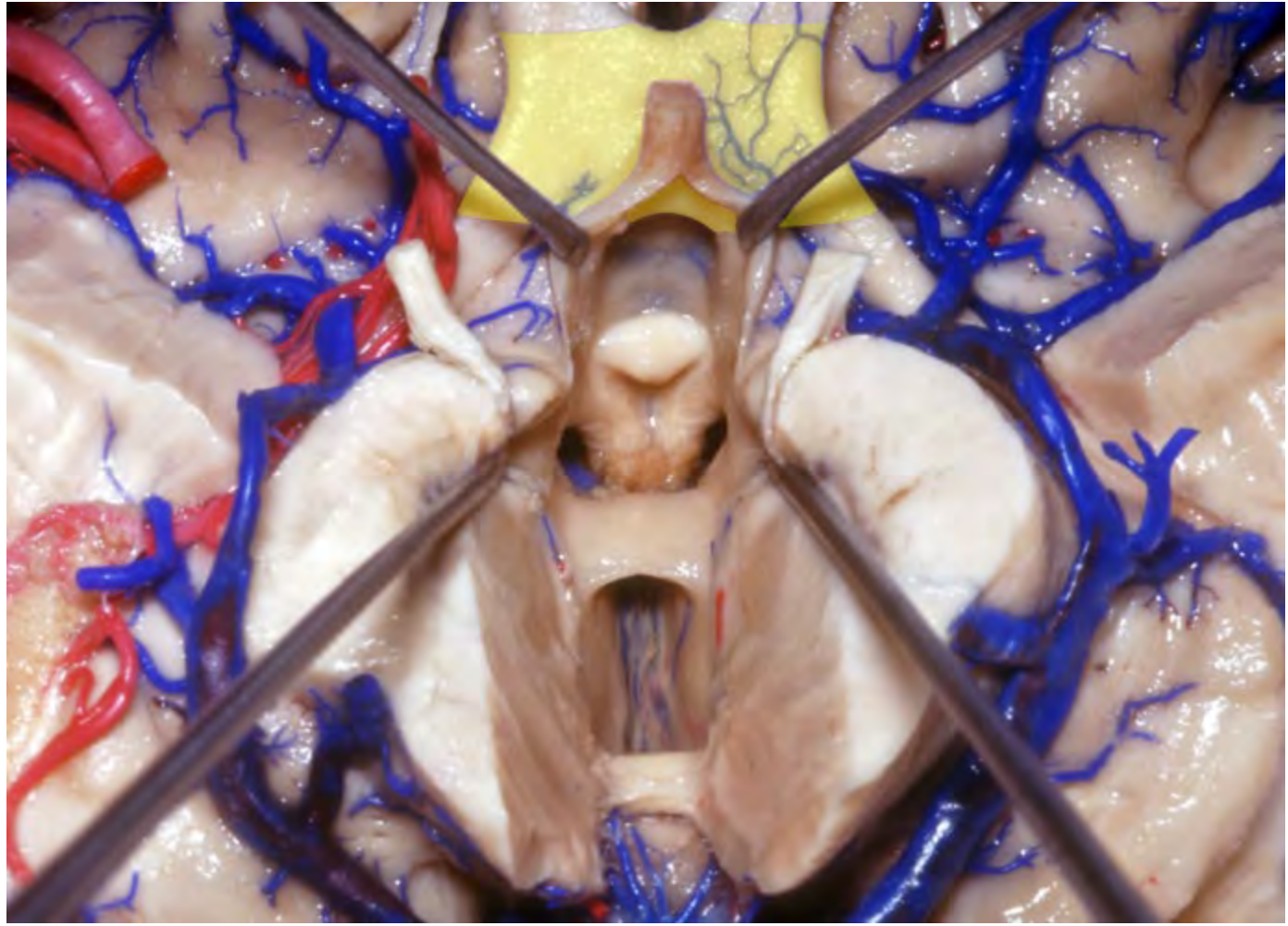






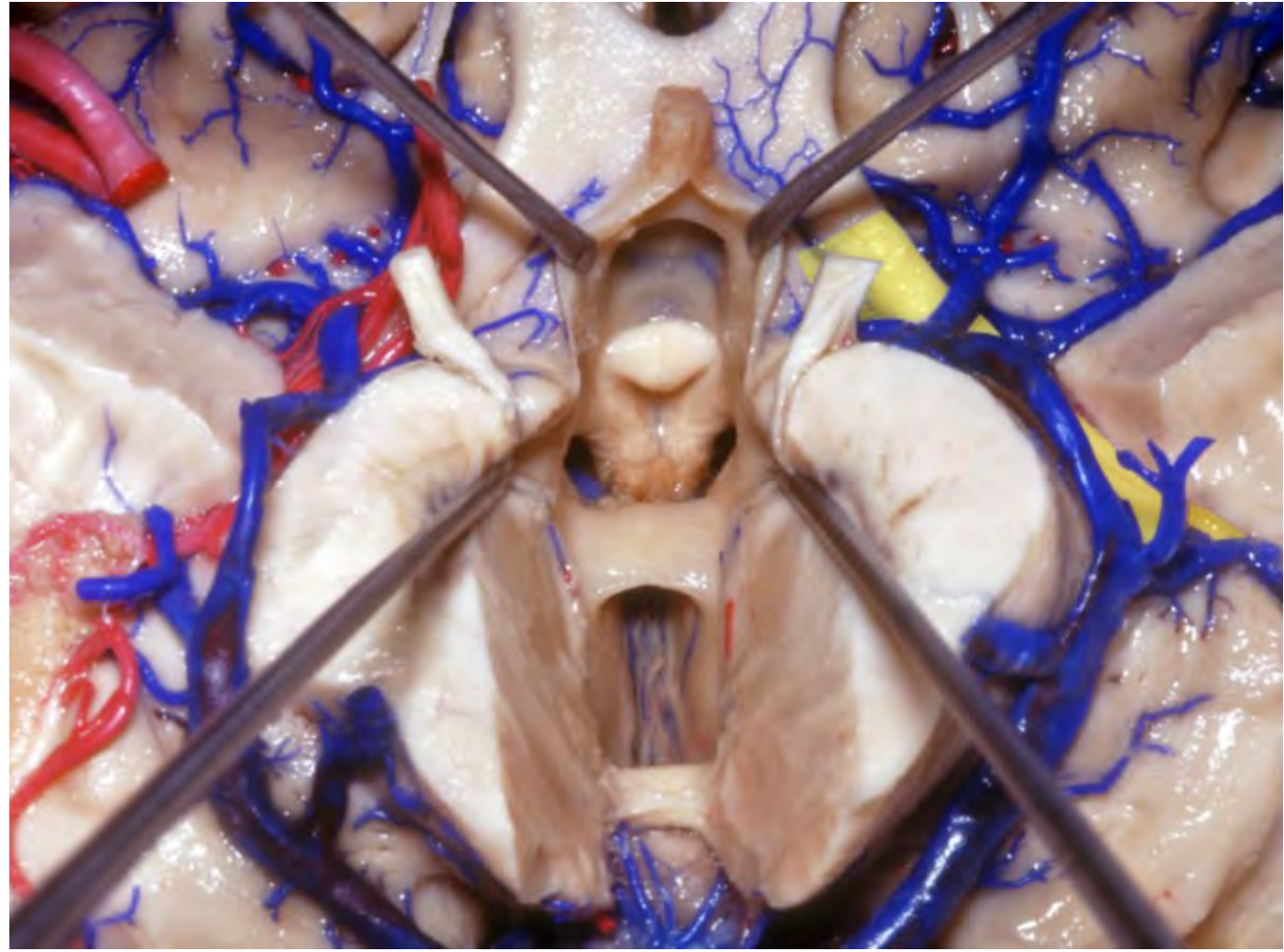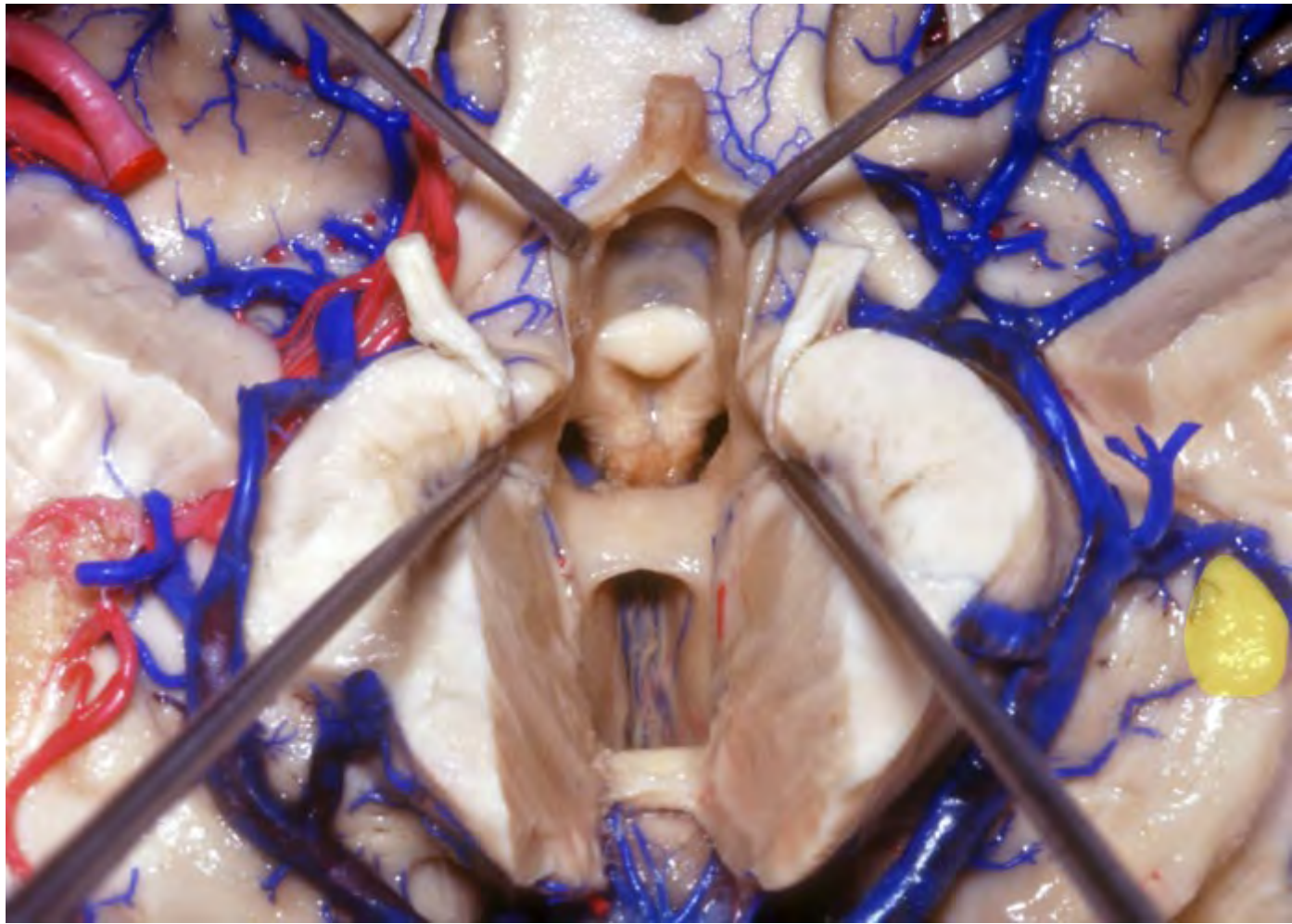


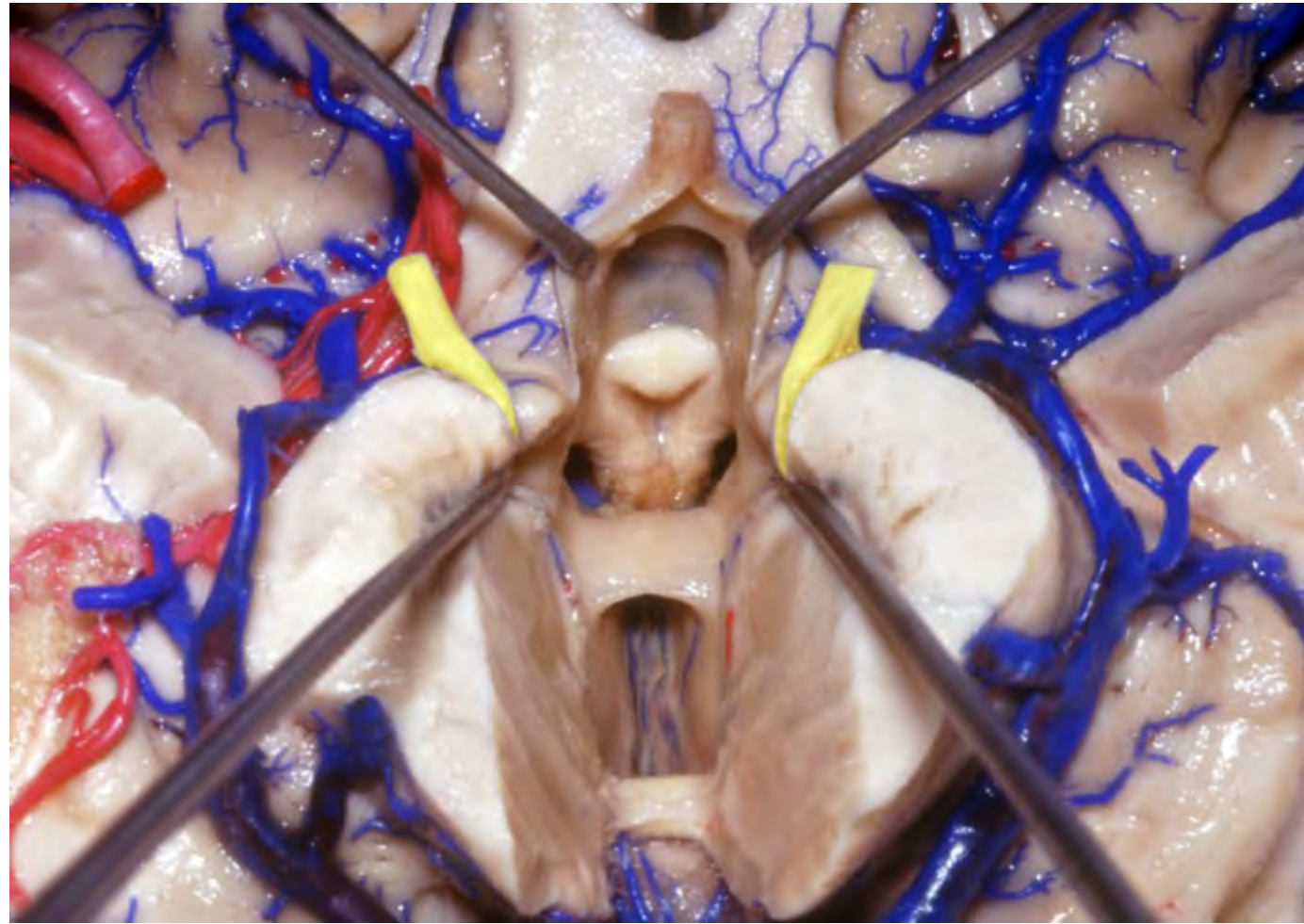


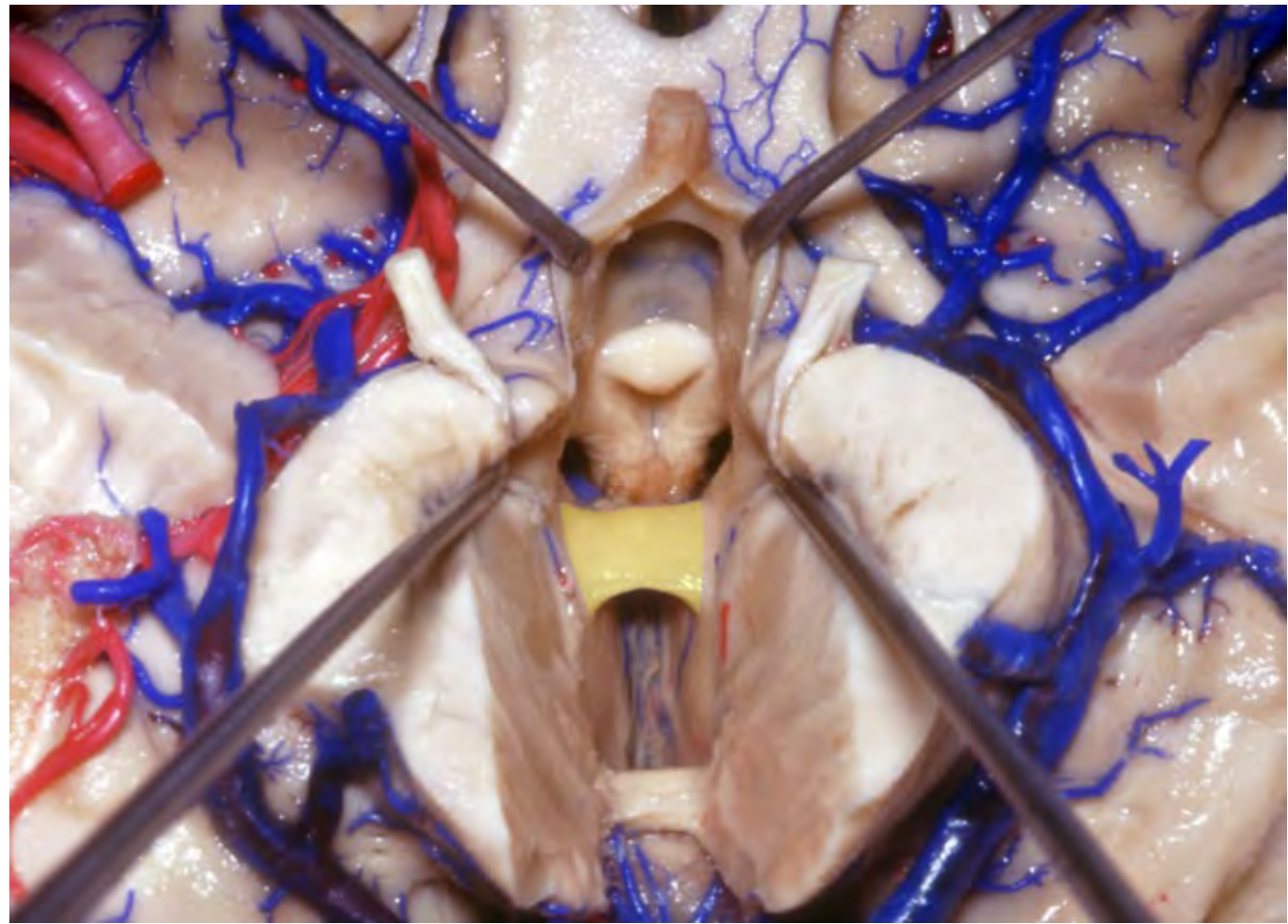


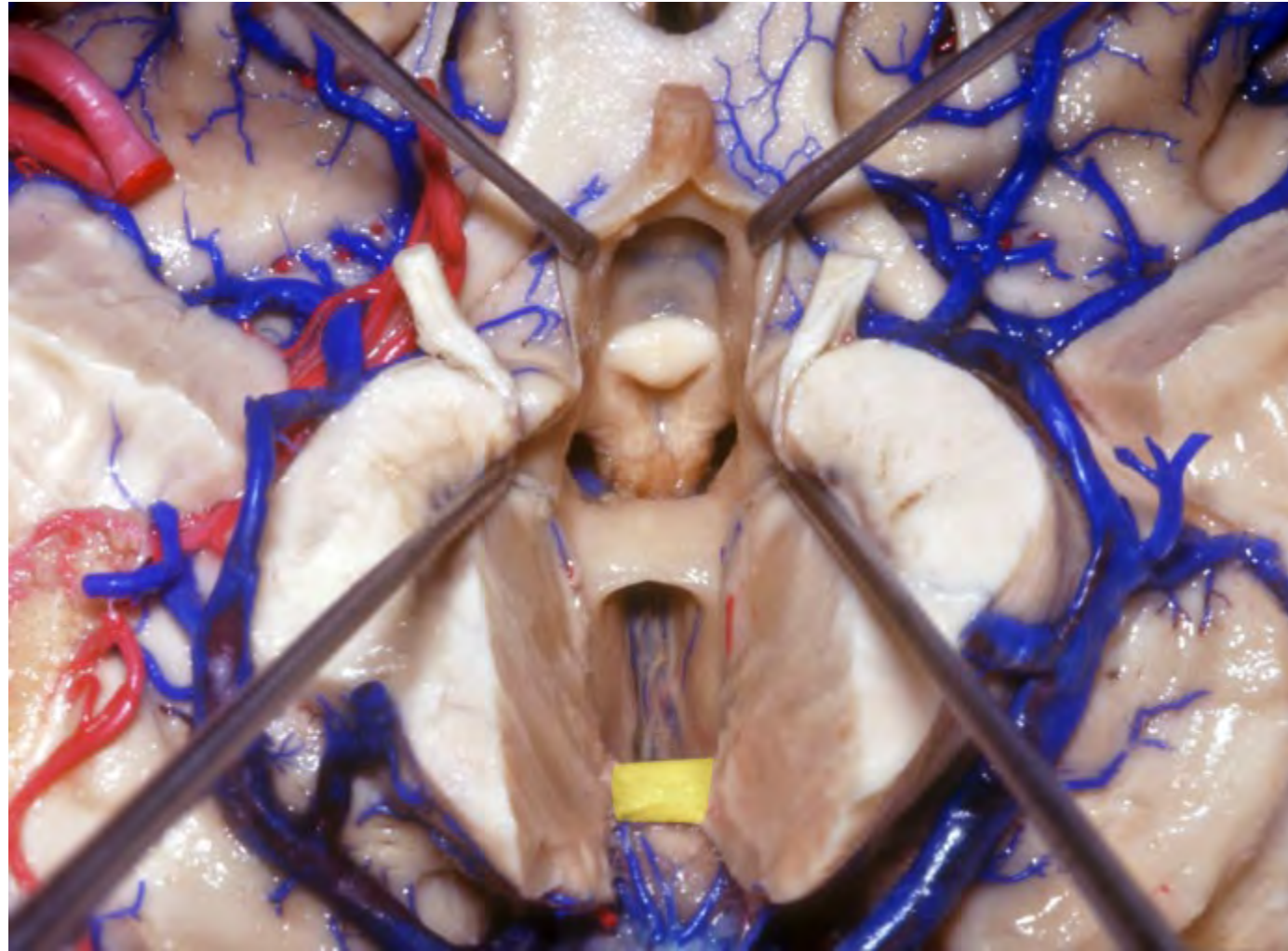


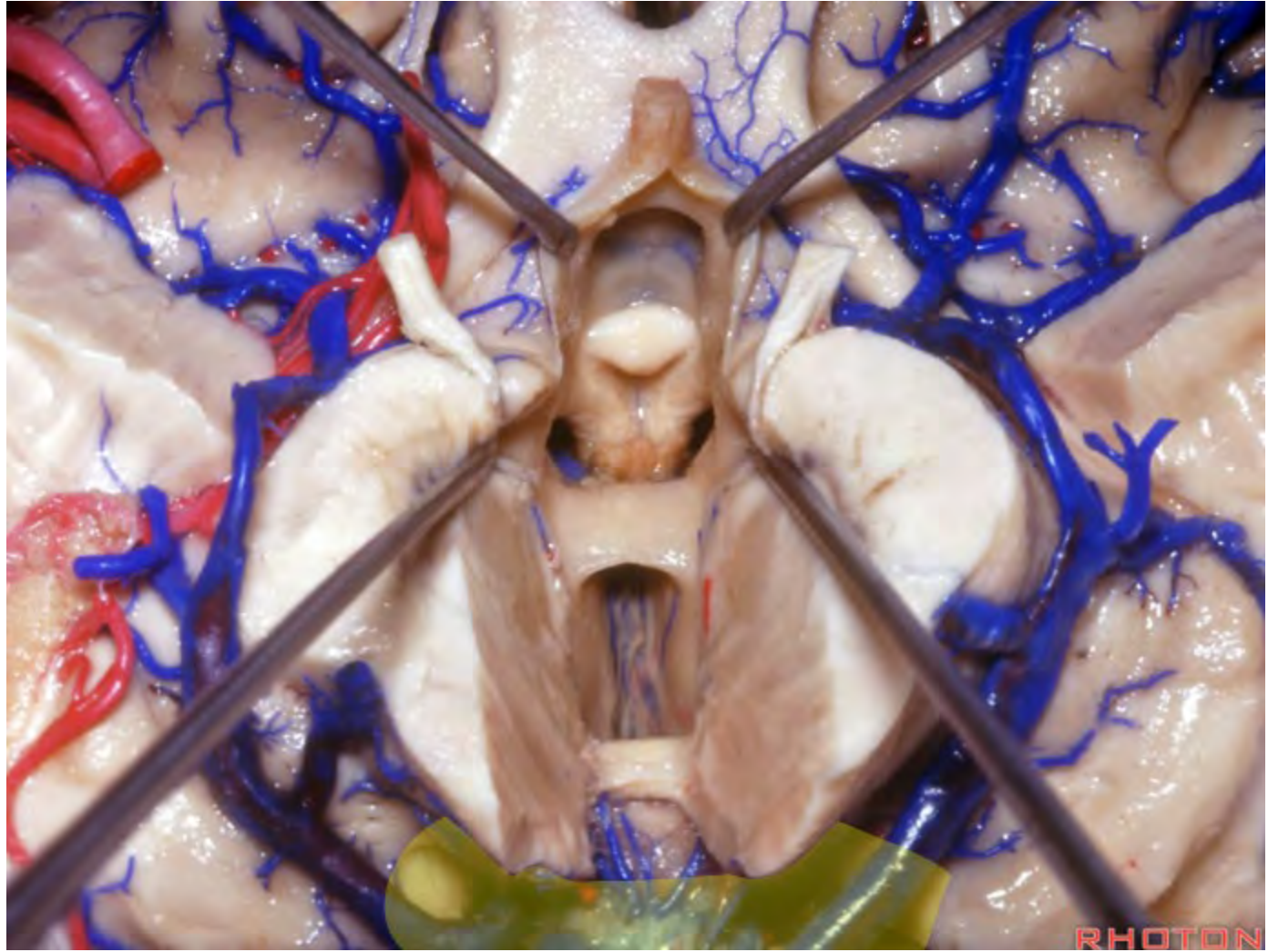


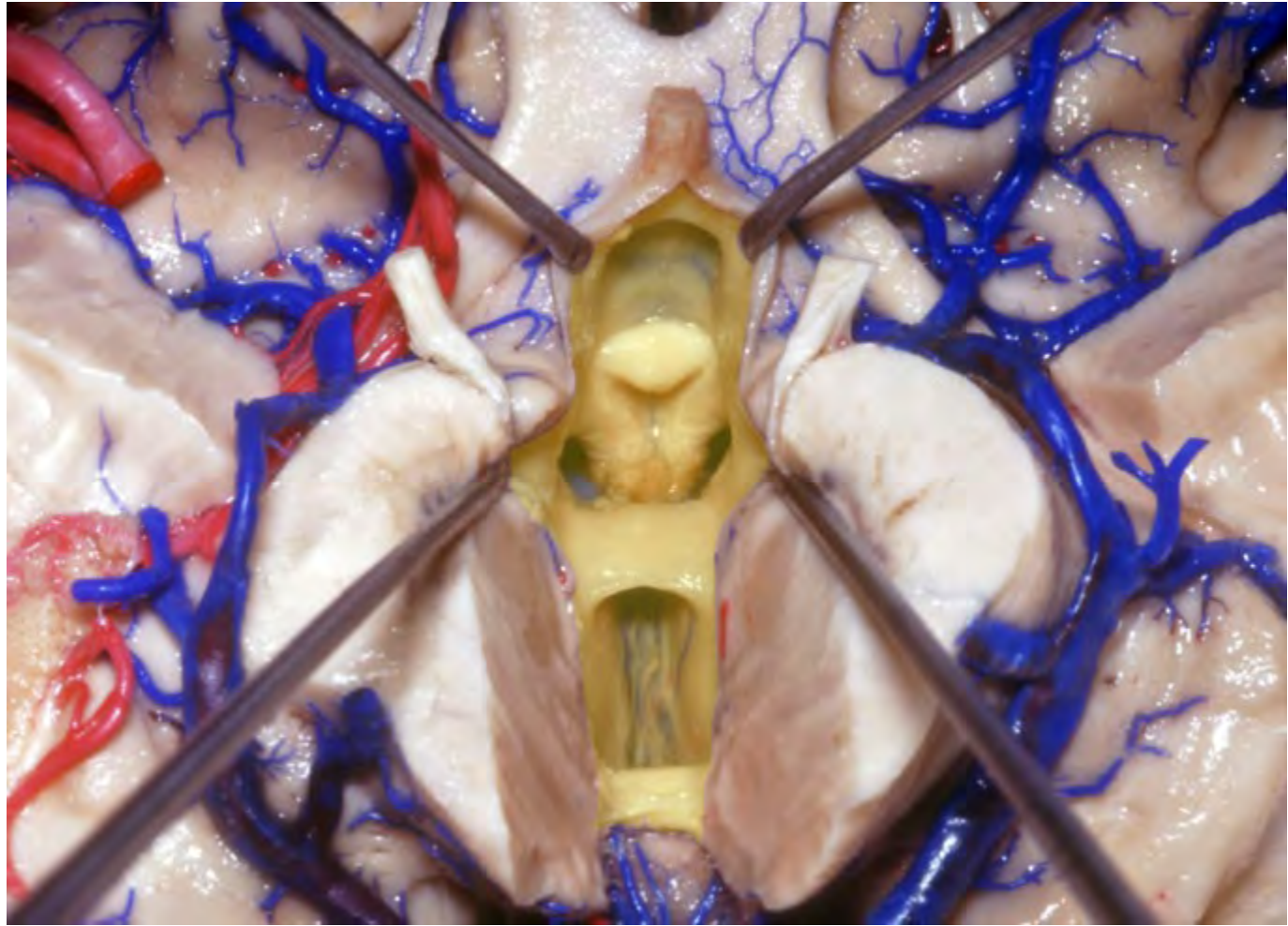


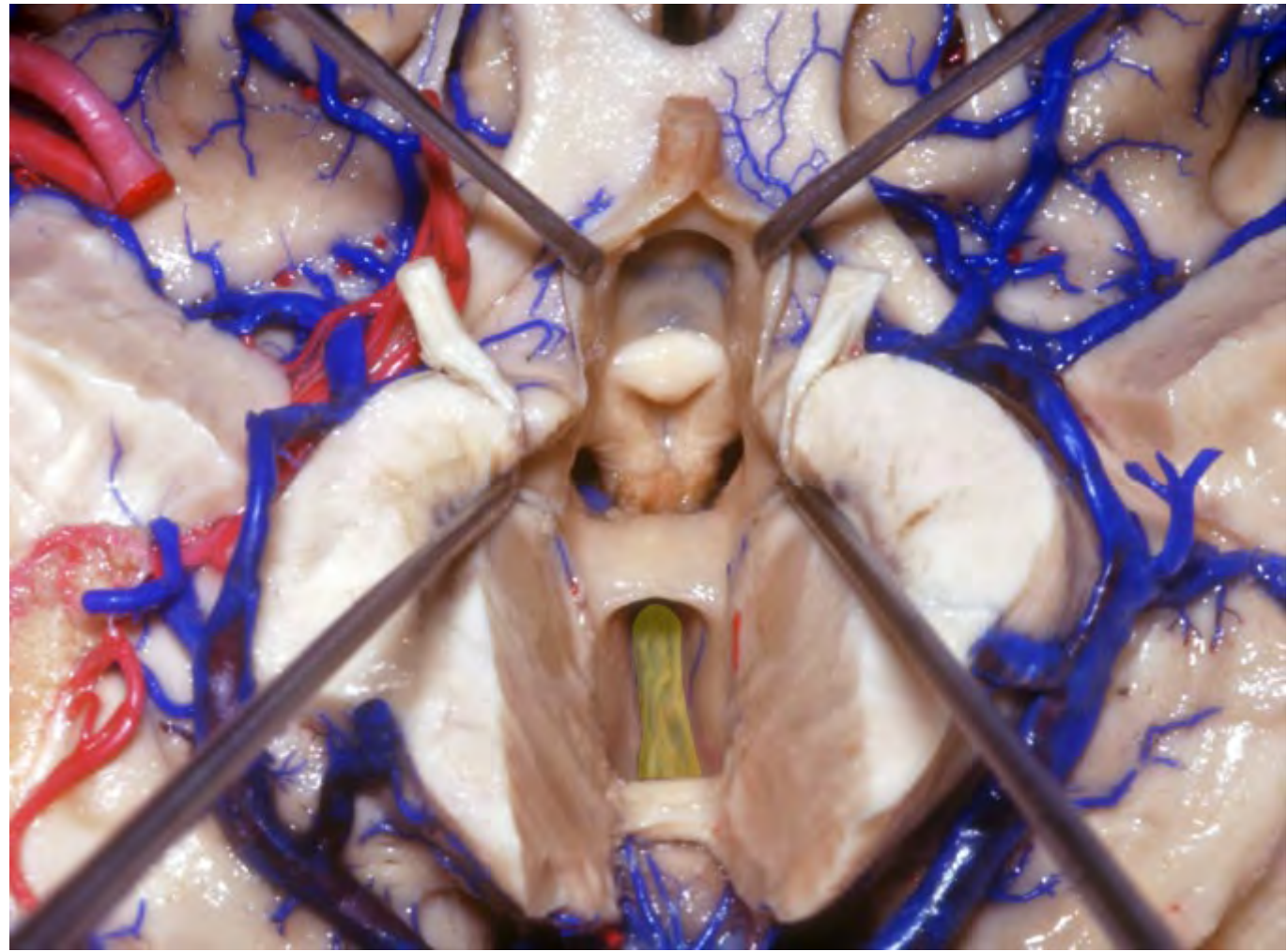


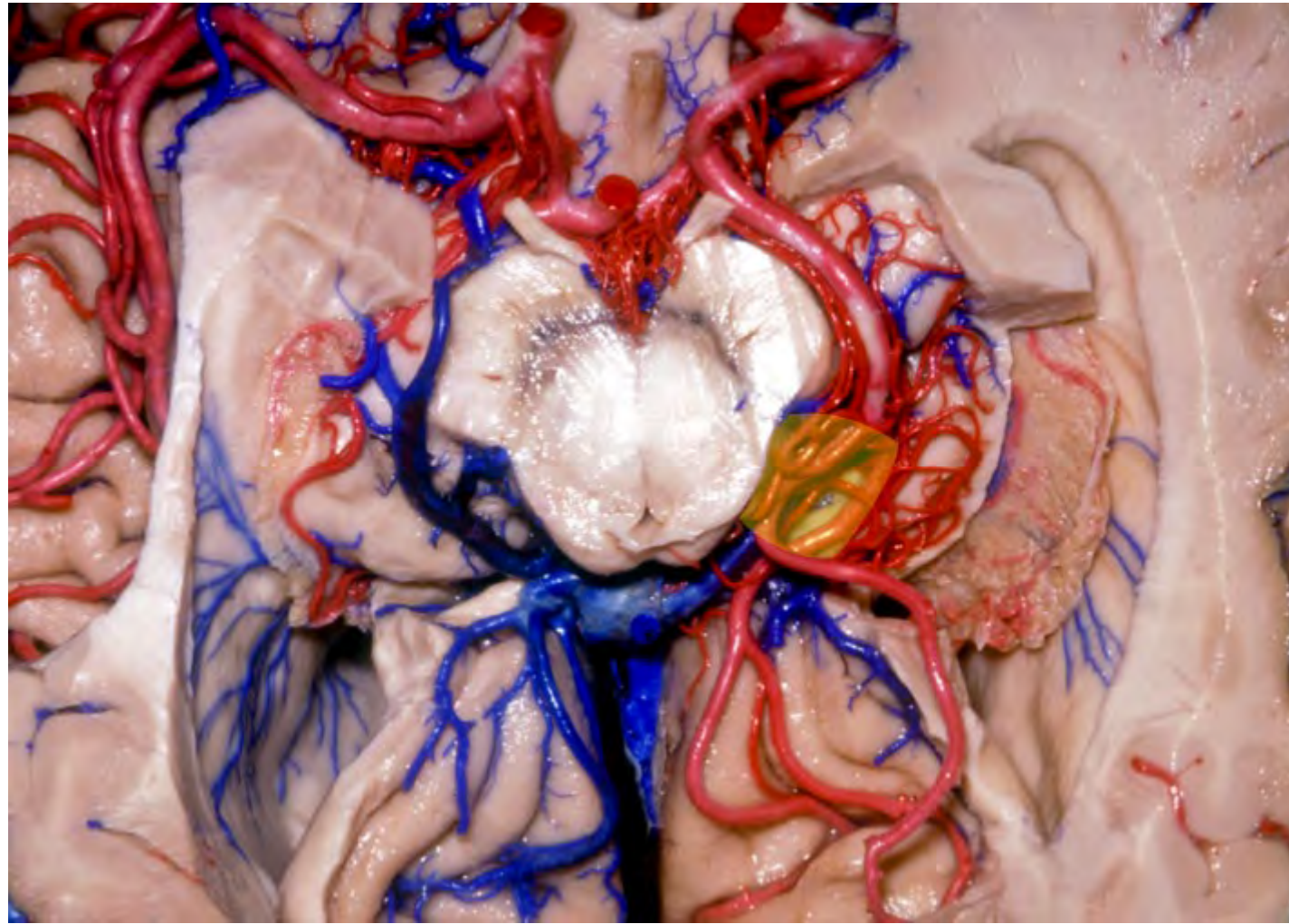




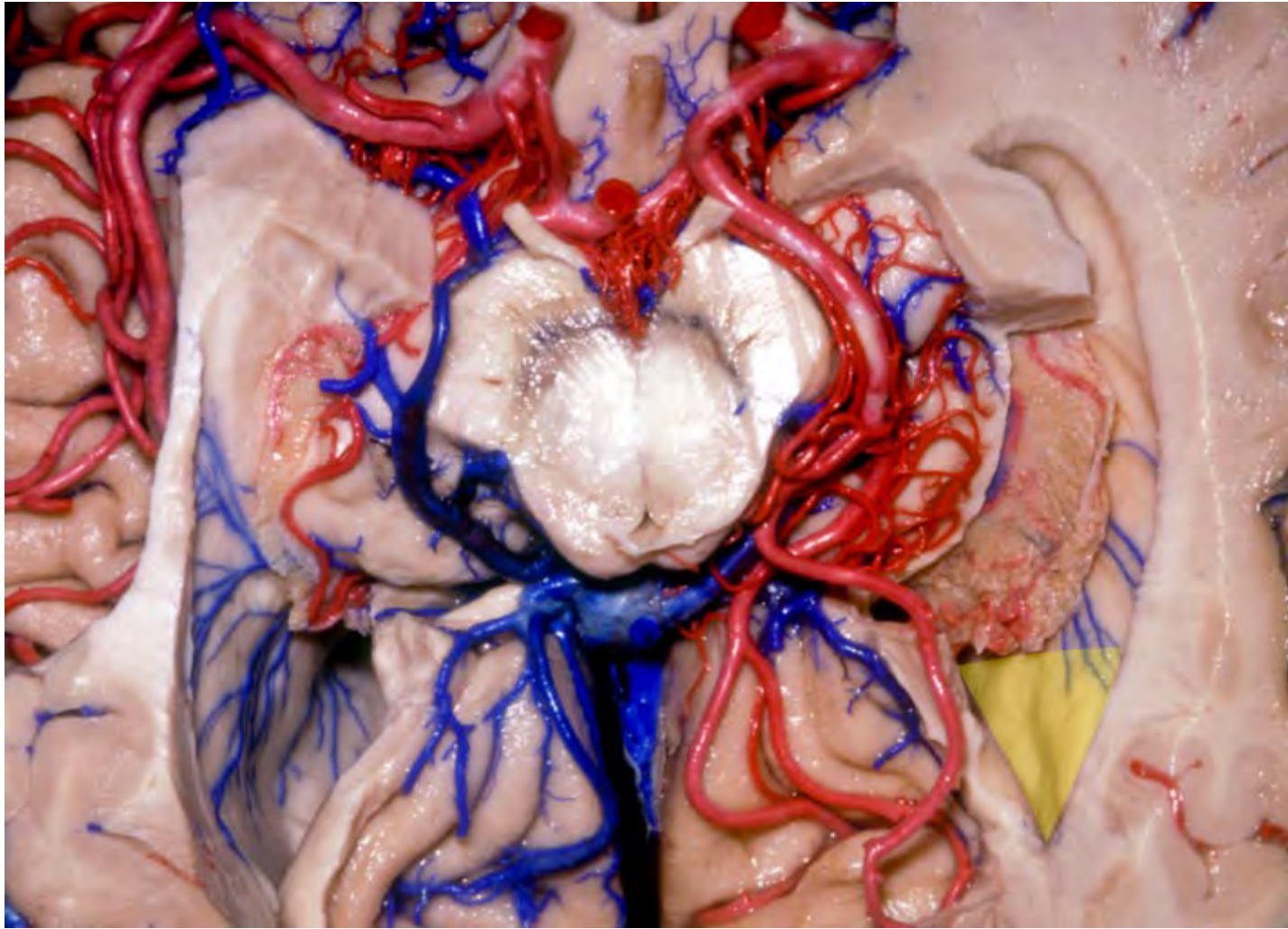




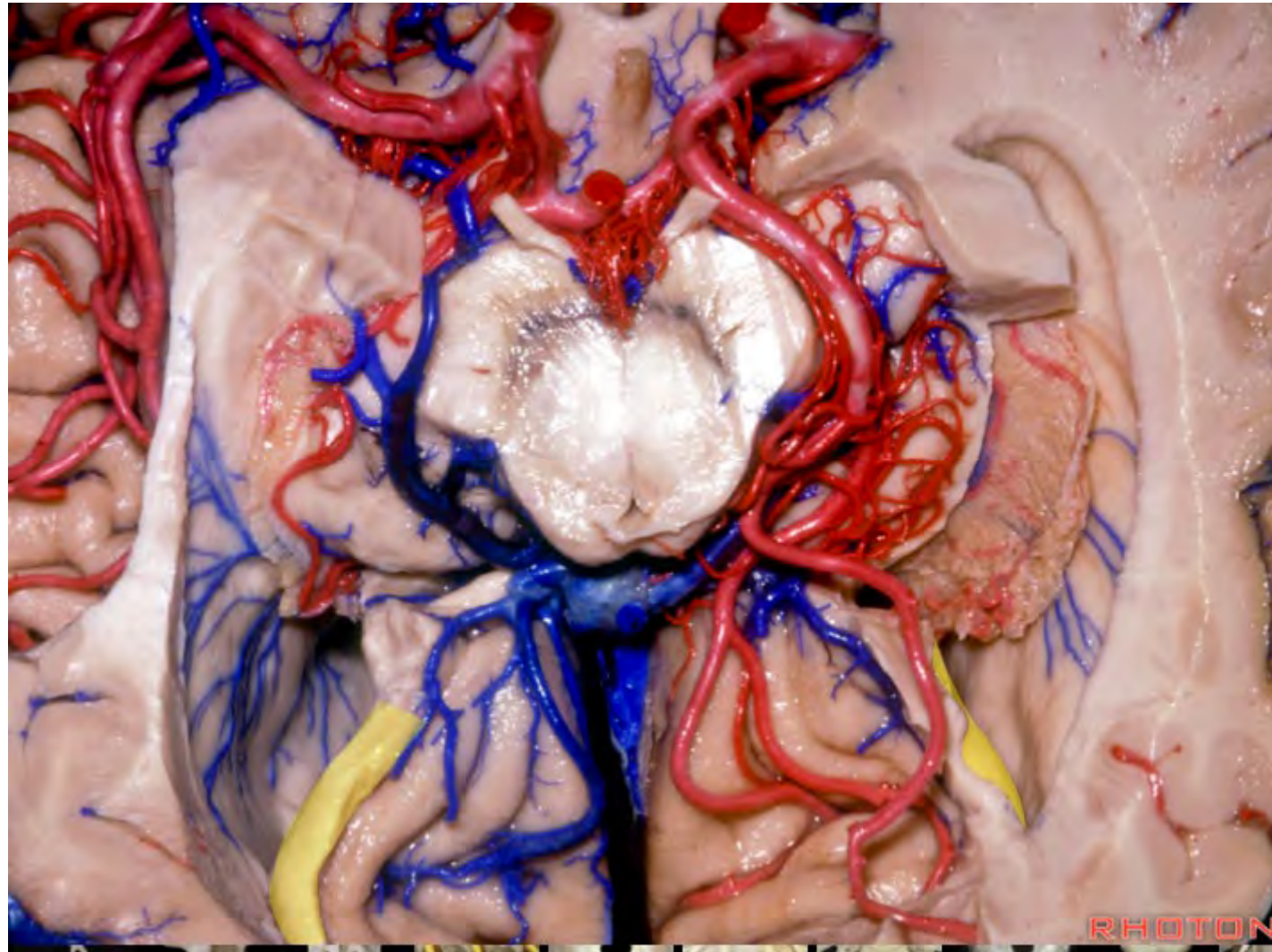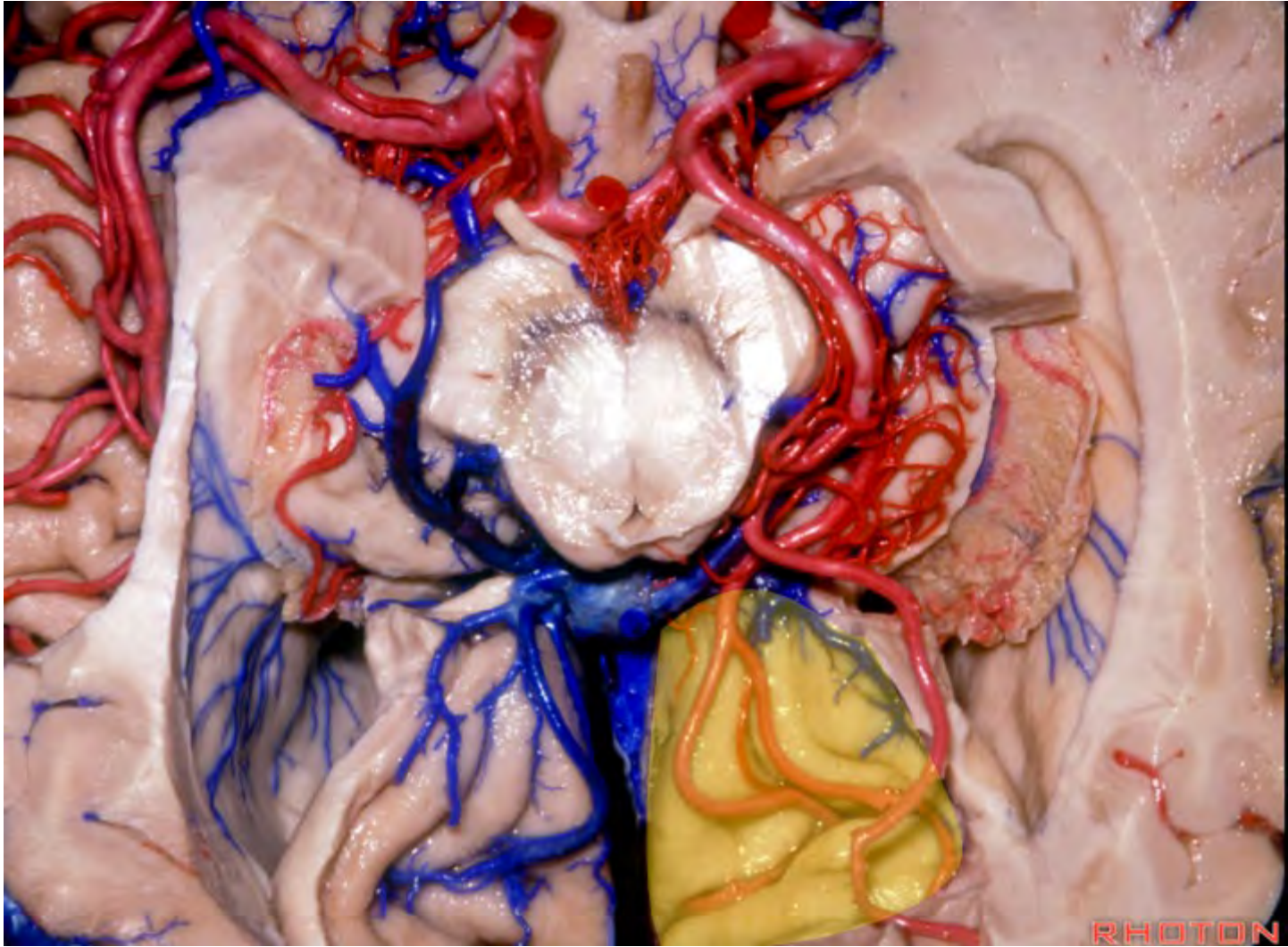


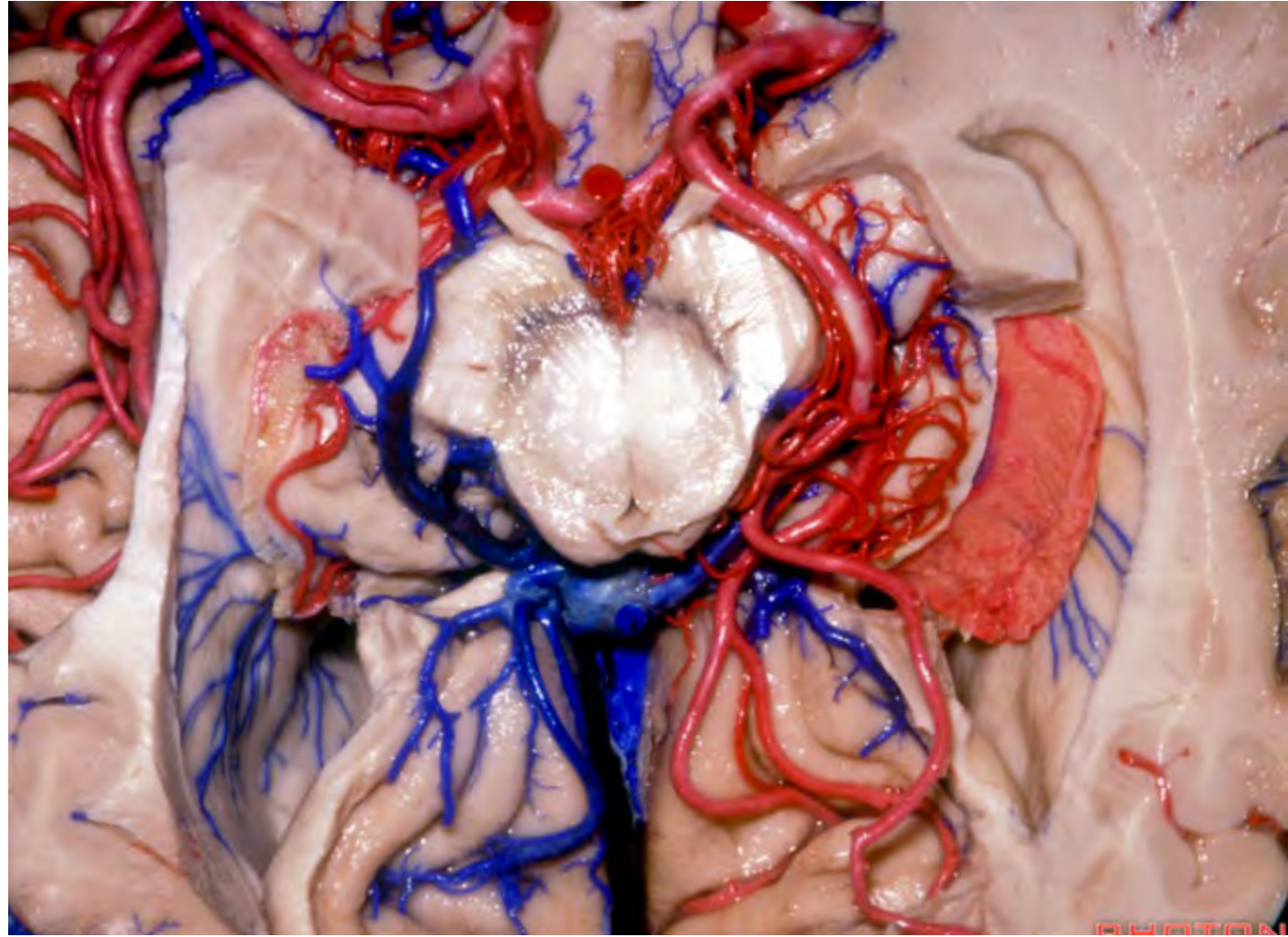


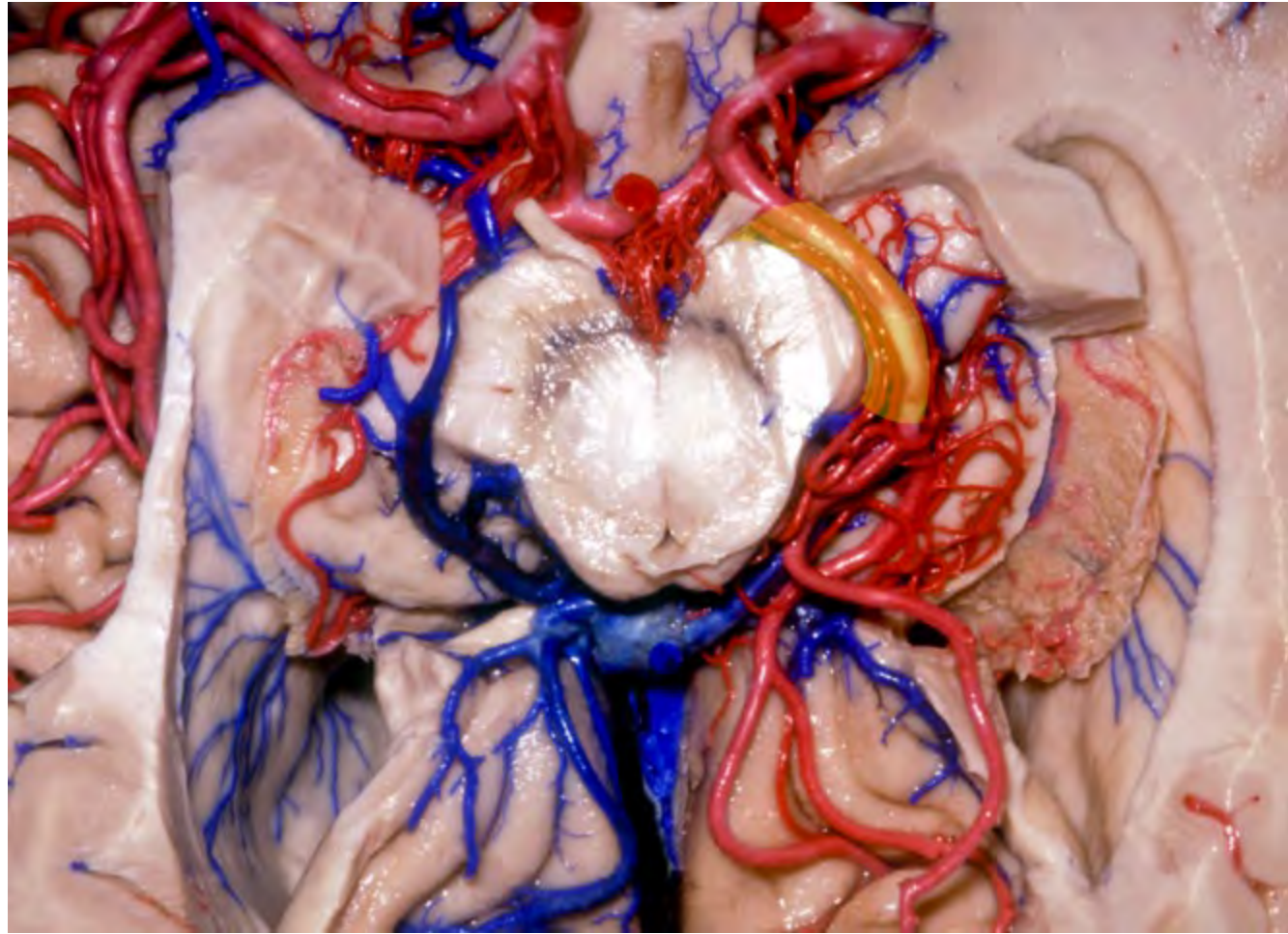




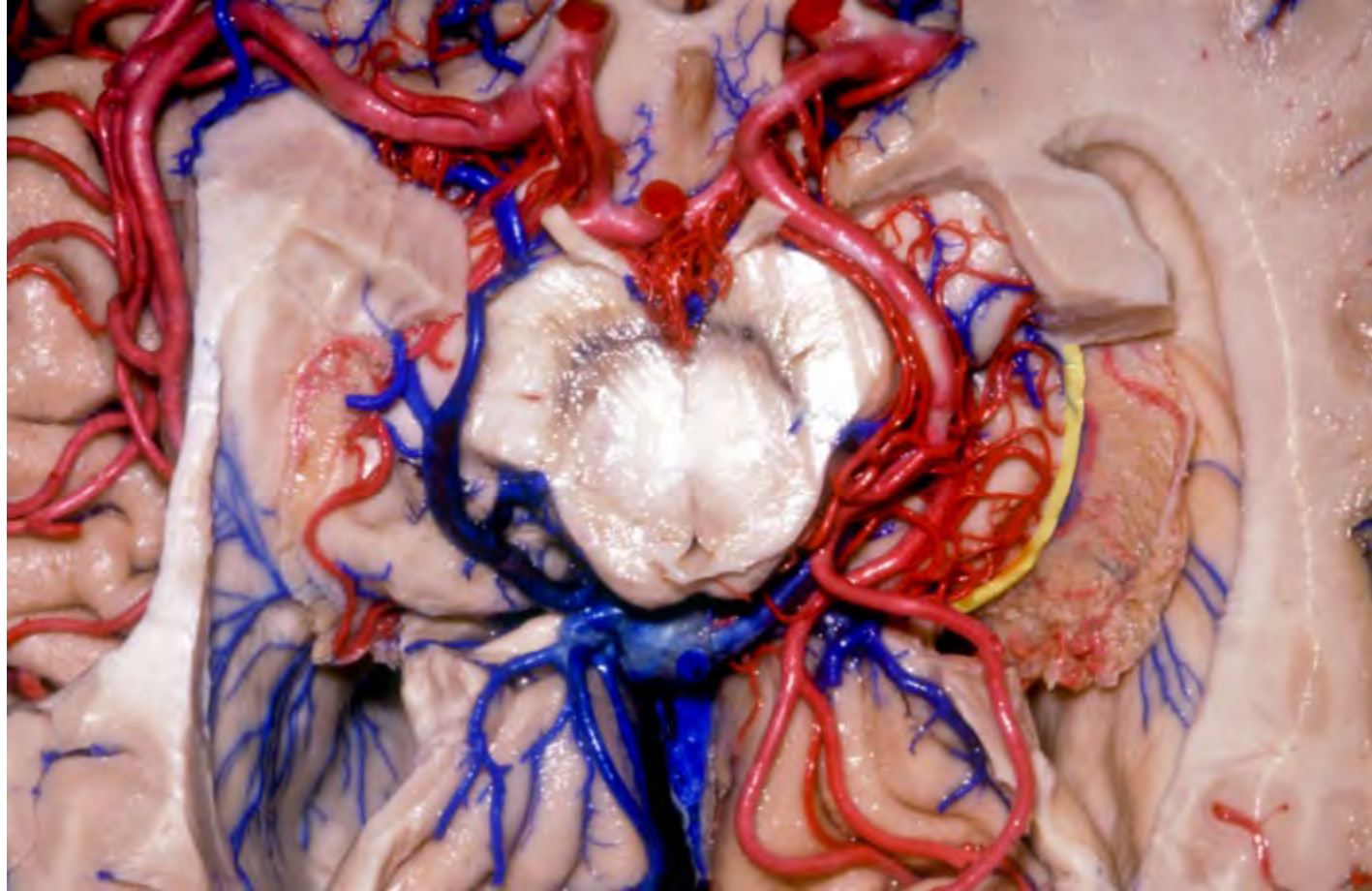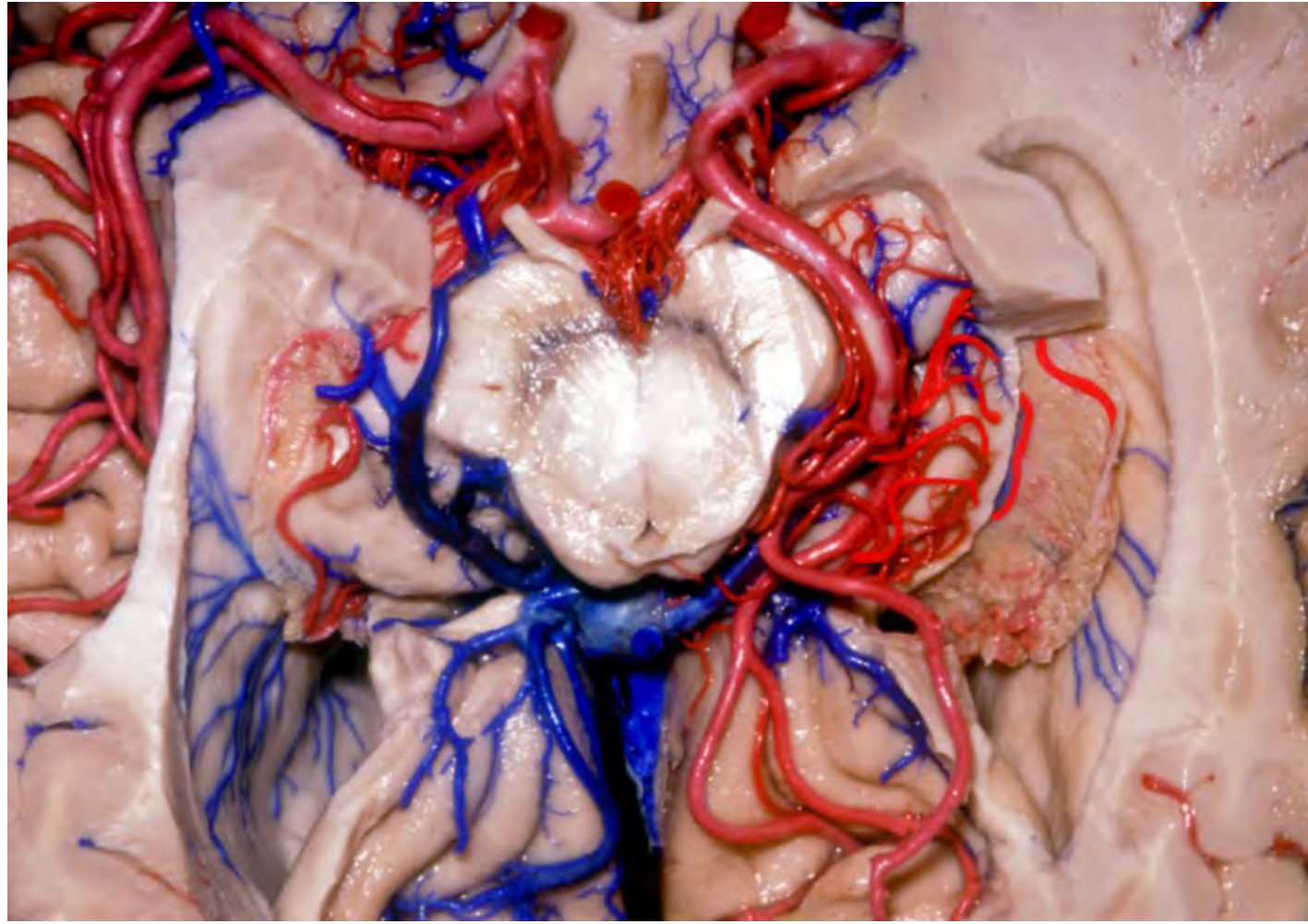






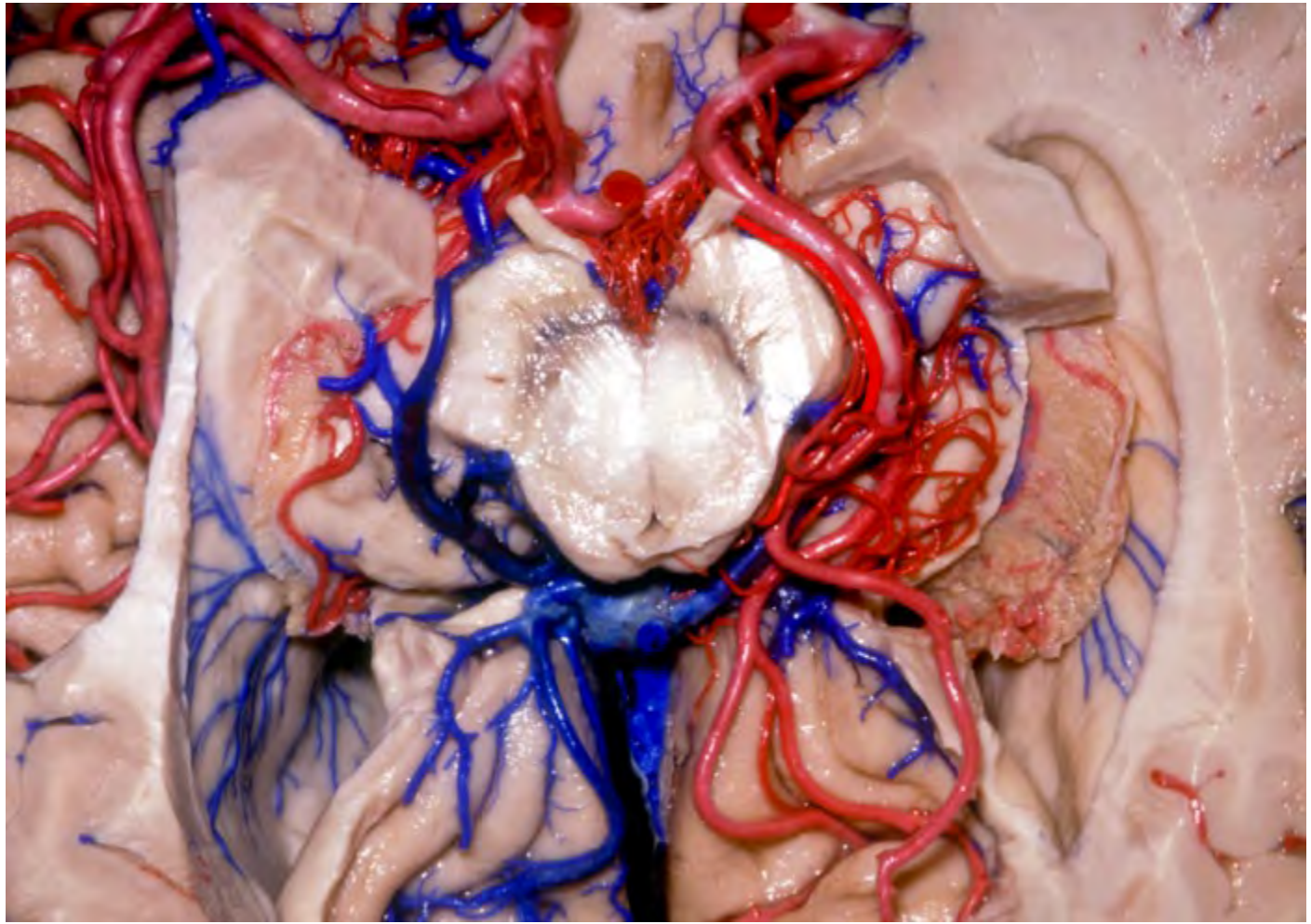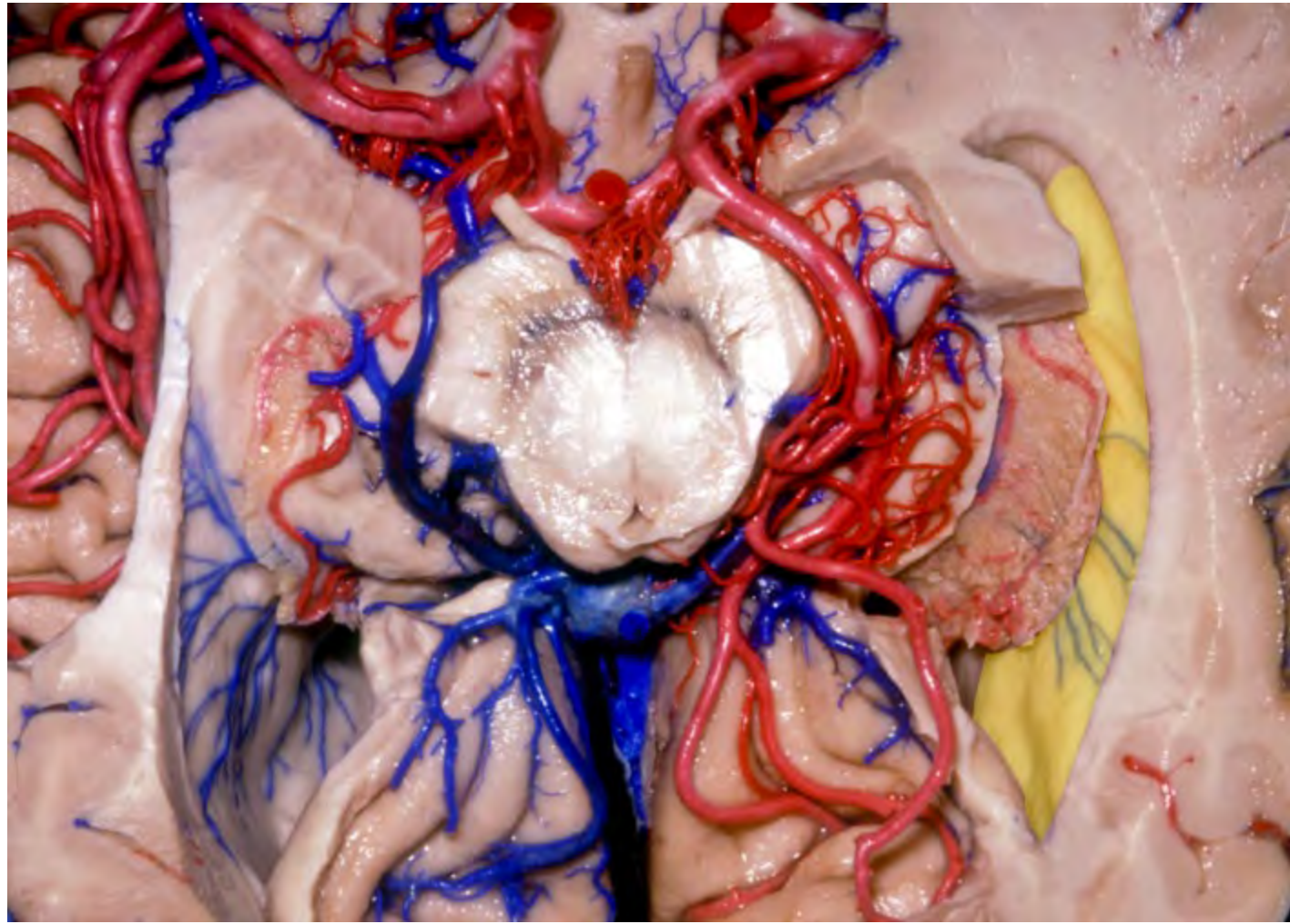








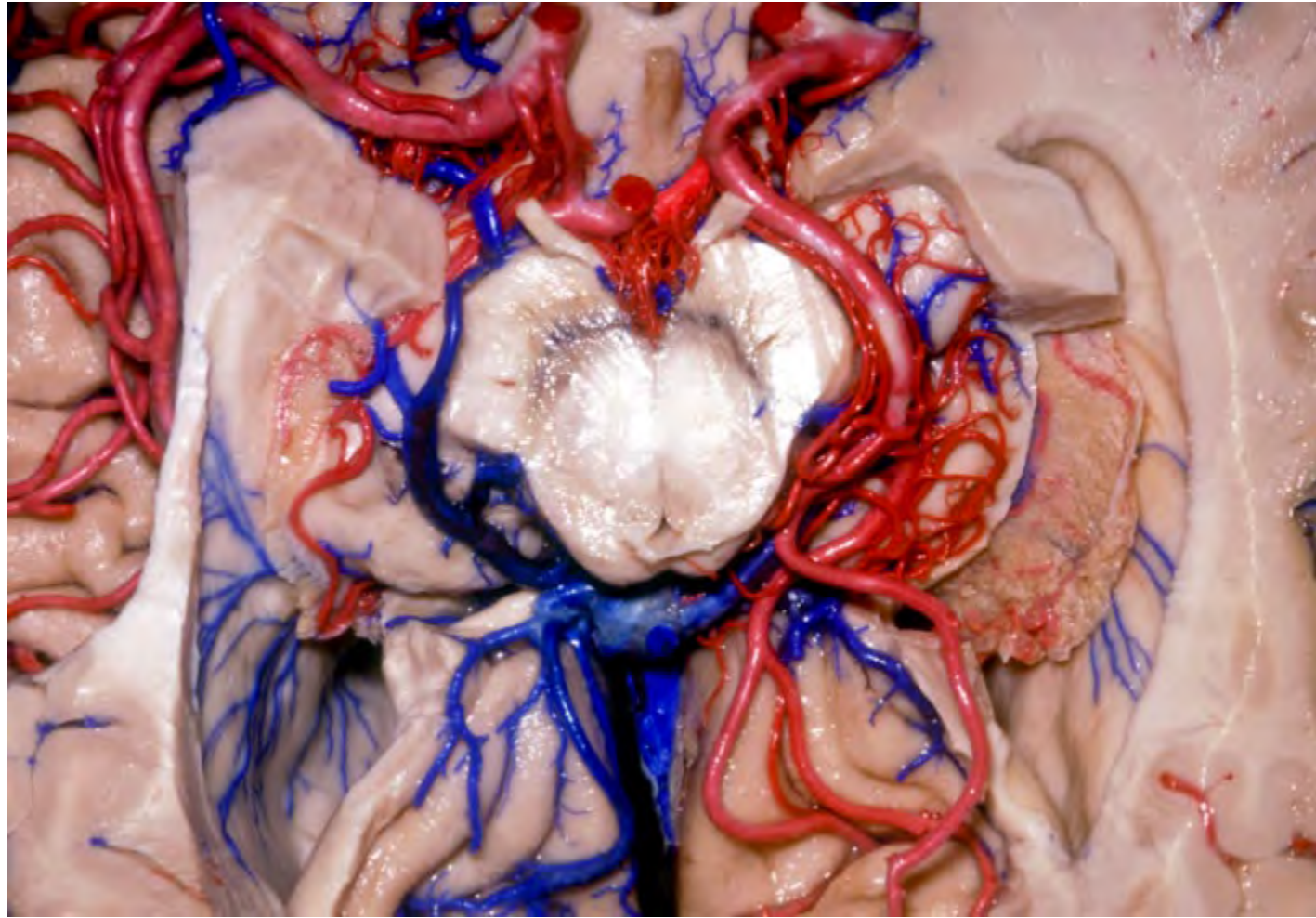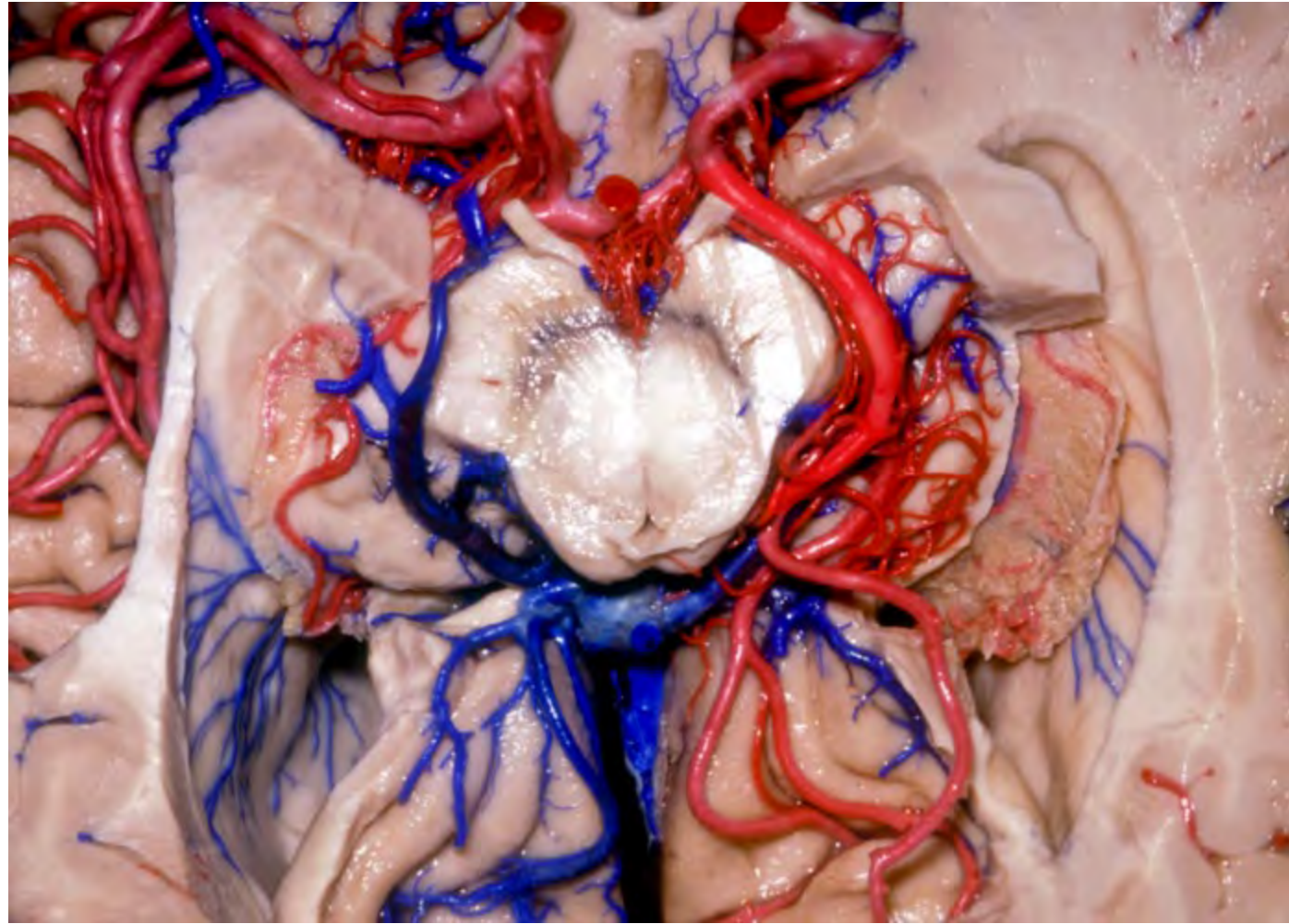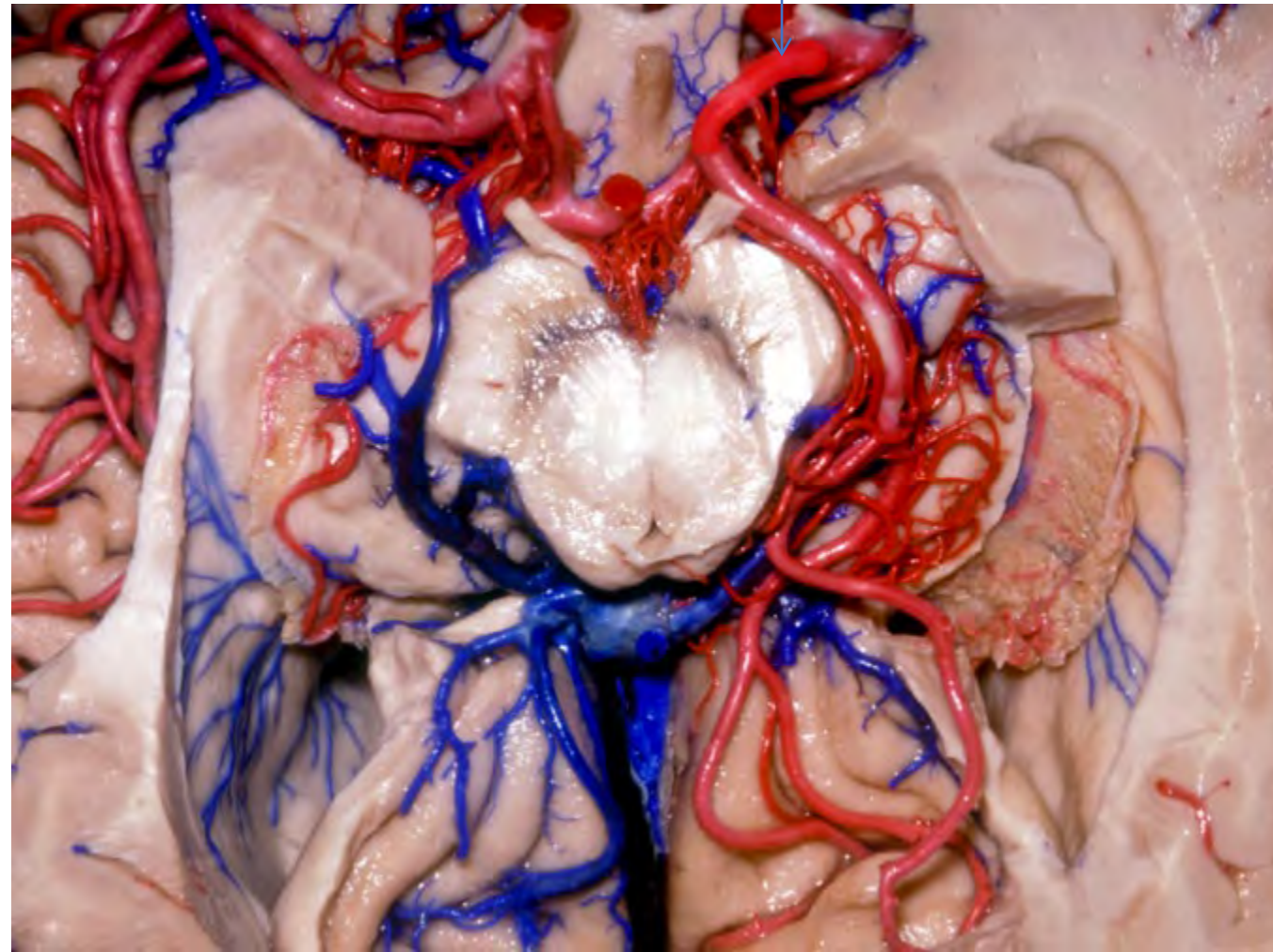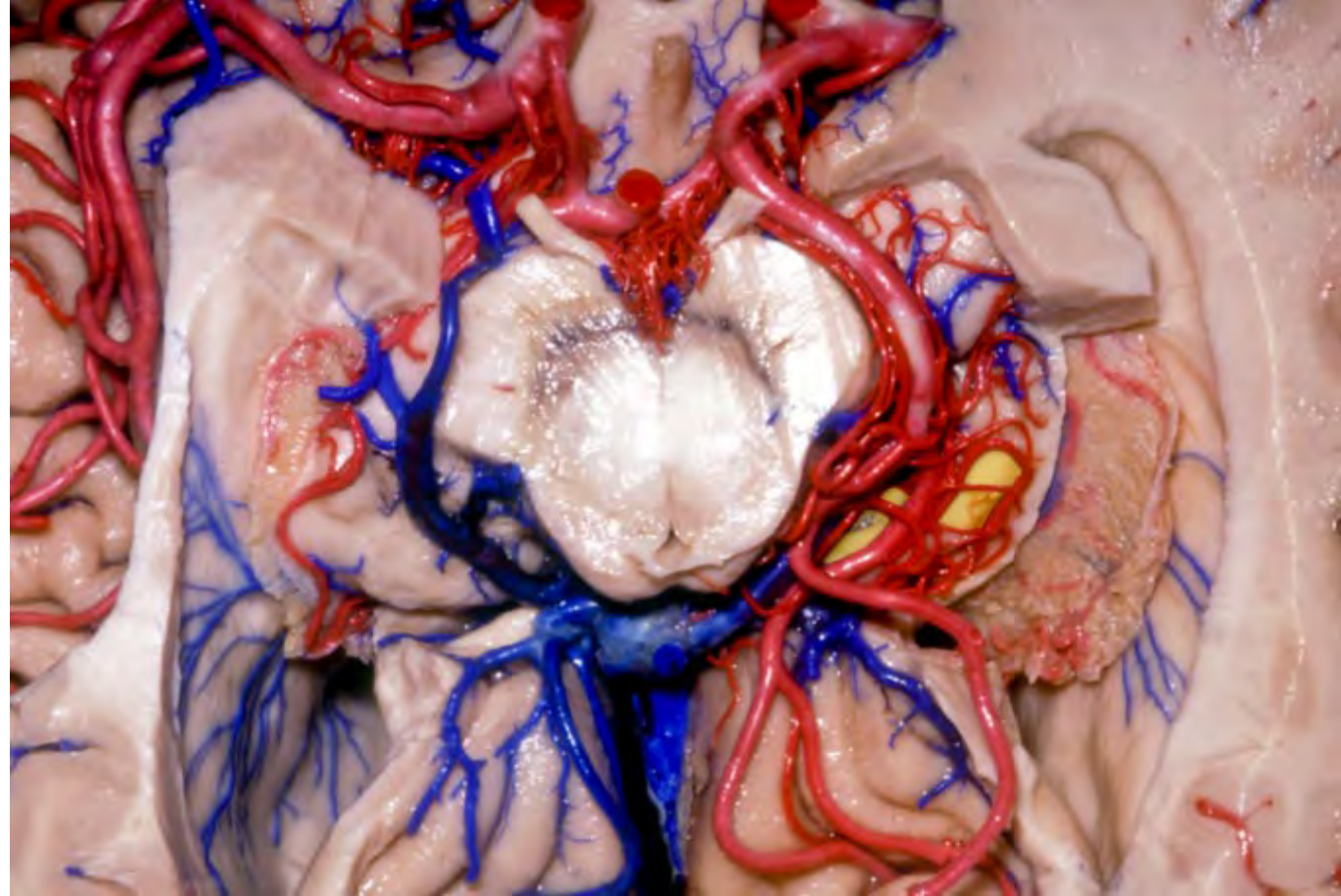


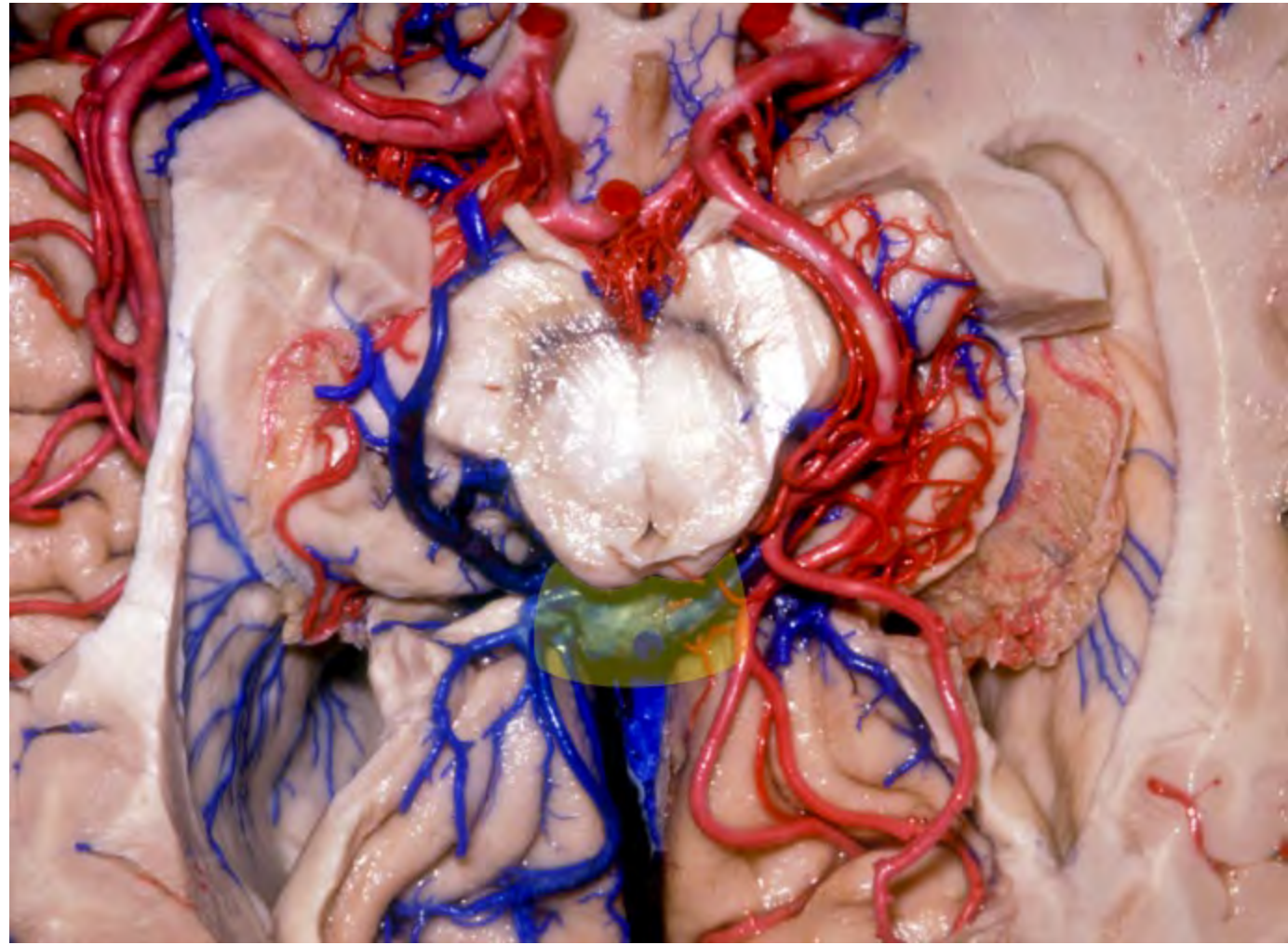


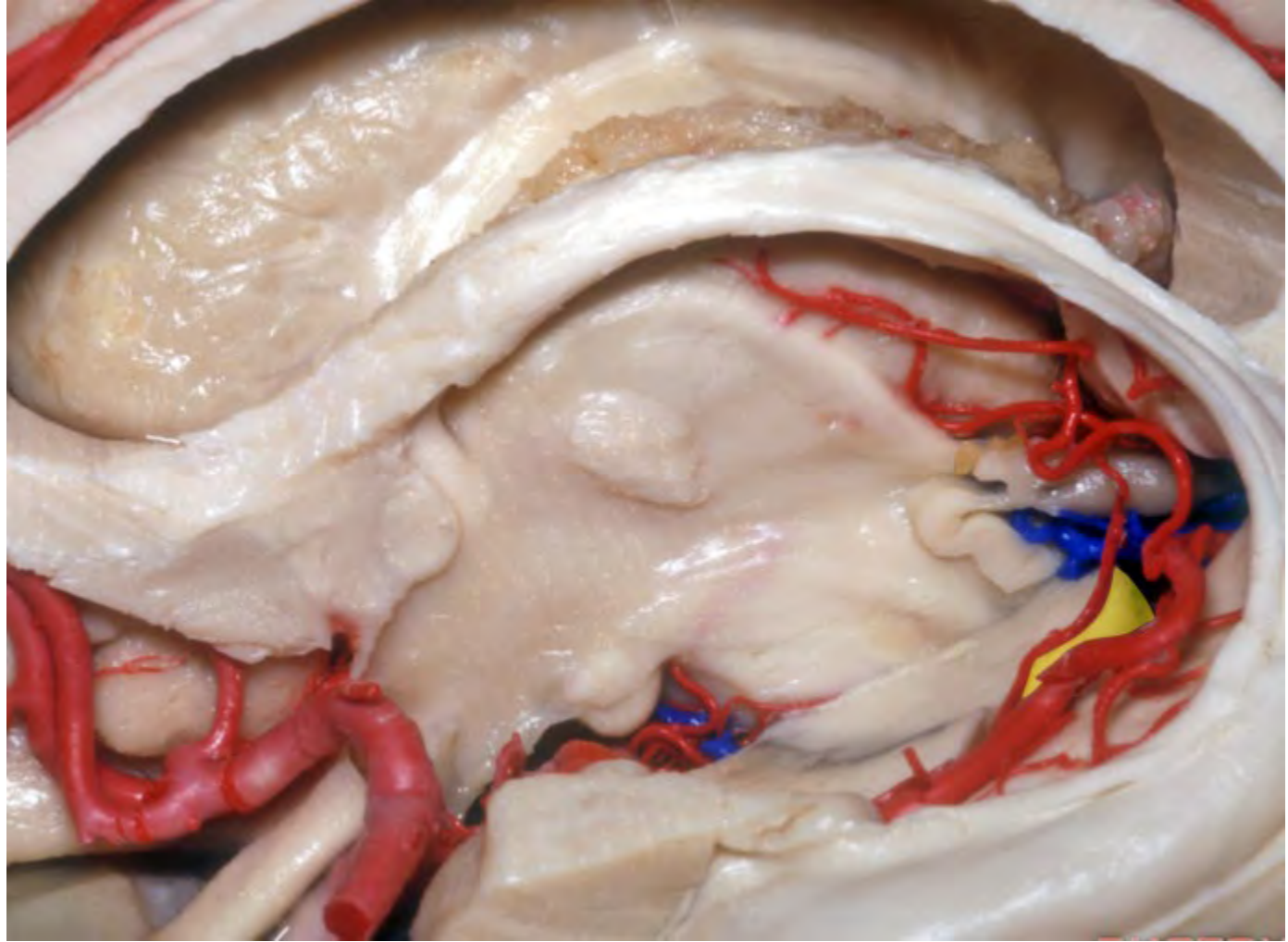


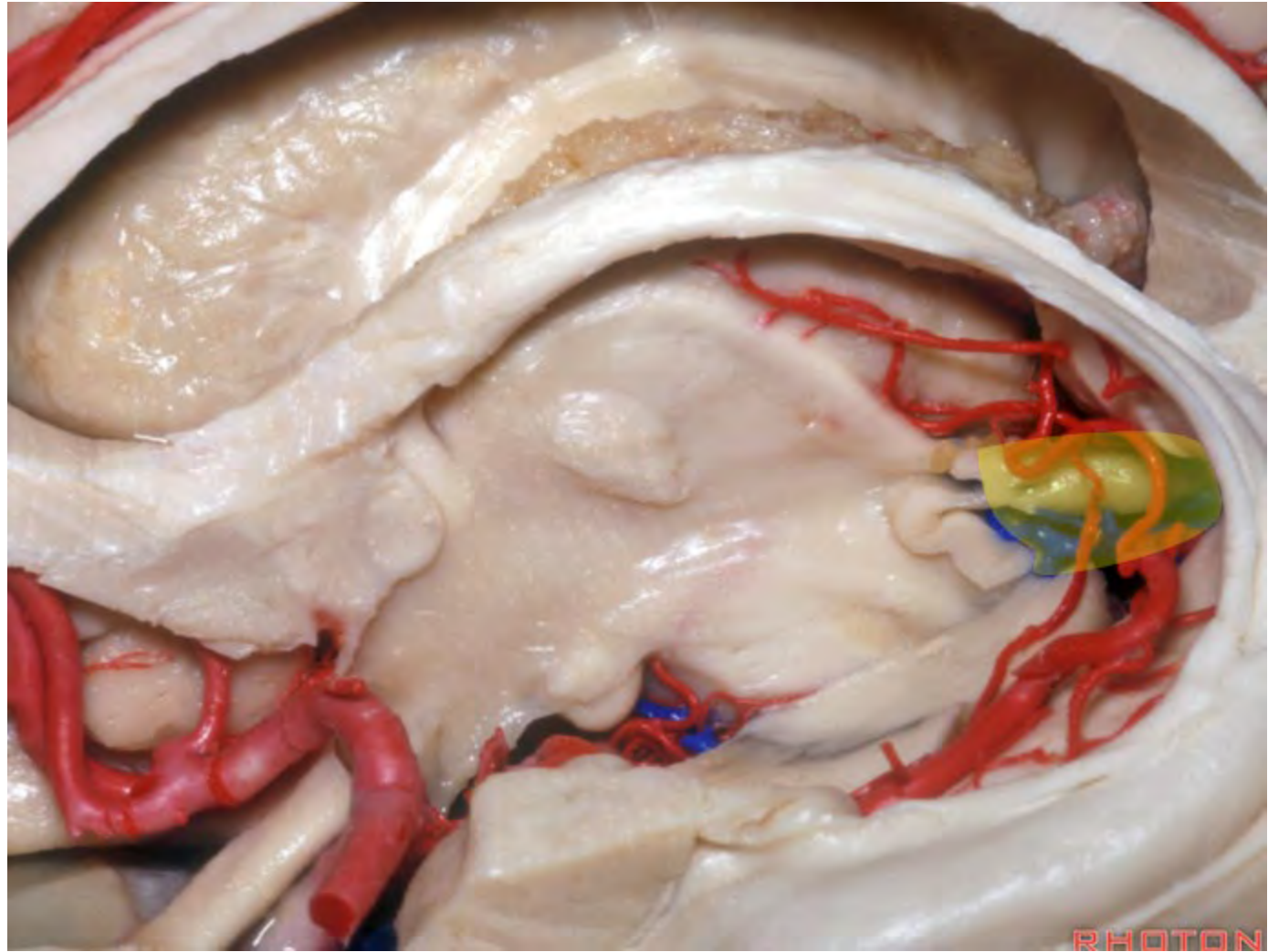




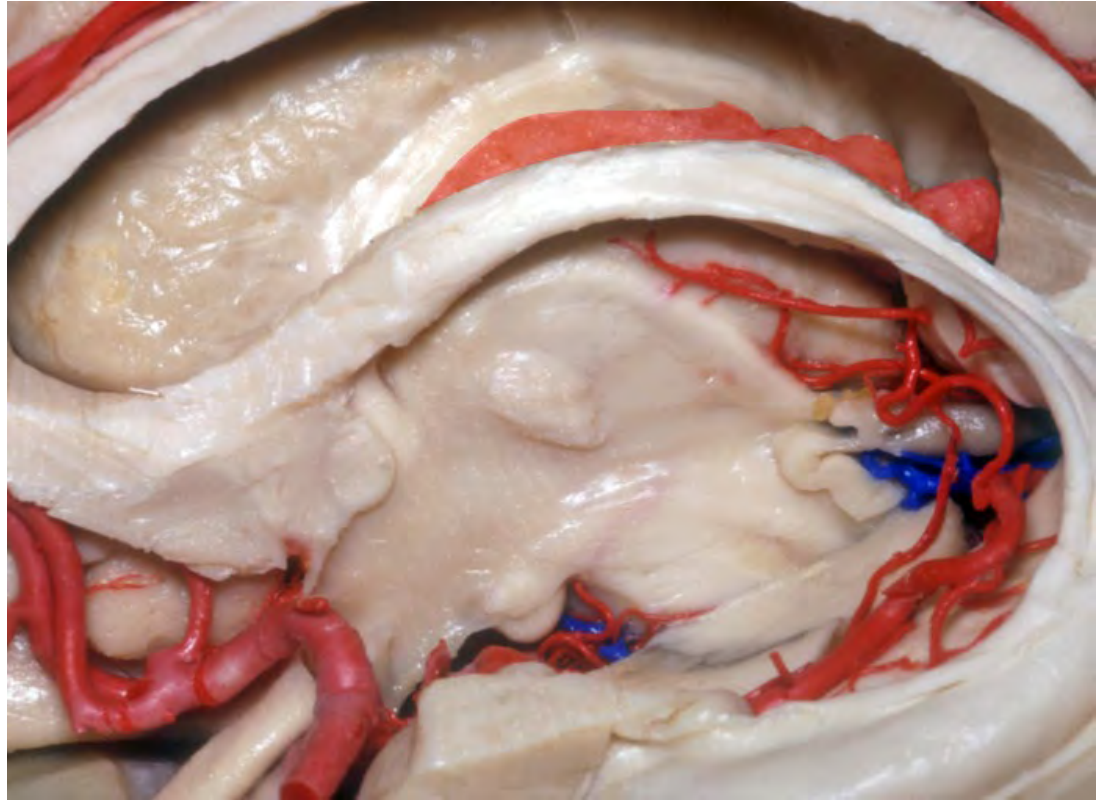
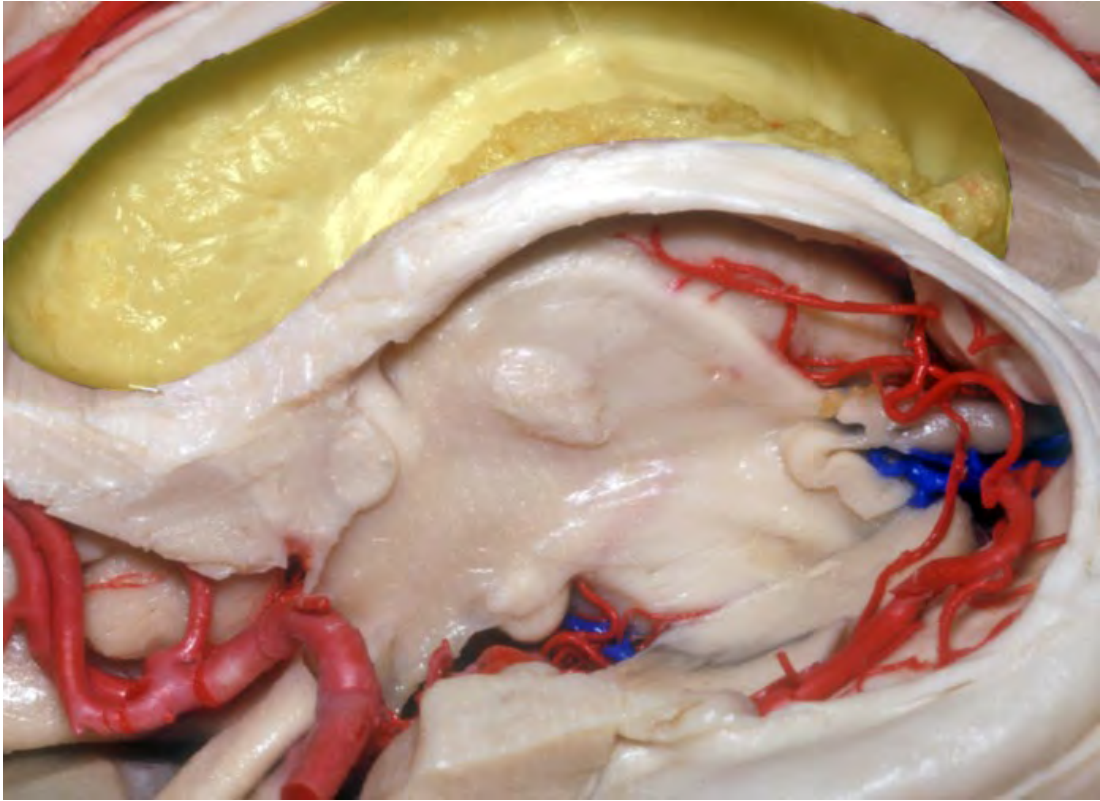


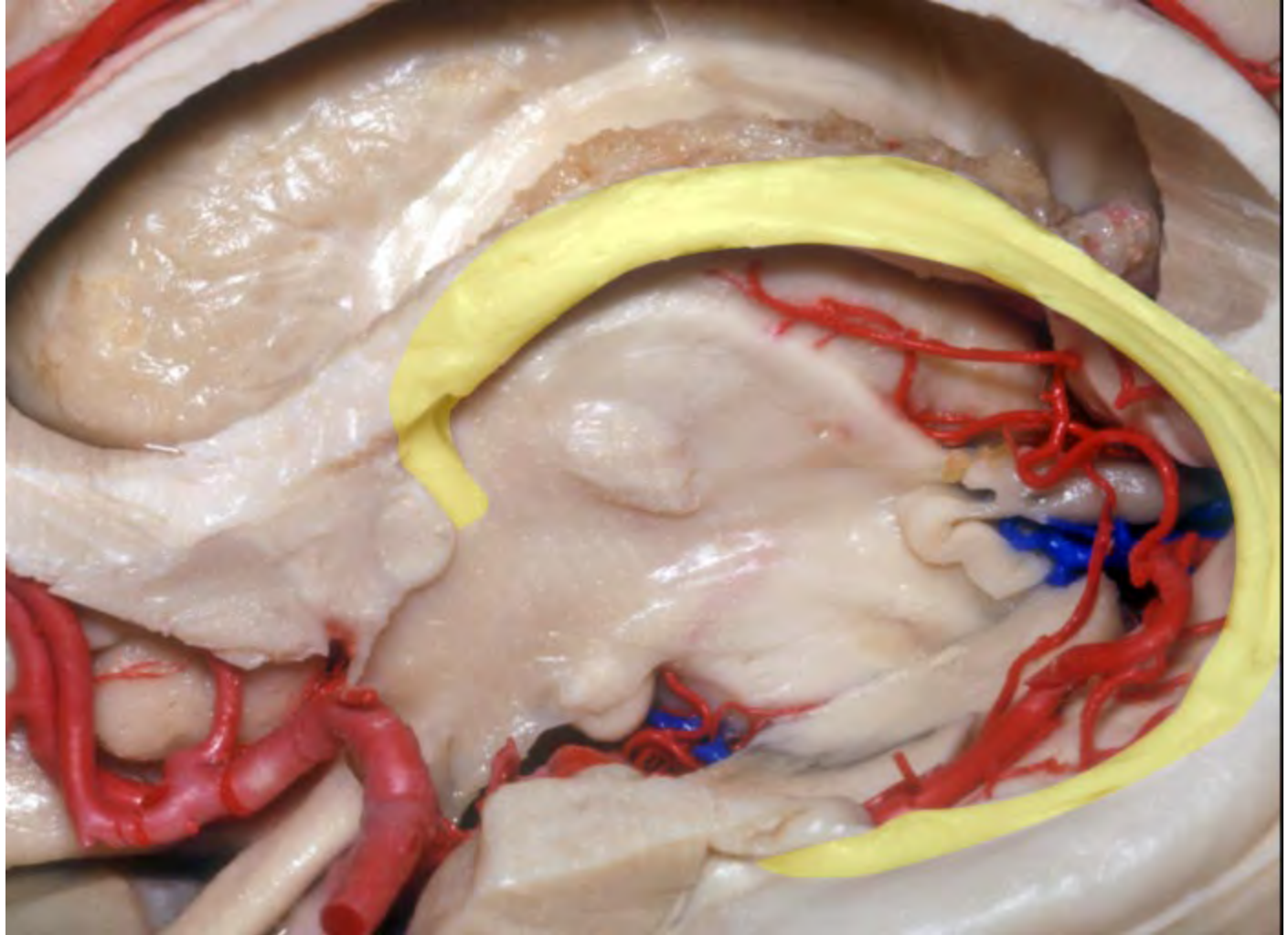


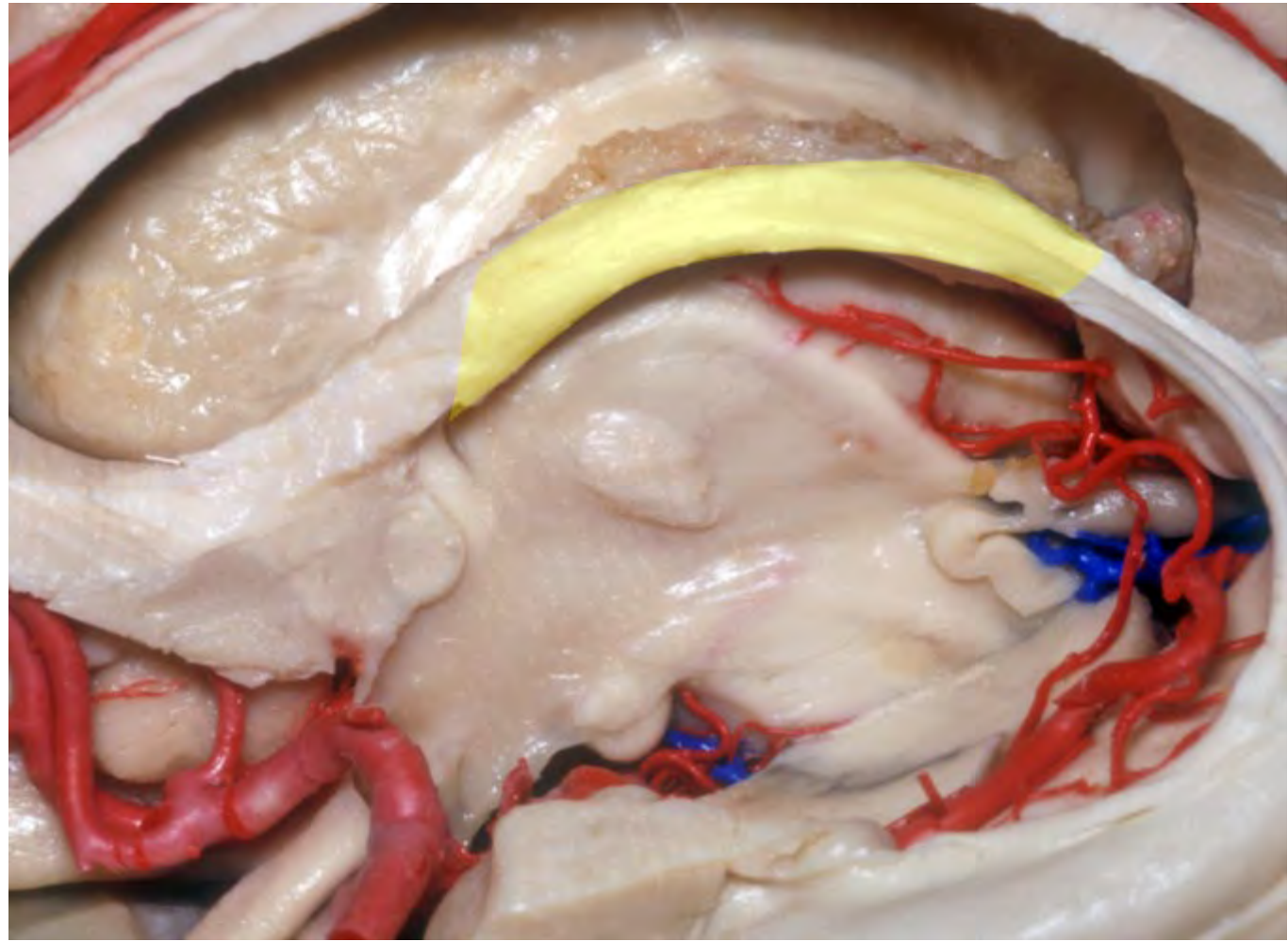


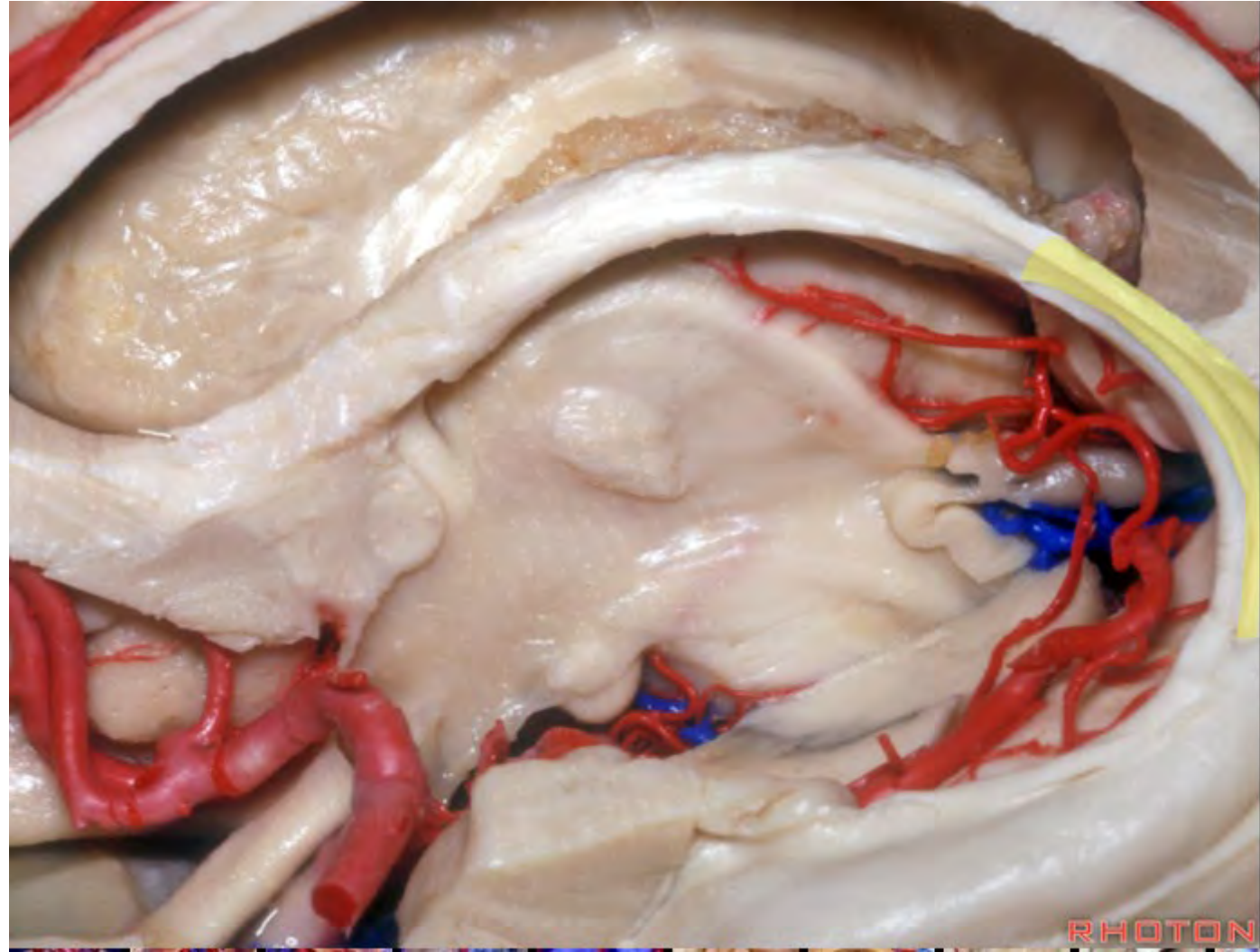


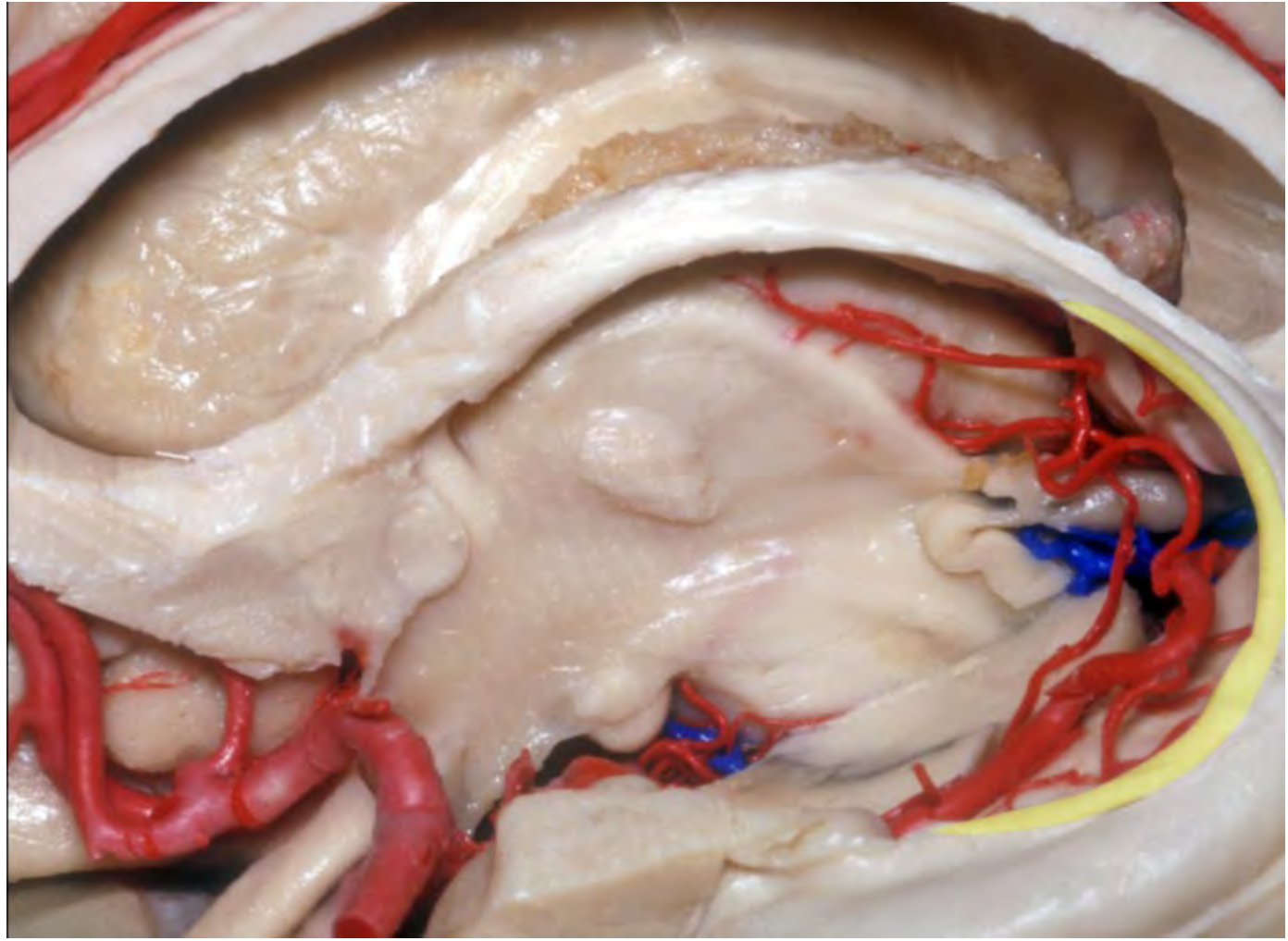


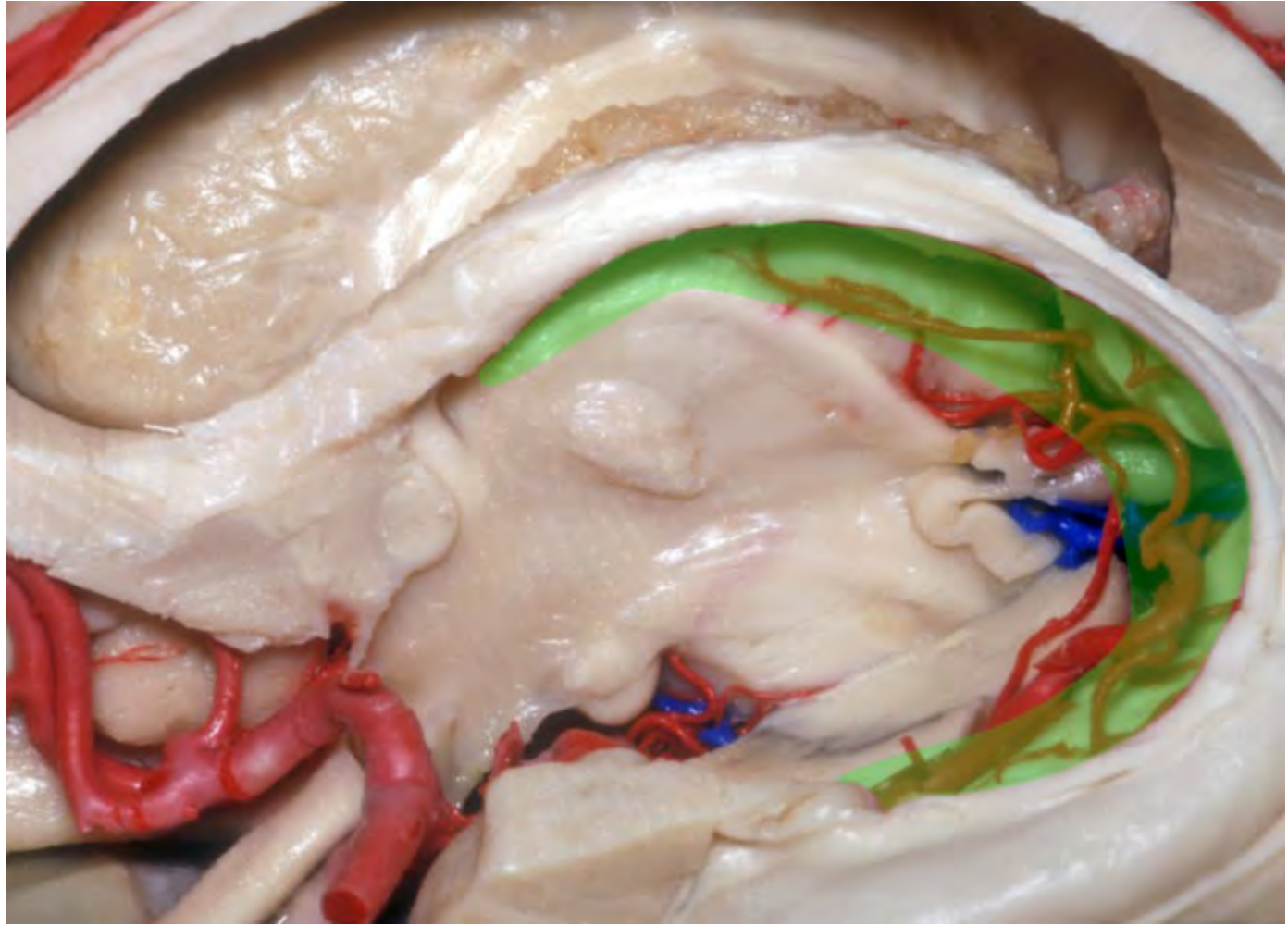


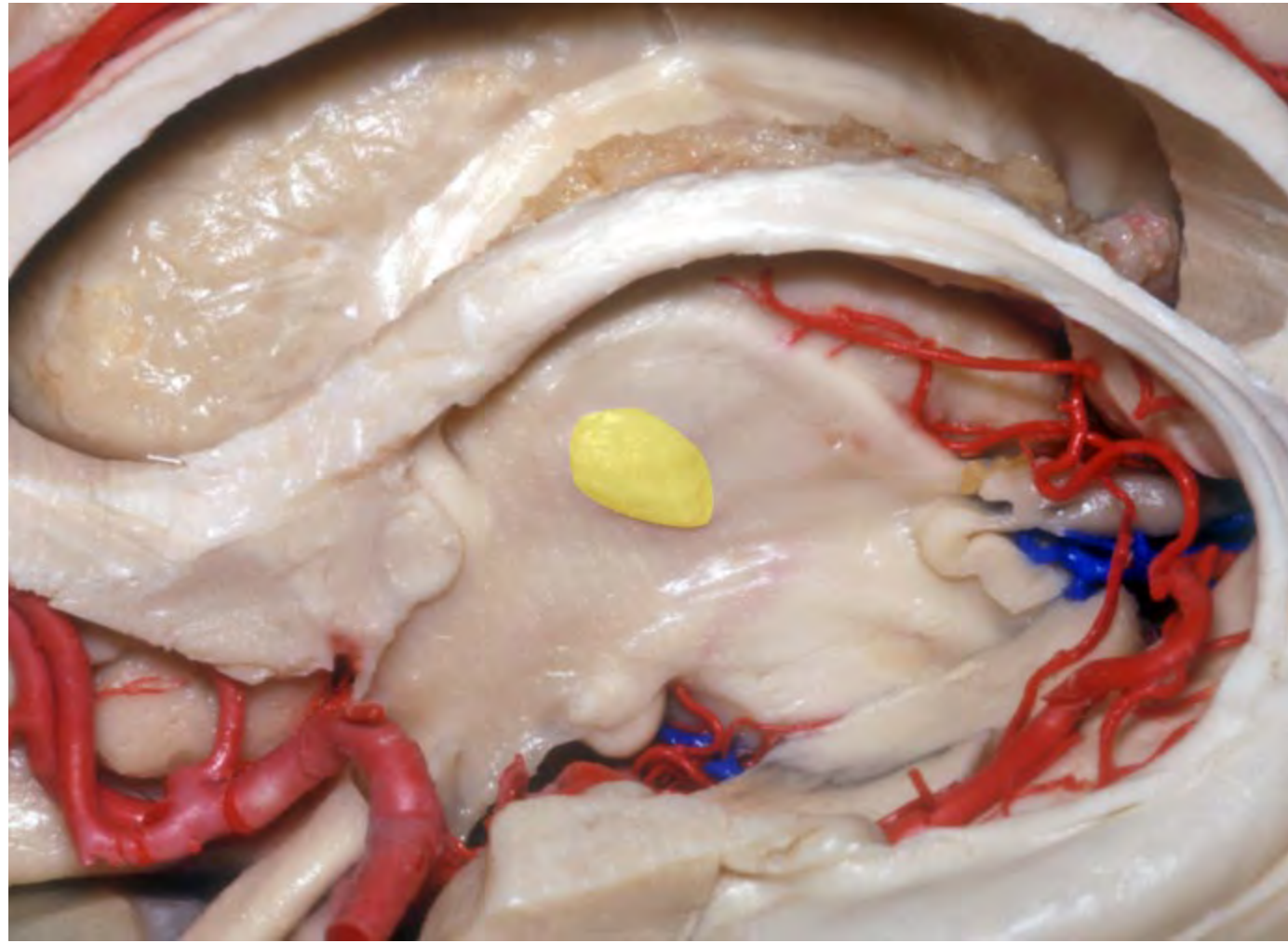


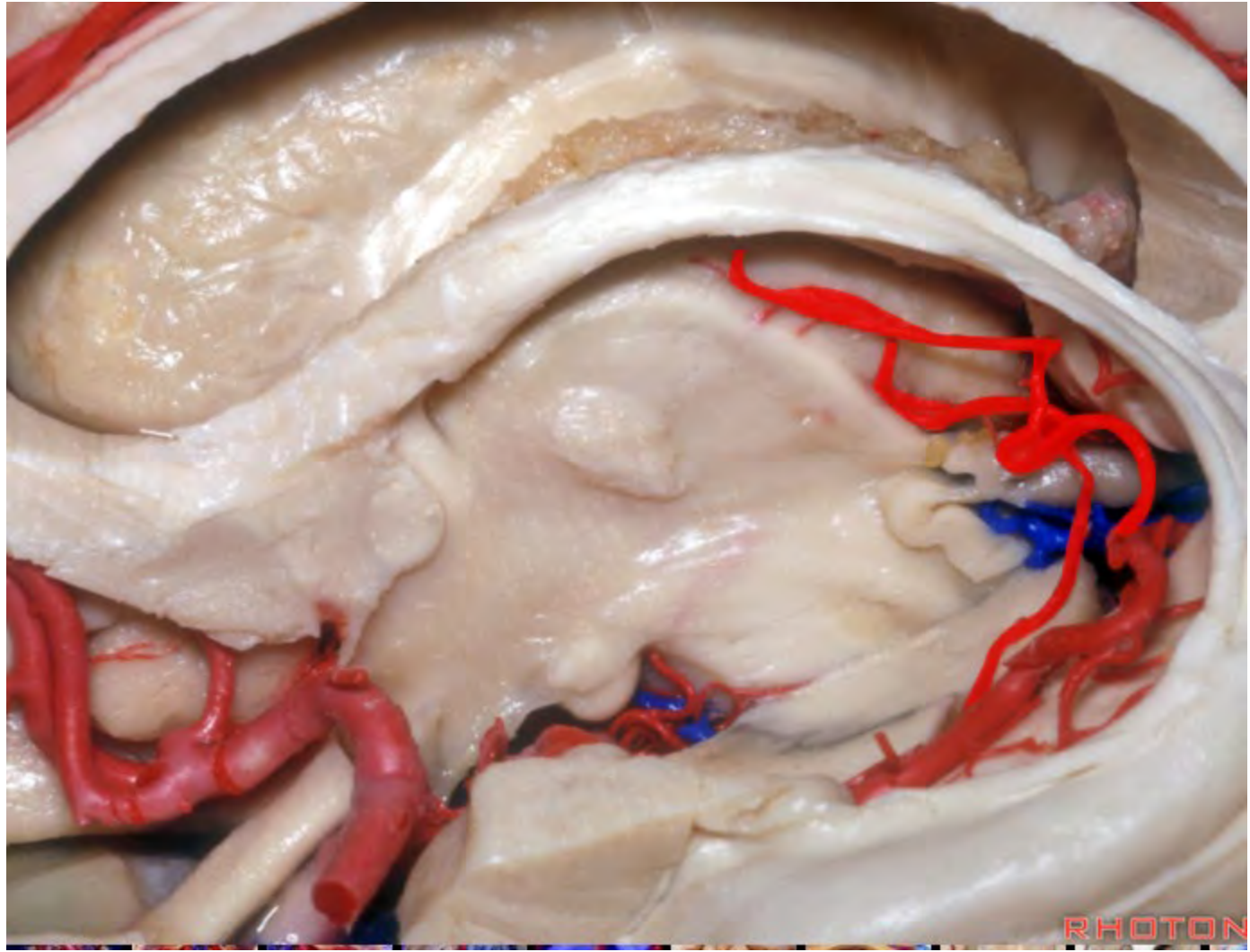






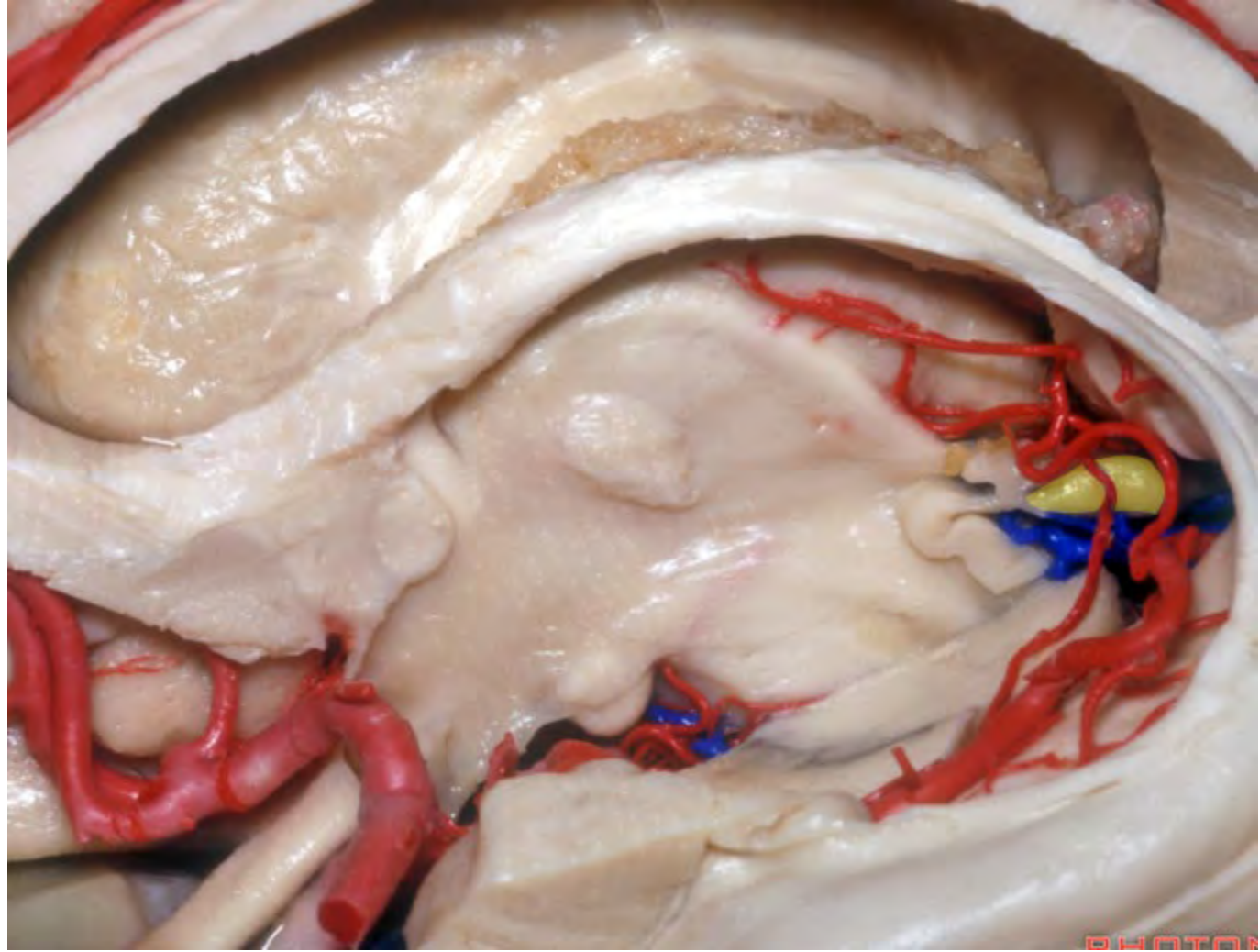


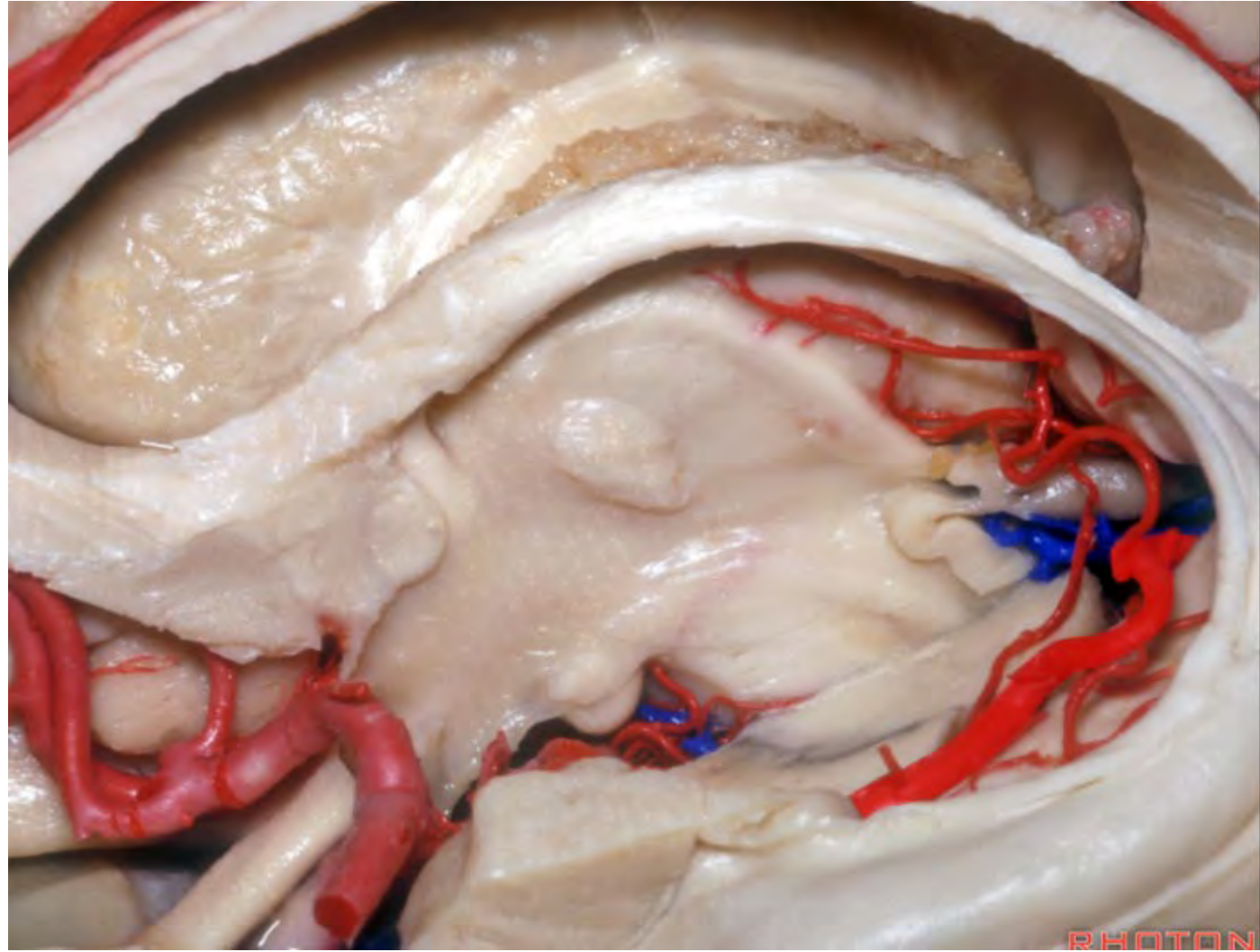


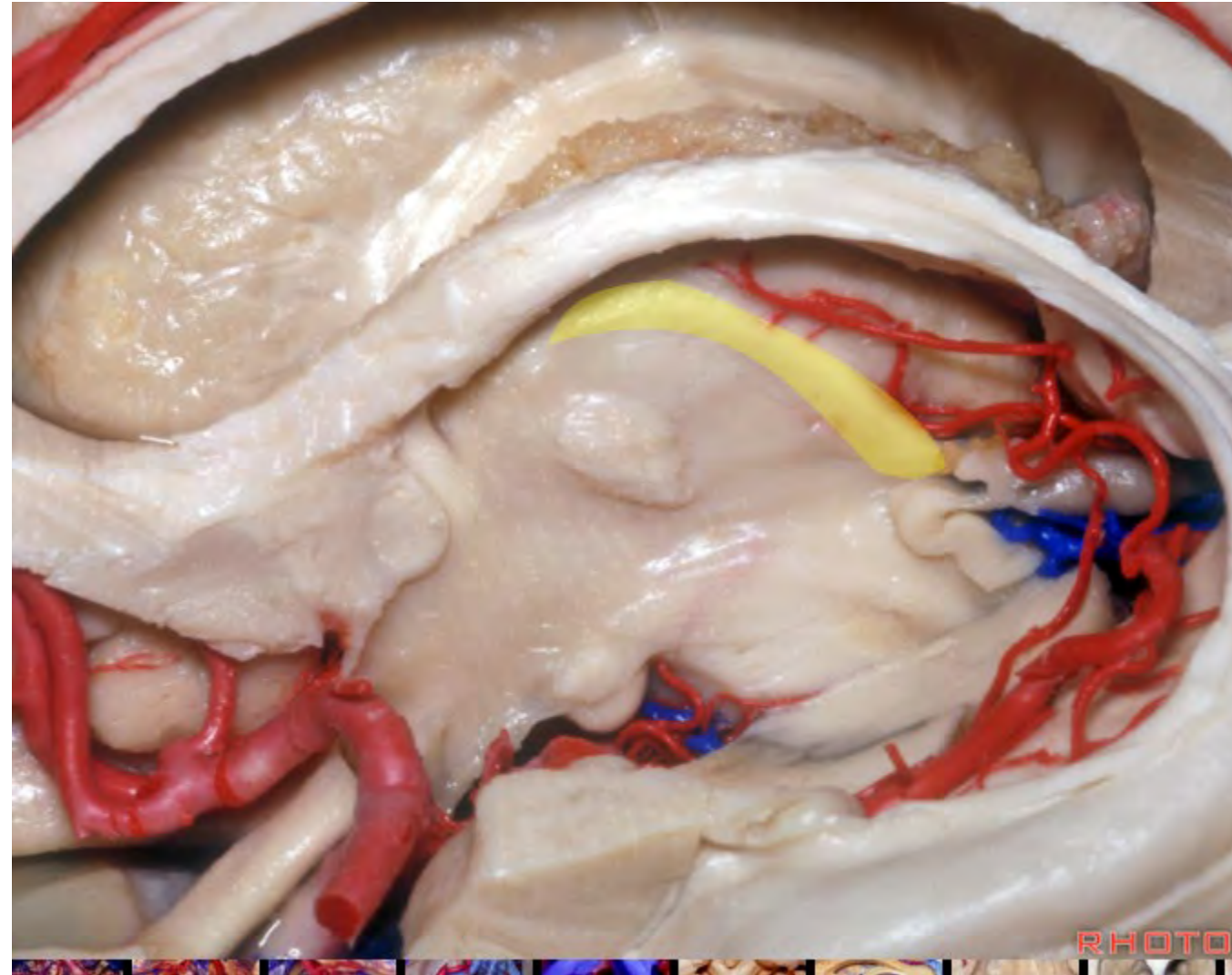


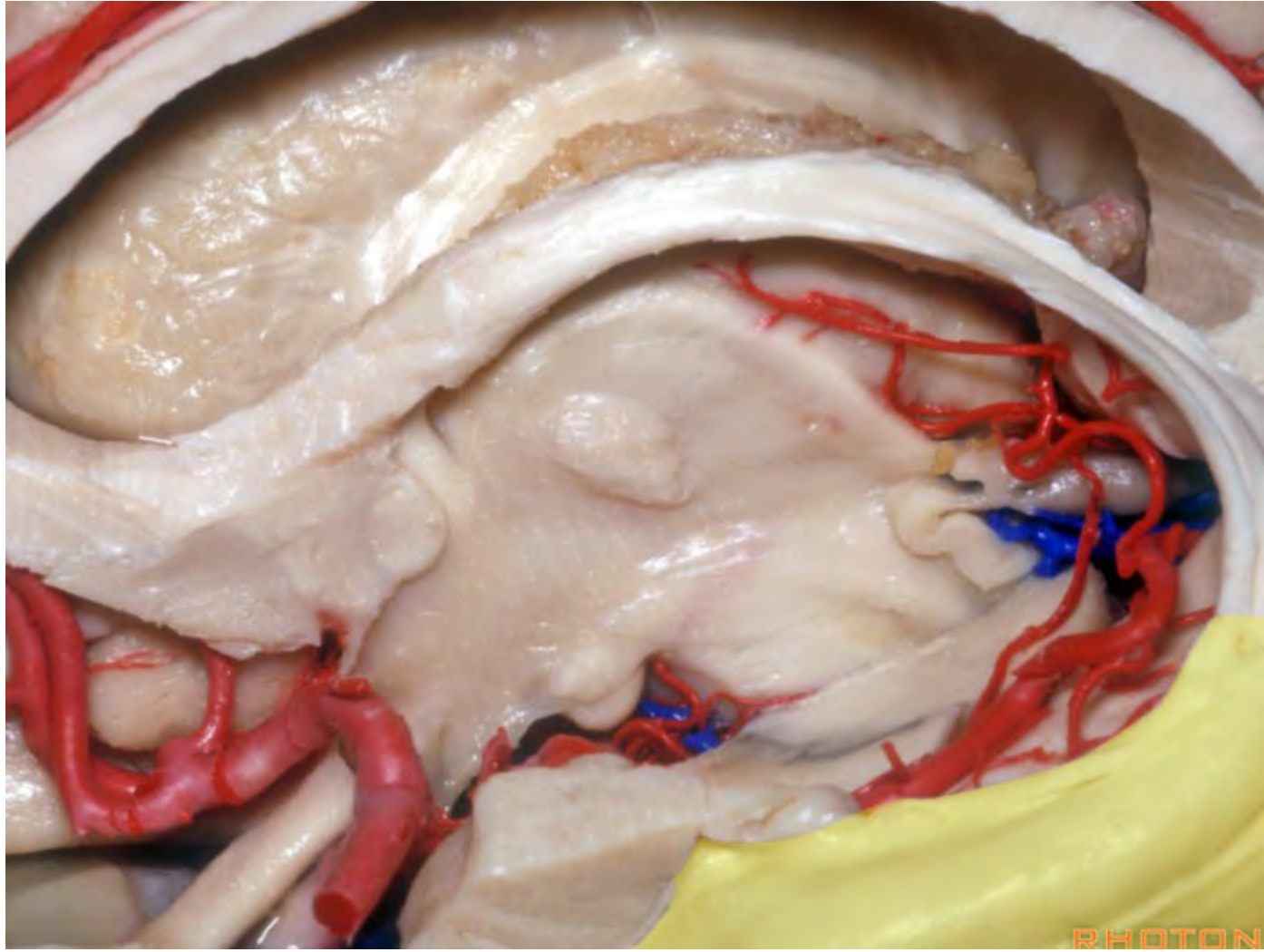
RHOTO

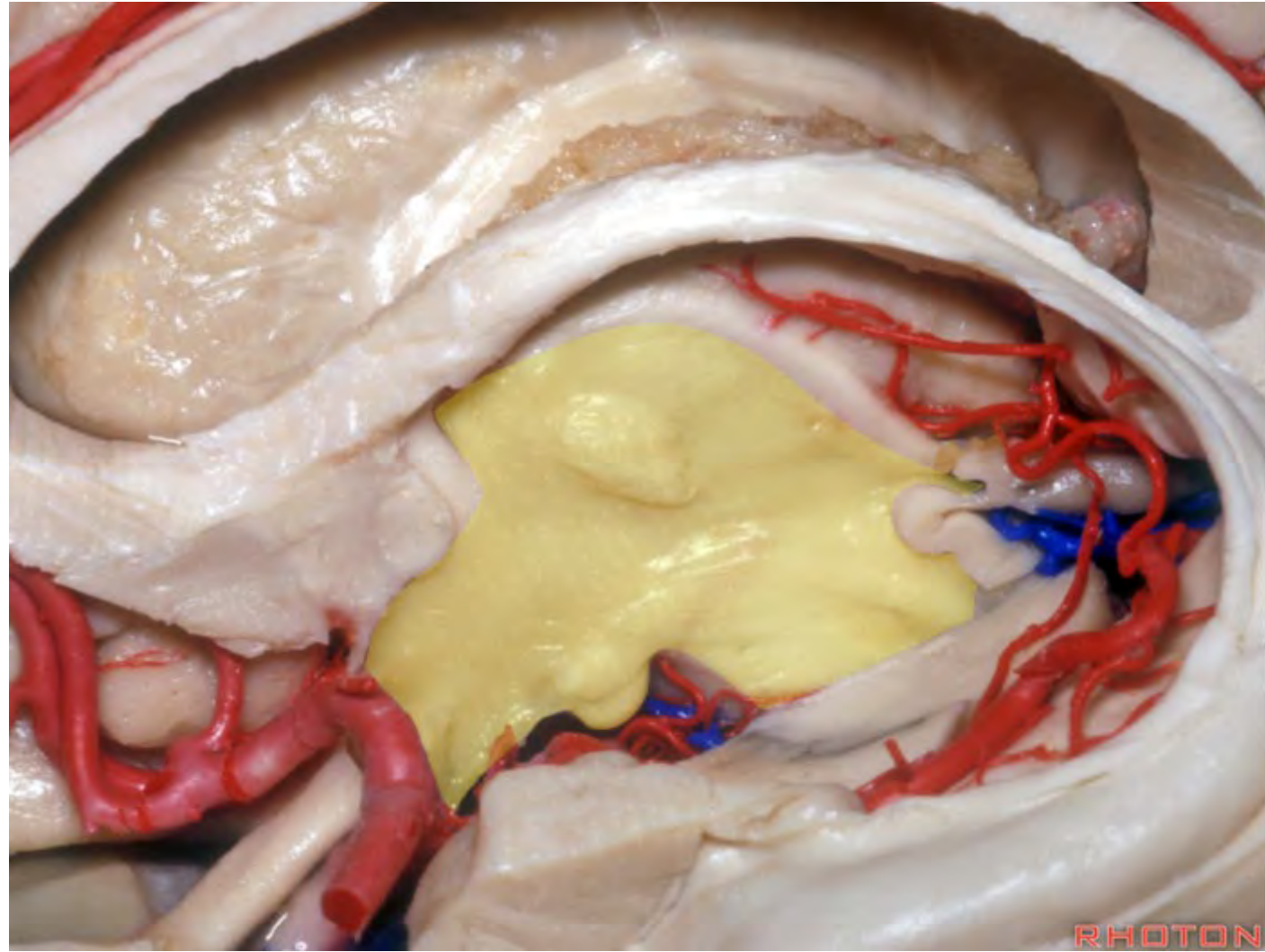


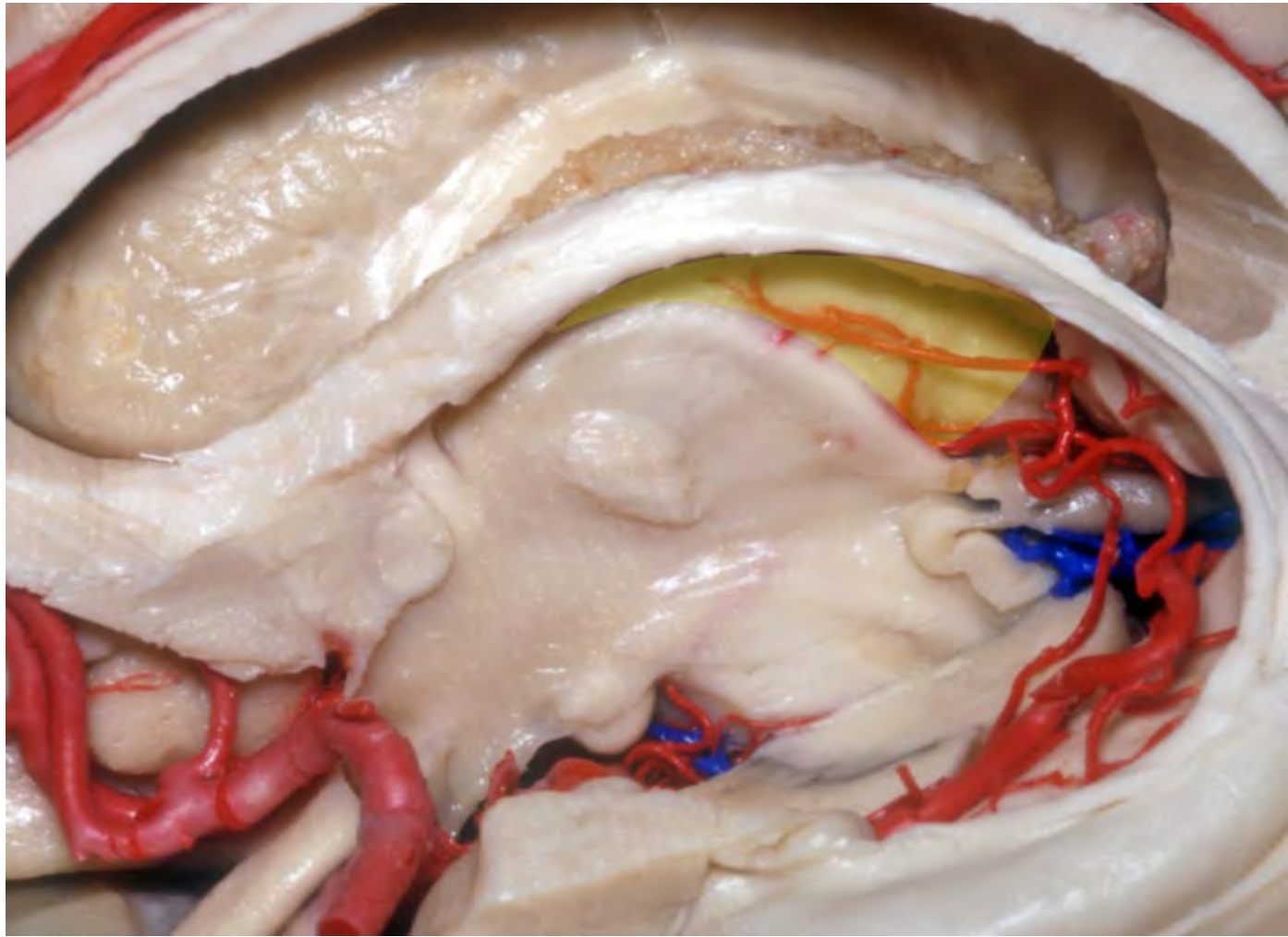


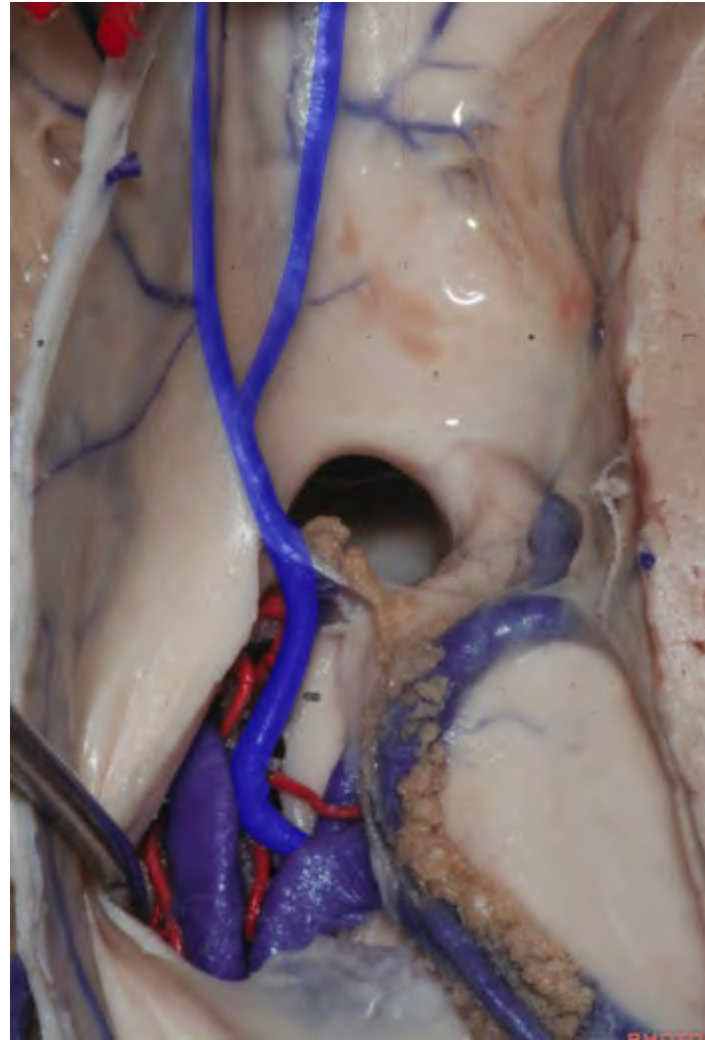


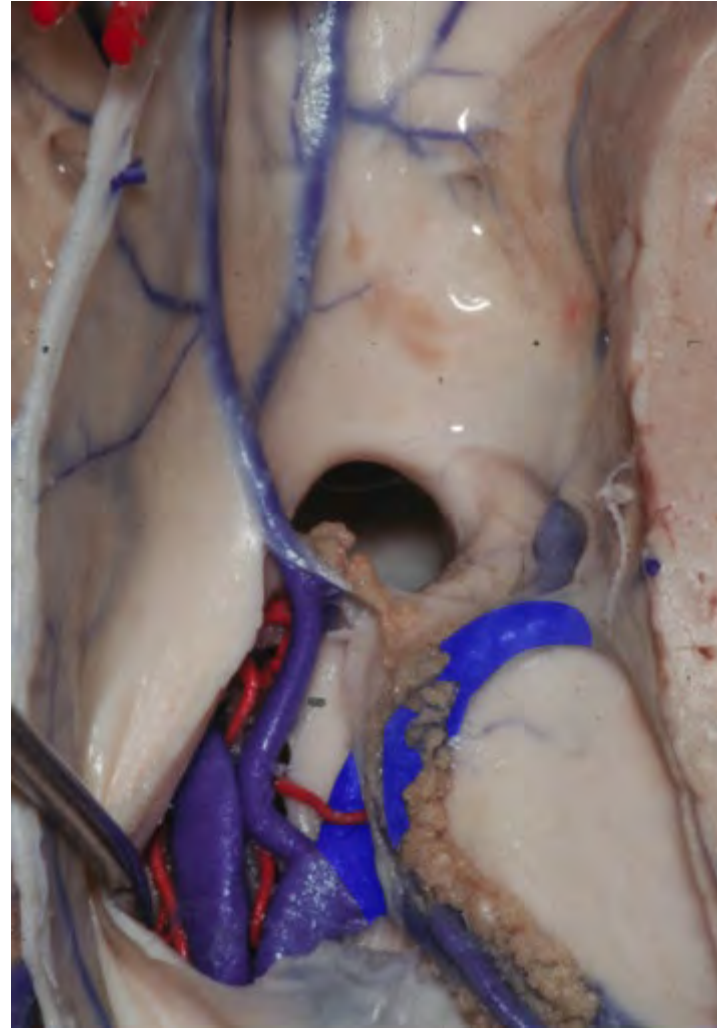




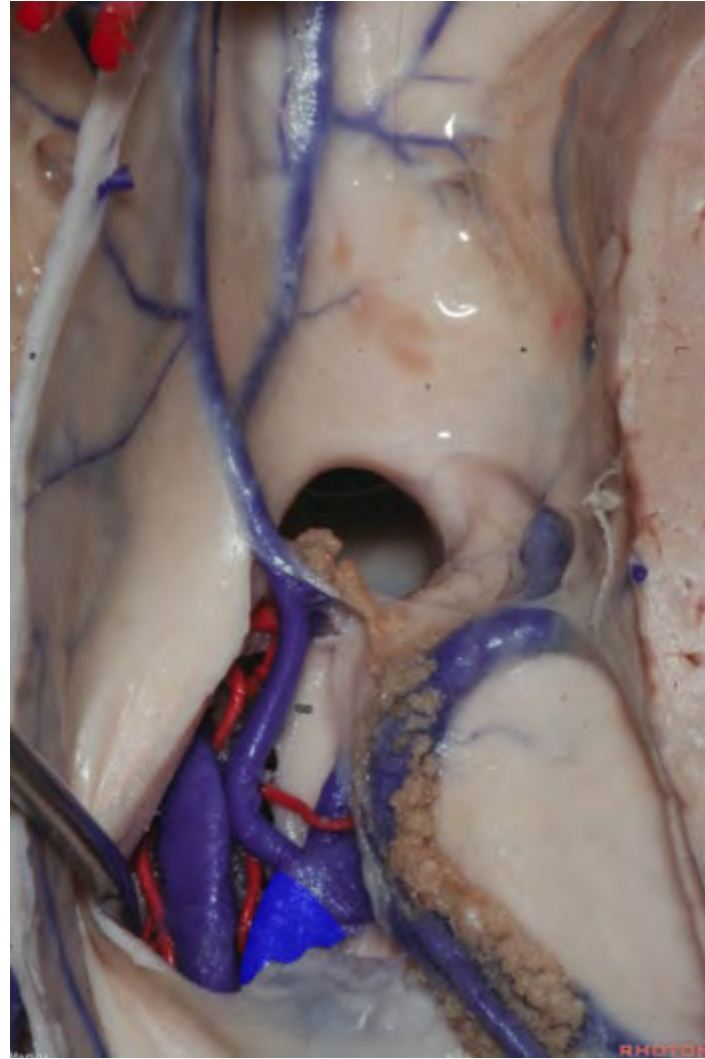


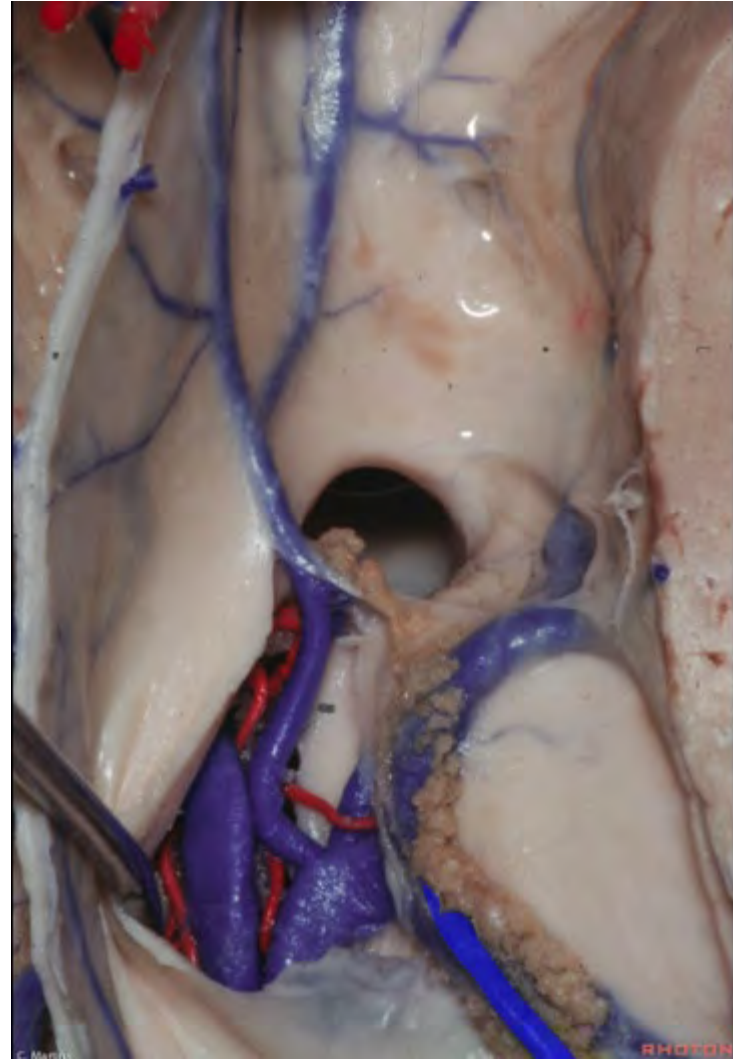


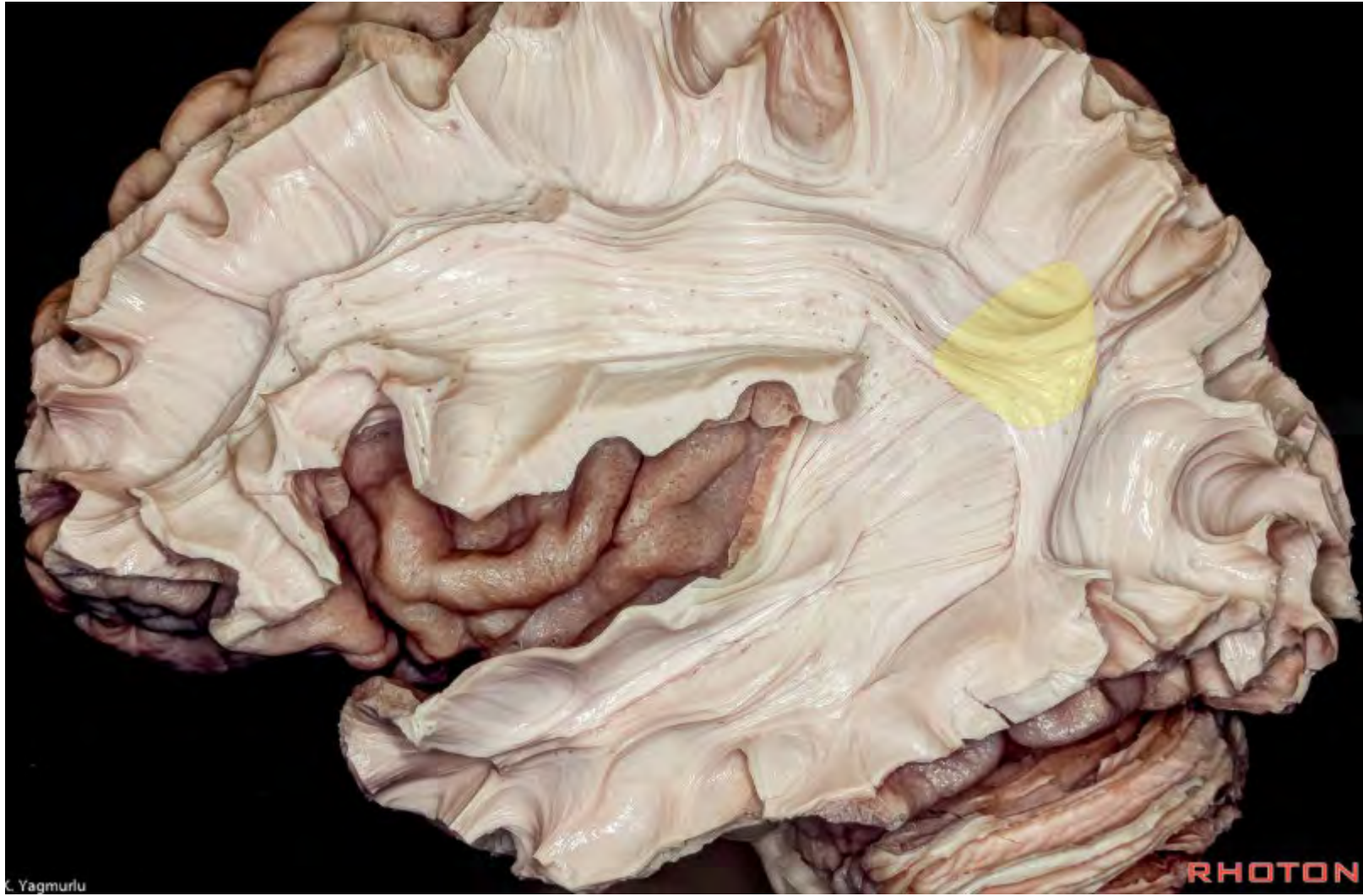


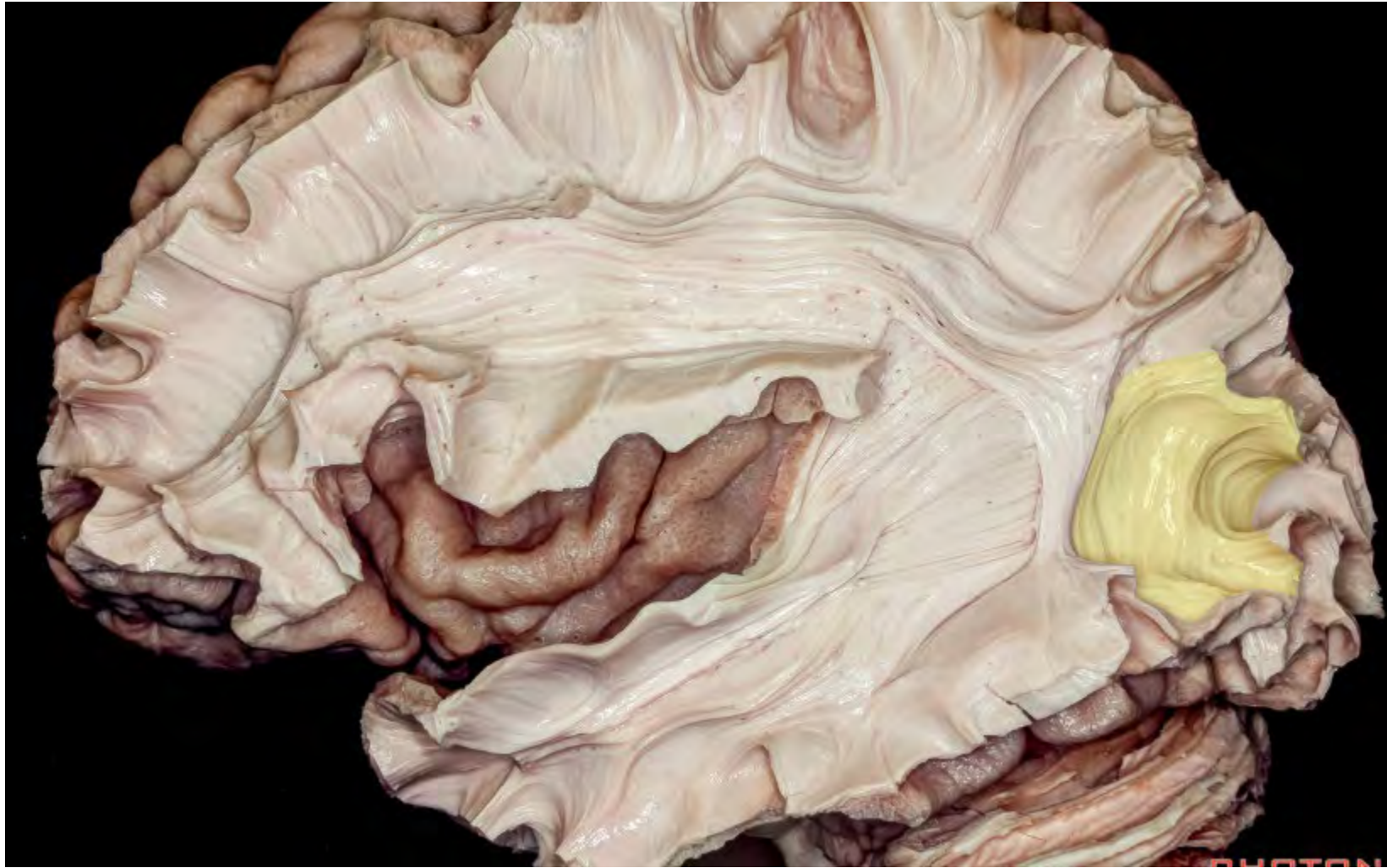


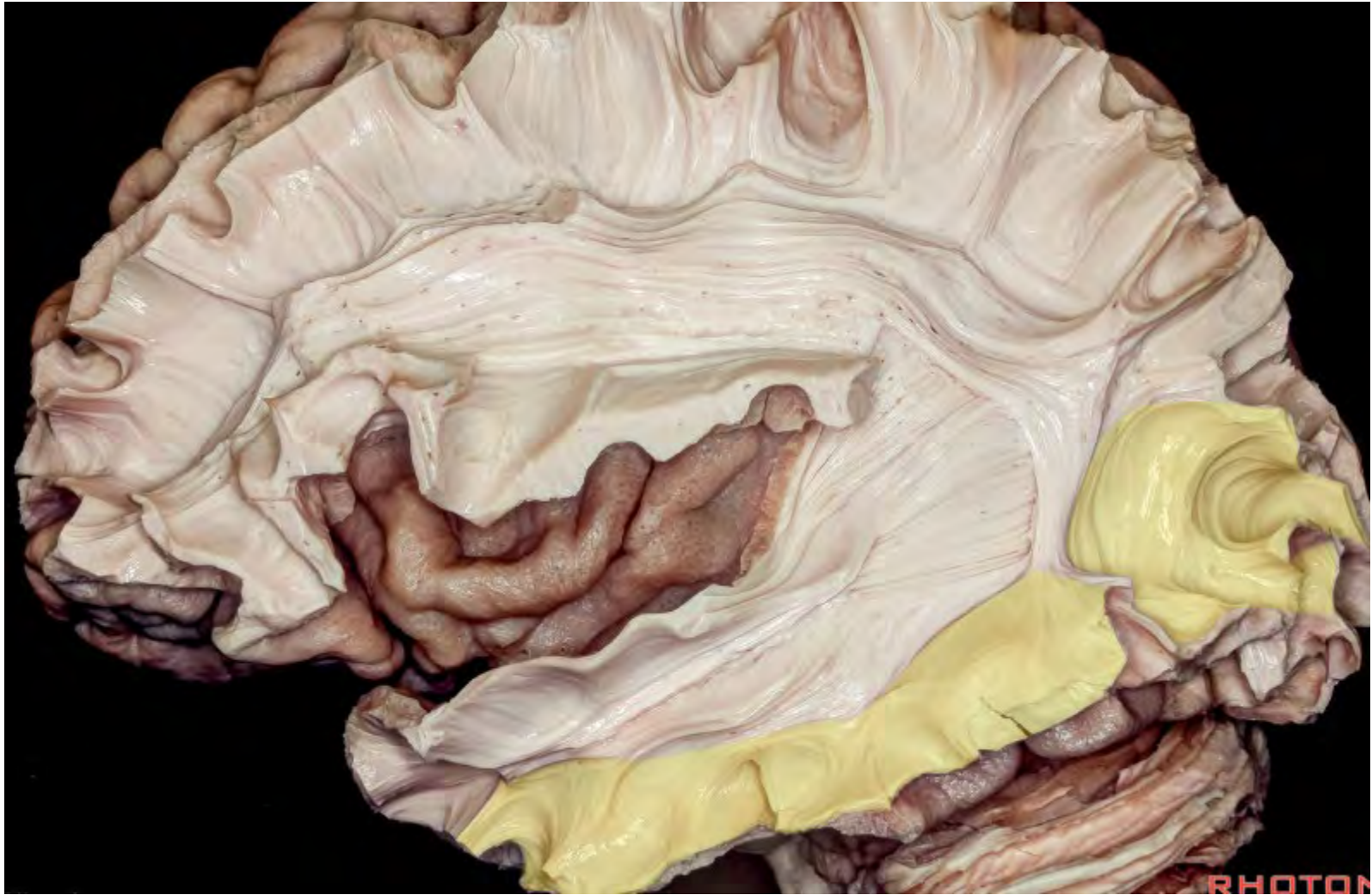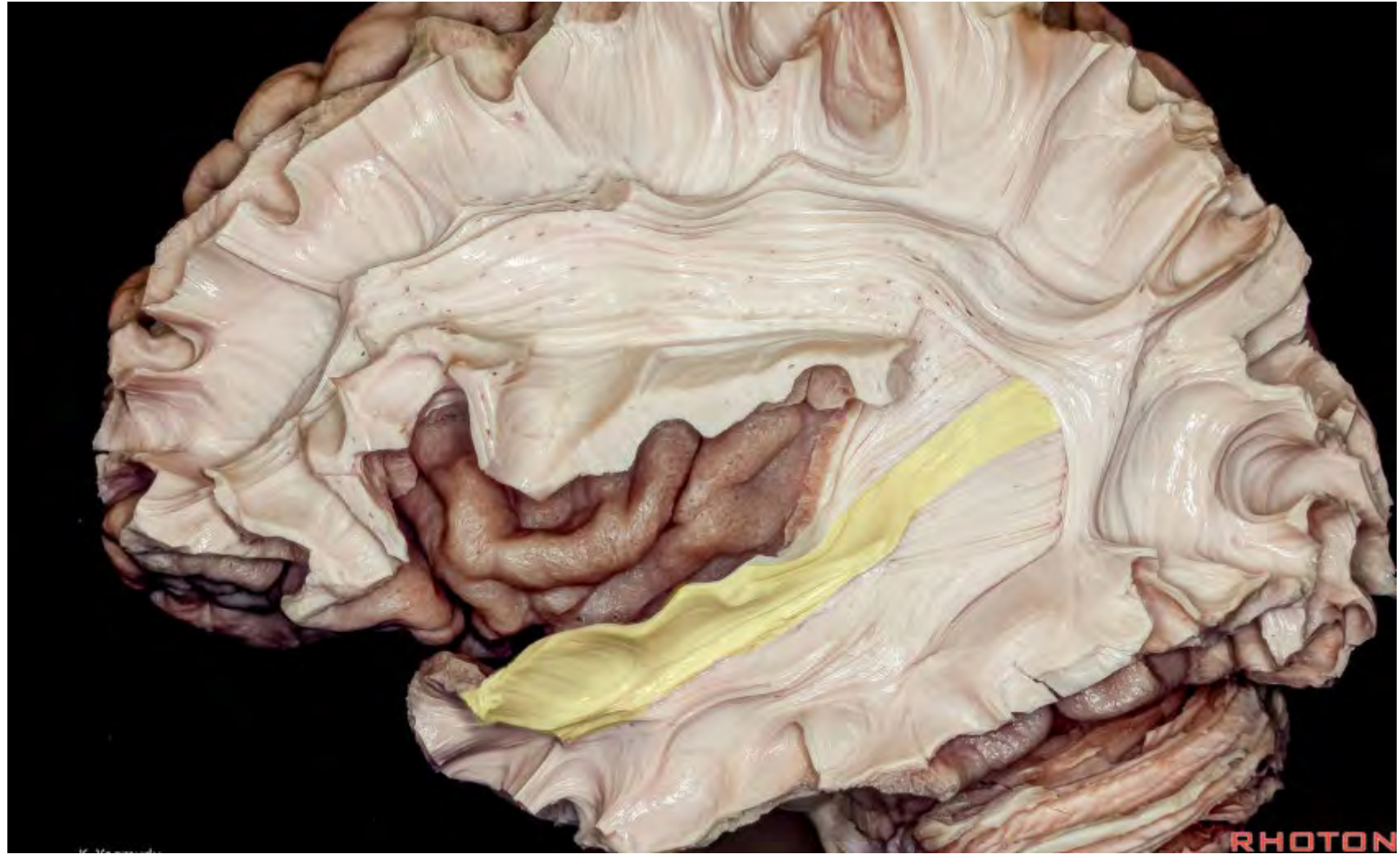


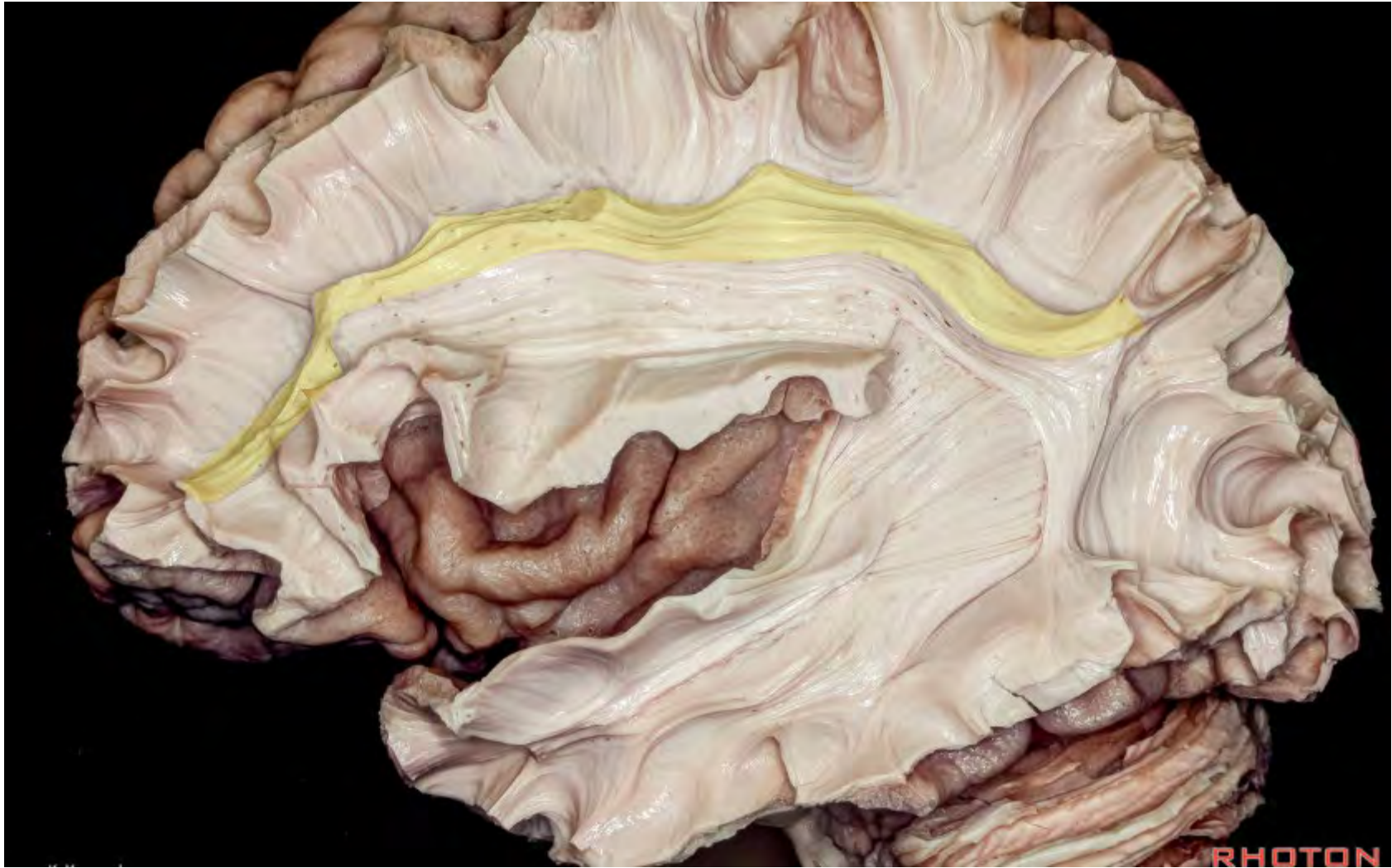


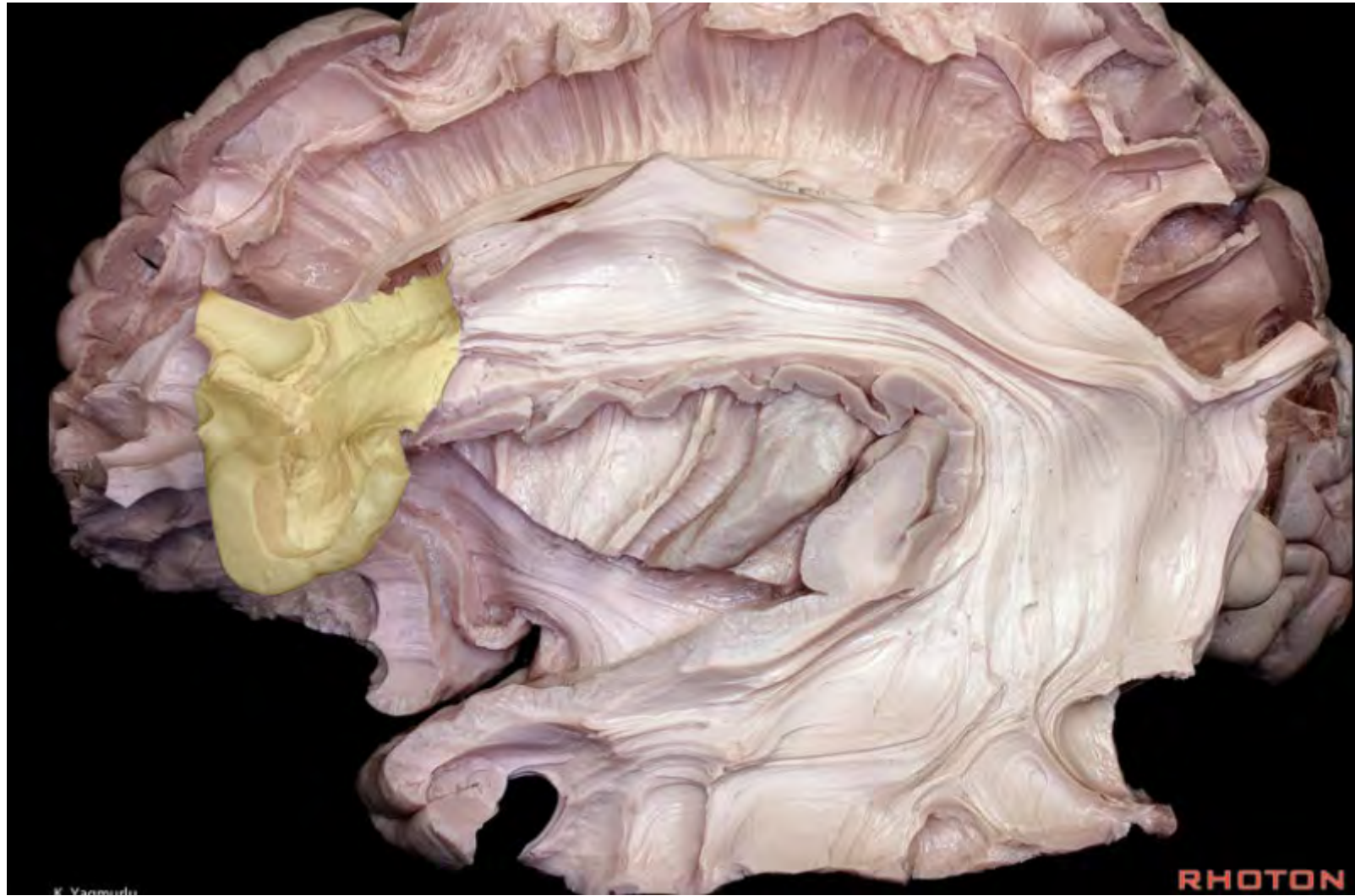







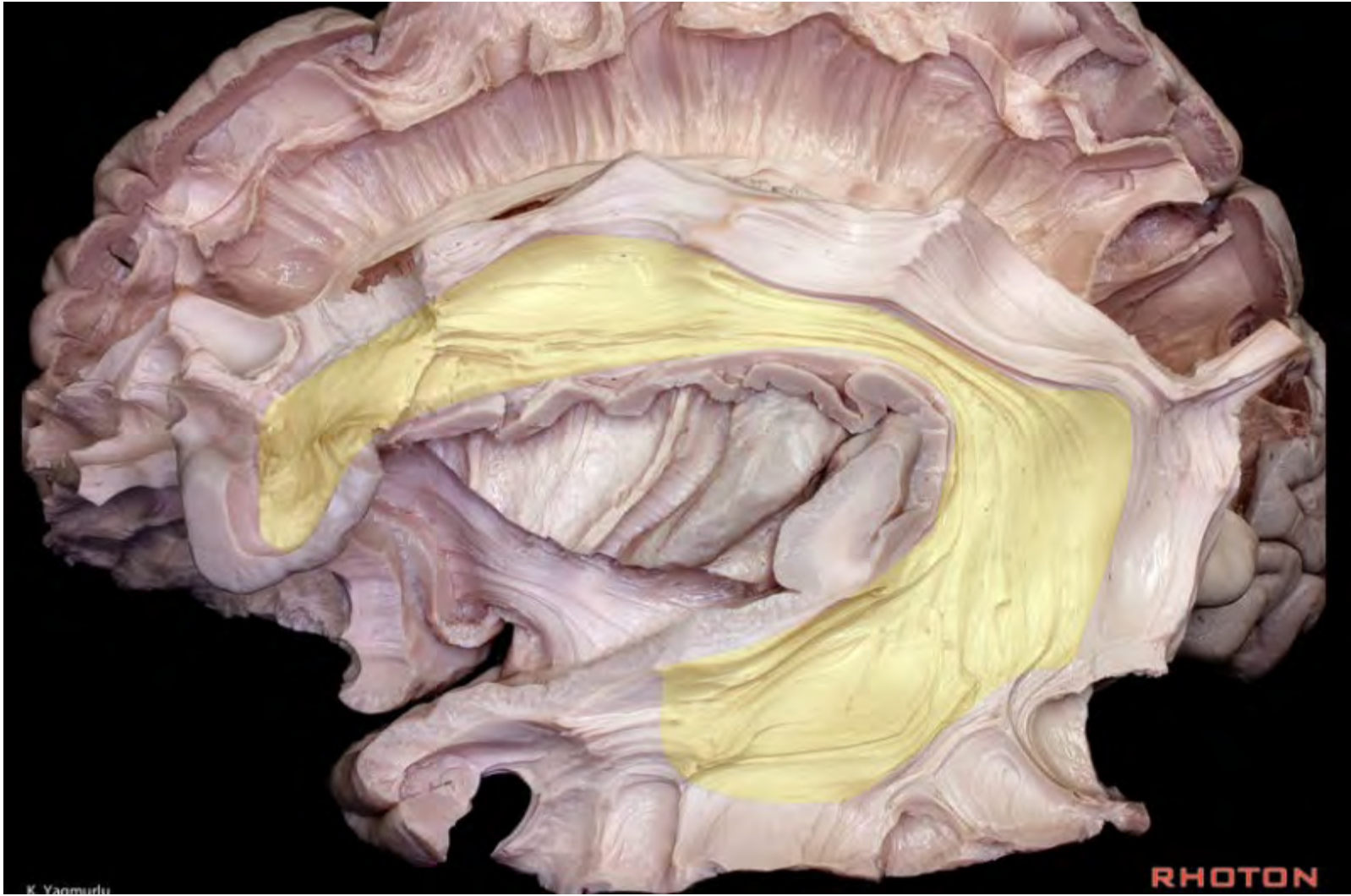


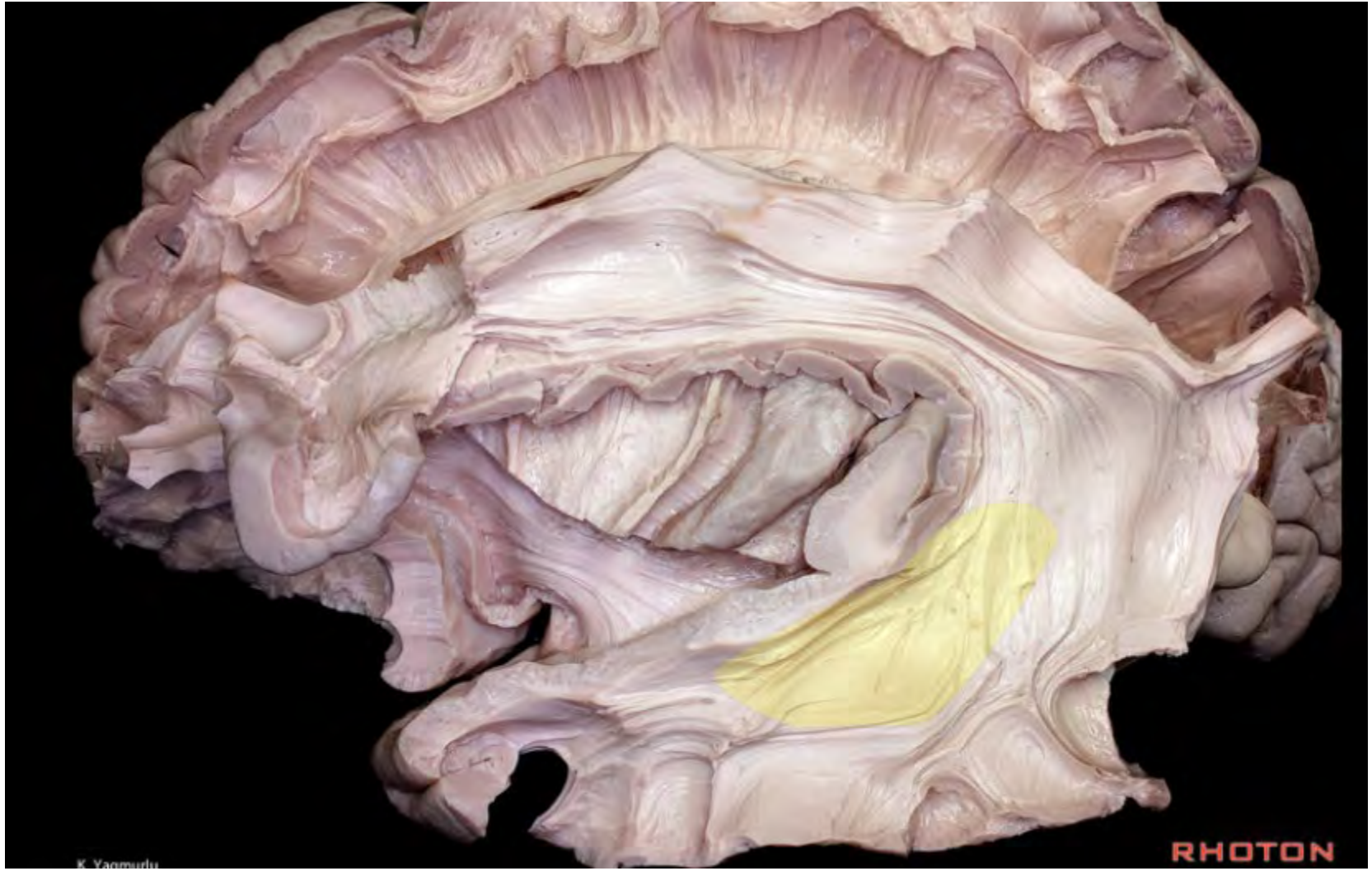






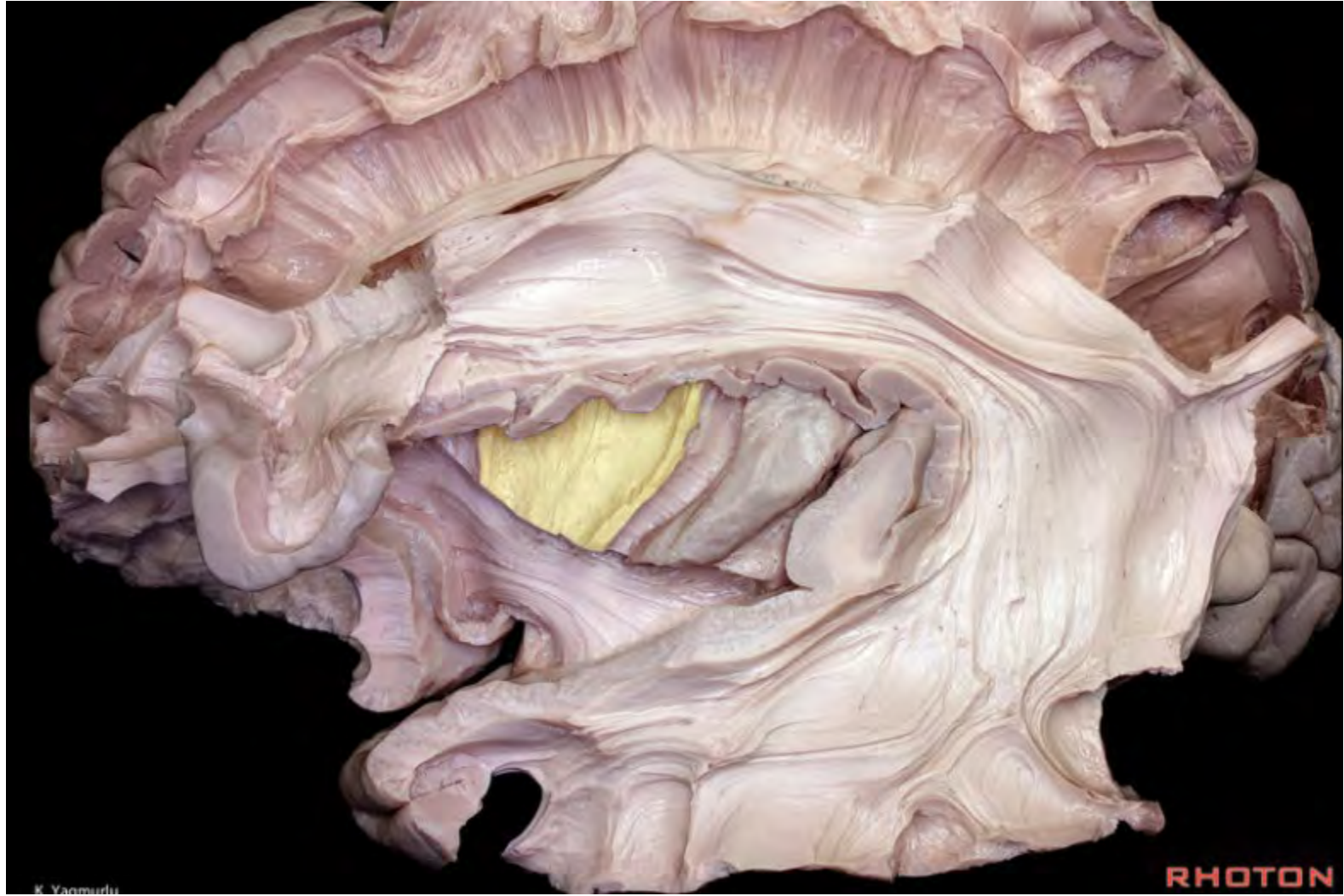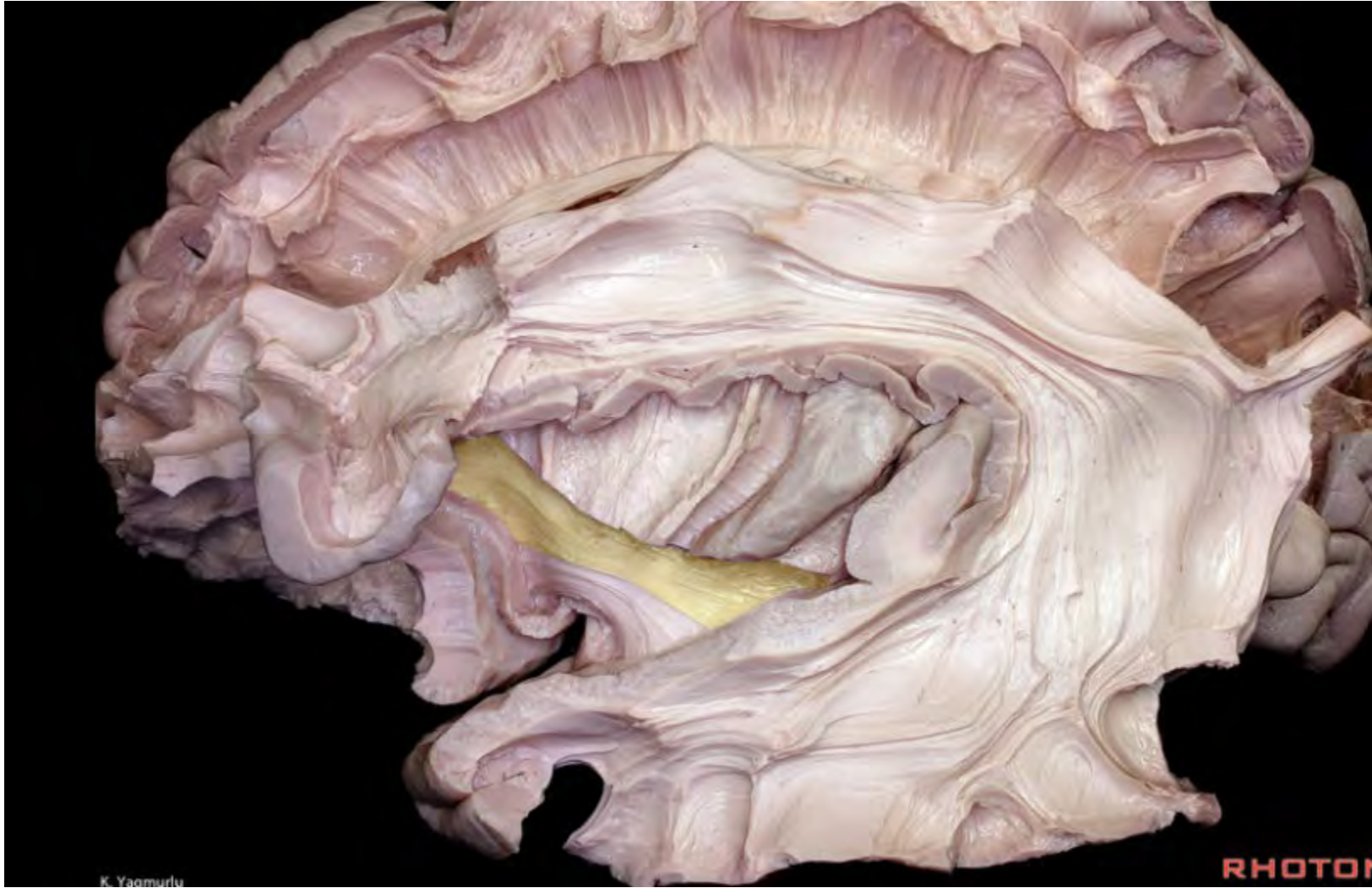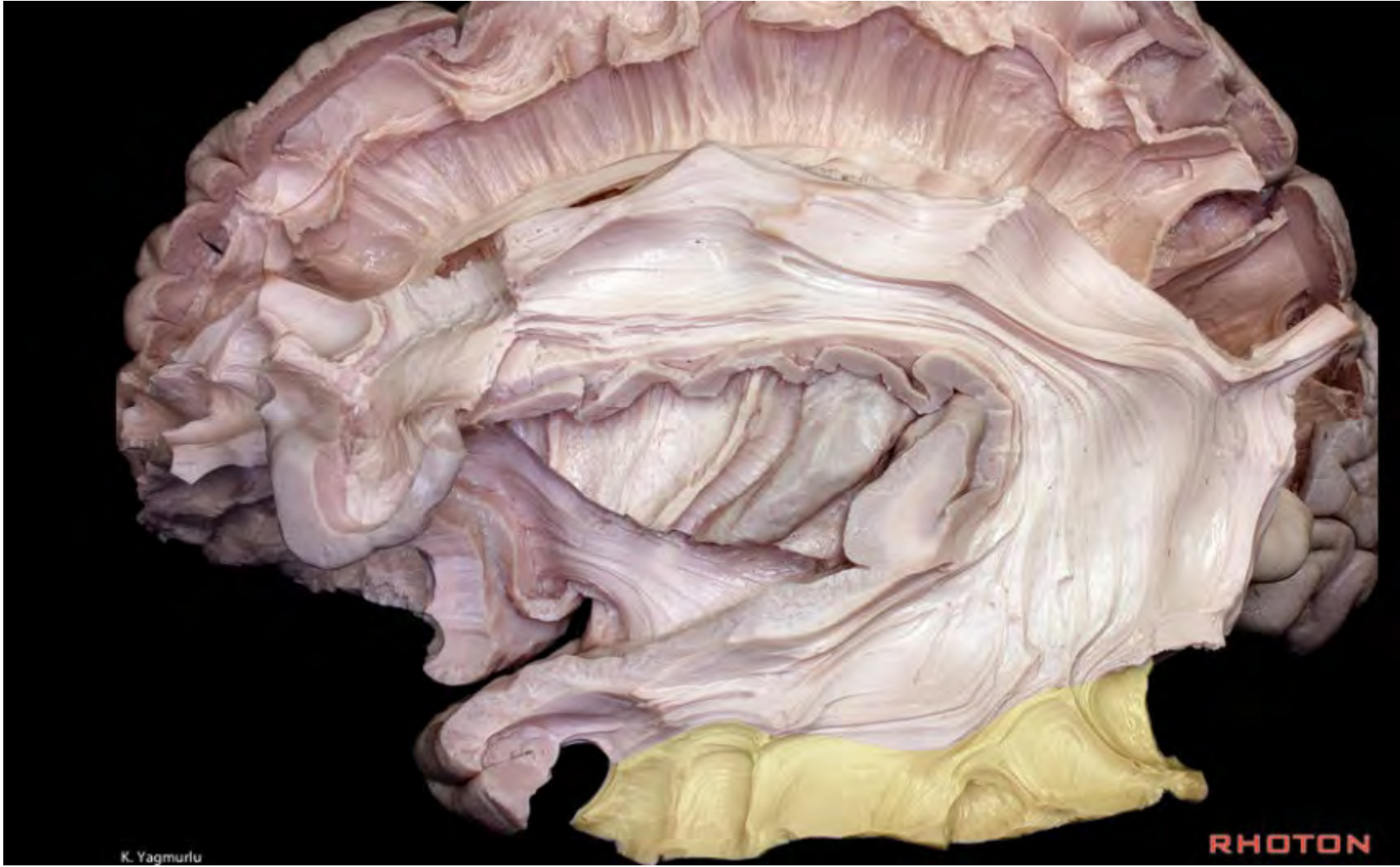K. Yagmurlu

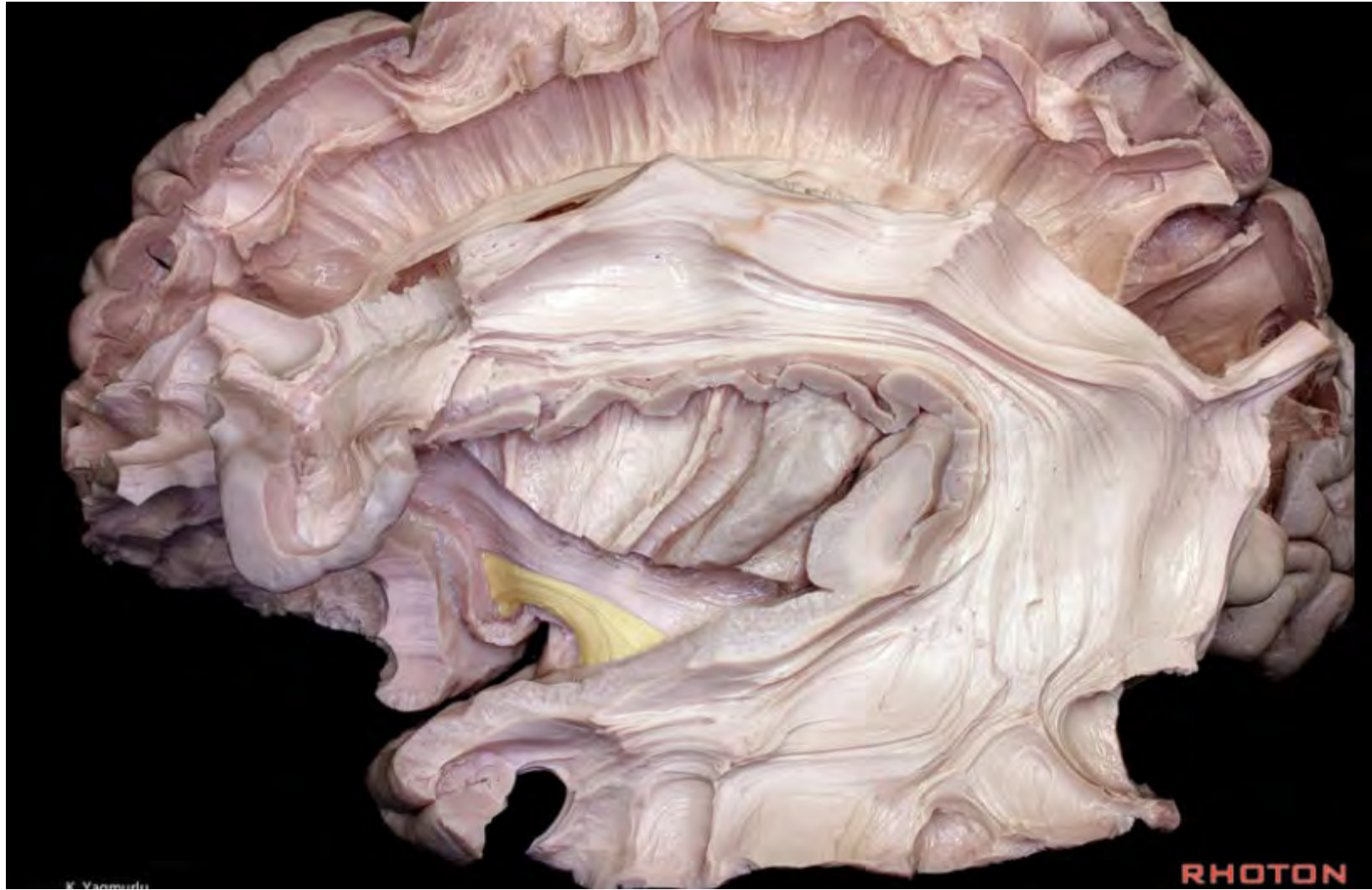**RHOTON**

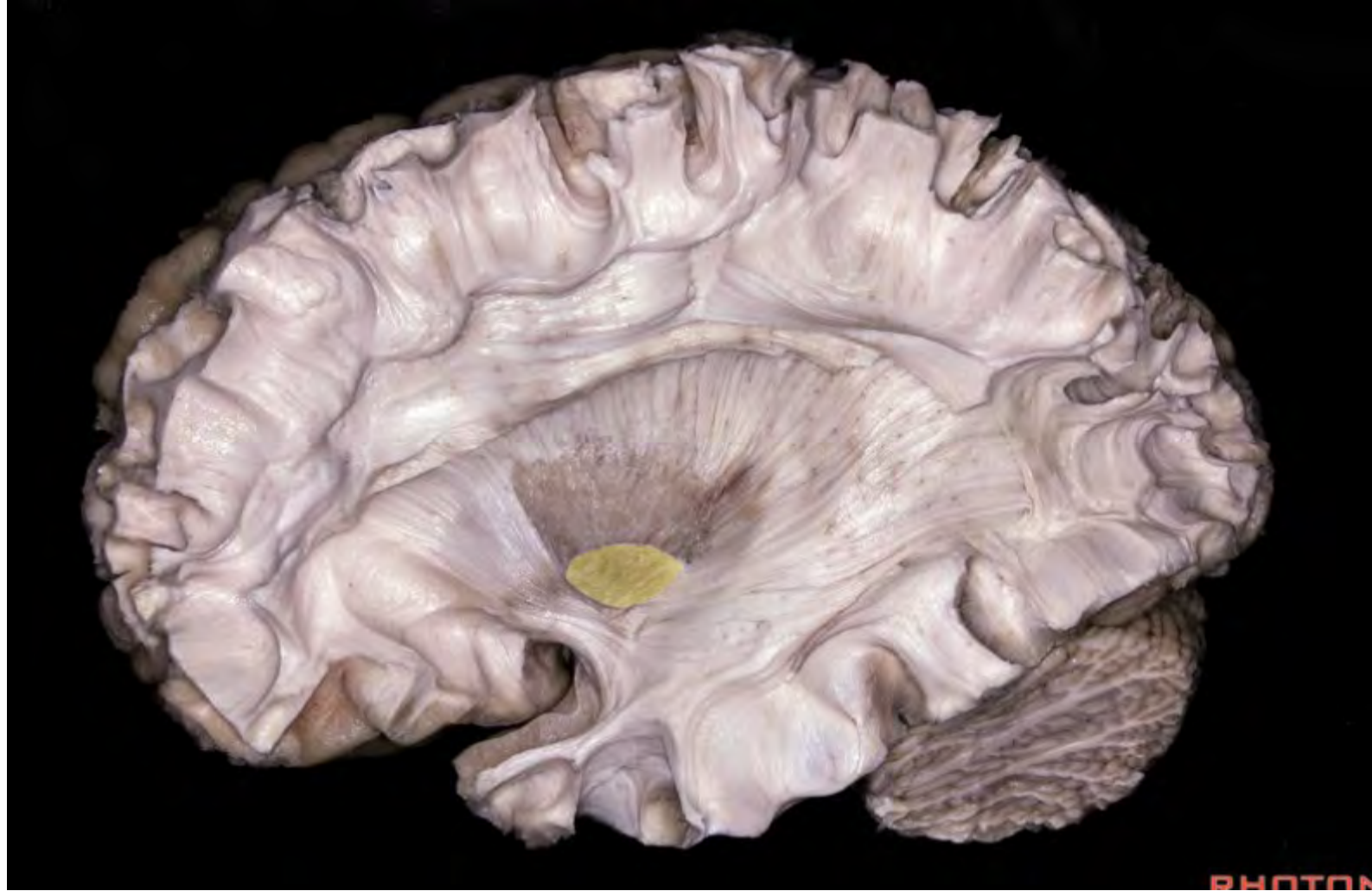

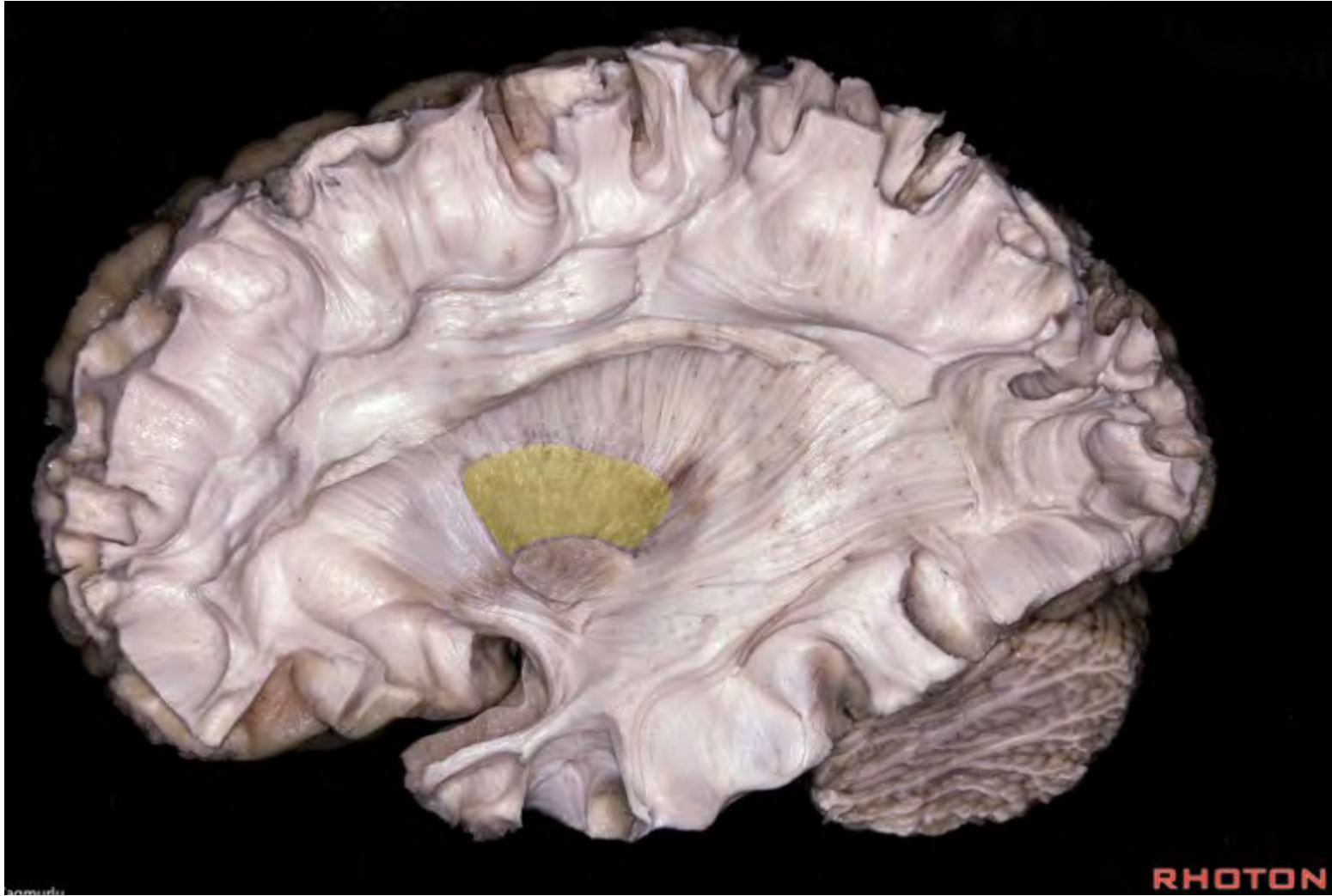




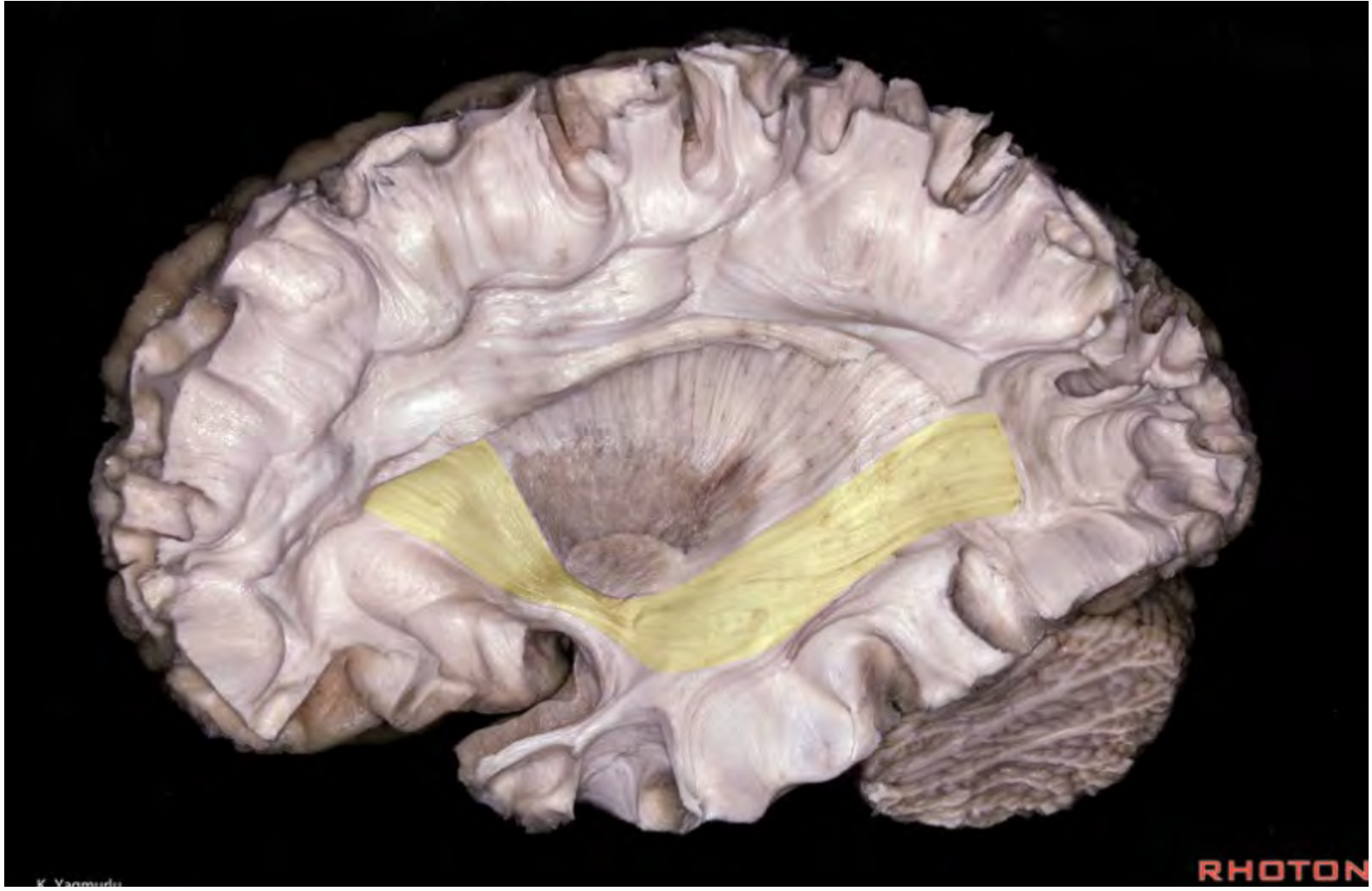



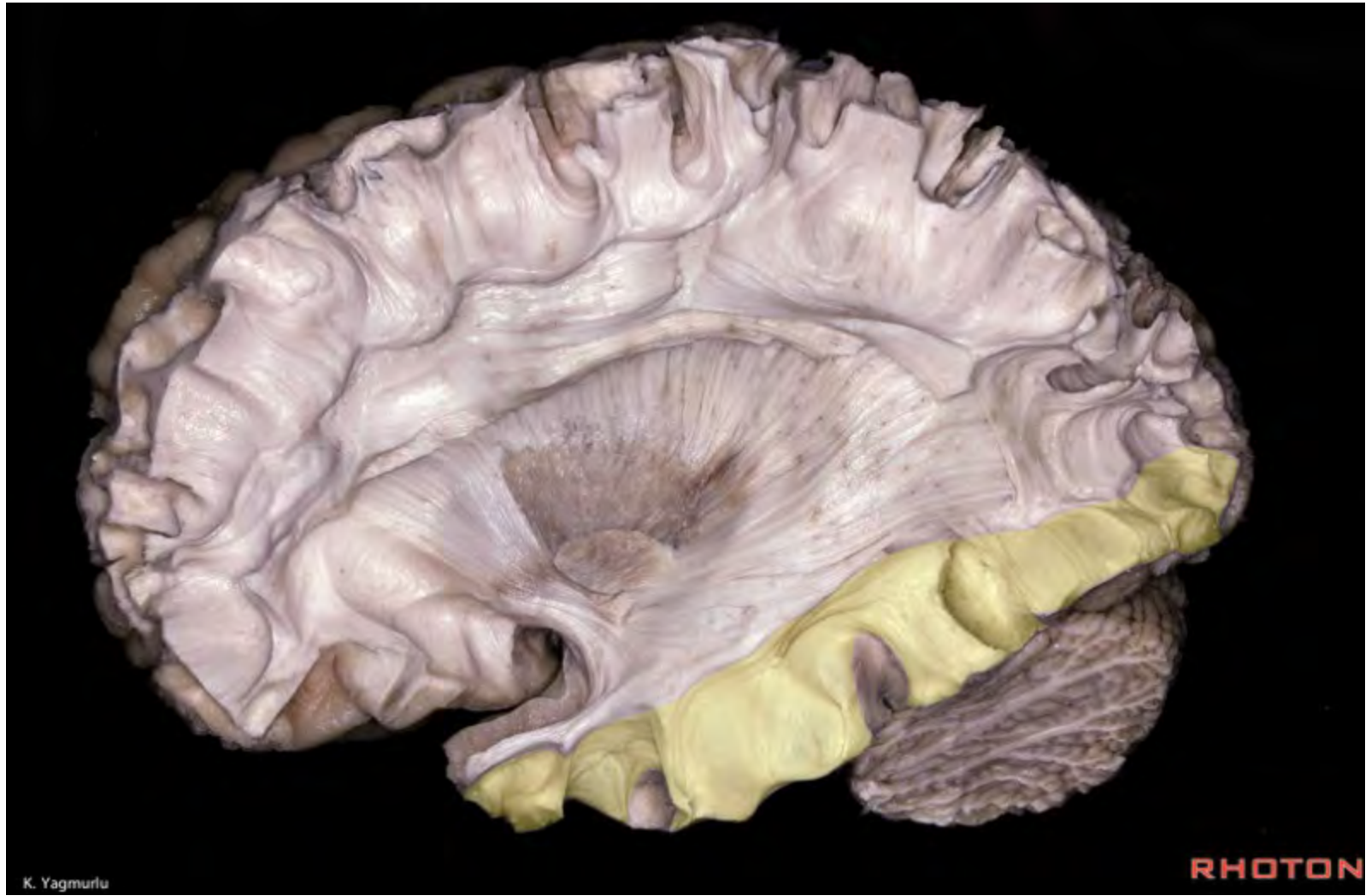


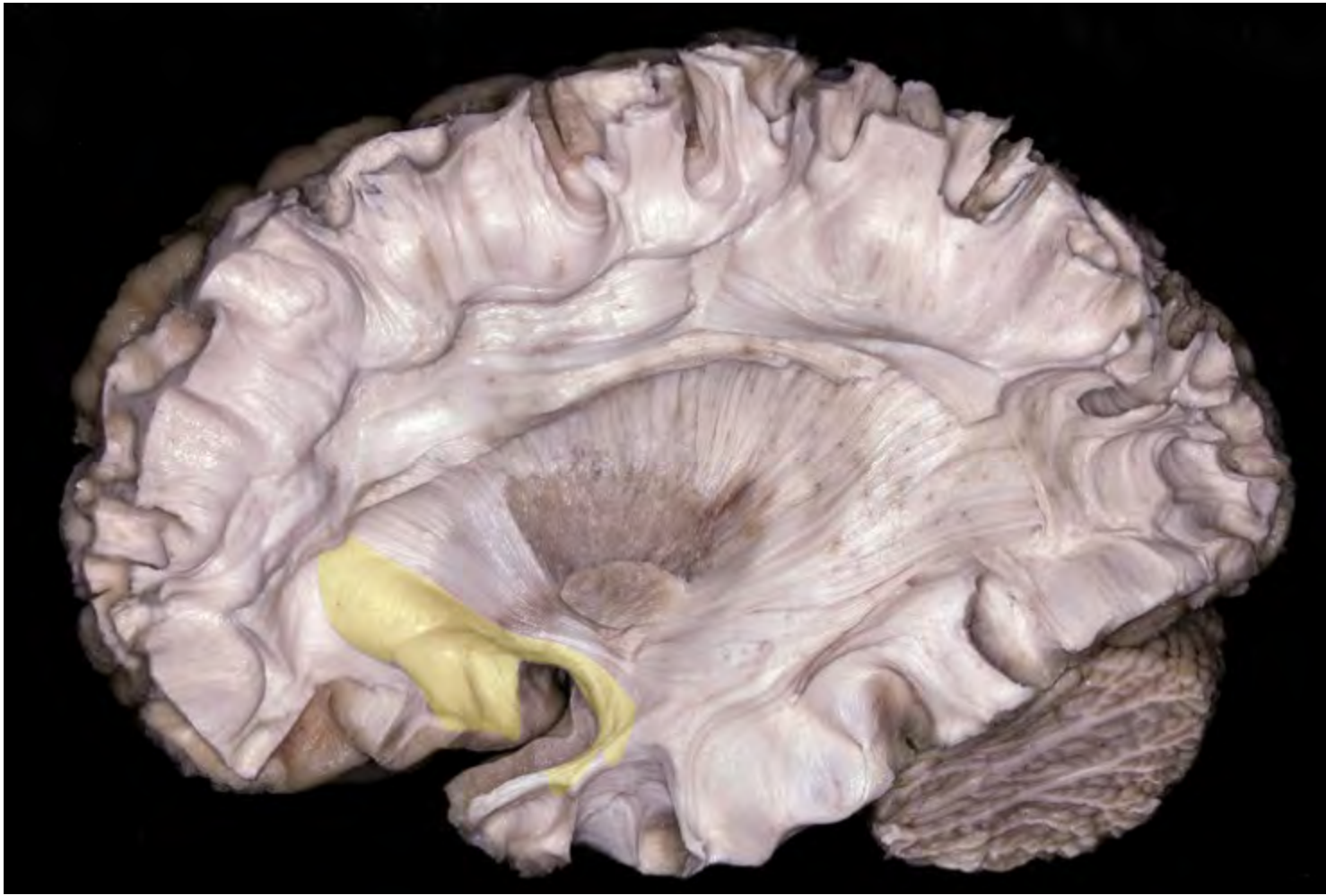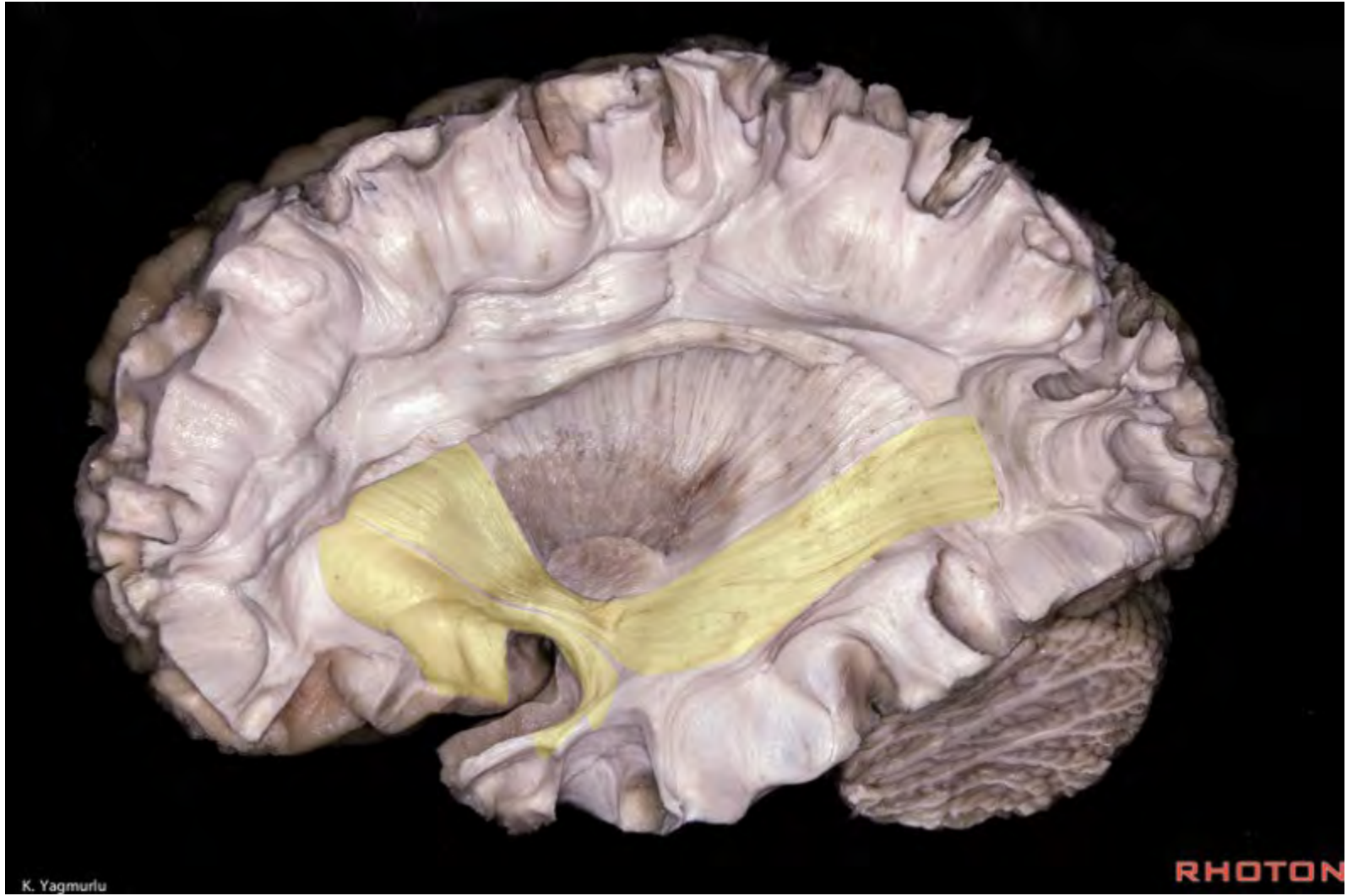


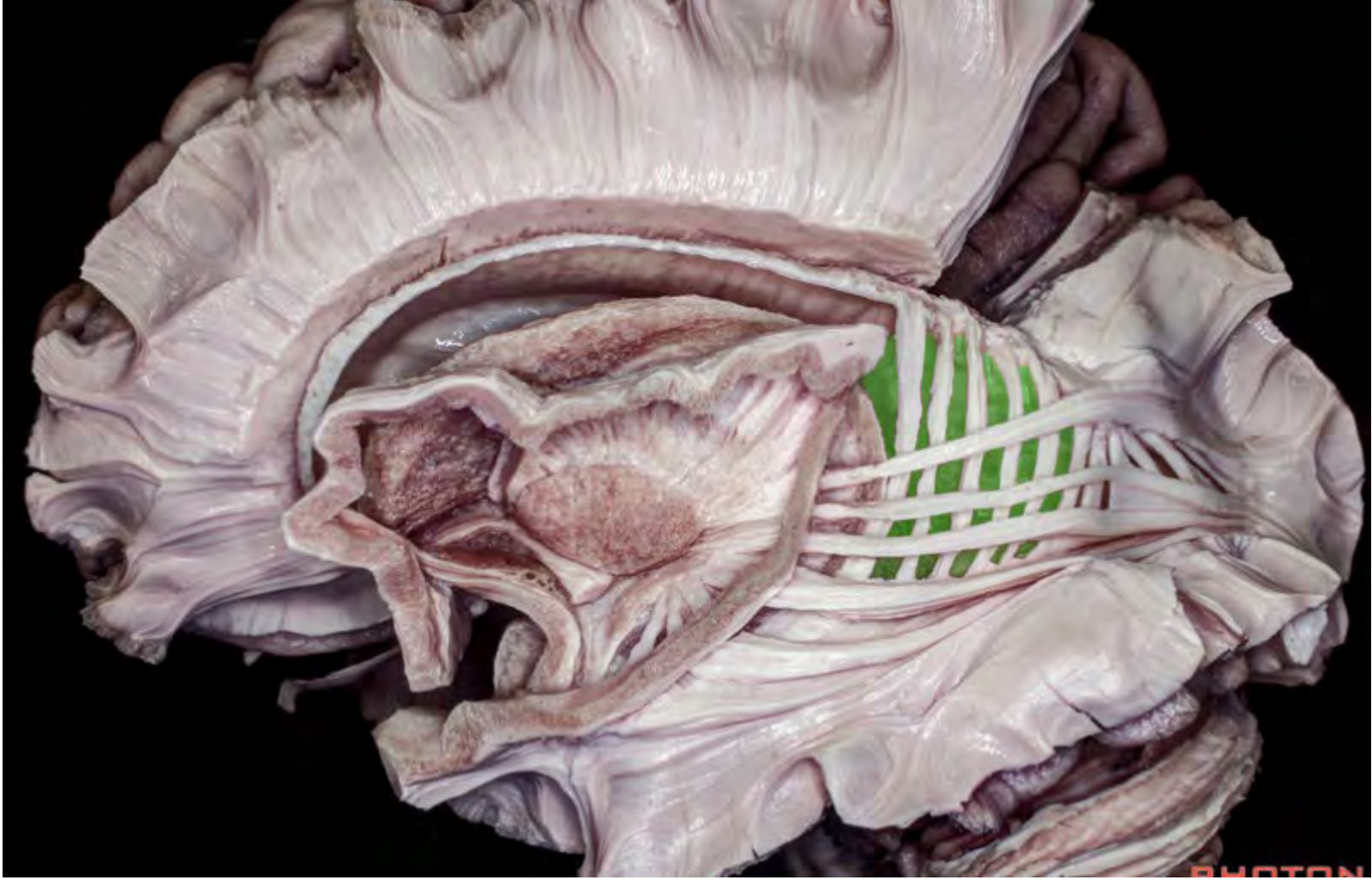


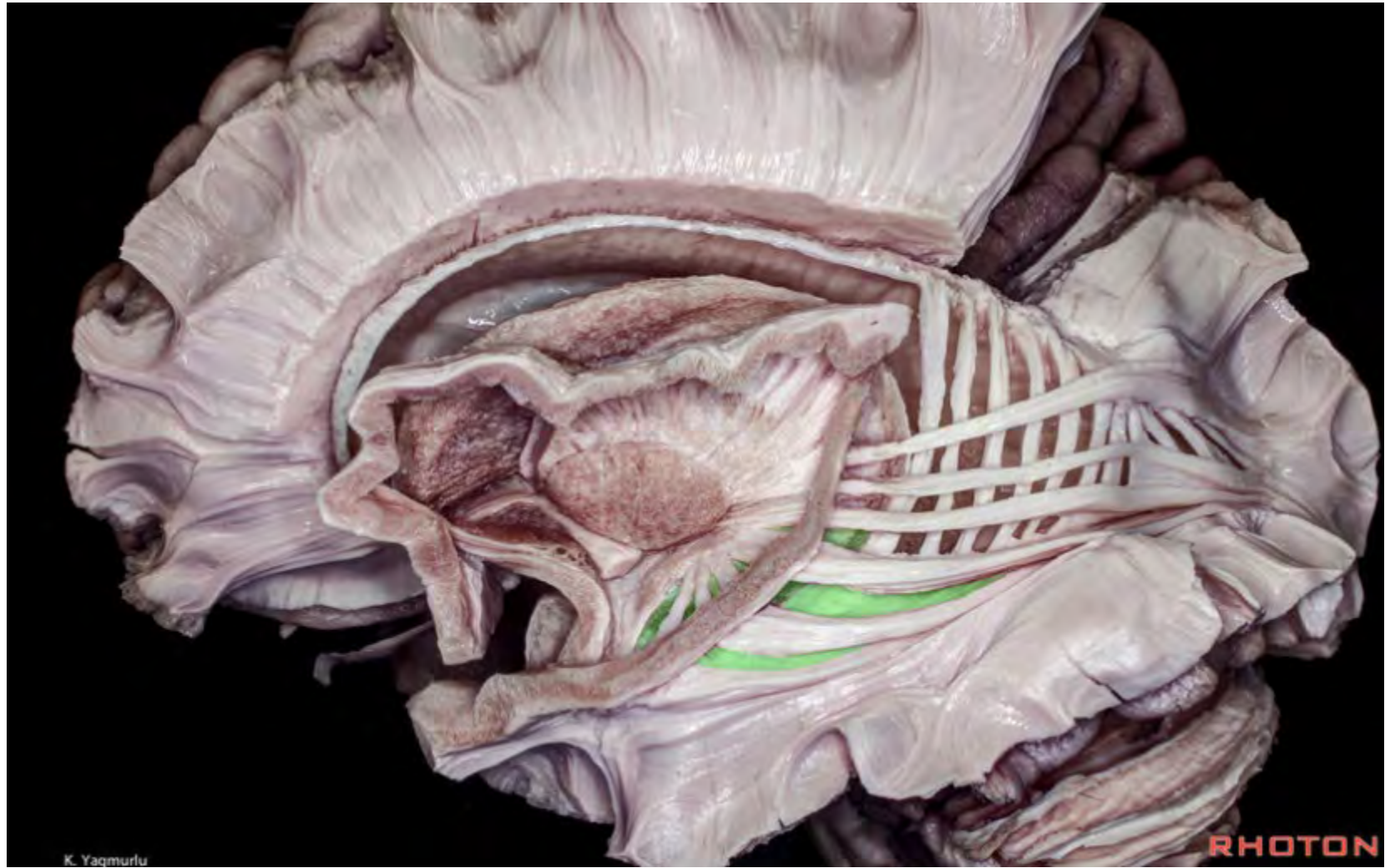


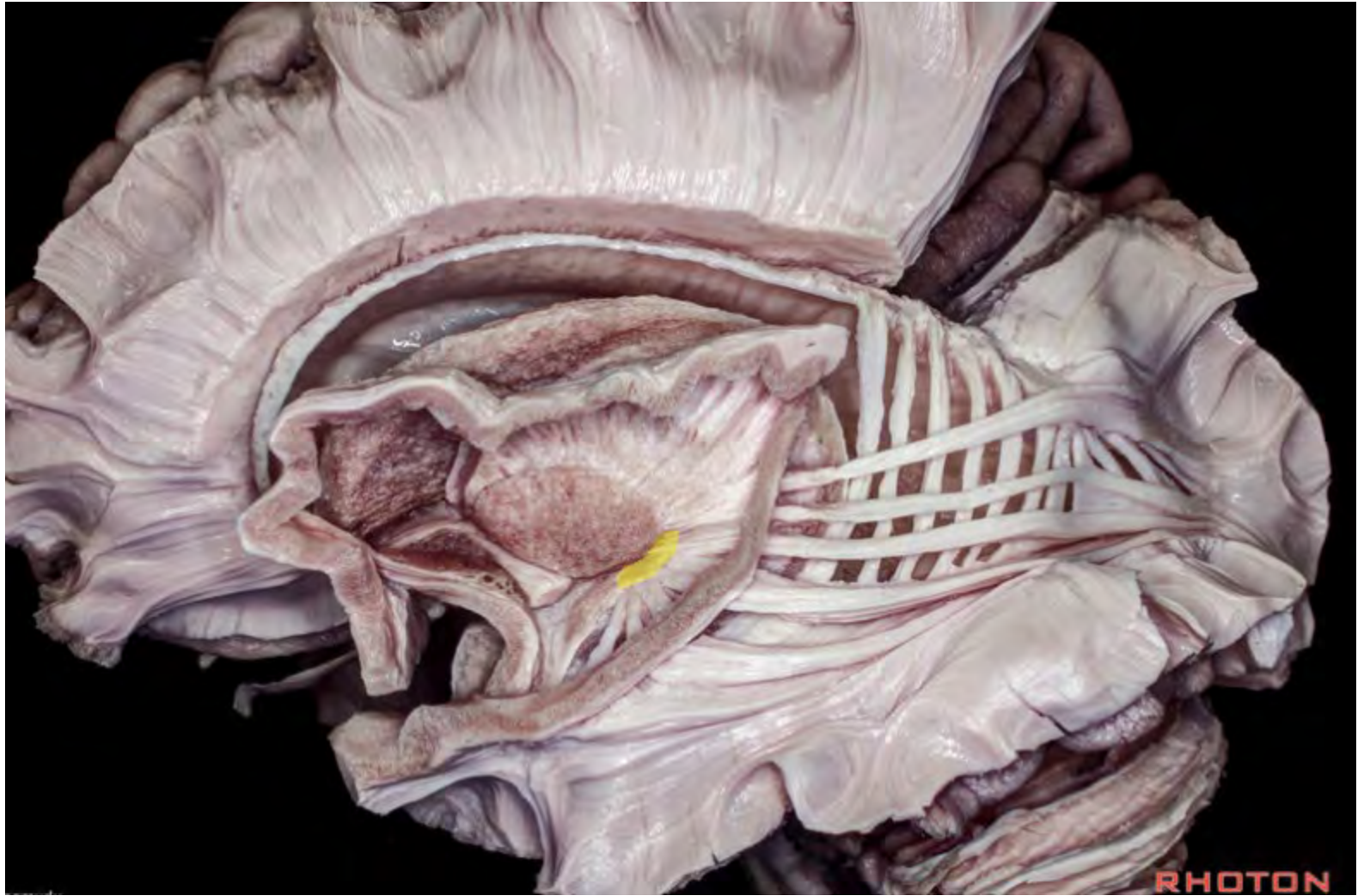


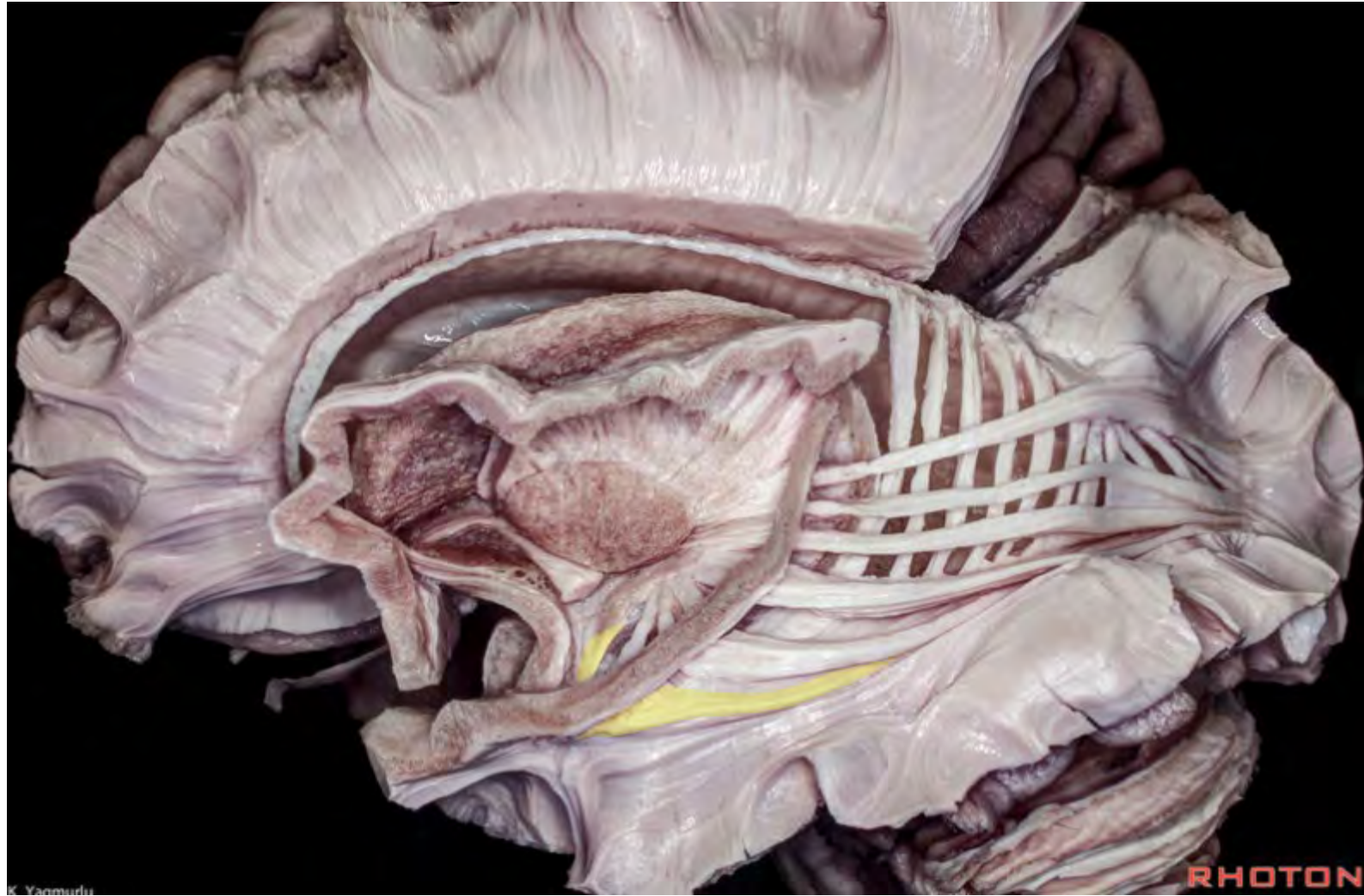




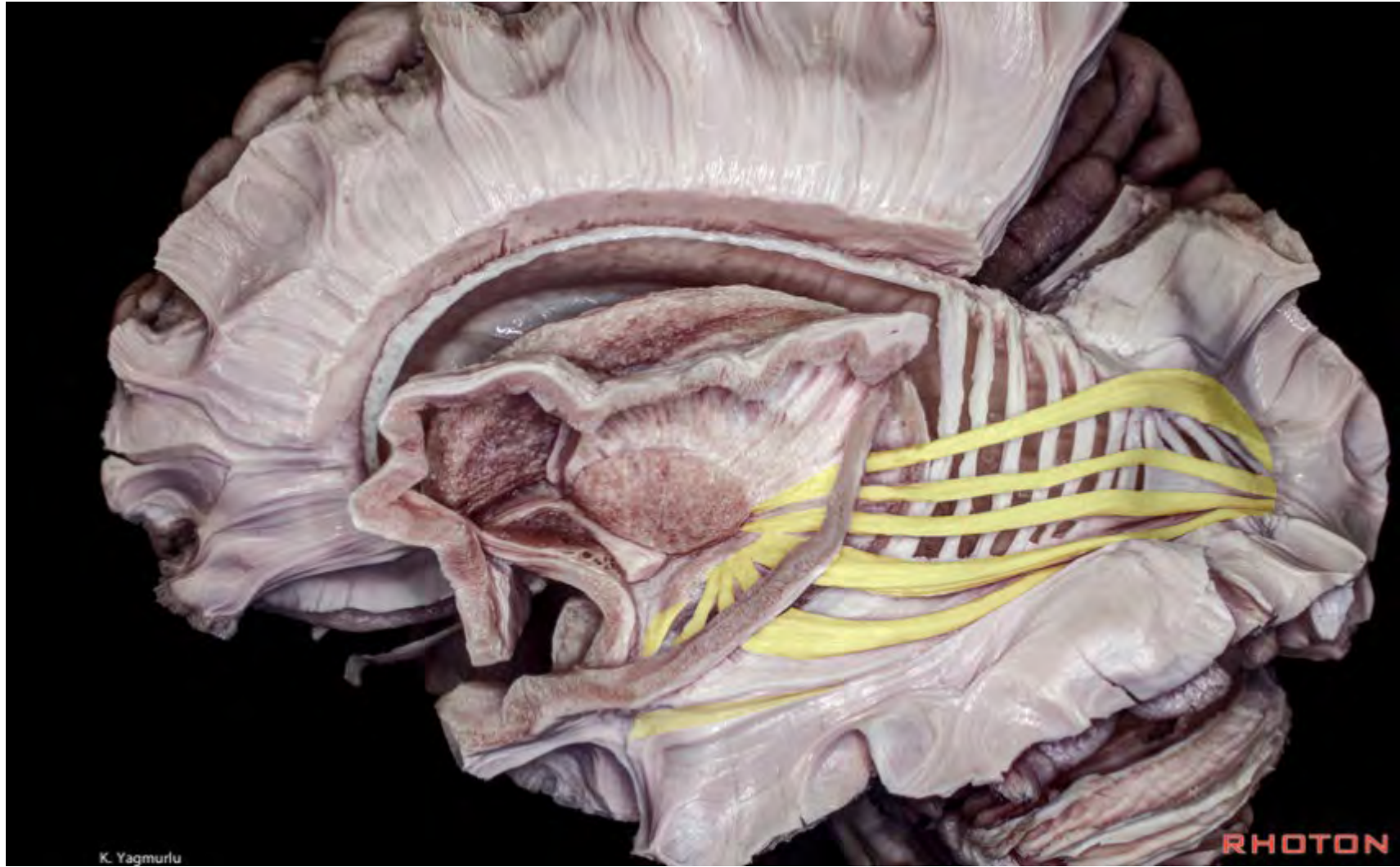


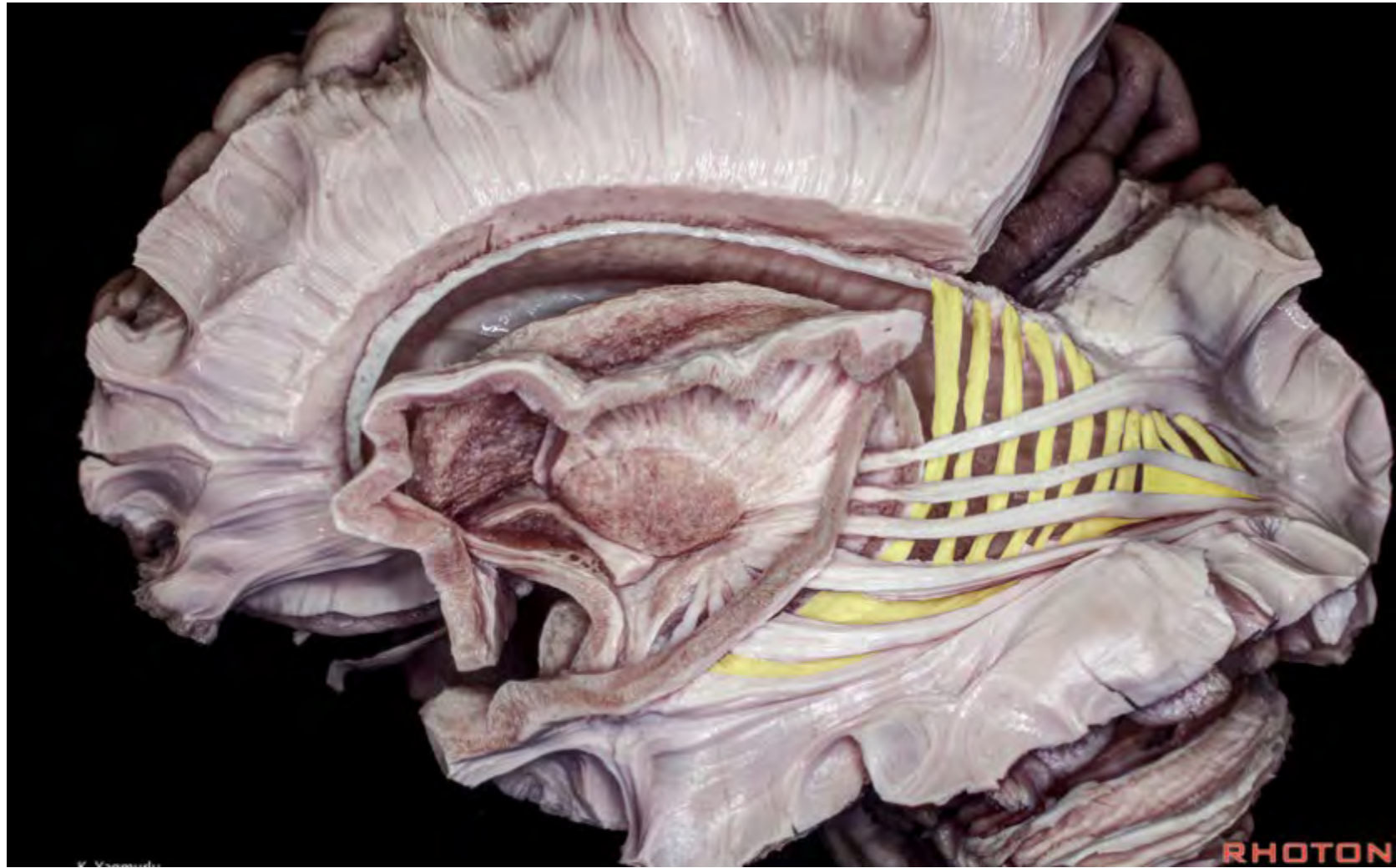





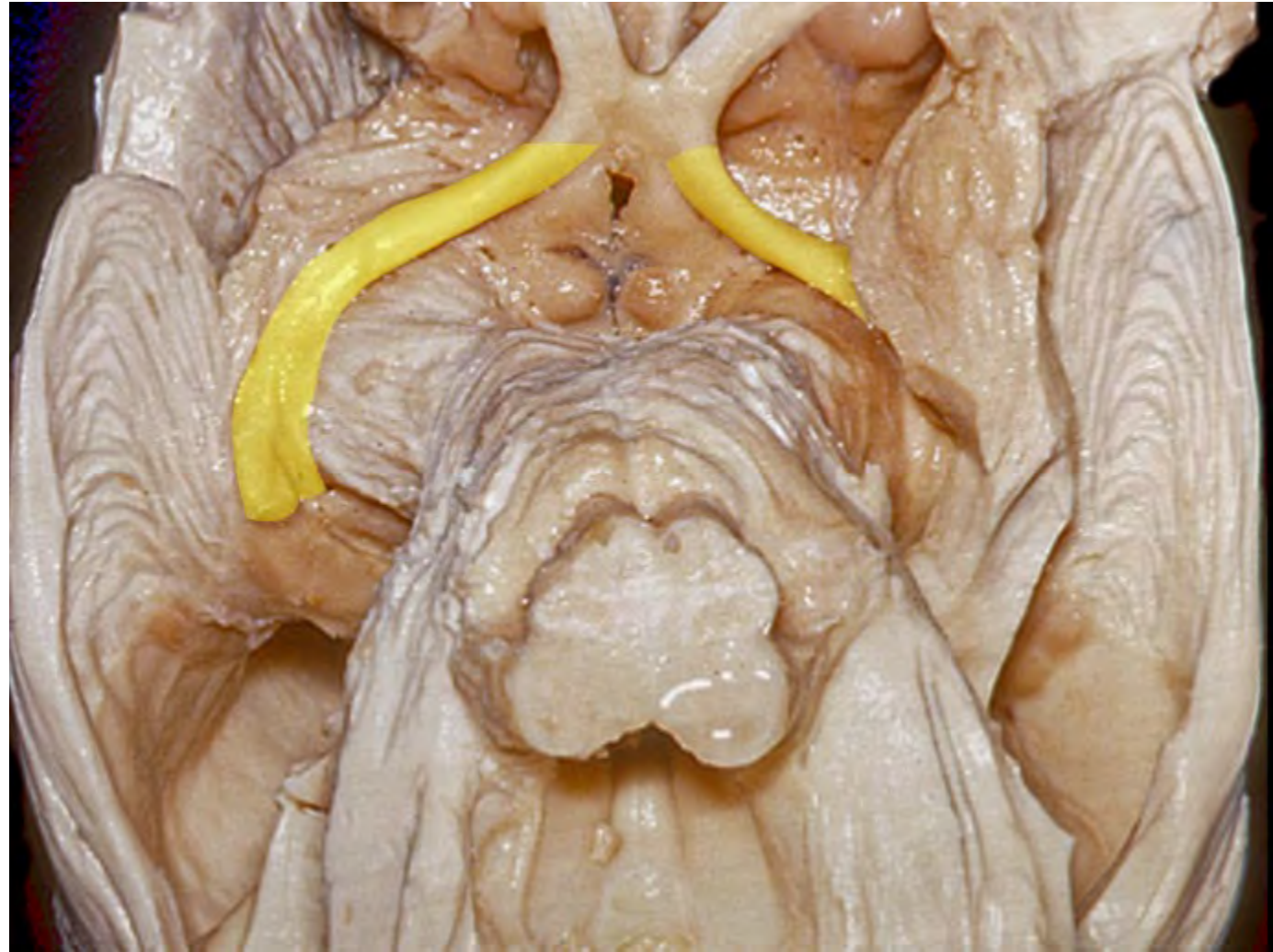


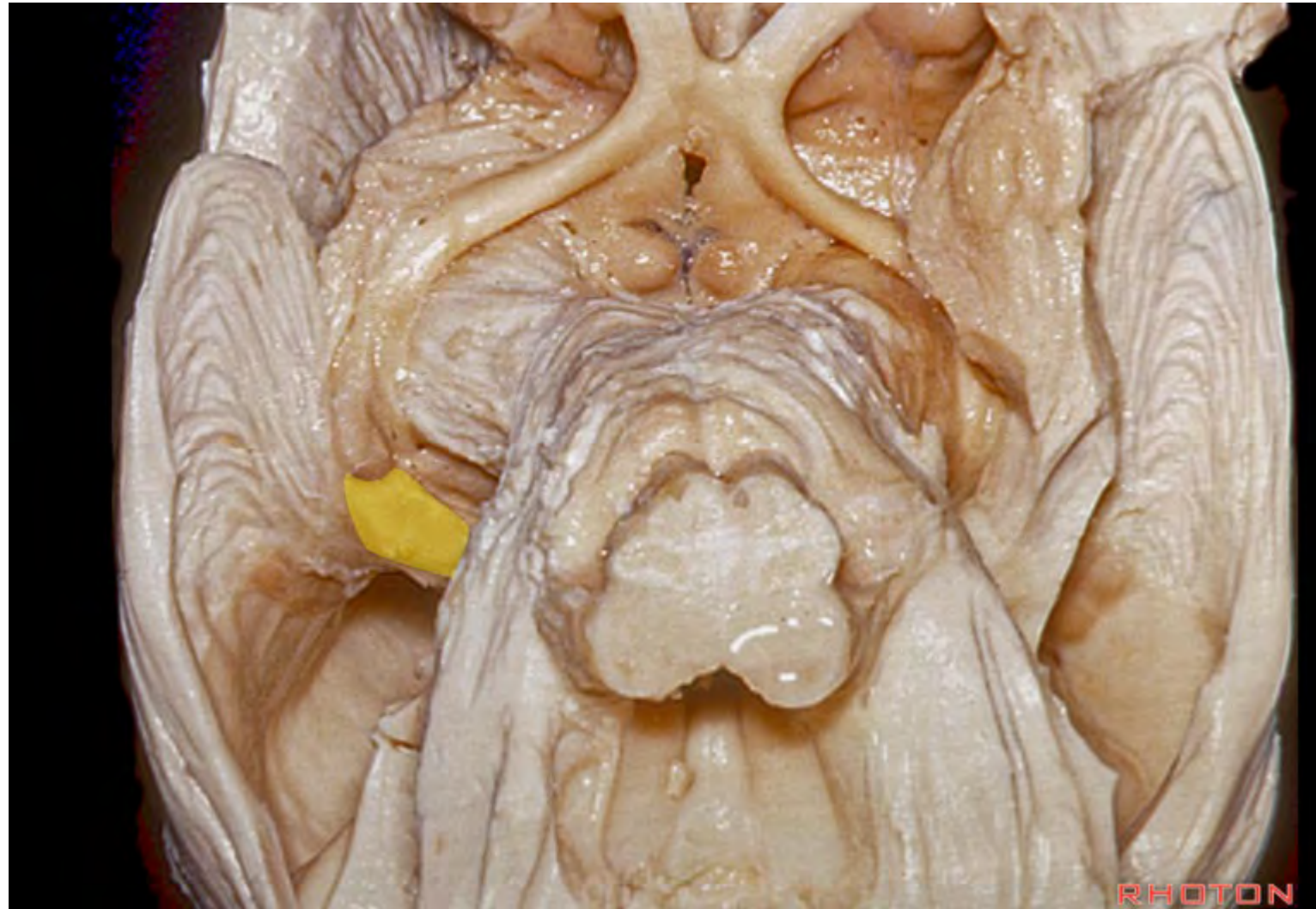


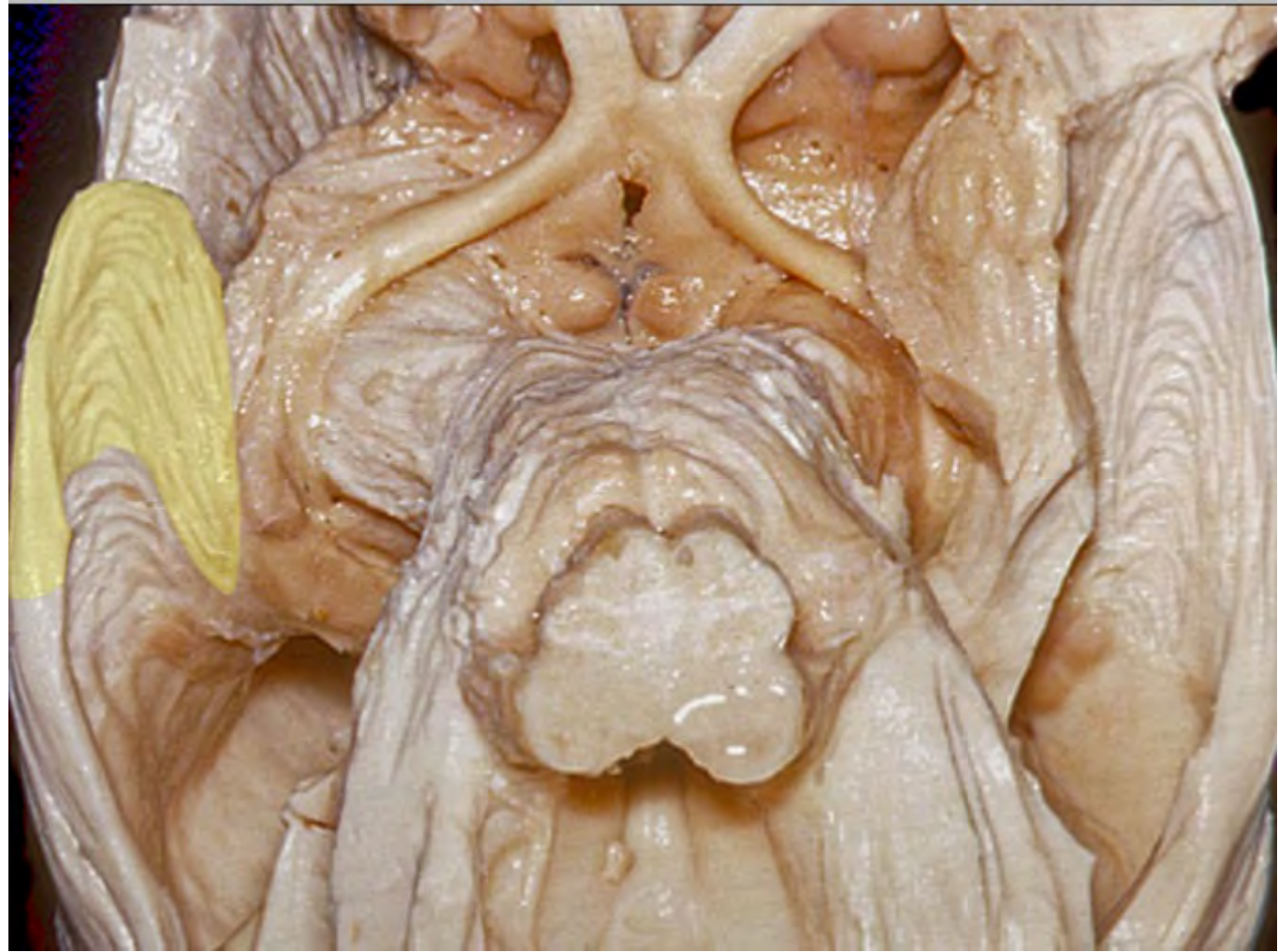
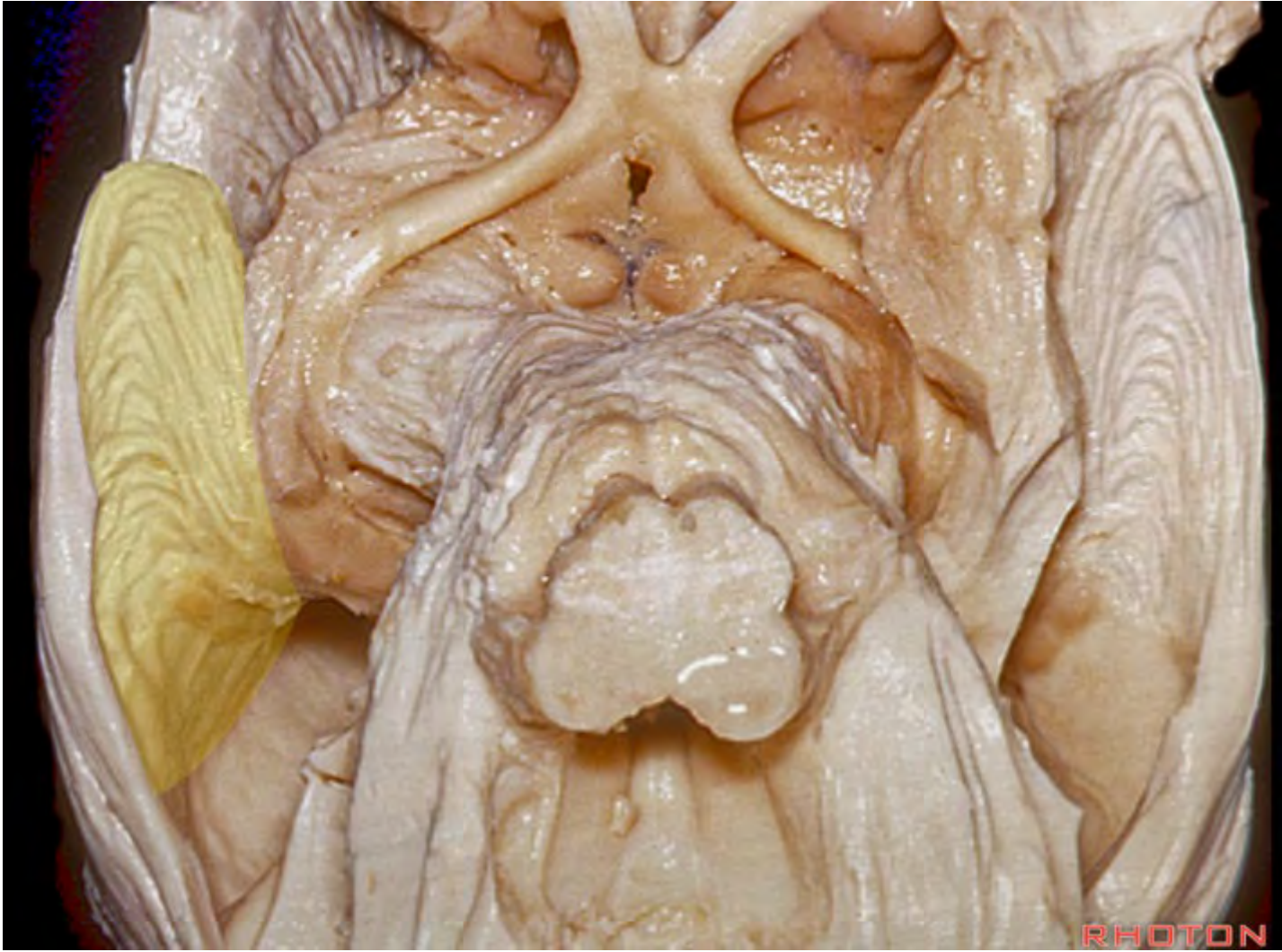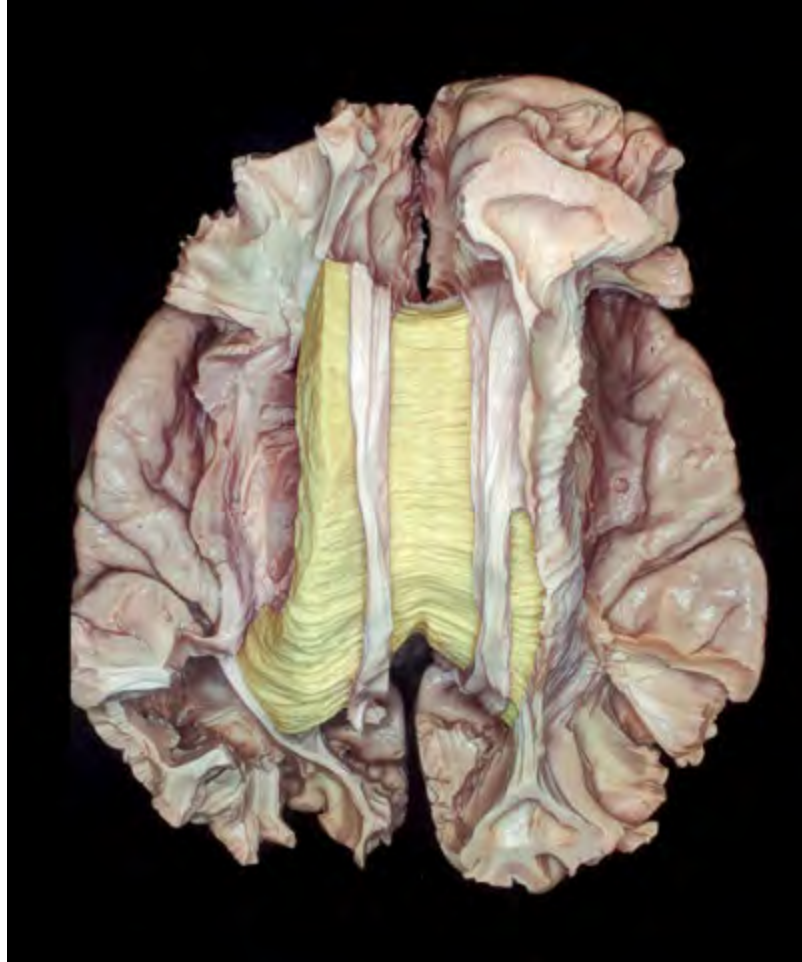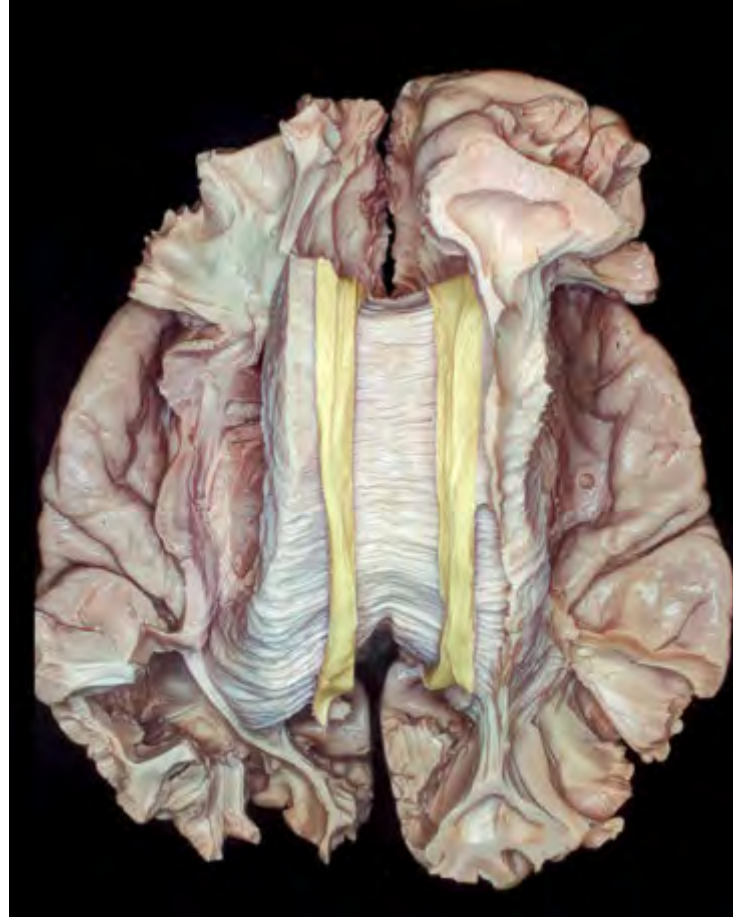




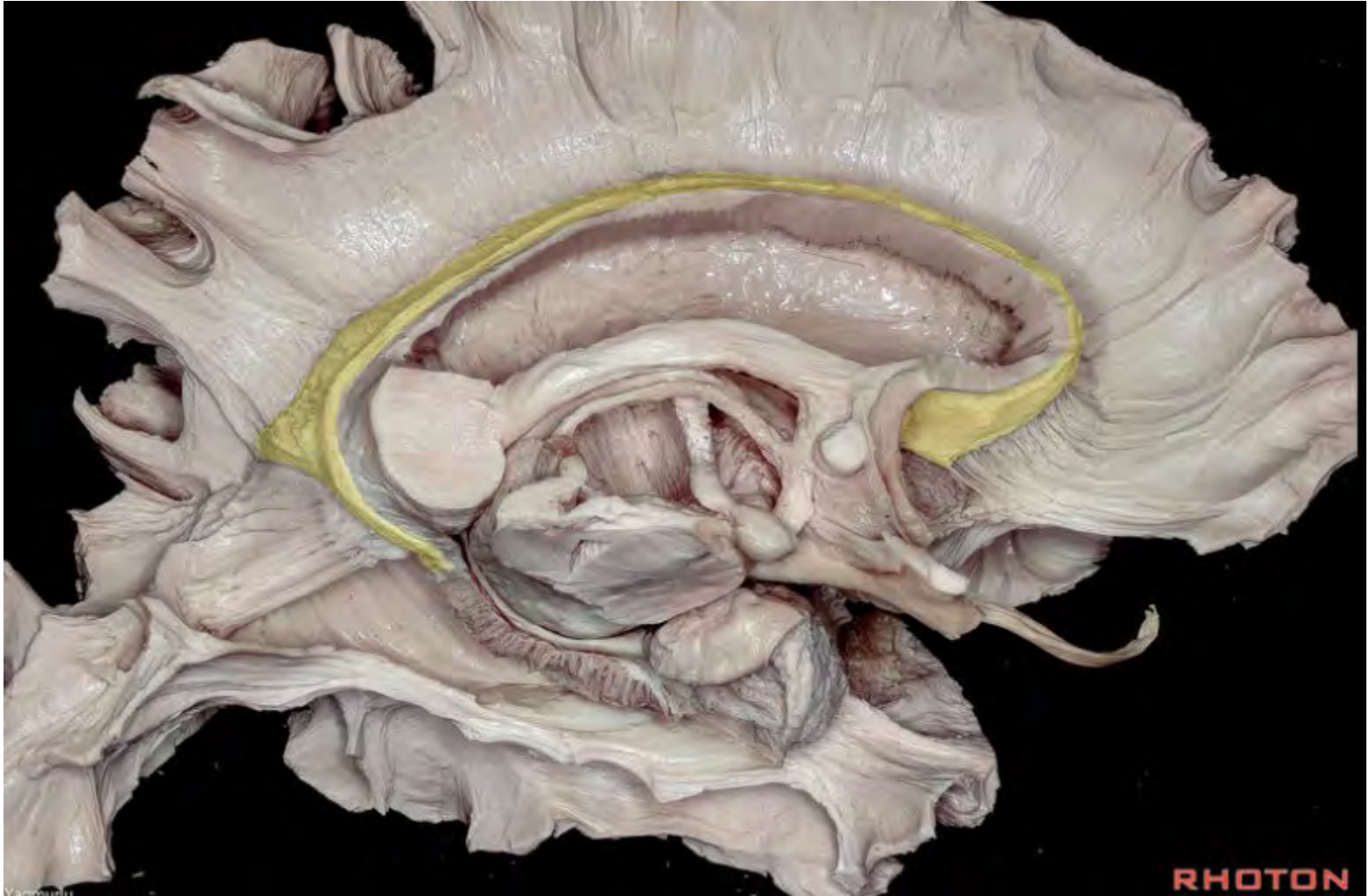








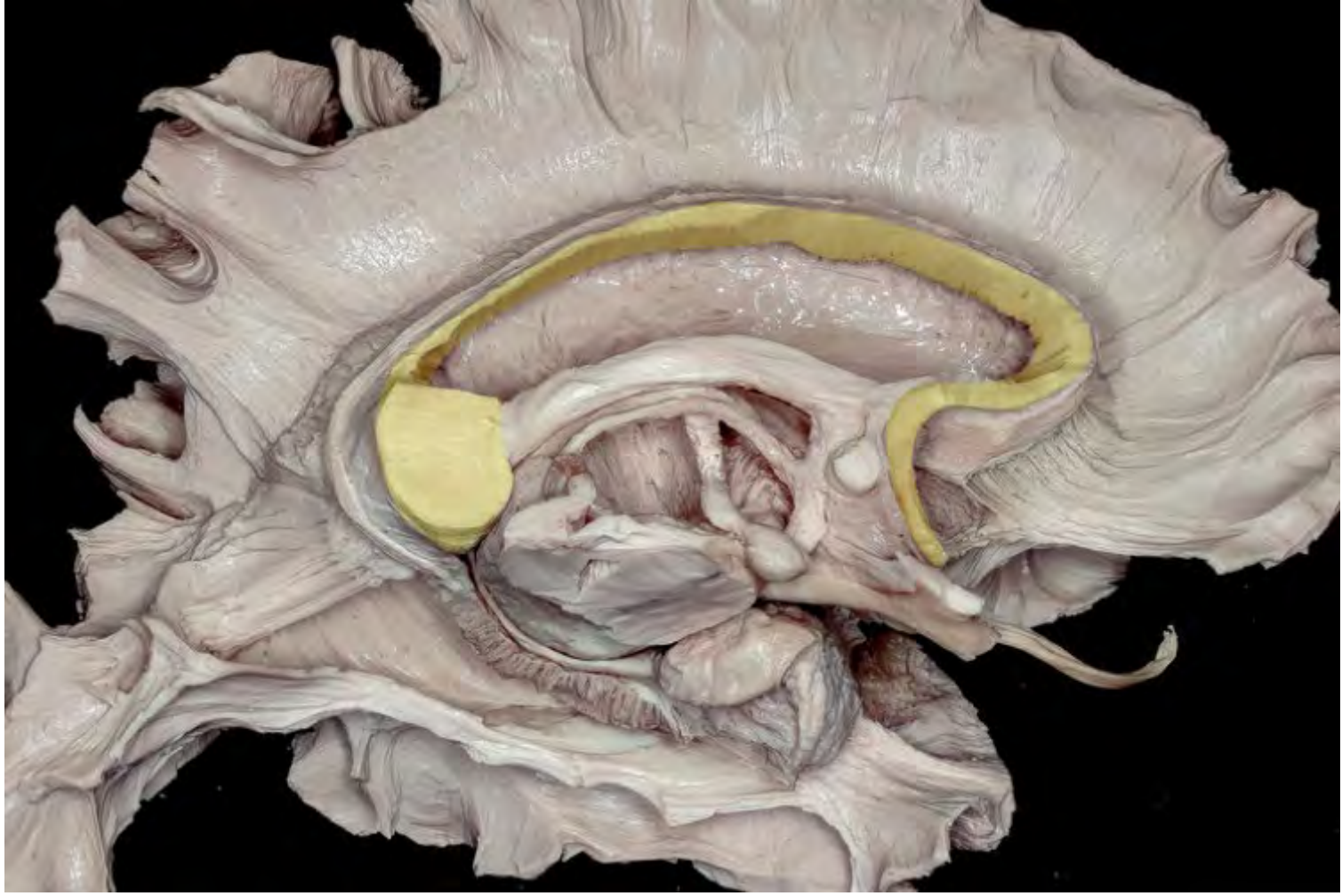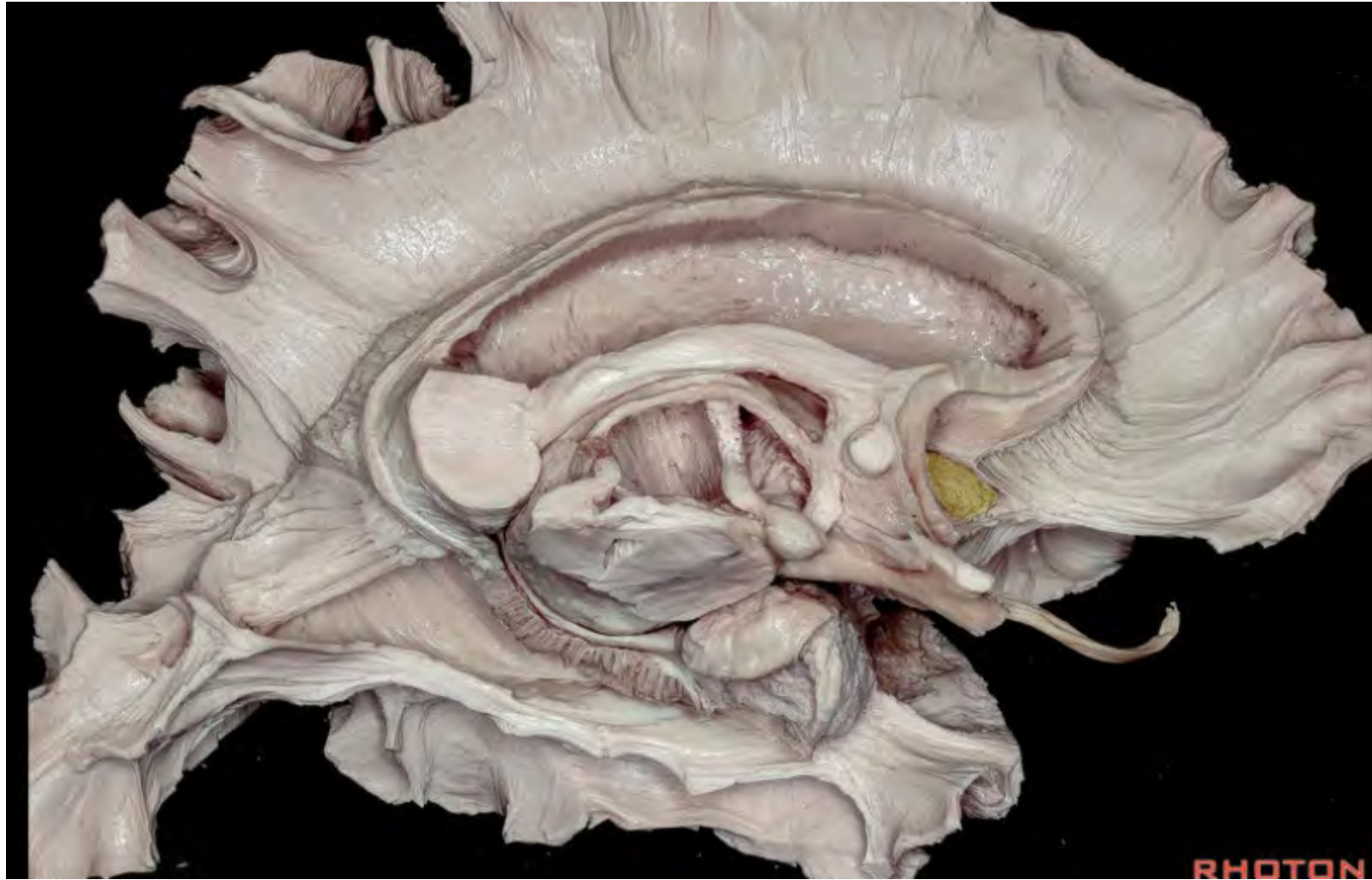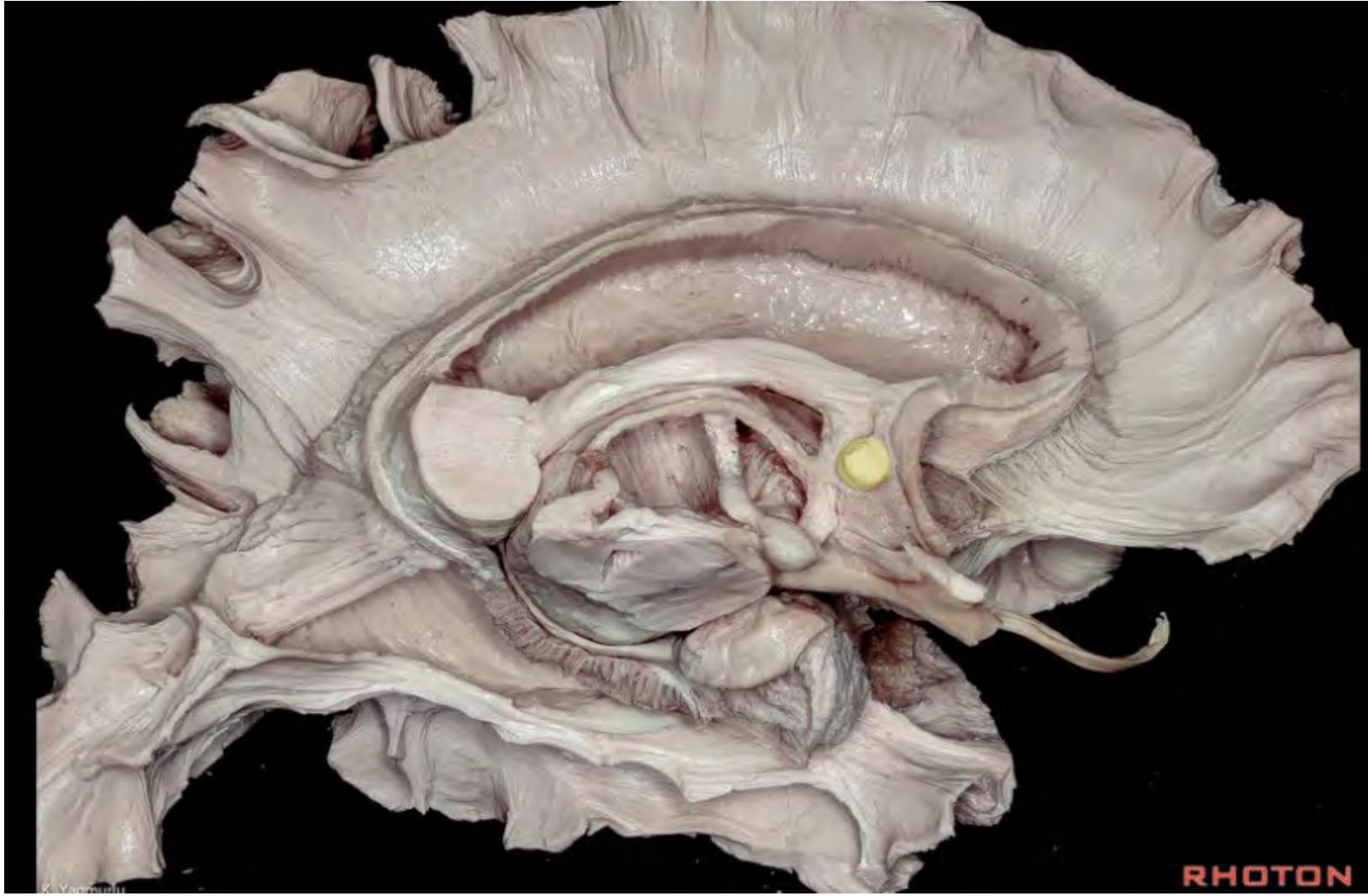




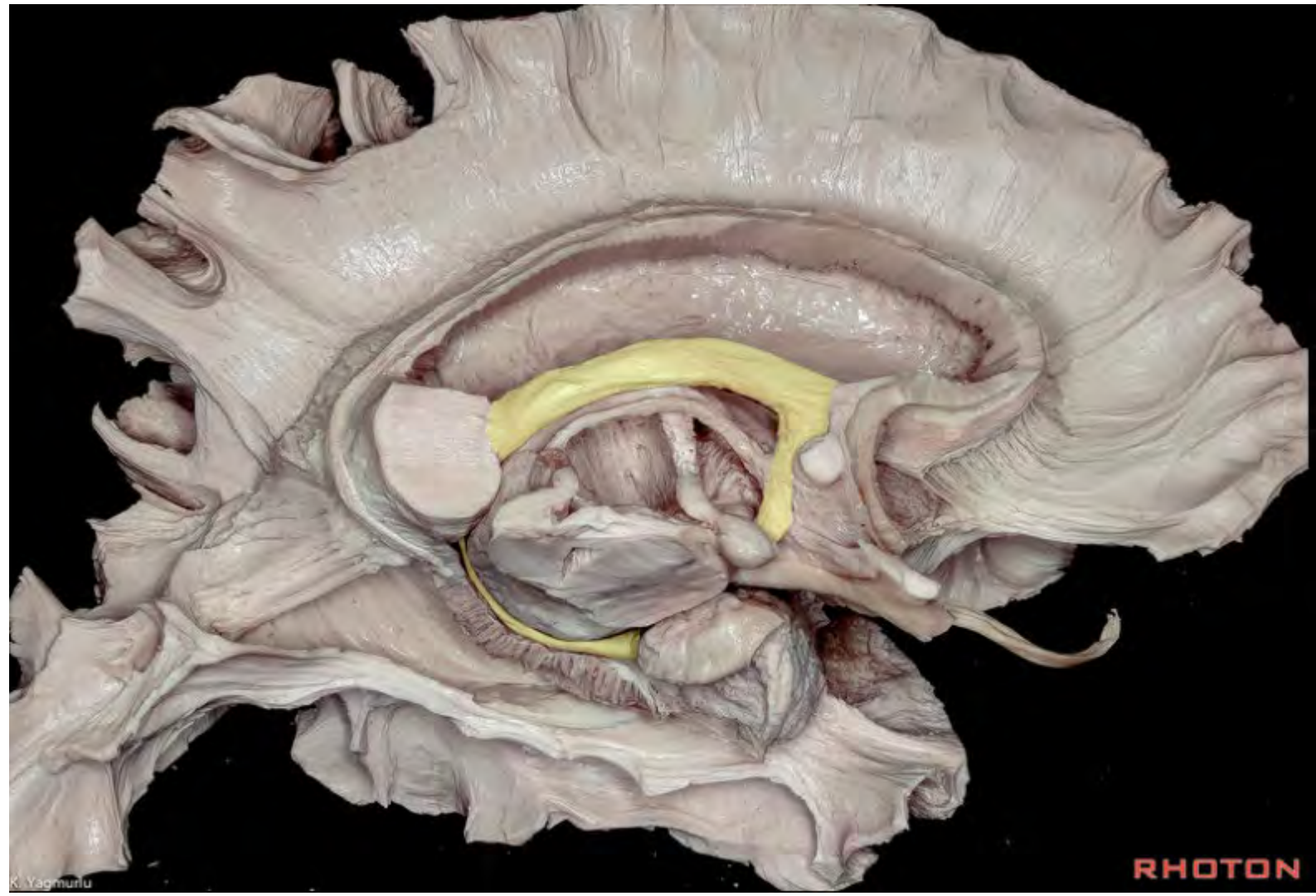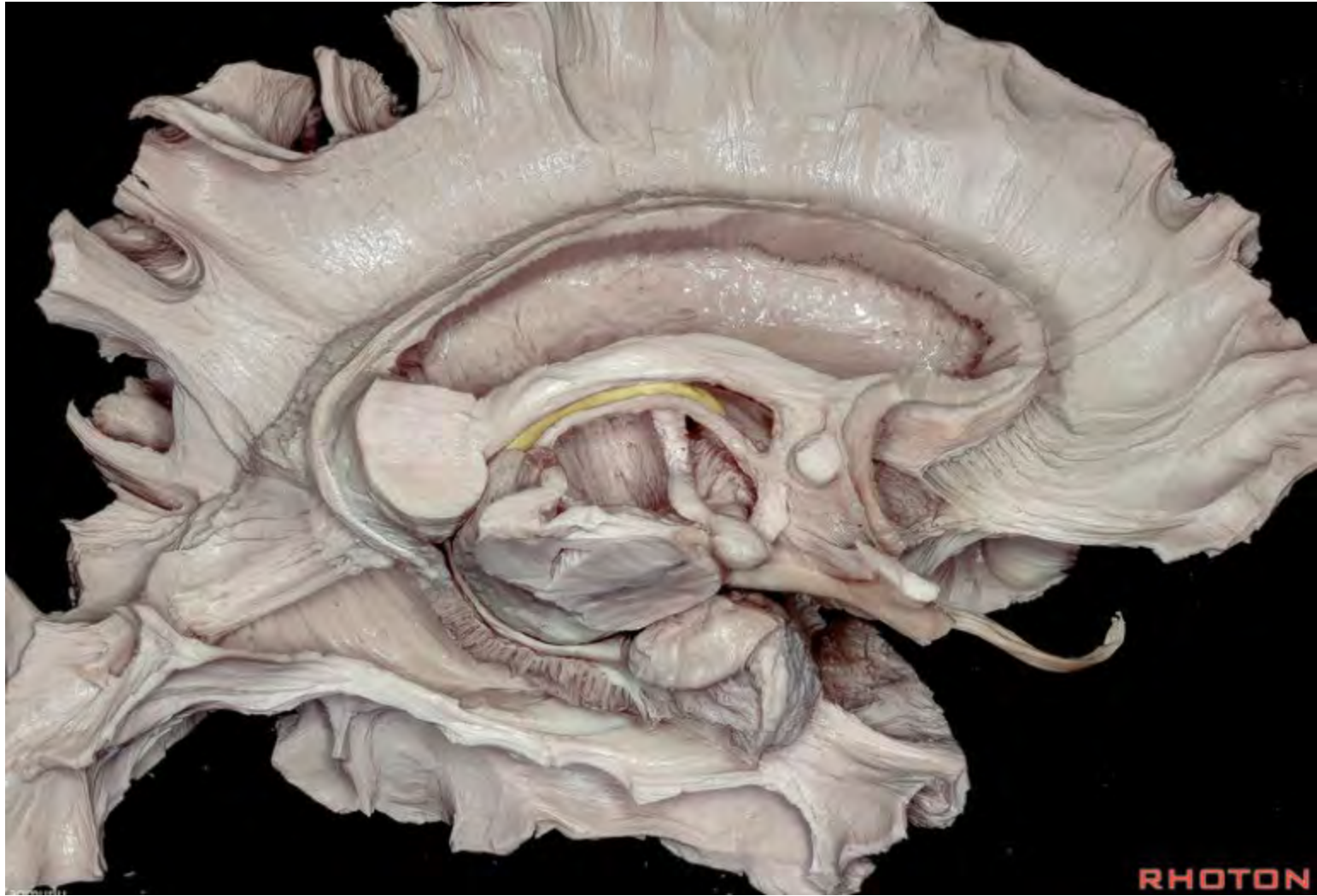
RHOTO

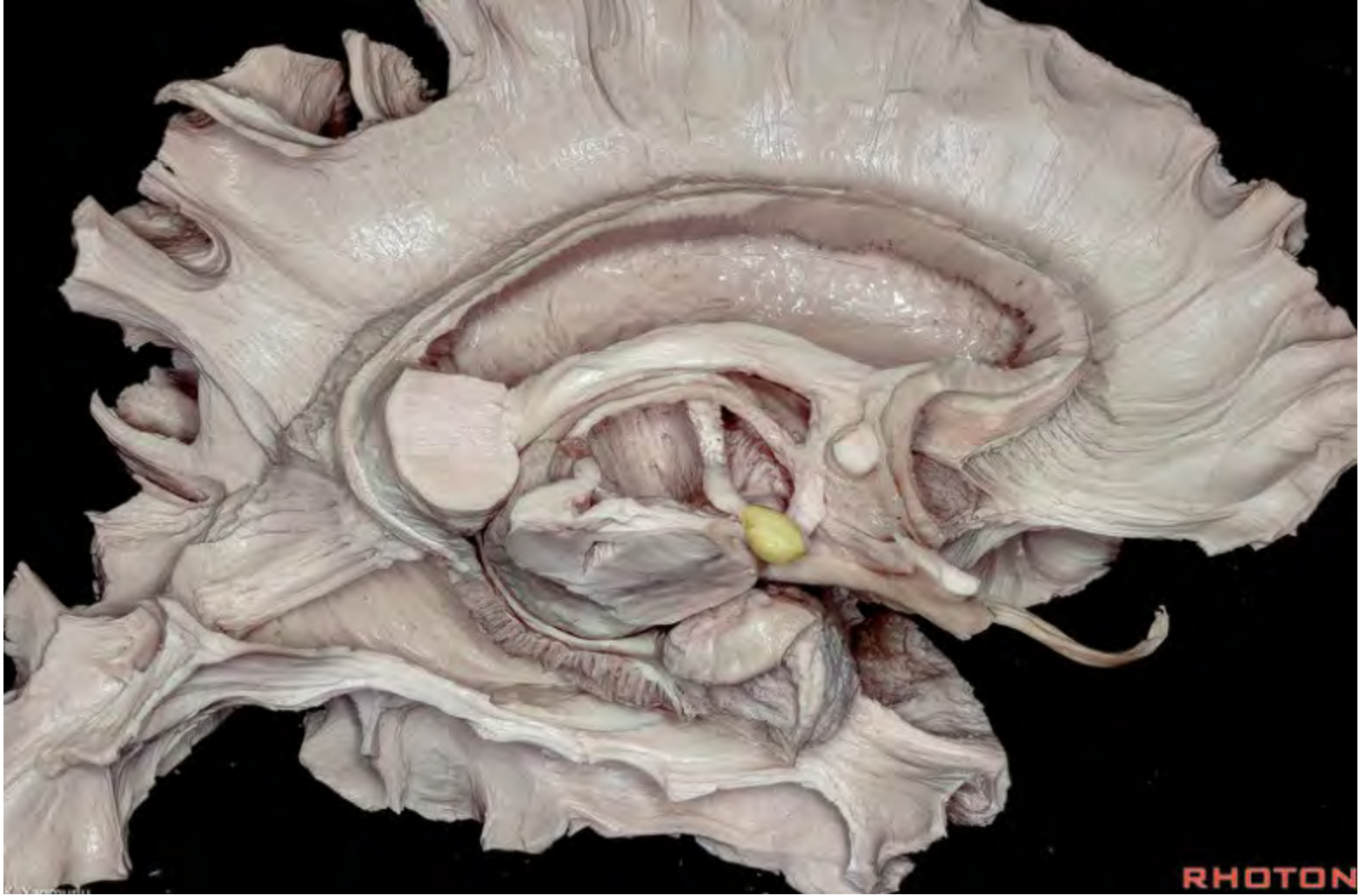


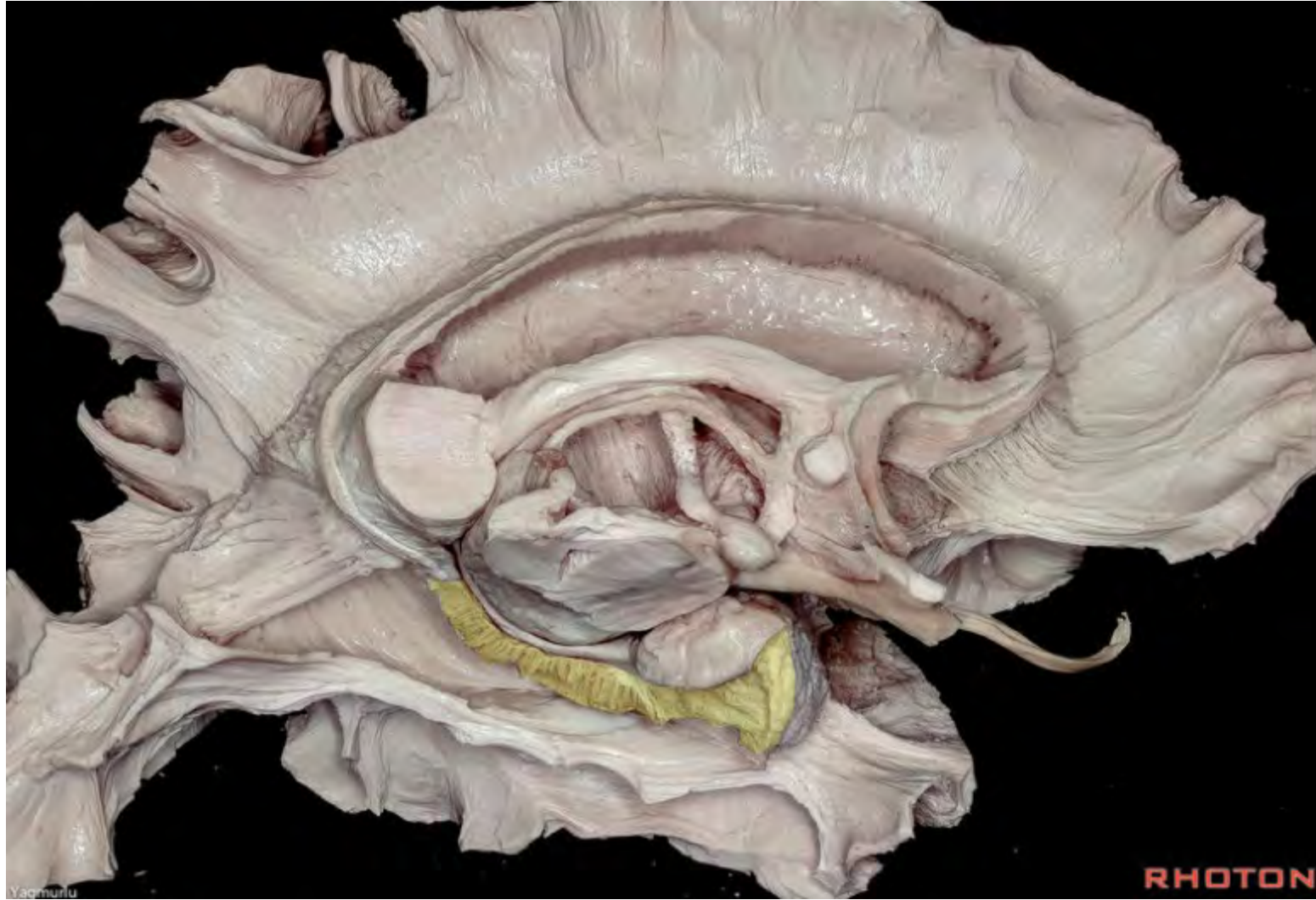




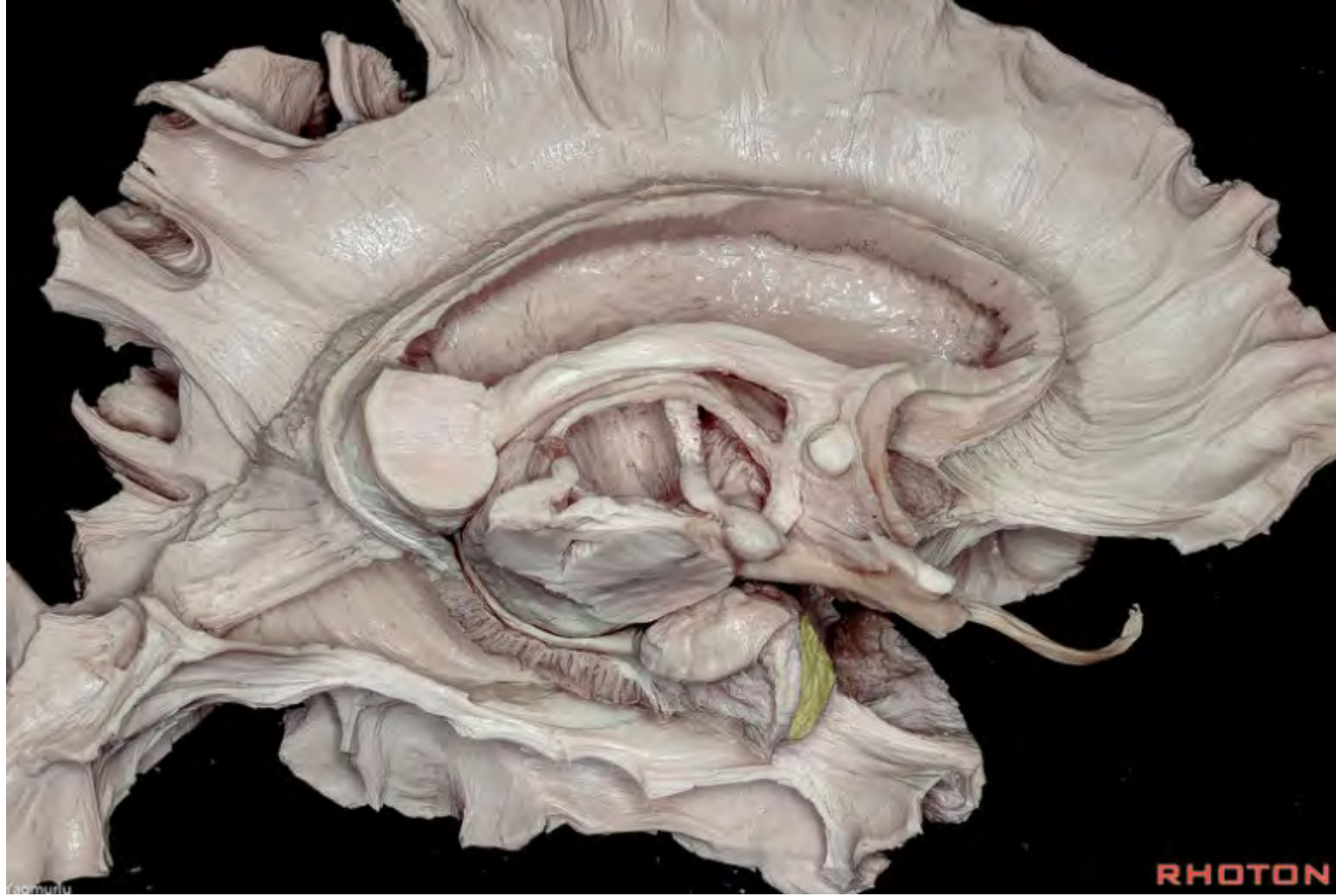


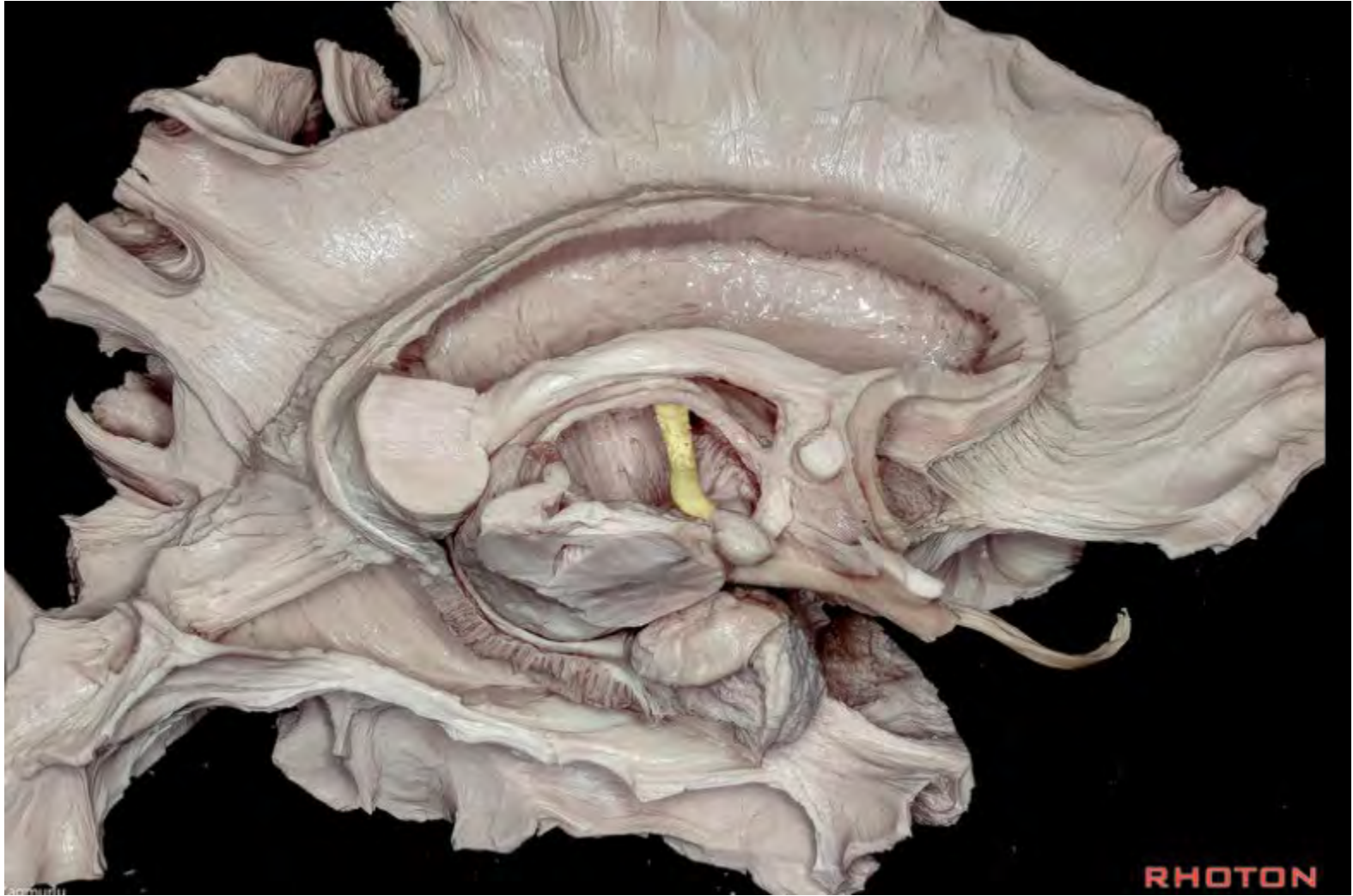


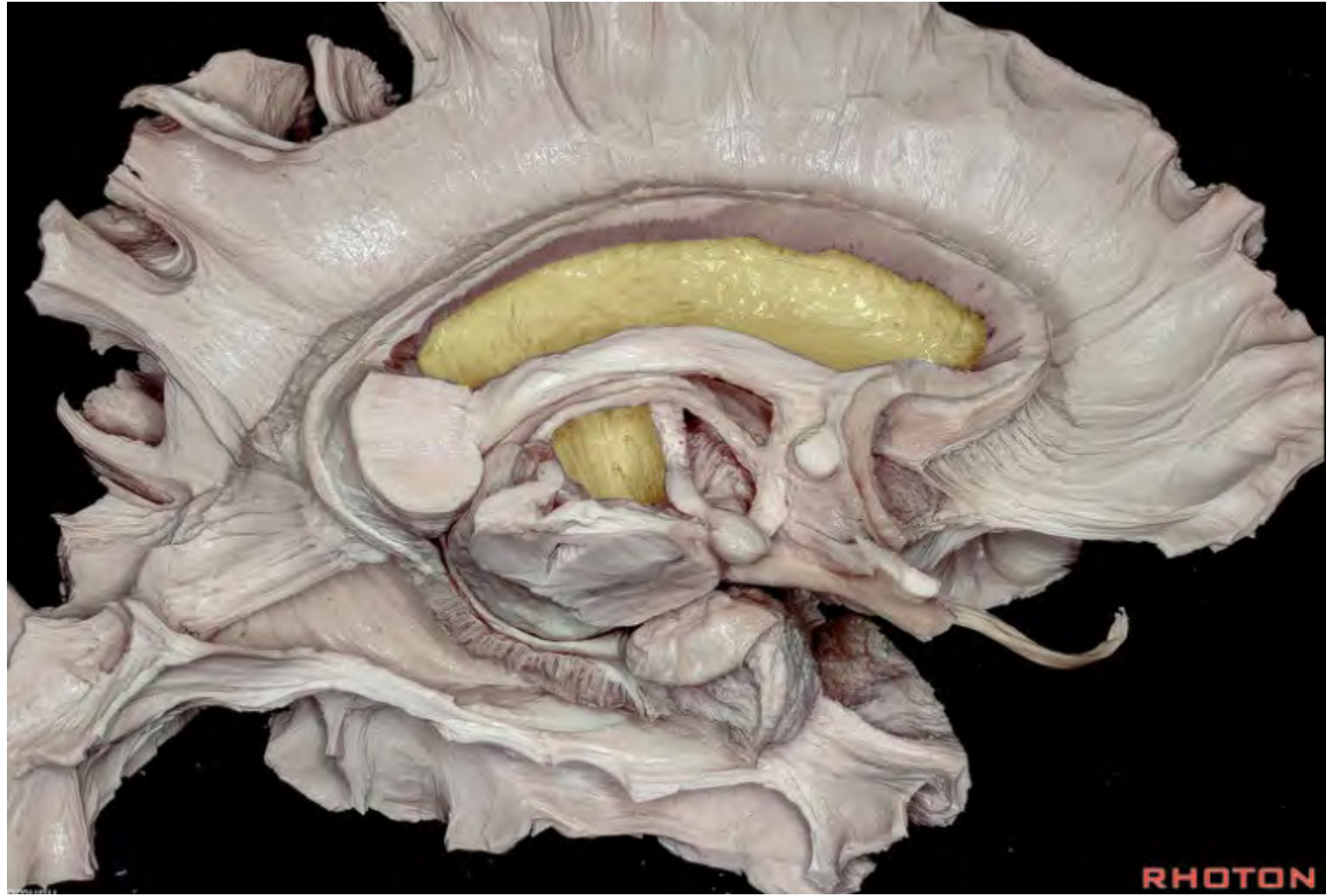

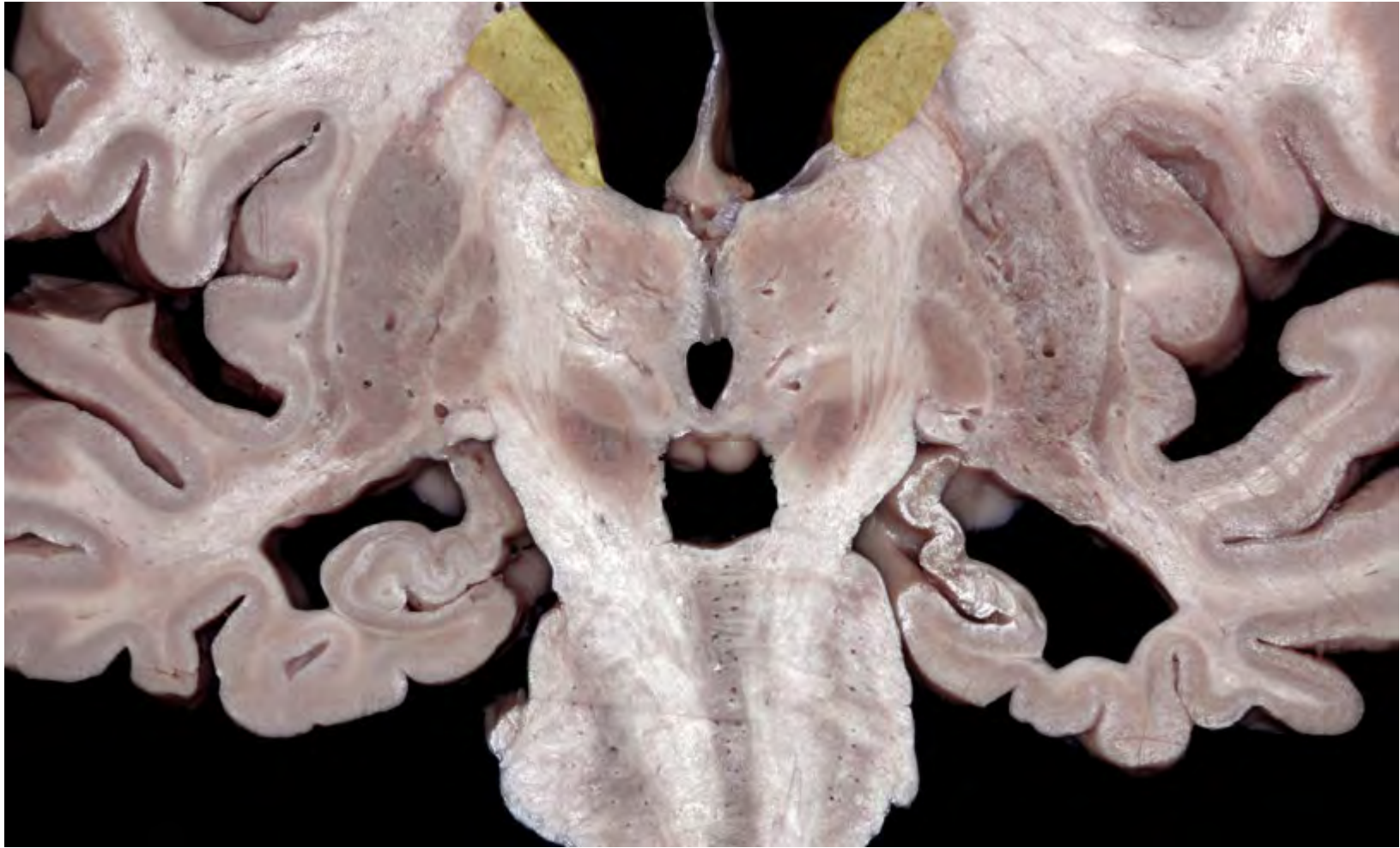


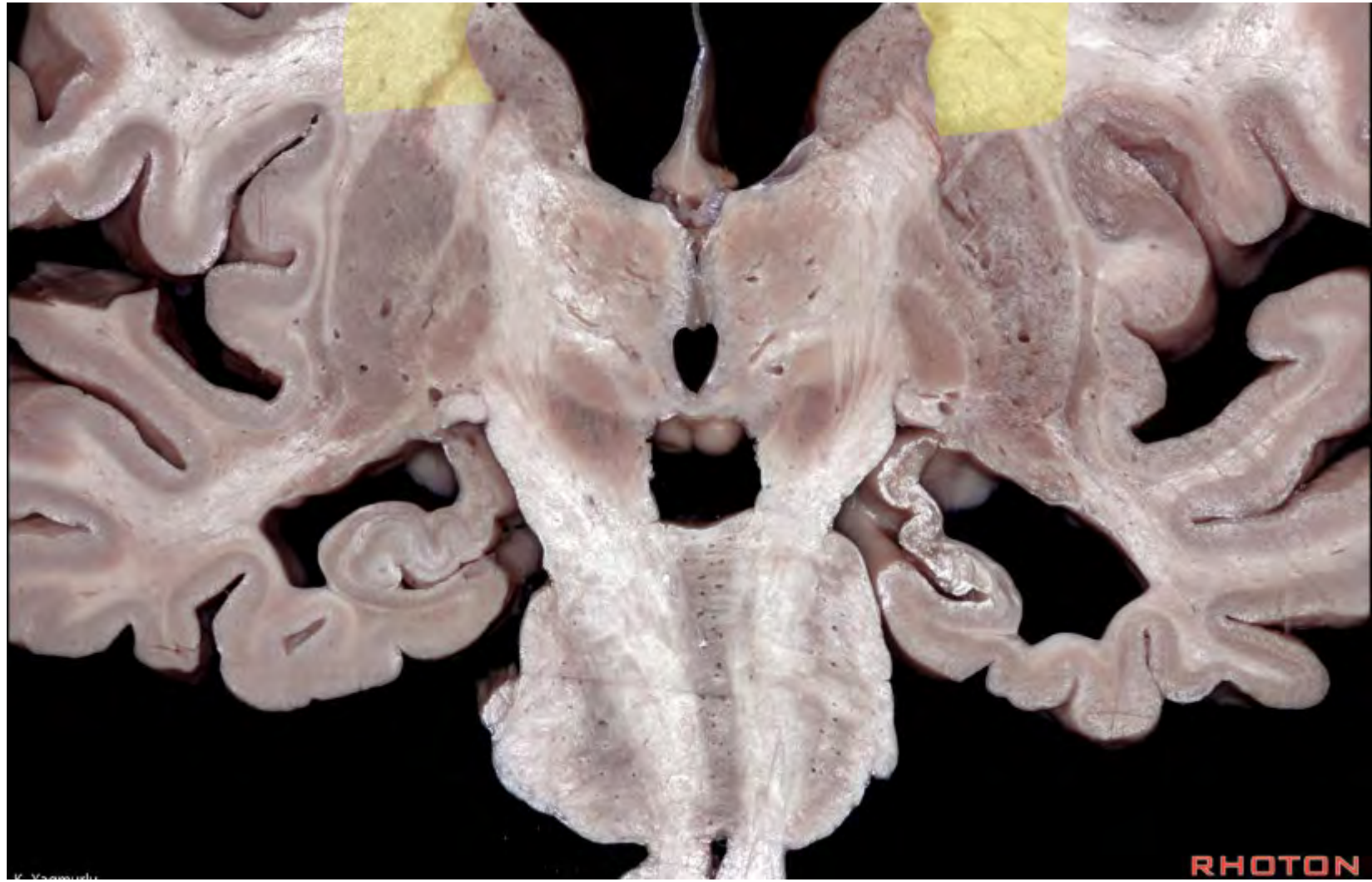


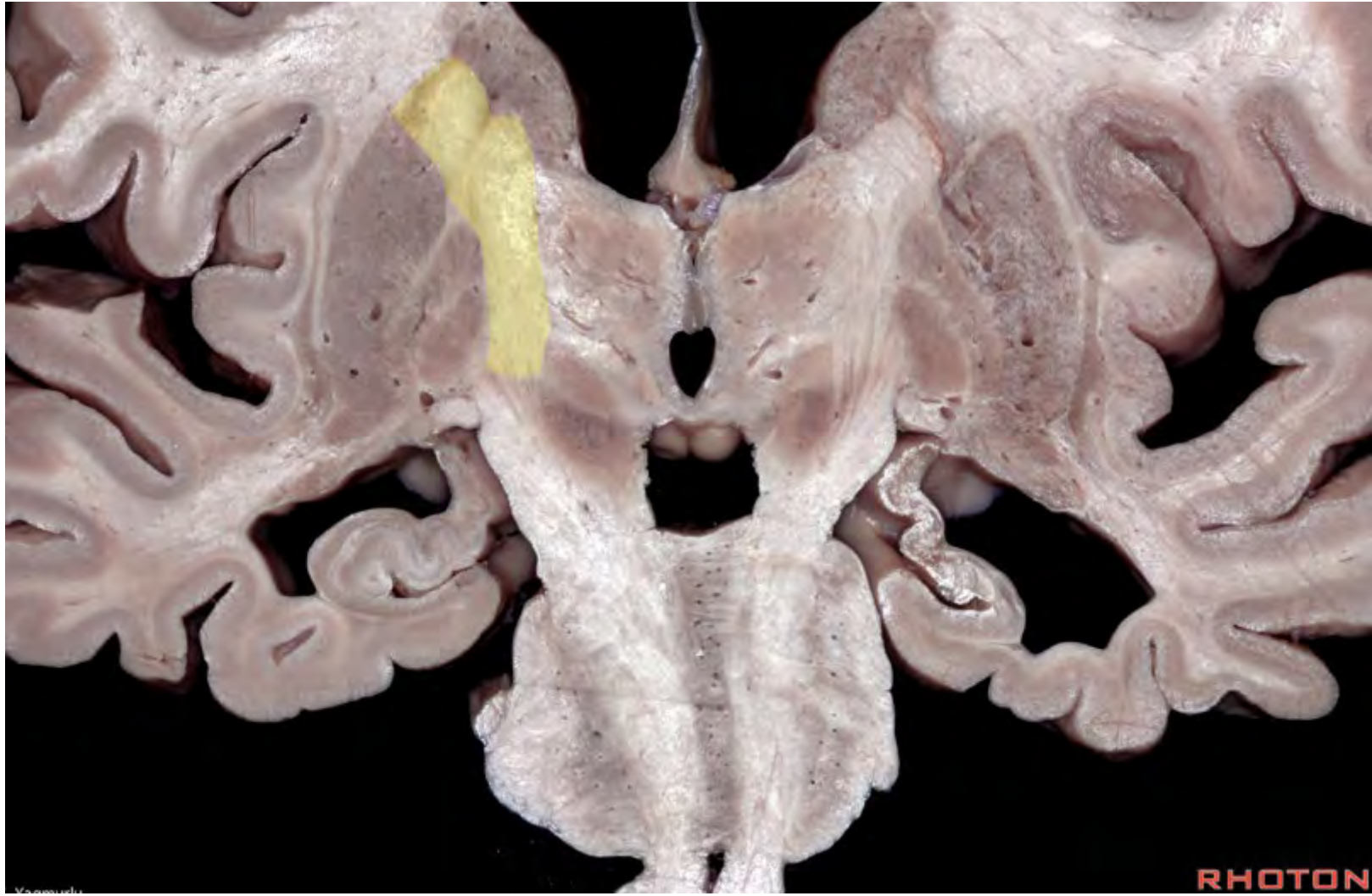



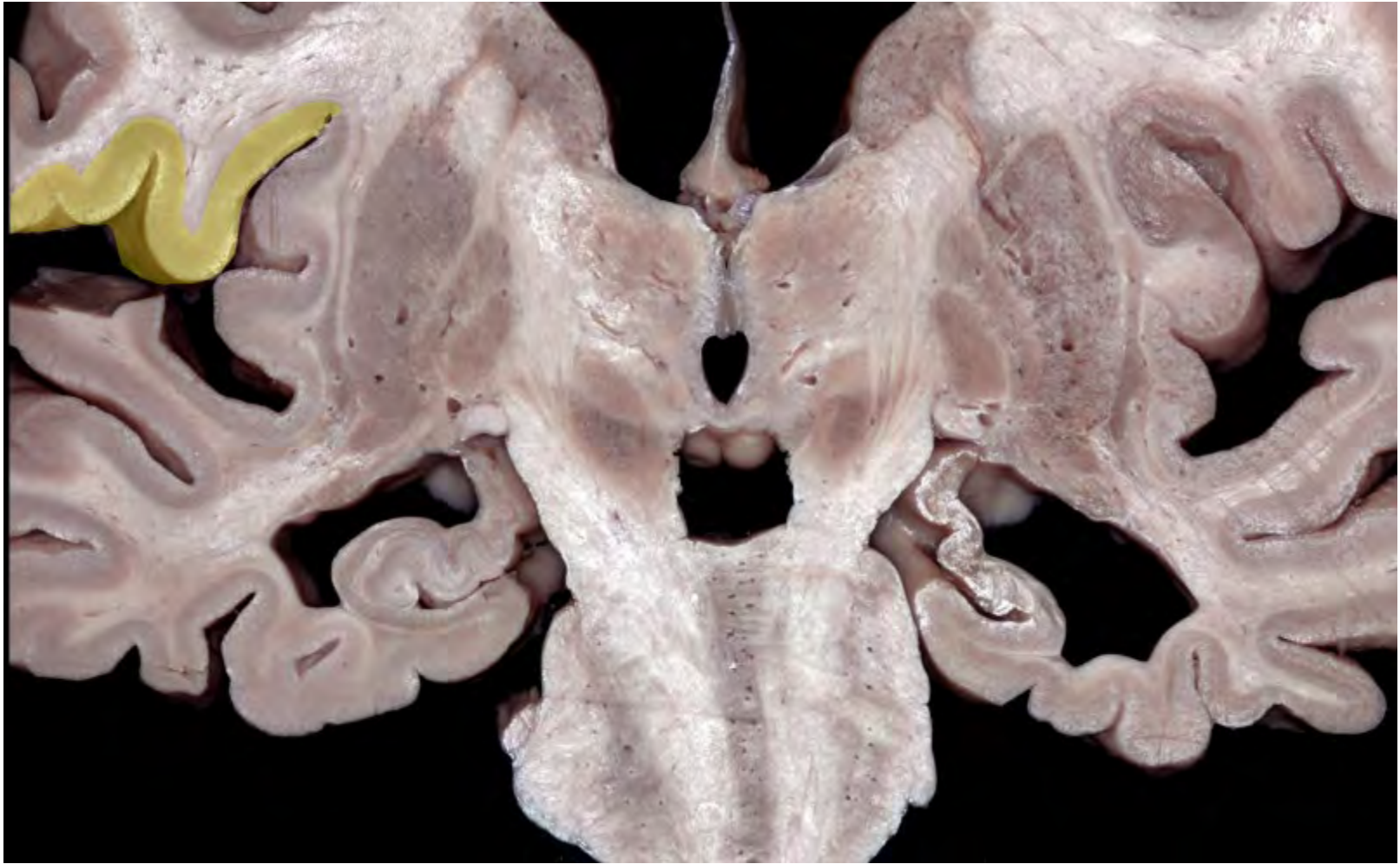
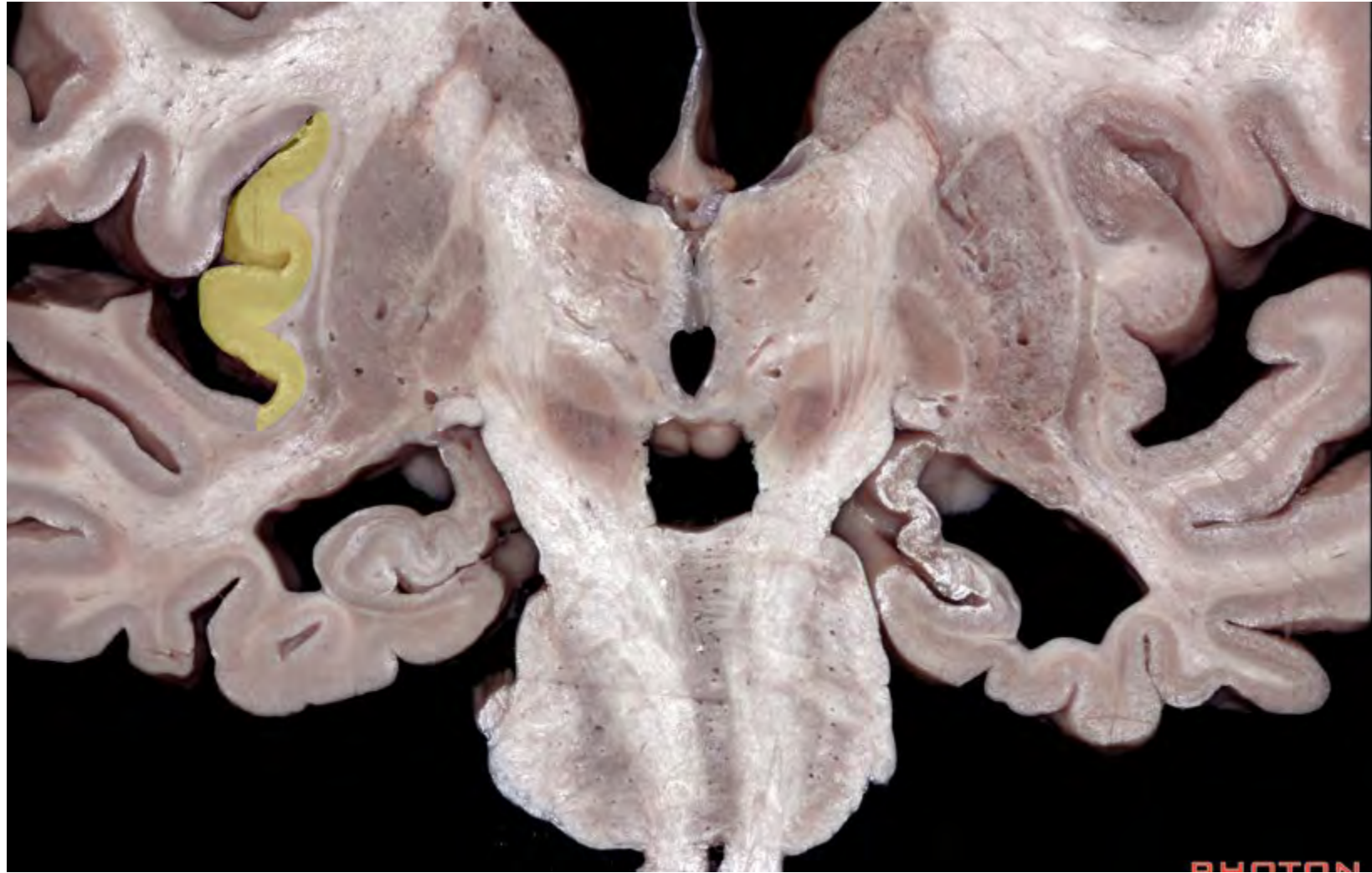




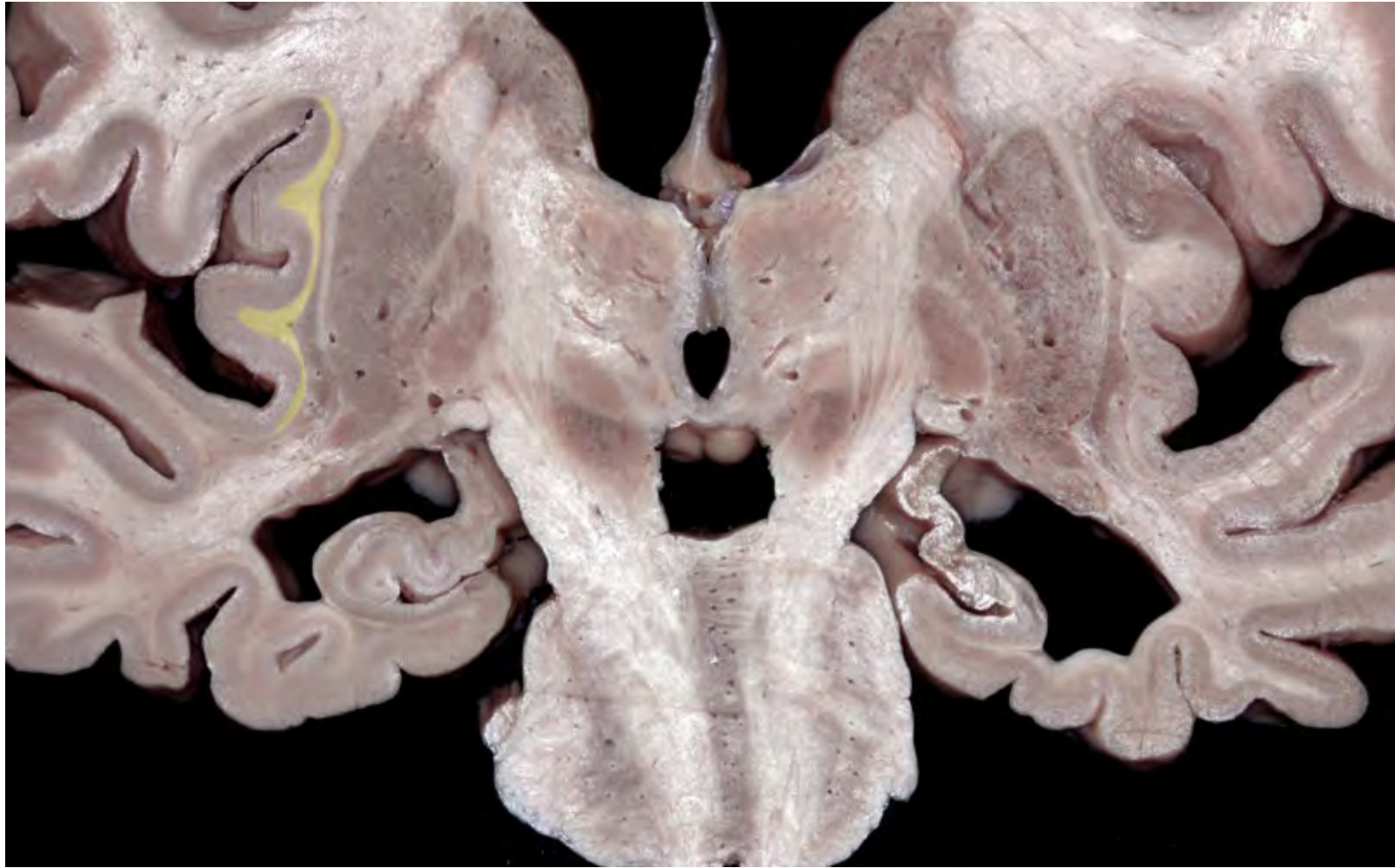


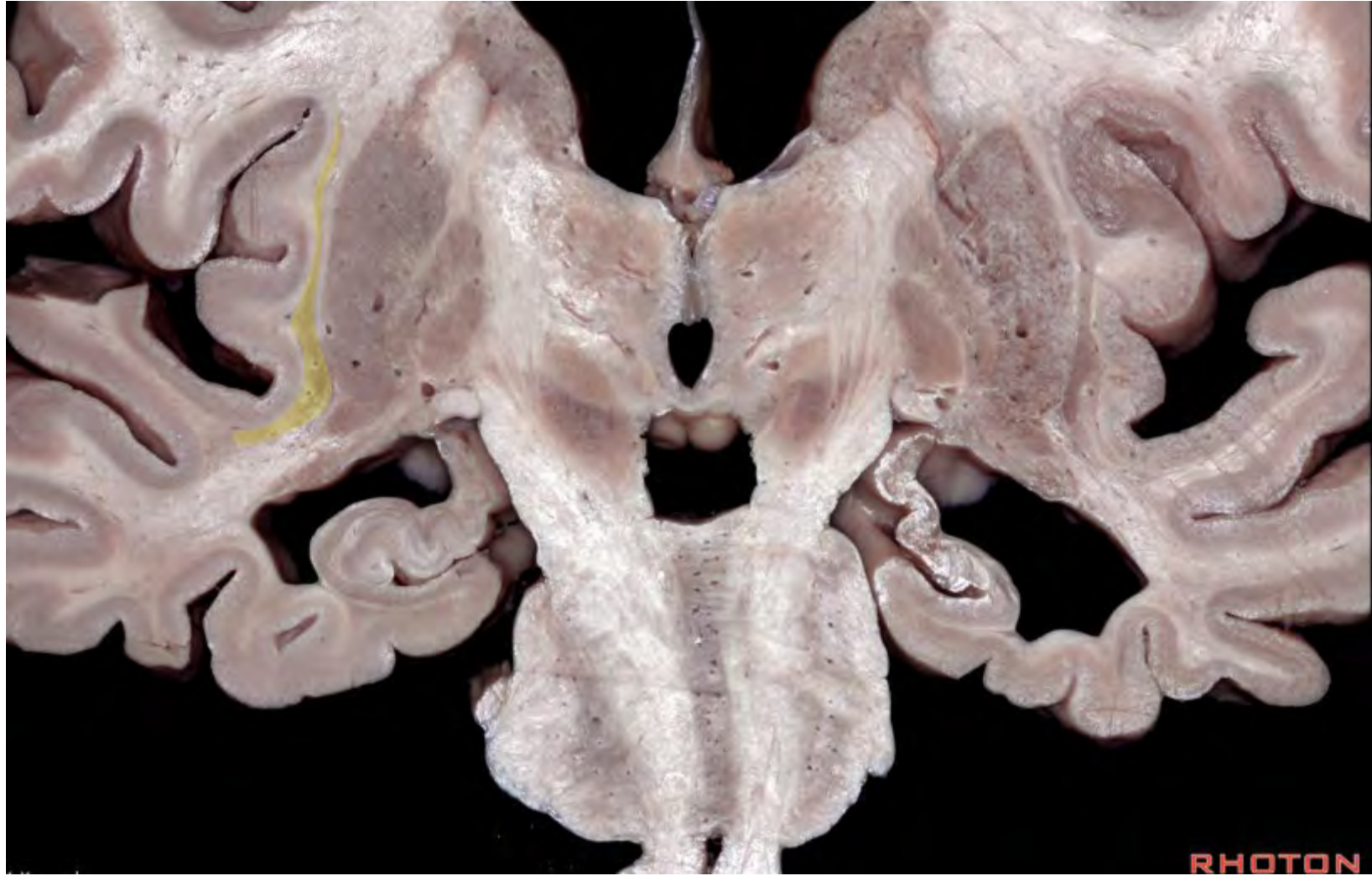




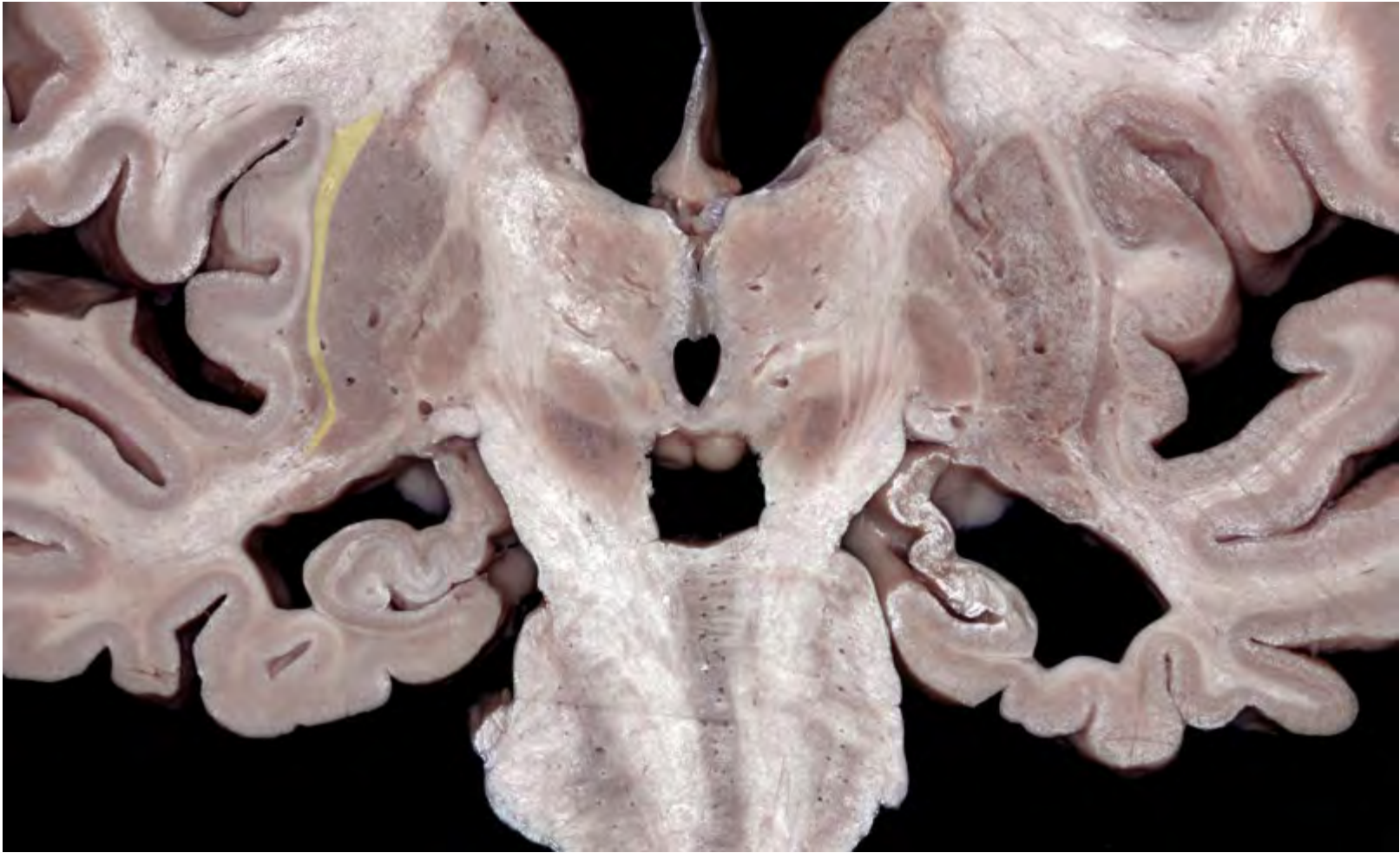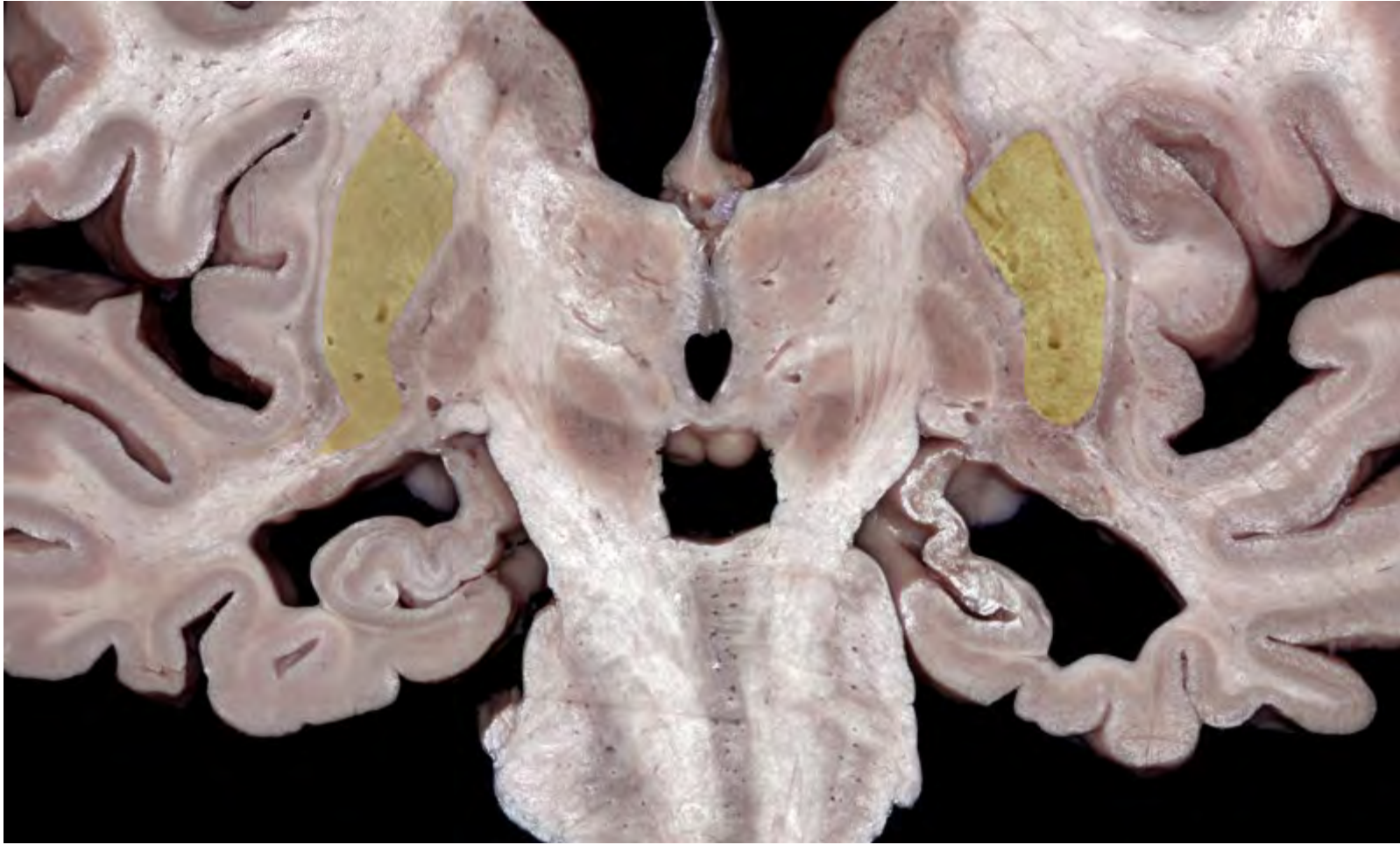


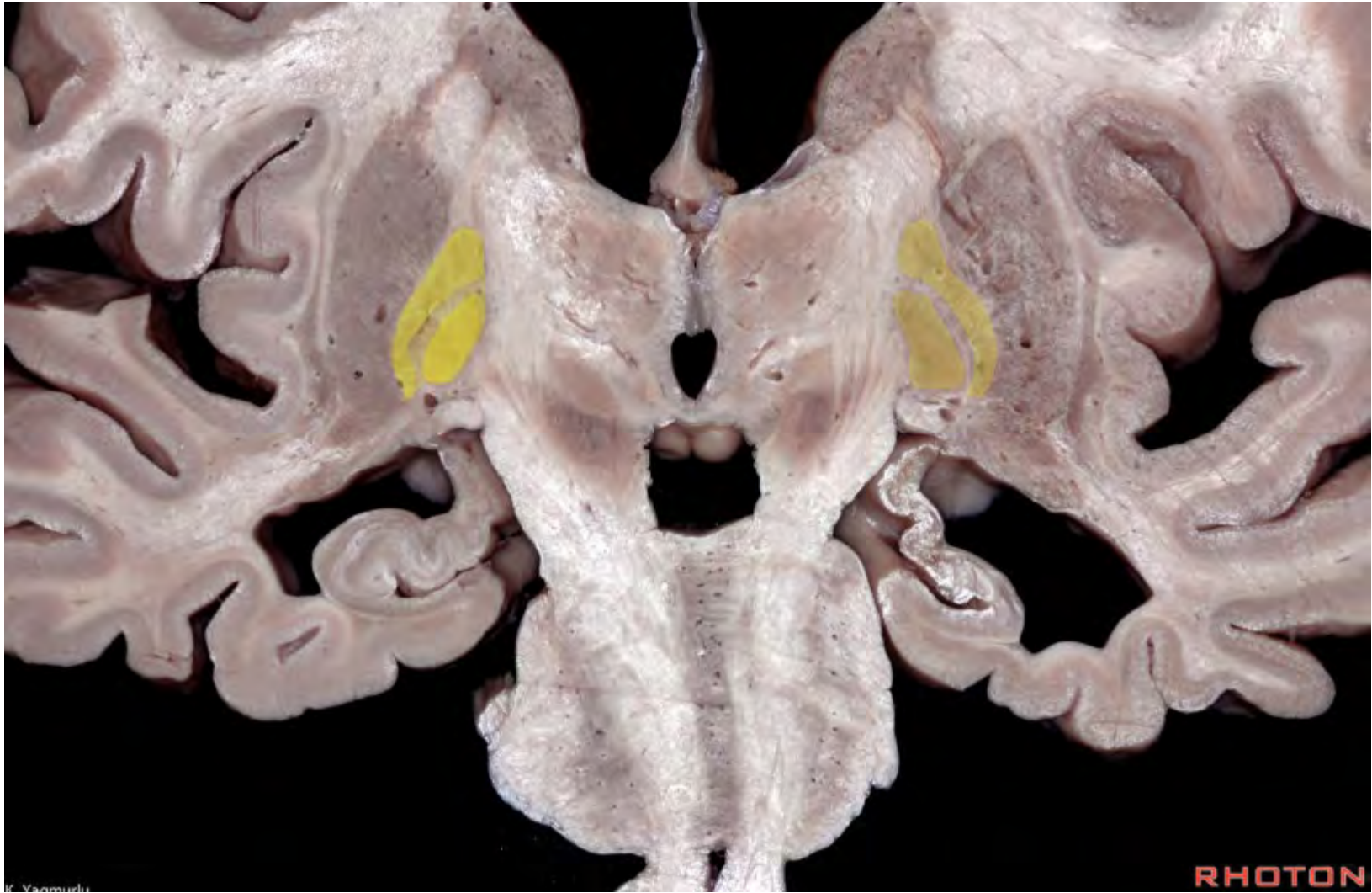


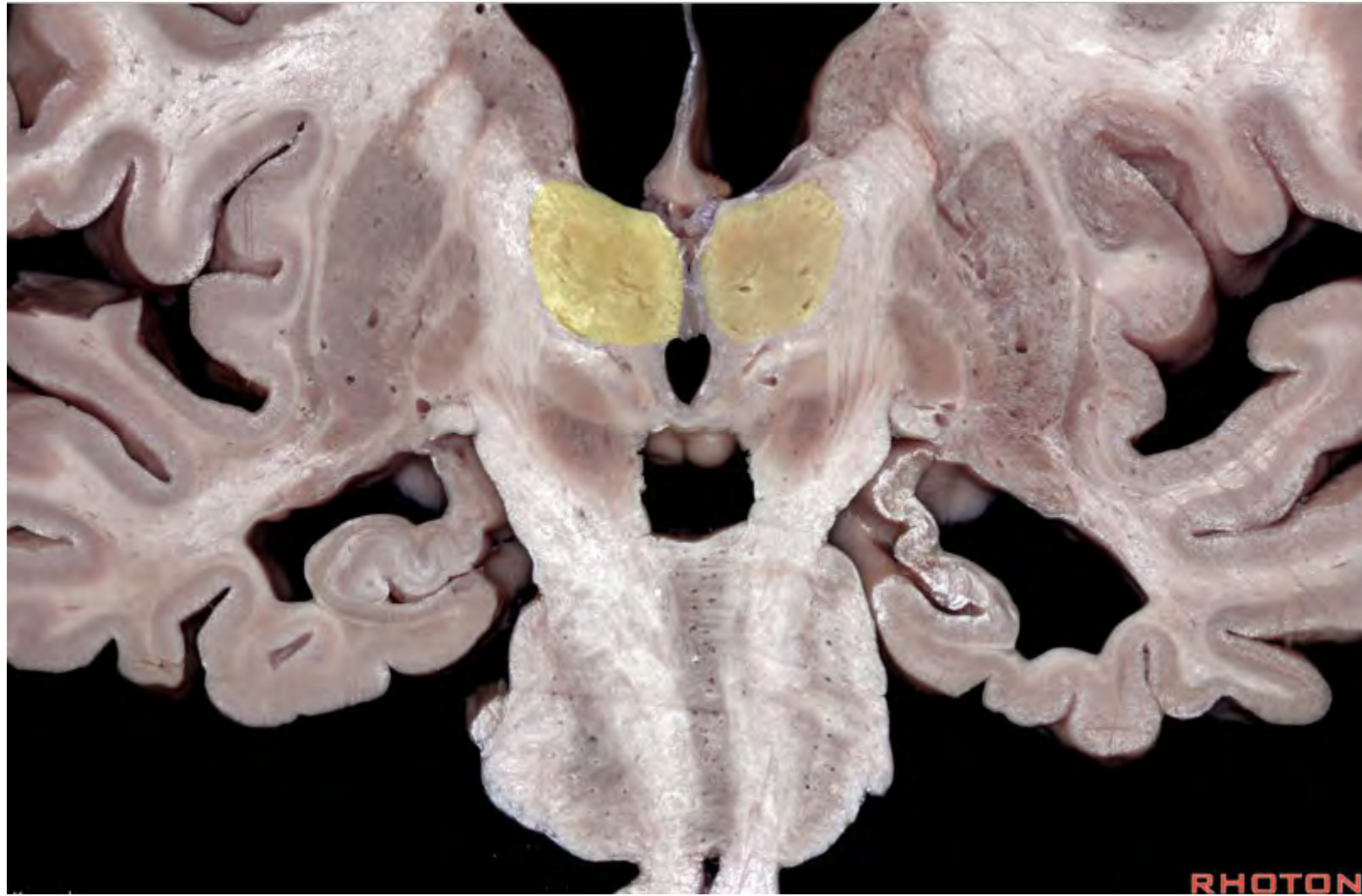


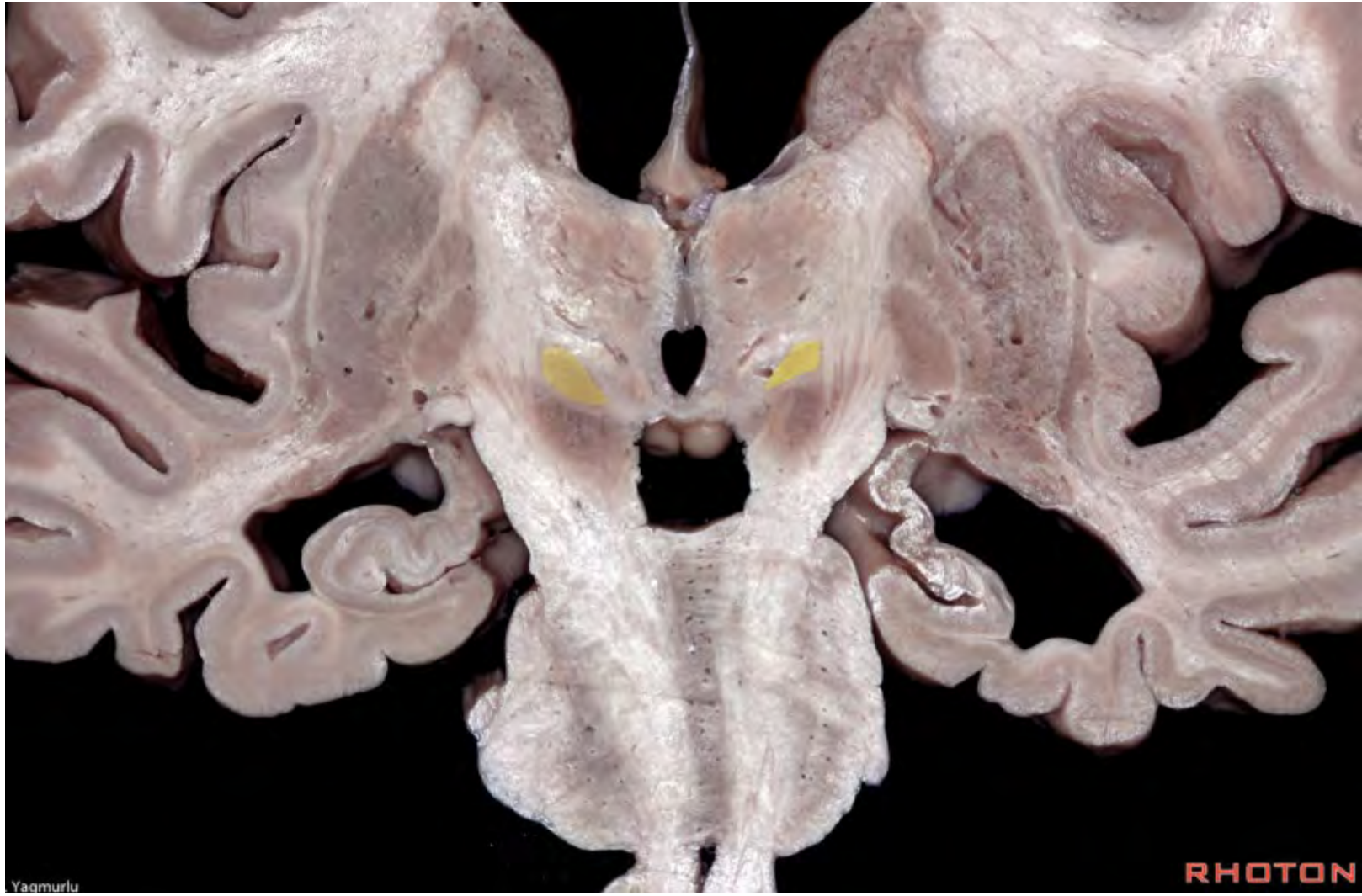


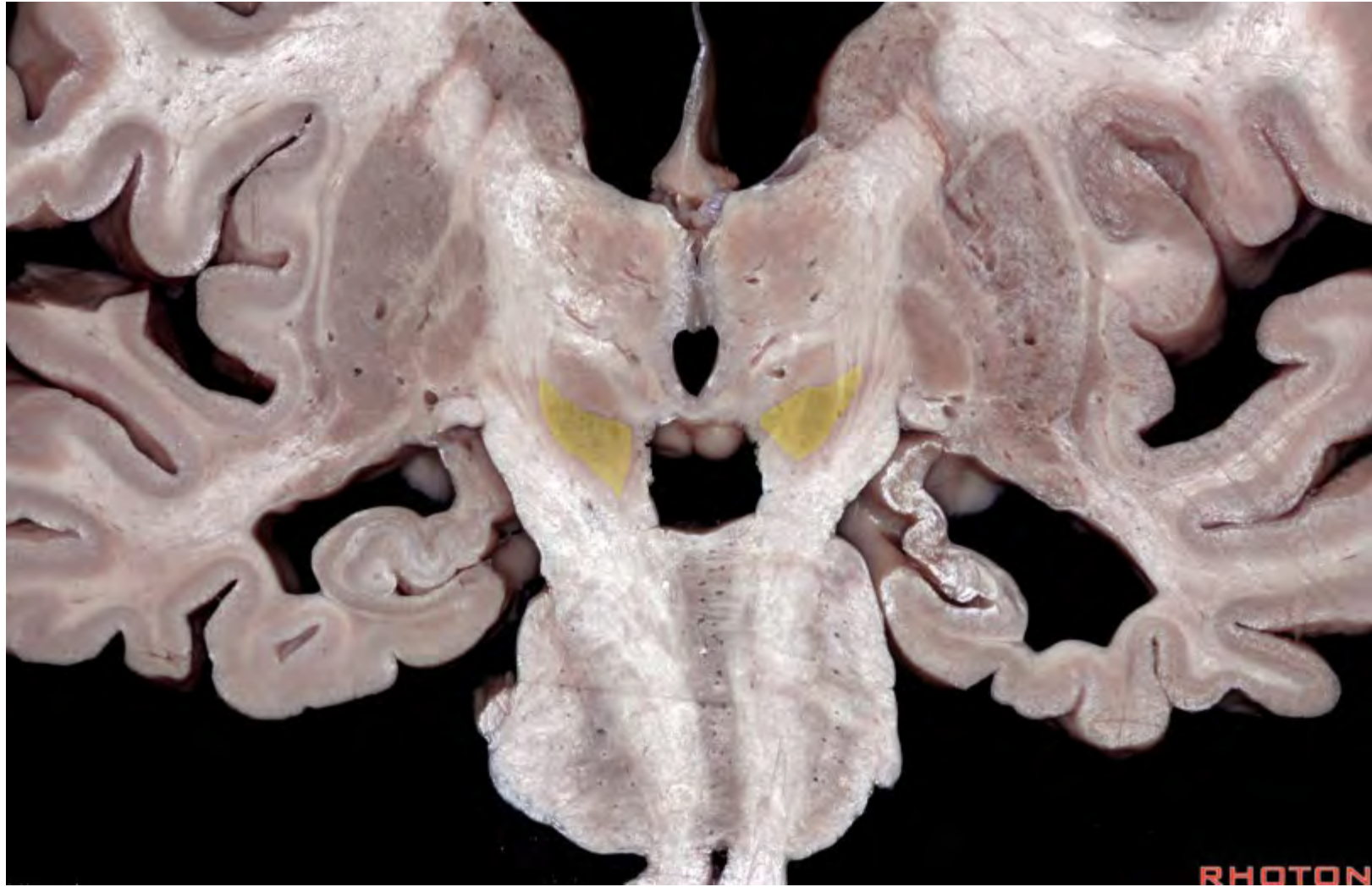




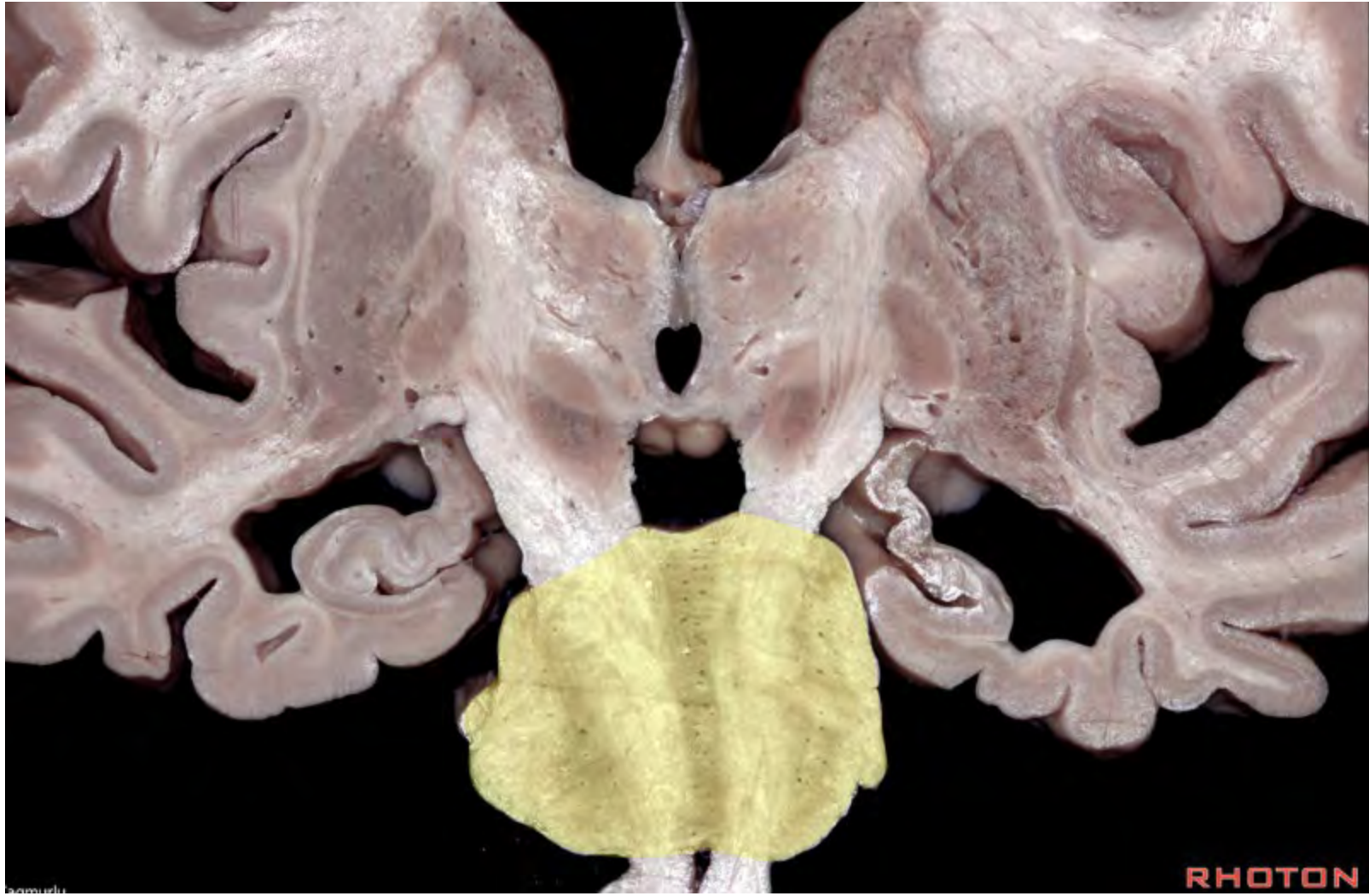


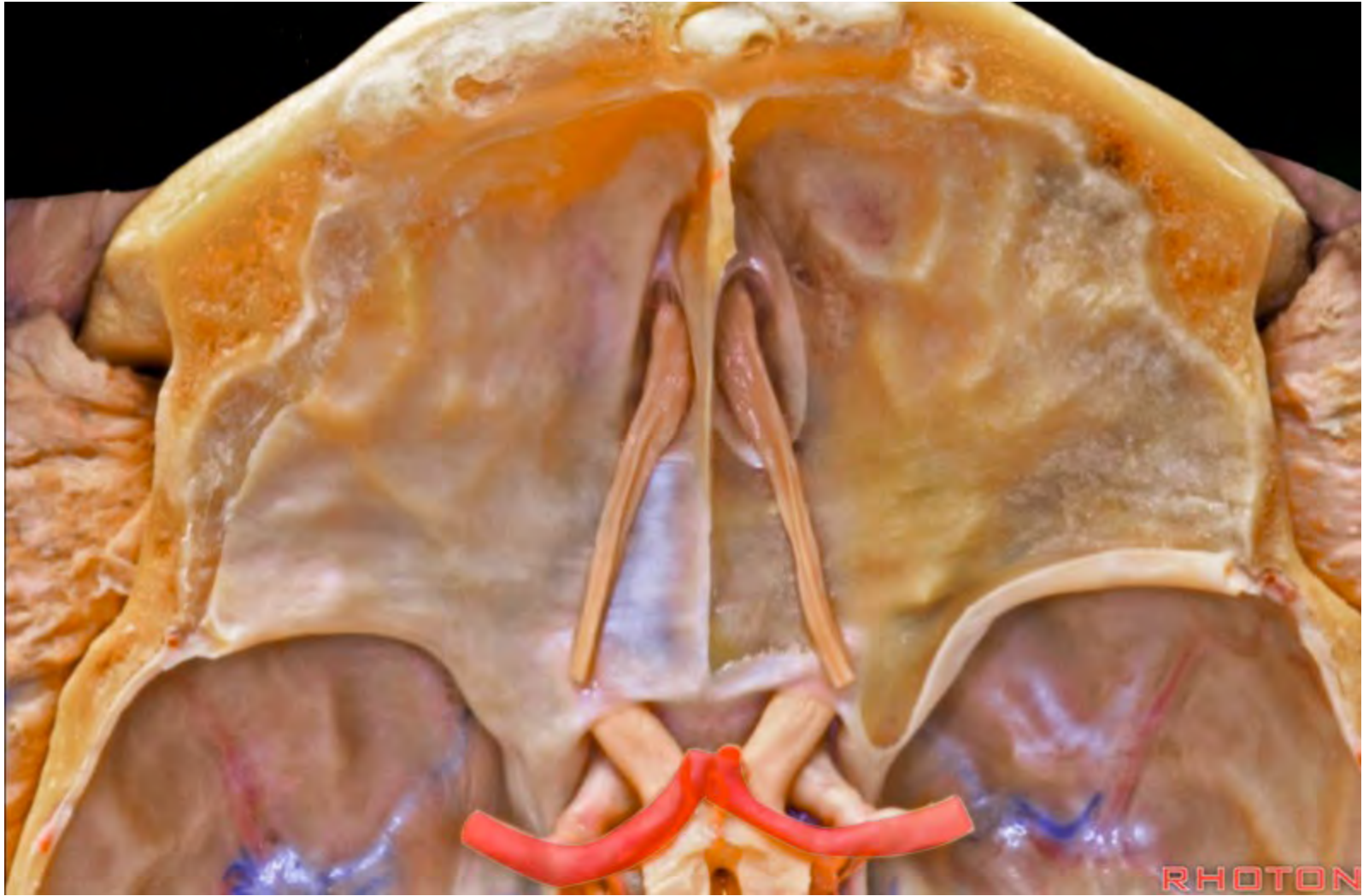




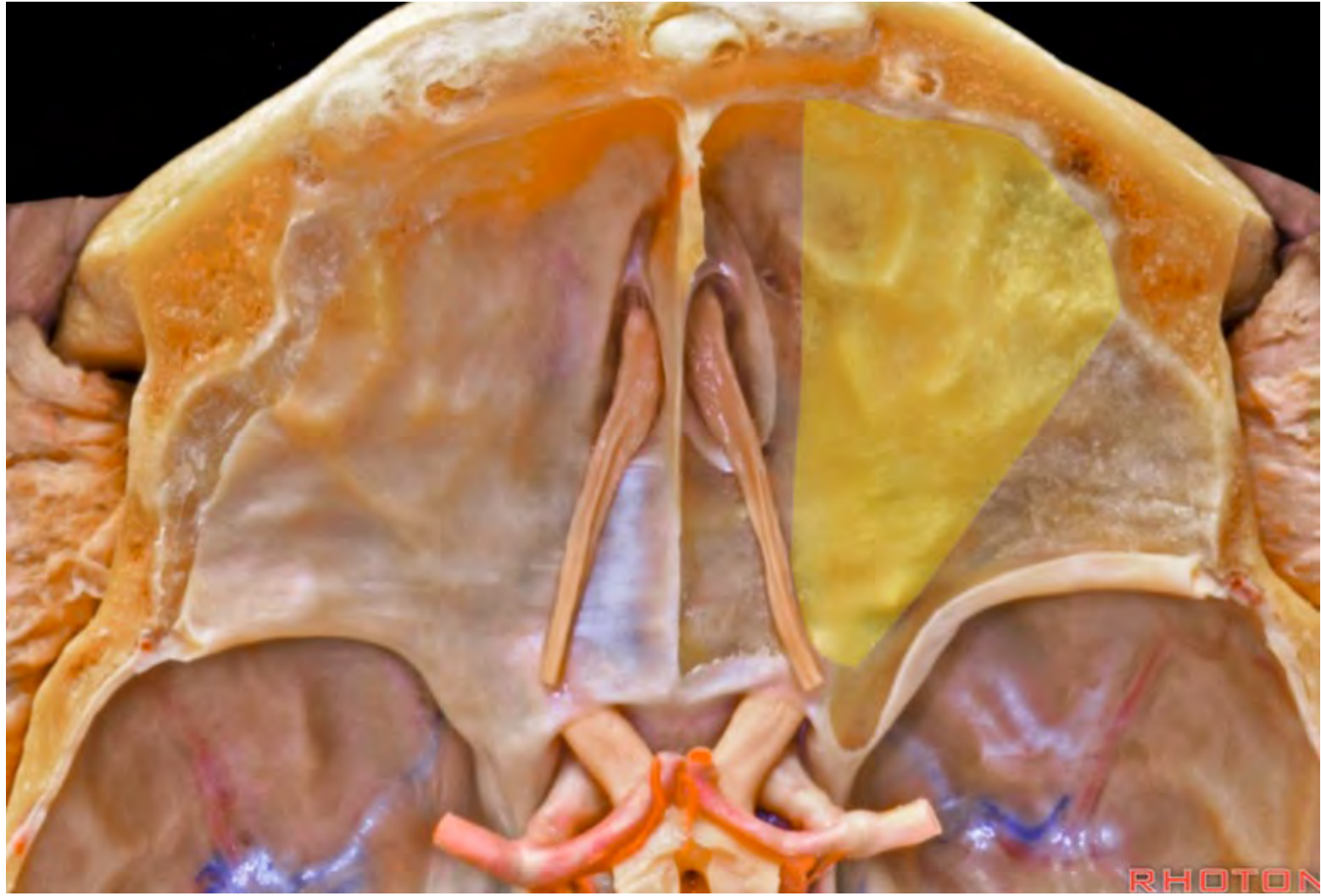


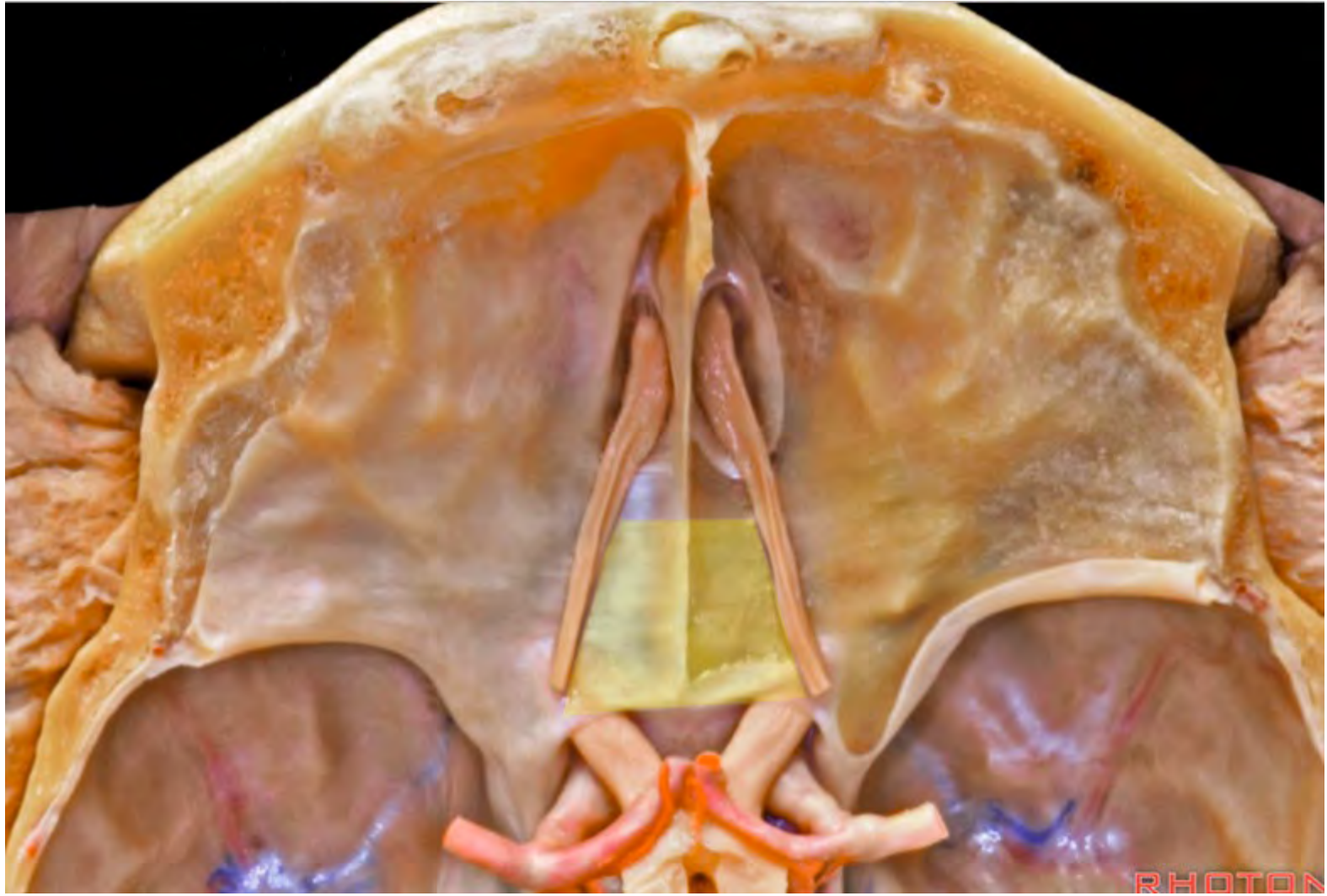


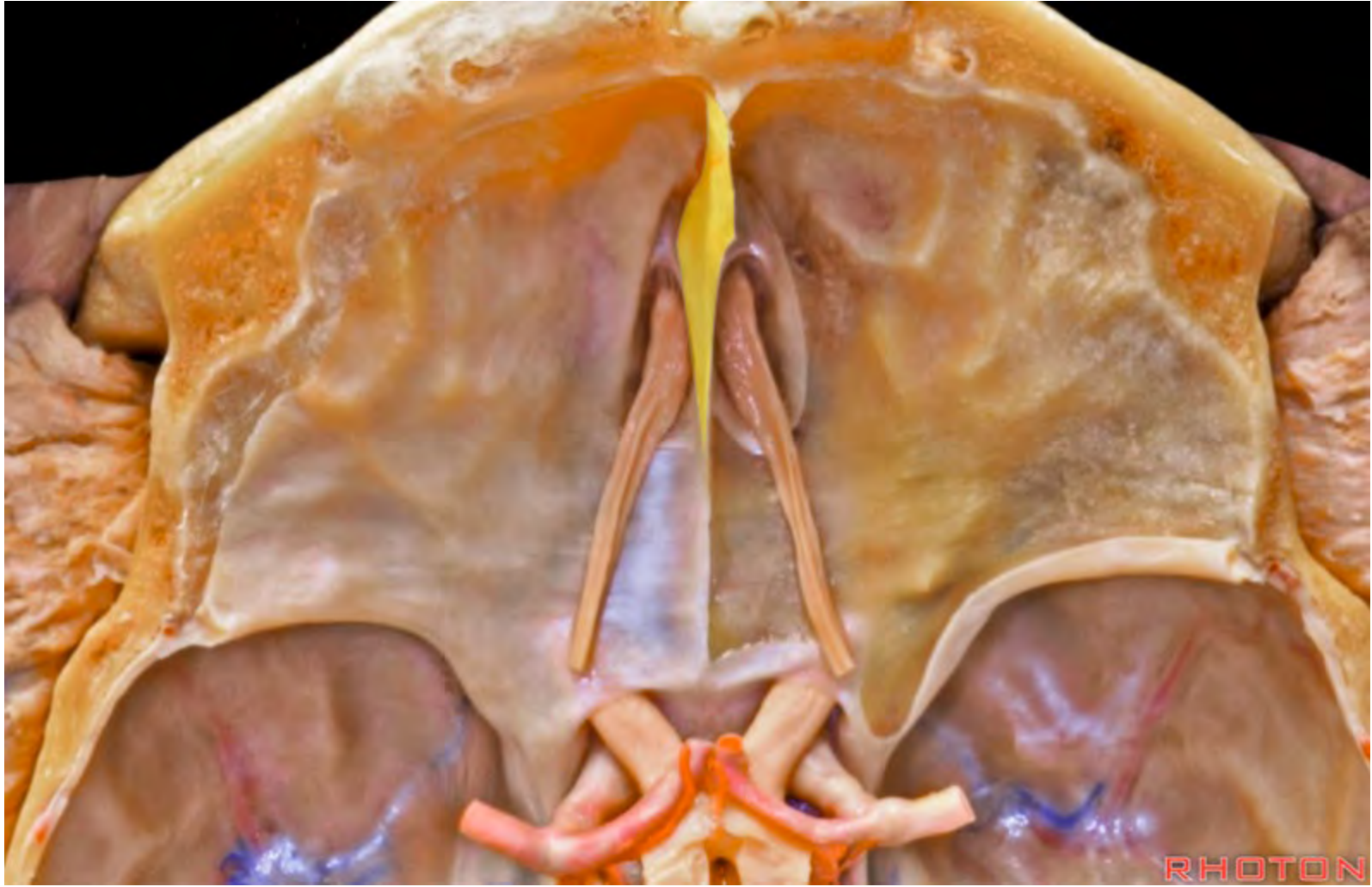




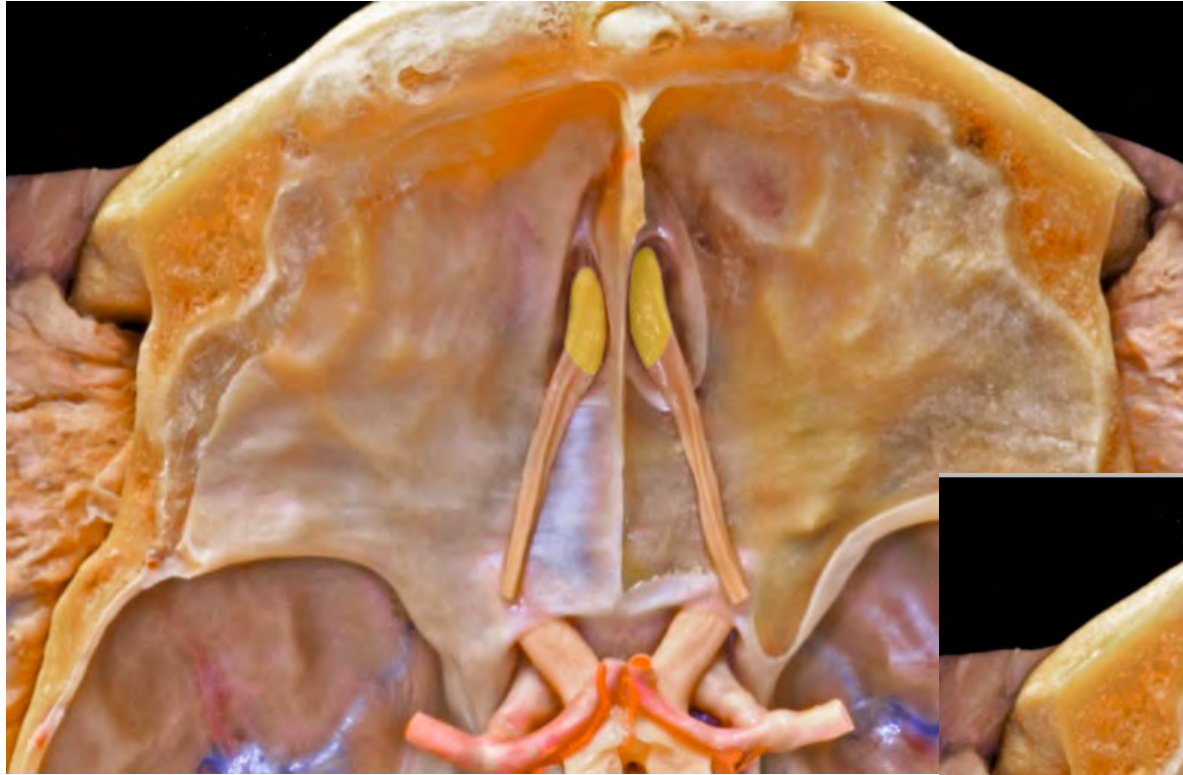







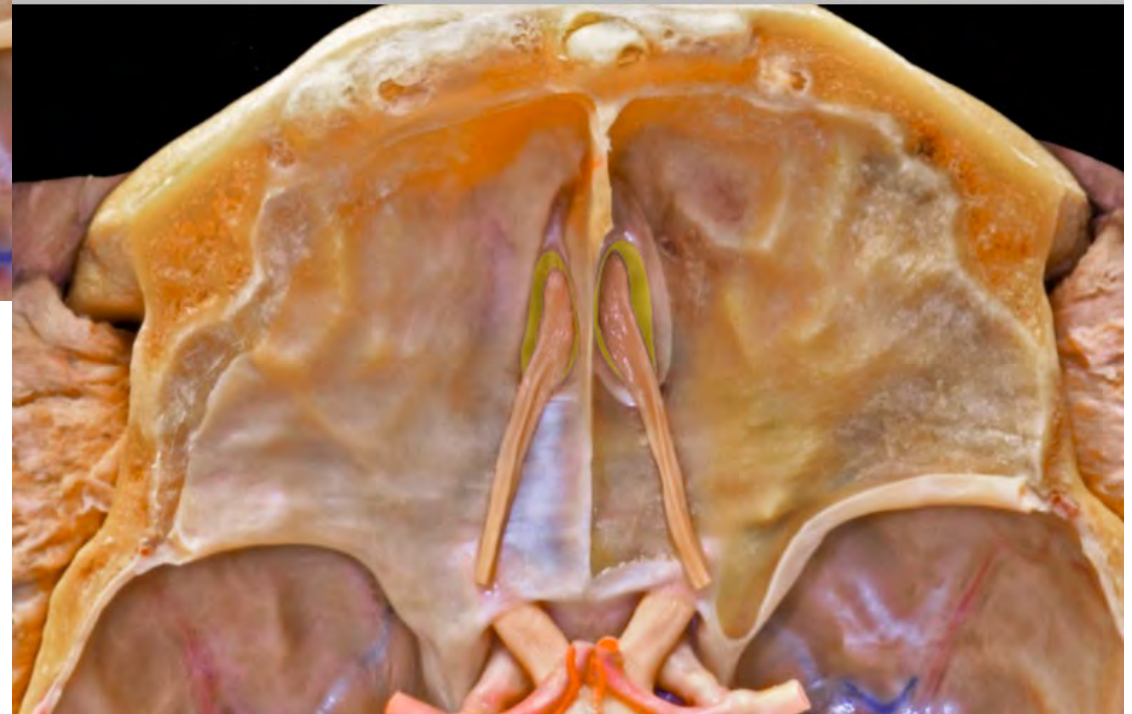
**Olfactory bulb**

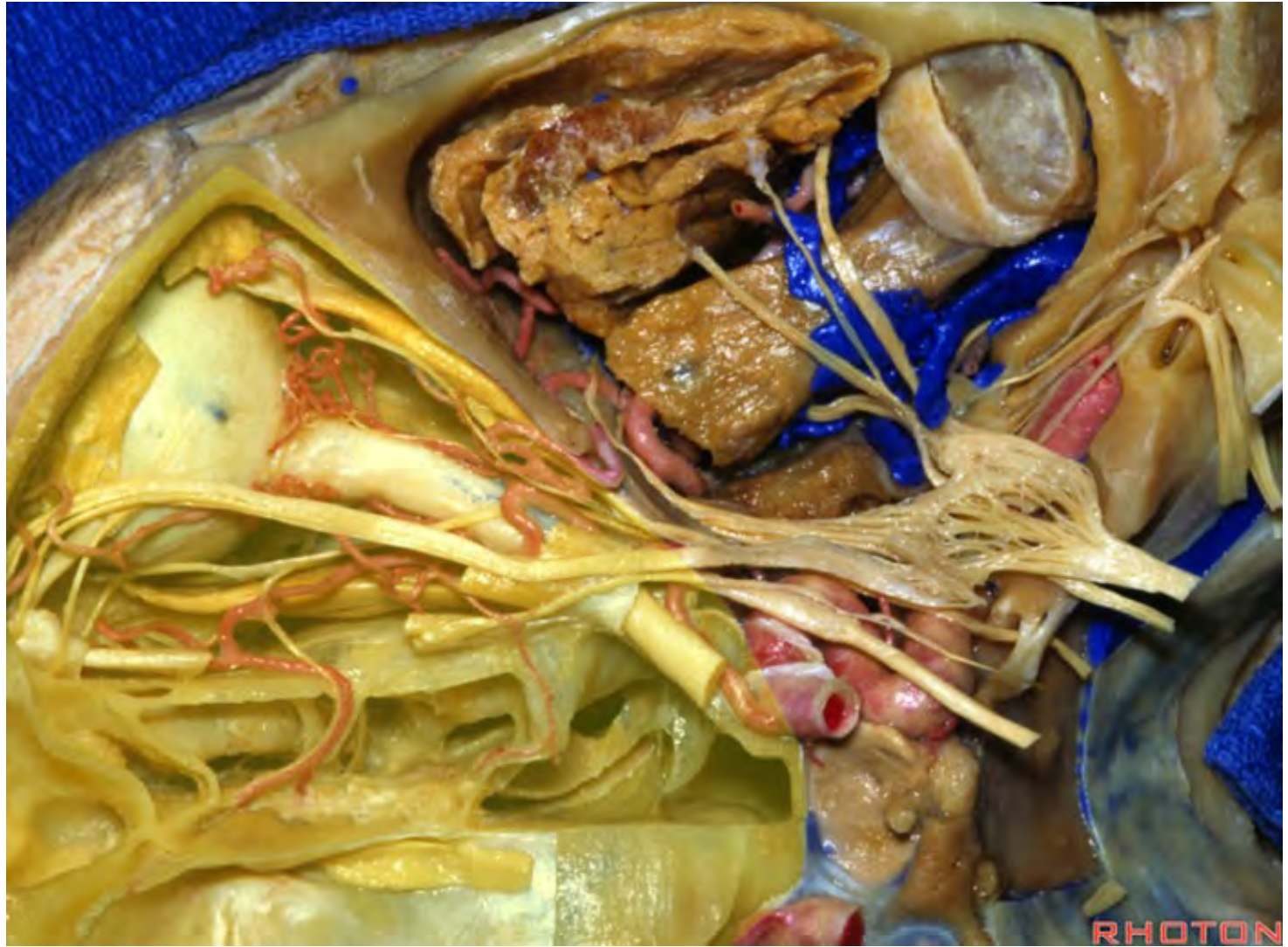


**Olfactory groove**

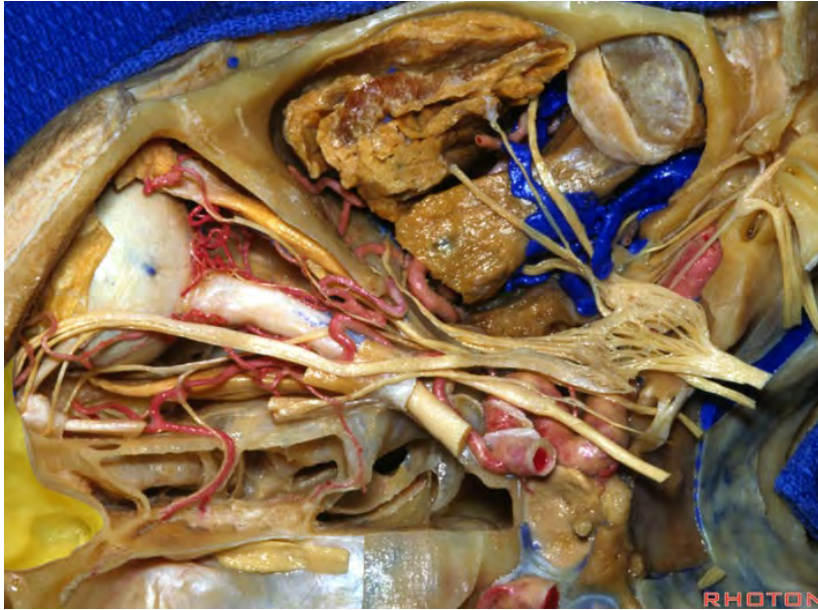




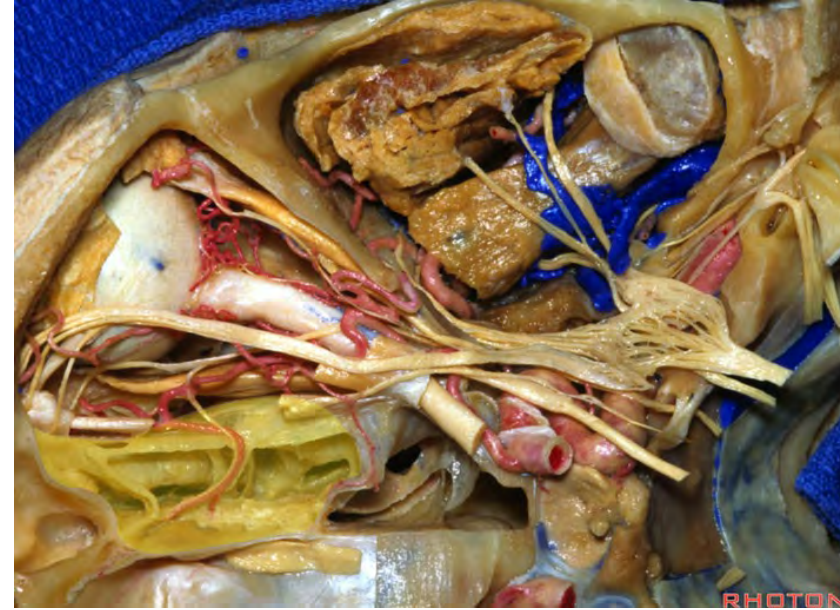




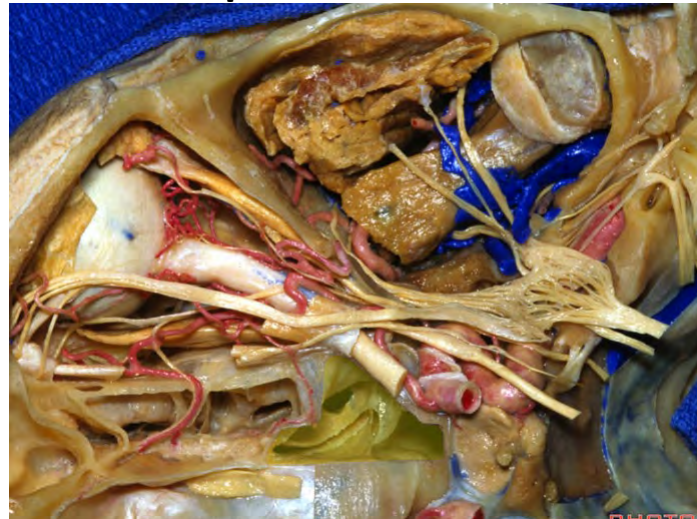**Frontal sinus**



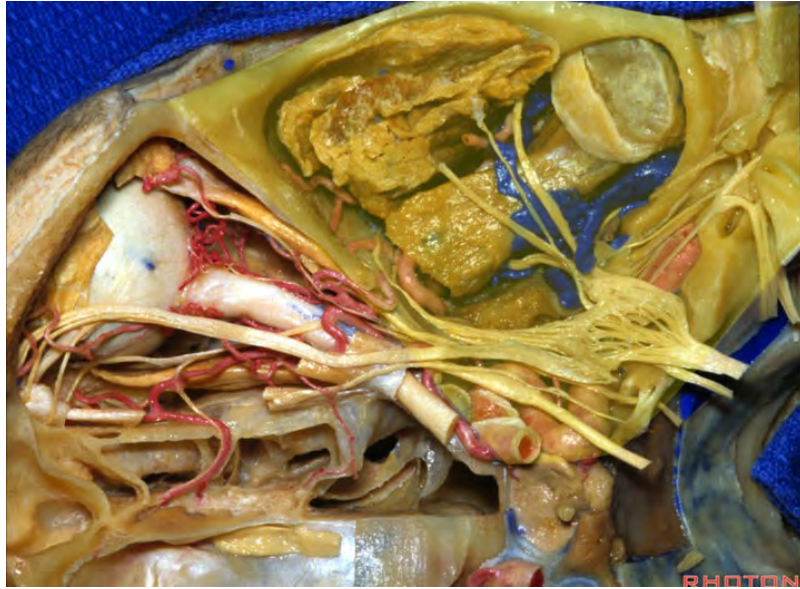
**Ethmoid sinus**



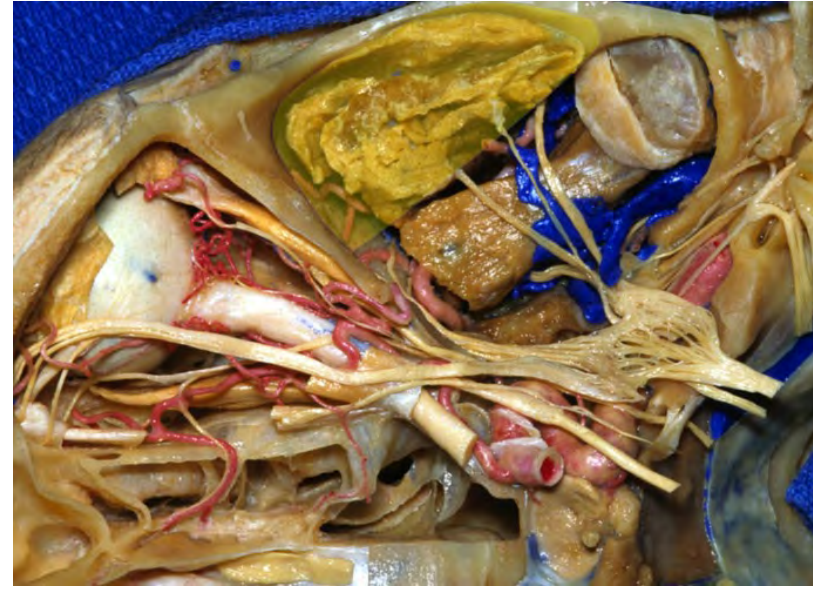**Sphenoid sinus**



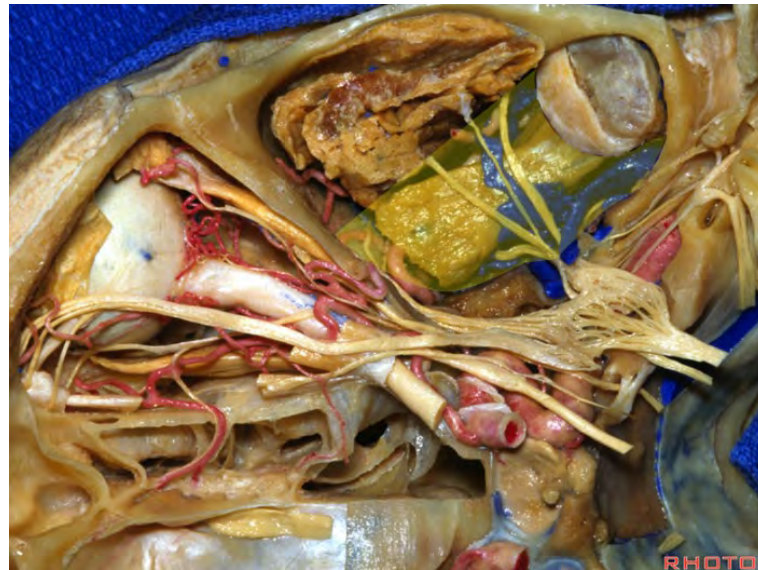**Middle fossa**



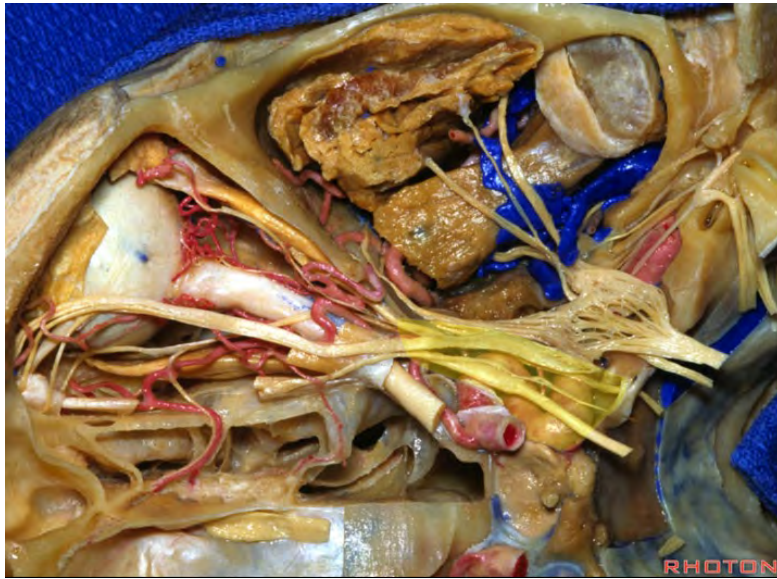**Temporal fossa**



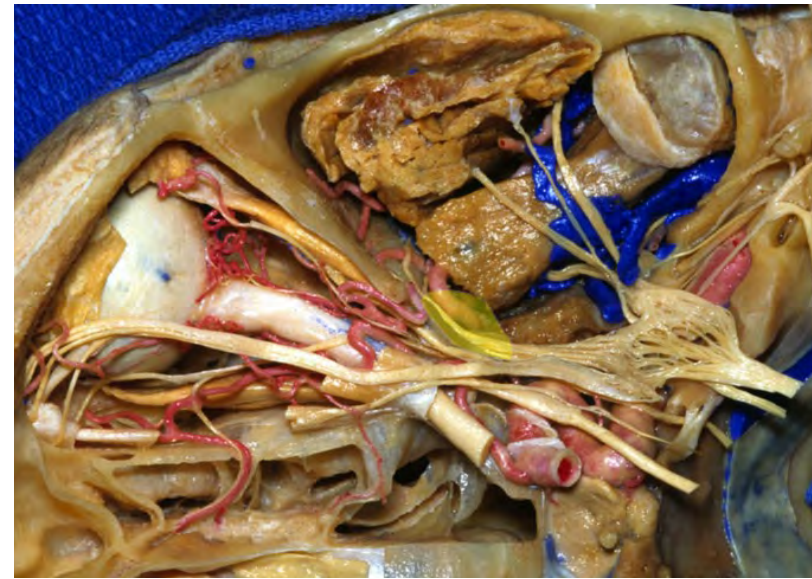
**Infratemporal fossa**



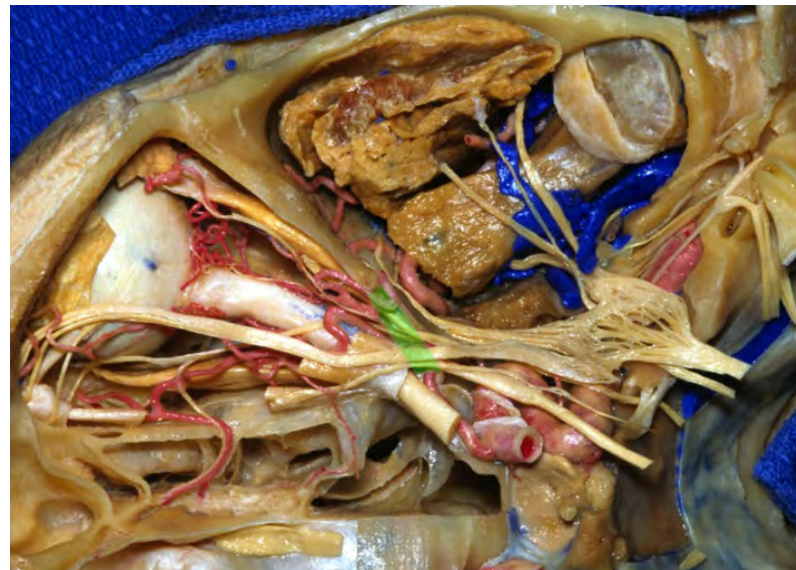**Cavernous sinus**

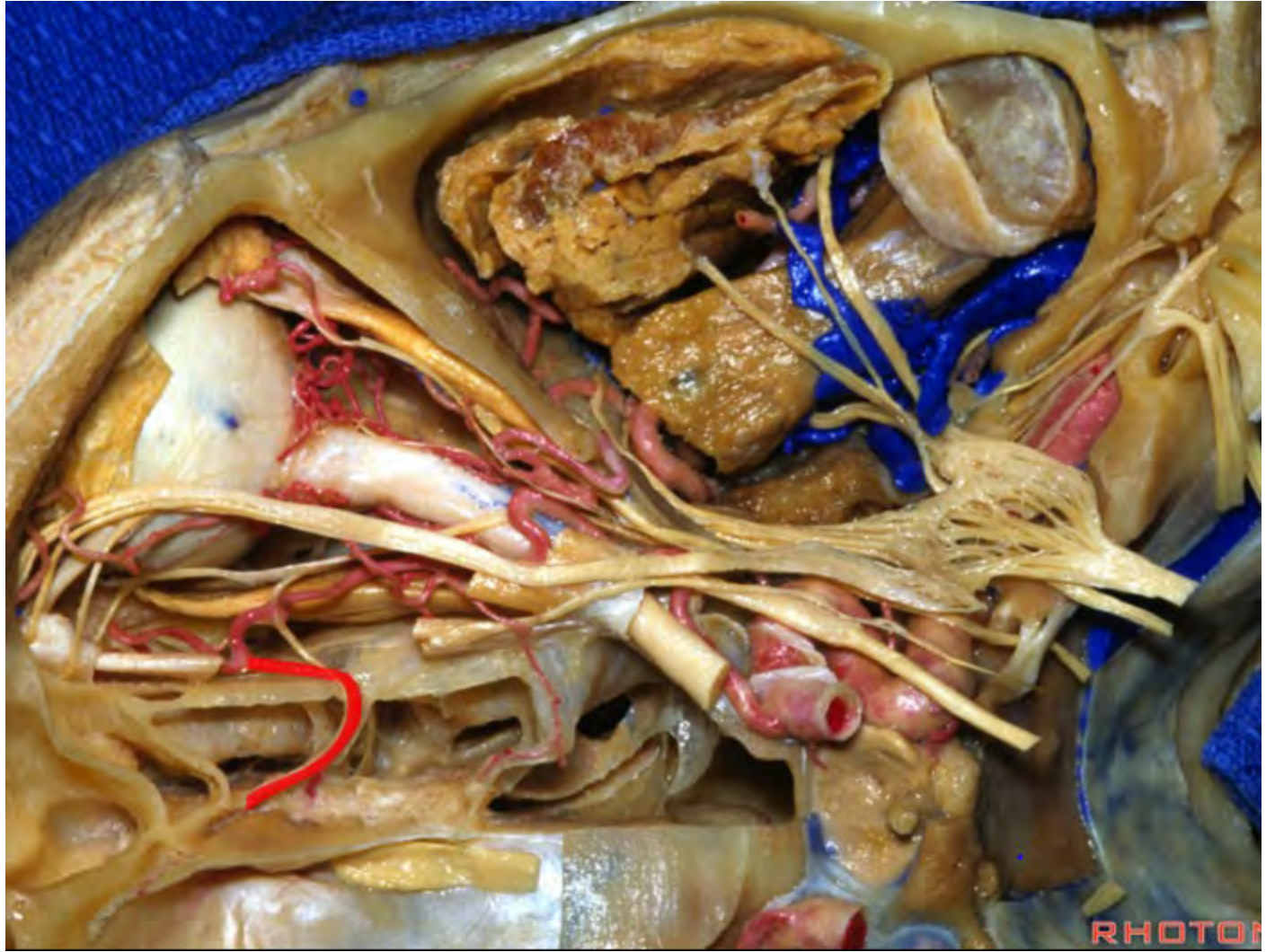


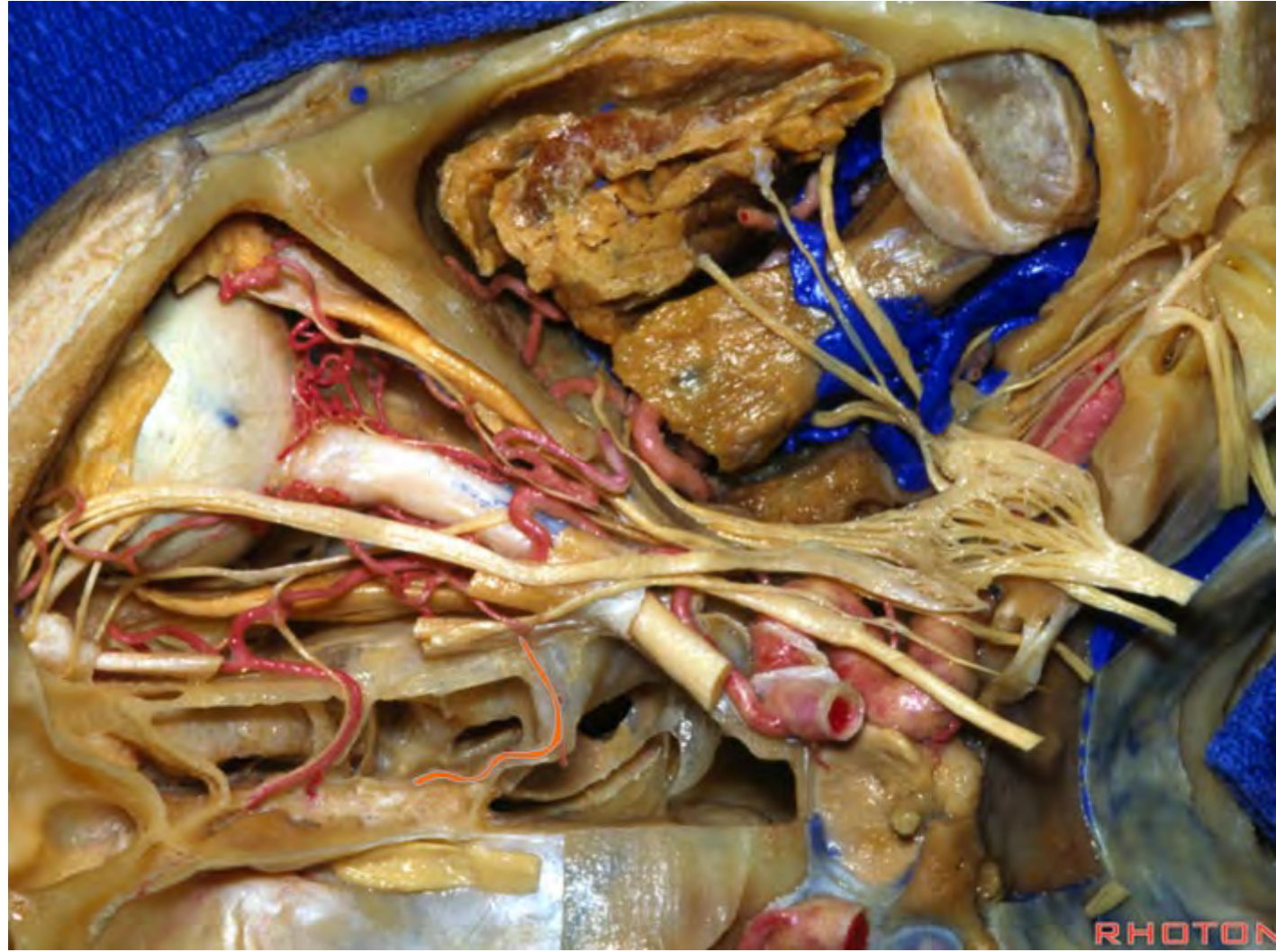
**Pterygopalatine fossa**

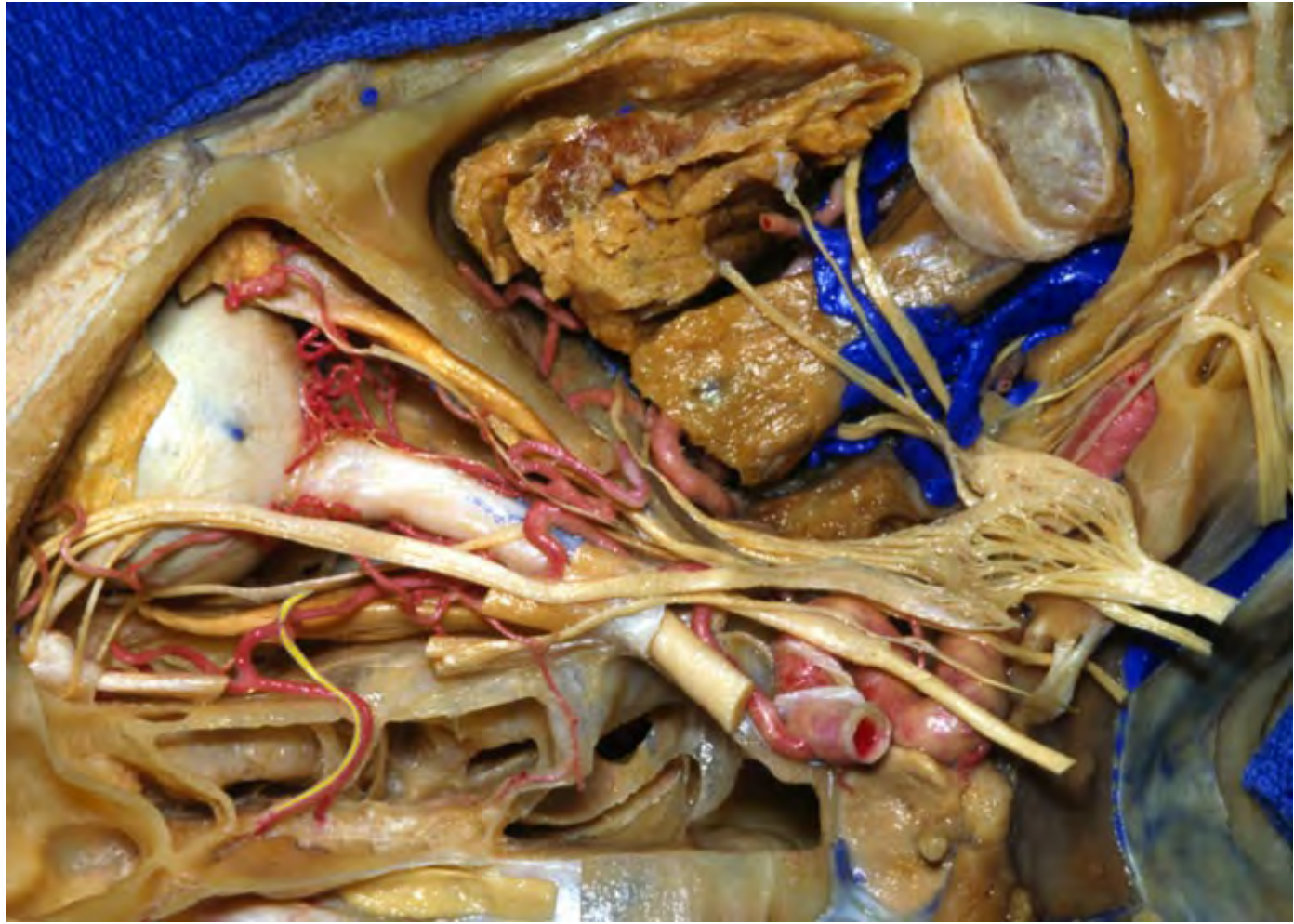

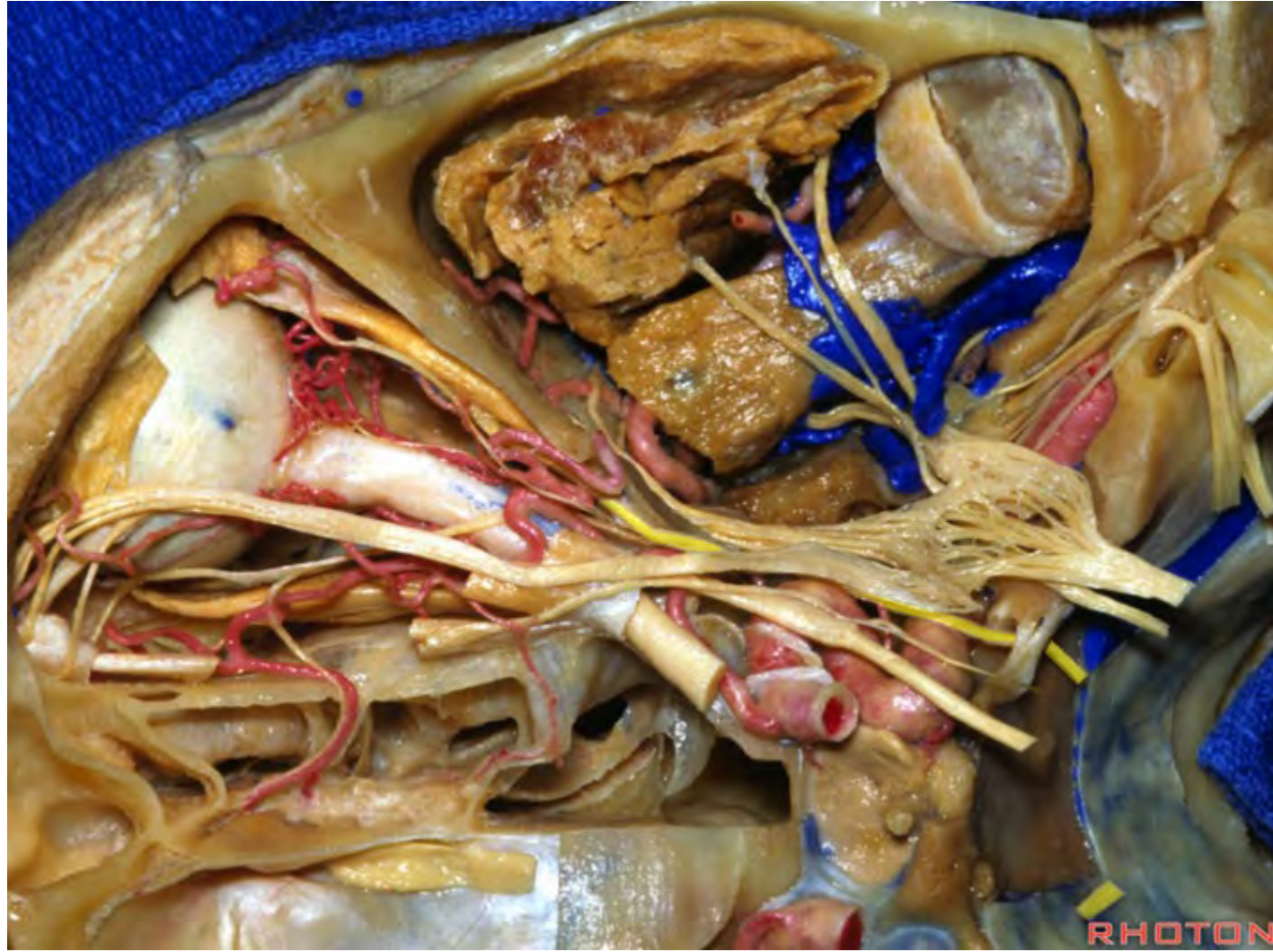
**Superior orbital fissure**



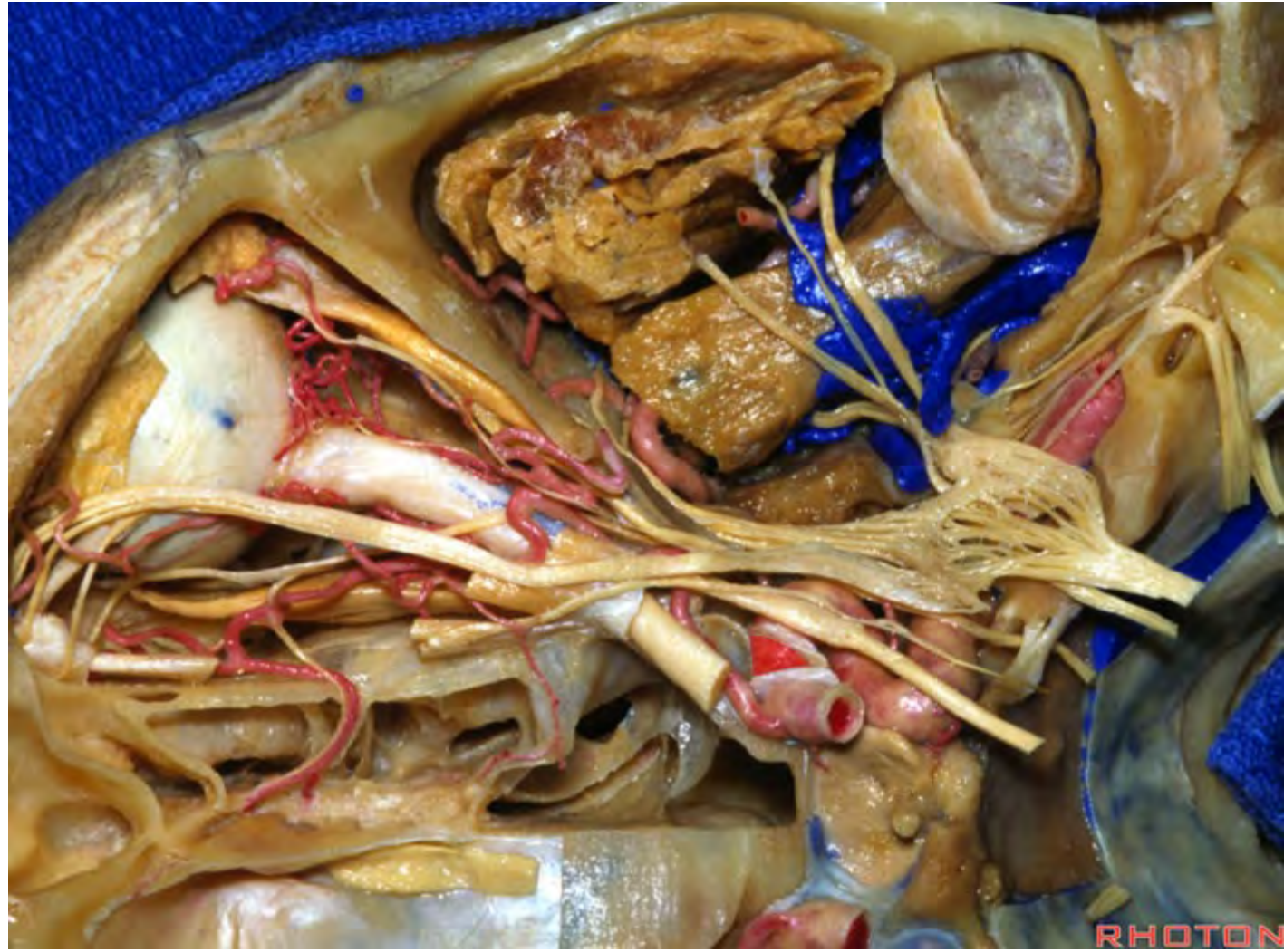


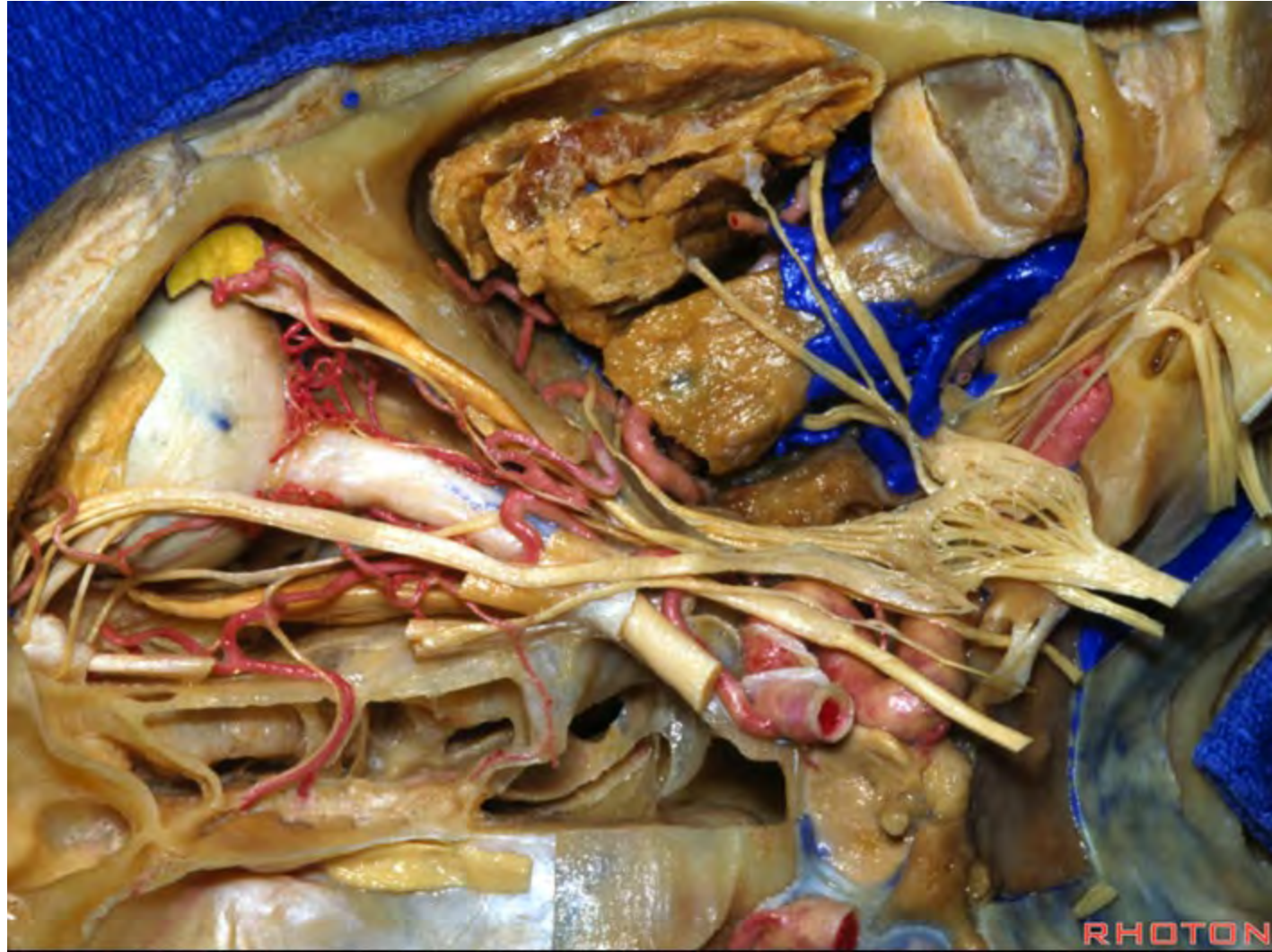


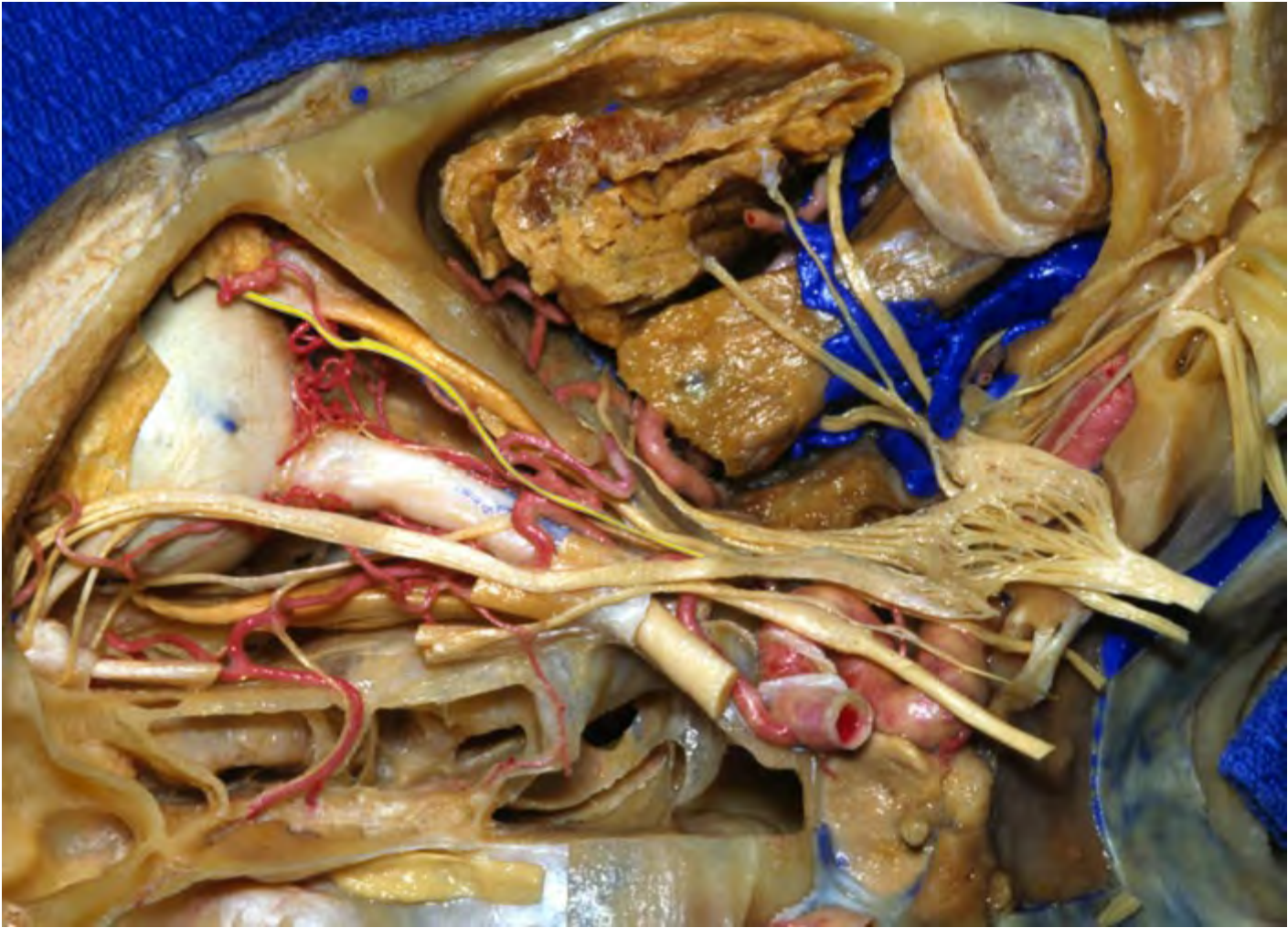


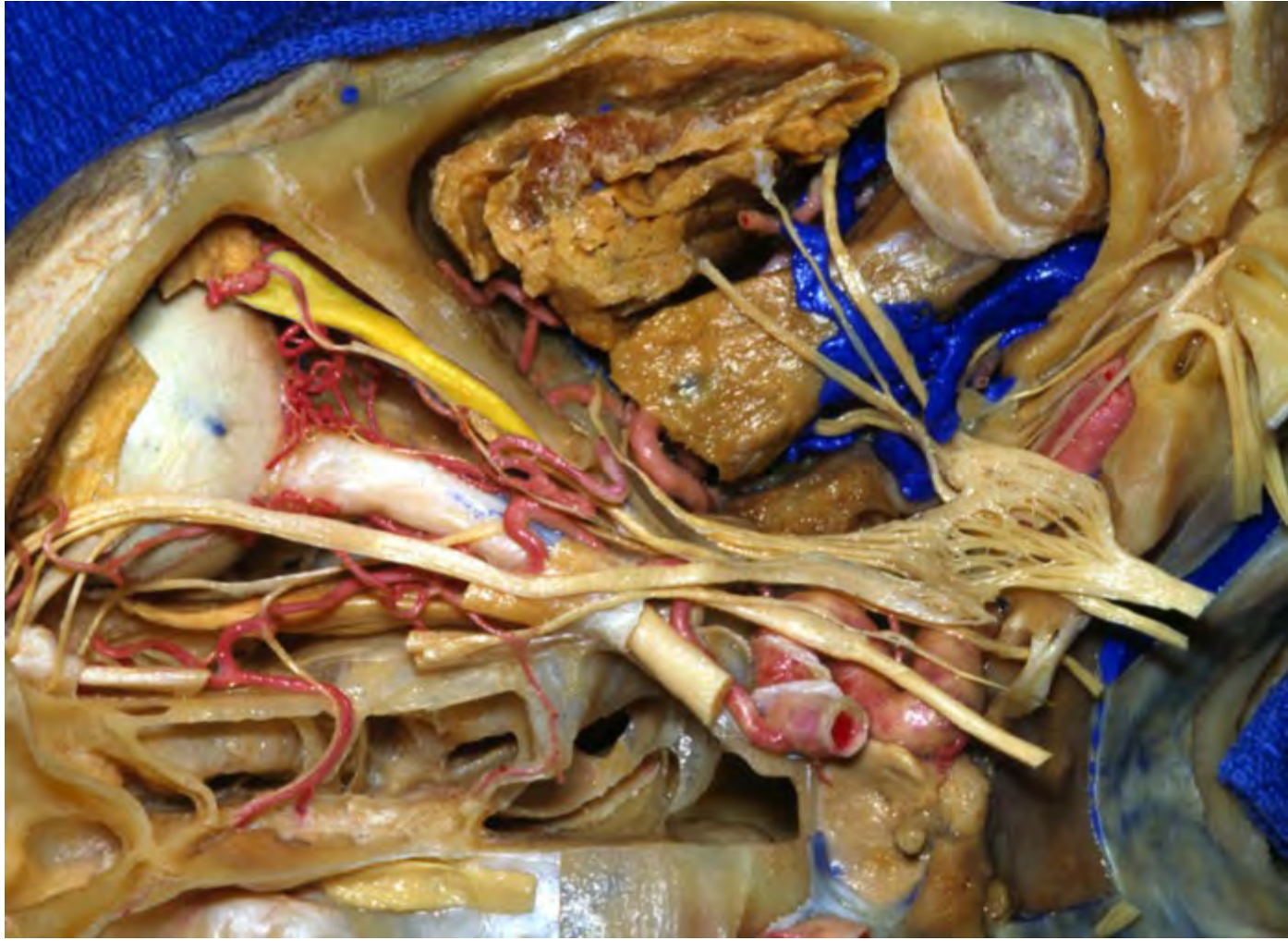


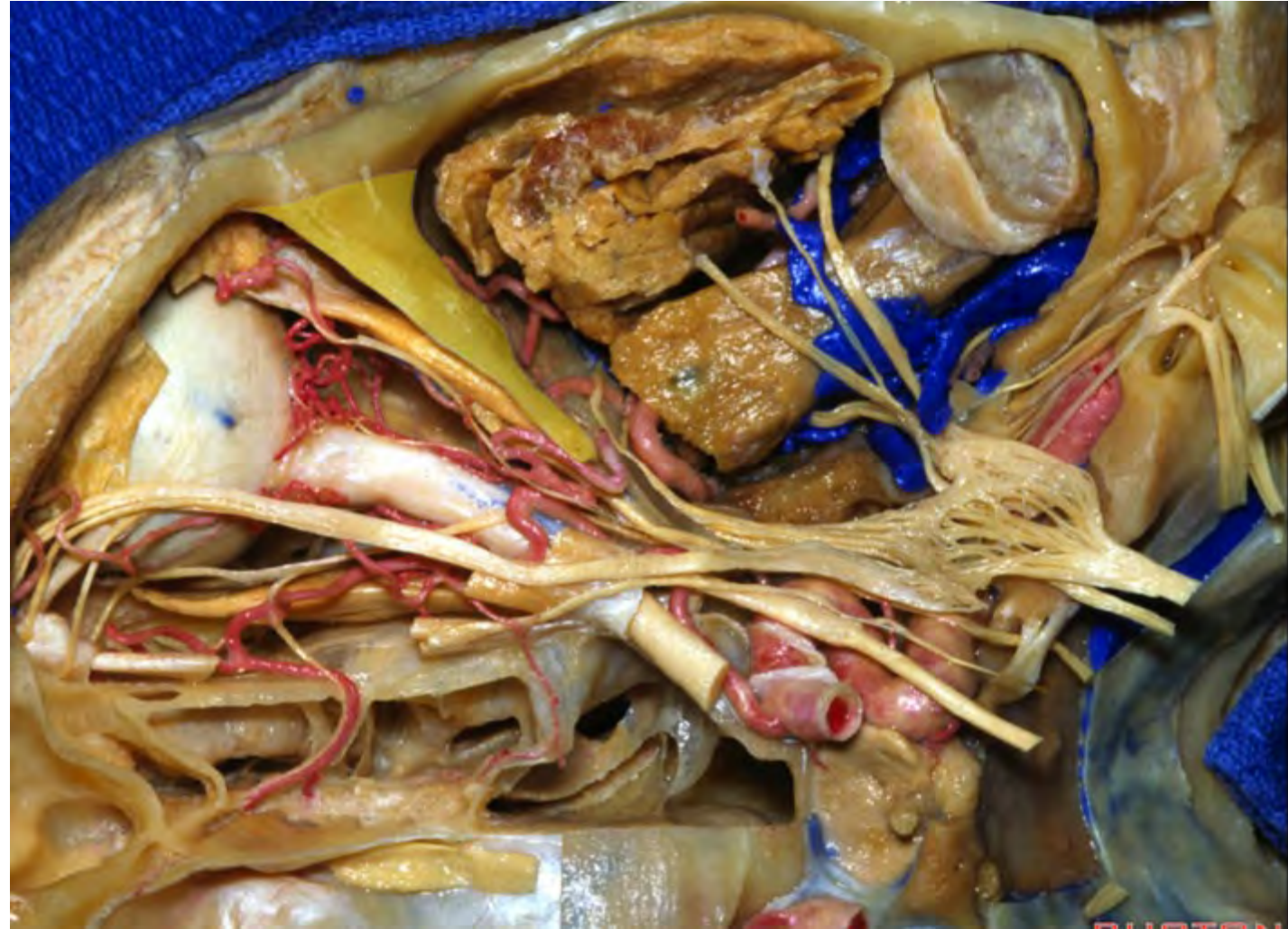

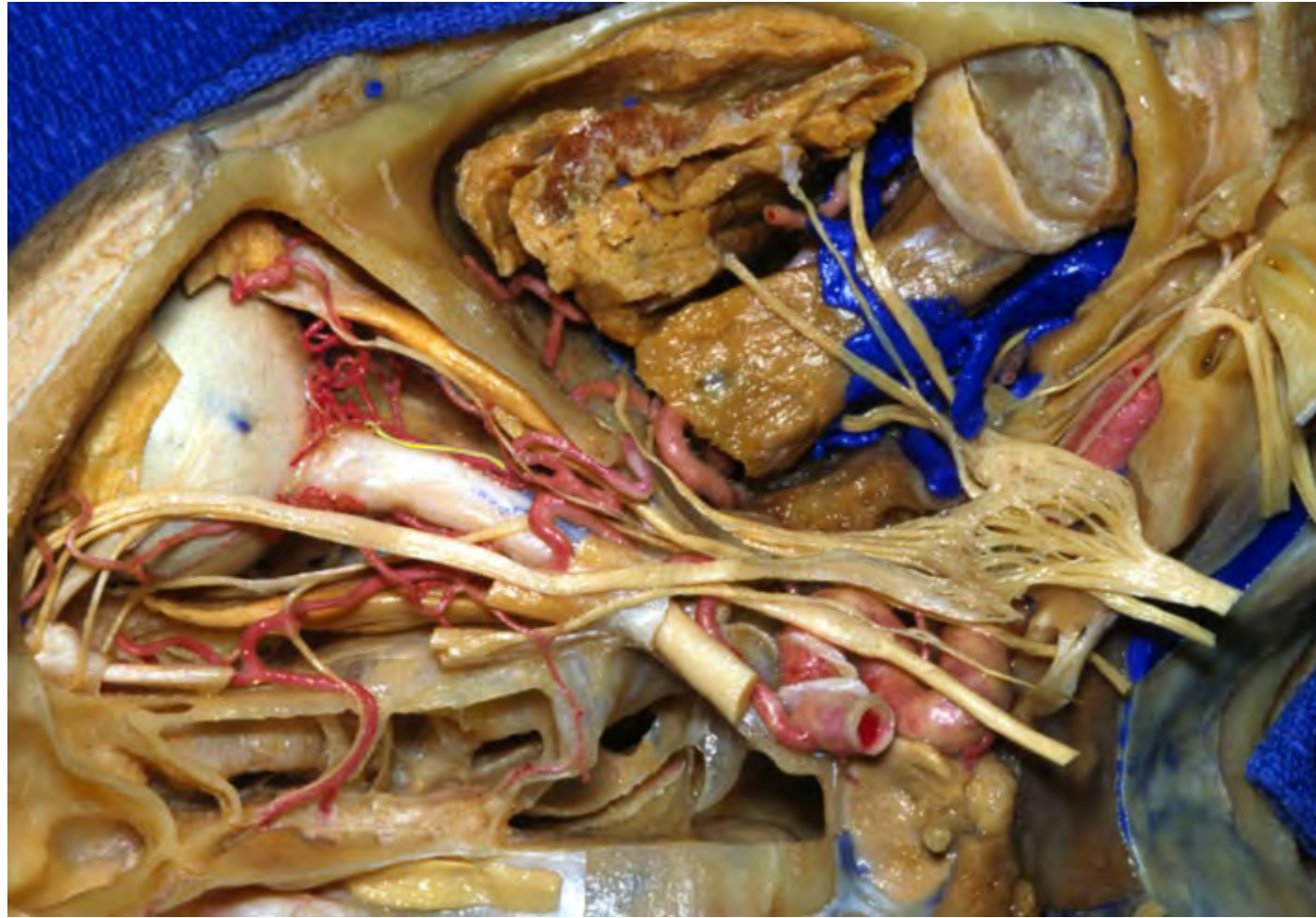


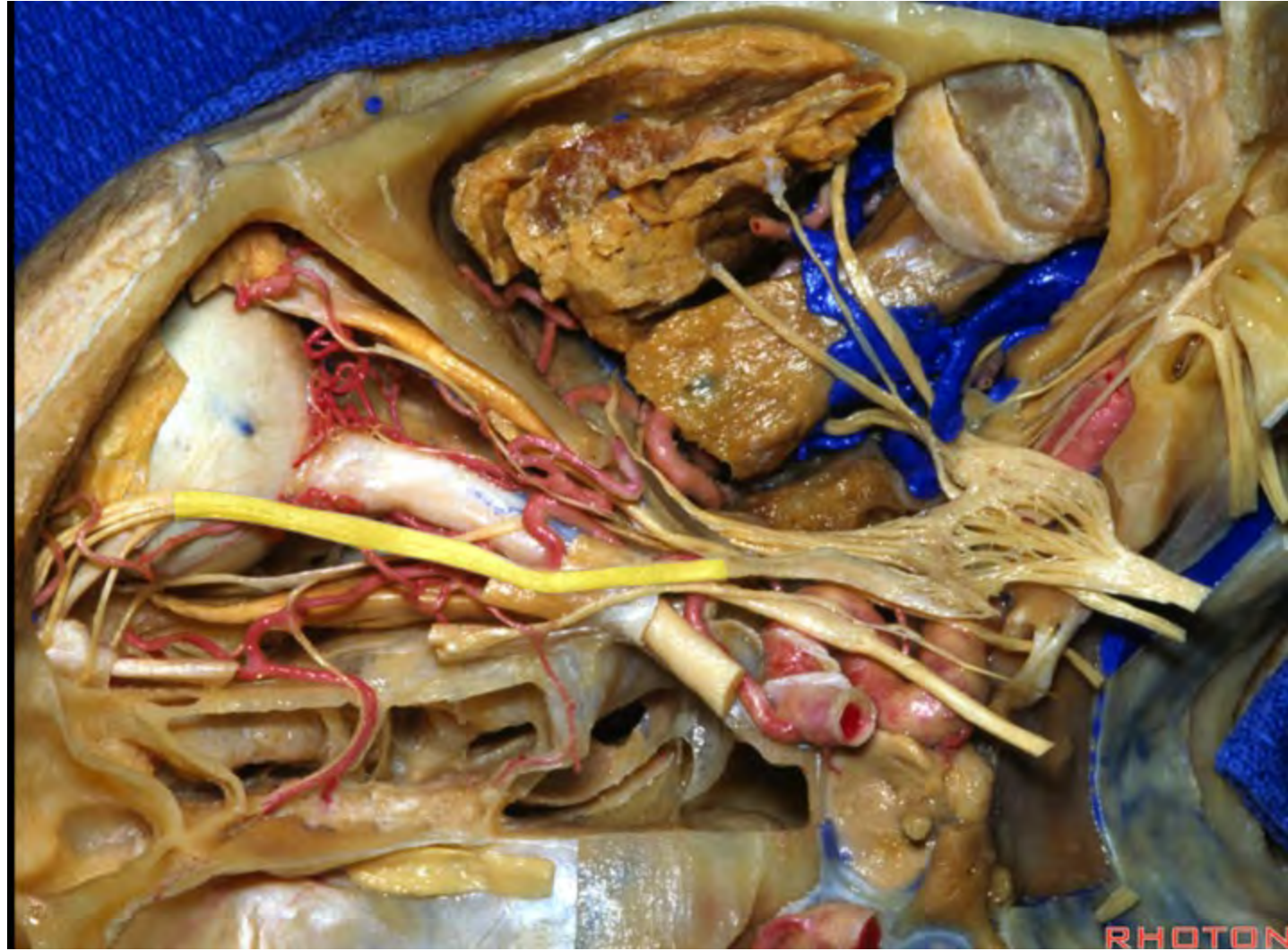


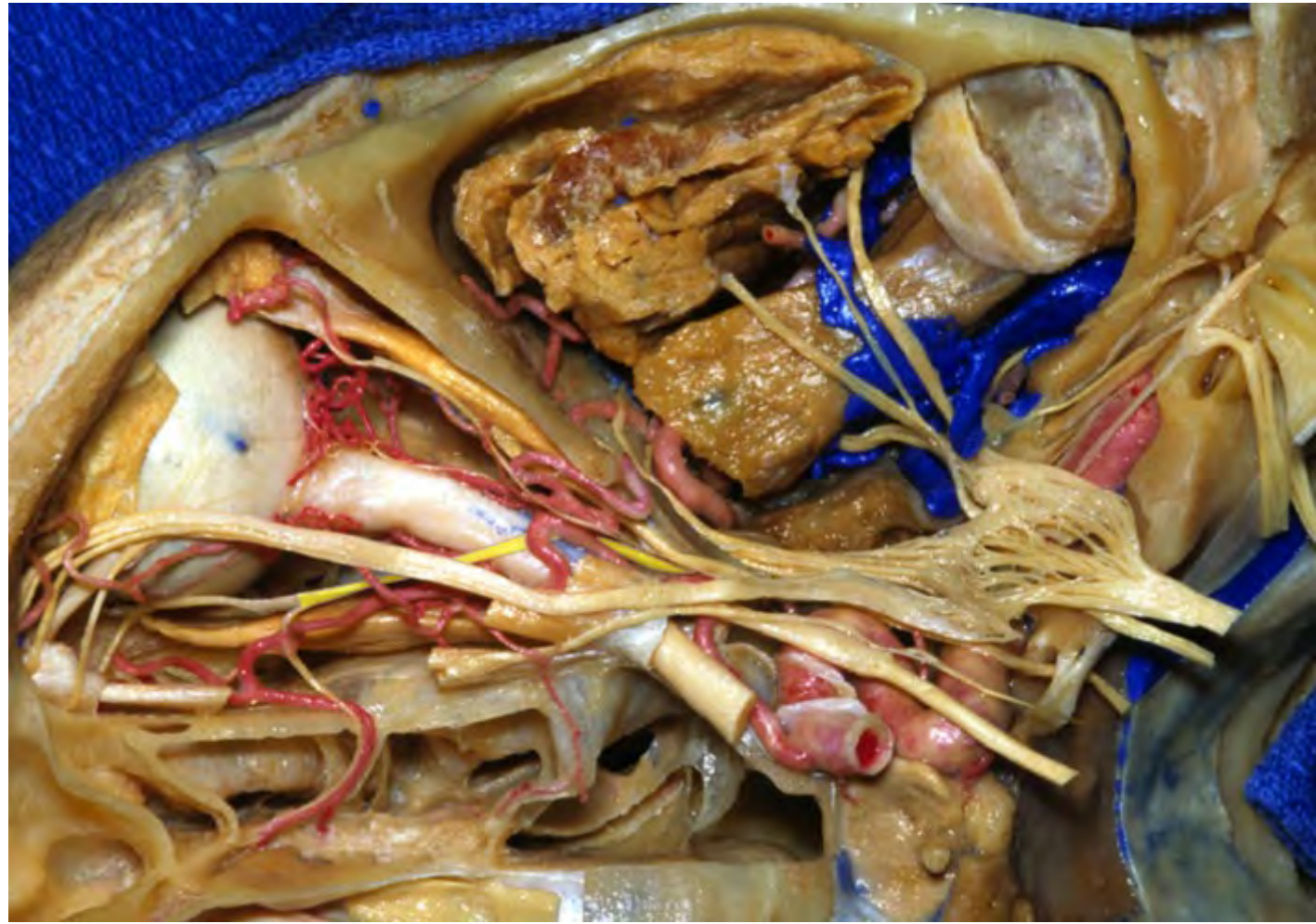




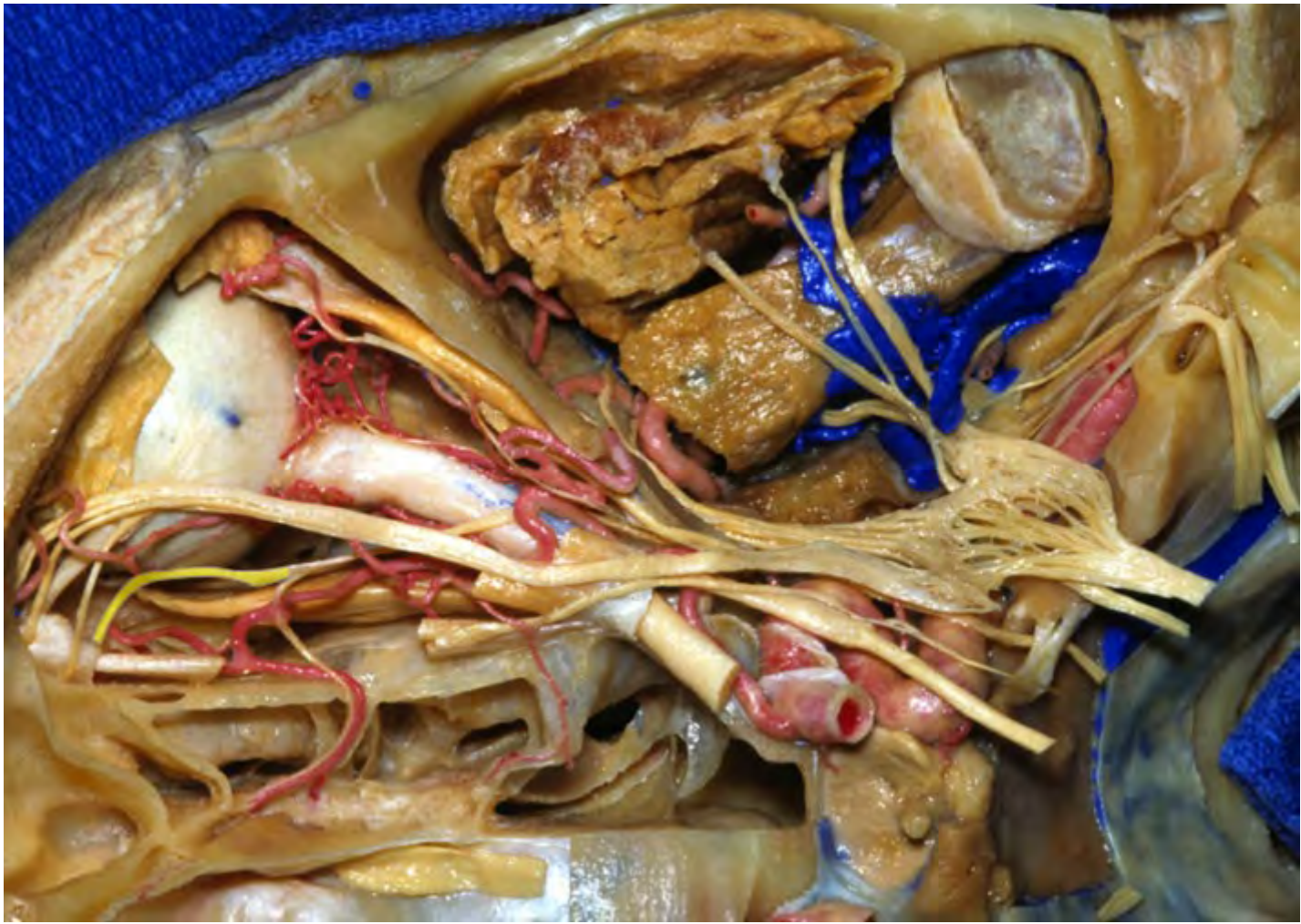



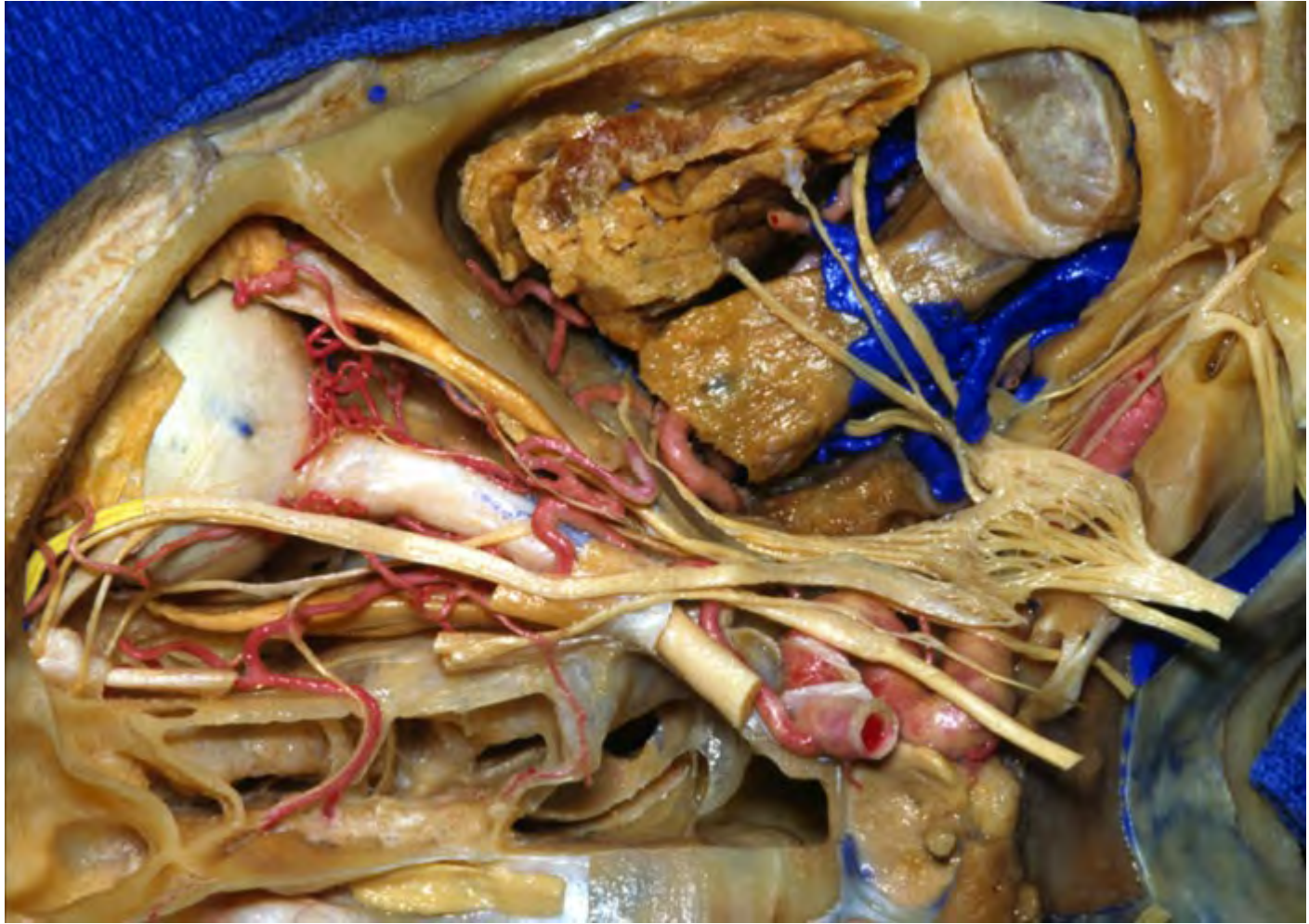


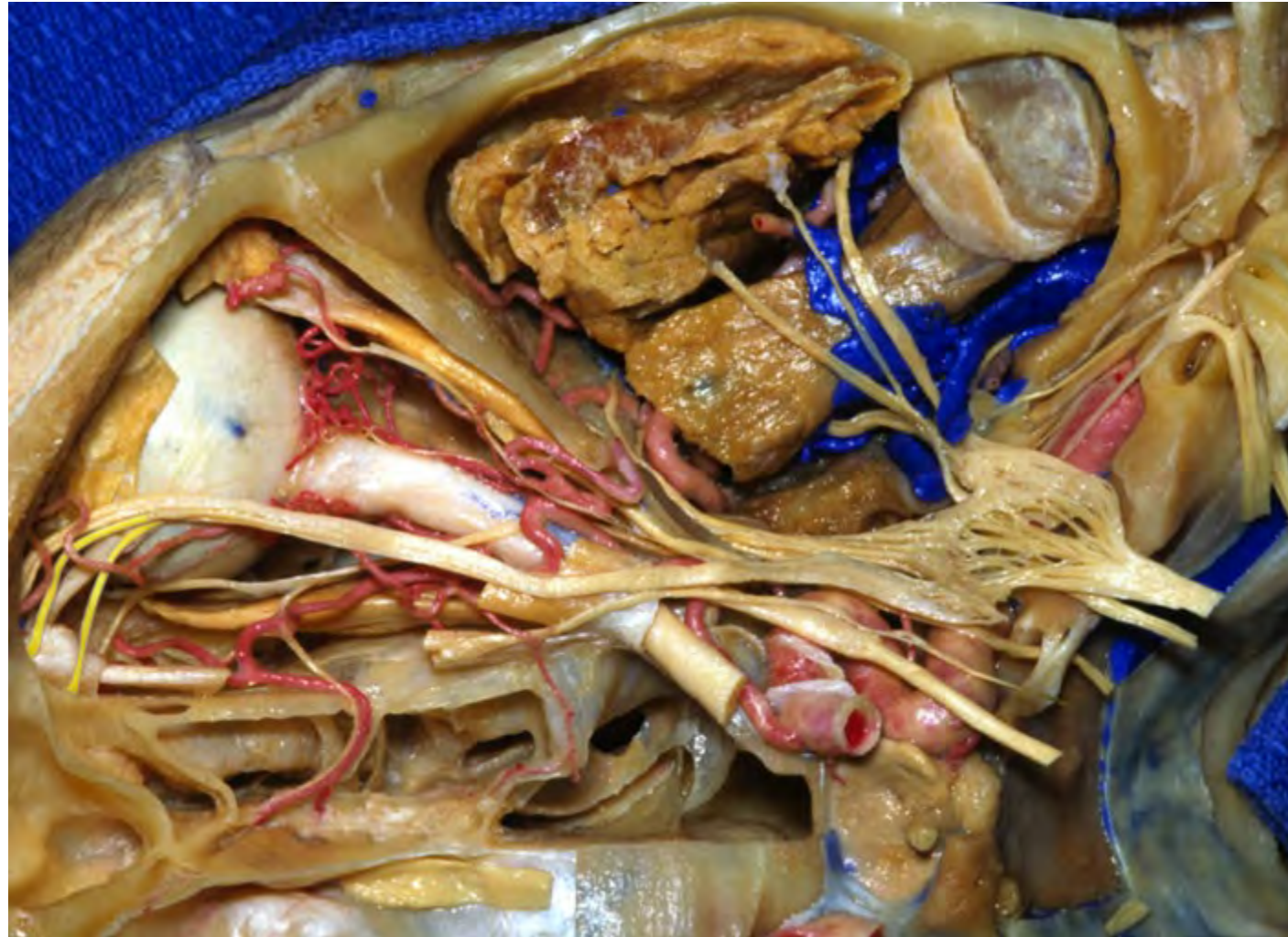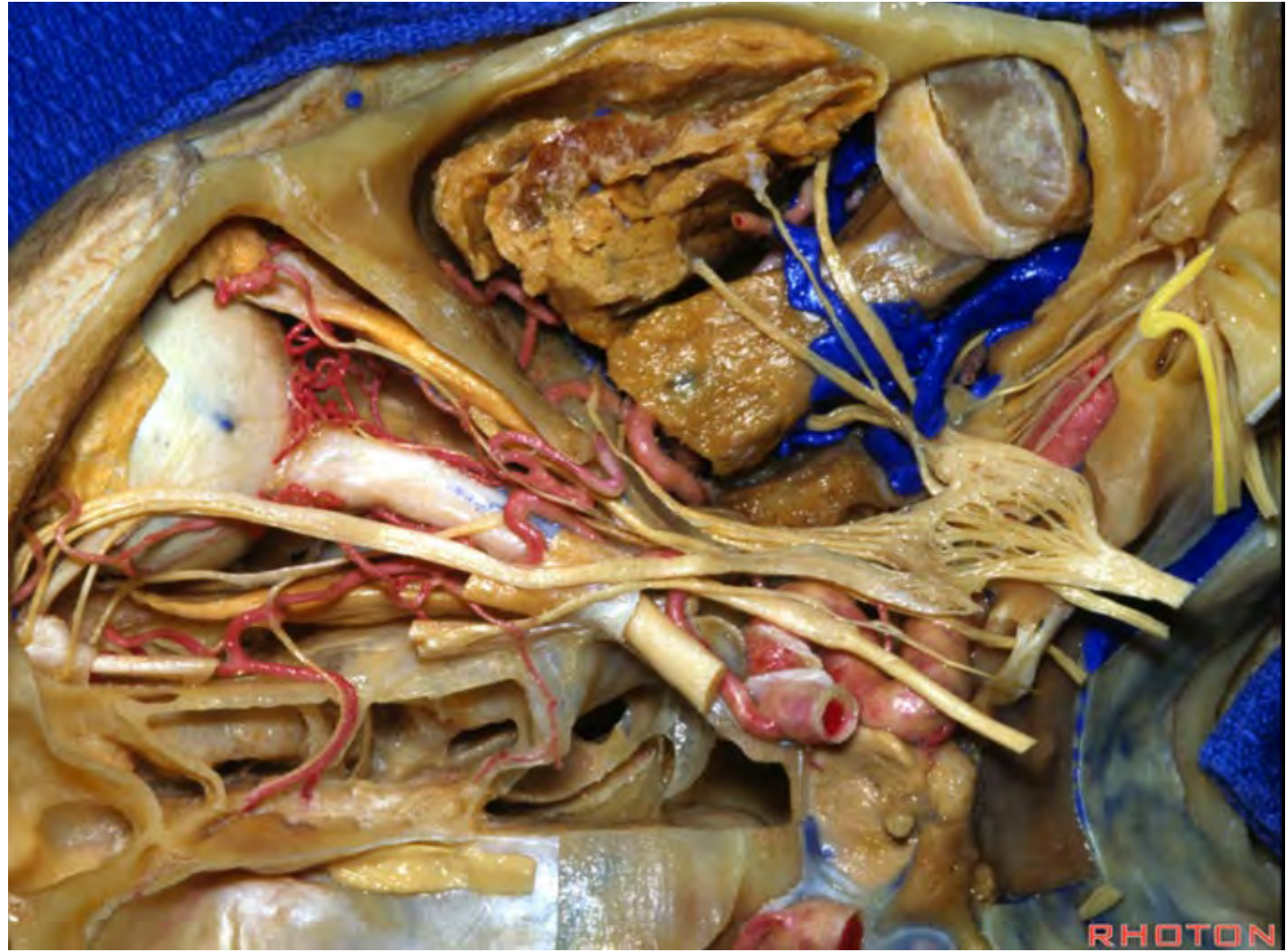


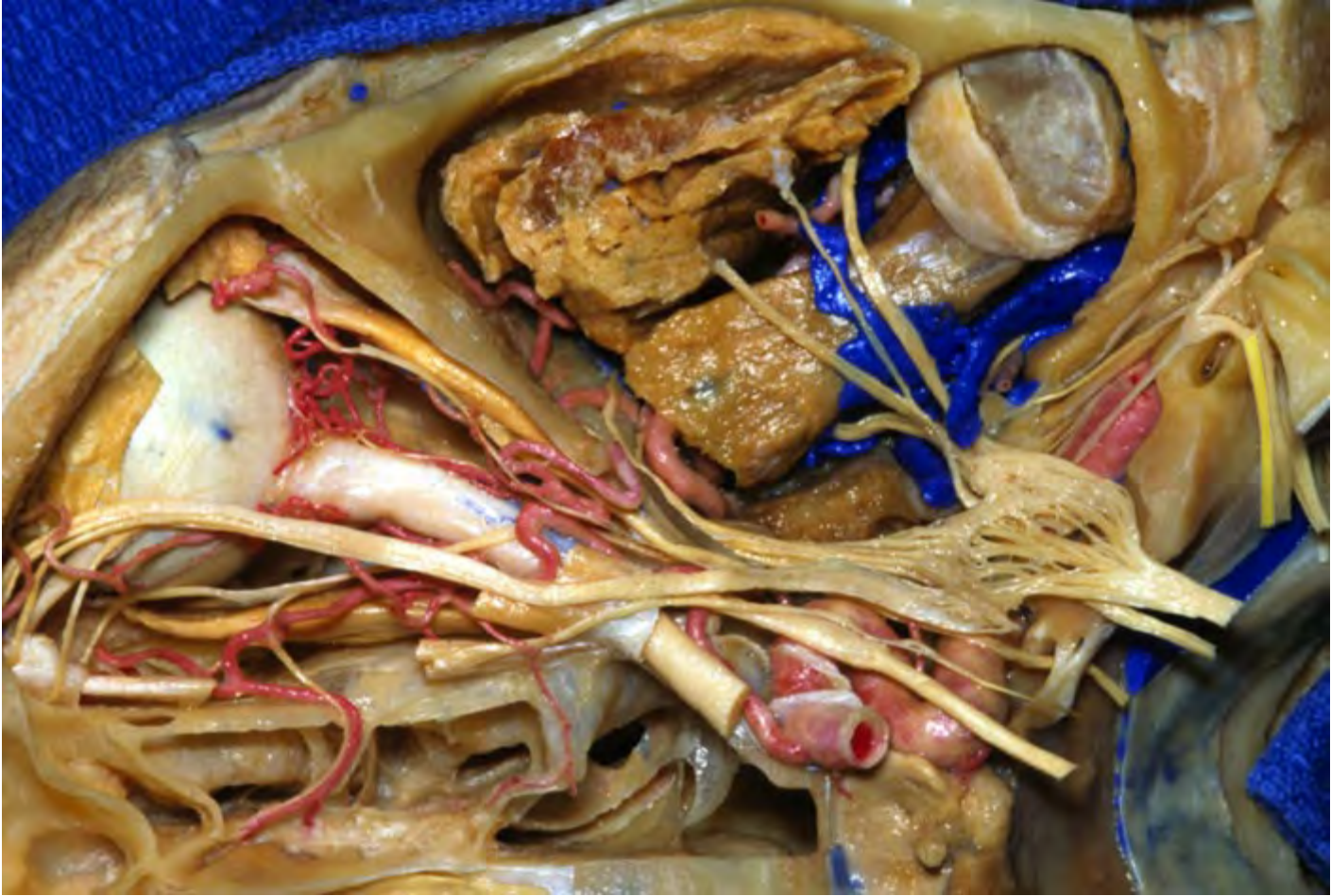


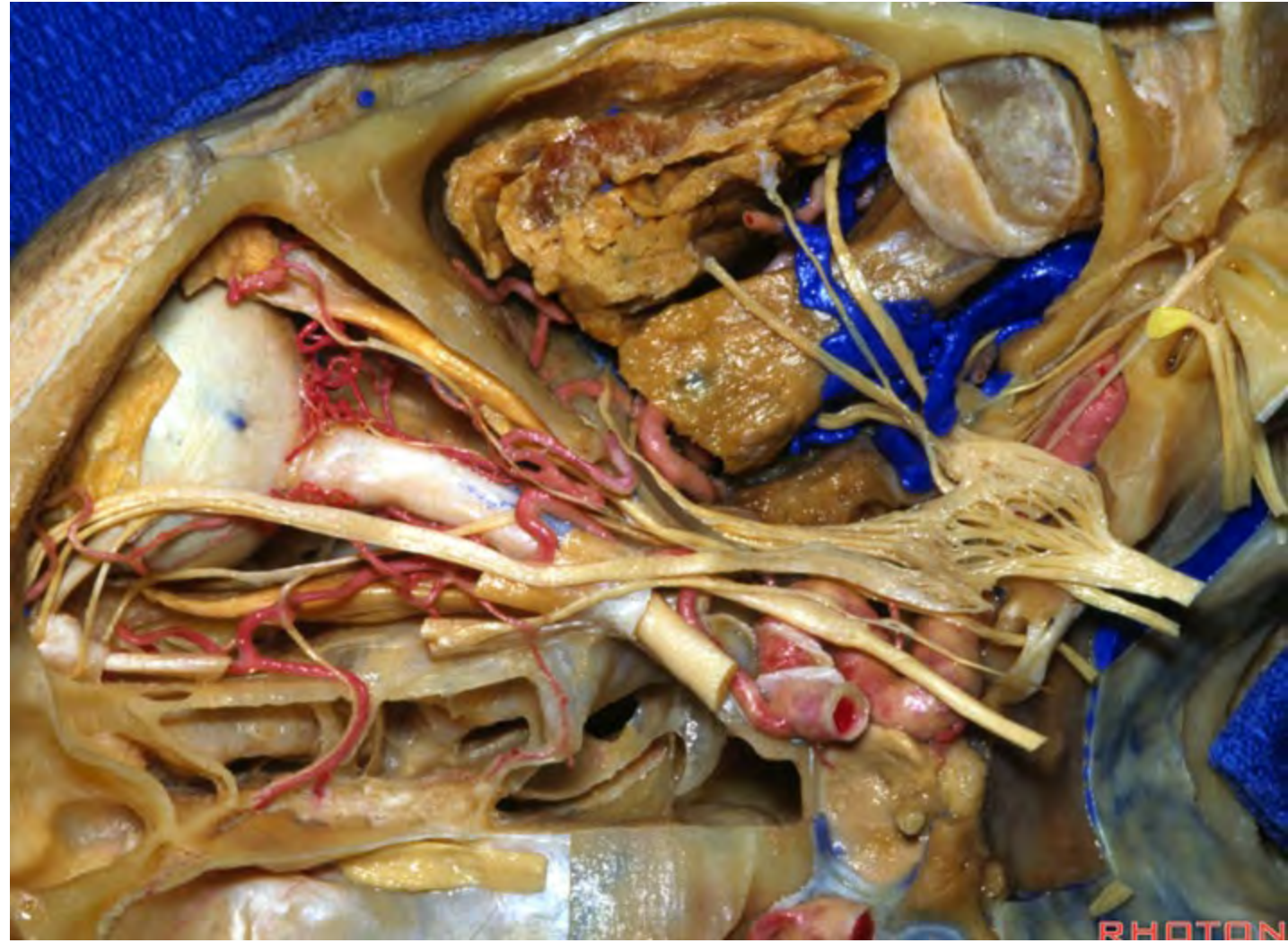





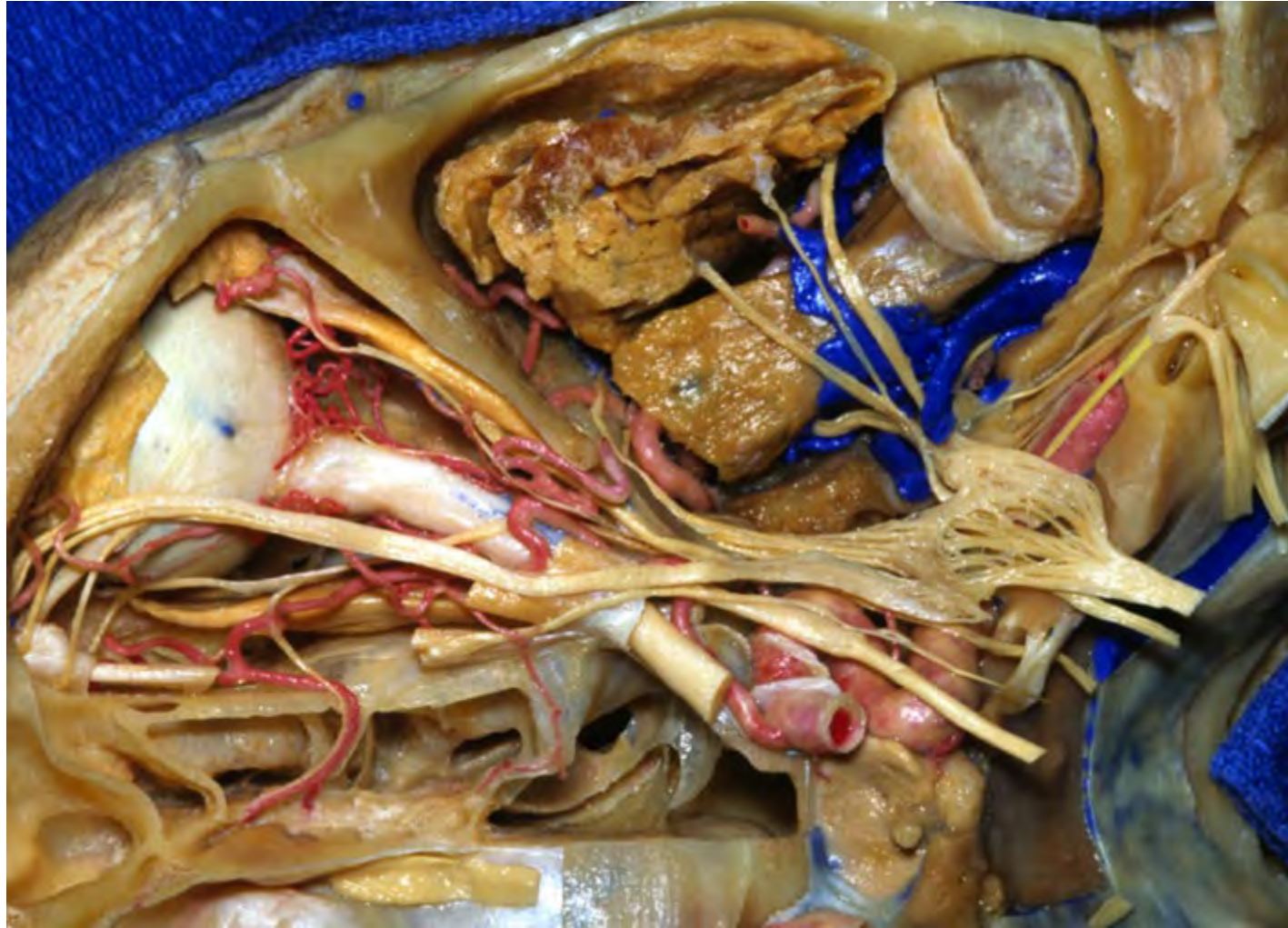


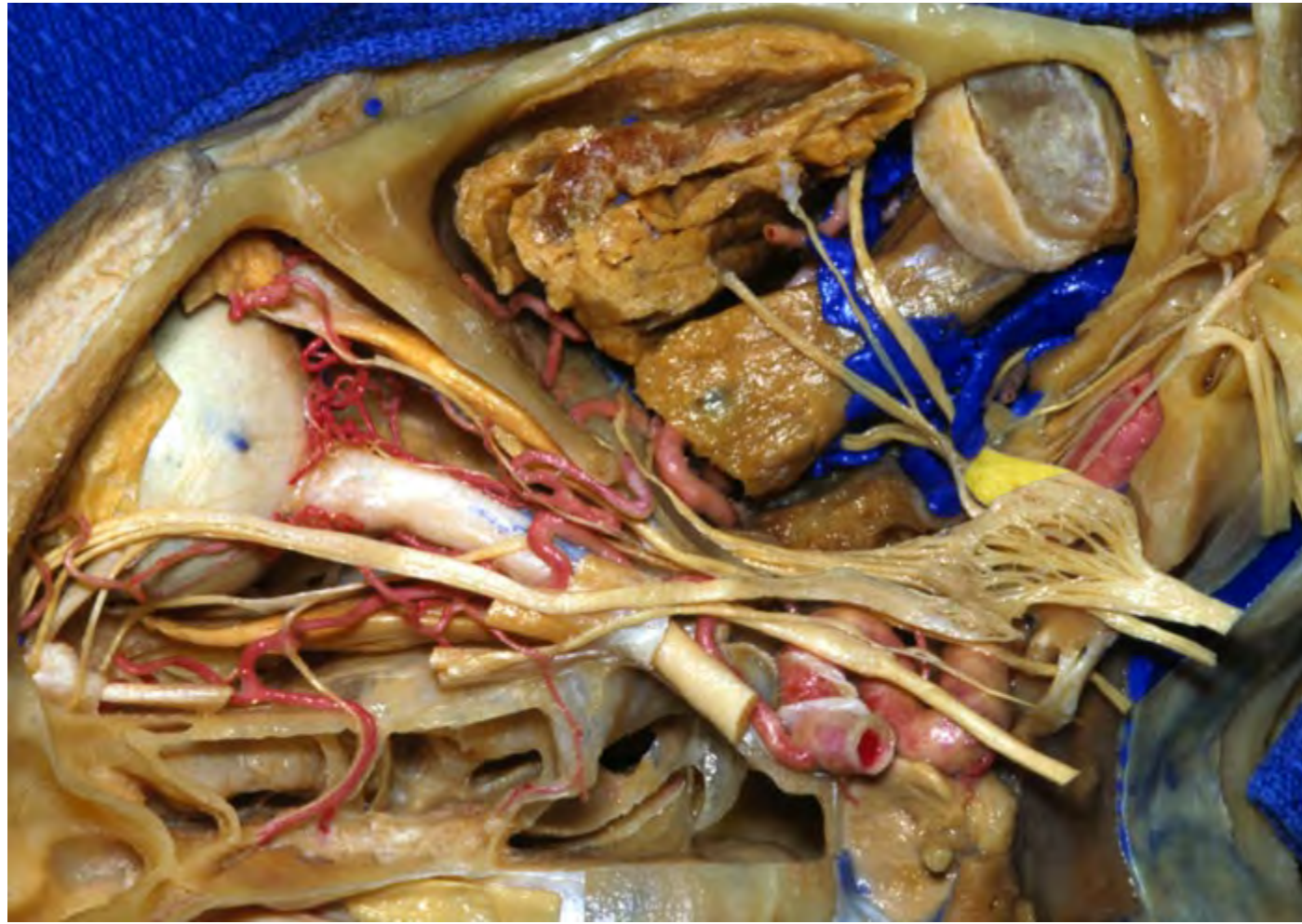

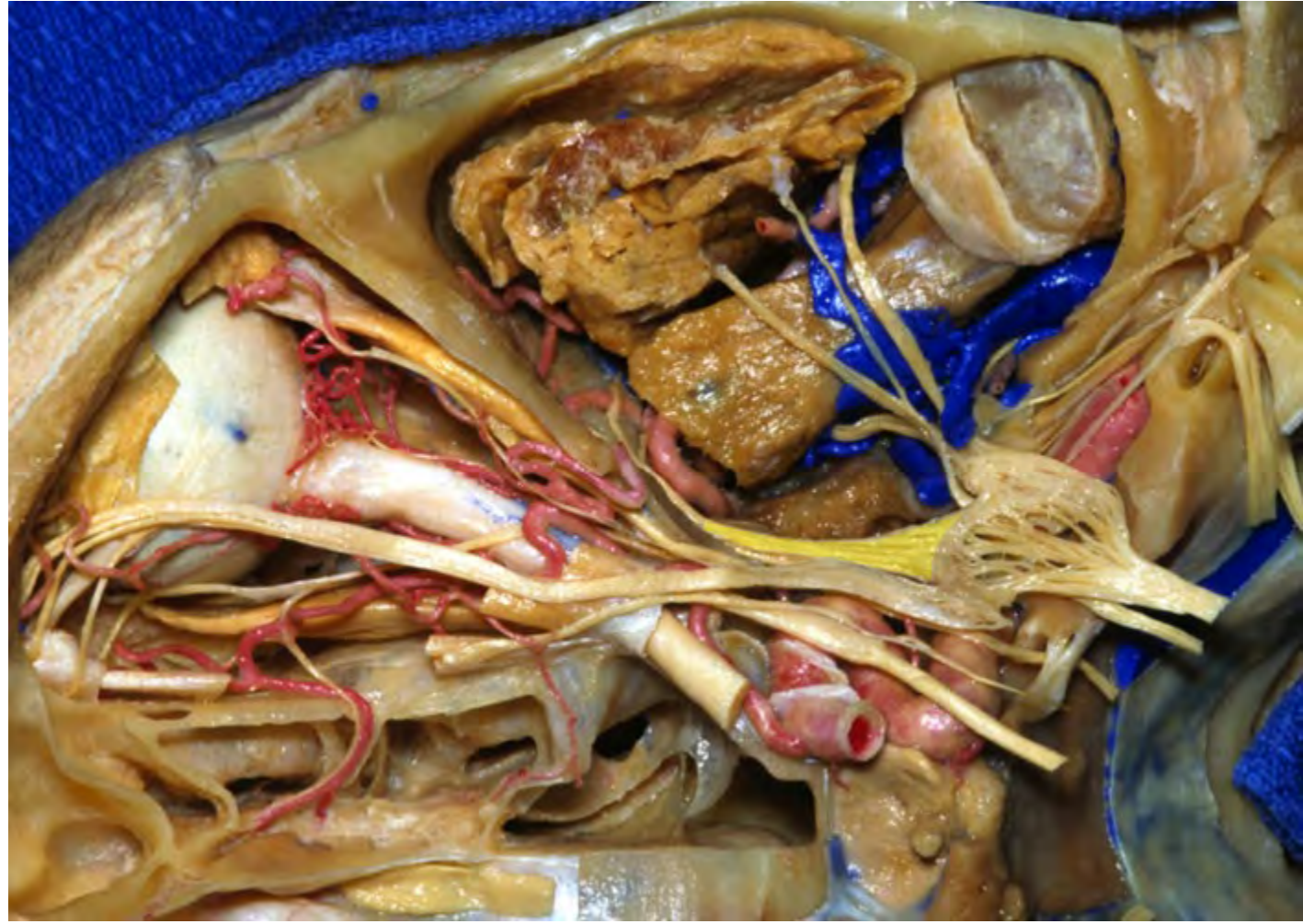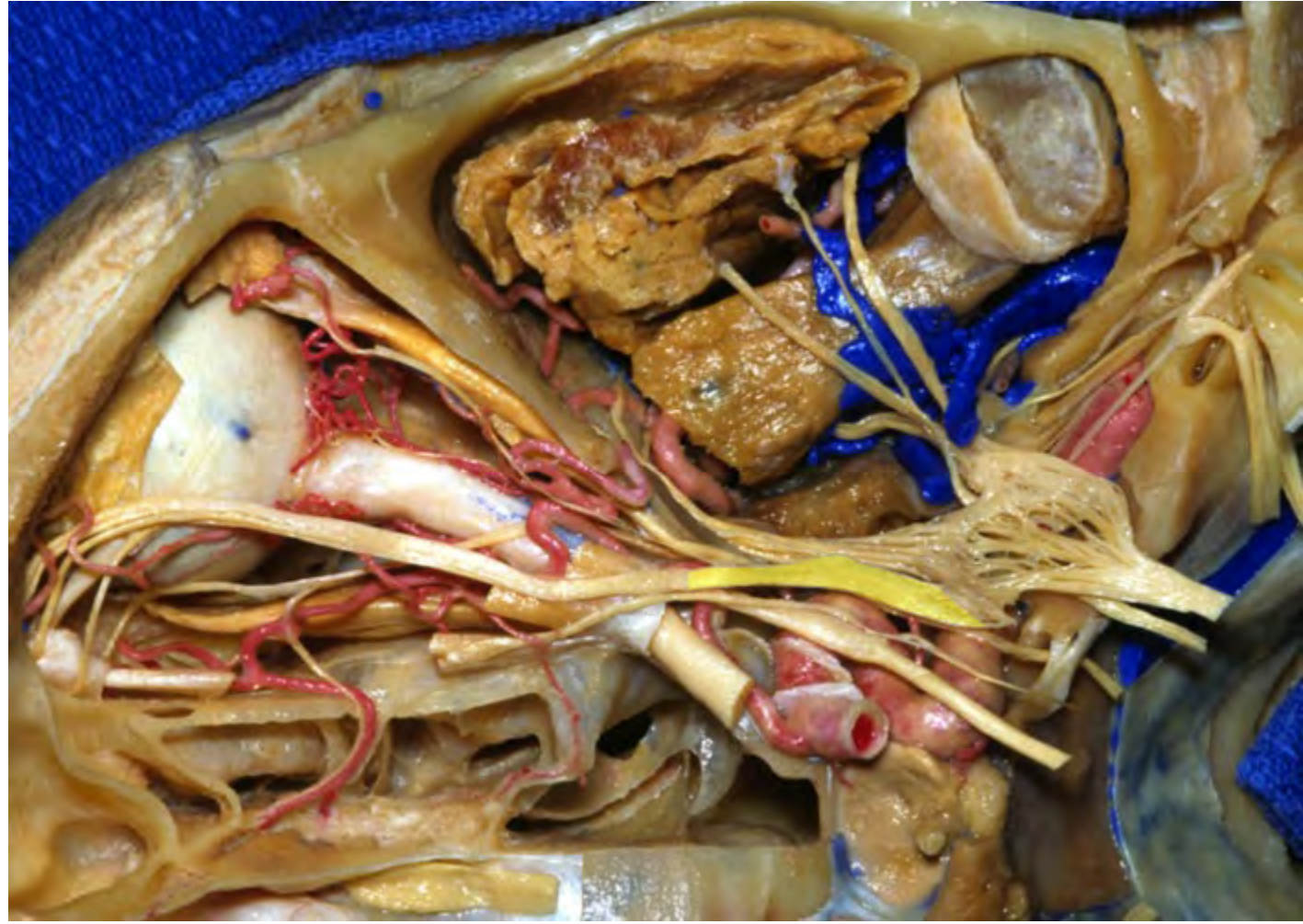


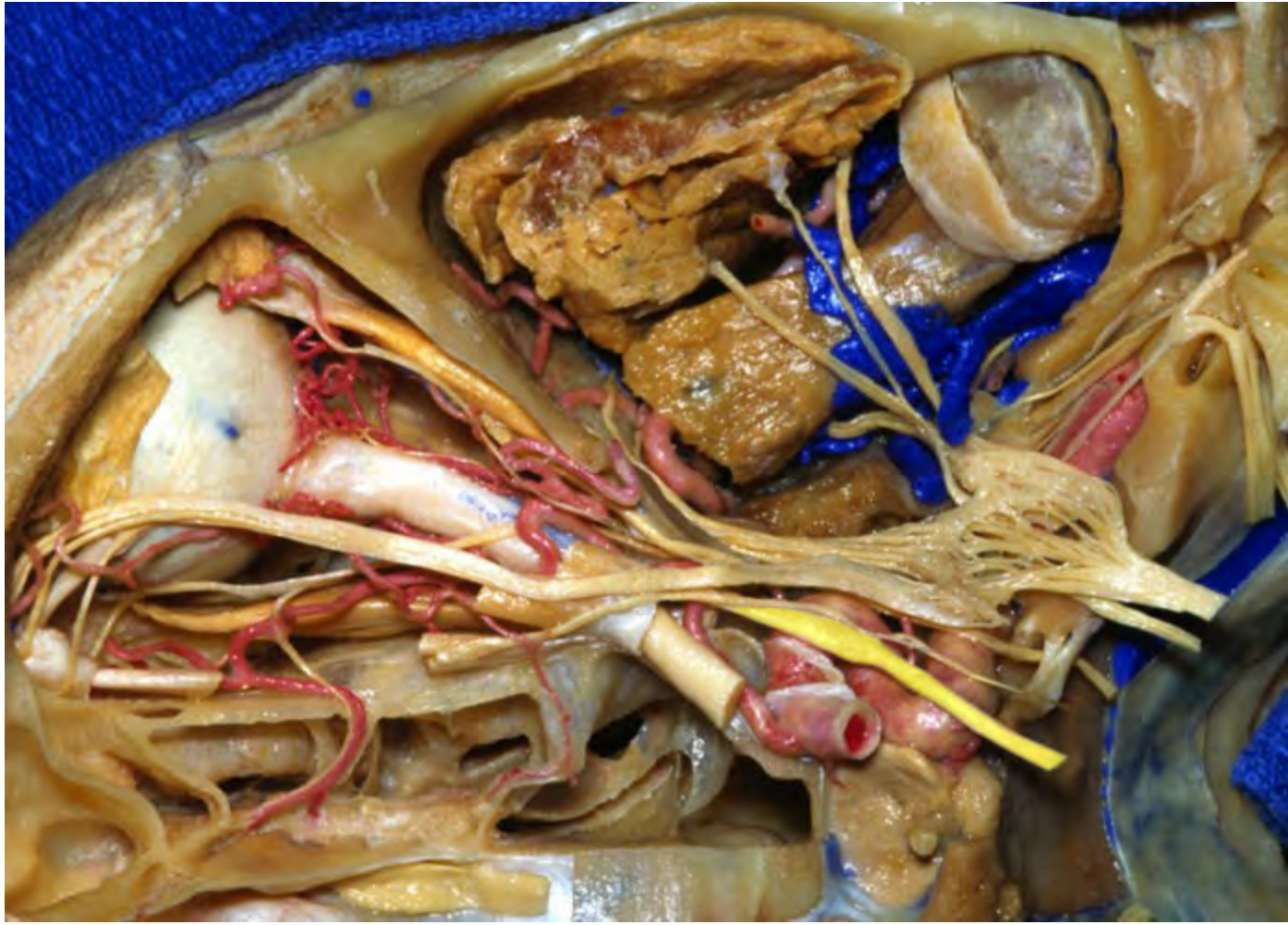


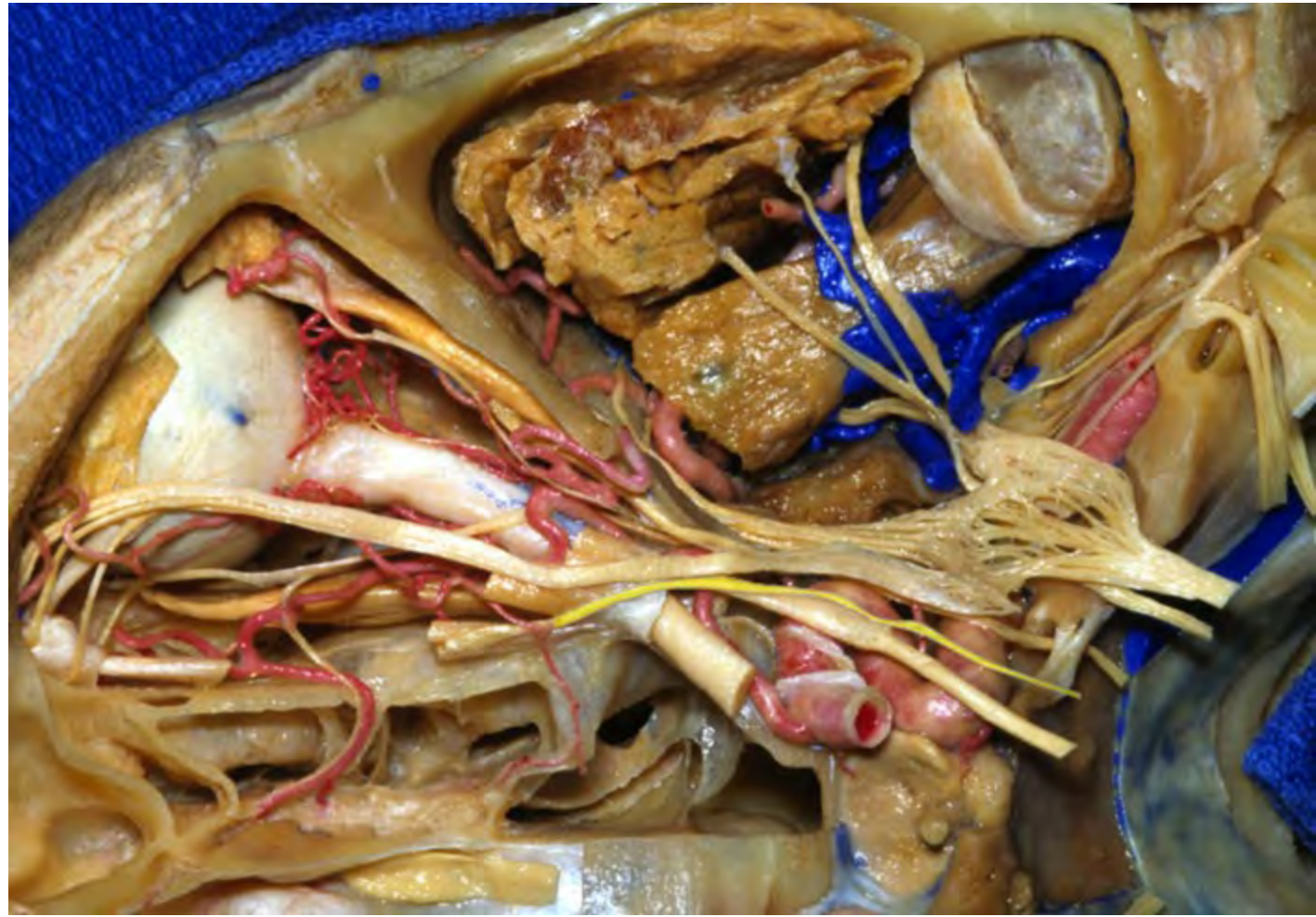


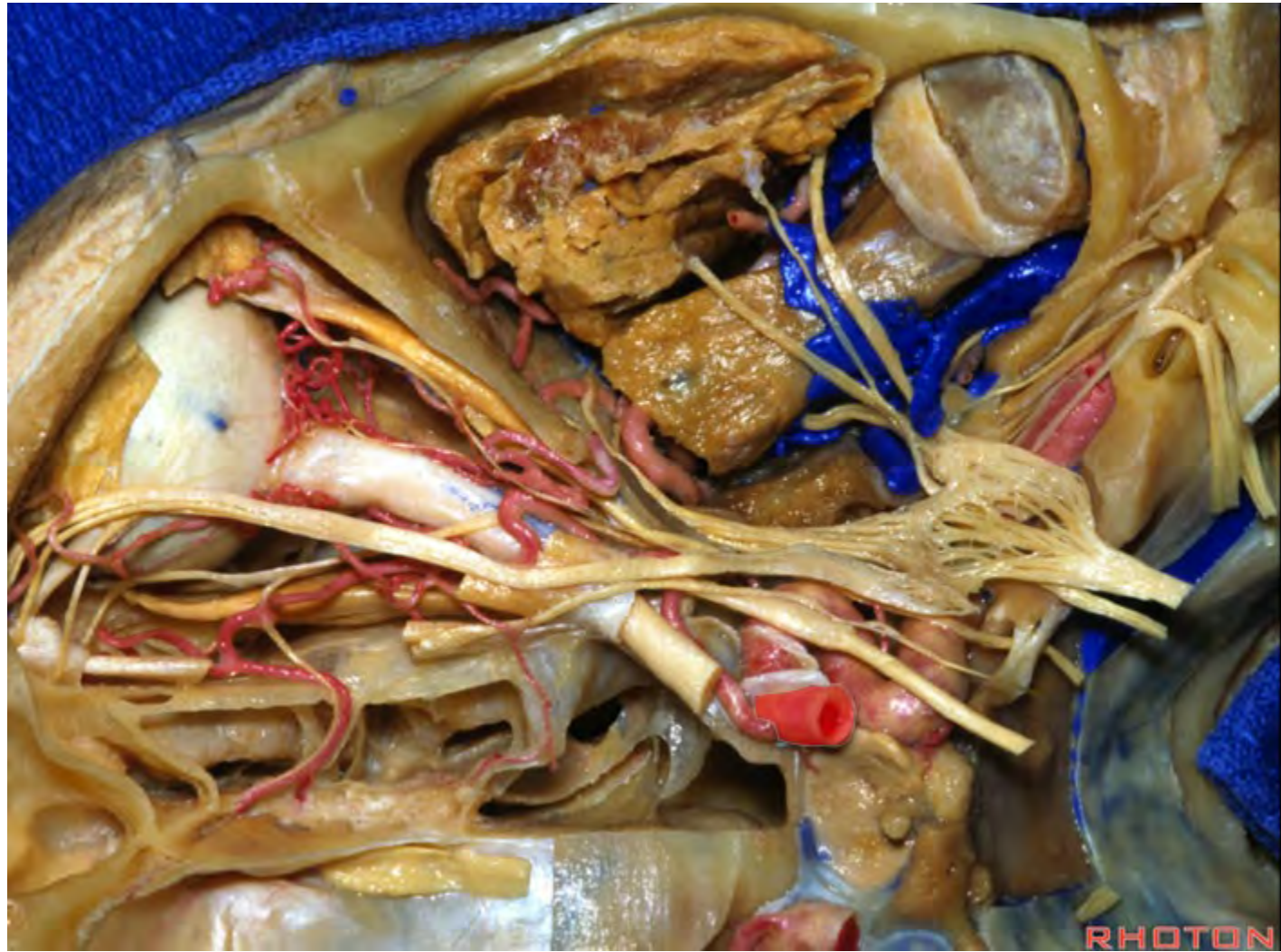


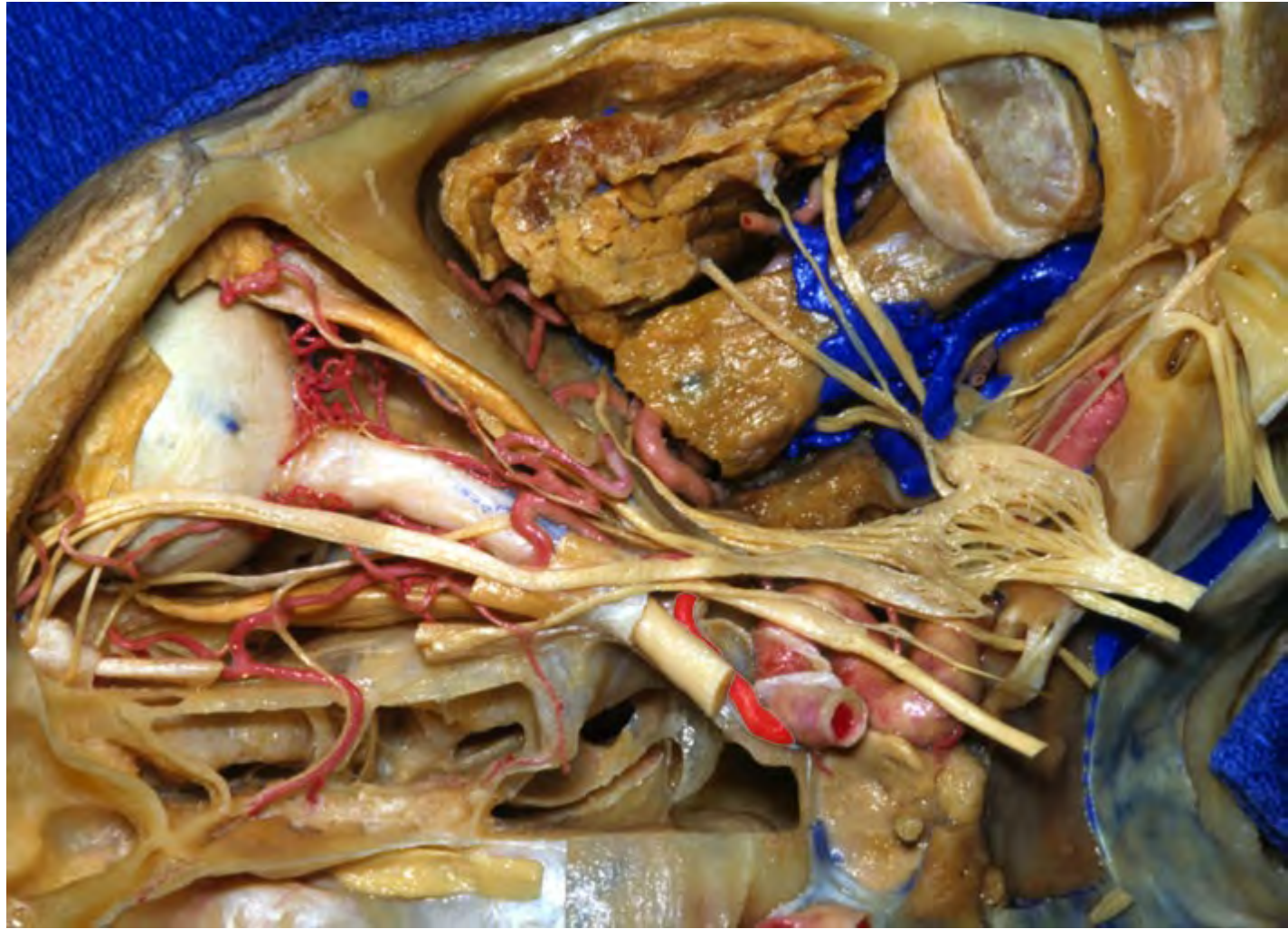








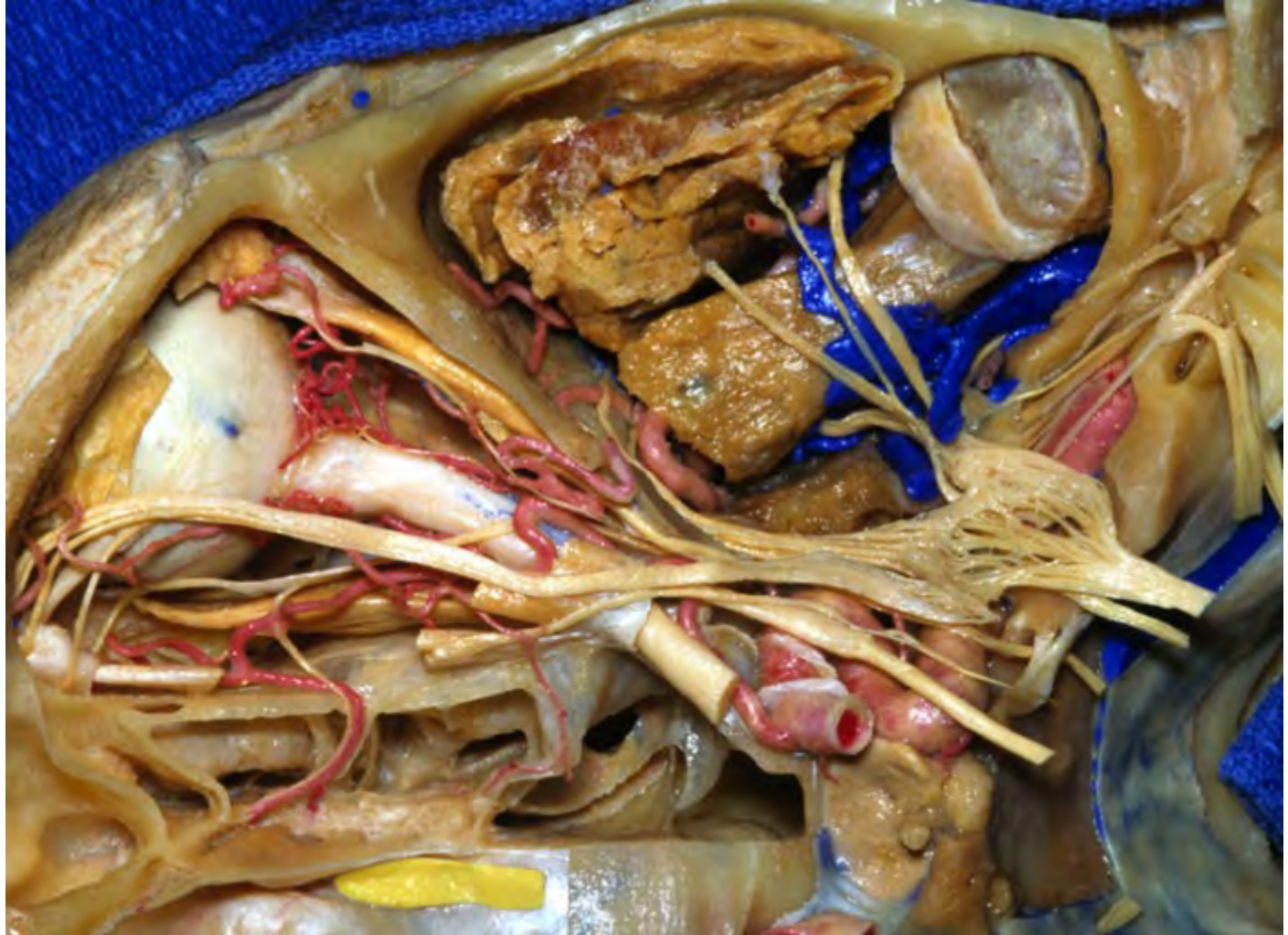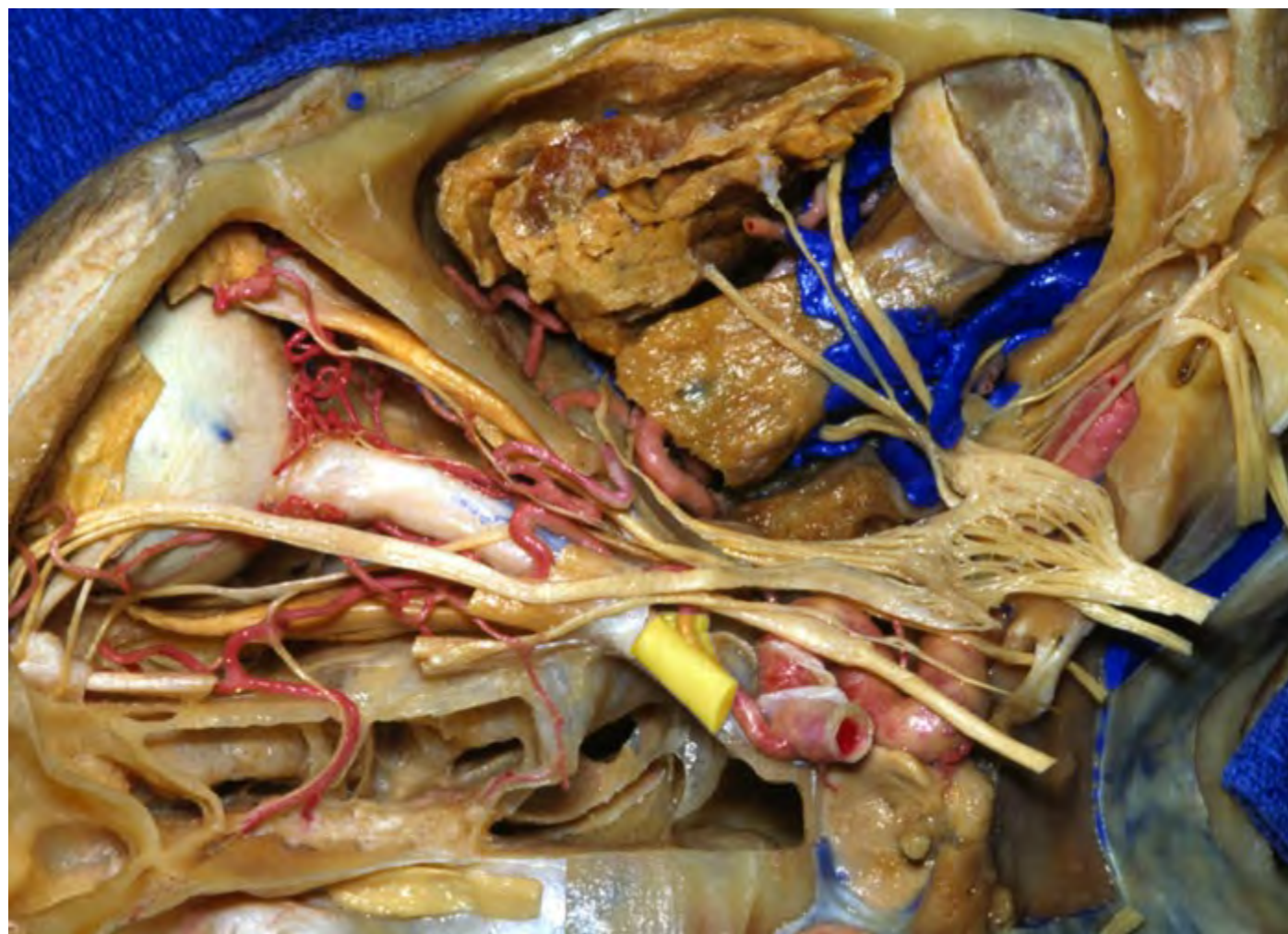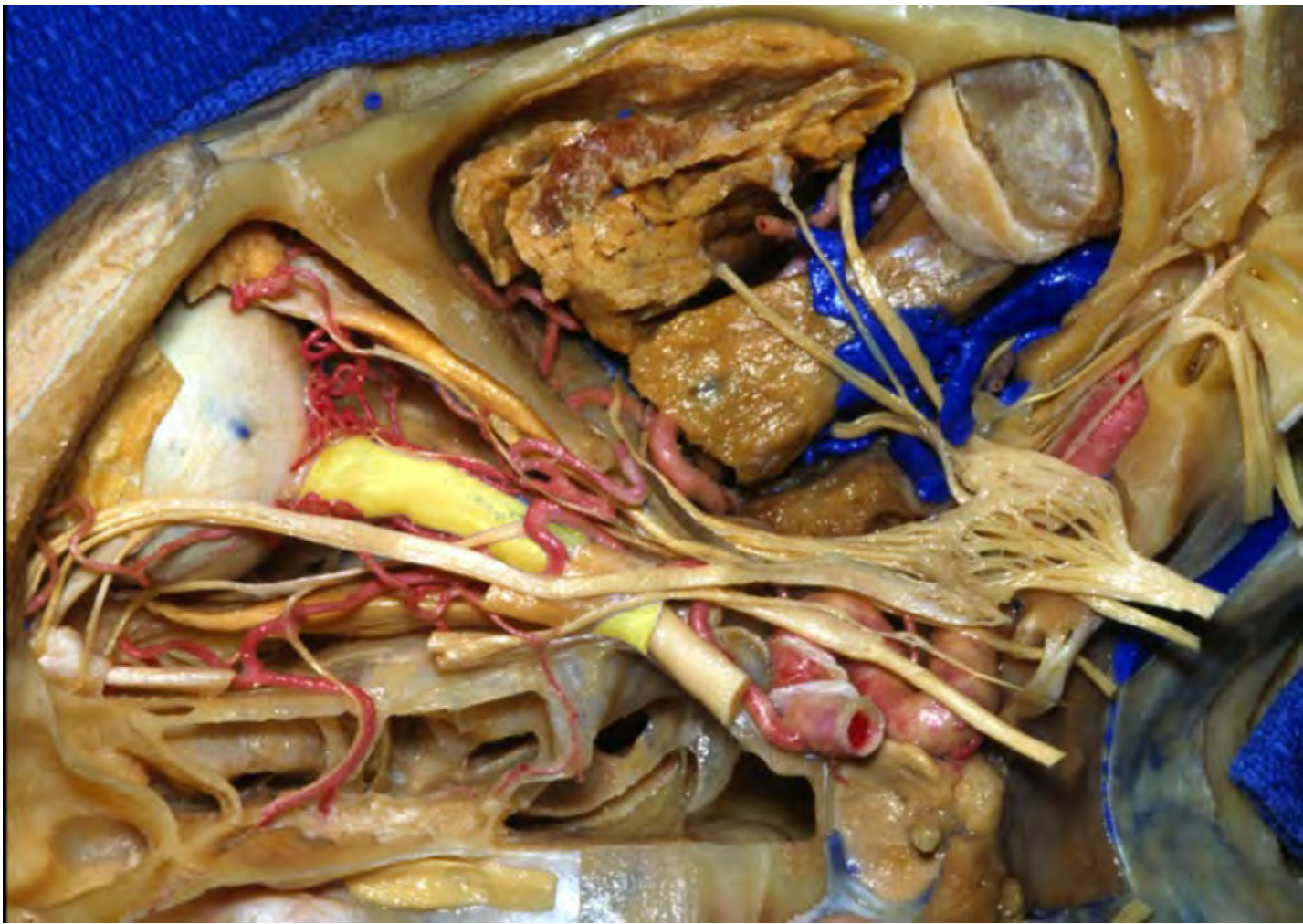


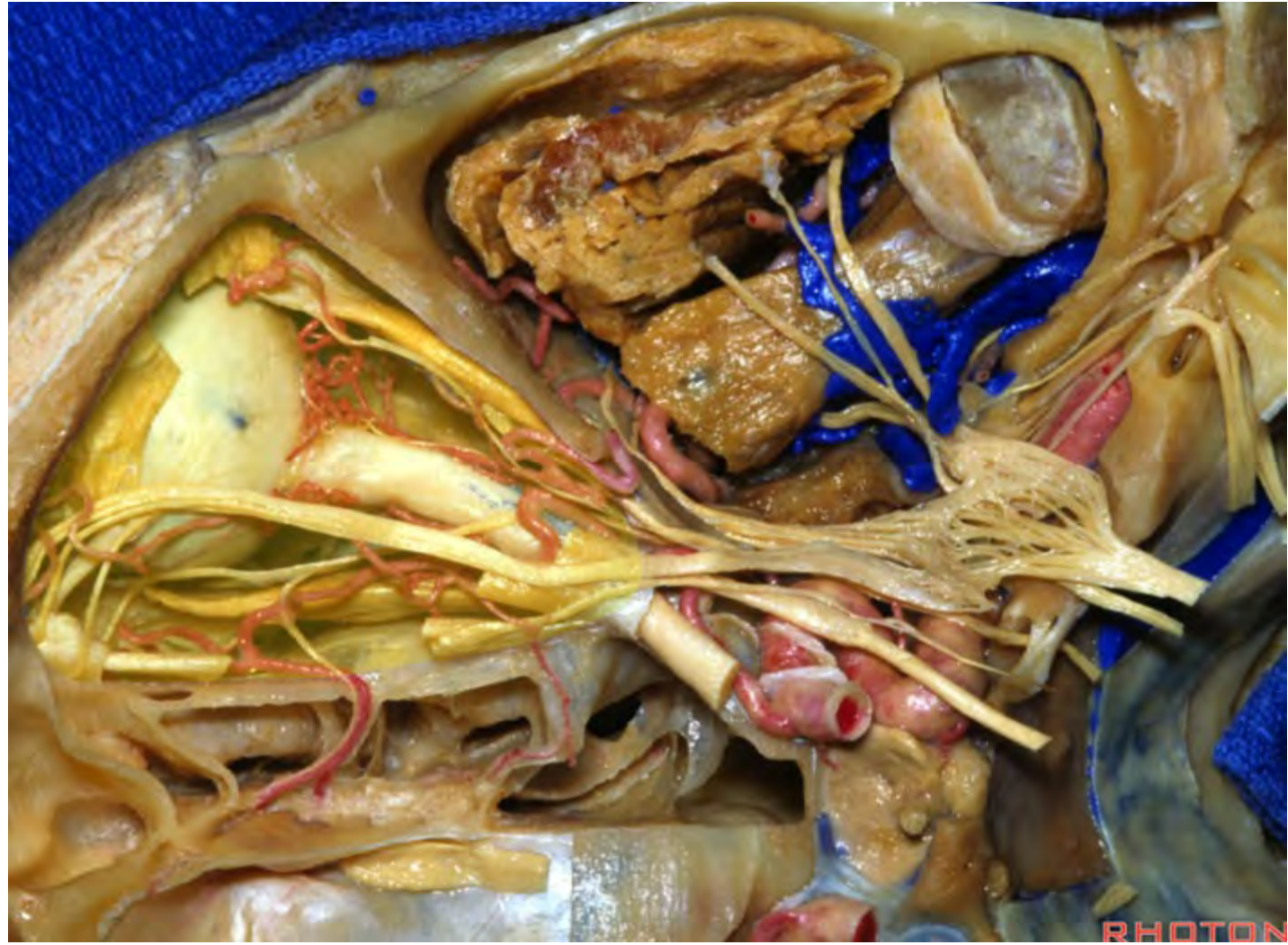


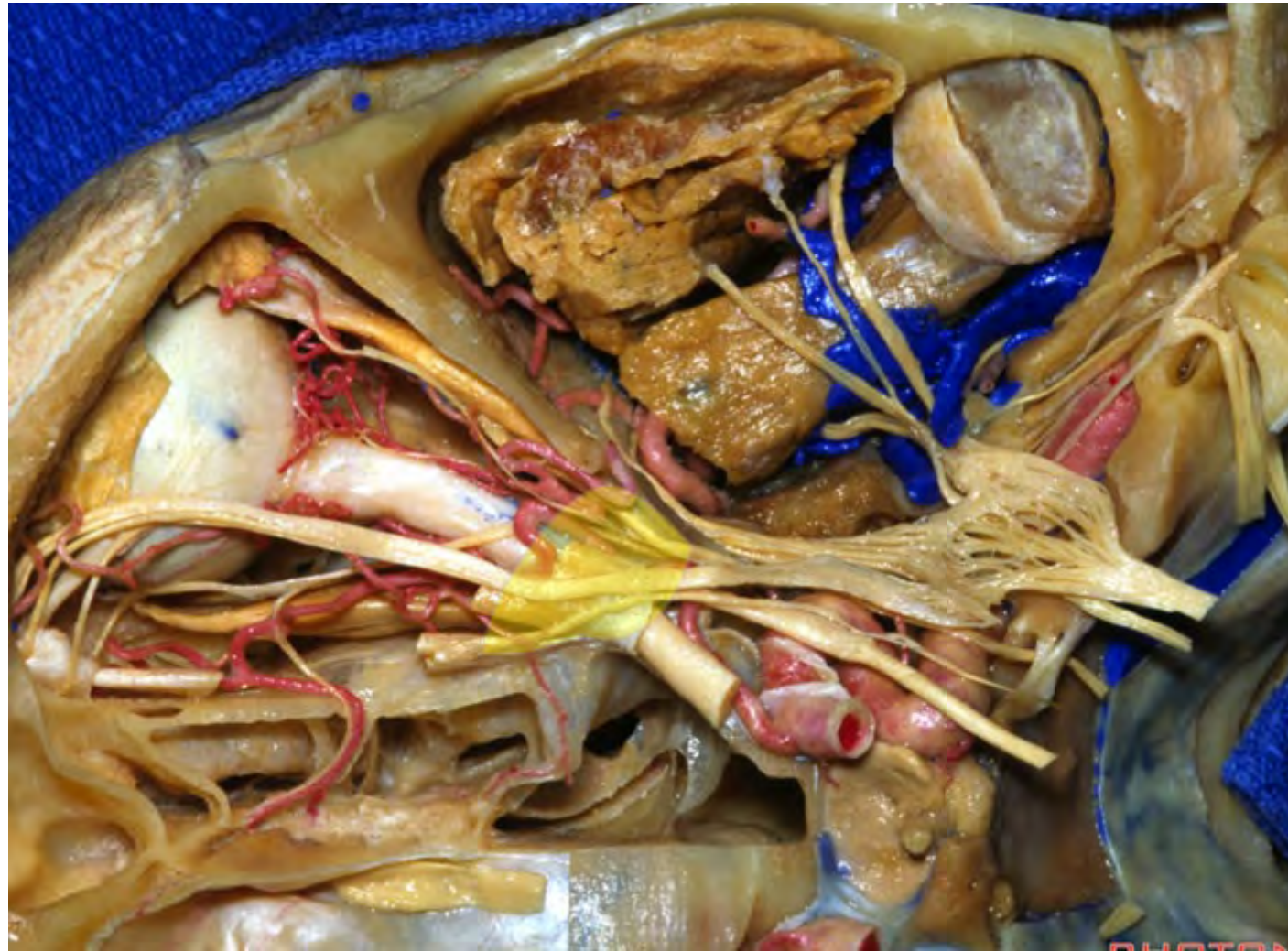


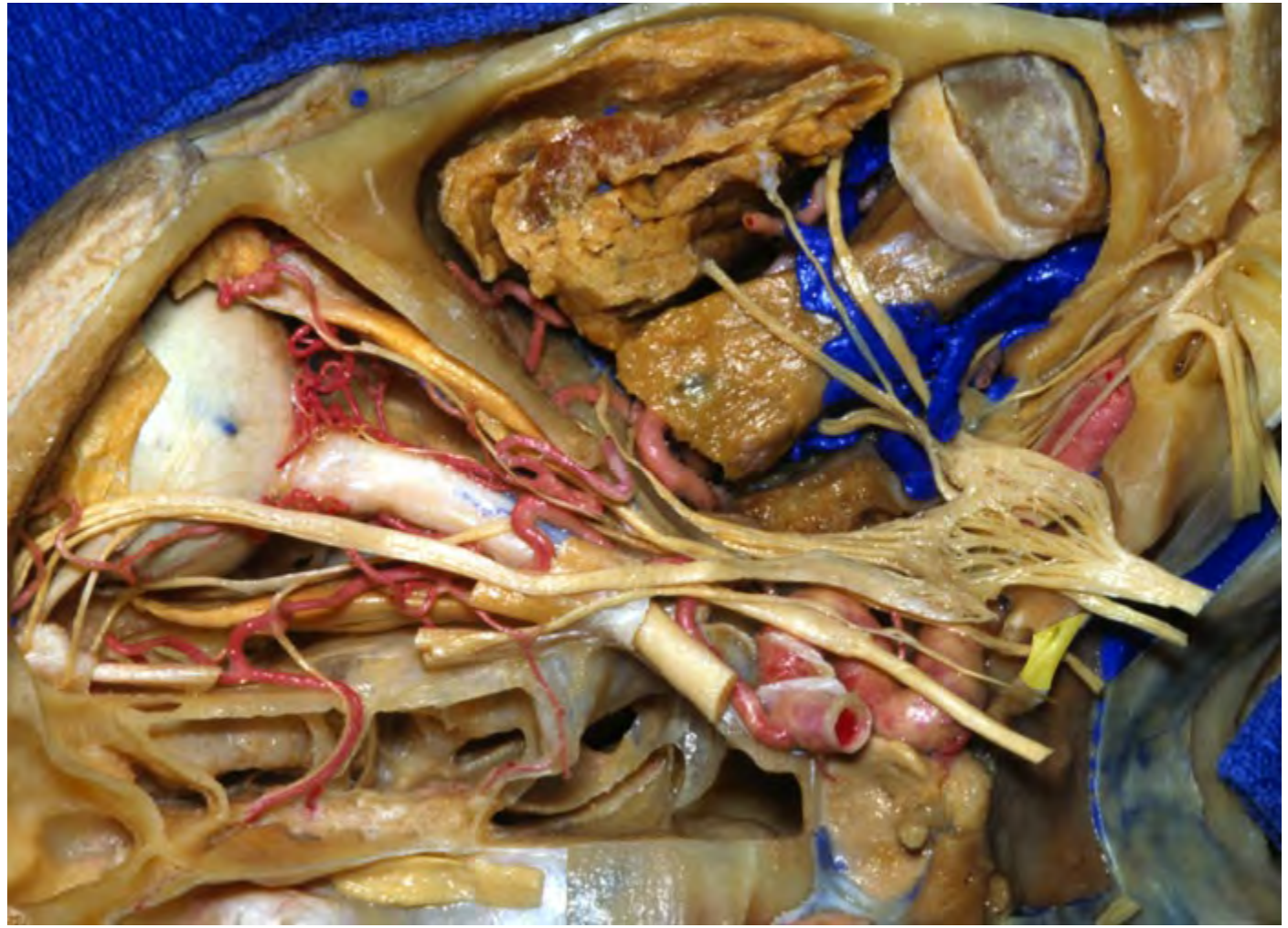


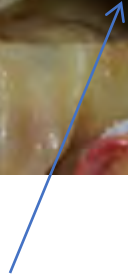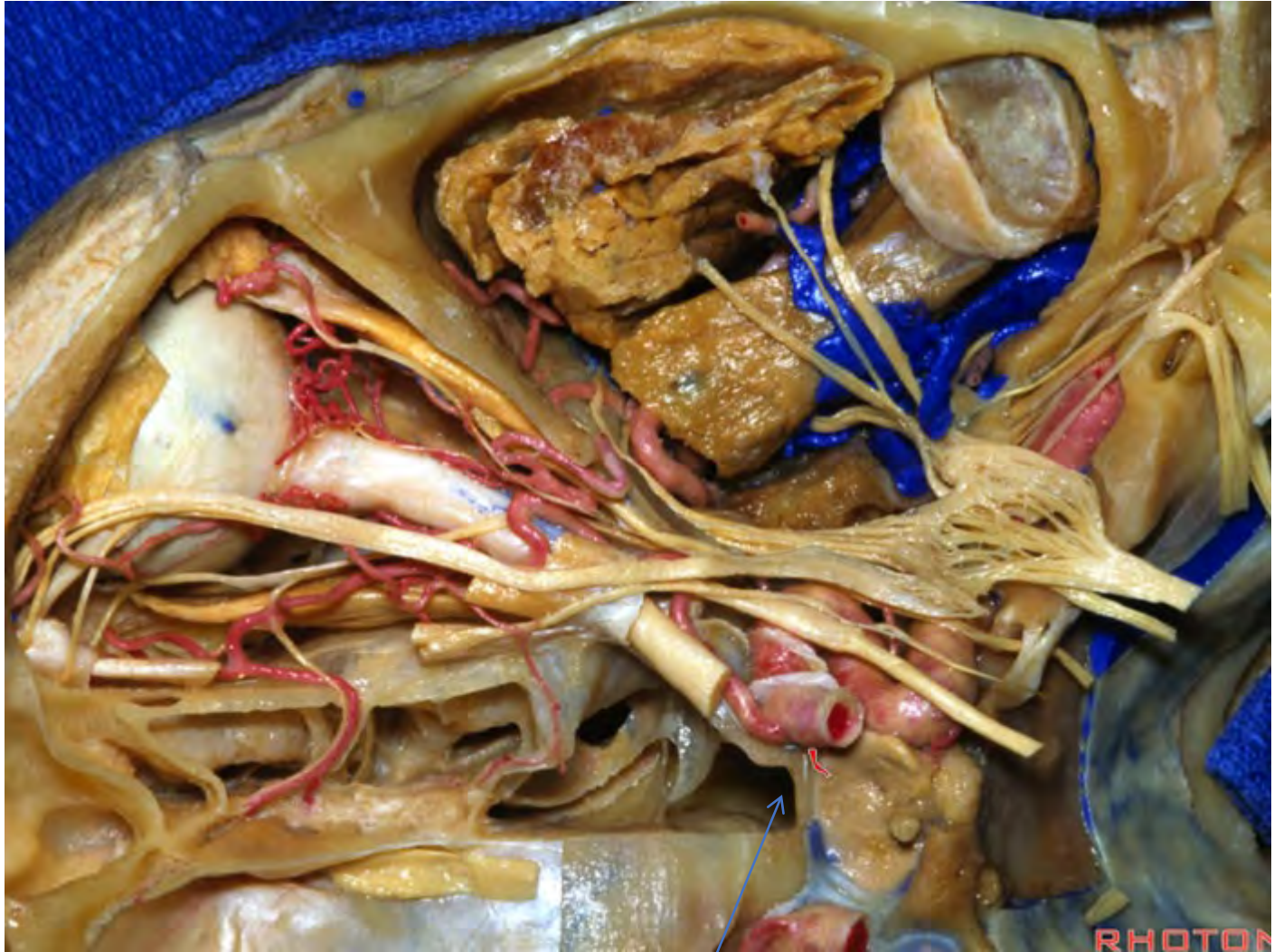


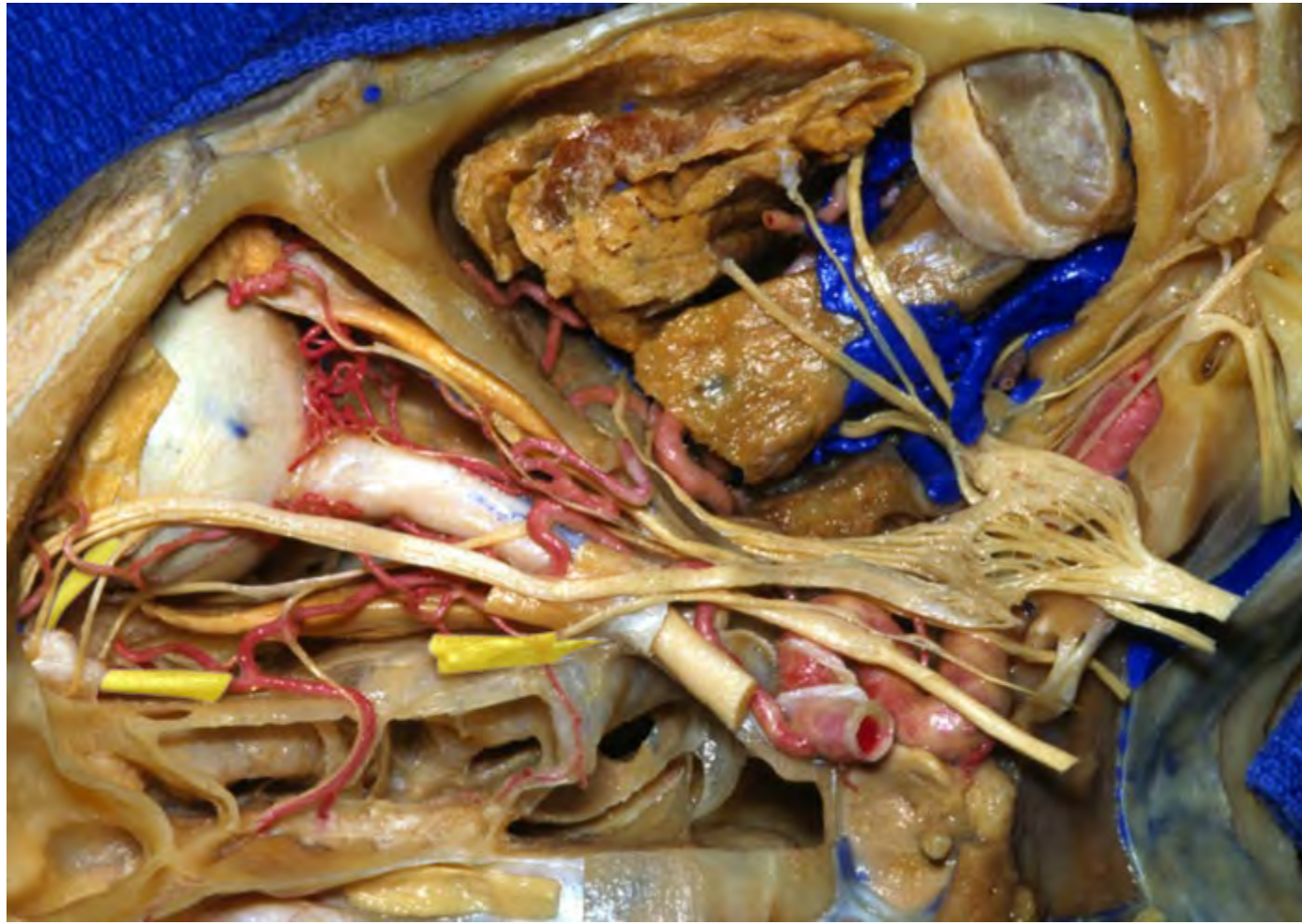




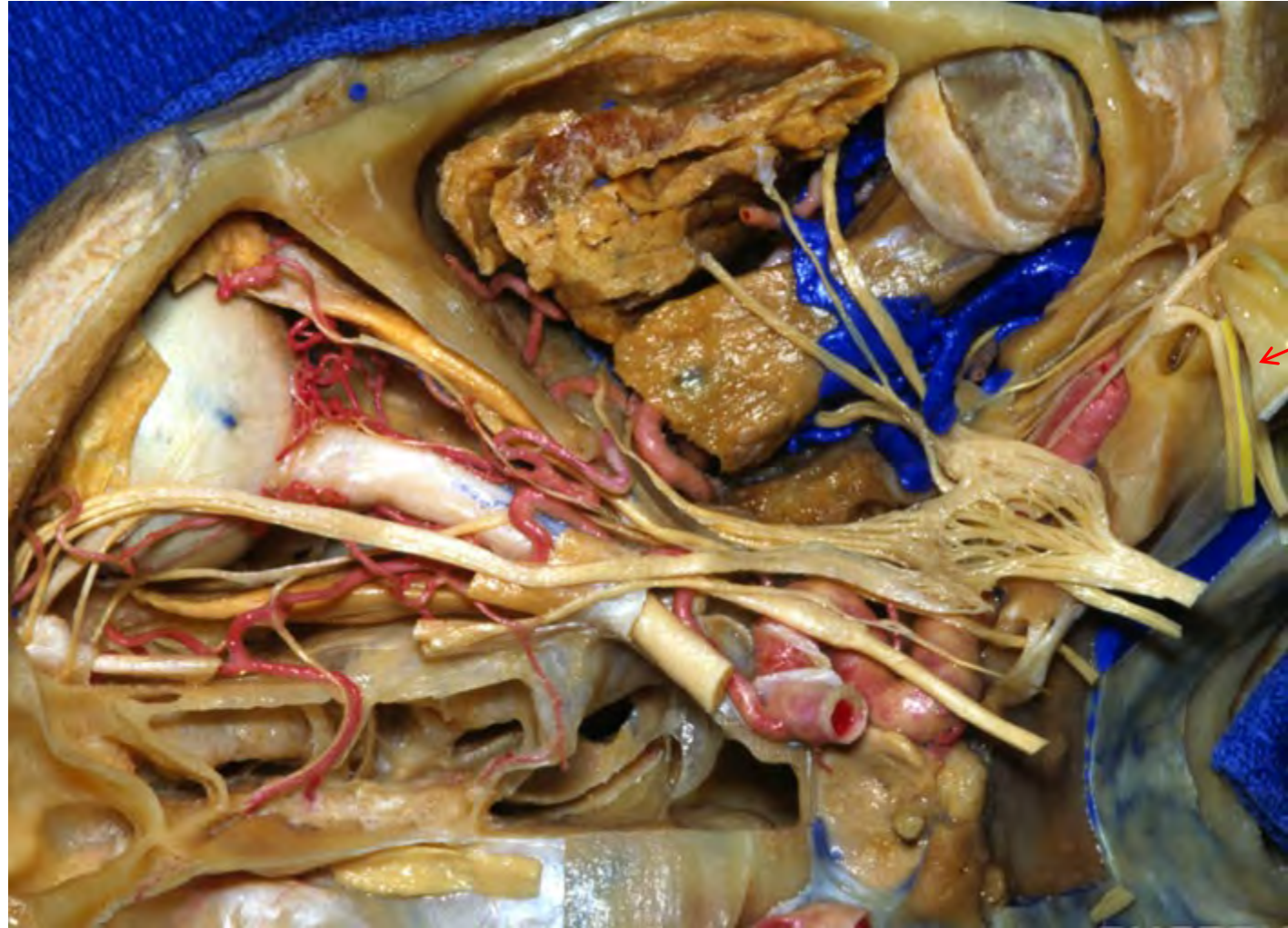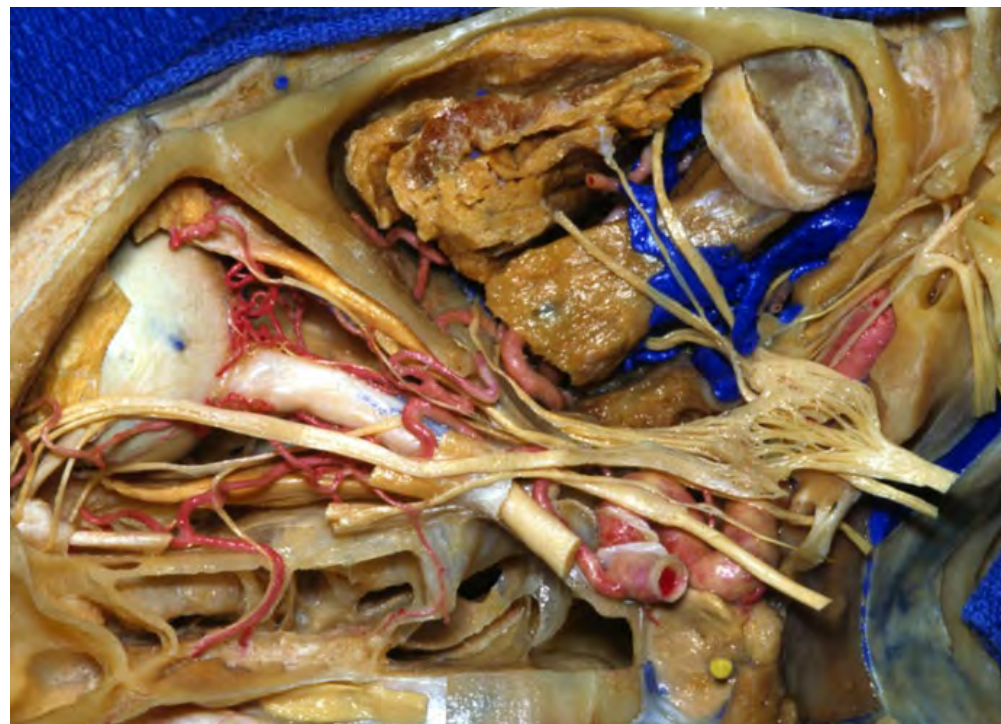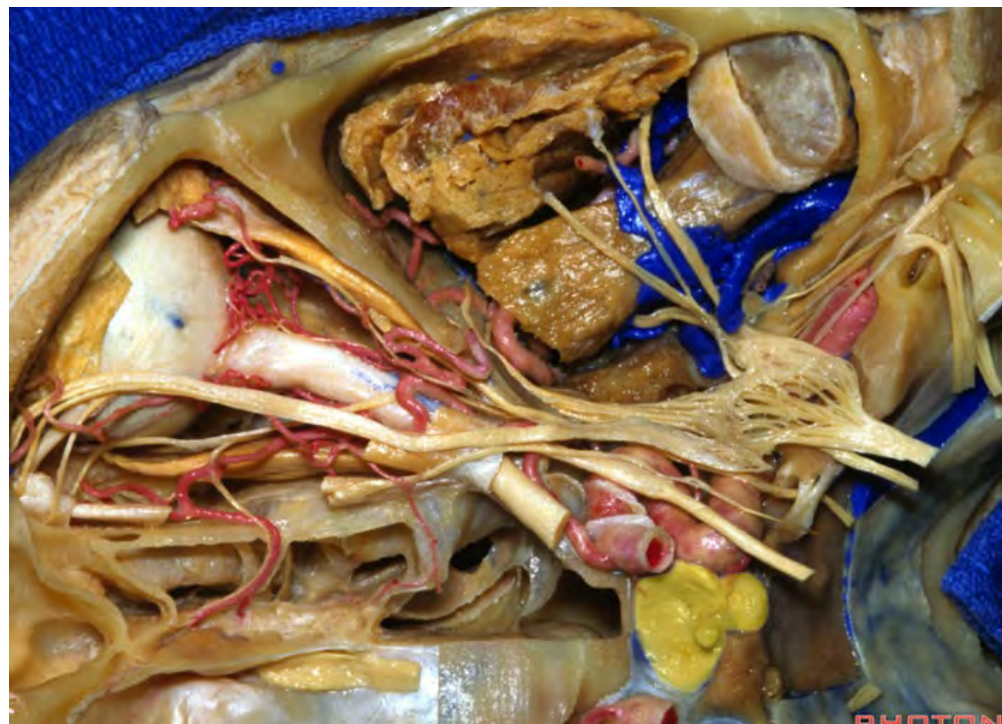




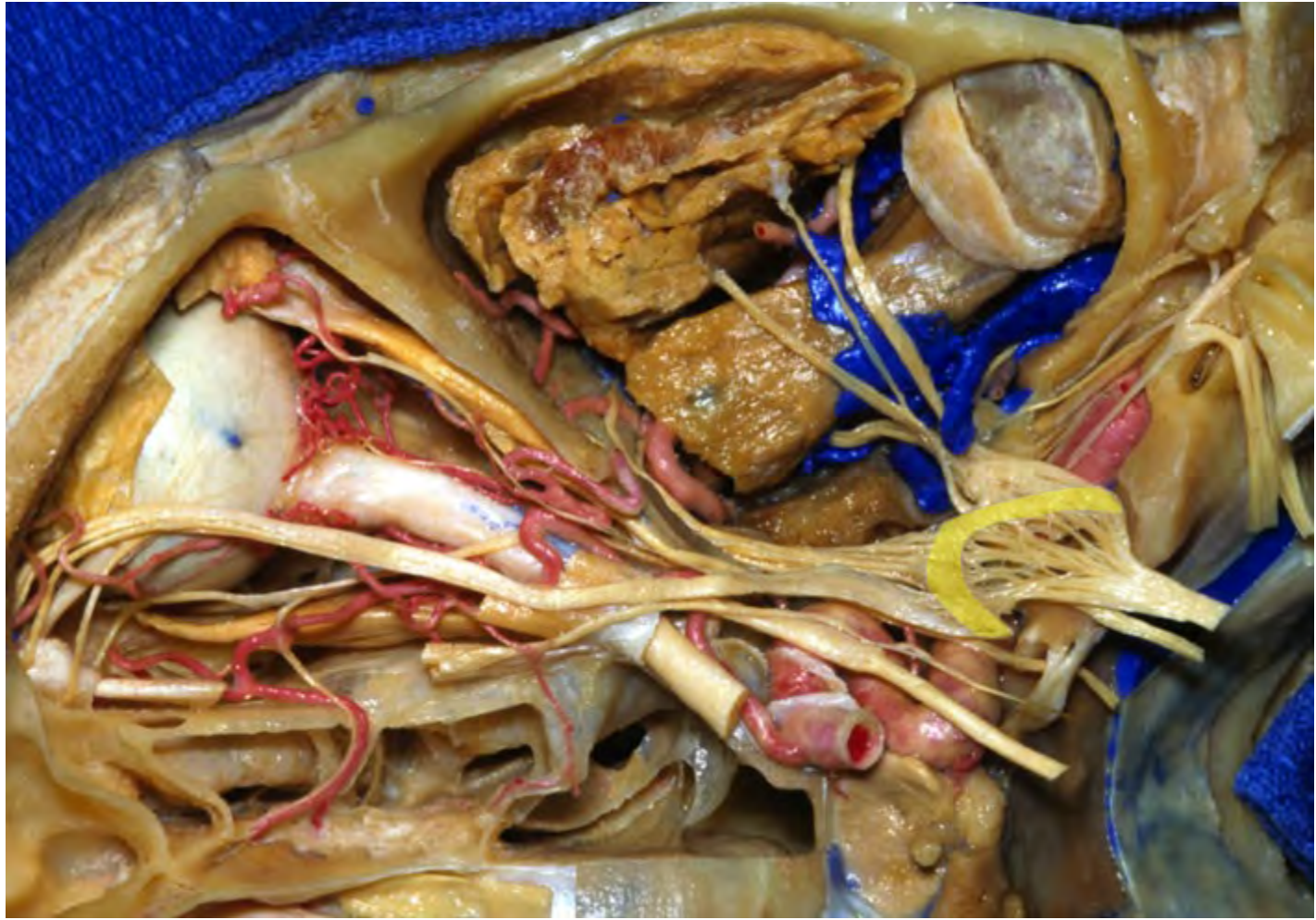


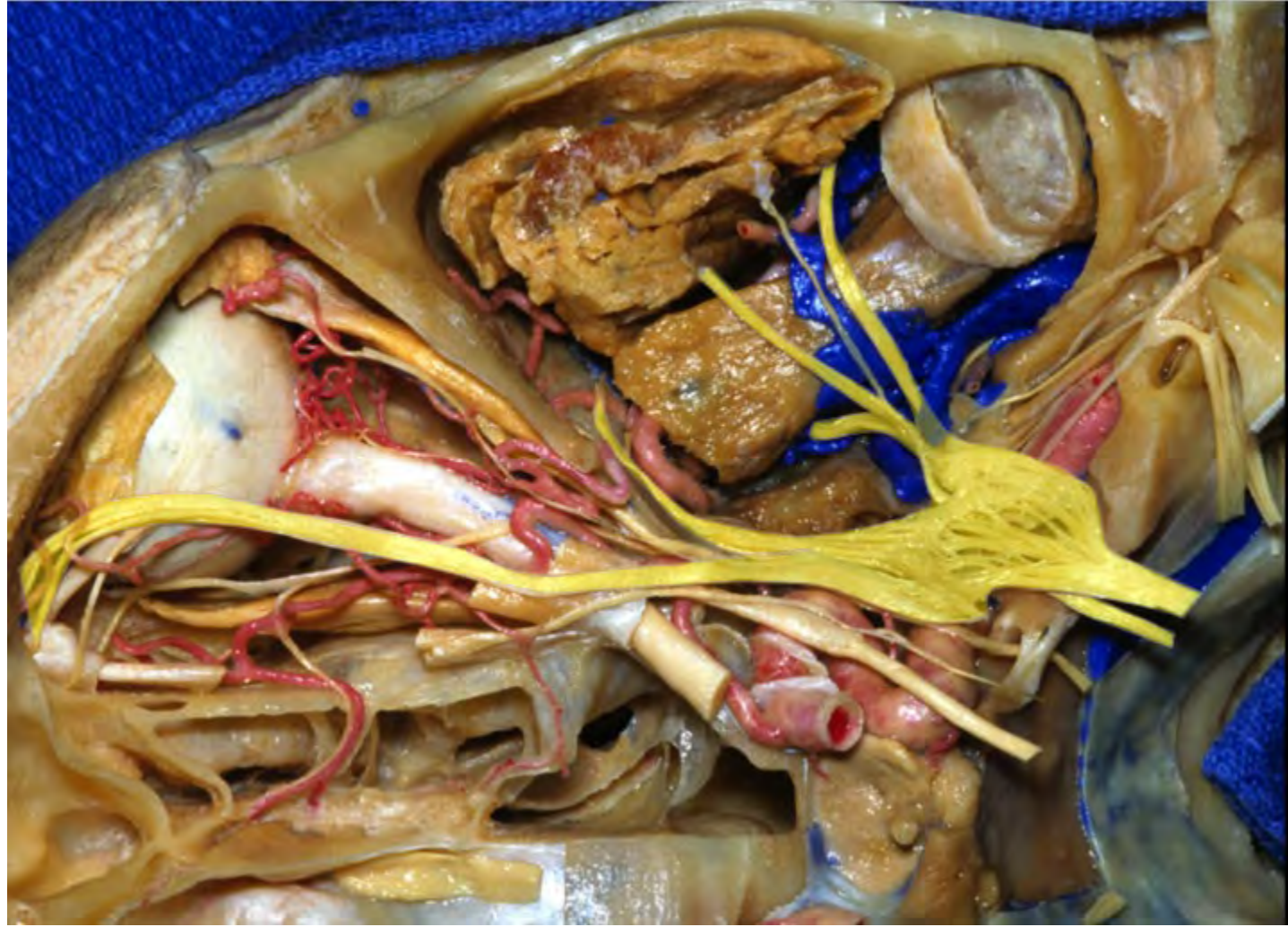


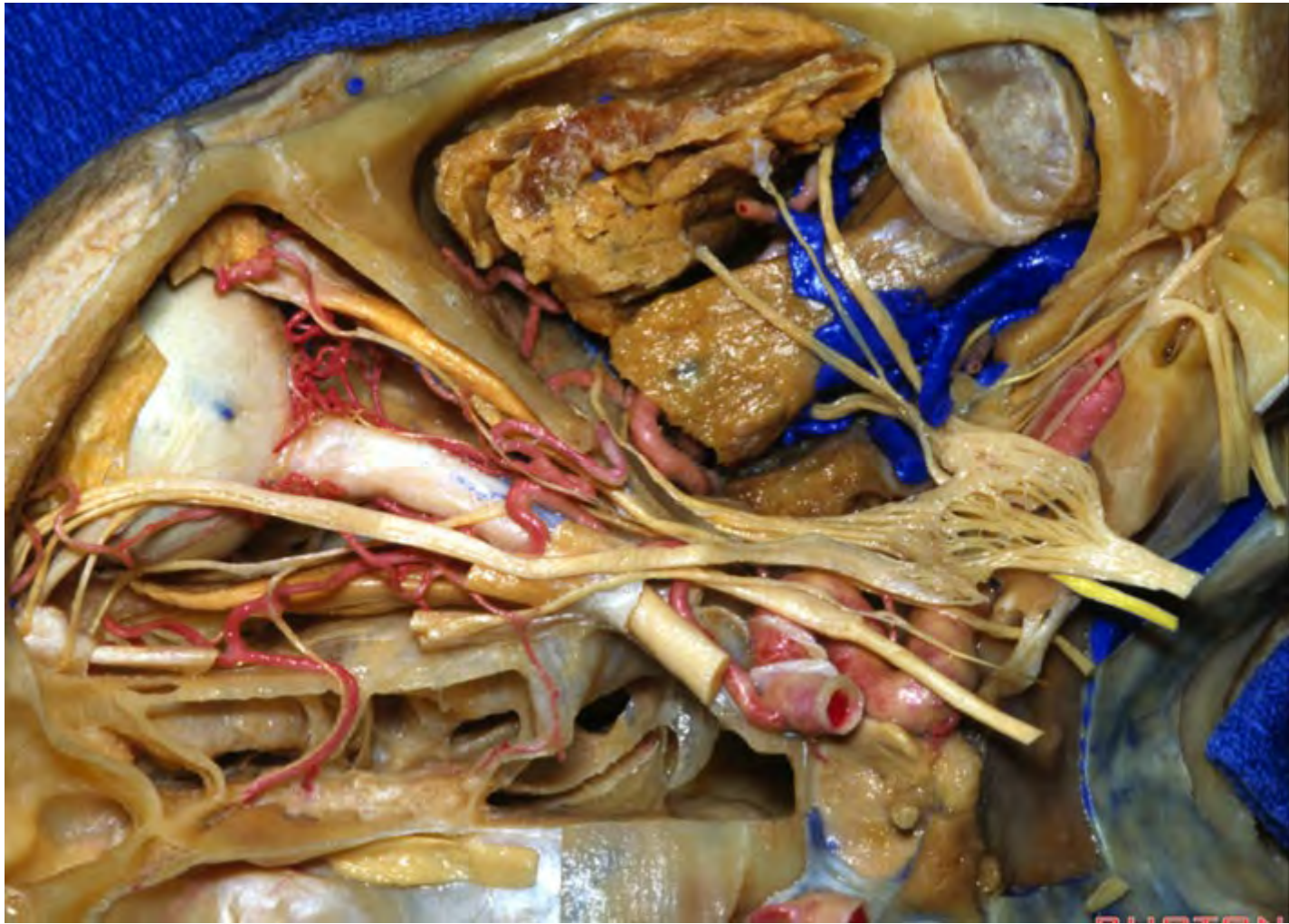


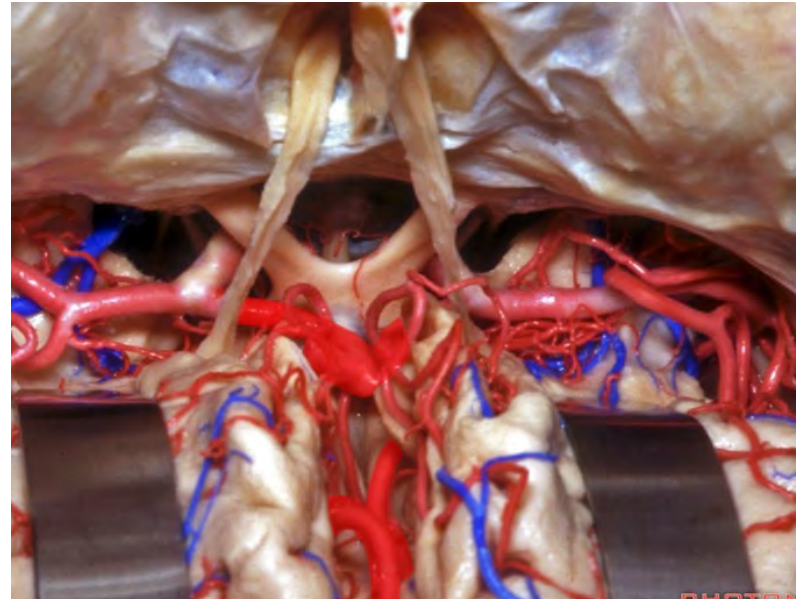
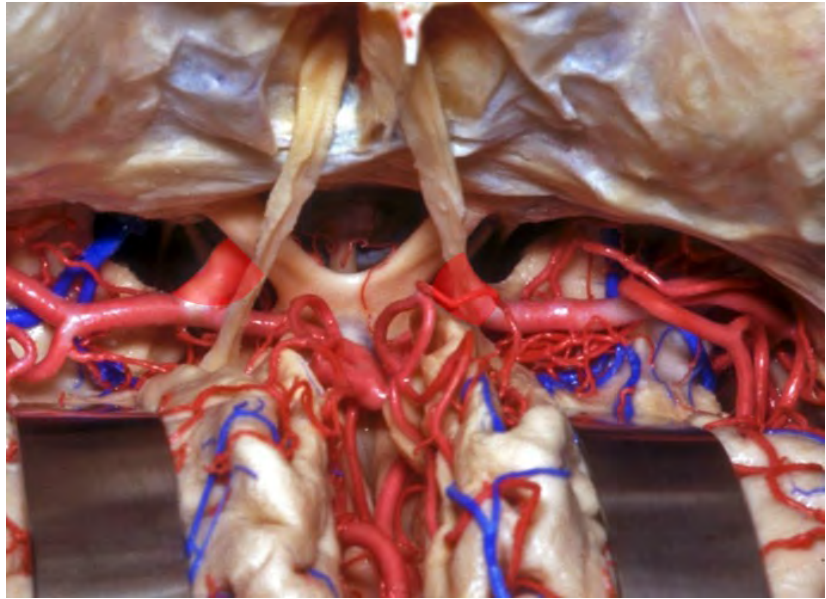


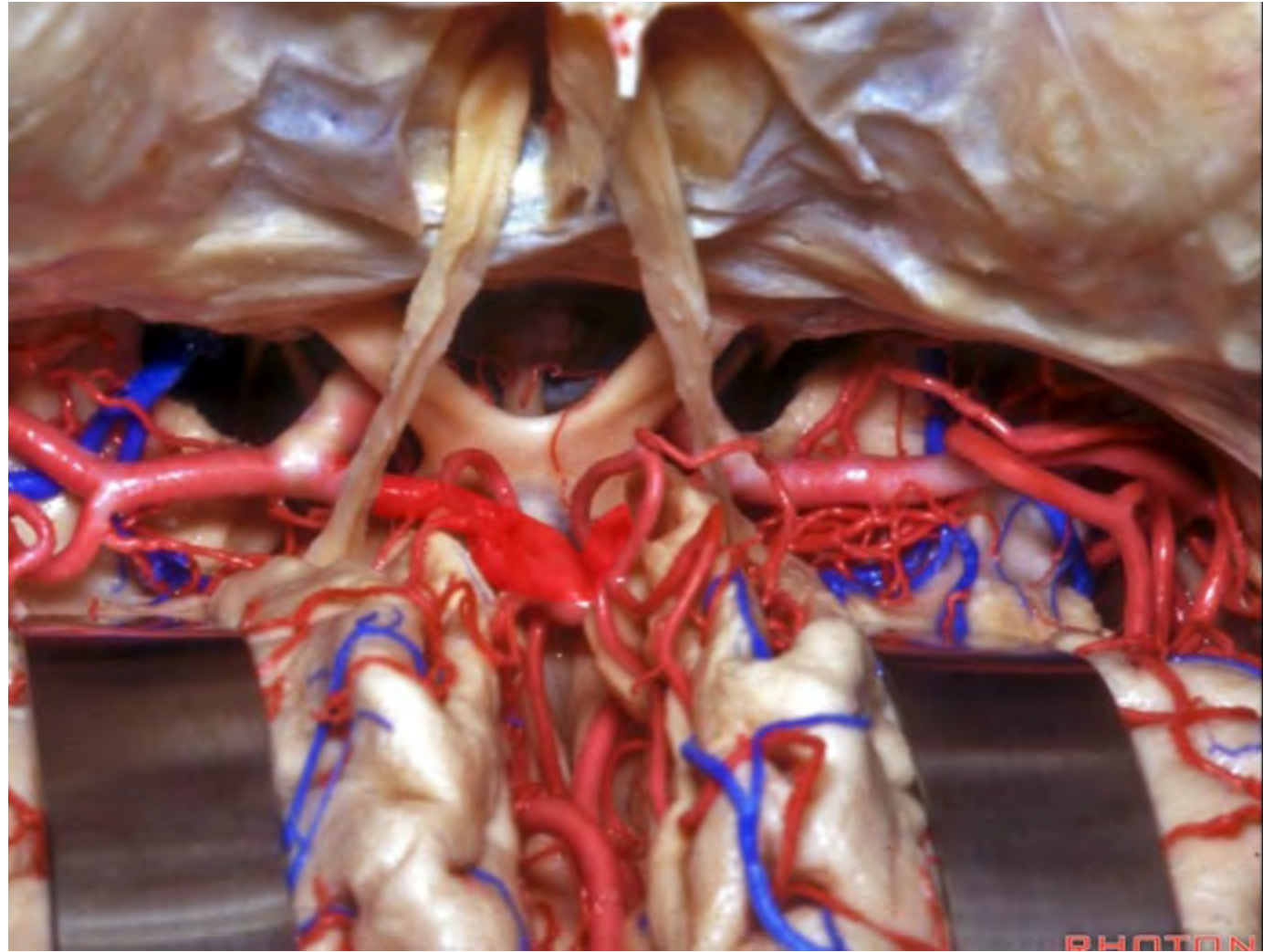


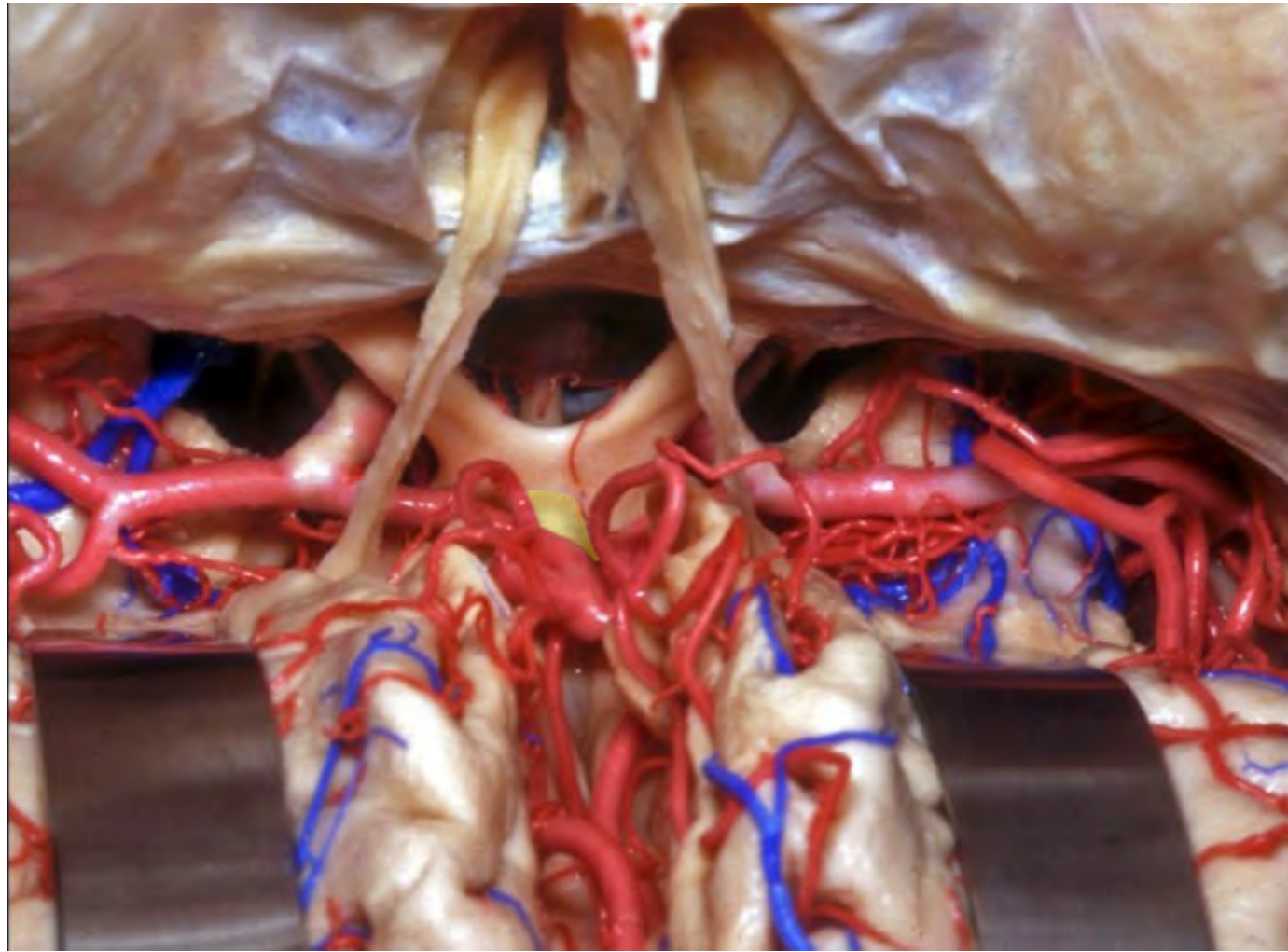


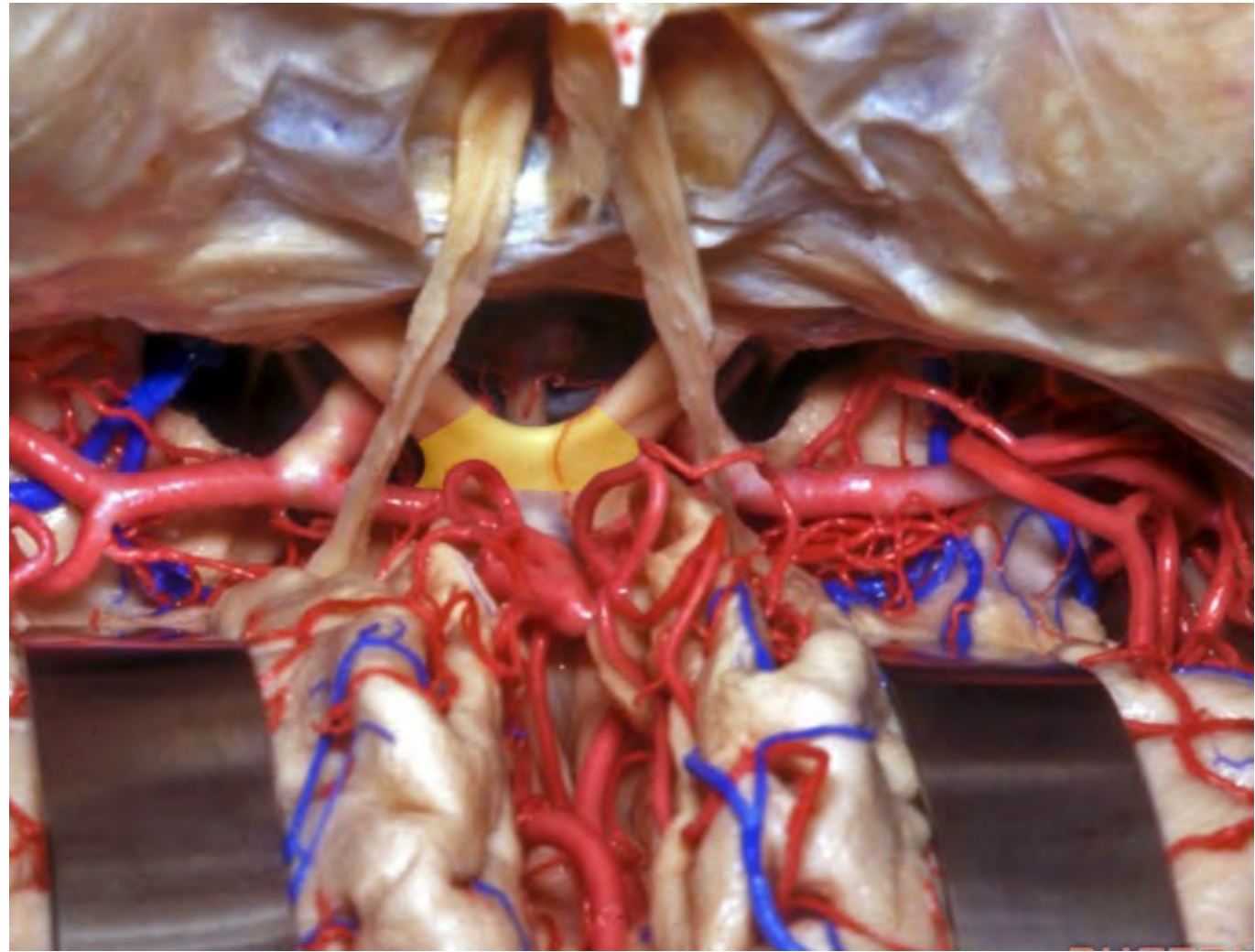


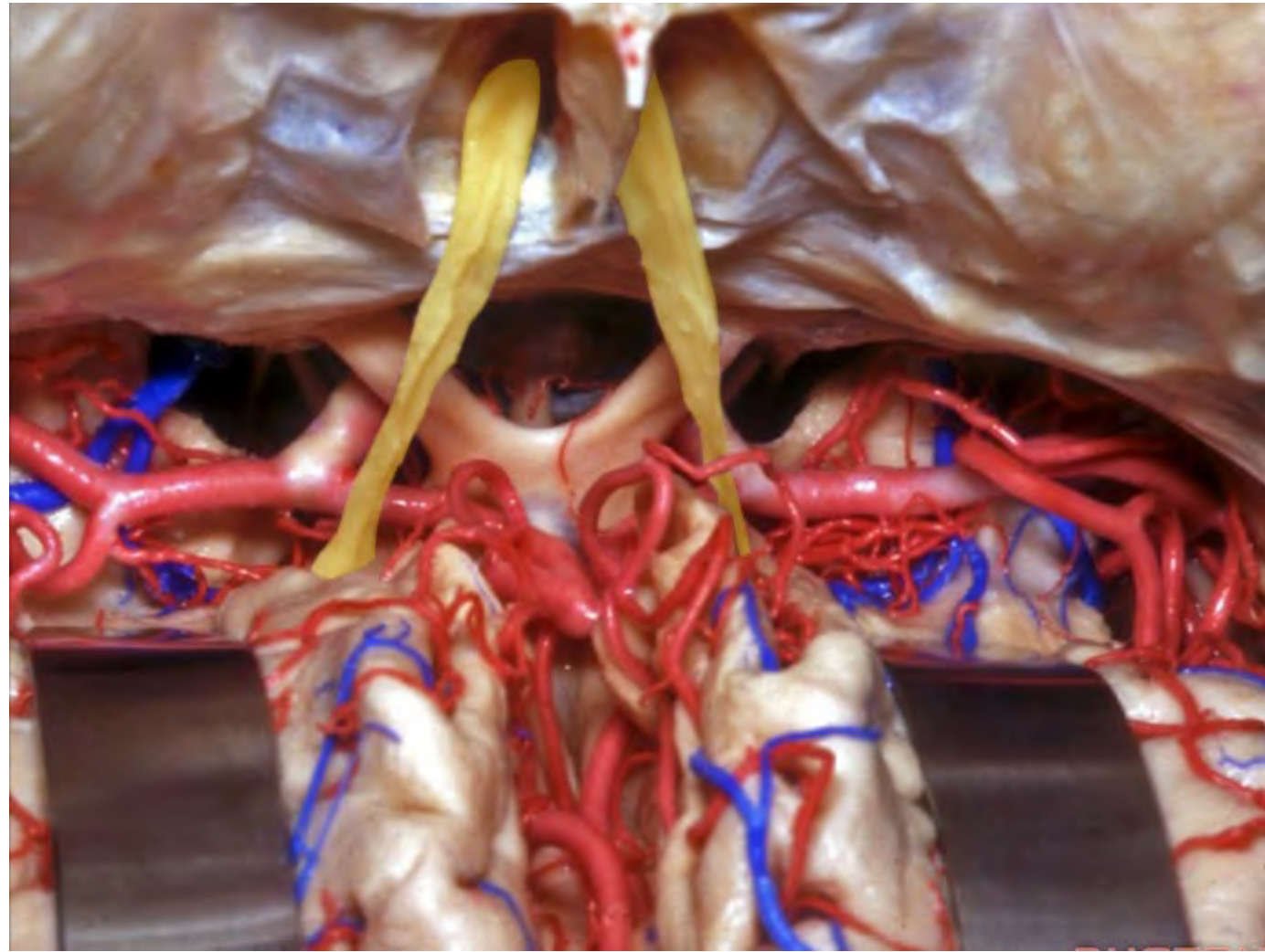






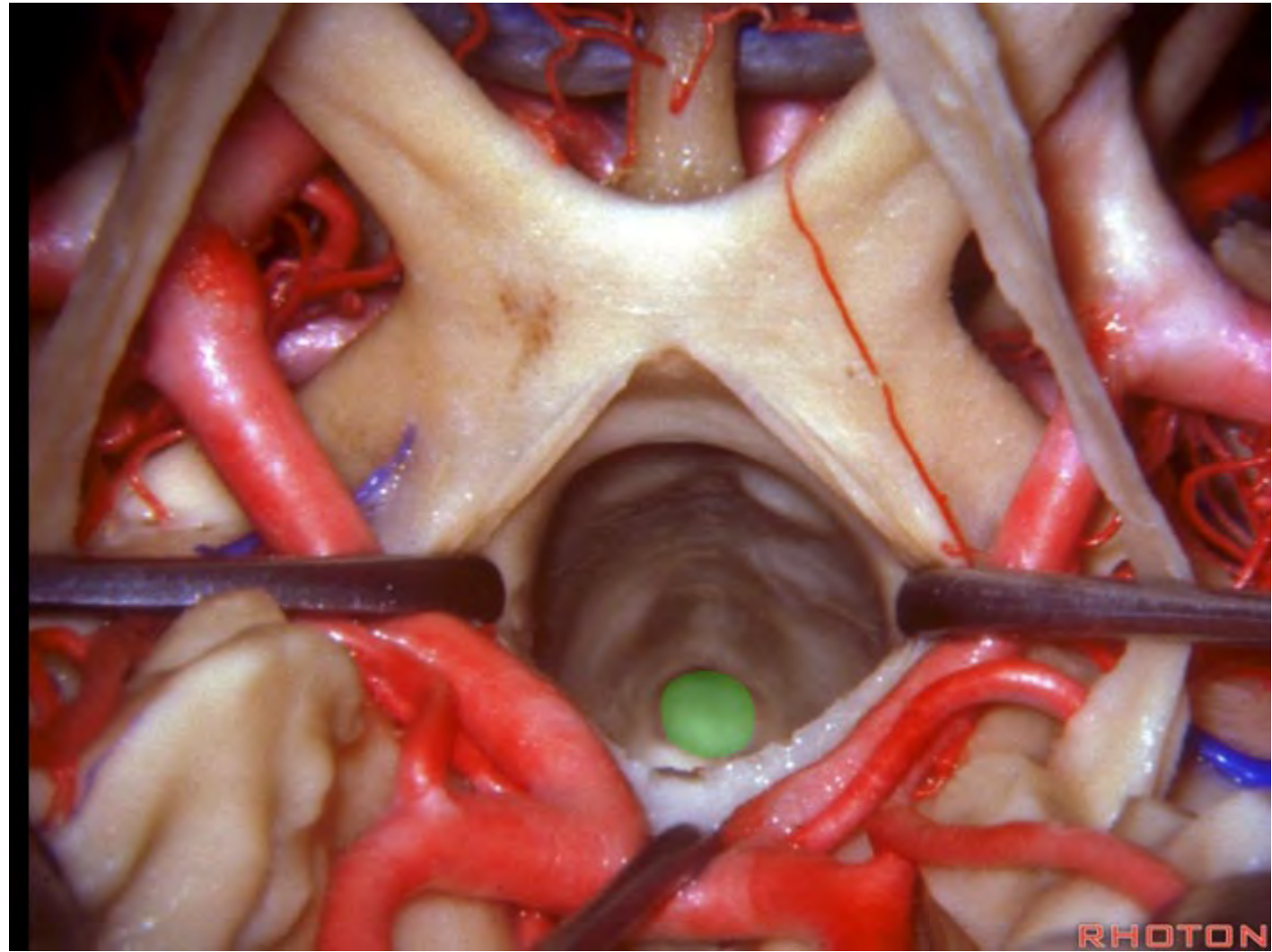


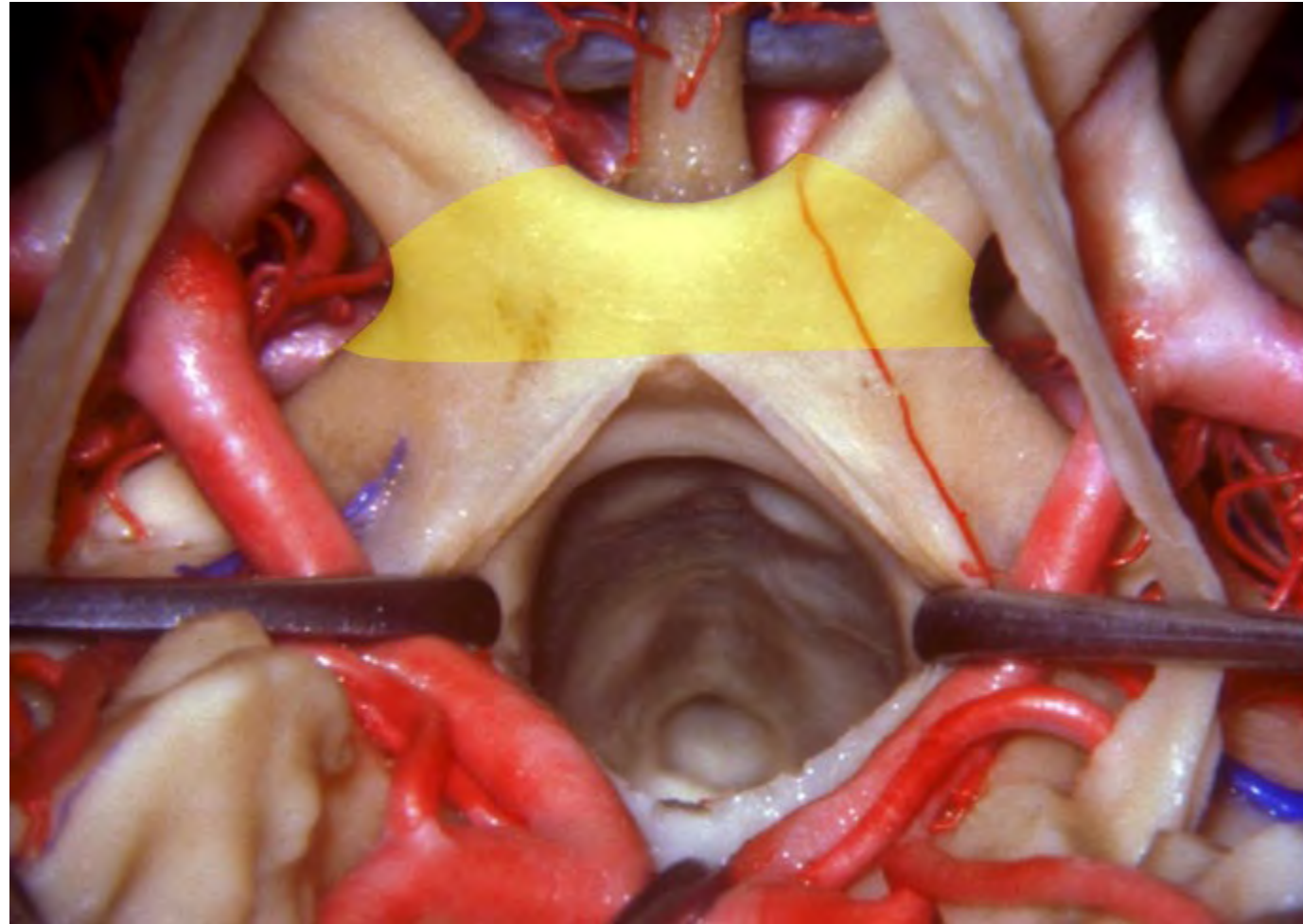


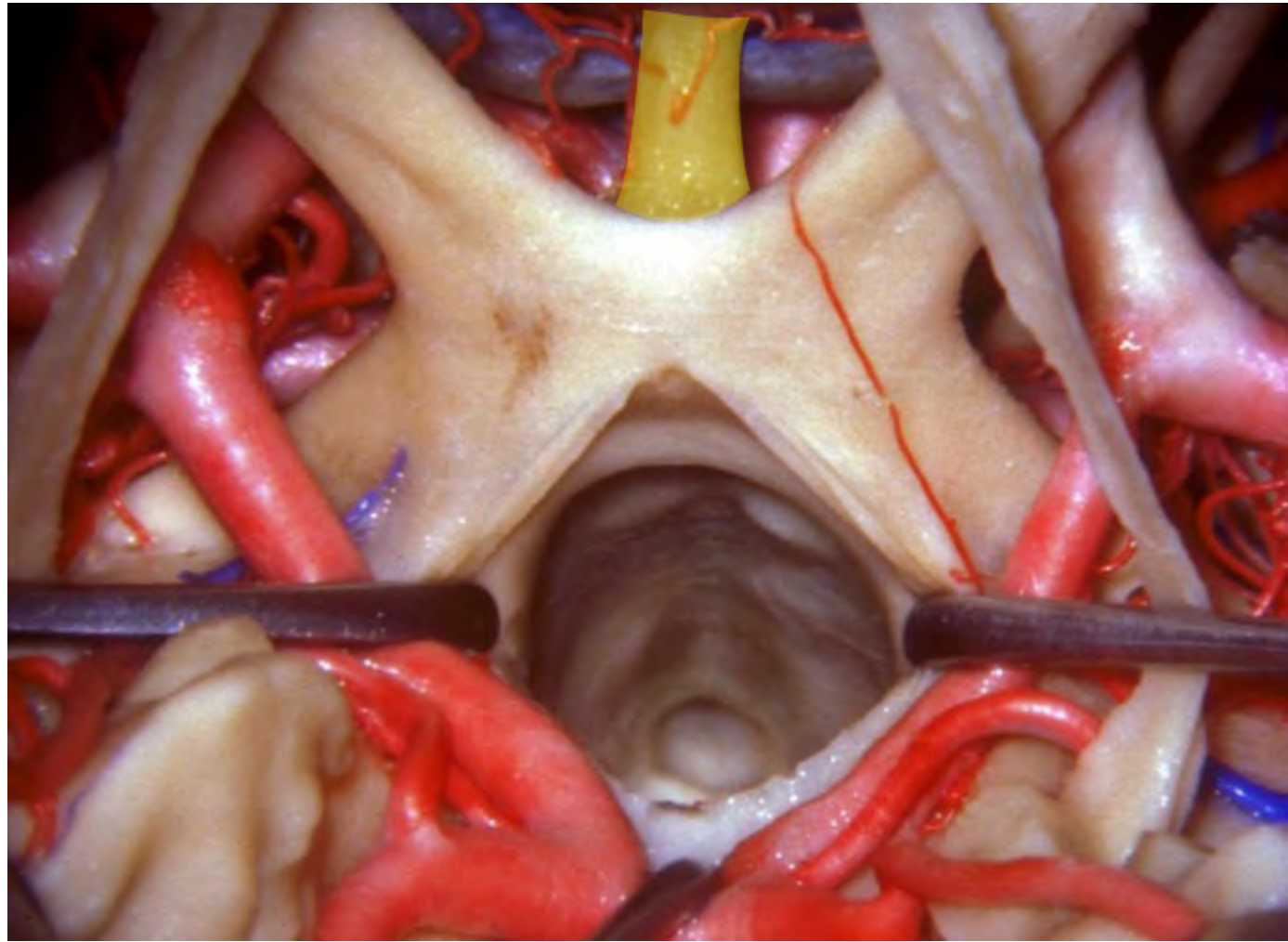


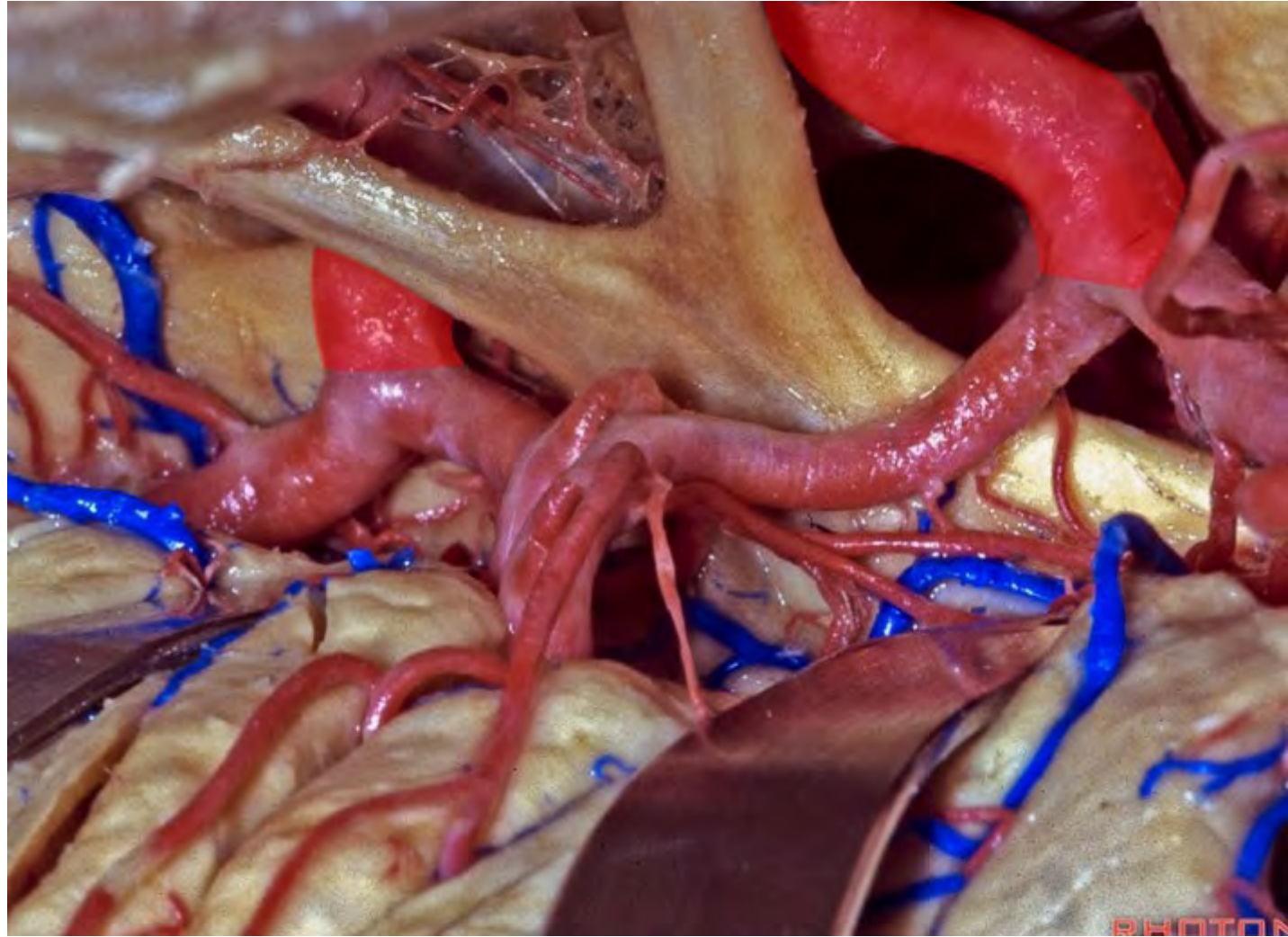


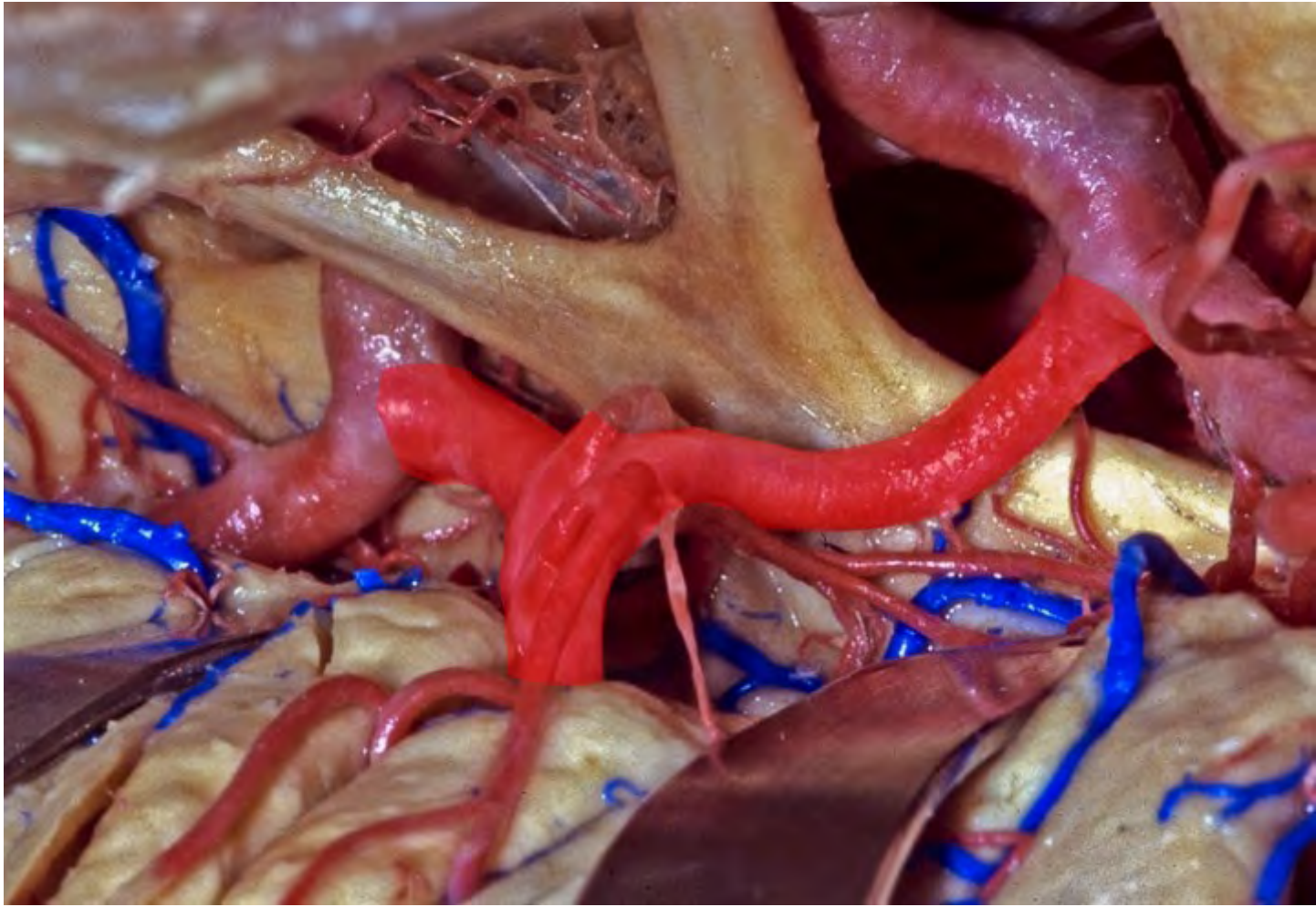


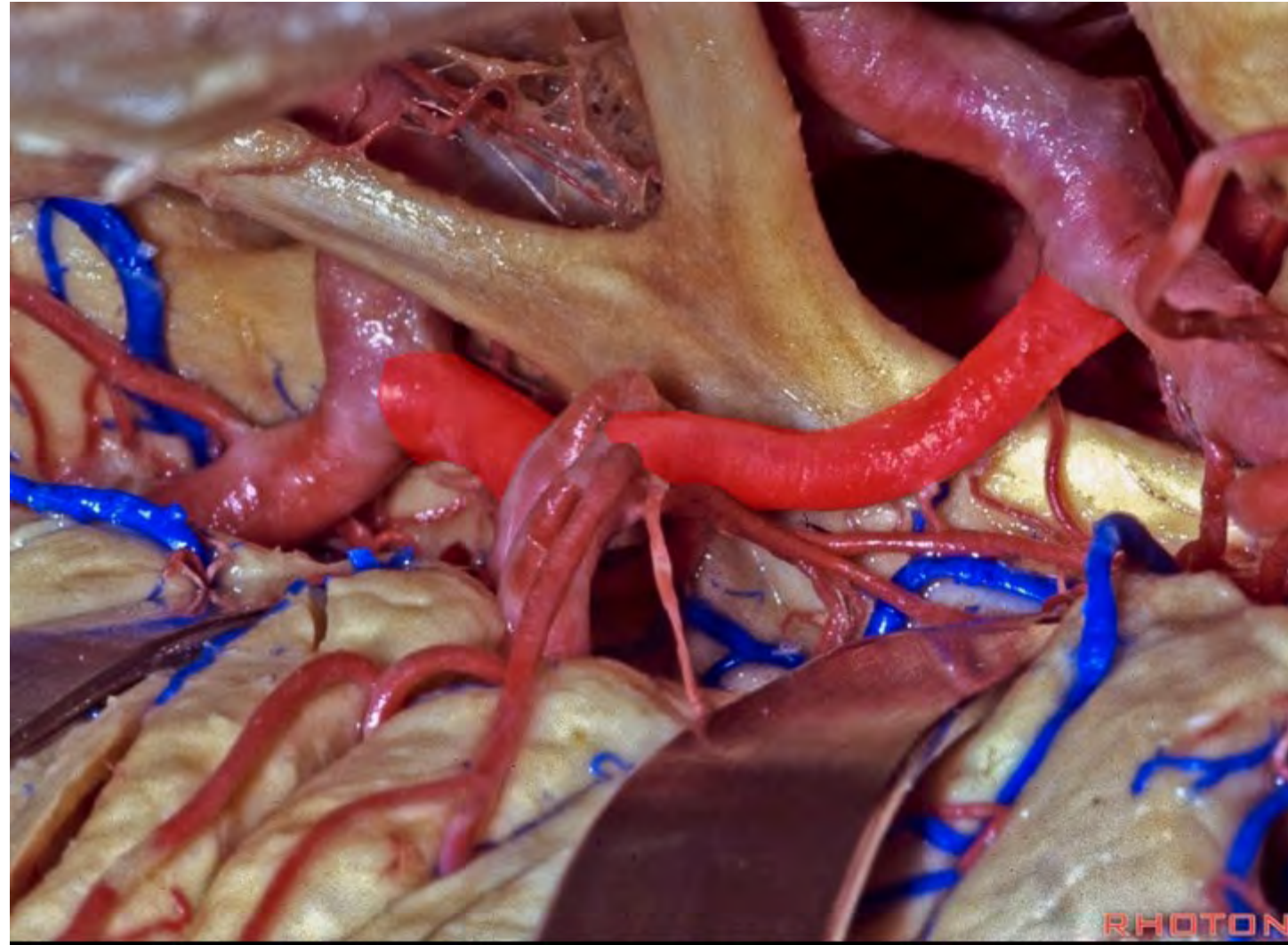


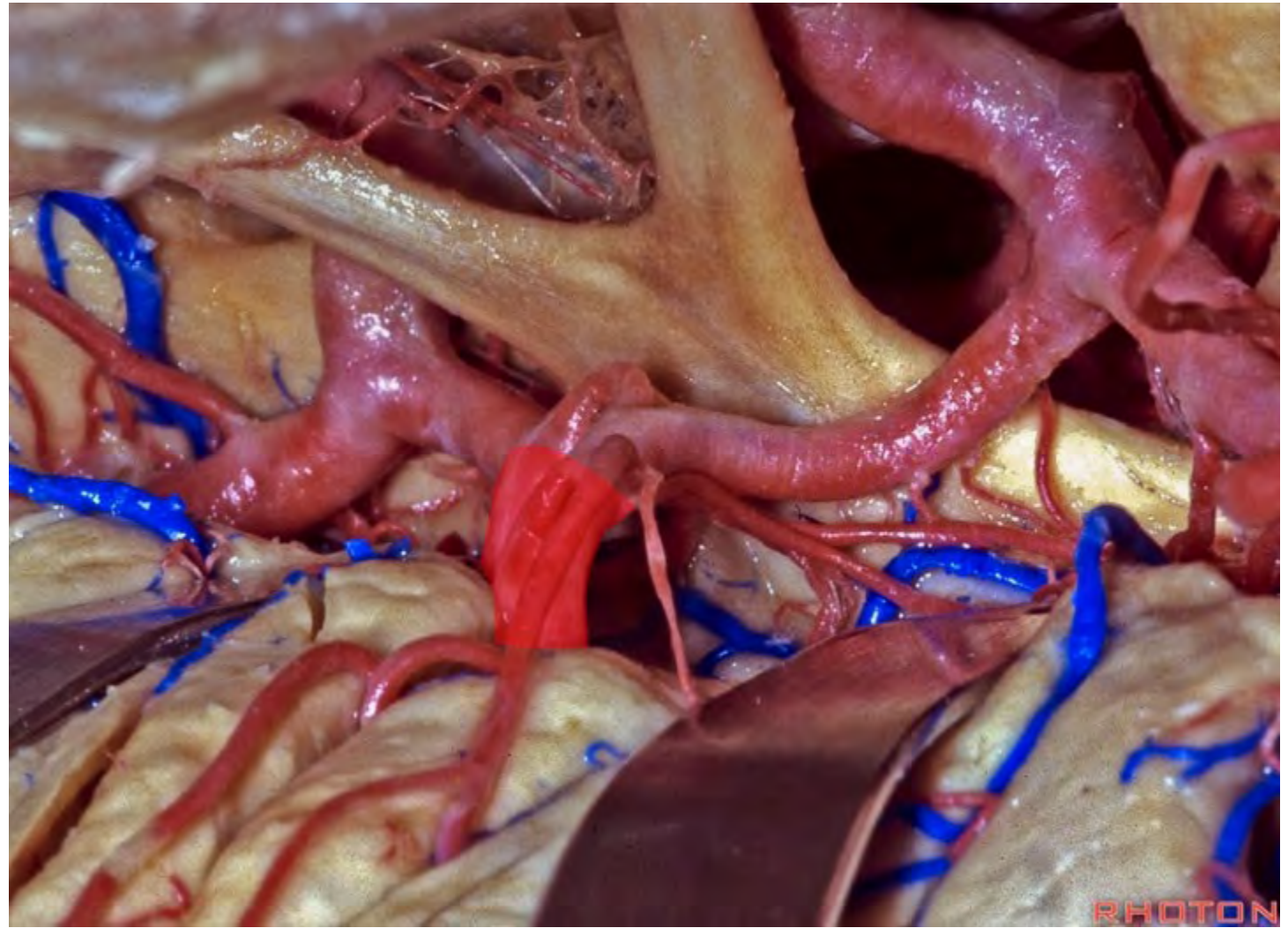








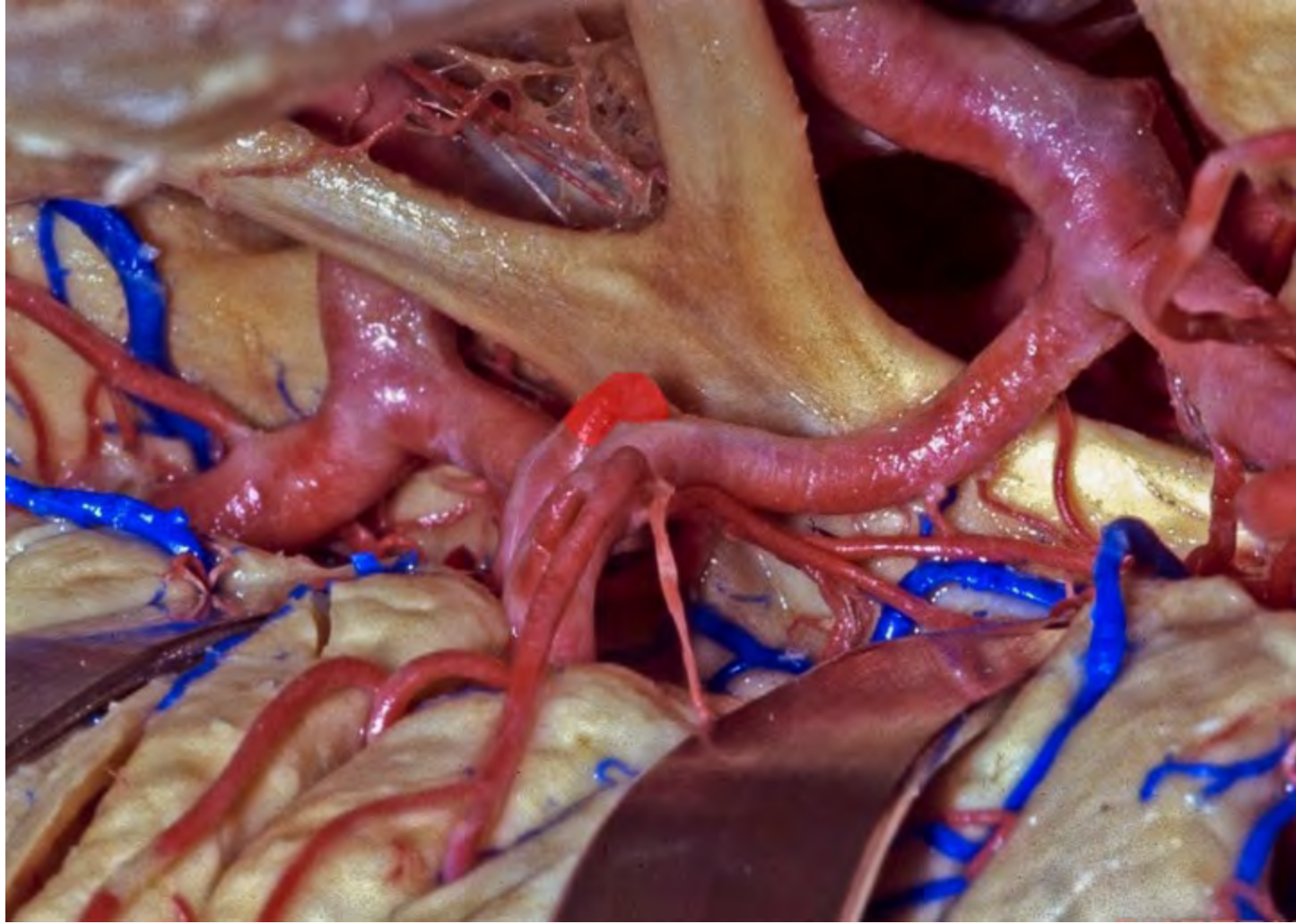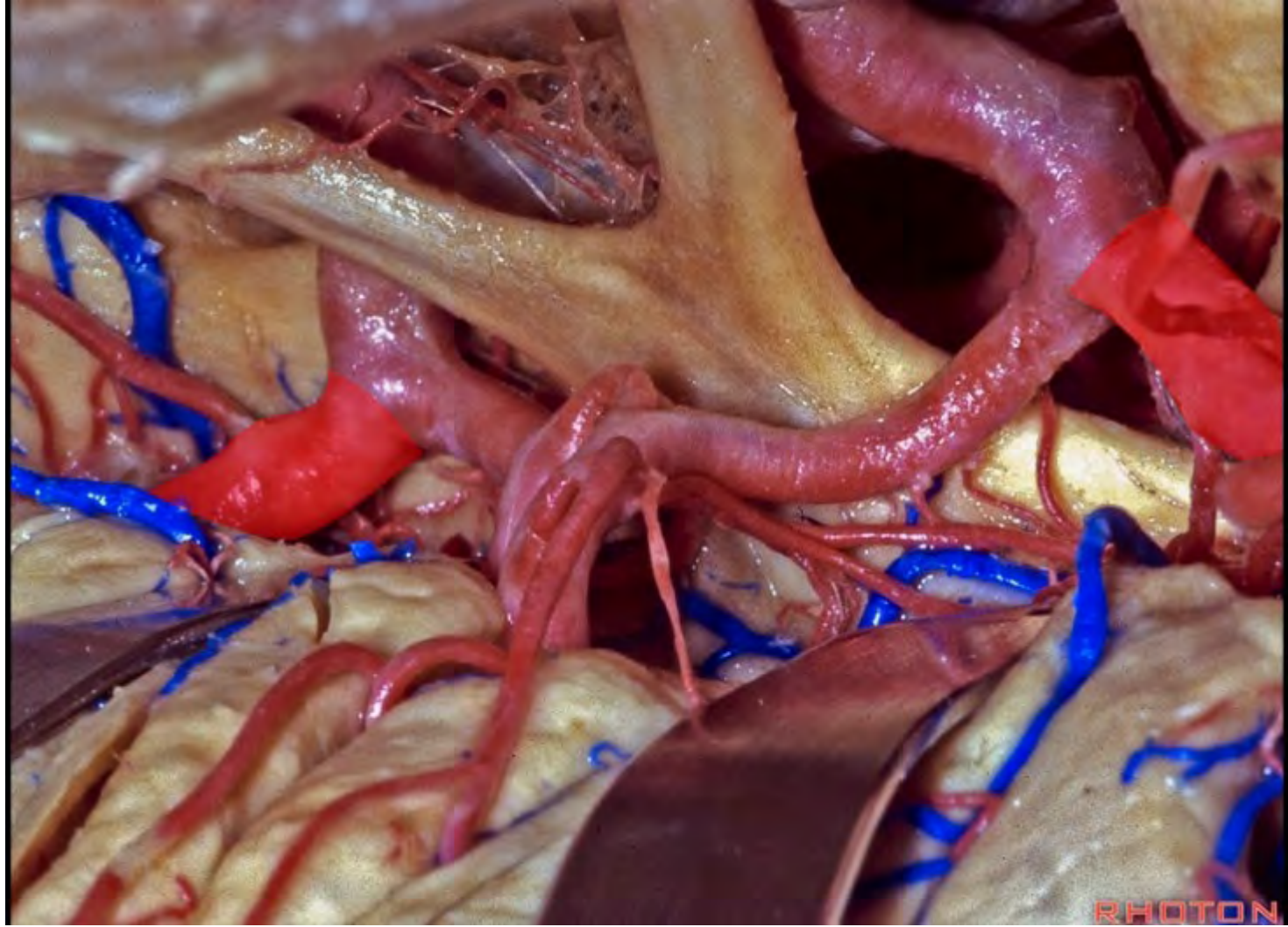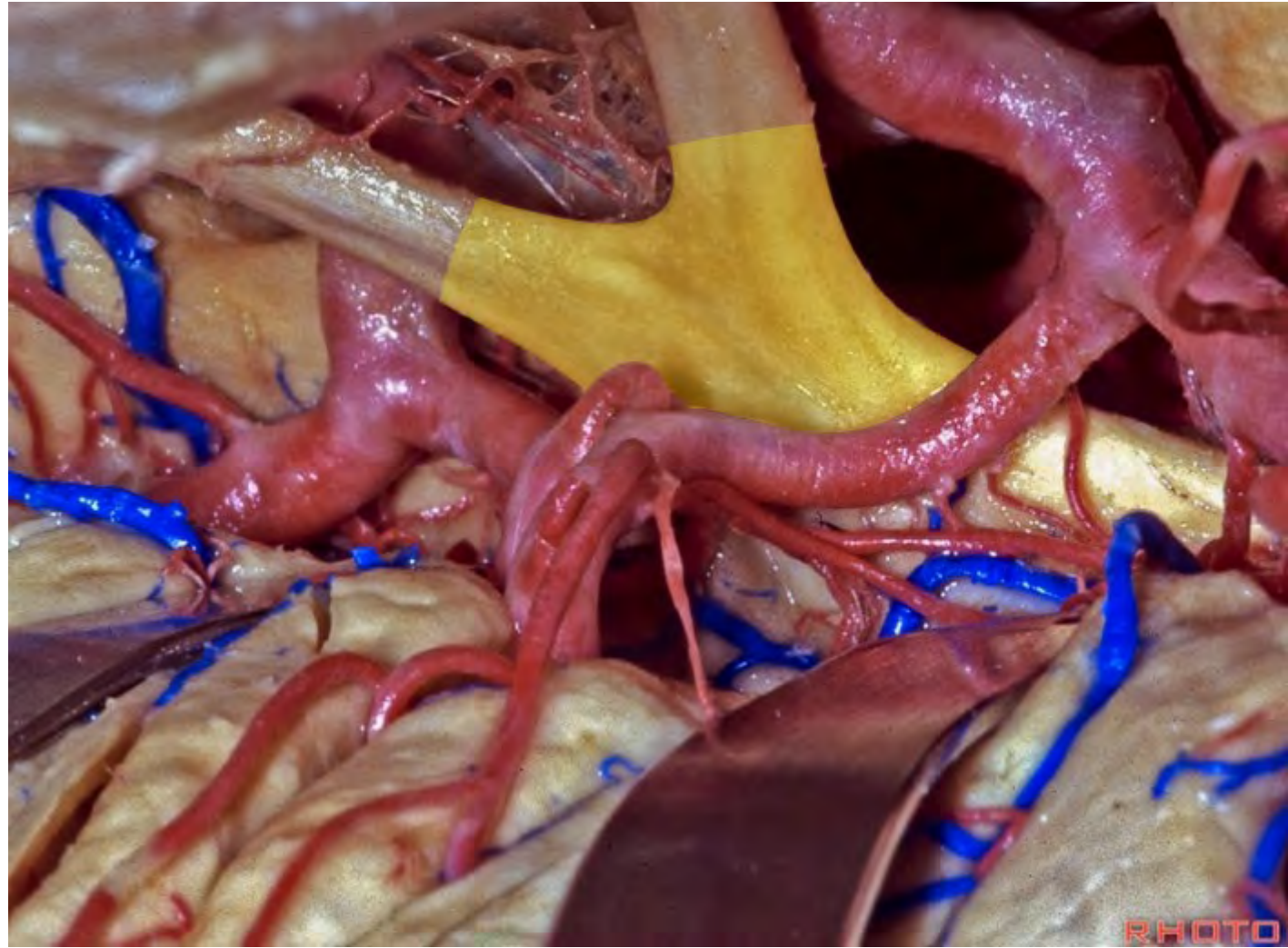


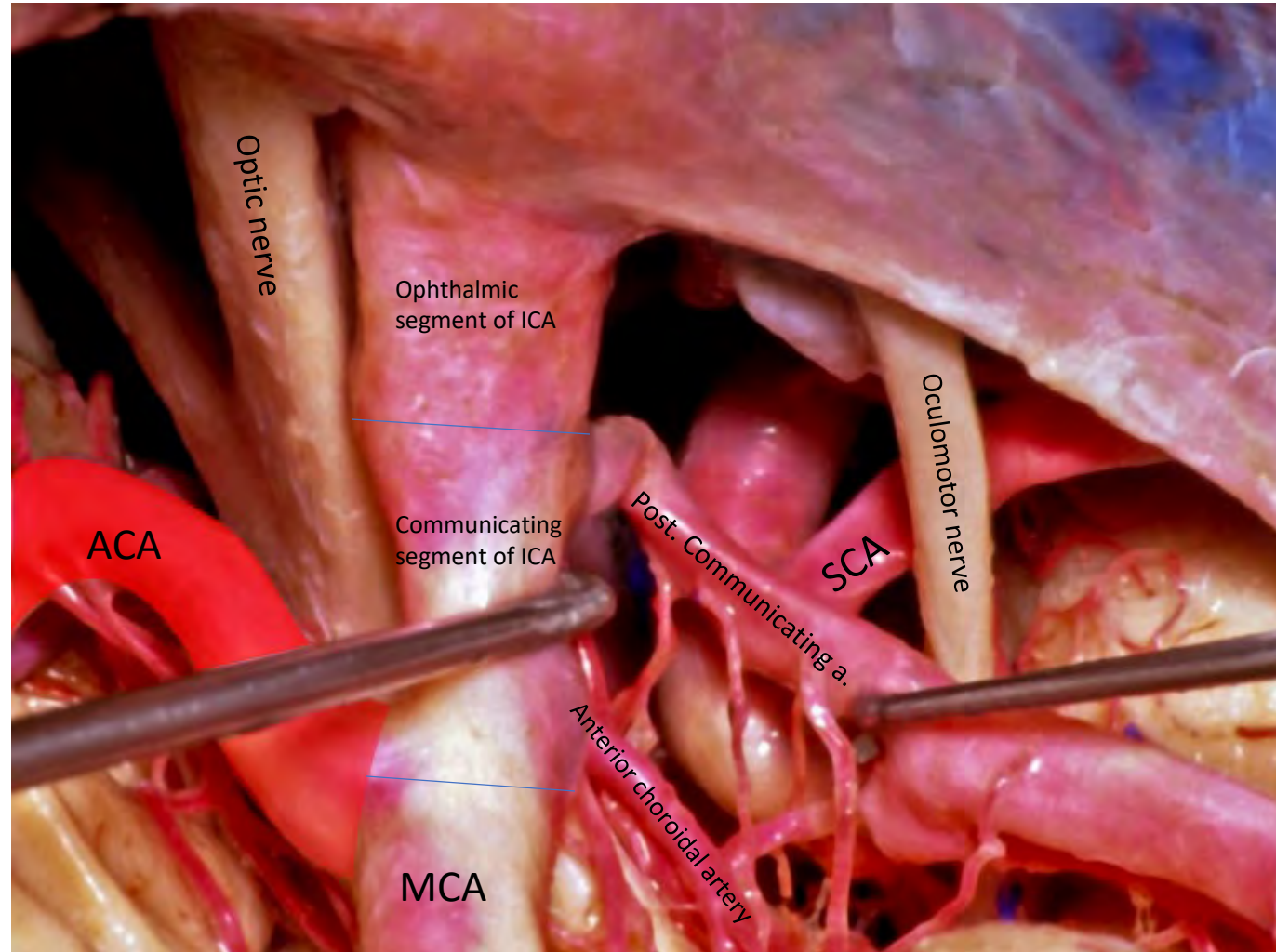


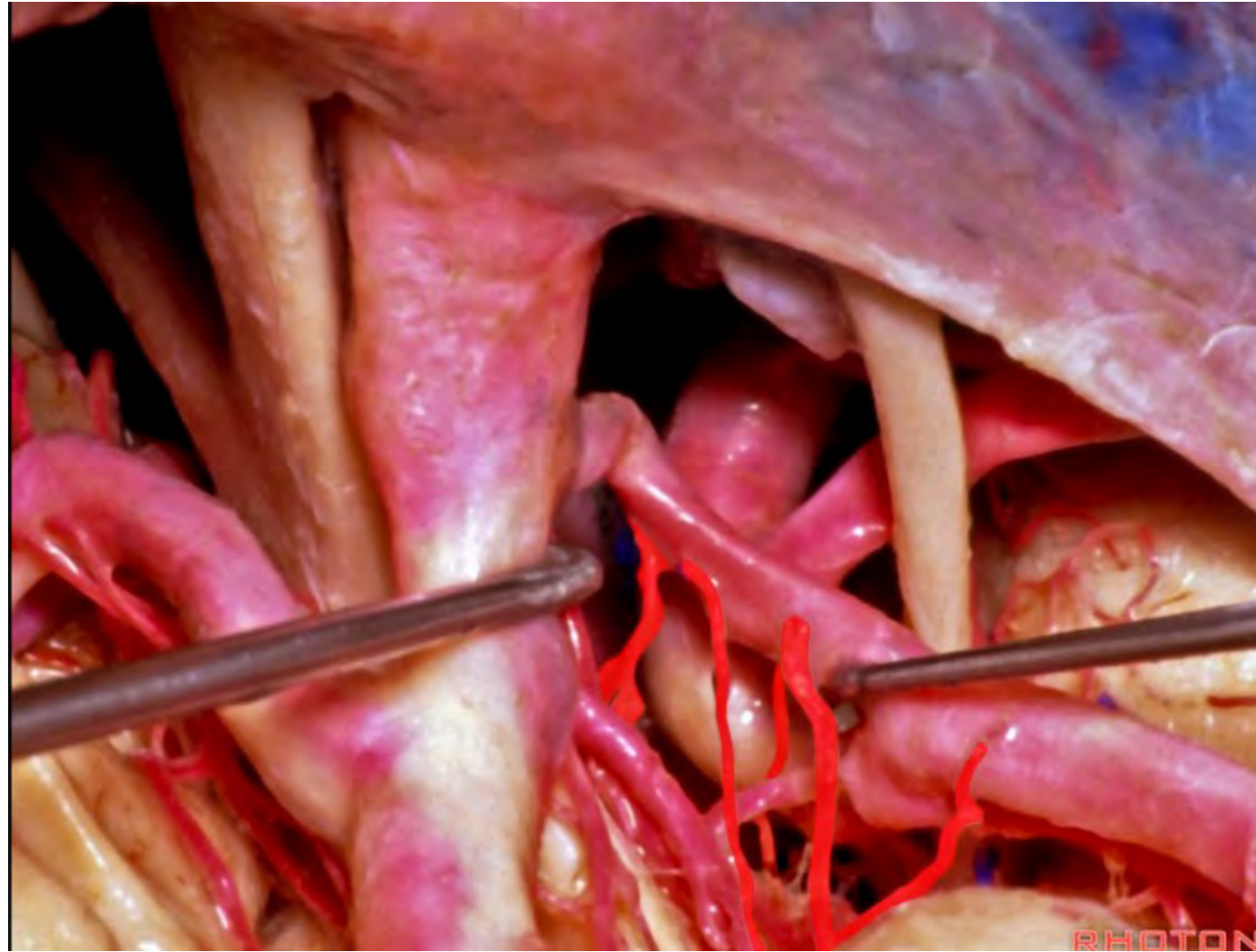




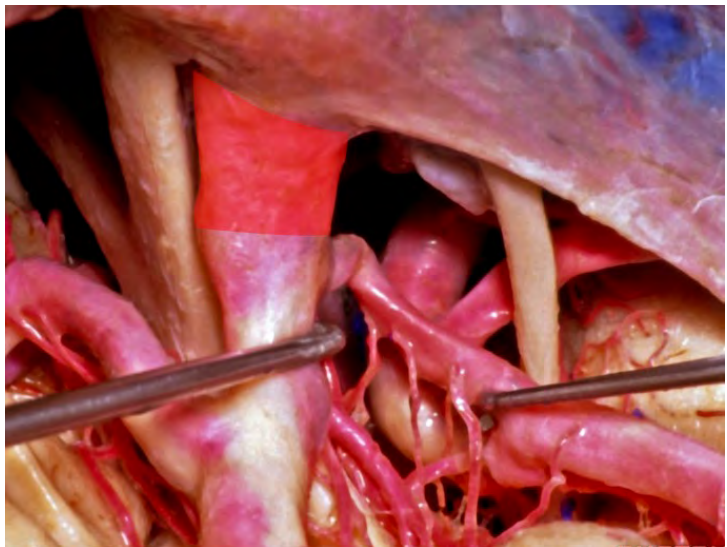




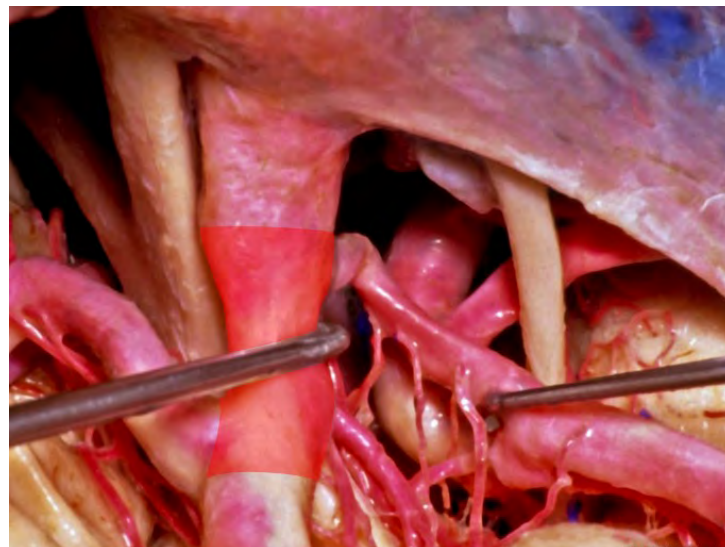




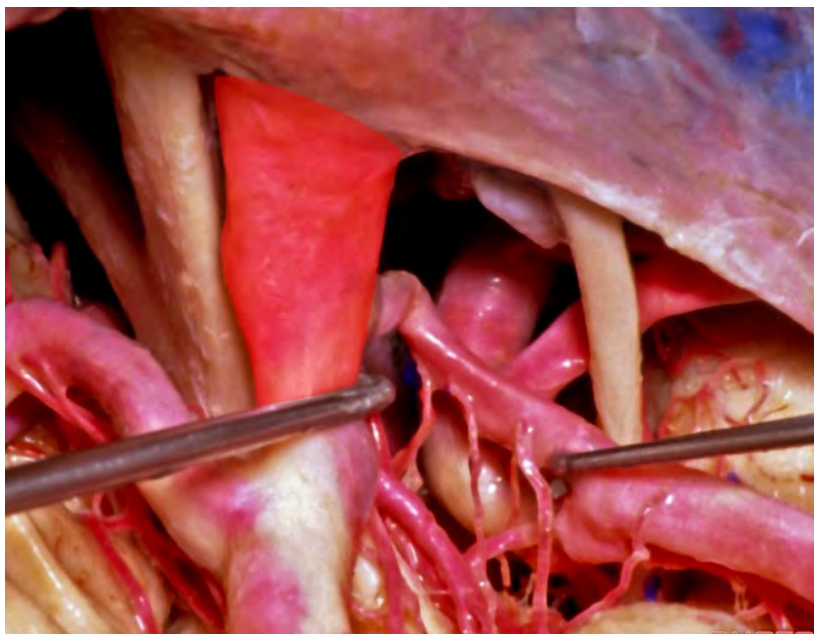
**ophthalmic segment of ICA**

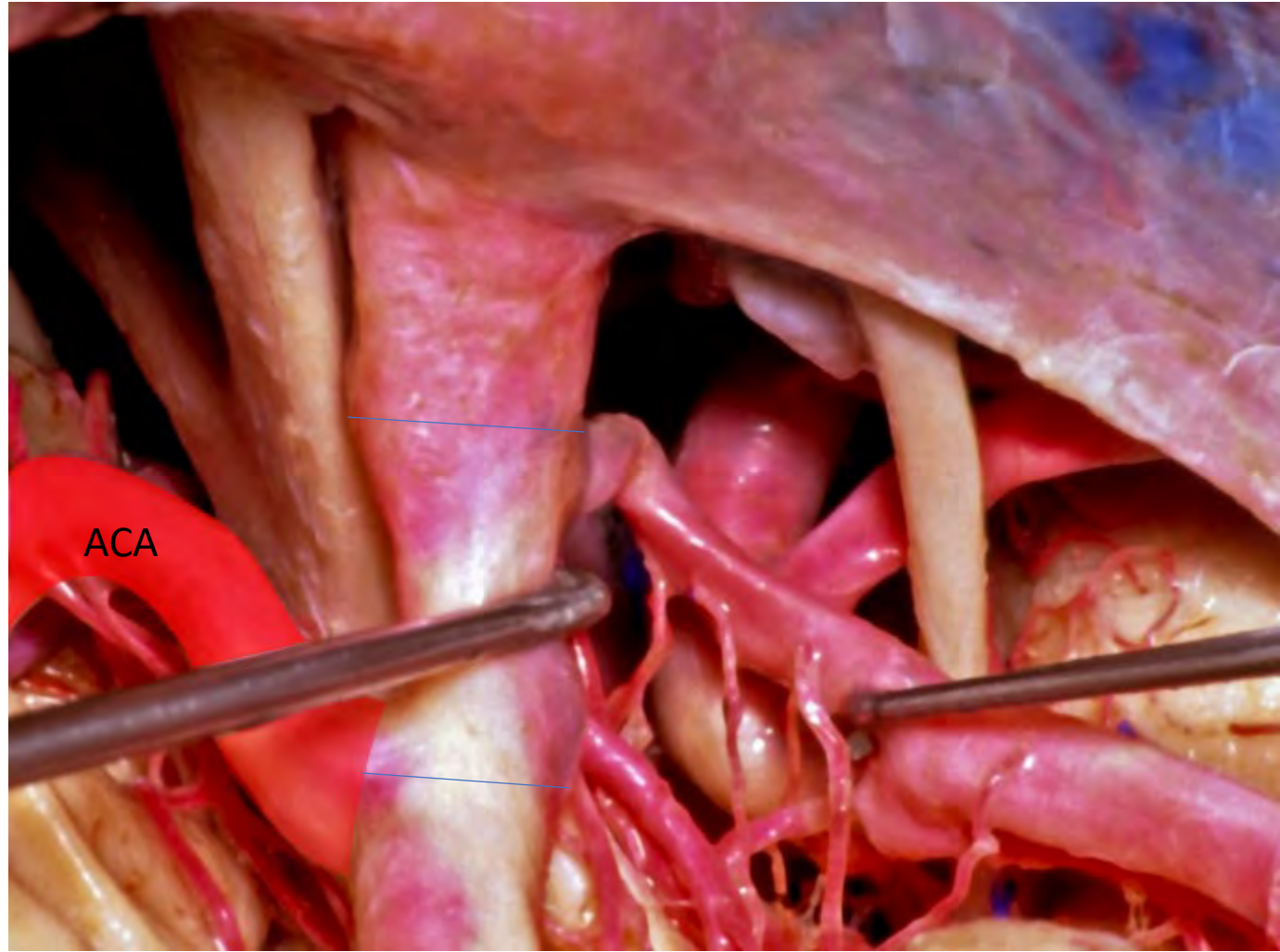


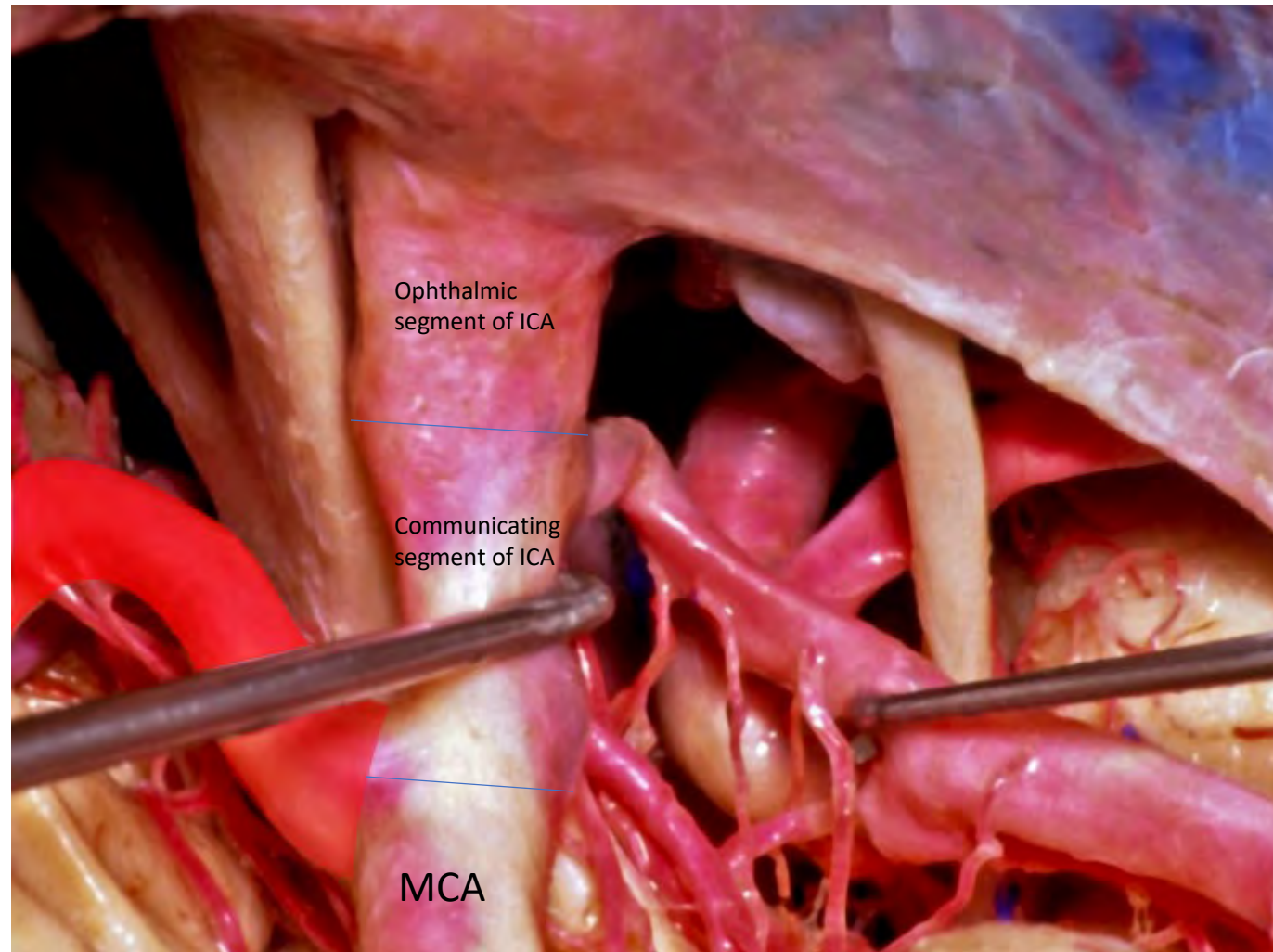
**communicating segment of ICA**



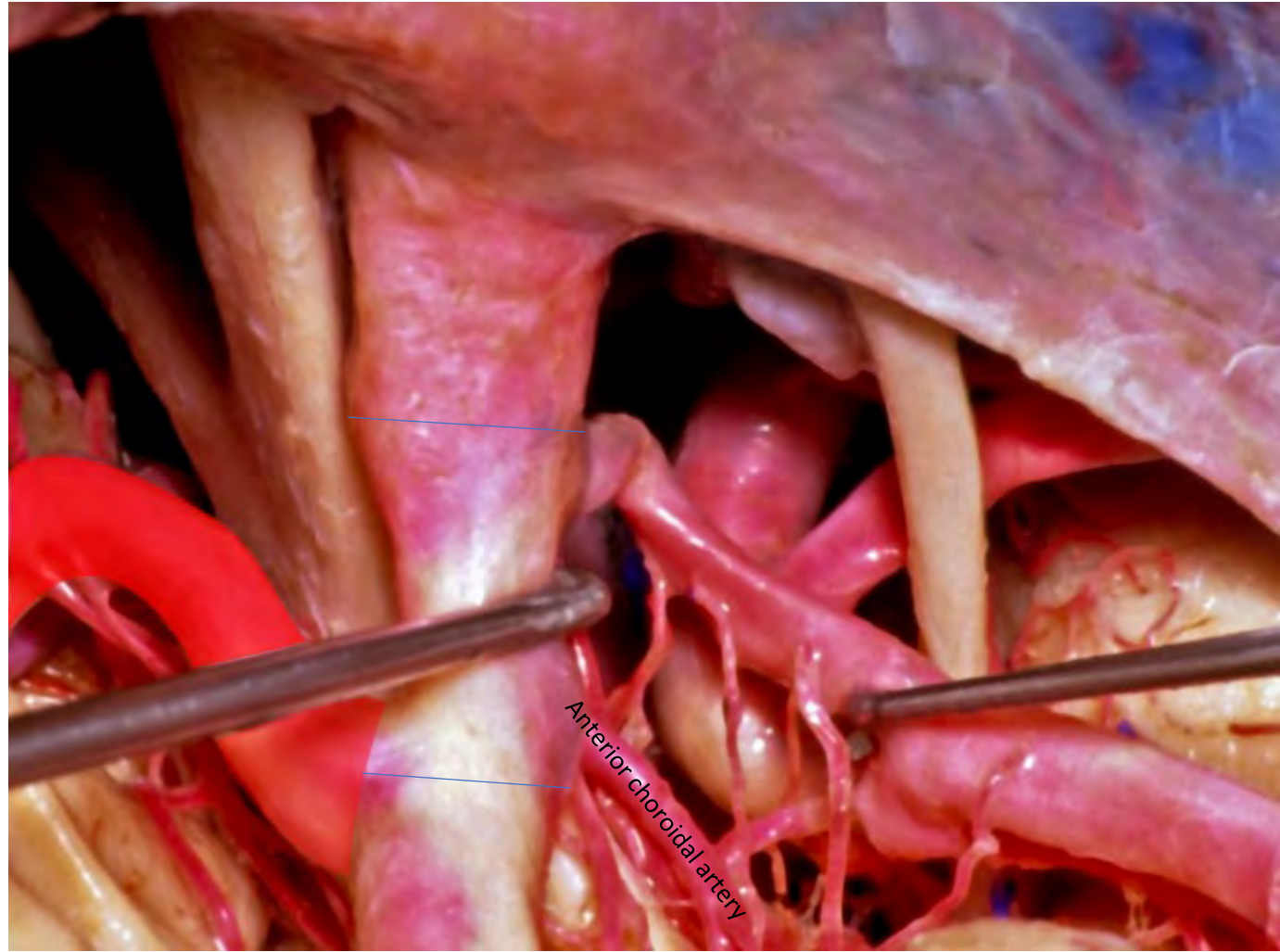
**supraclinoid portion of ICA**

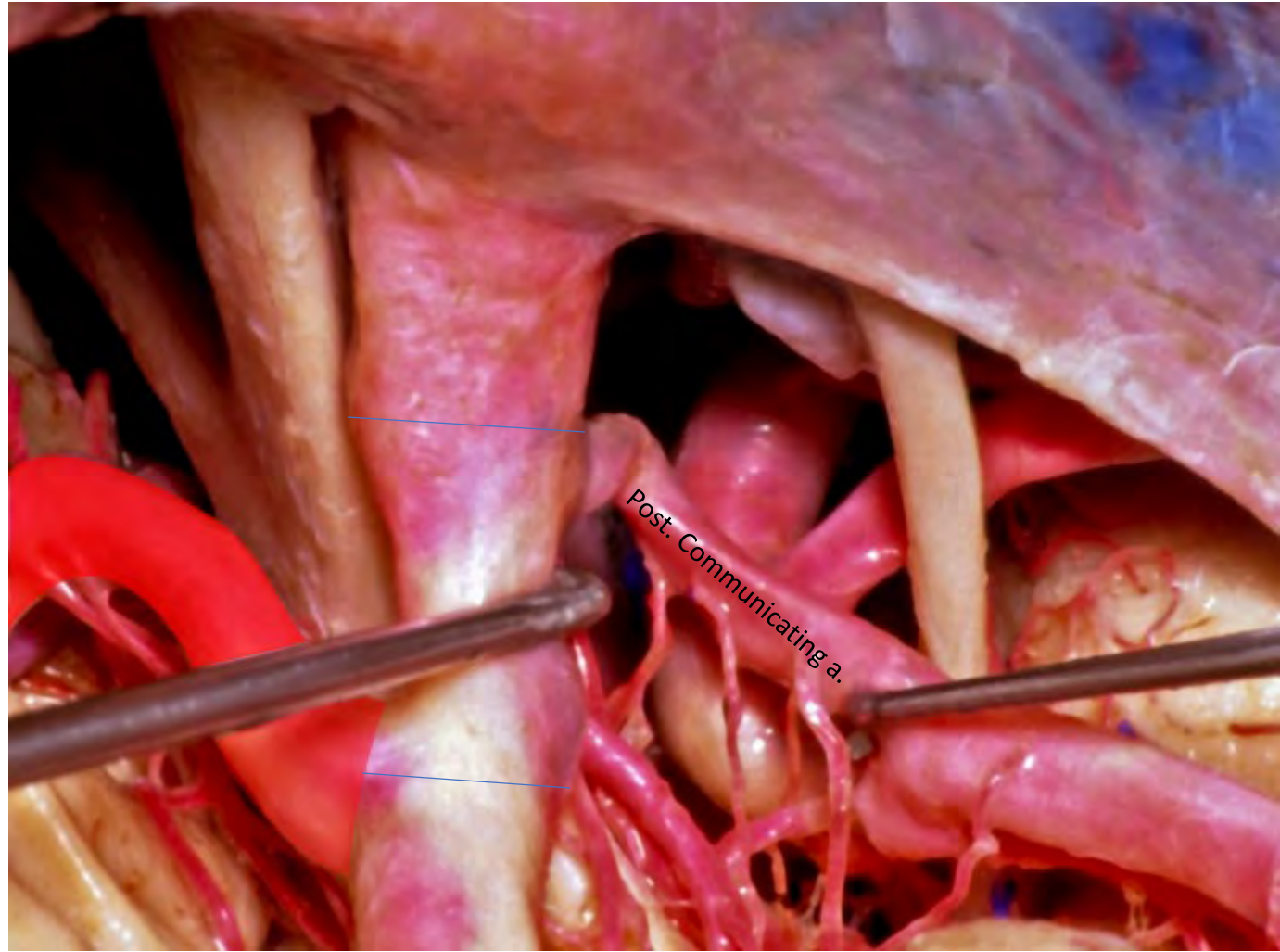


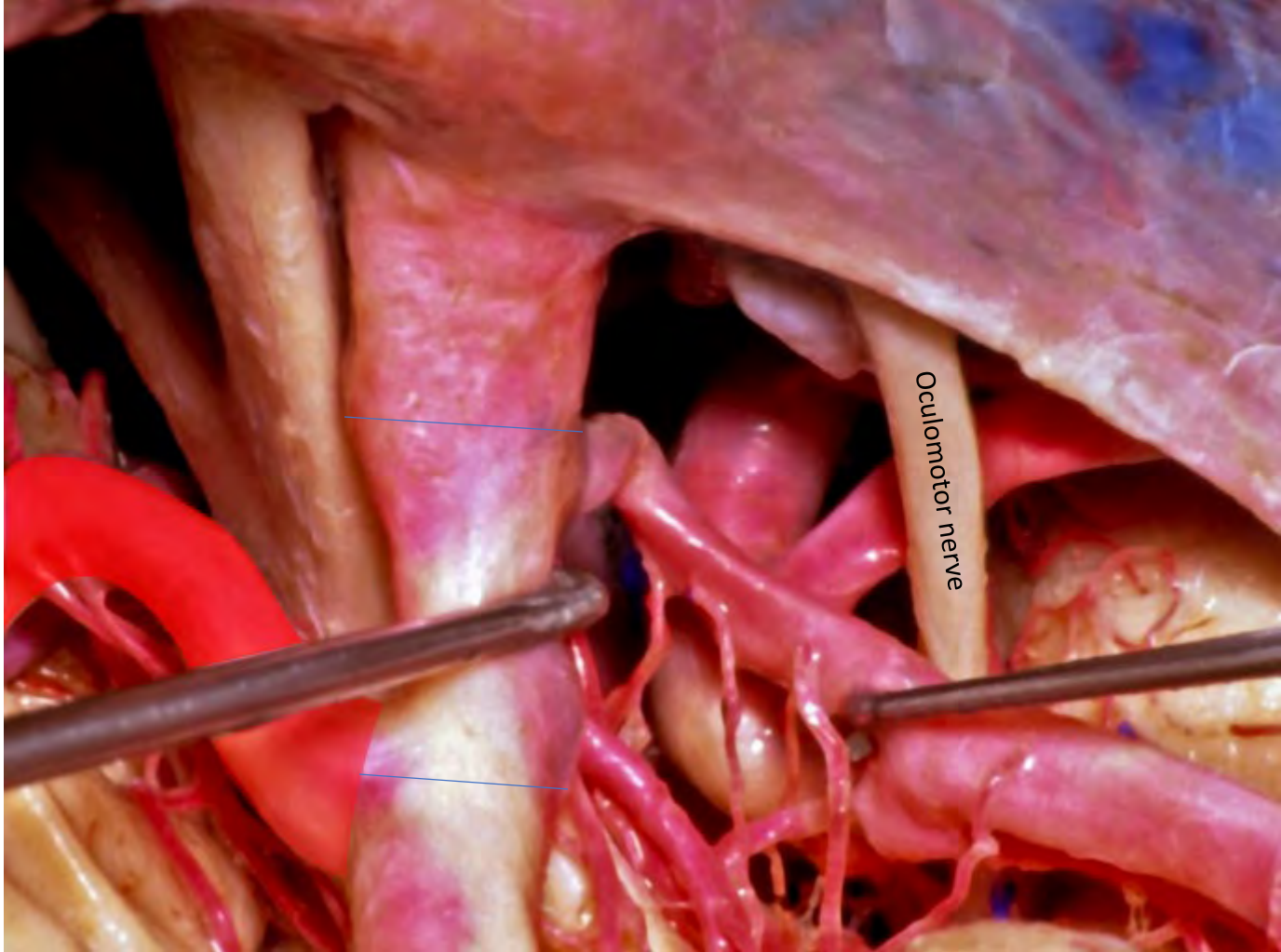


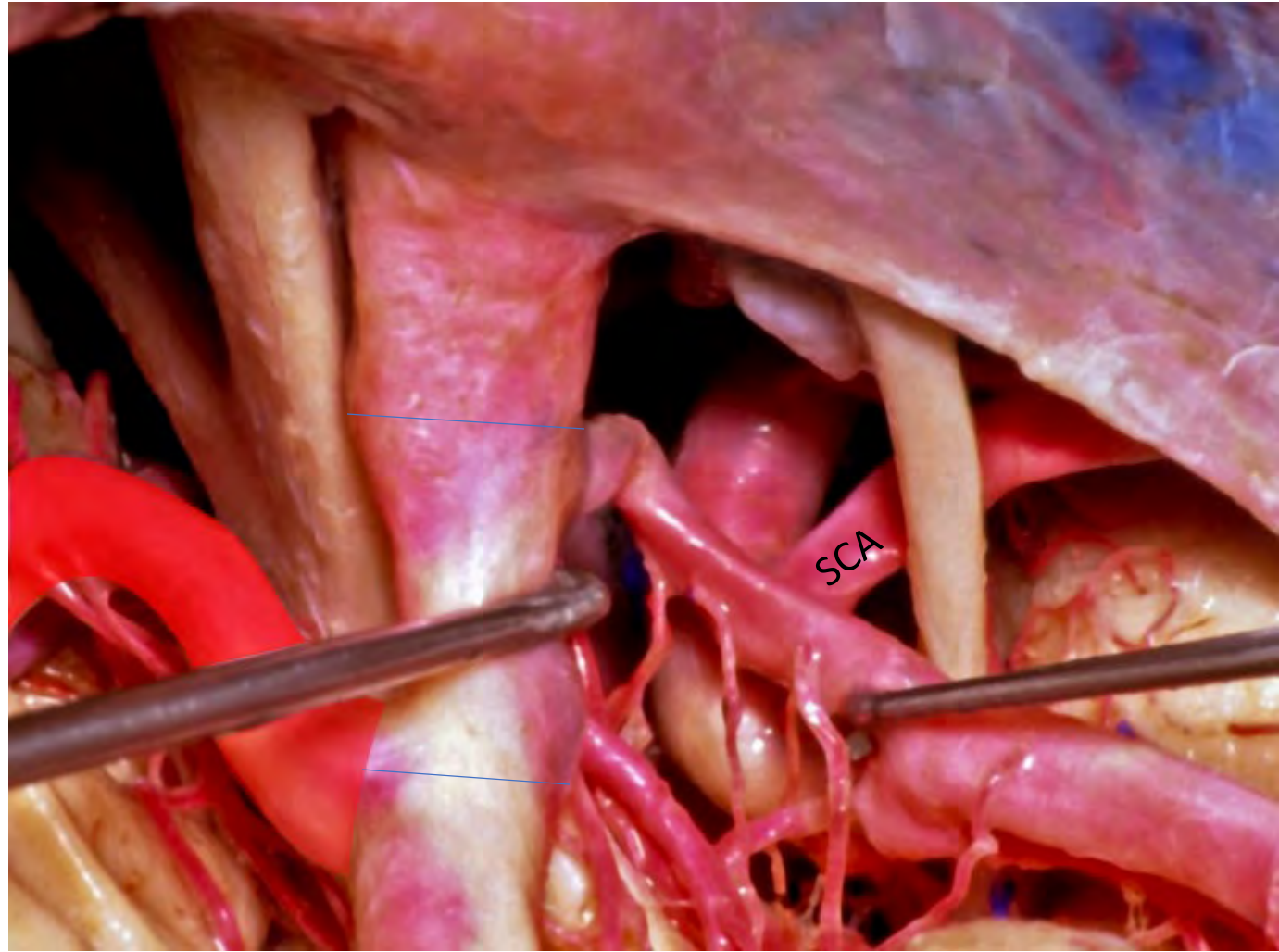


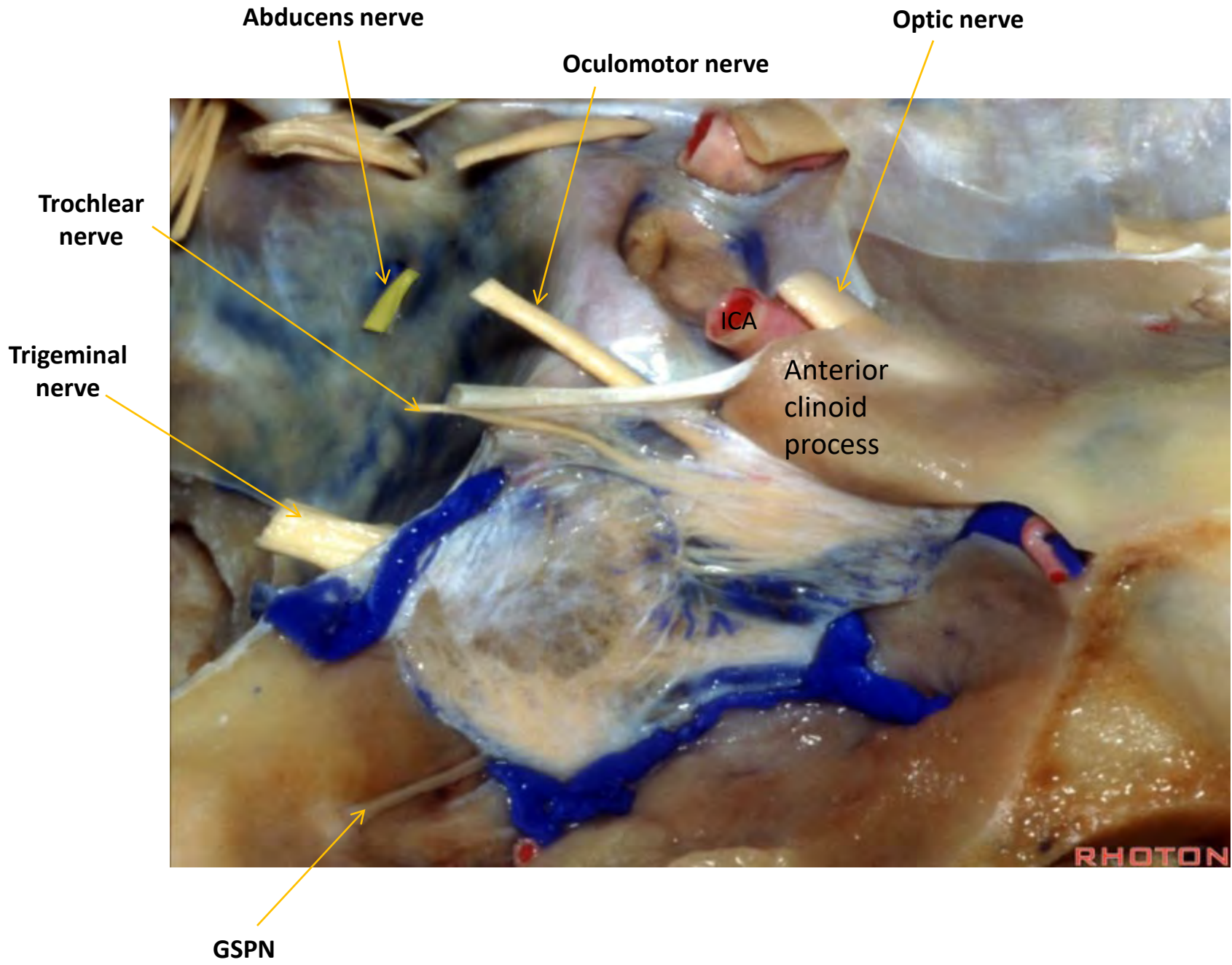


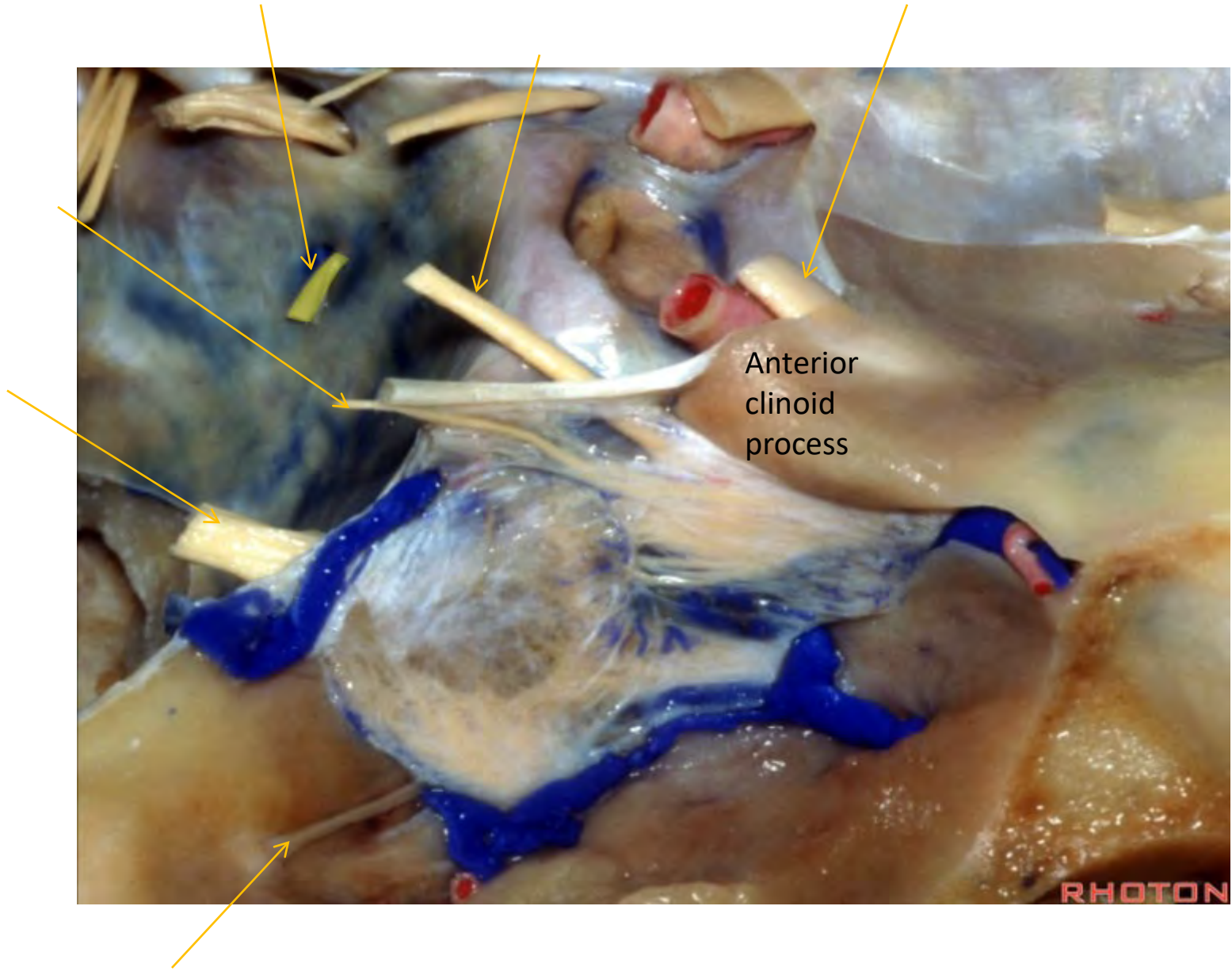










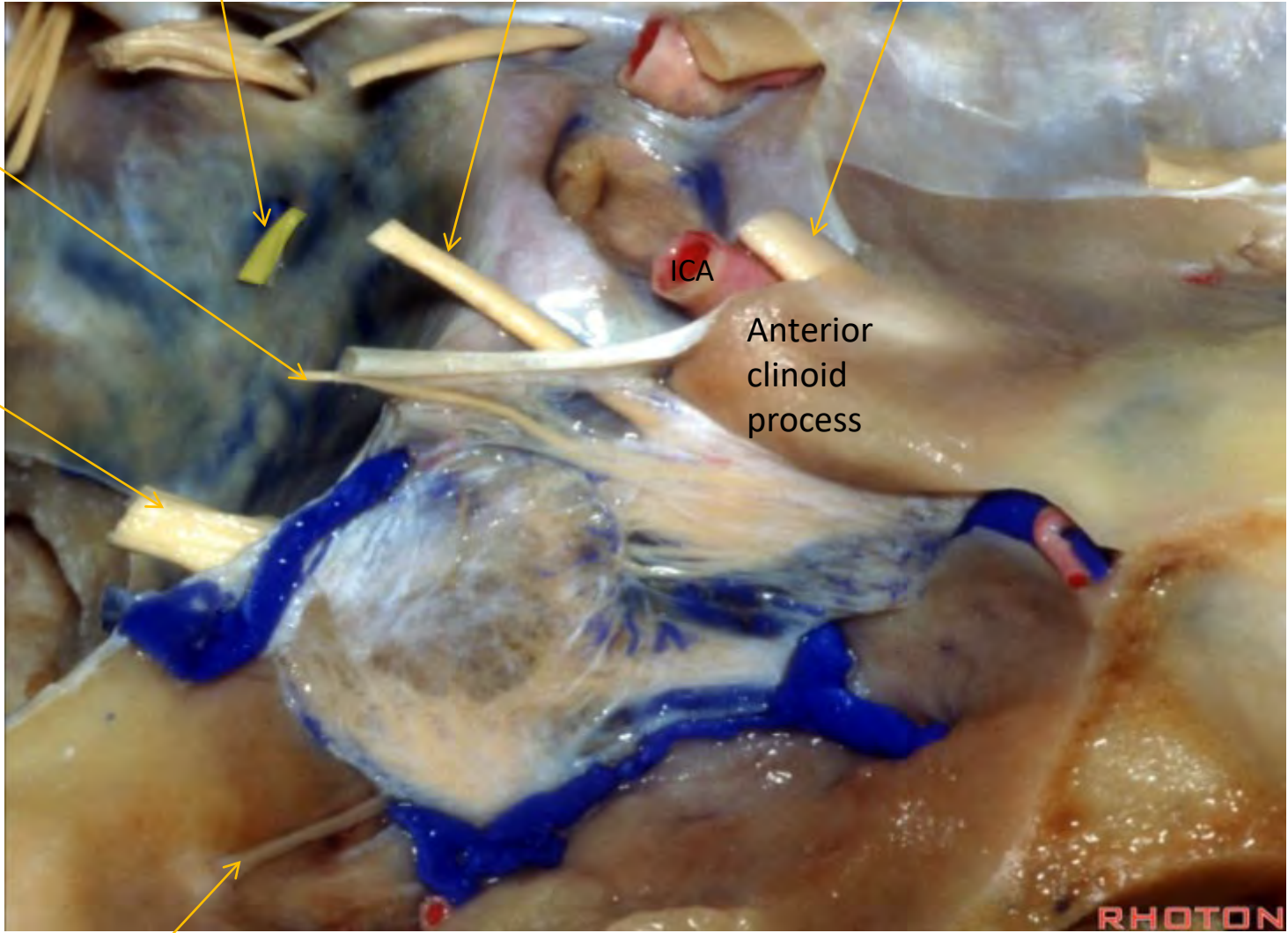




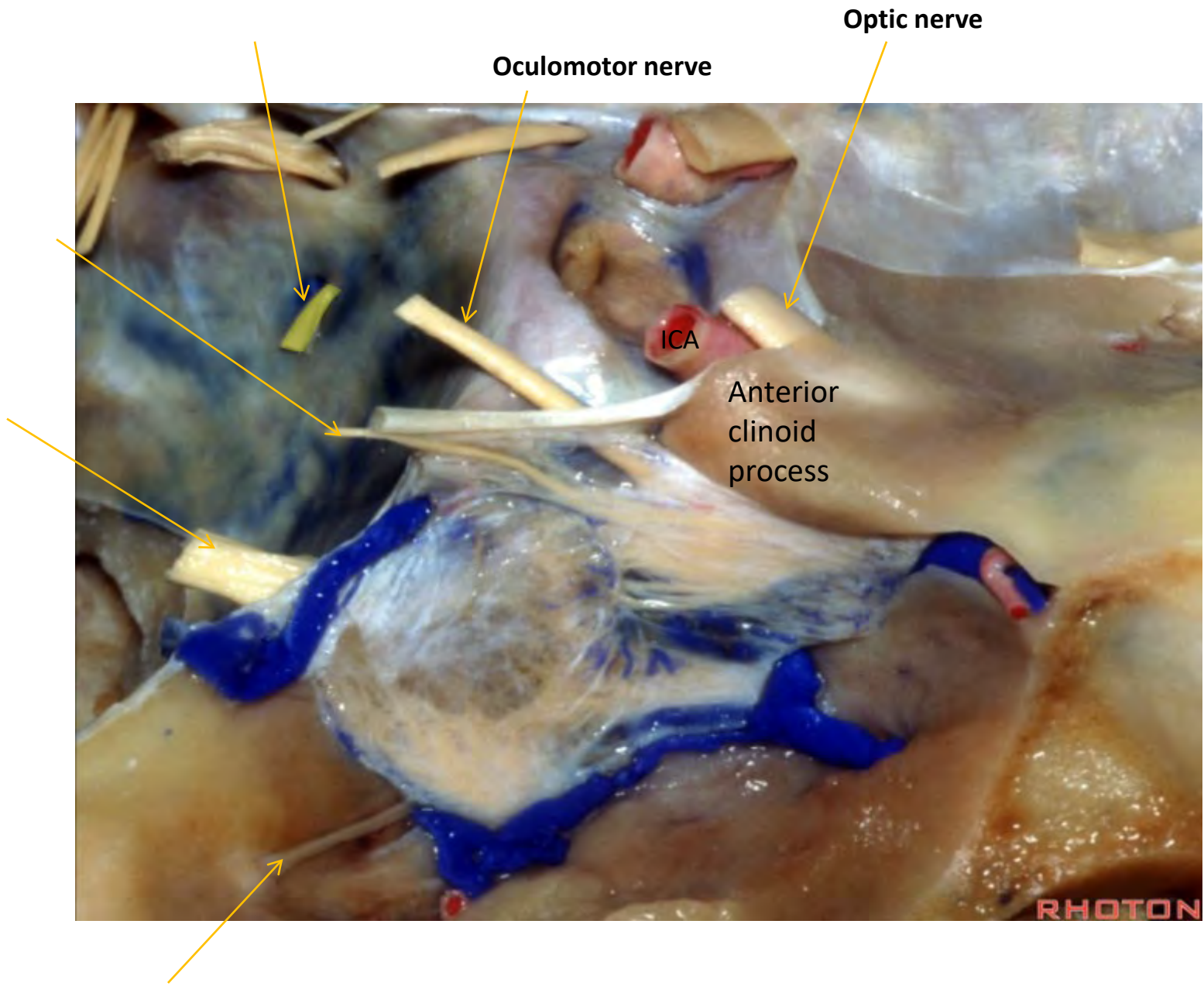
Optic nerve

ICA

Anterior  
clinoid  
process



RHOTON



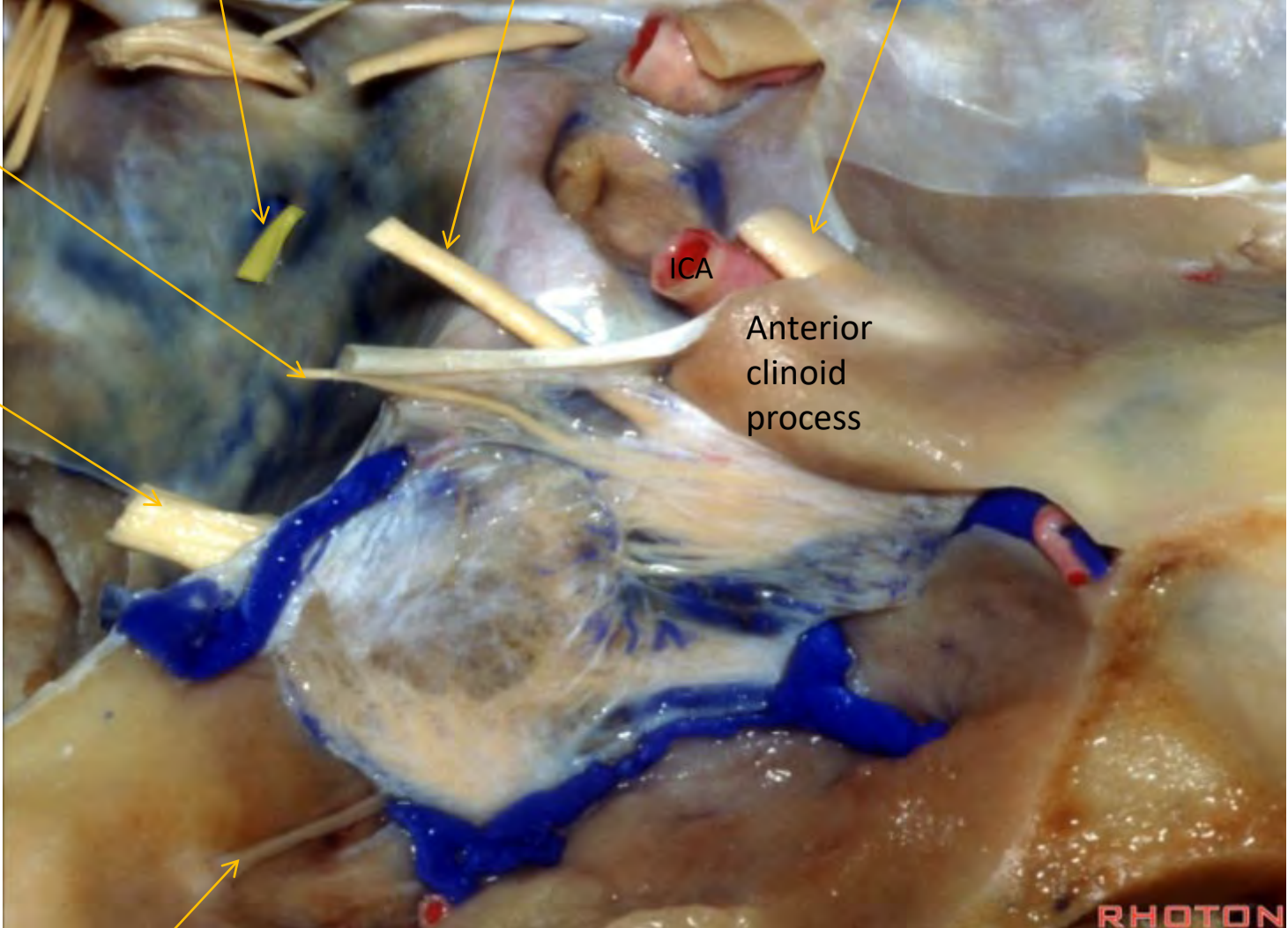




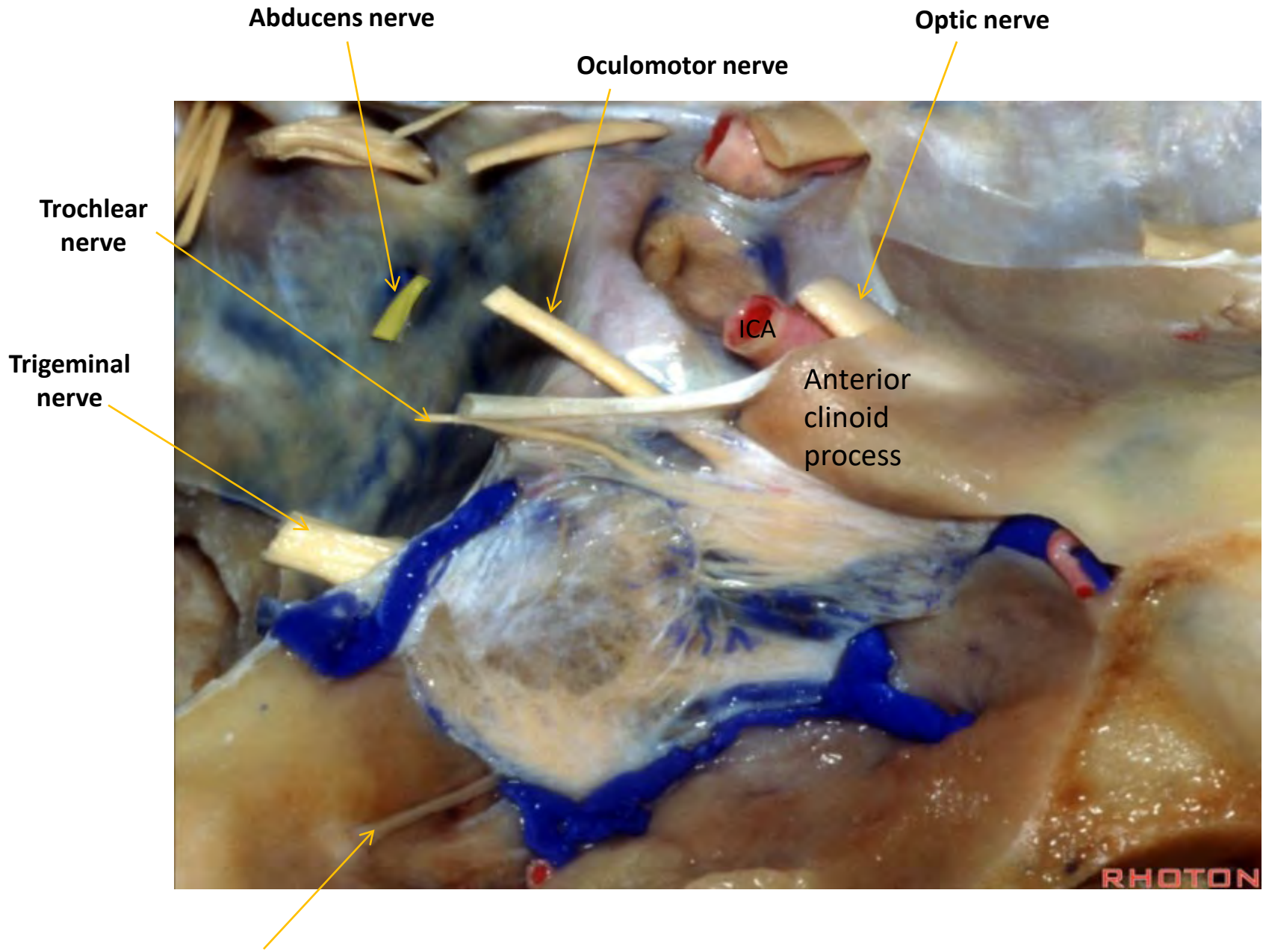
Abducens nerve

Oculomotor nerve

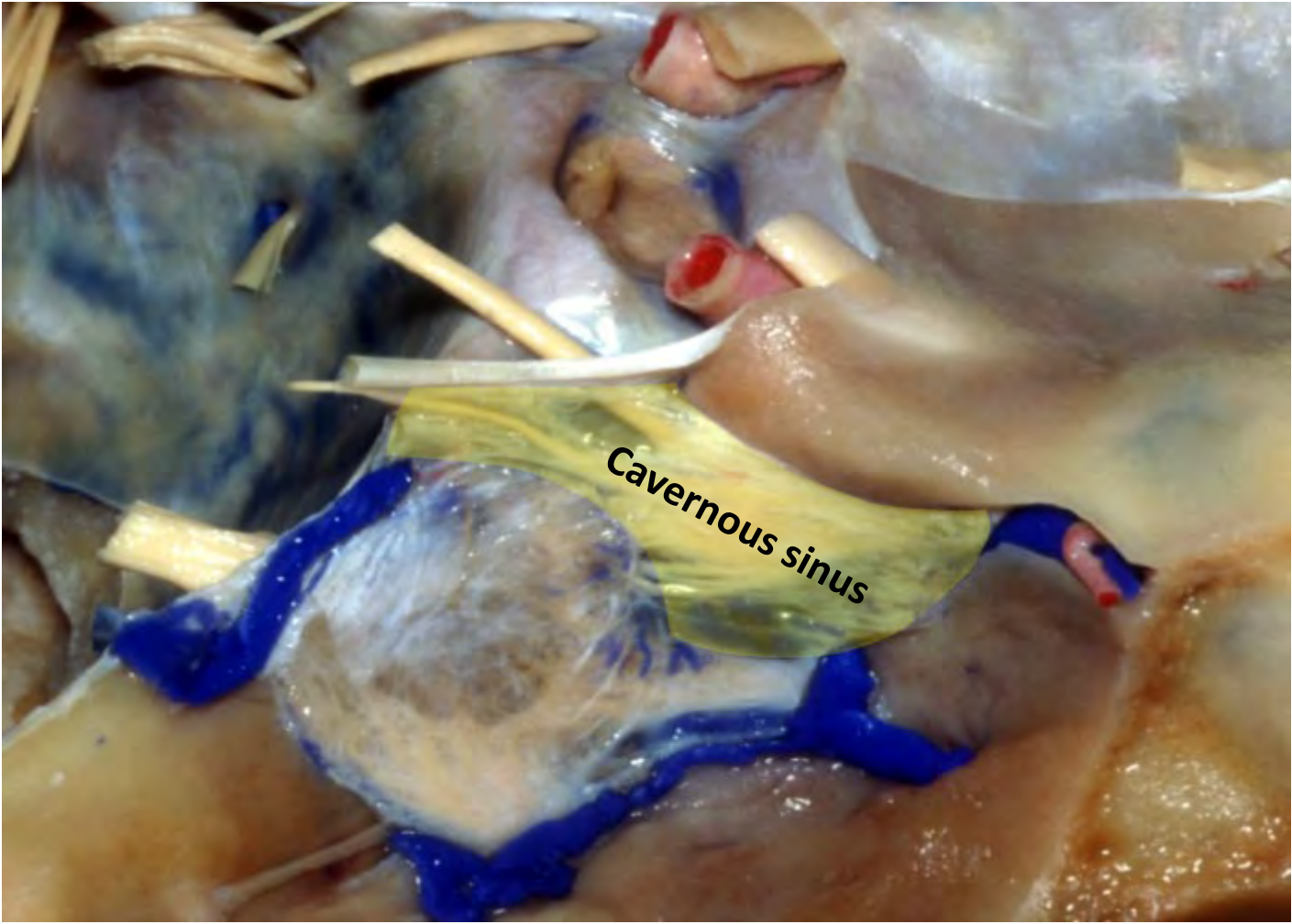
Optic nerve



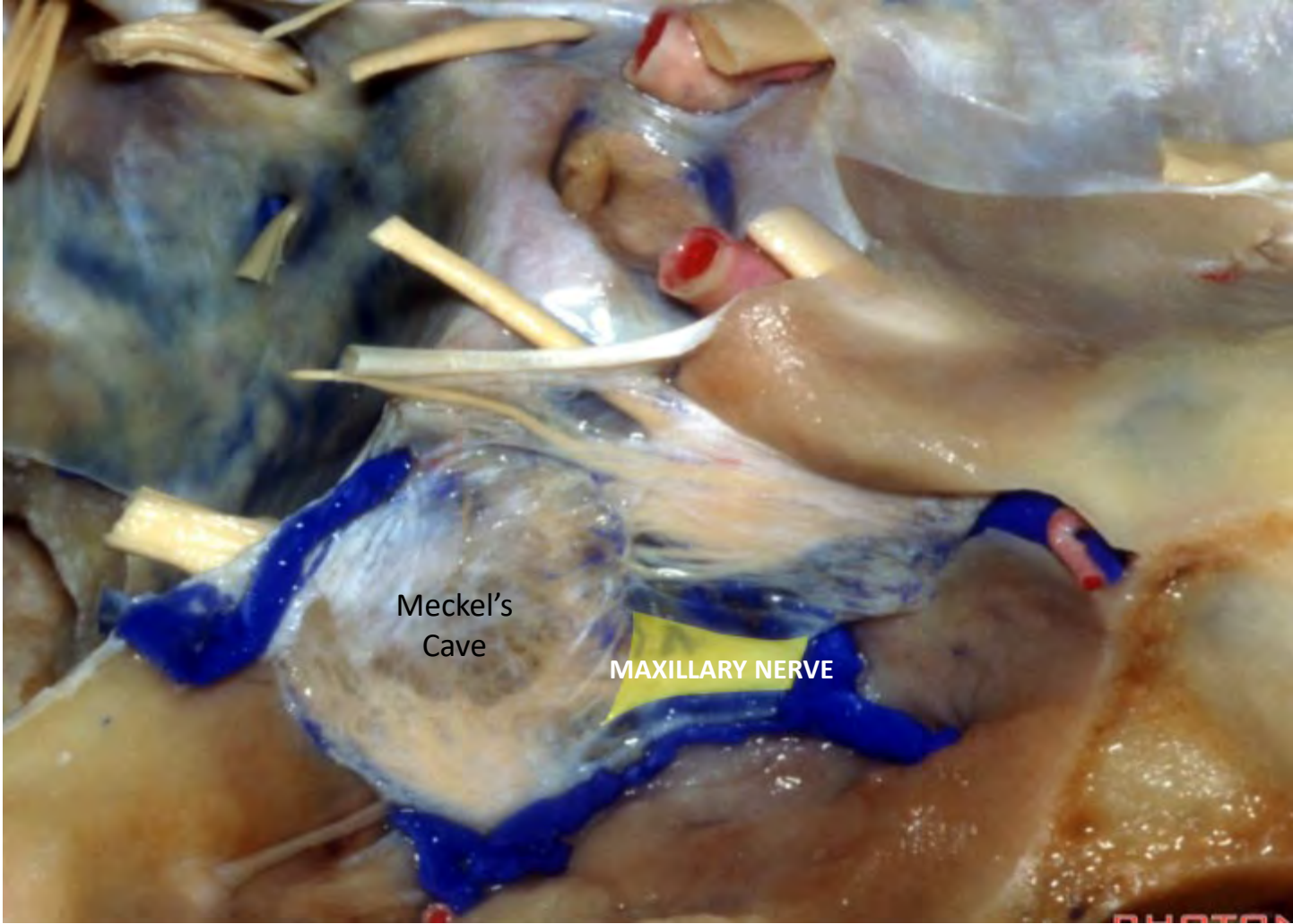


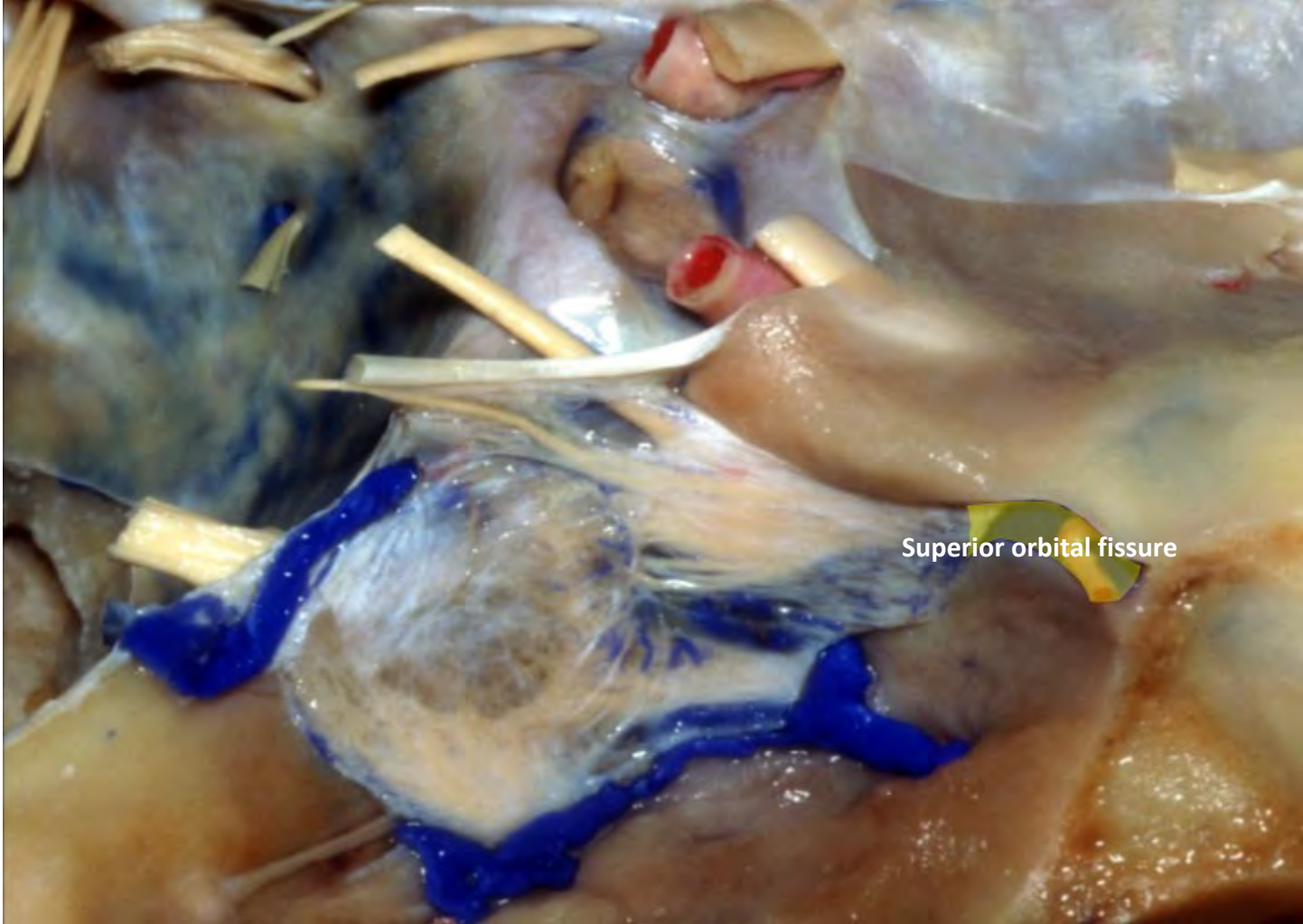




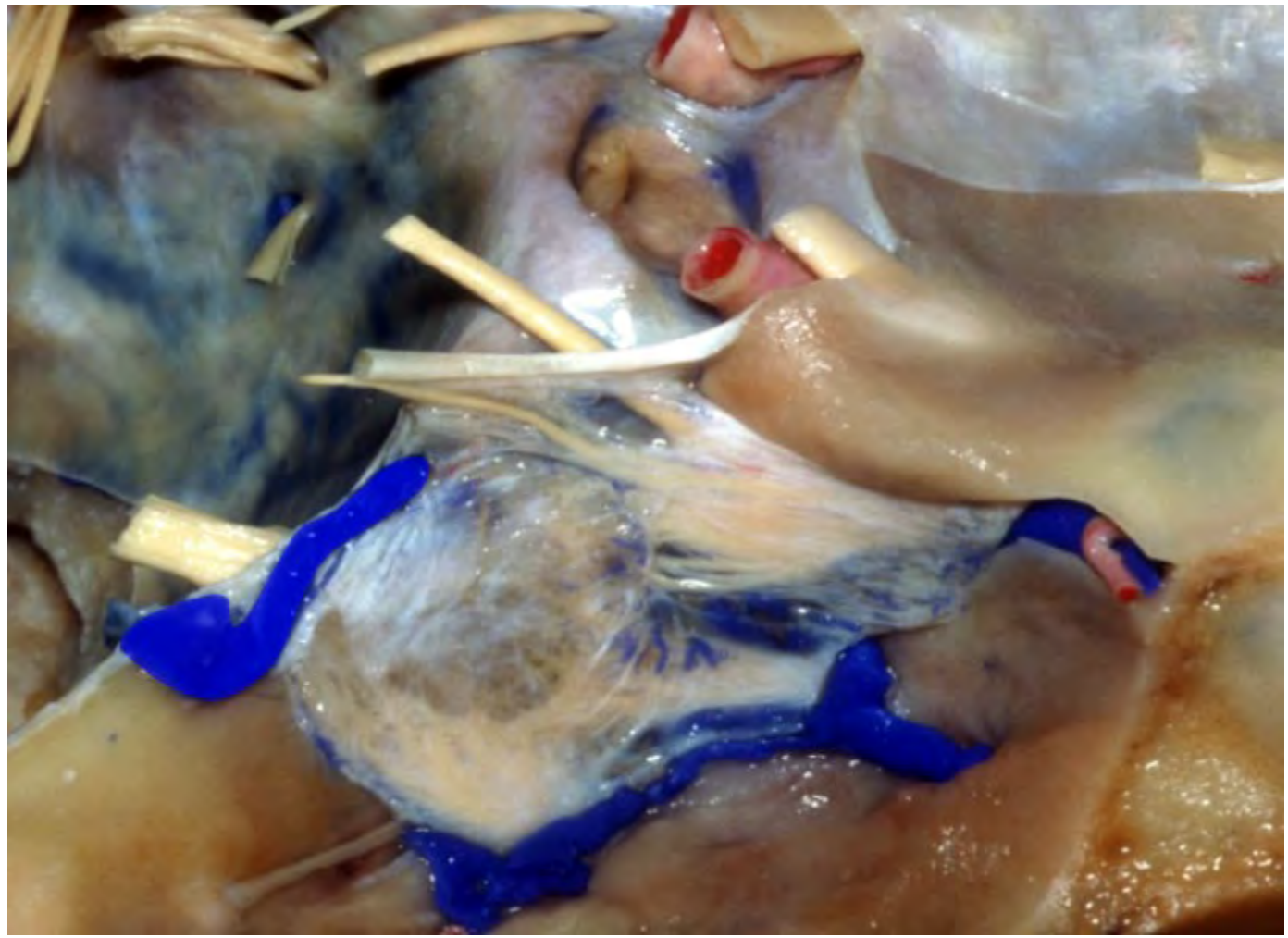


Cavernous sinus

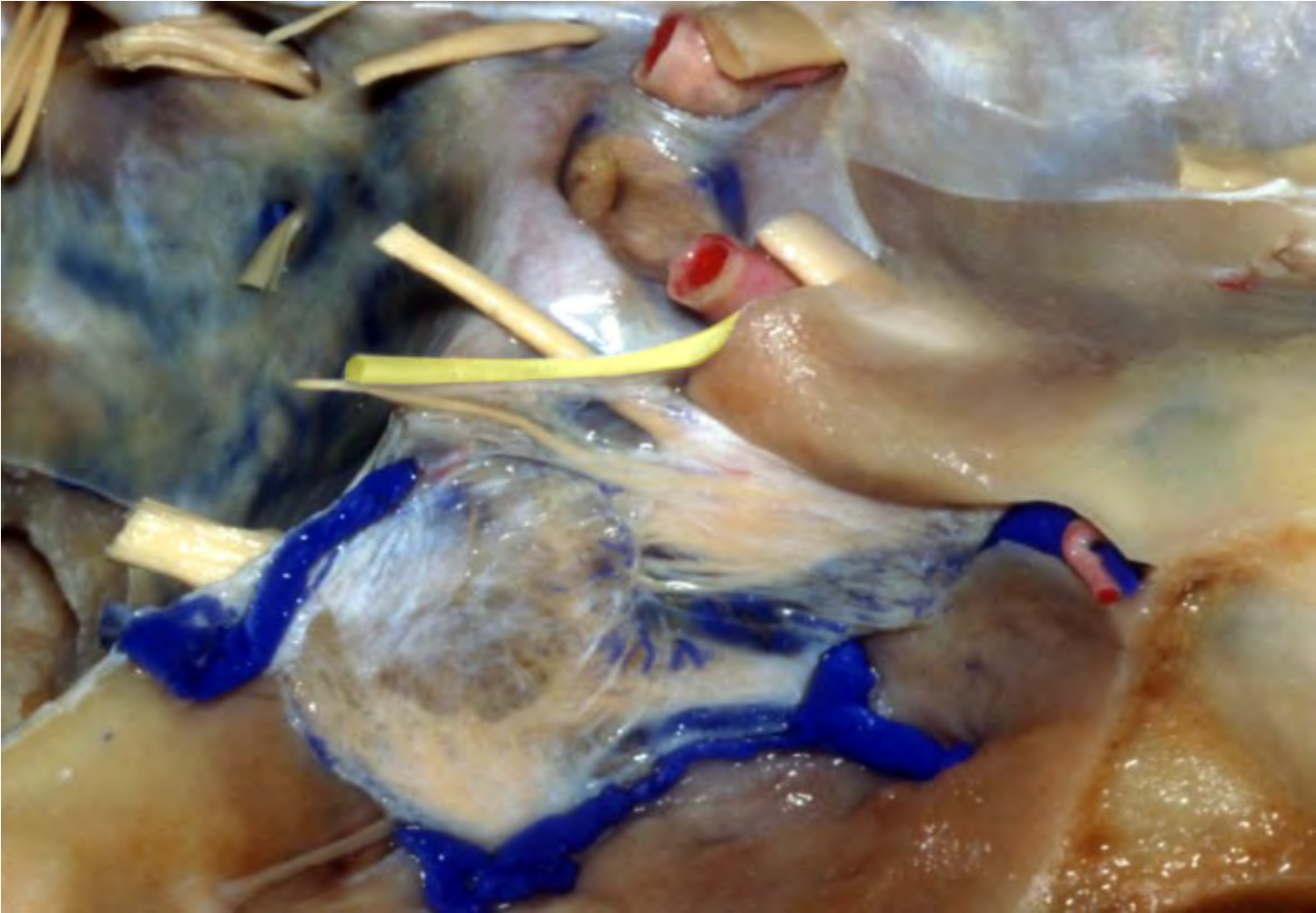


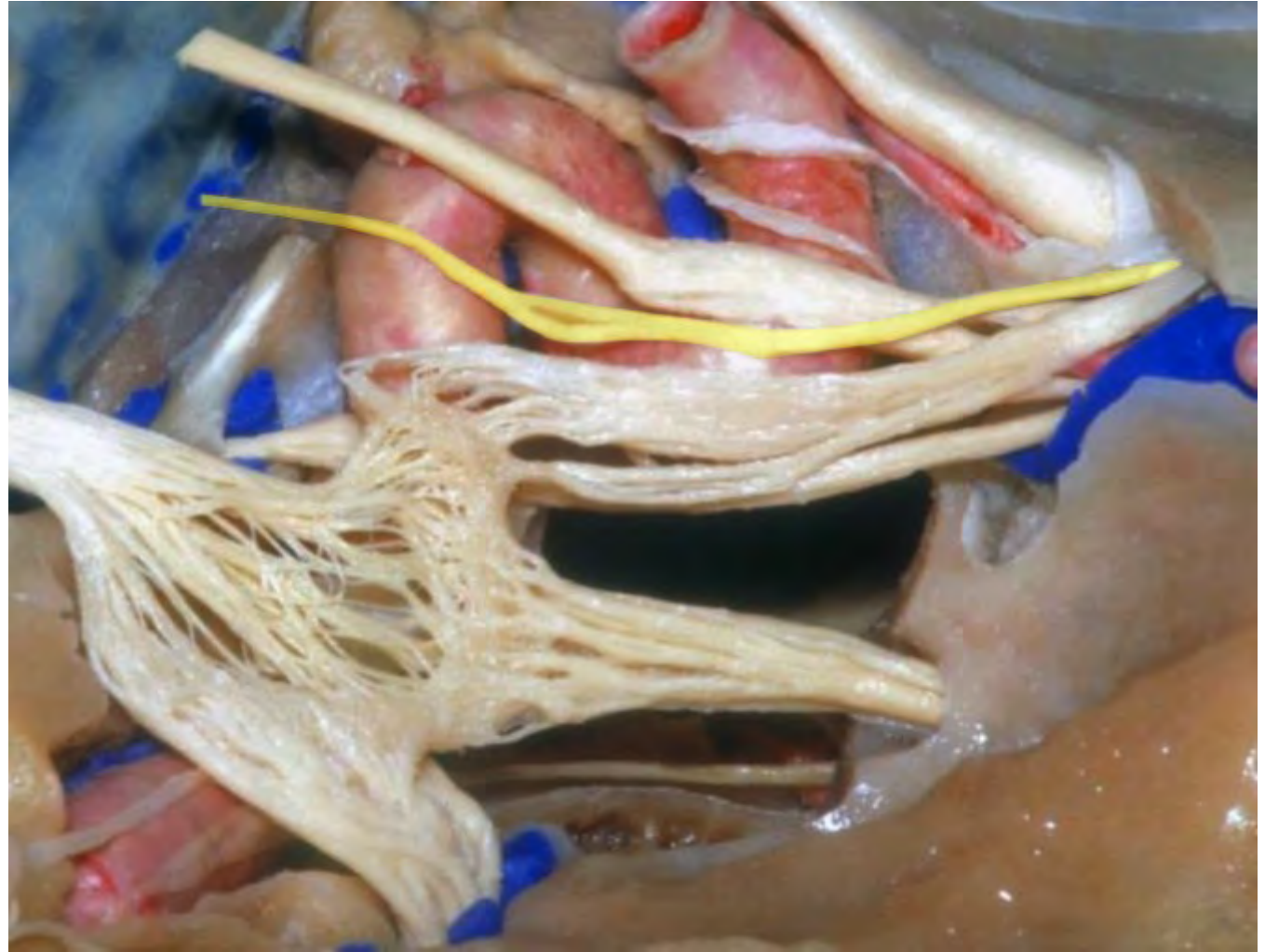


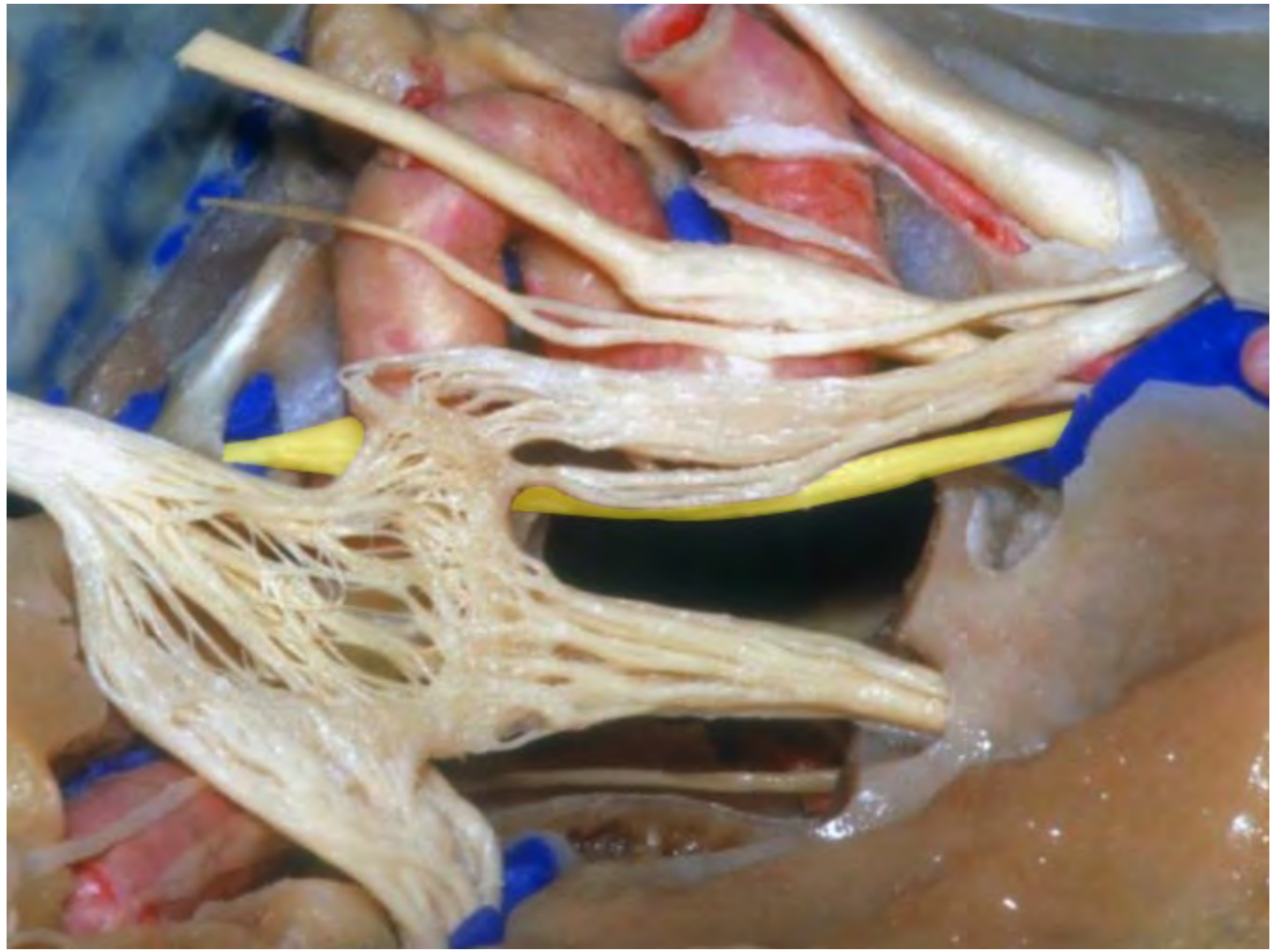
Superior orbital fissure

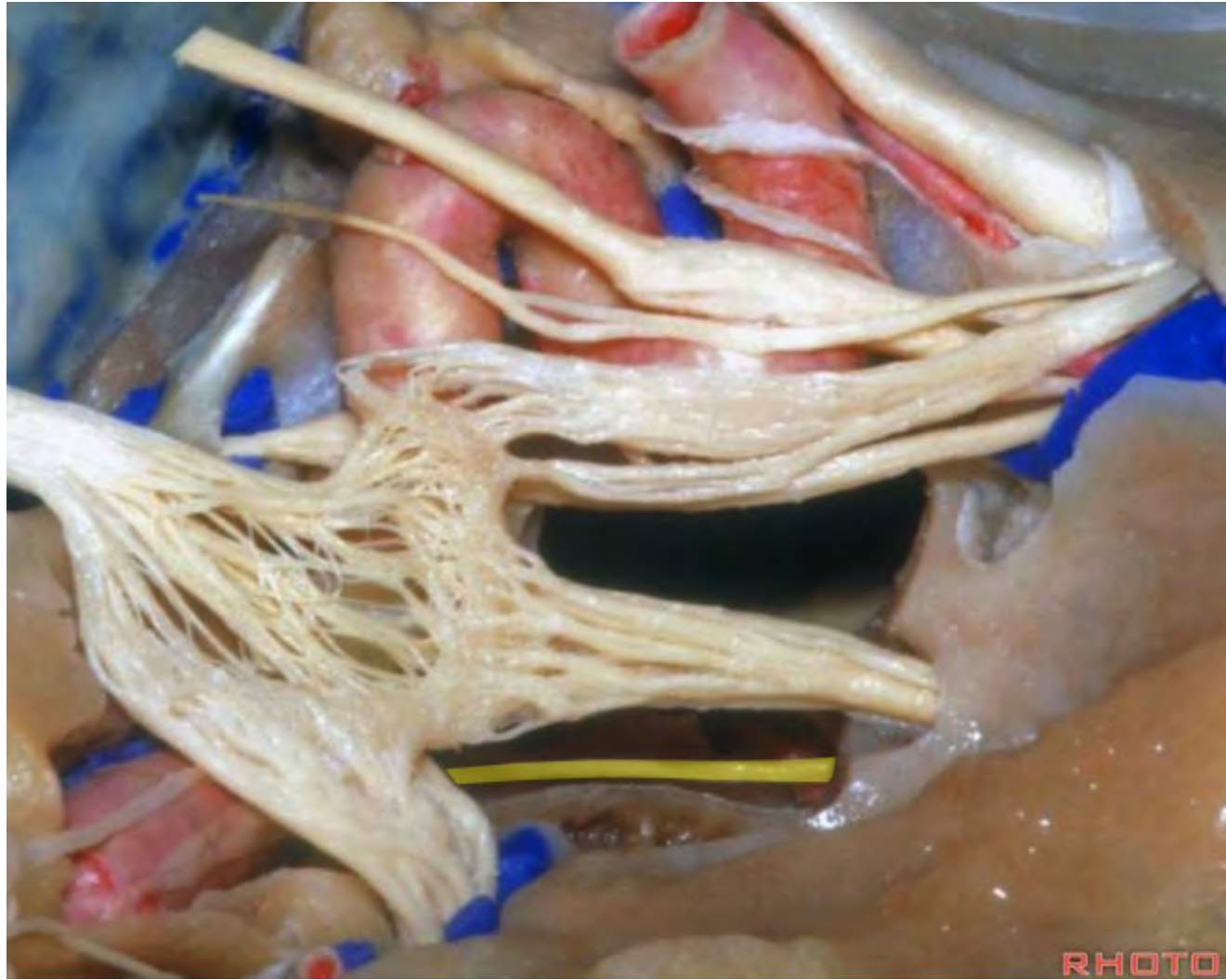


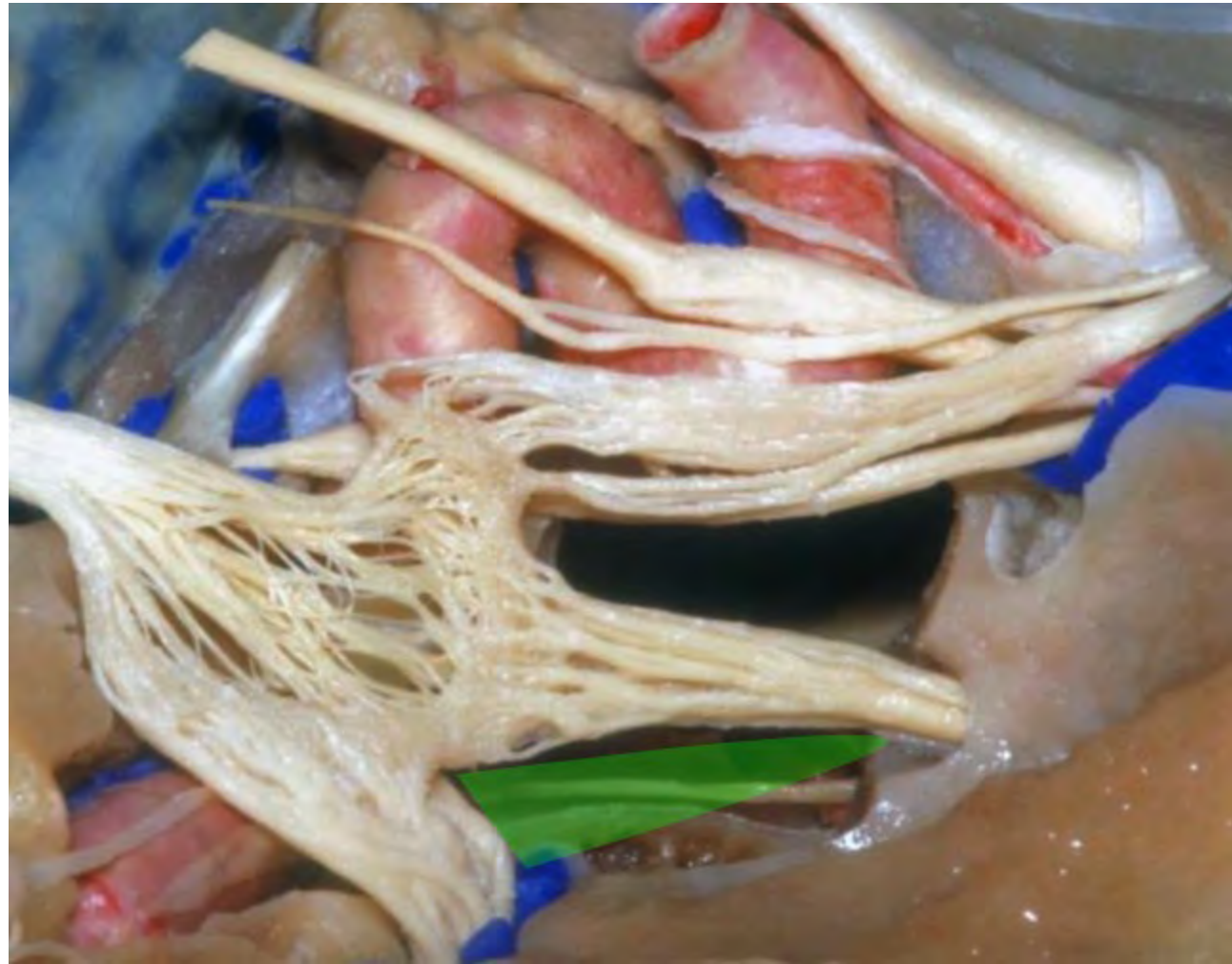


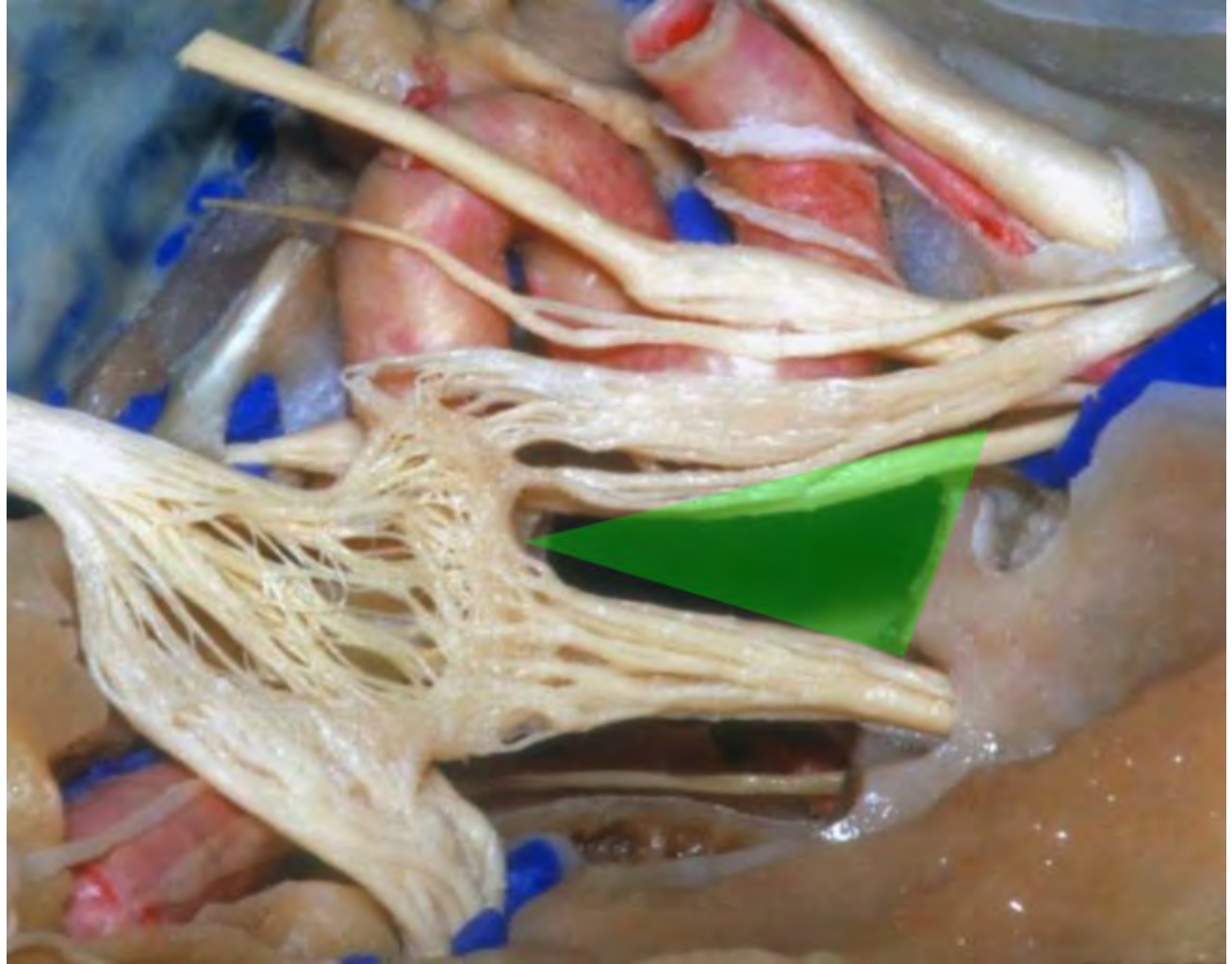


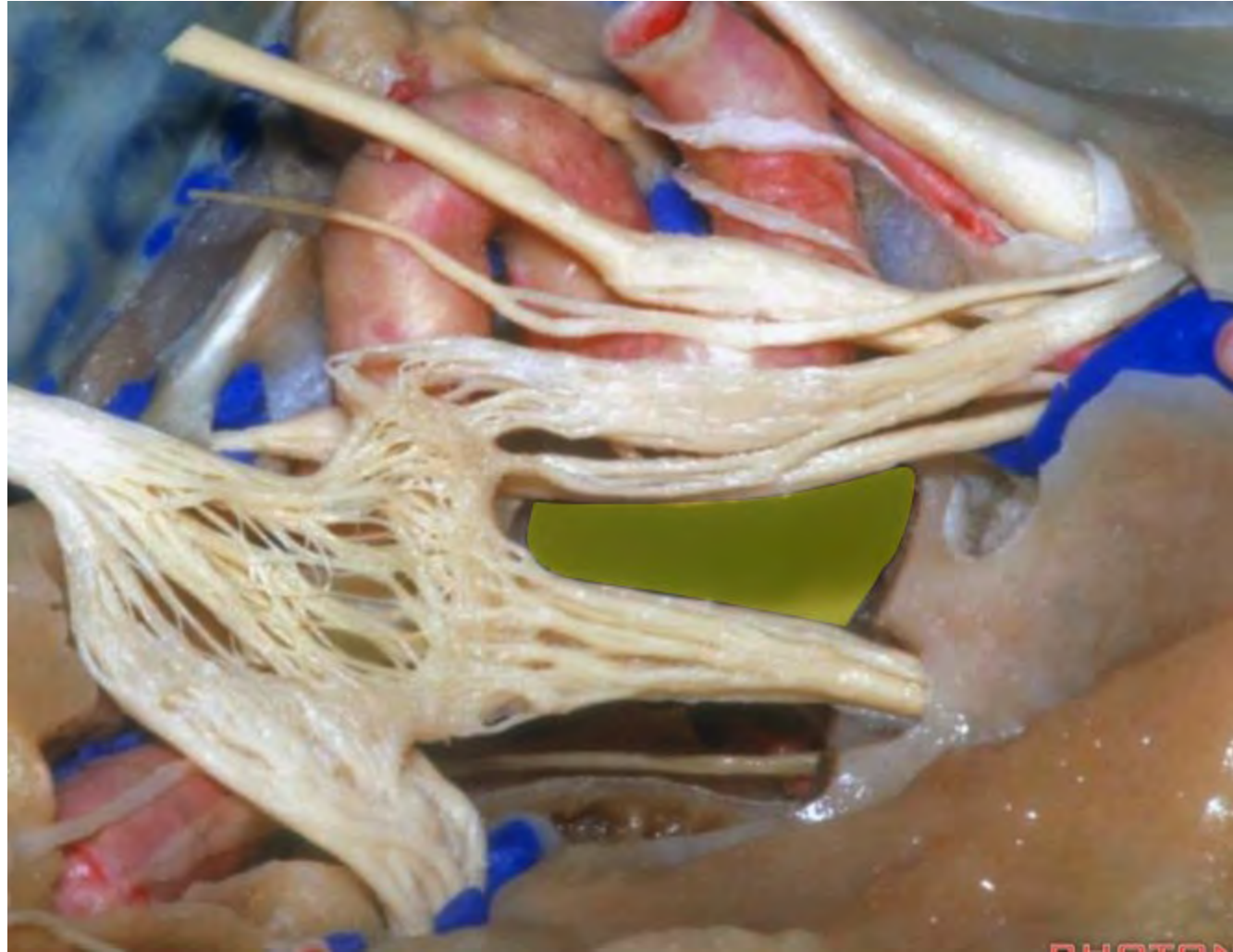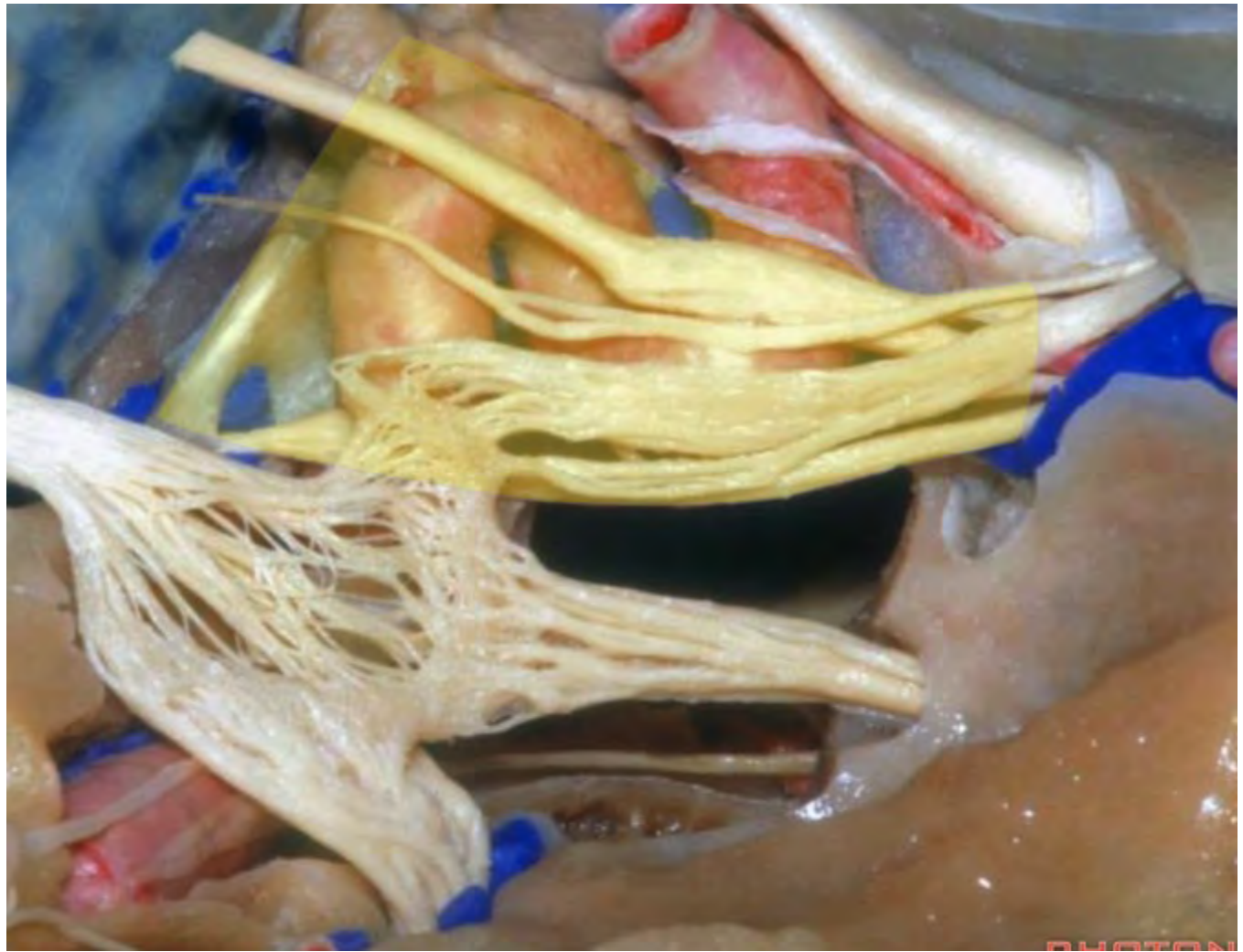








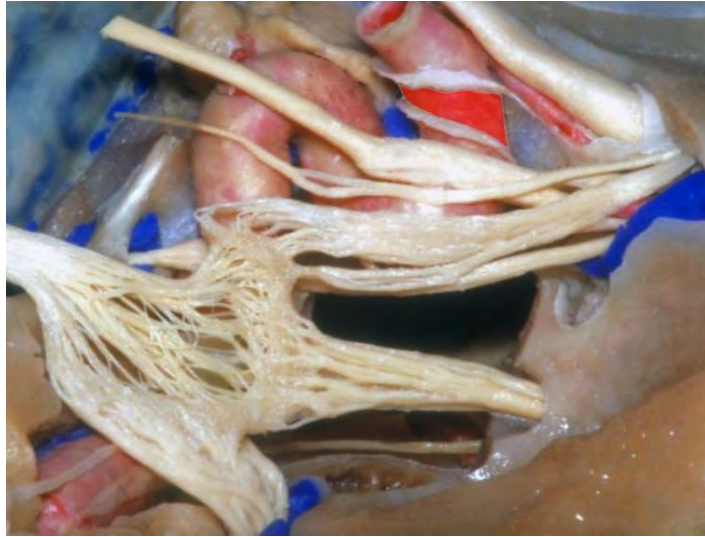




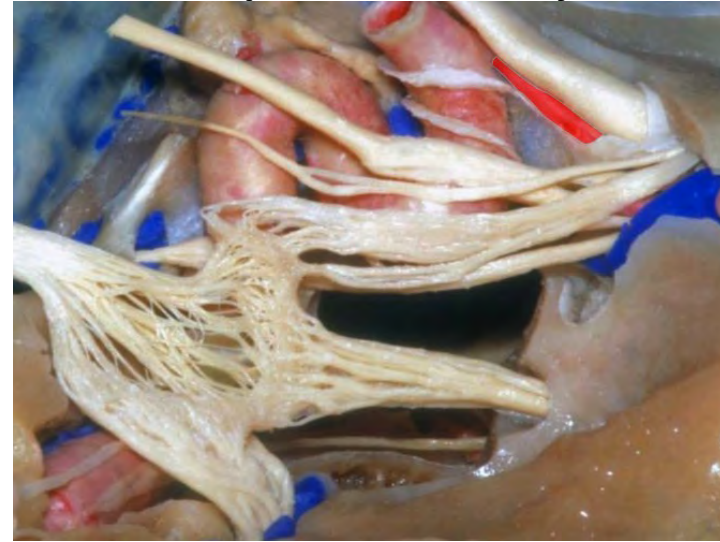
PHOTON



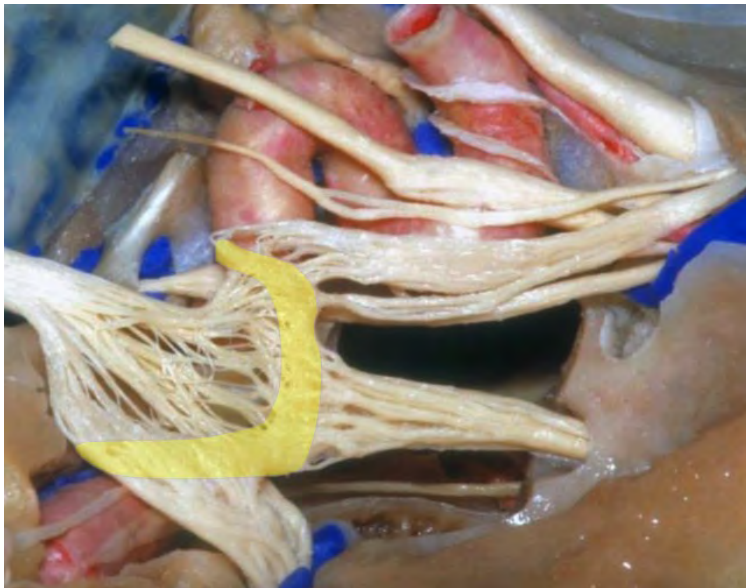**Clinoidal segment of ICA**



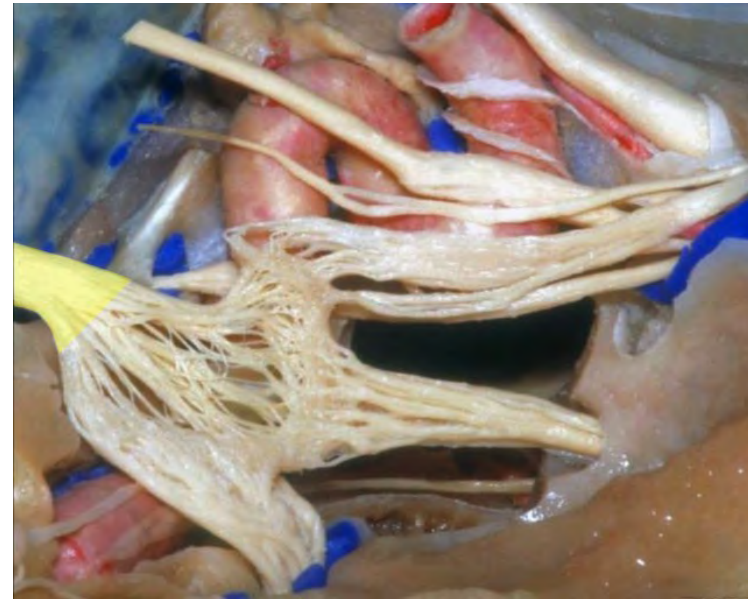
**Ophthalmic artery**

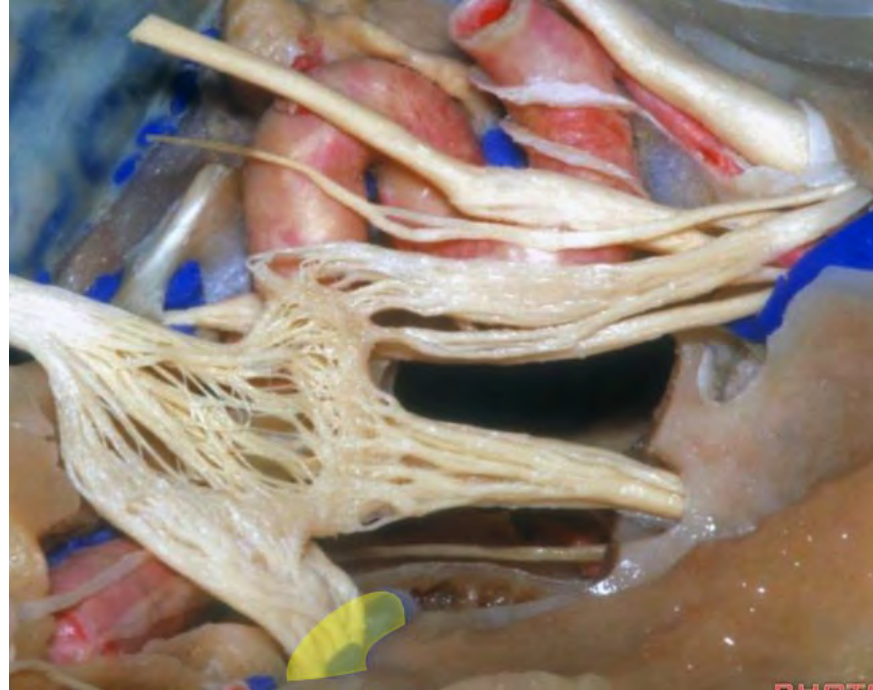
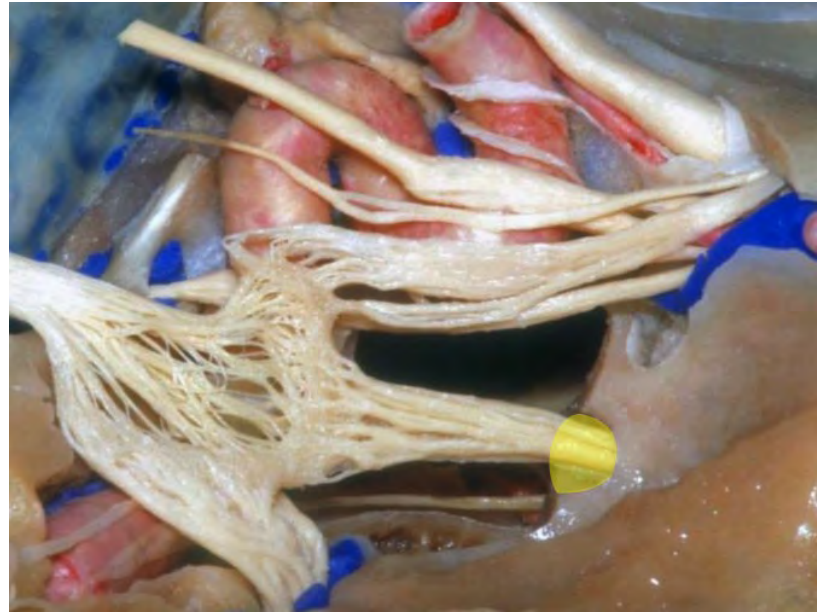
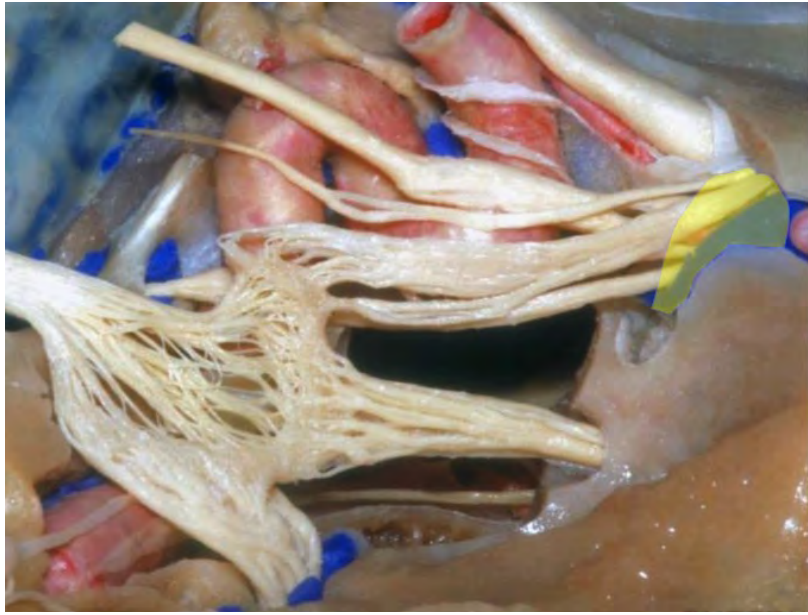


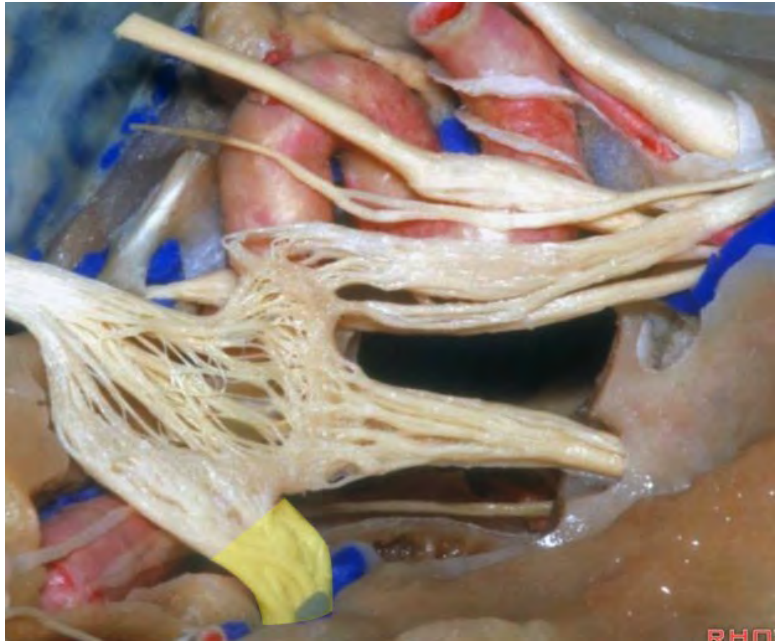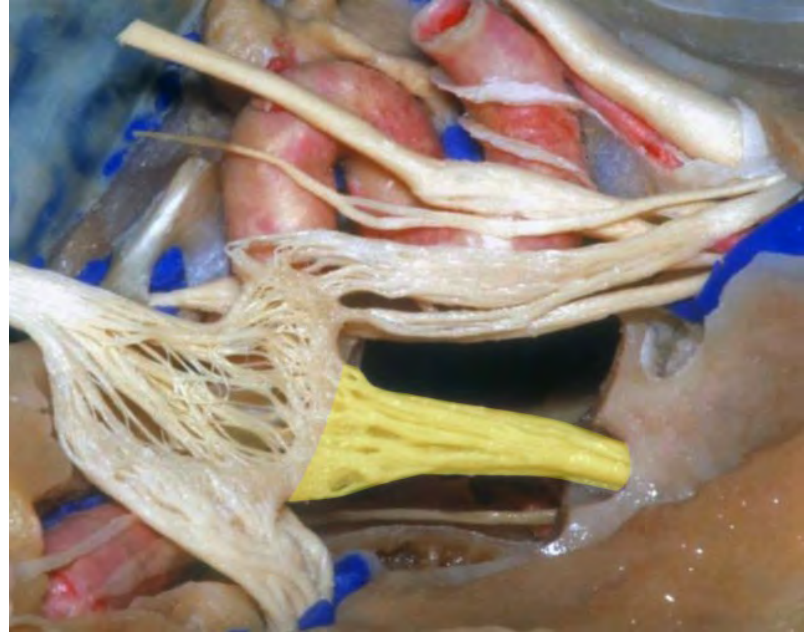
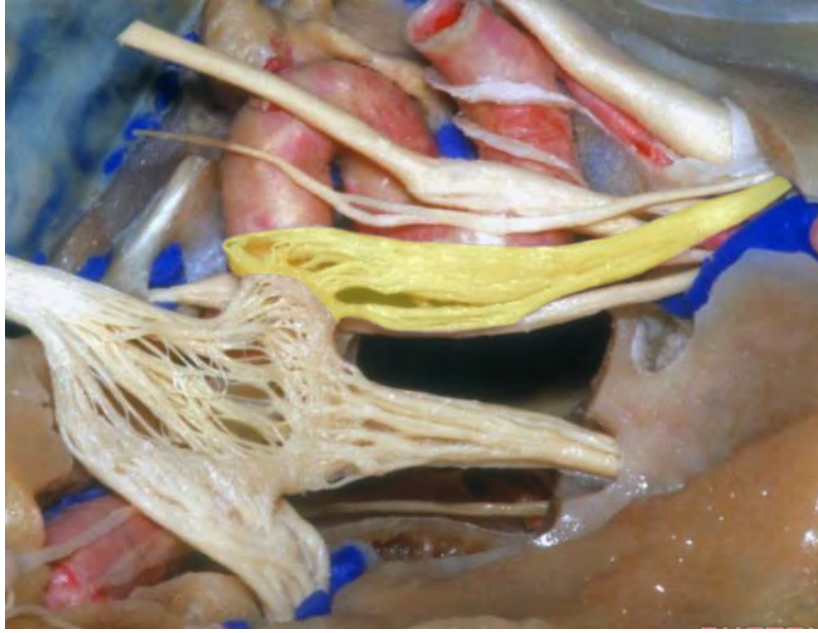
**Trigeminal ganglion**



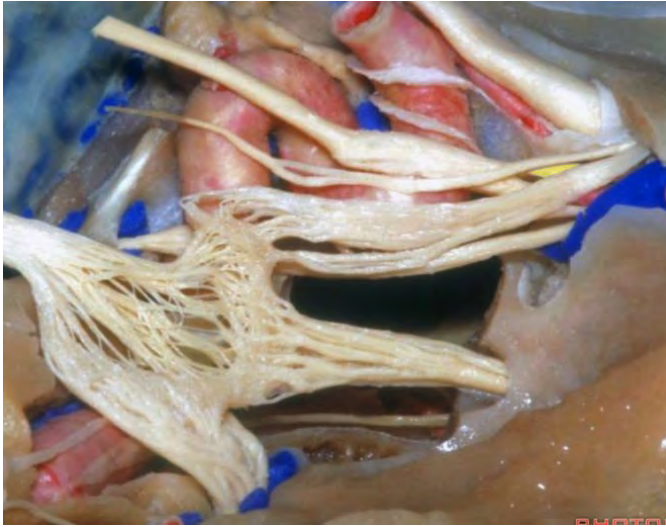**Trigeminal nerve**



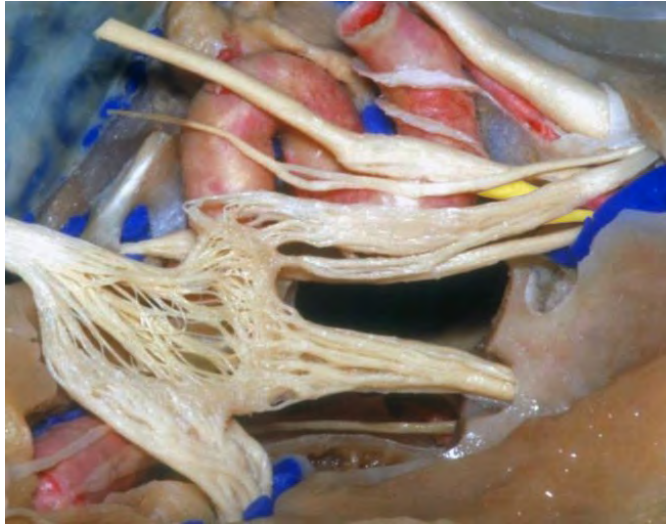



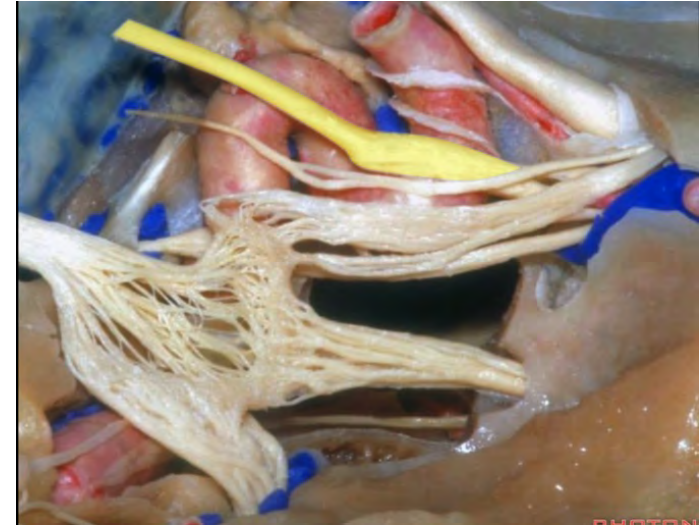
**Superior division of oculomotor nerve**



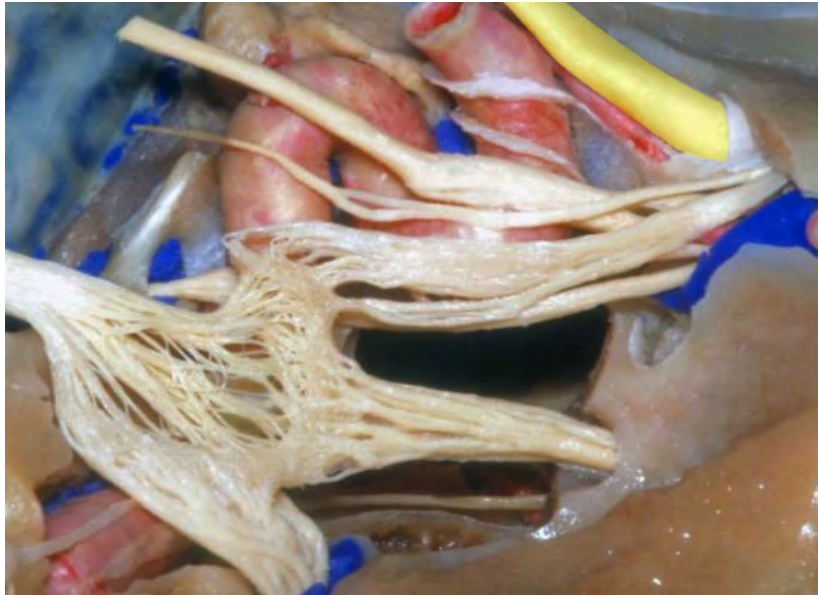**Inferior division of oculomotor nerve**



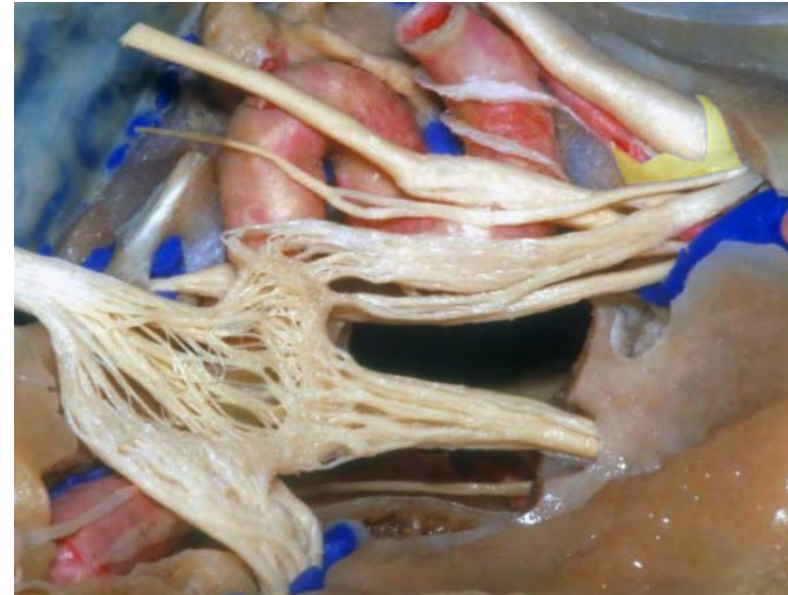
**Oculomotor nerve**



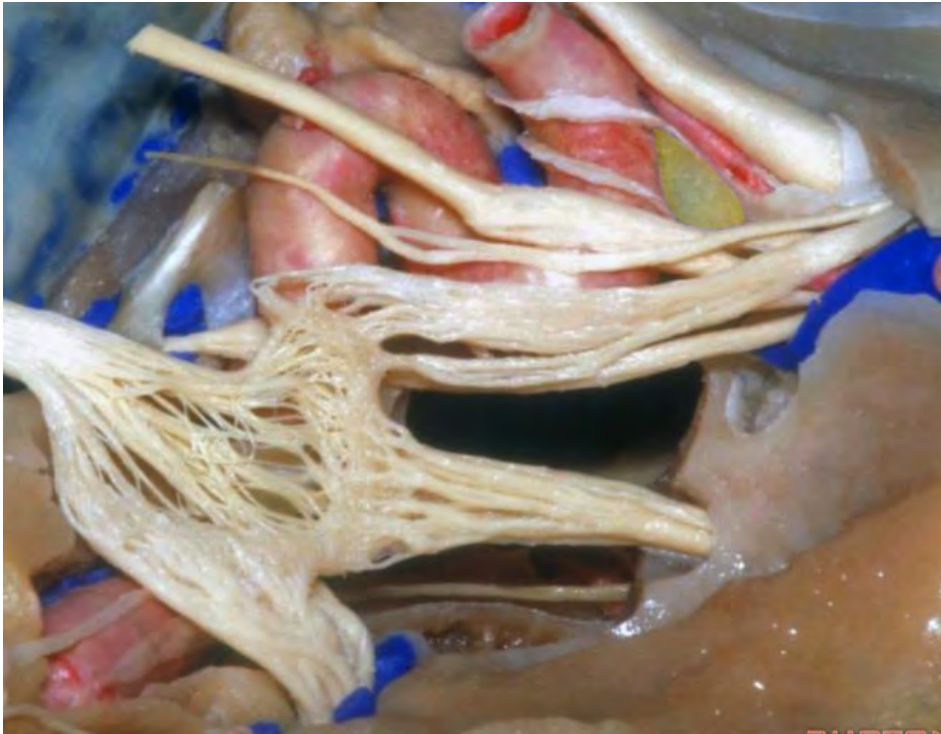**Optic nerve**



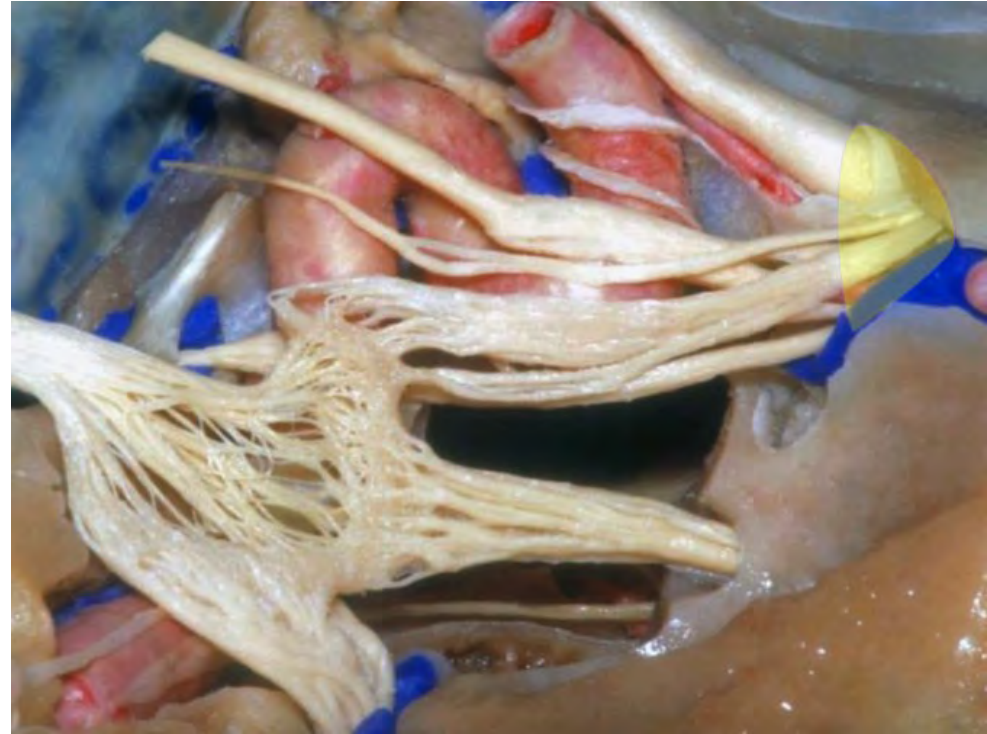
**Optic nerve sheath**



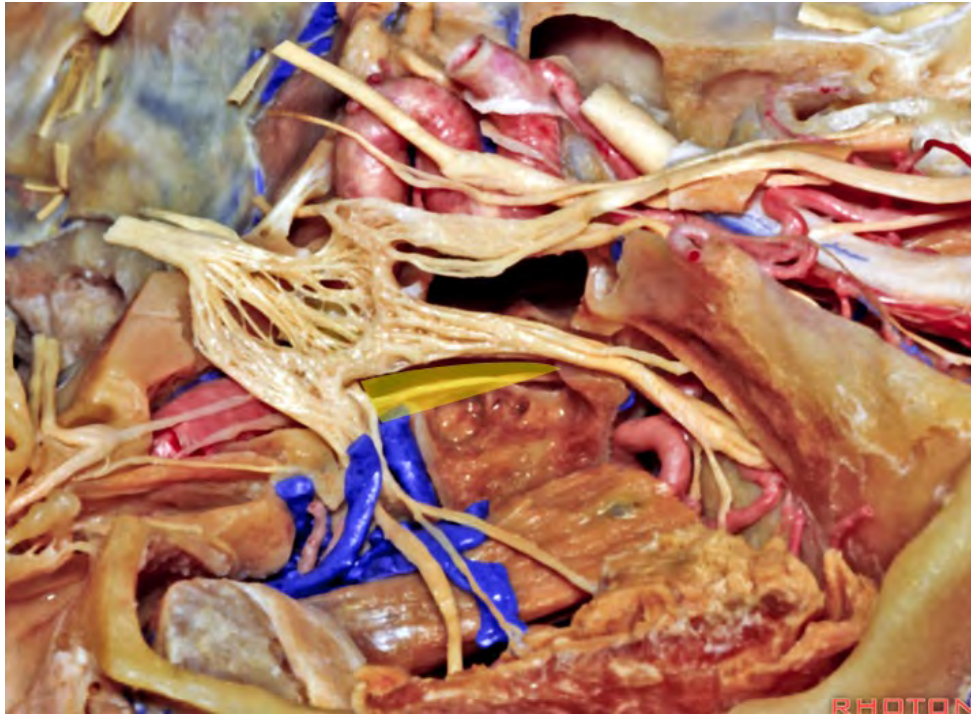
**Optic strut**



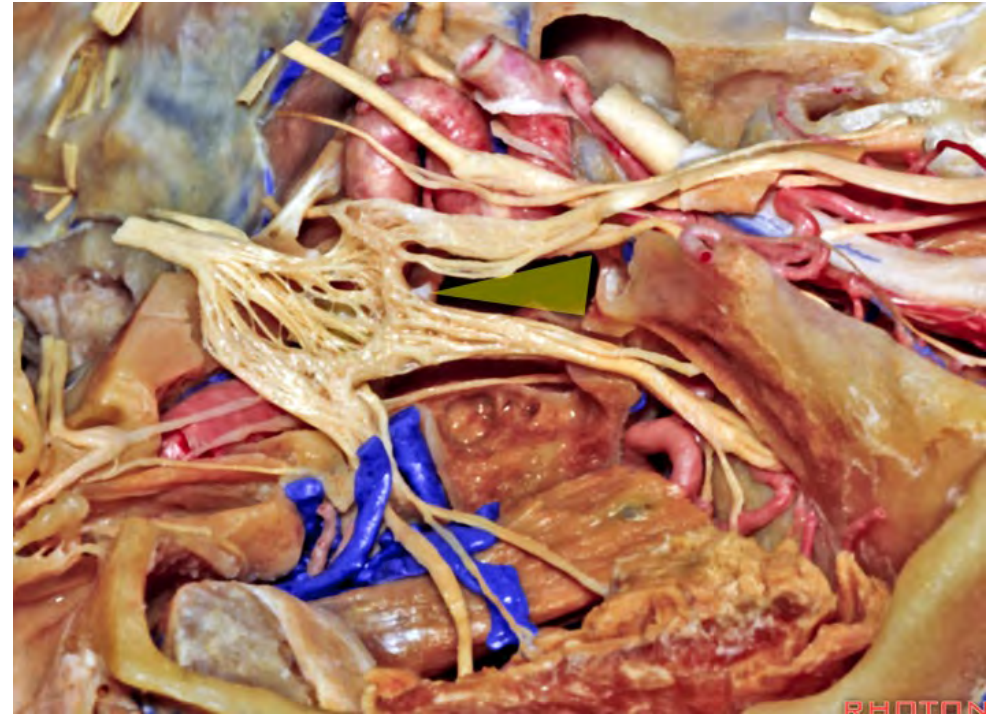
**Orbital apex**



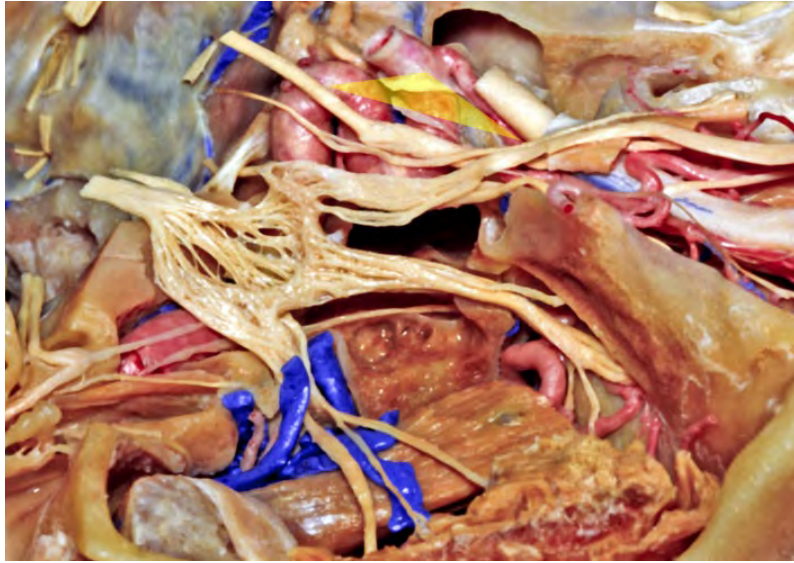**Anterolateral triangle**



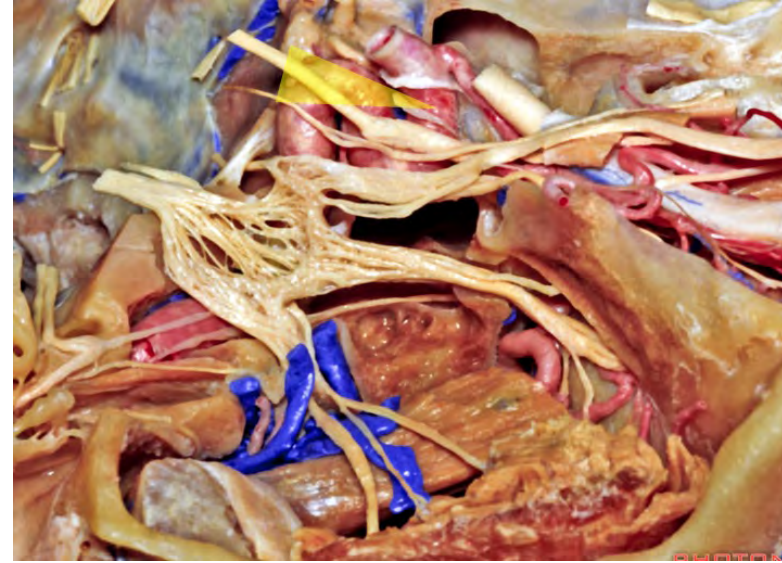
**Anteromedial triangle**



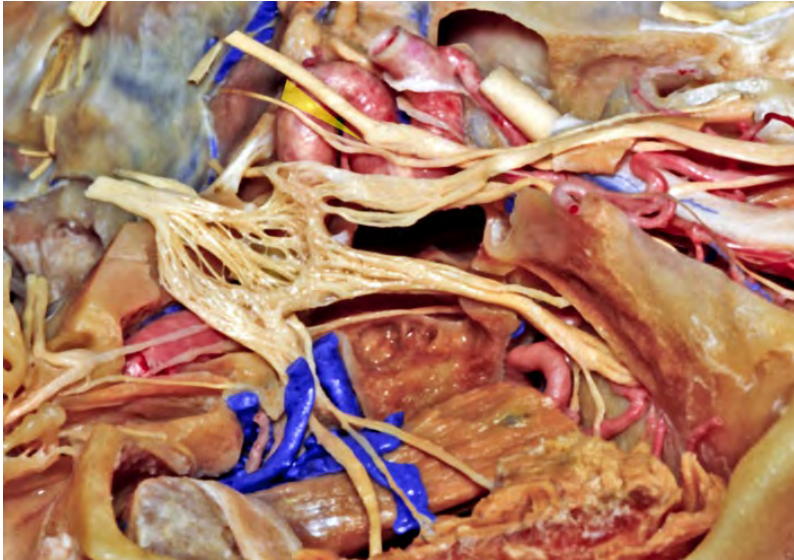**Clinoidal triangle**



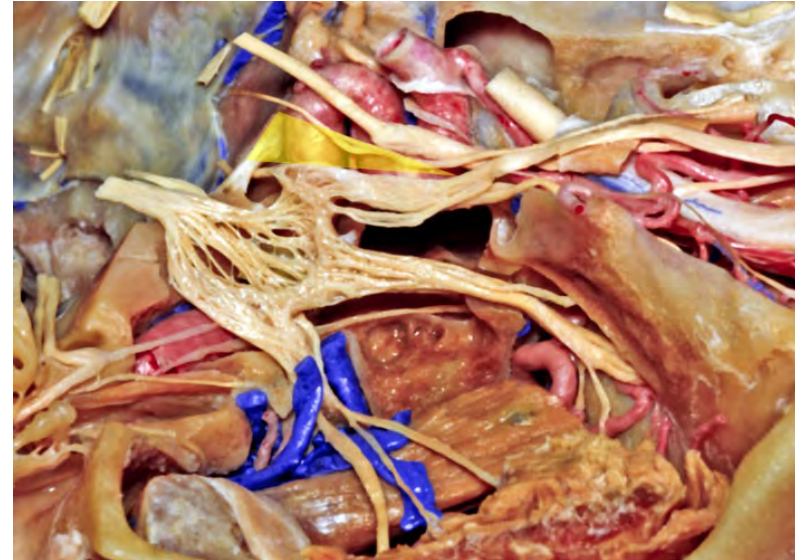**Oculomotor triangle**

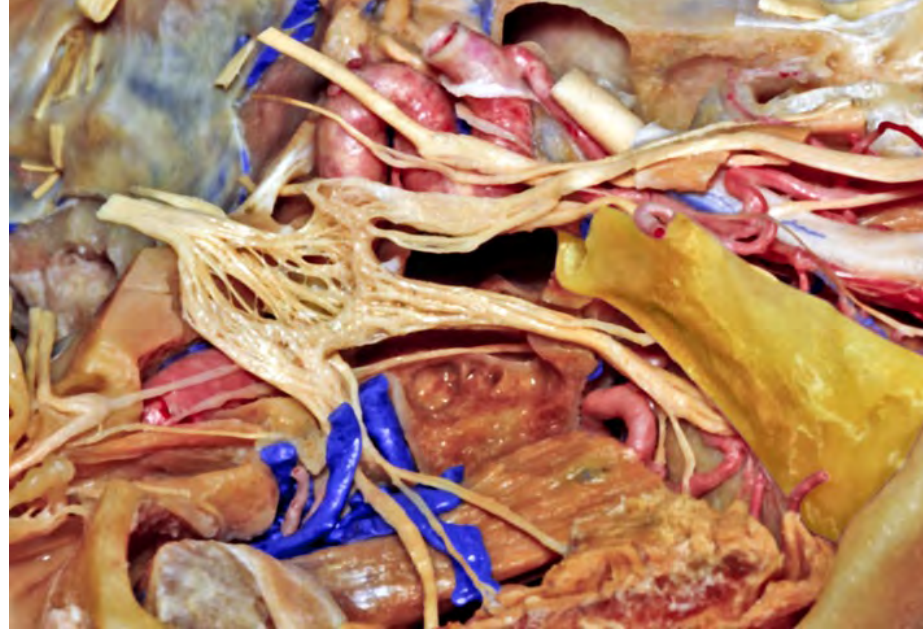
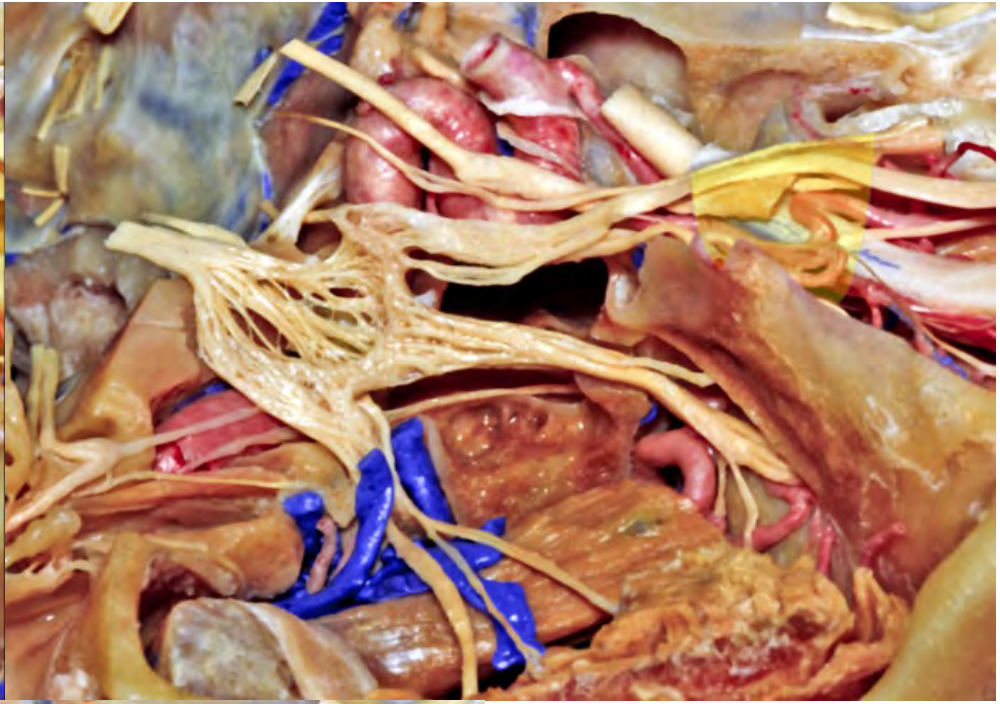
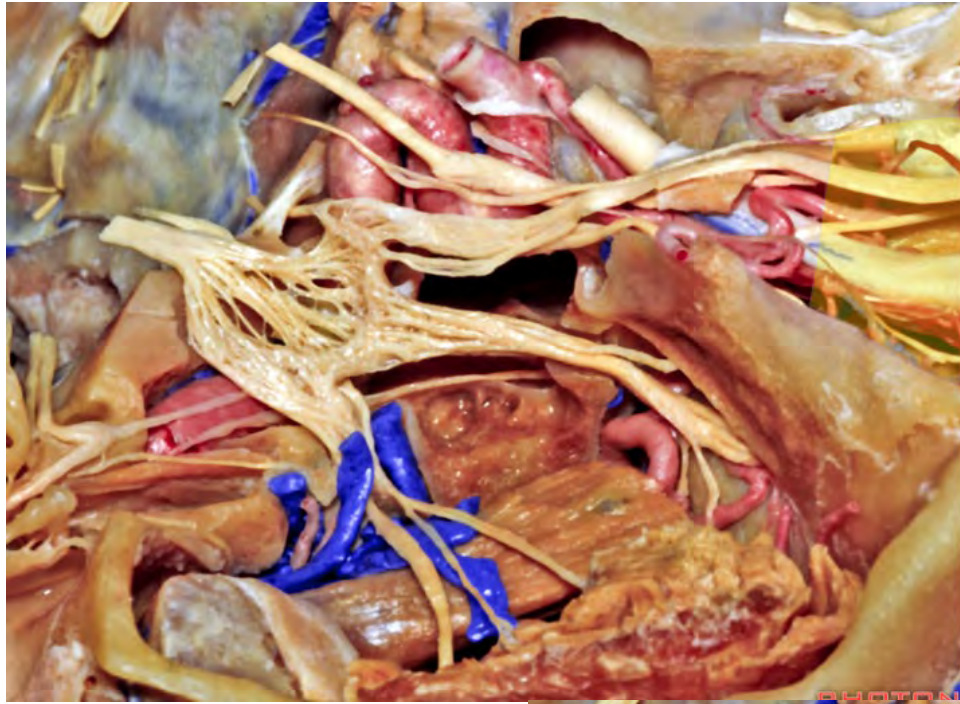


**Supratrochlear triangle**

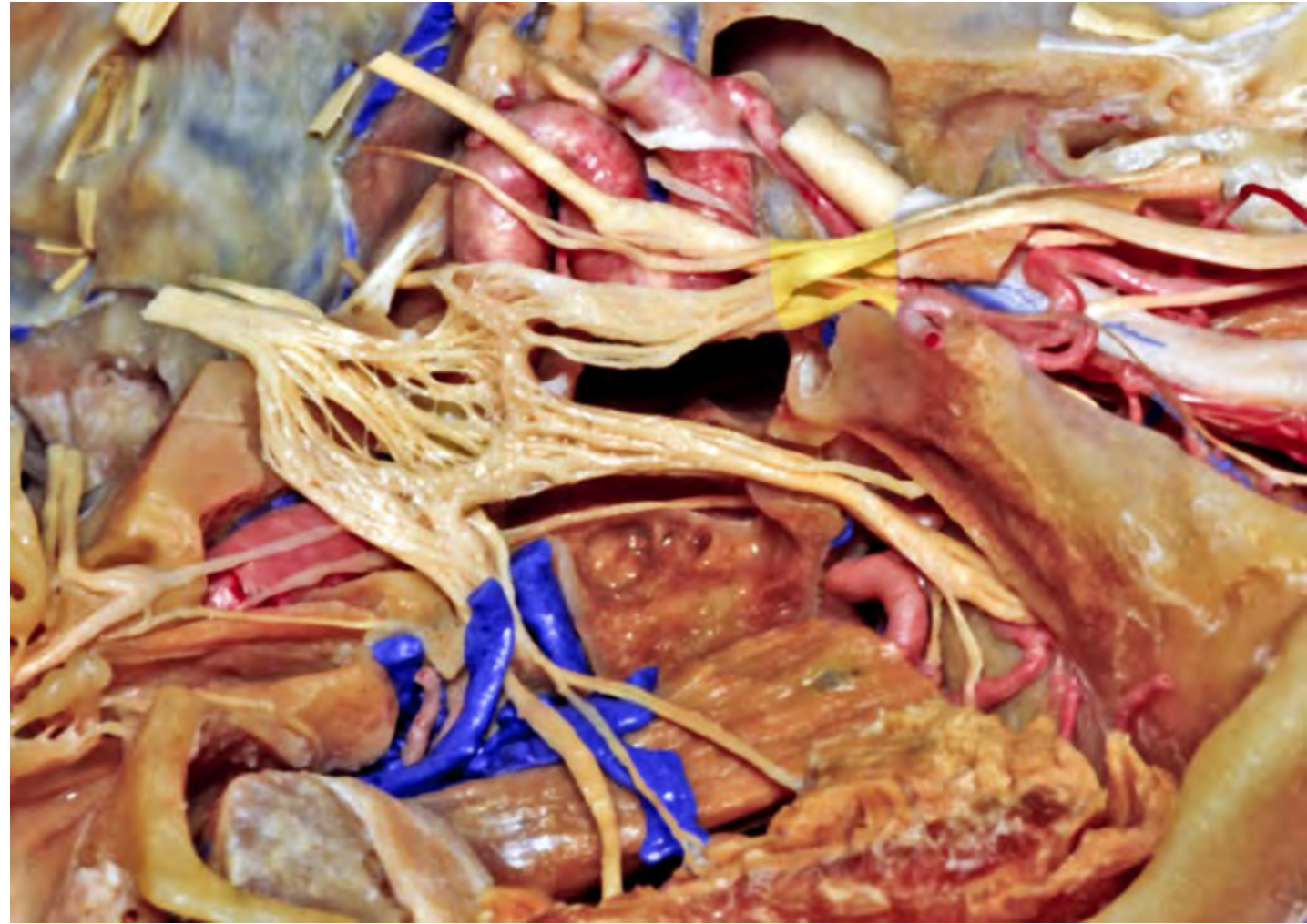


**Infratrochlear triangle**

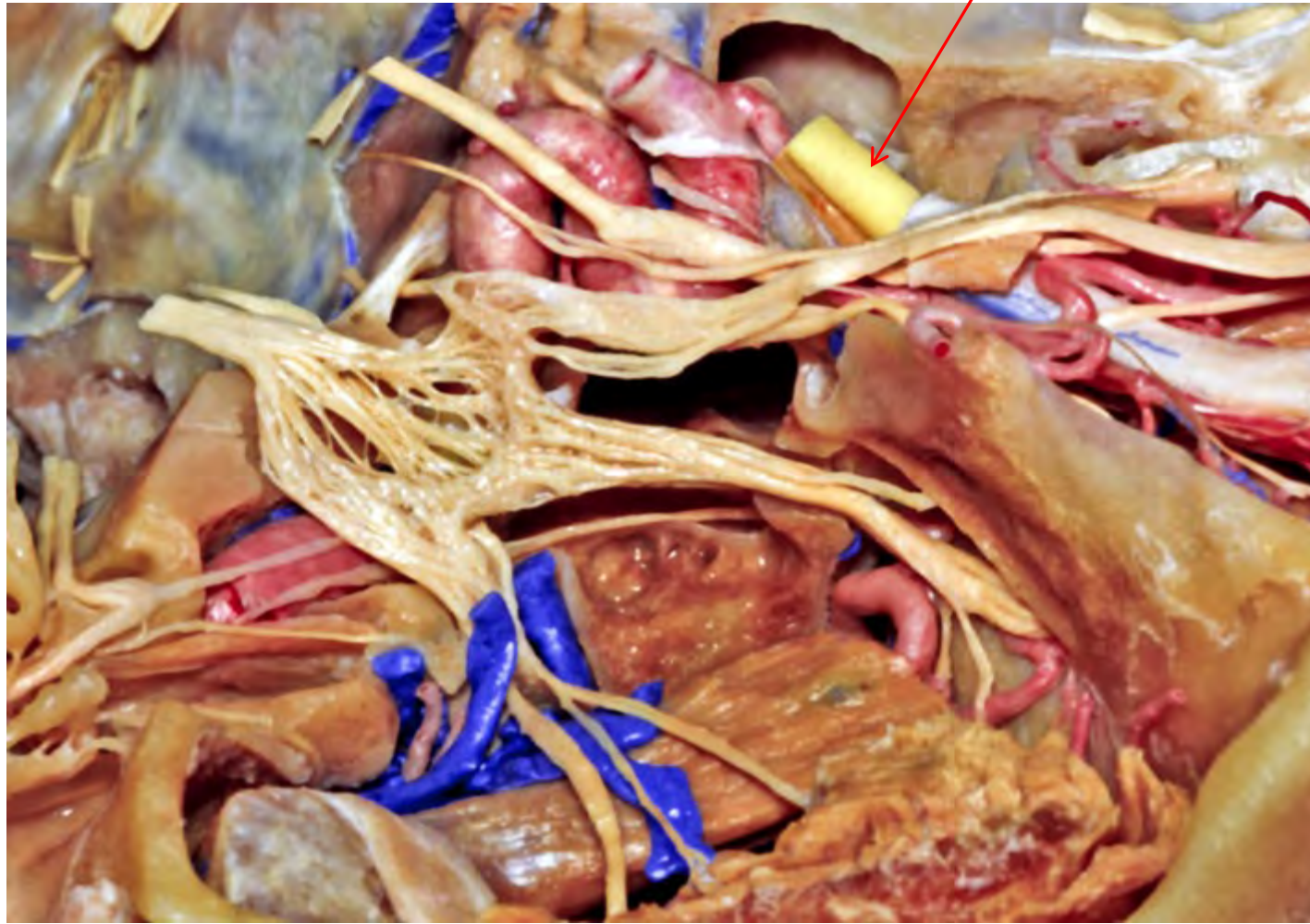




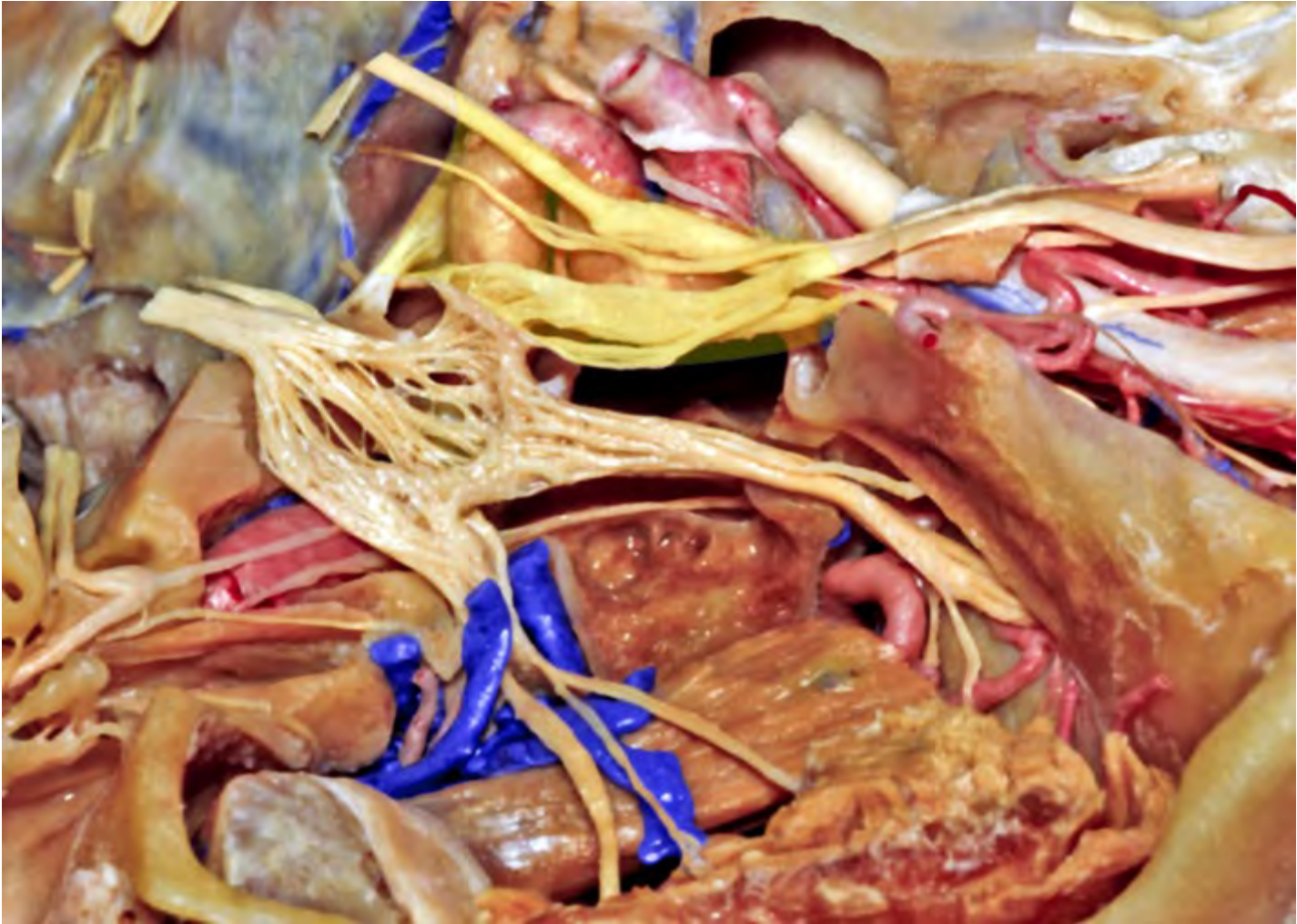


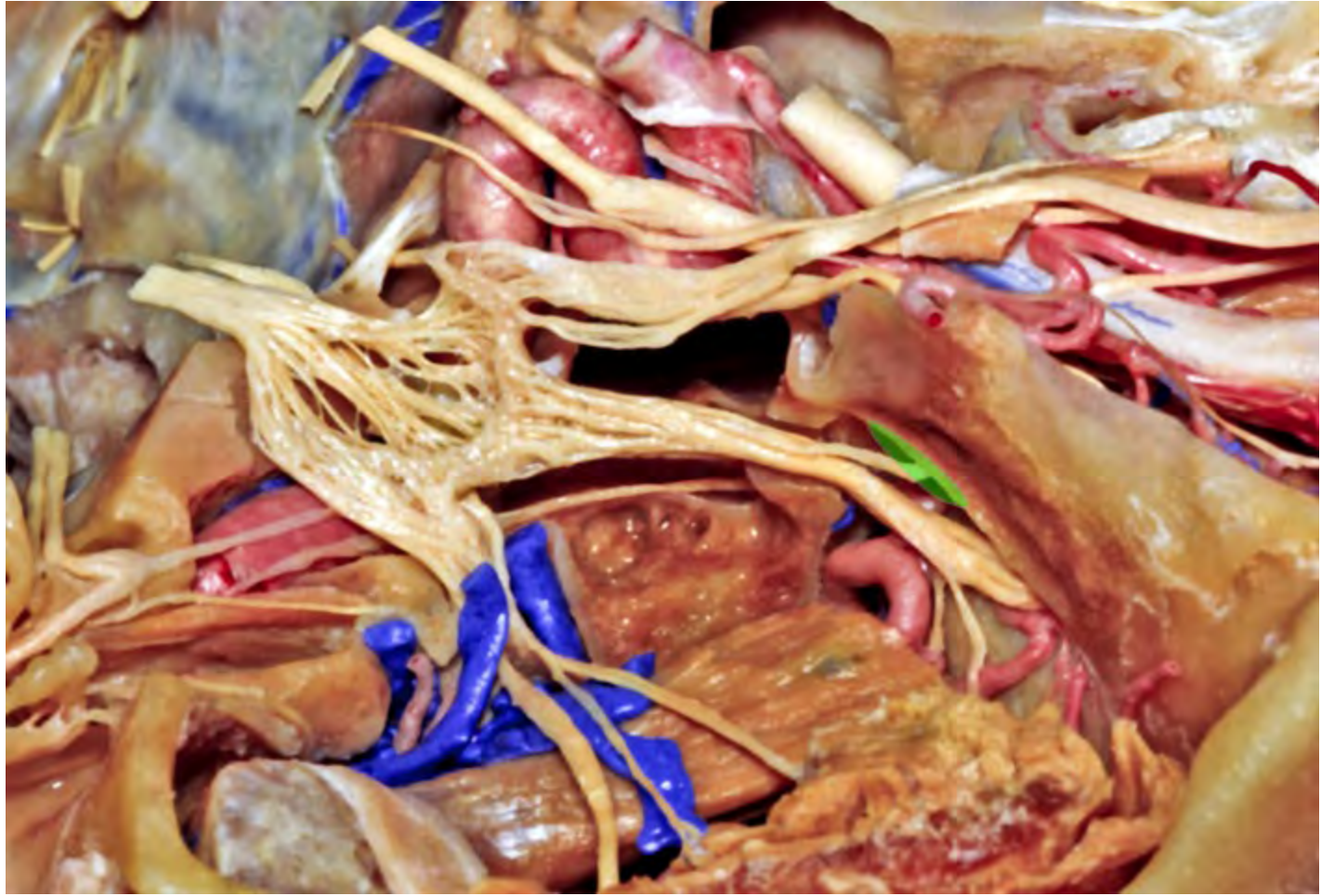


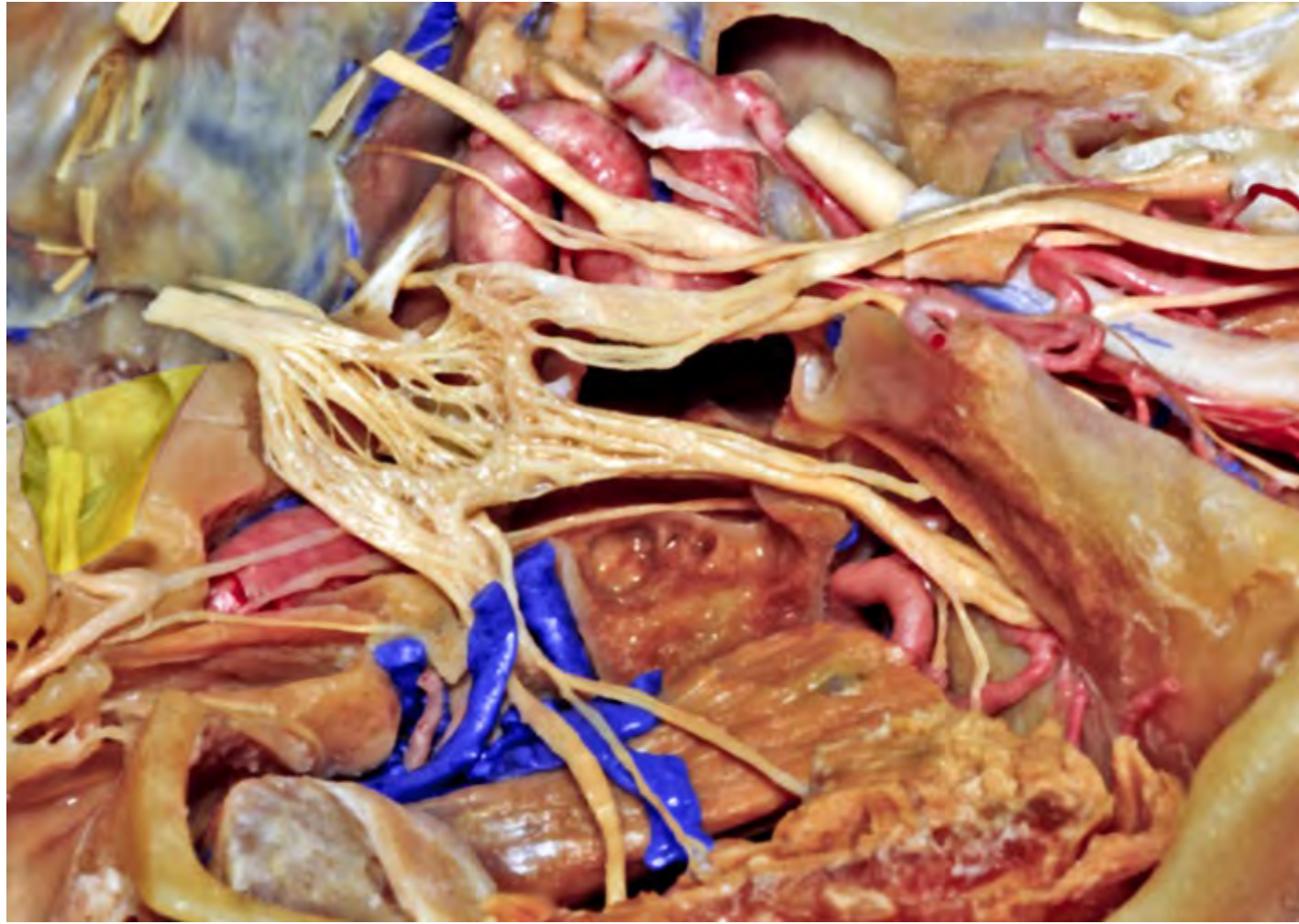
**Optic canal**

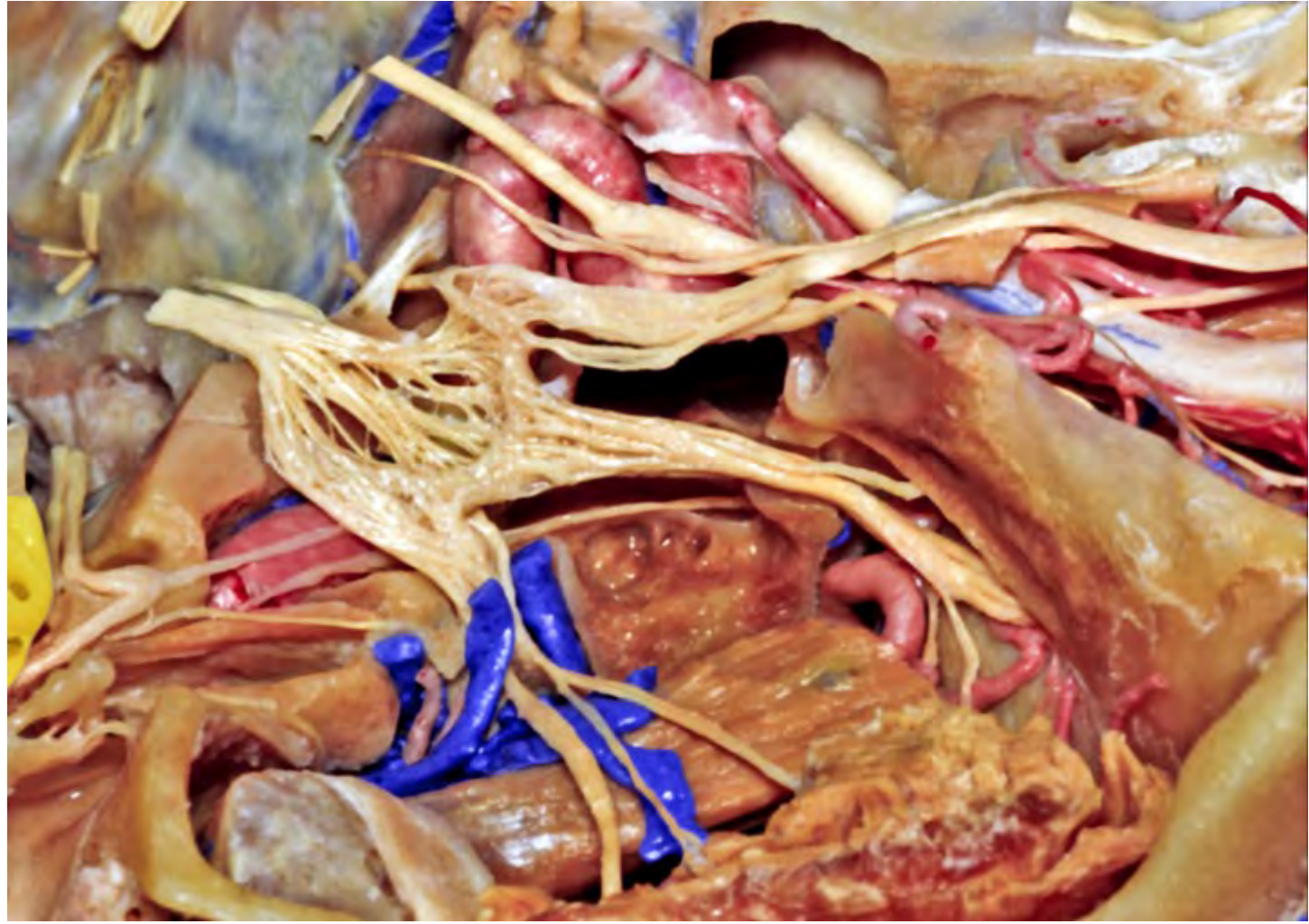


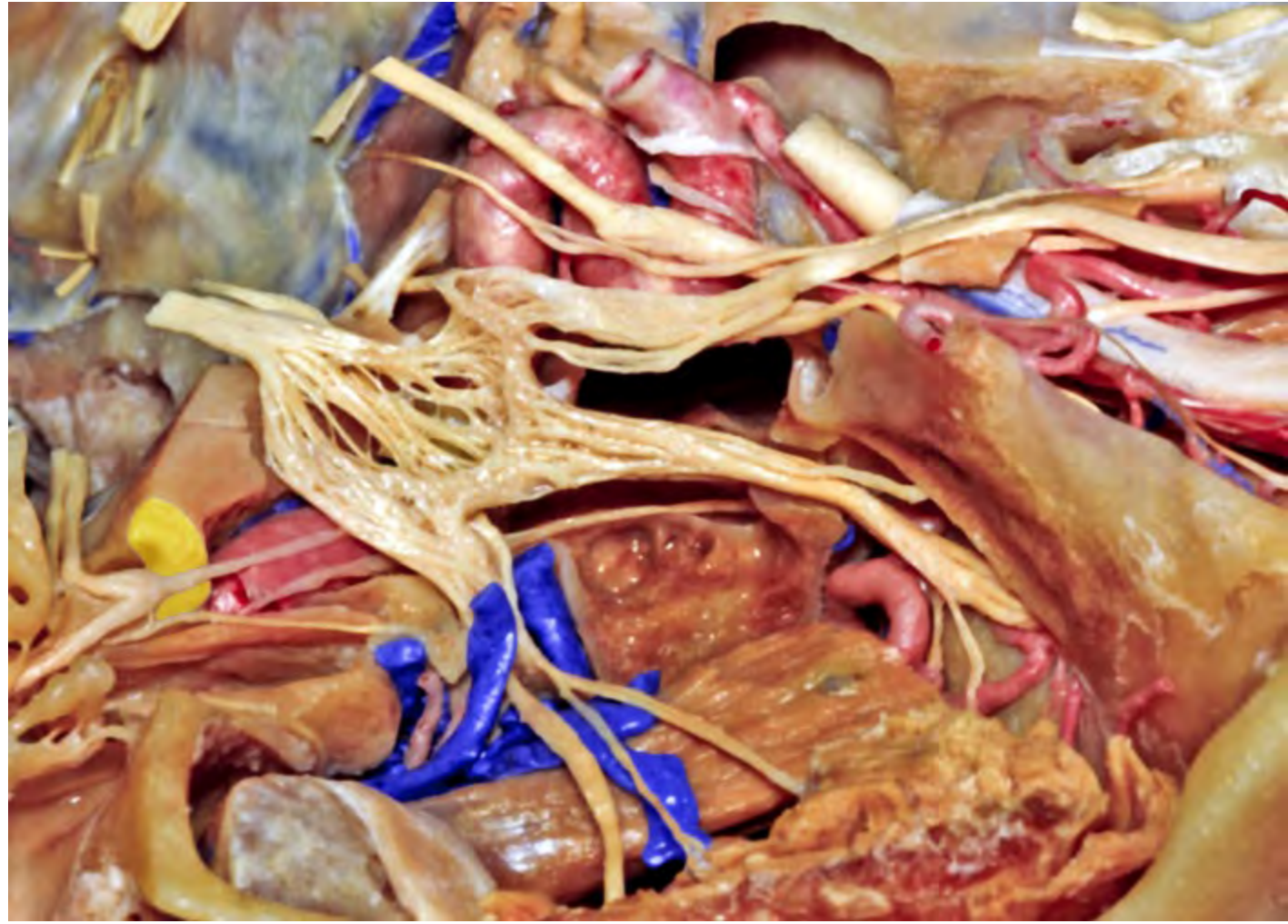
**Cavernous sinus**

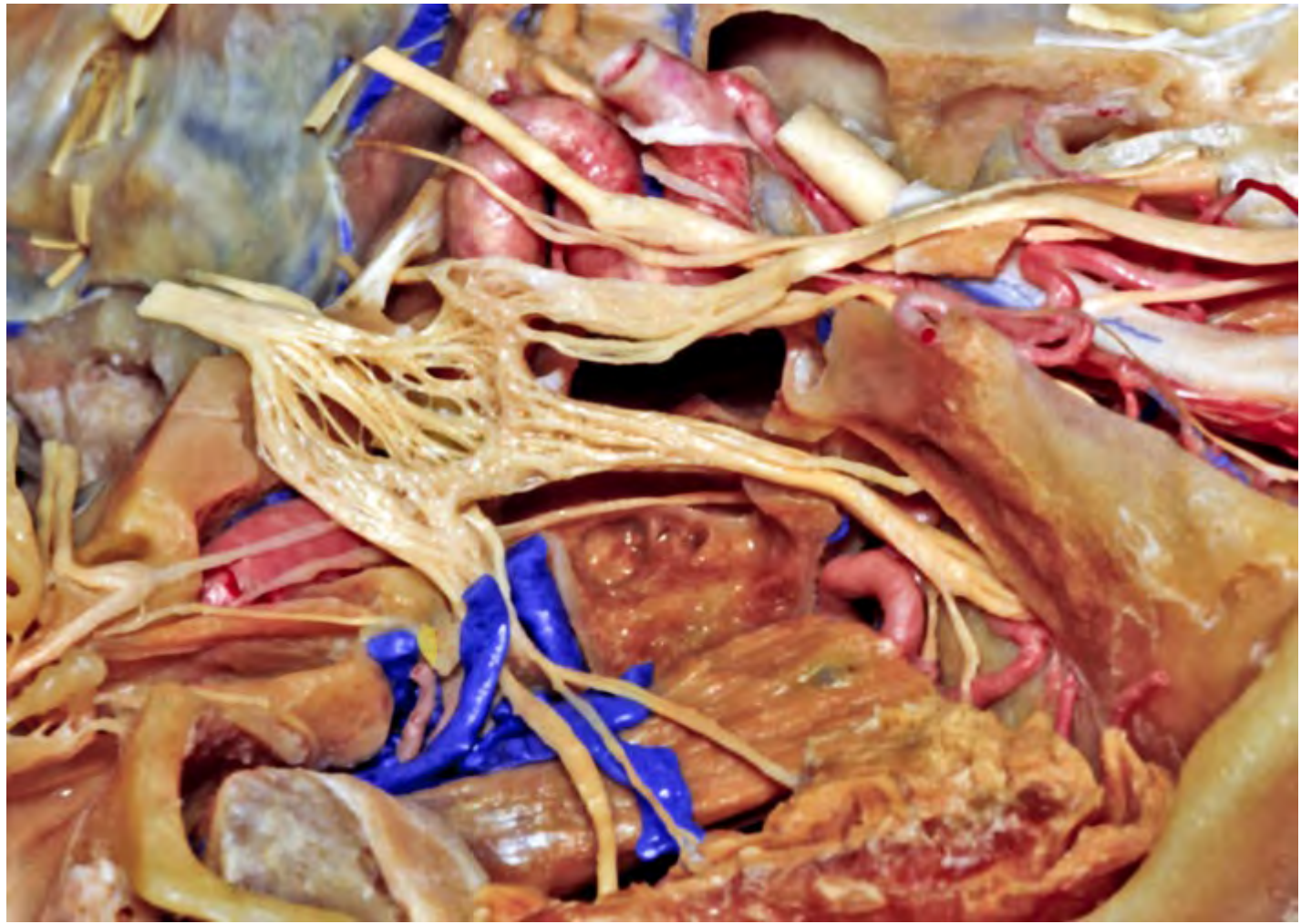




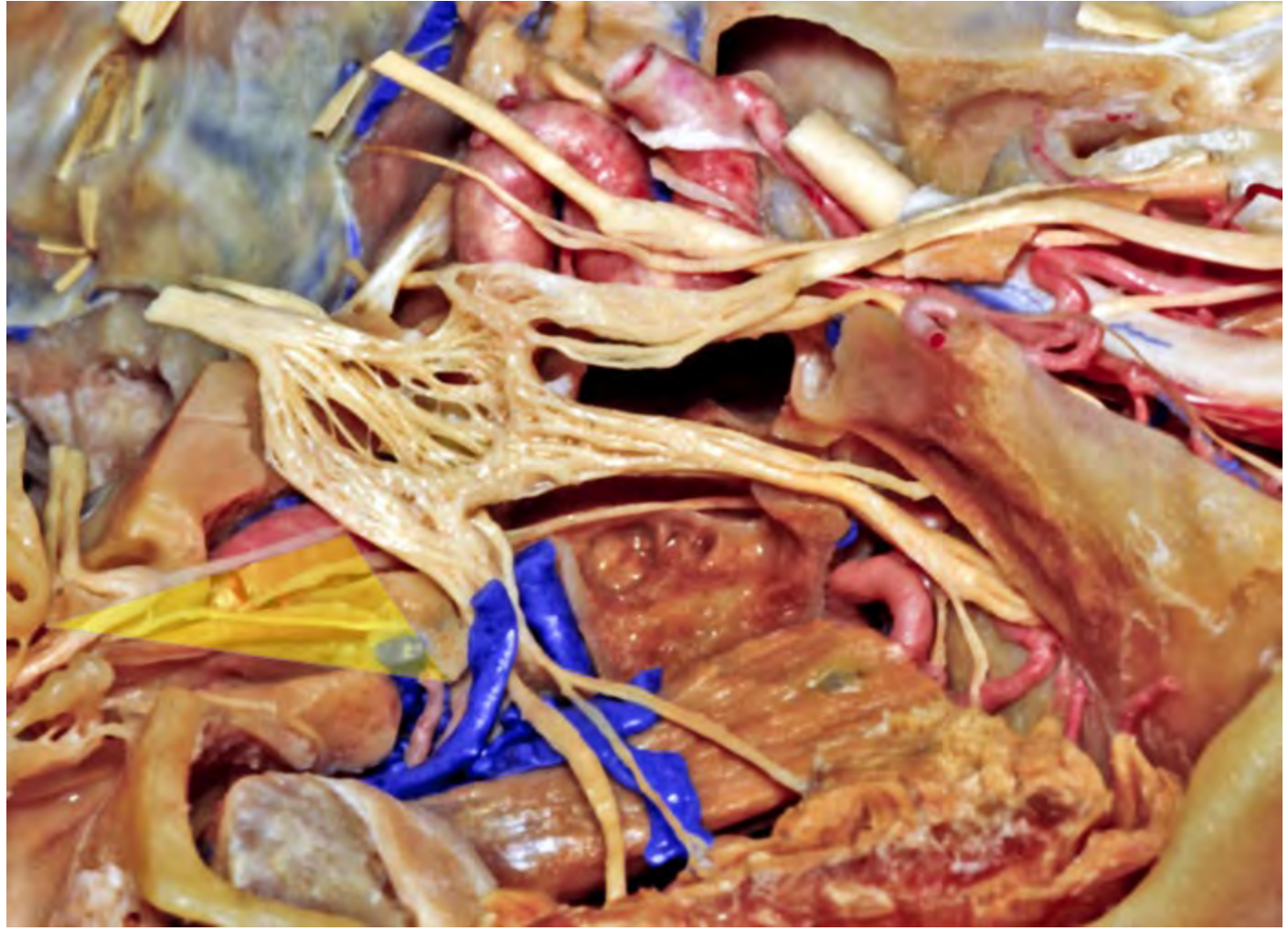

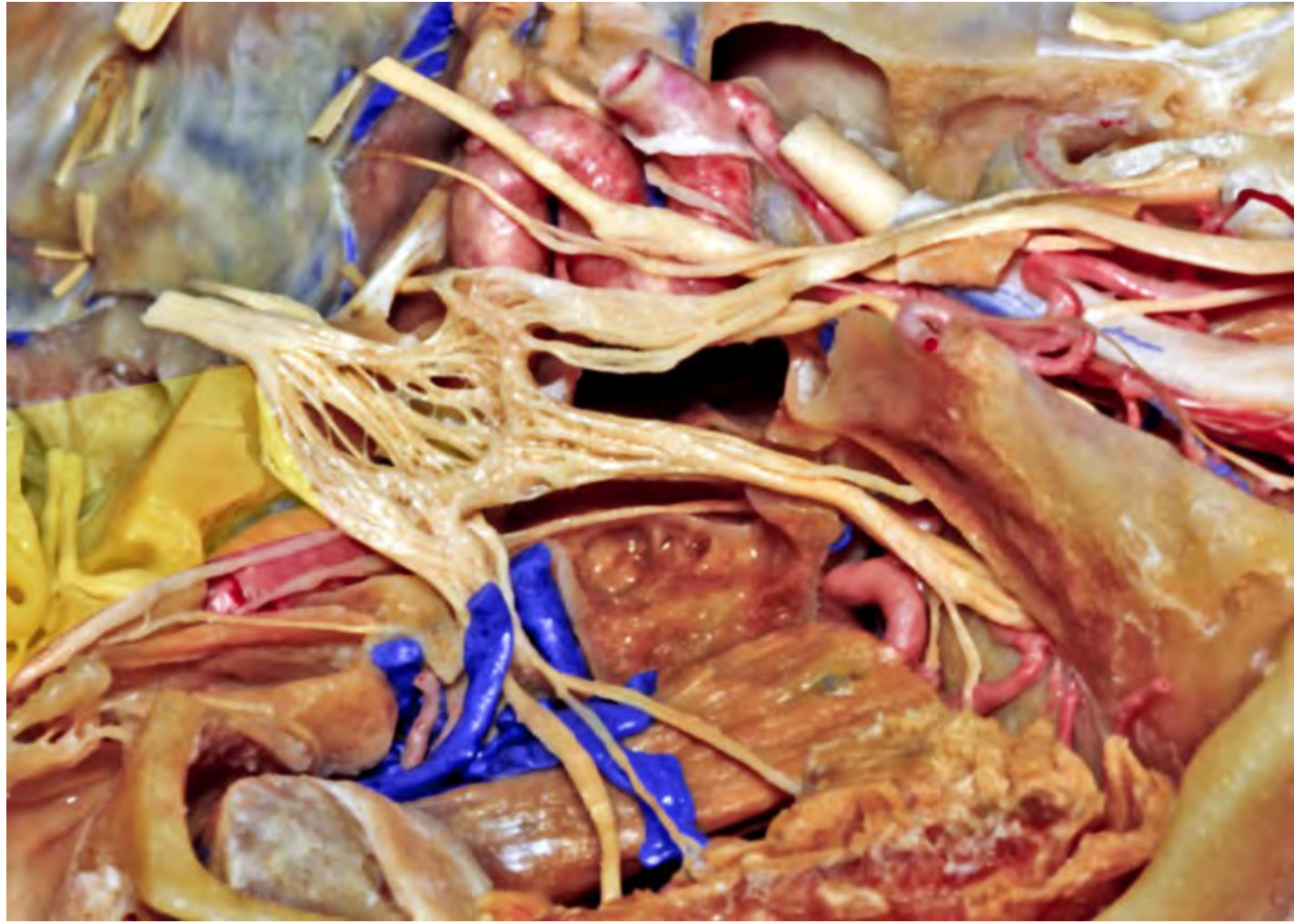


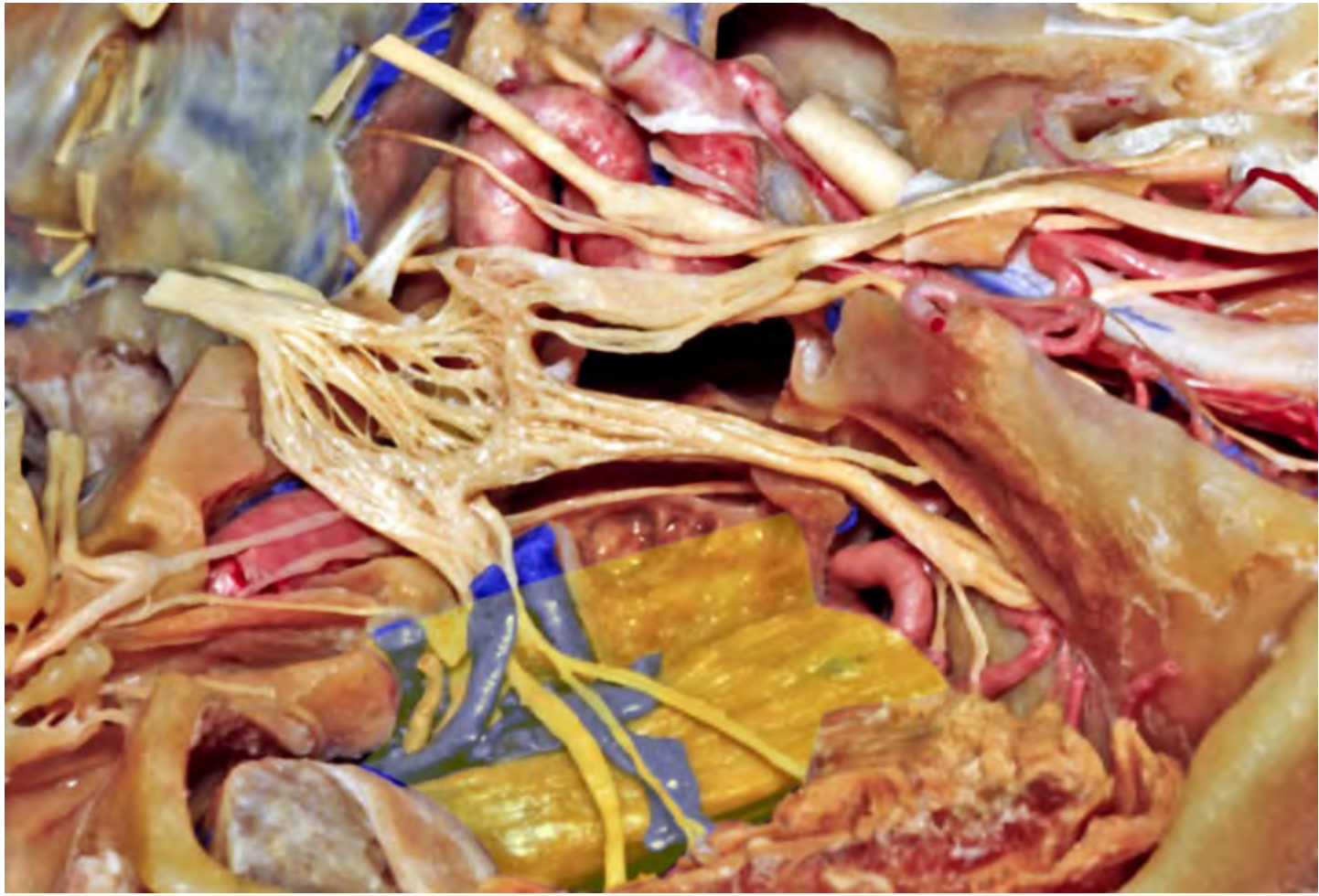



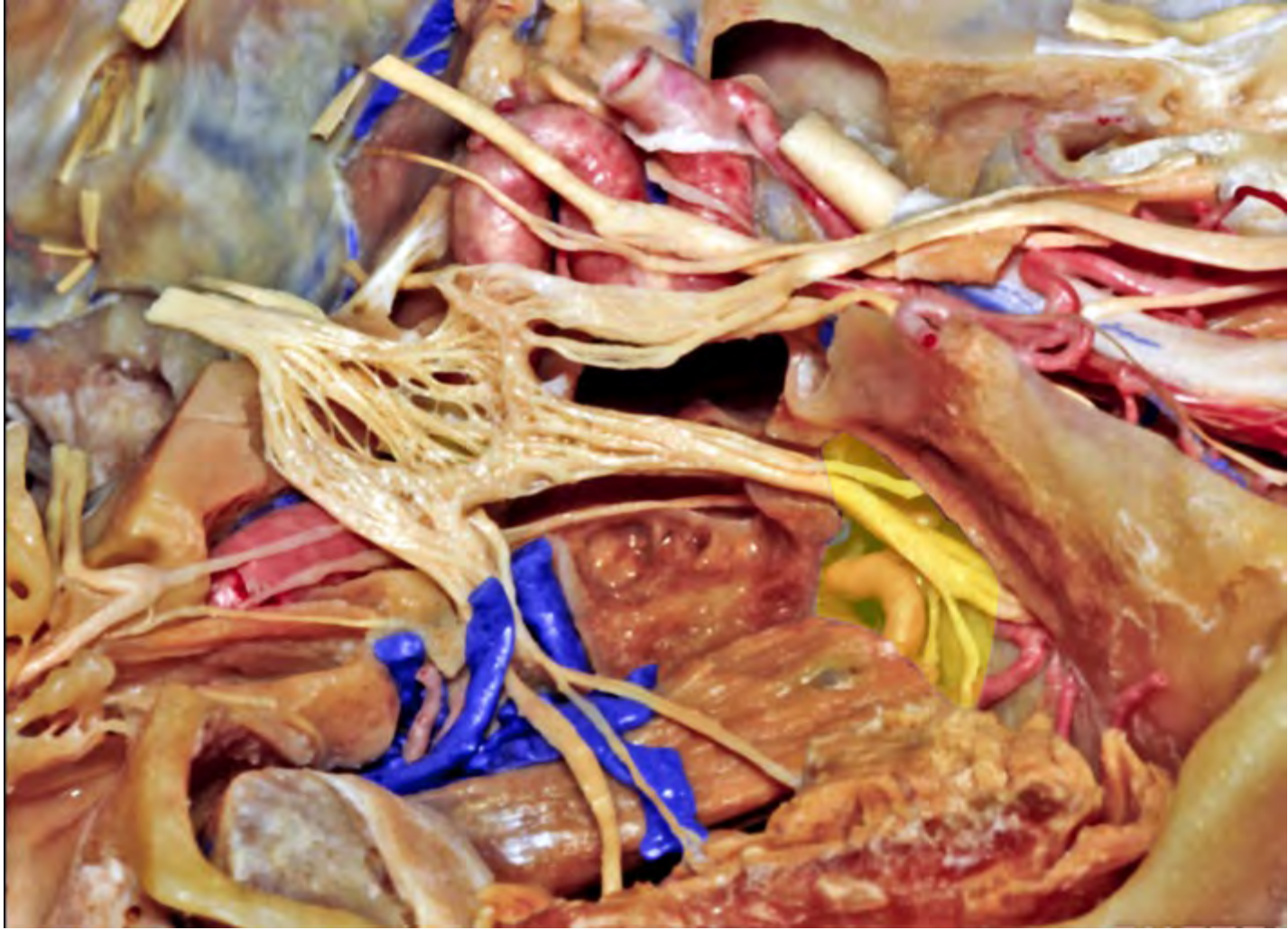
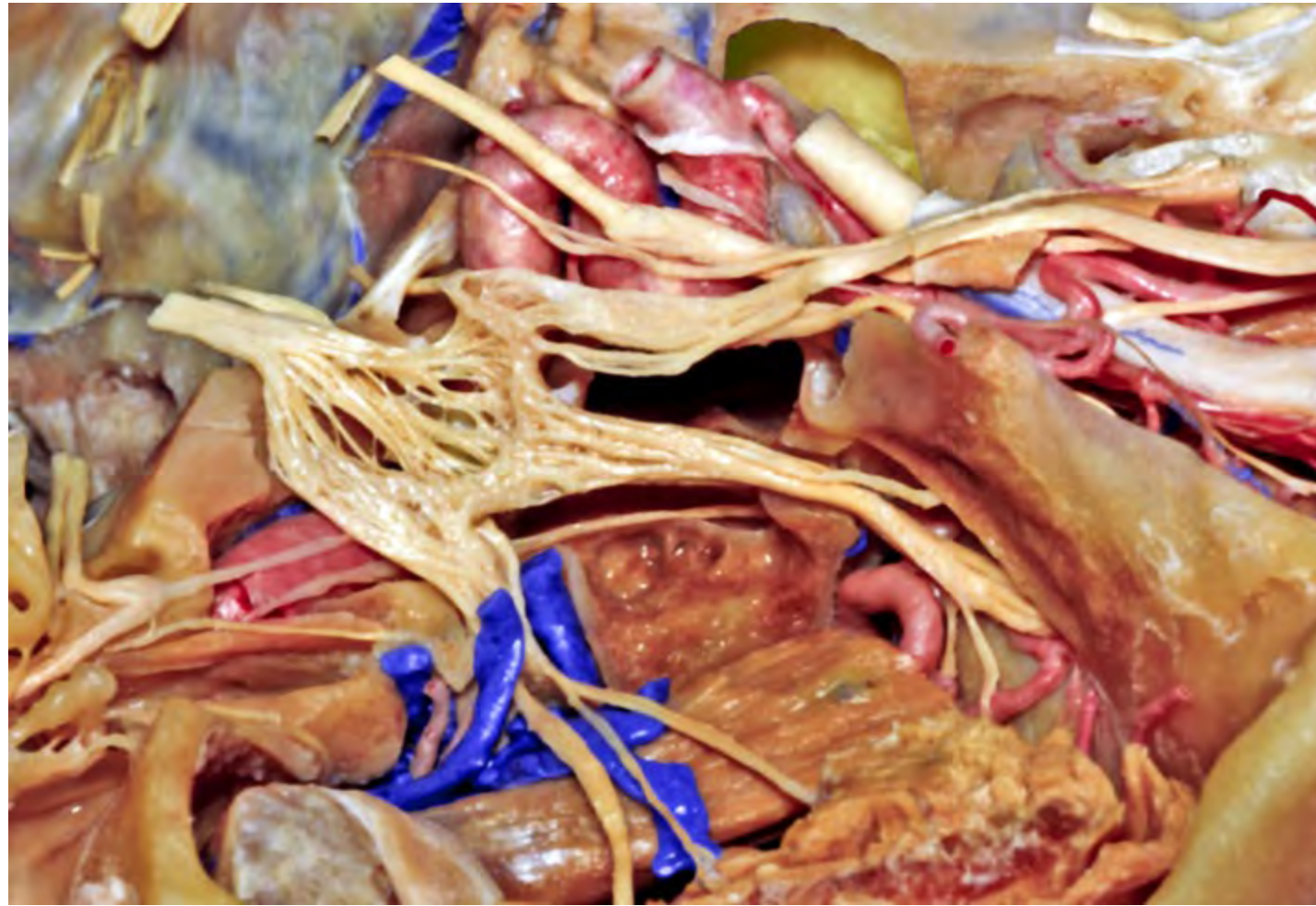


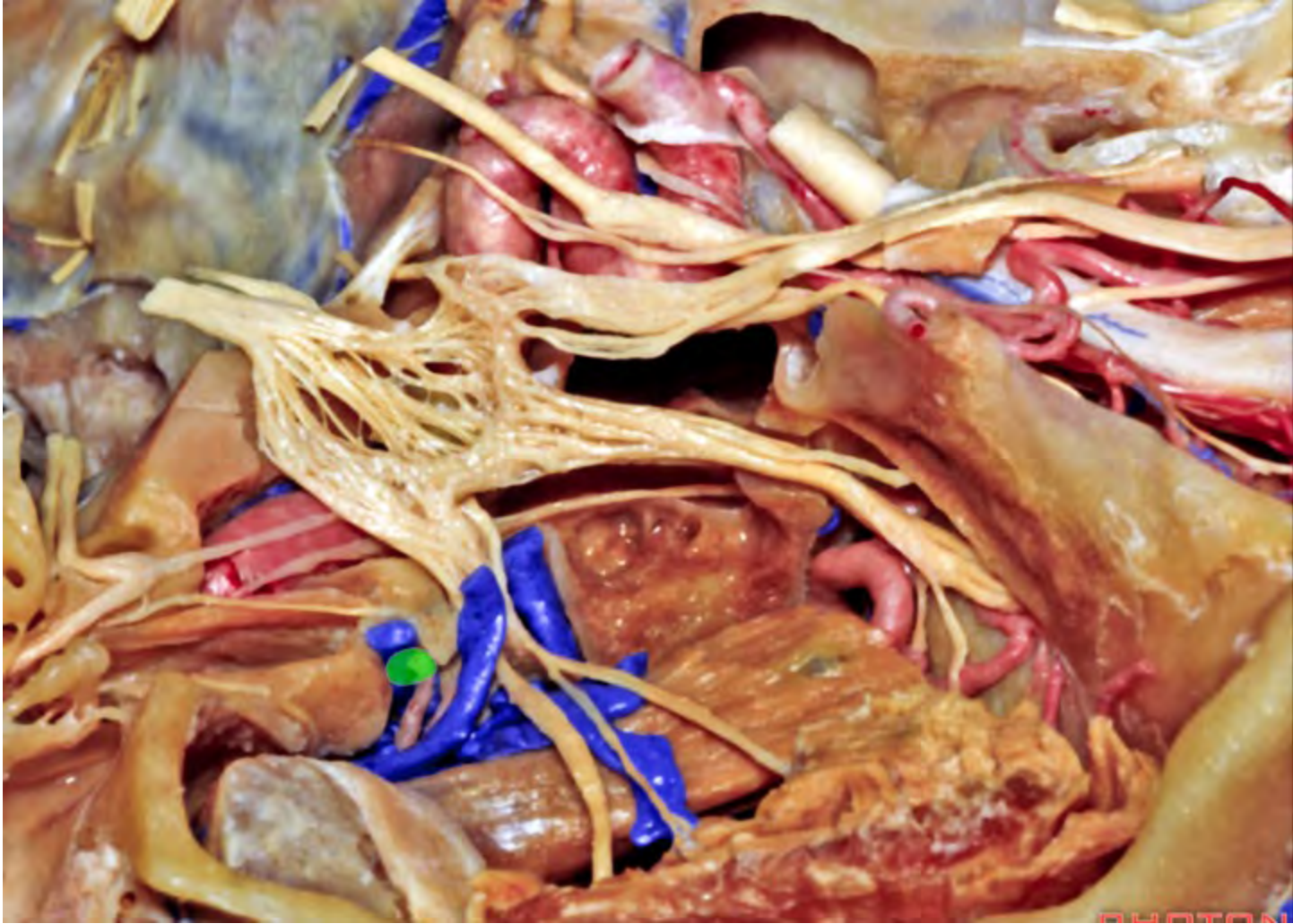


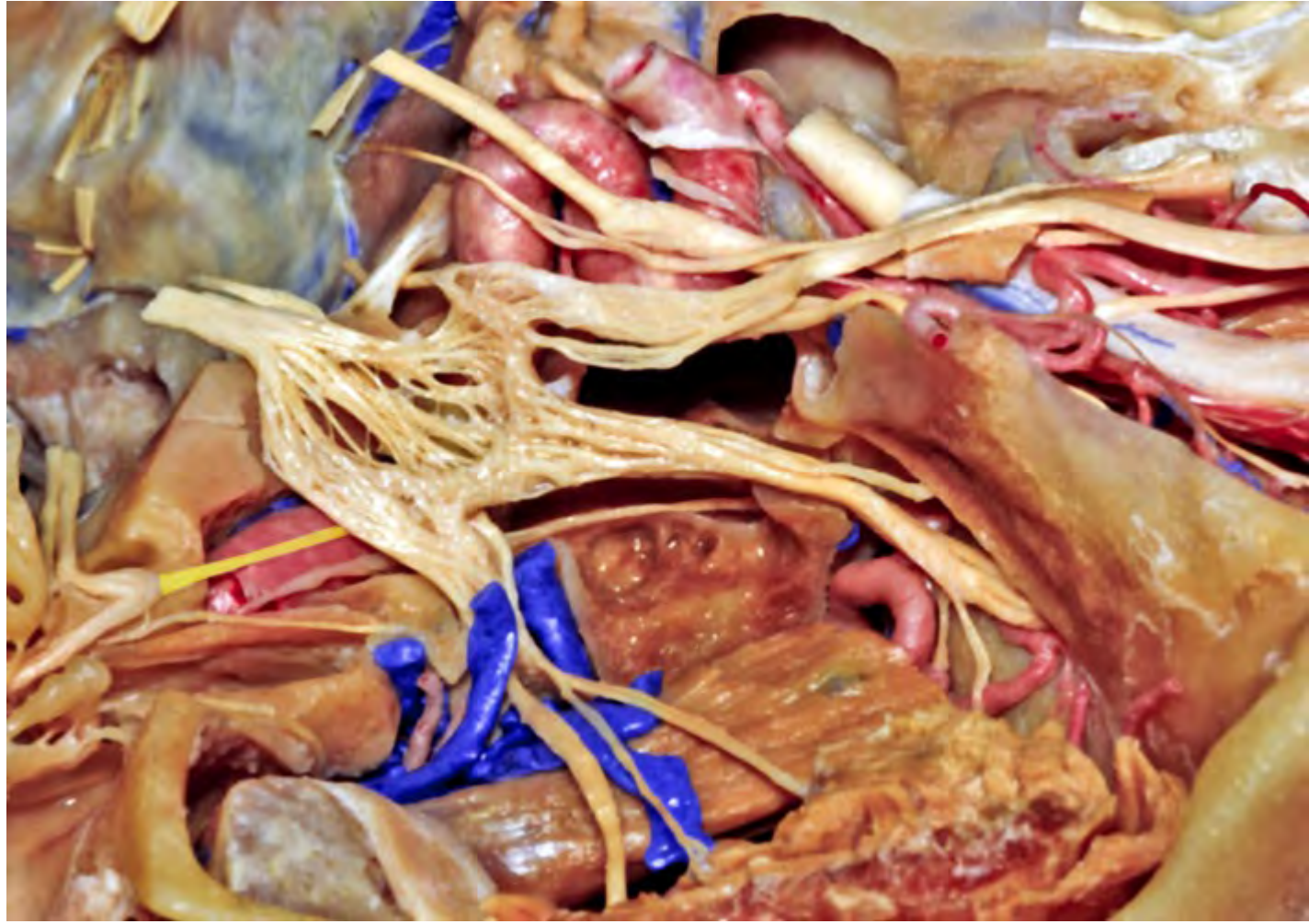


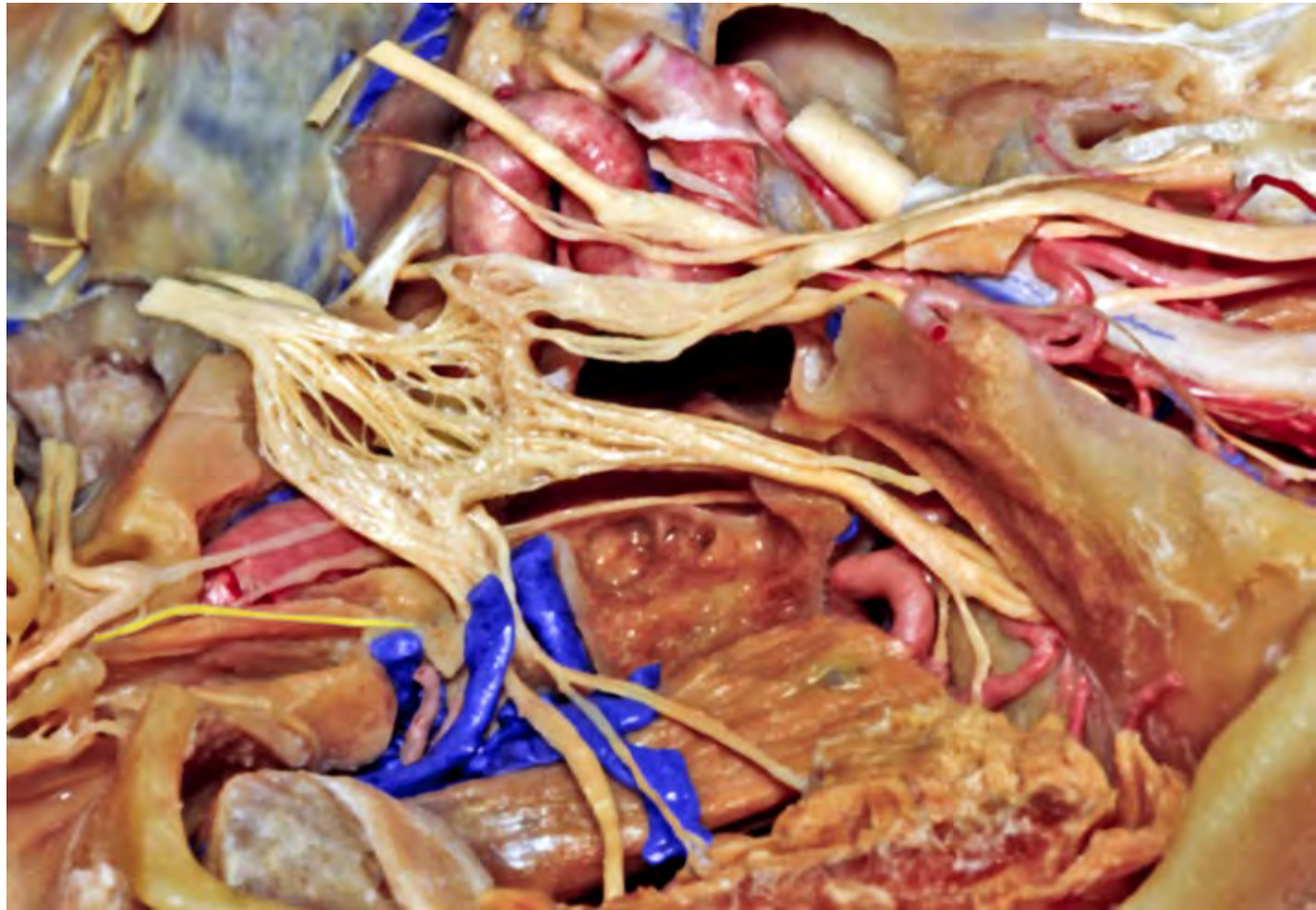




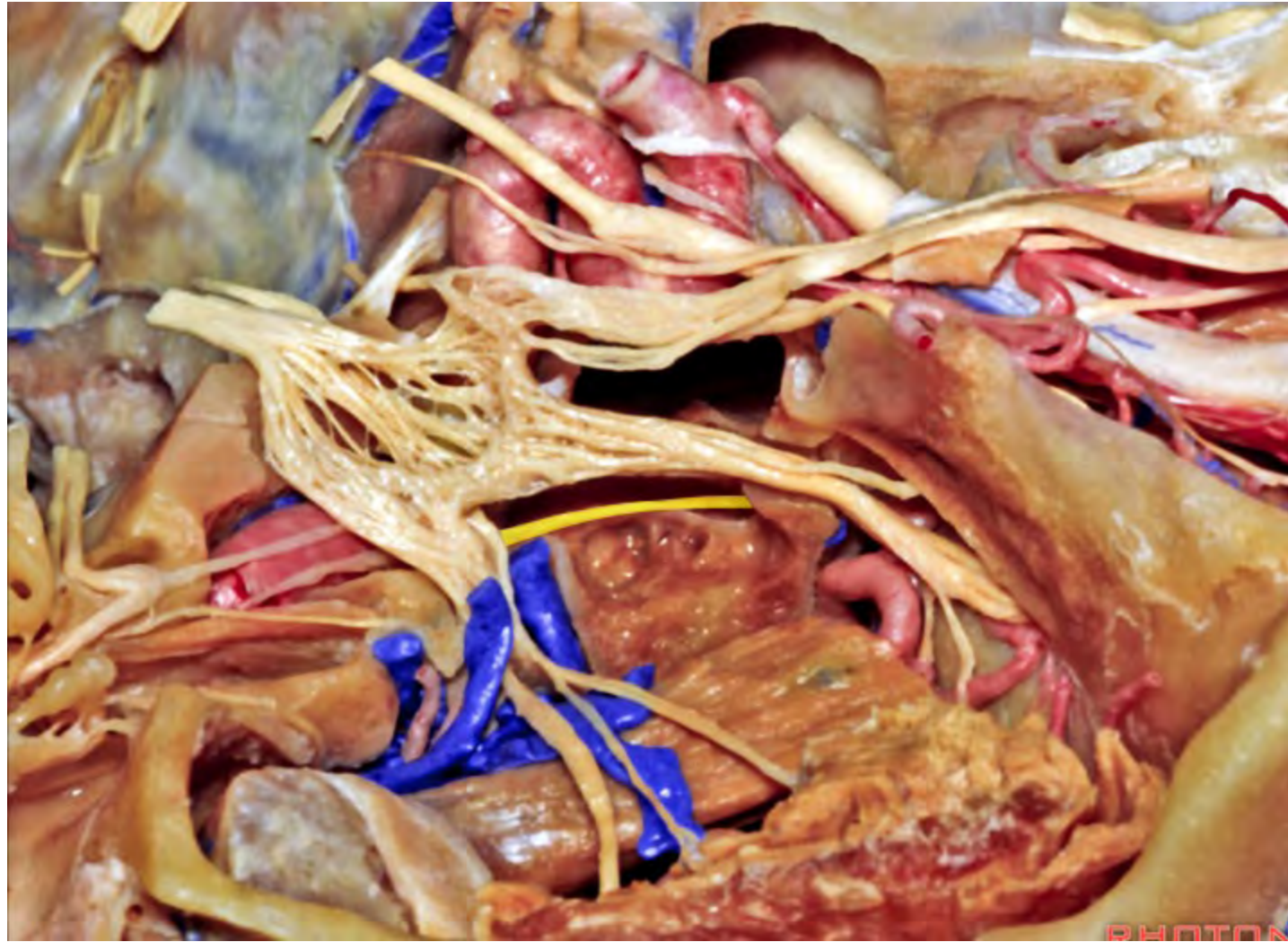


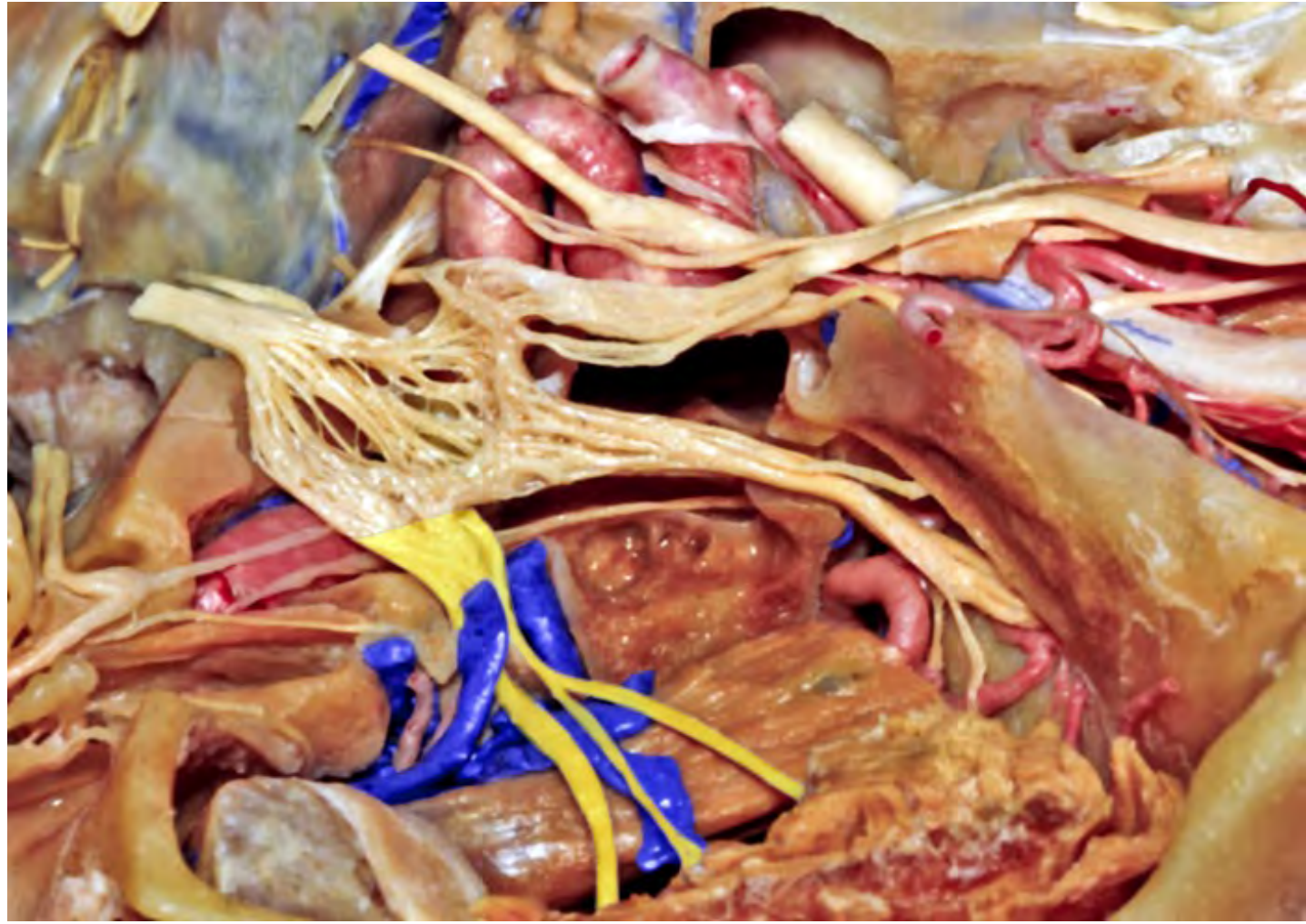




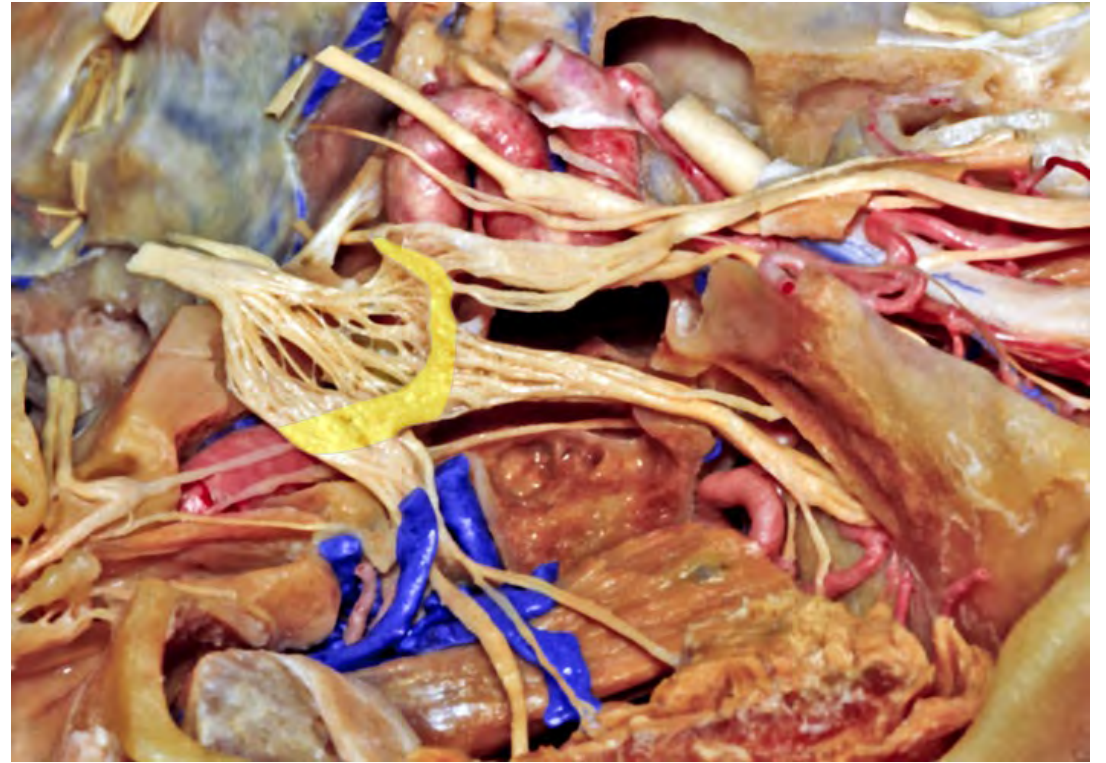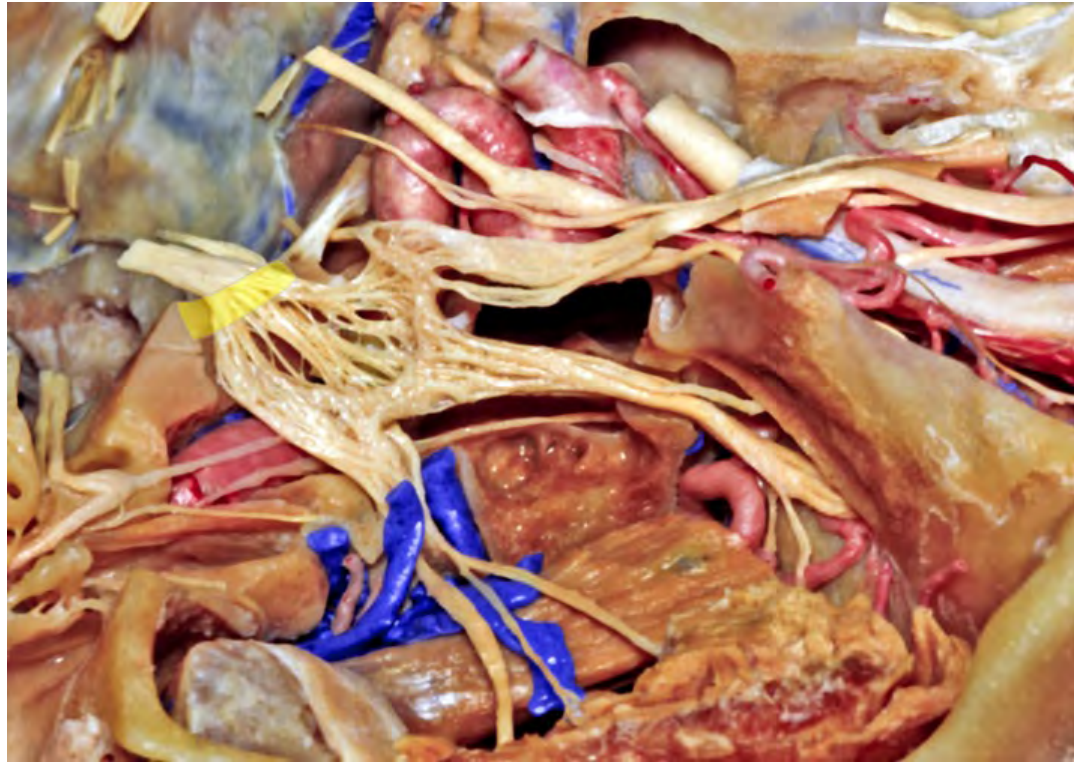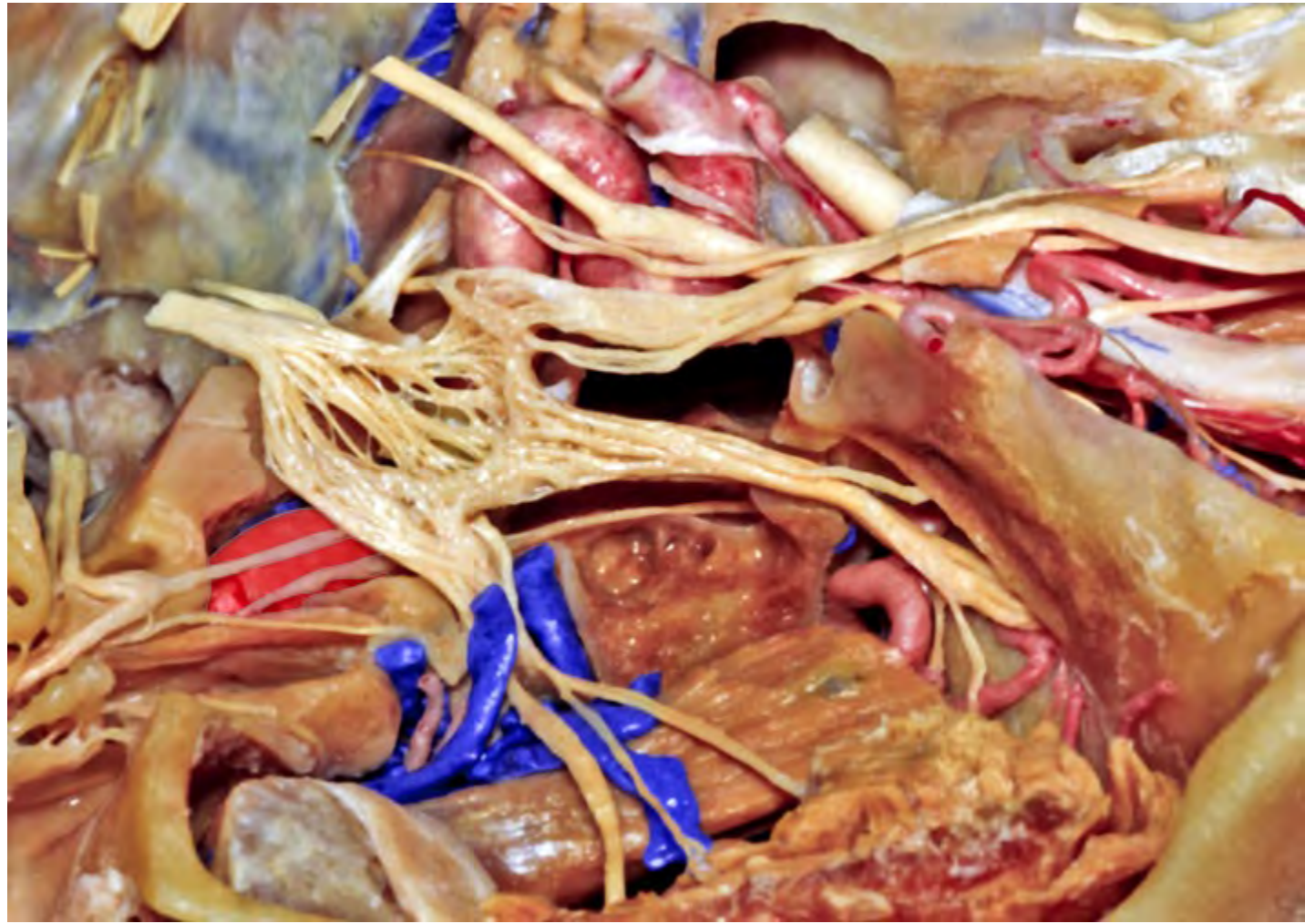


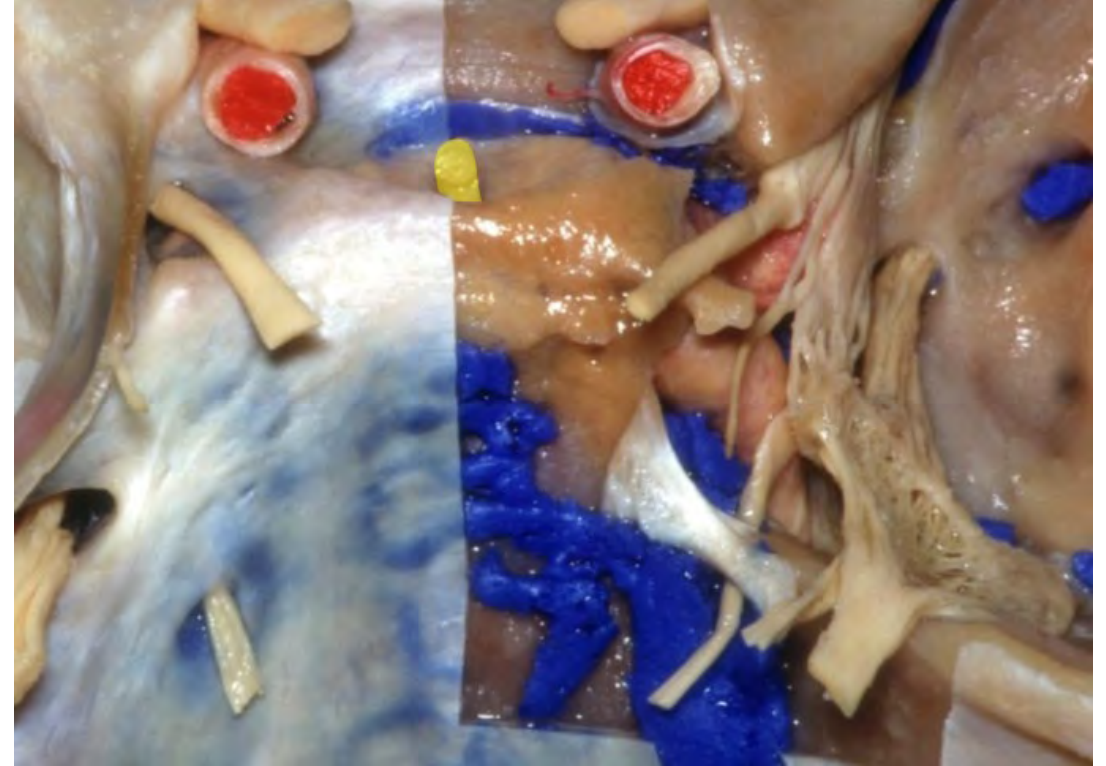
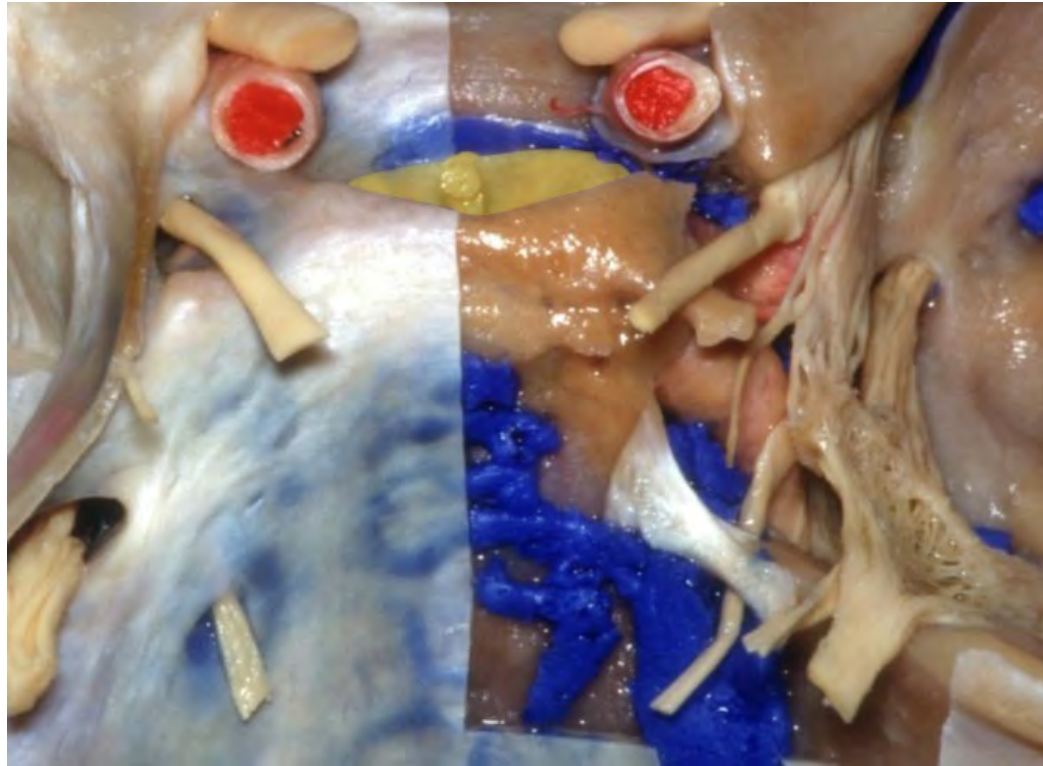






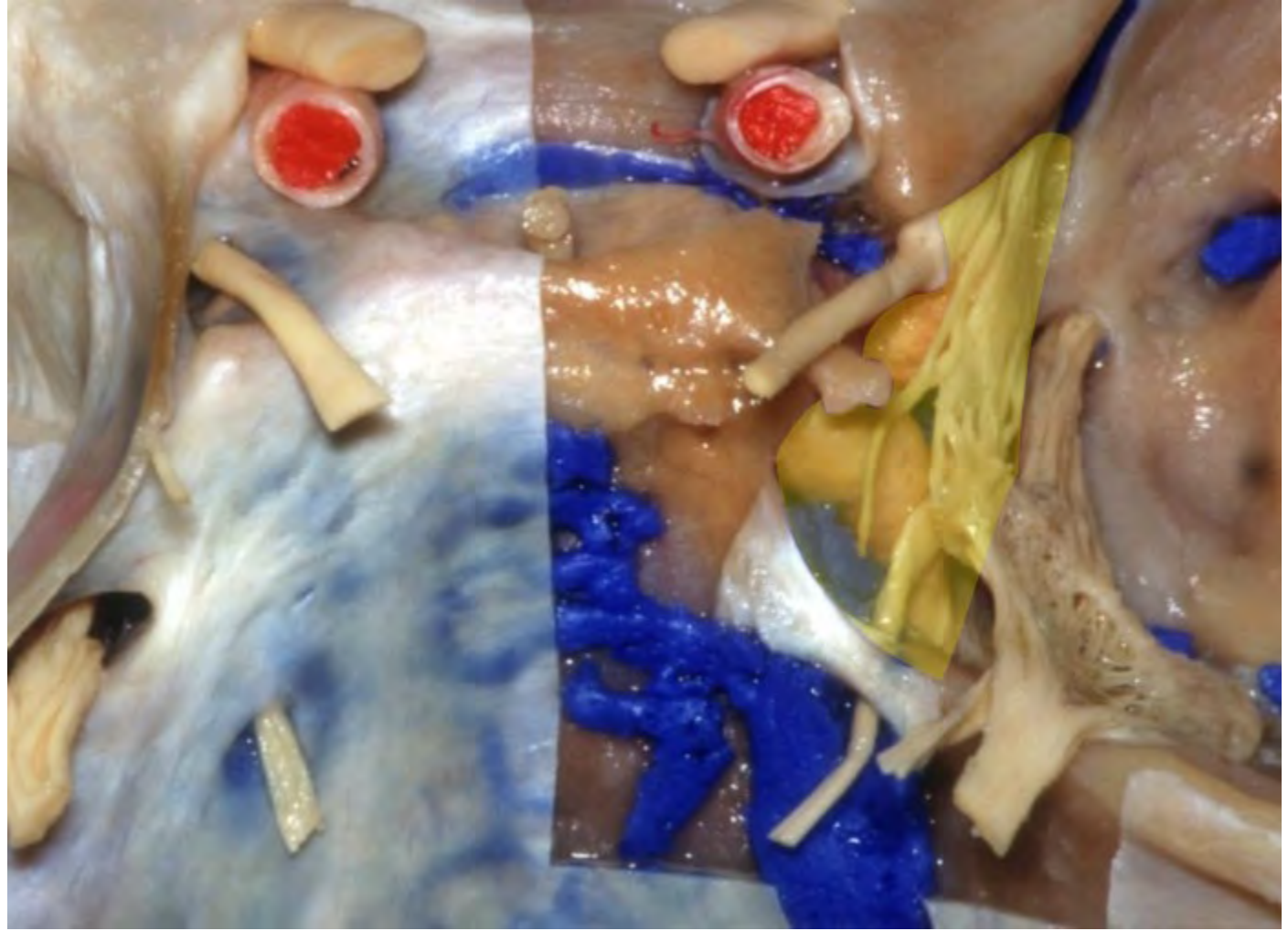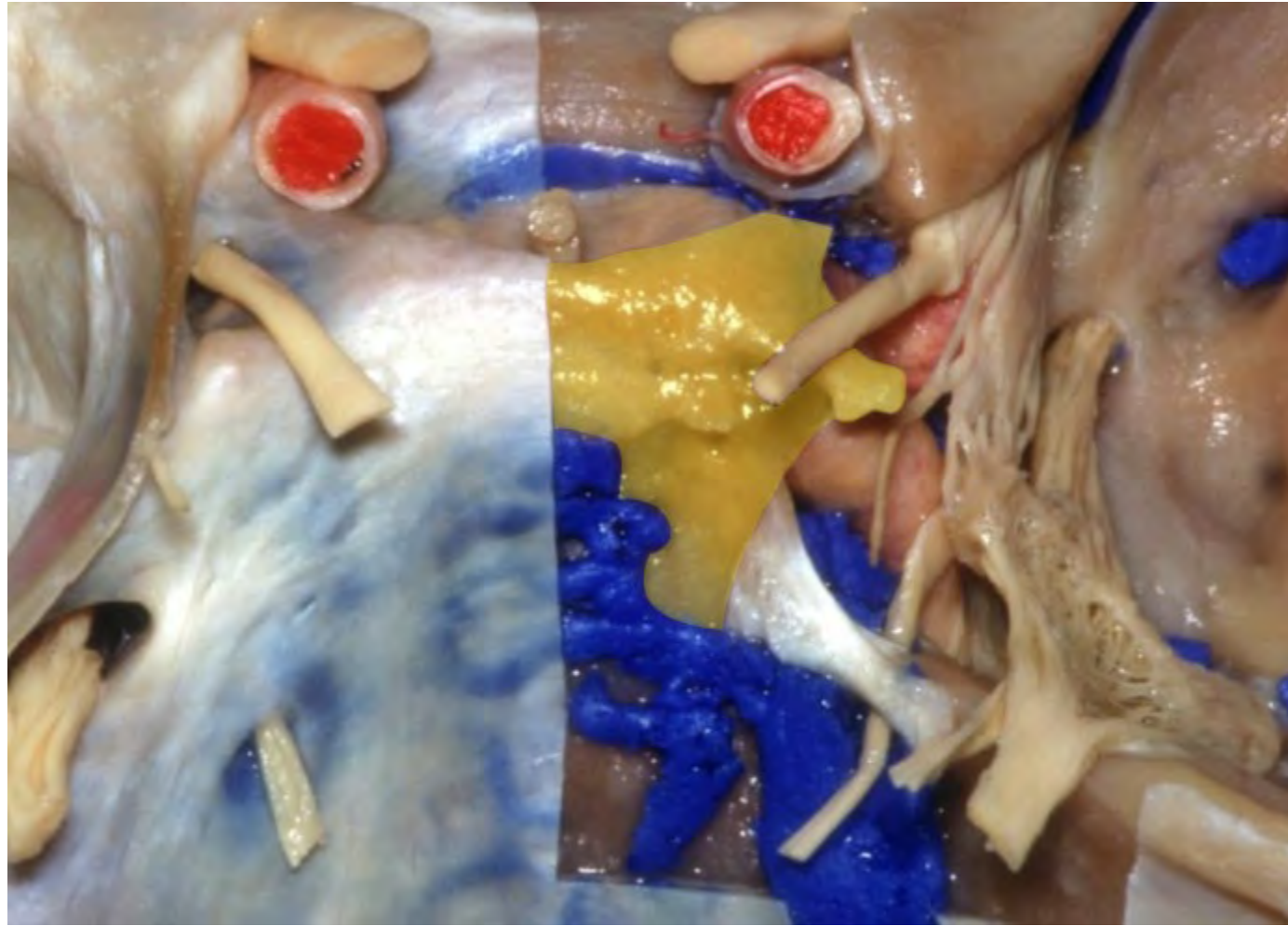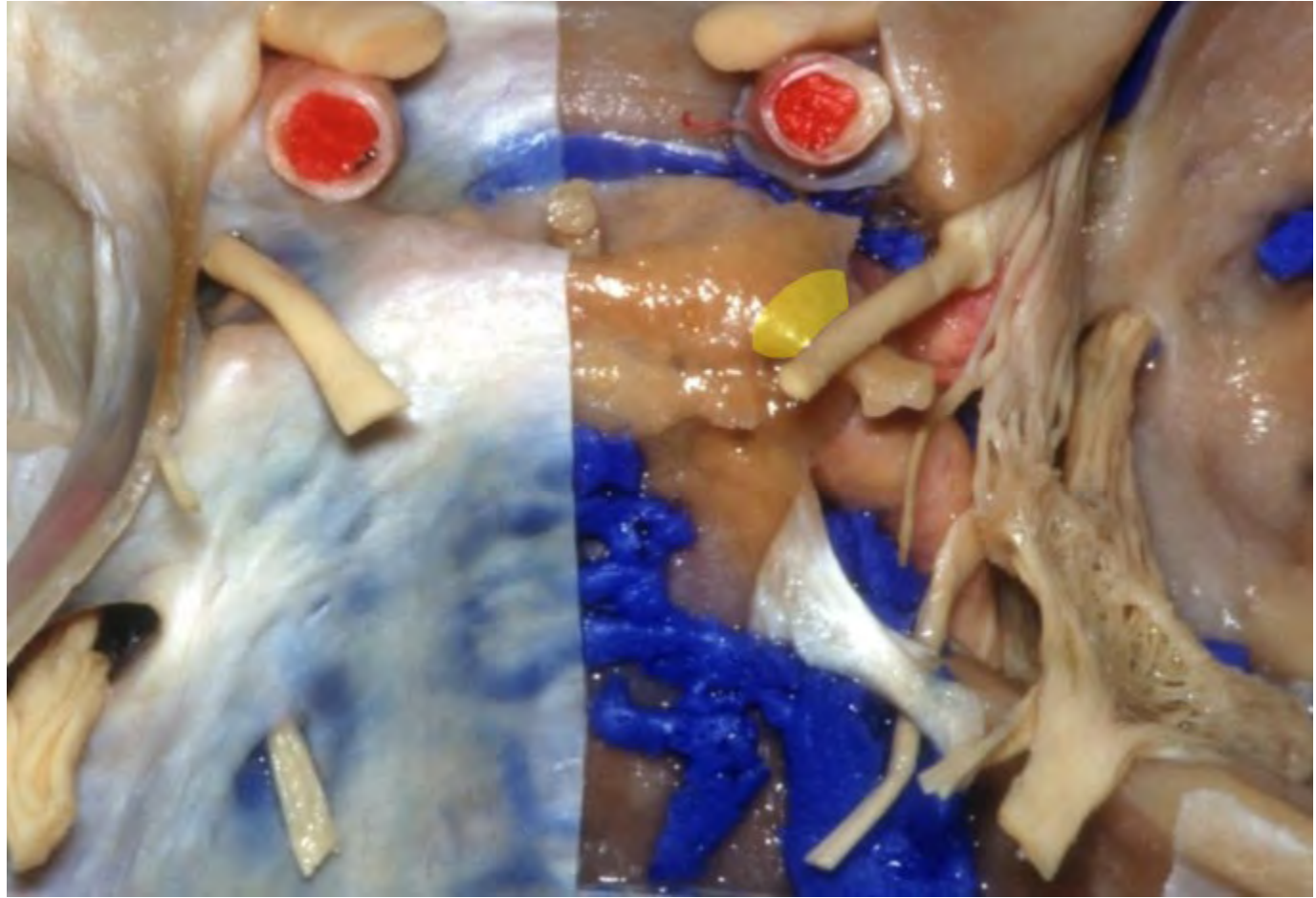










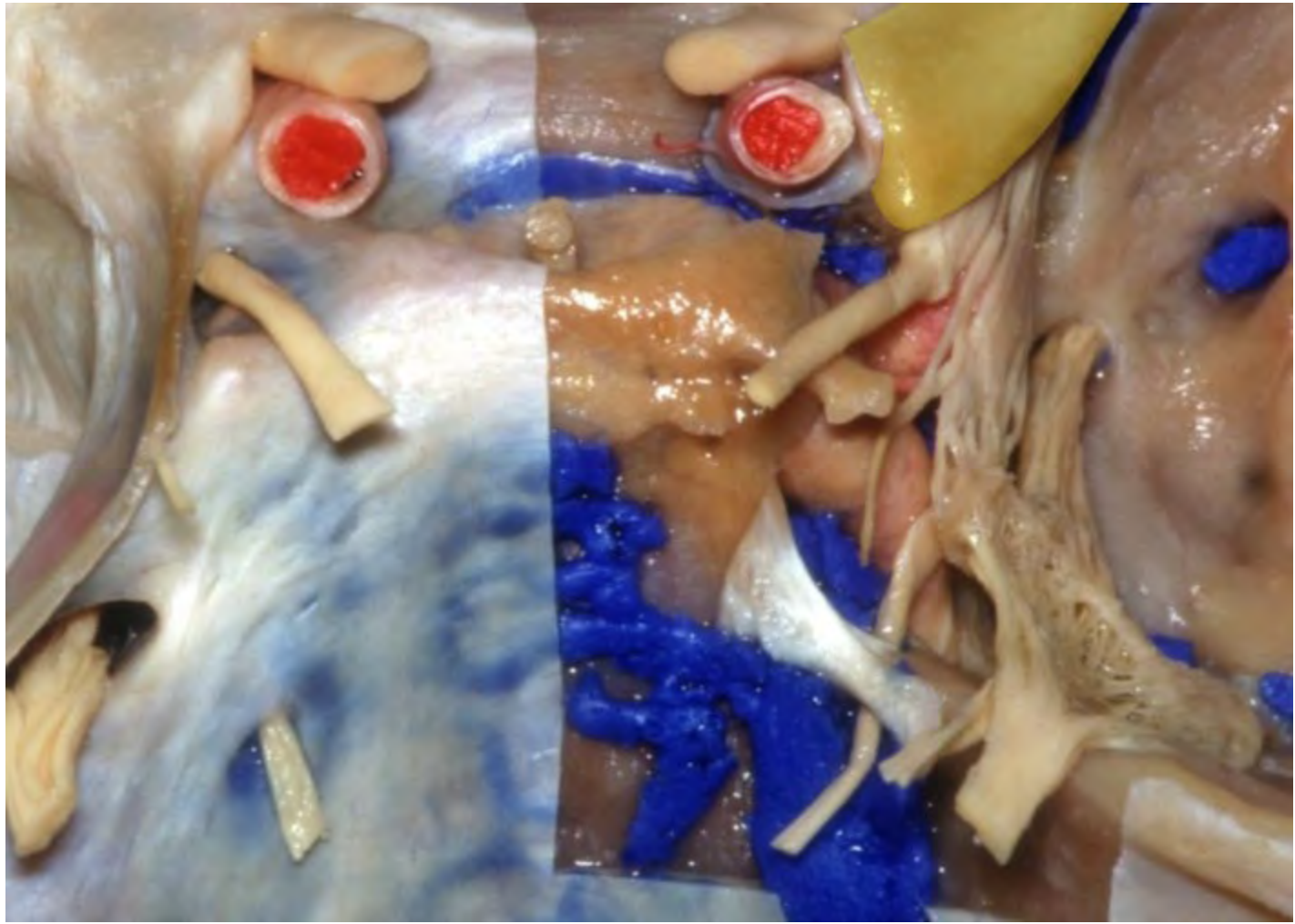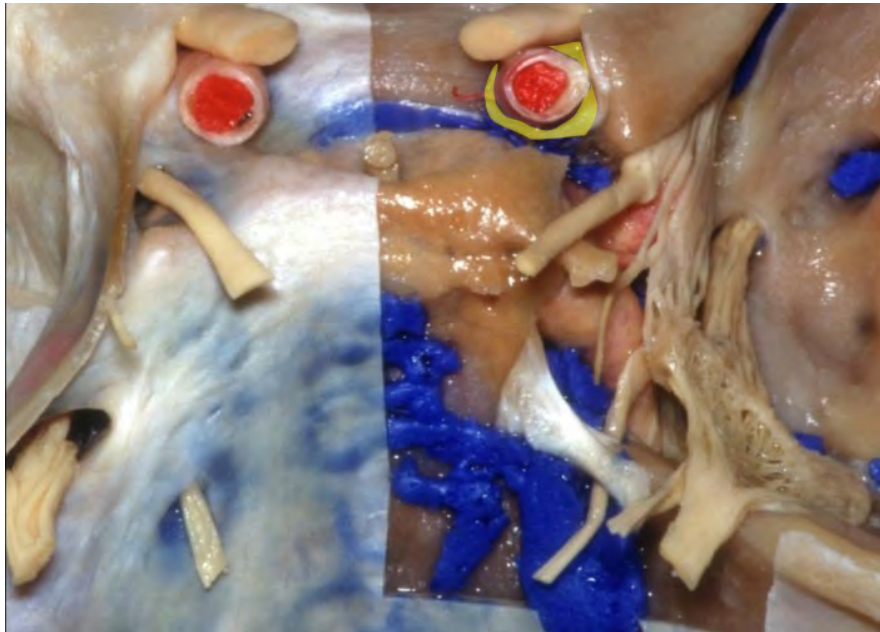




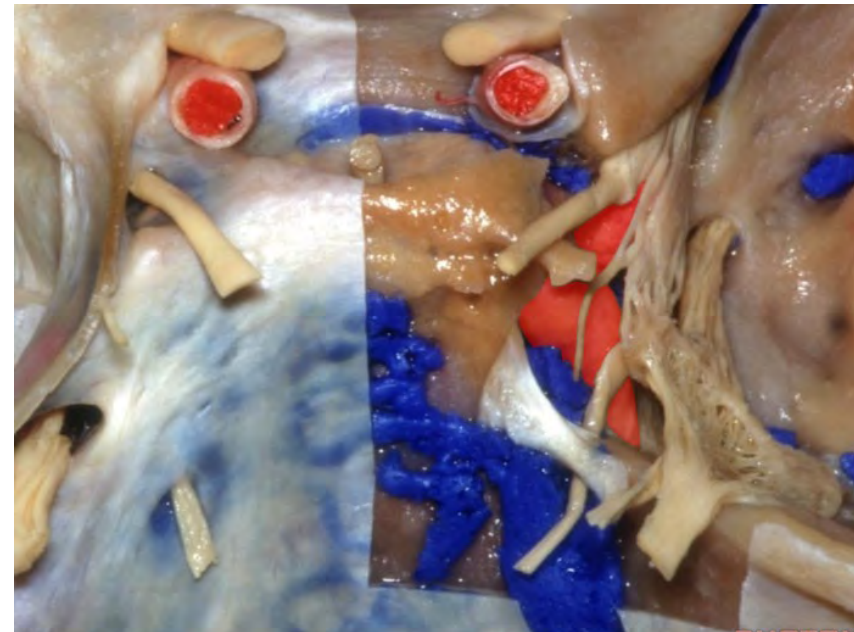




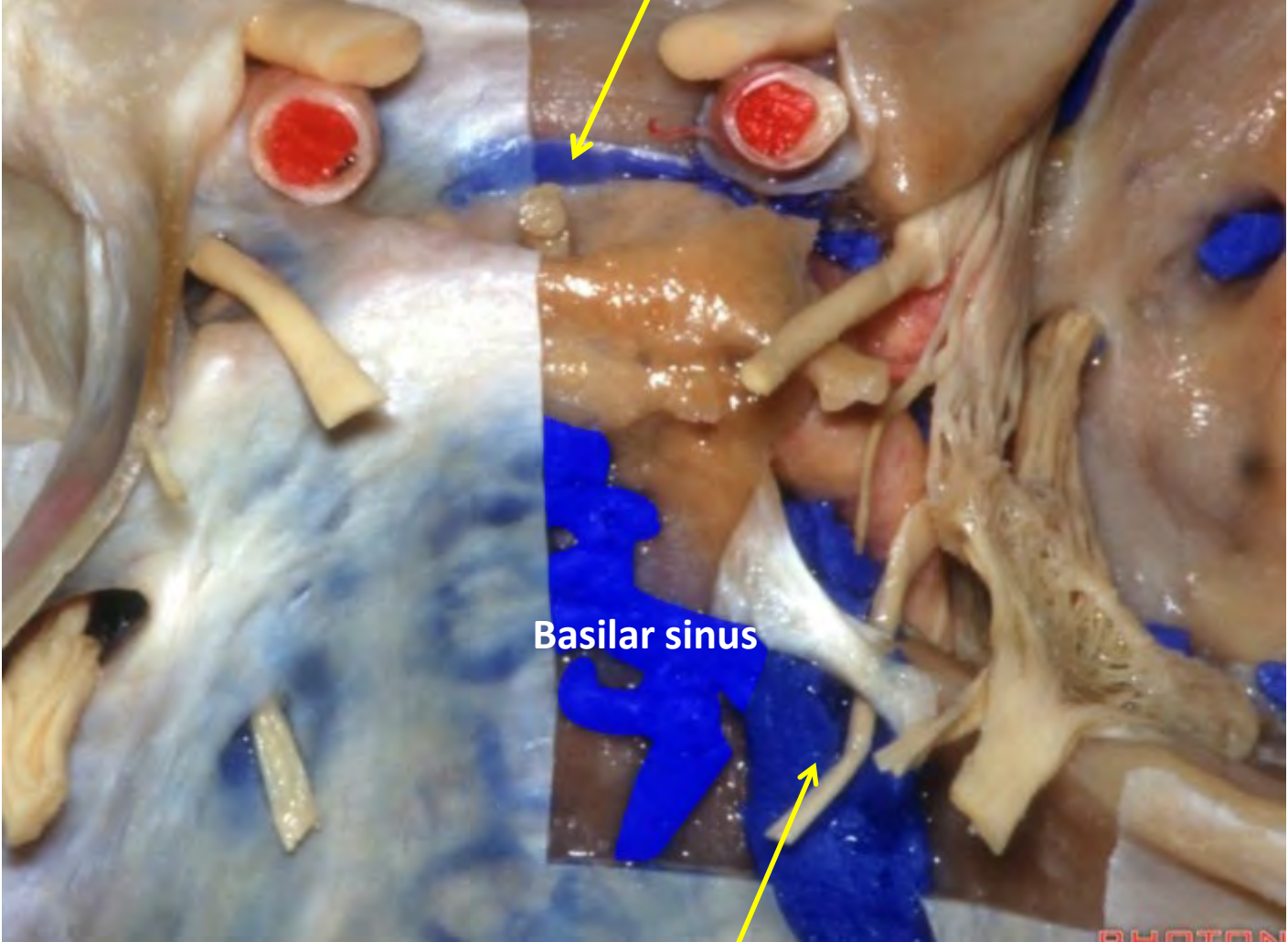
**Carotid collar**  
(around supraclinoid ICA)



**Cavernous segment of ICA**

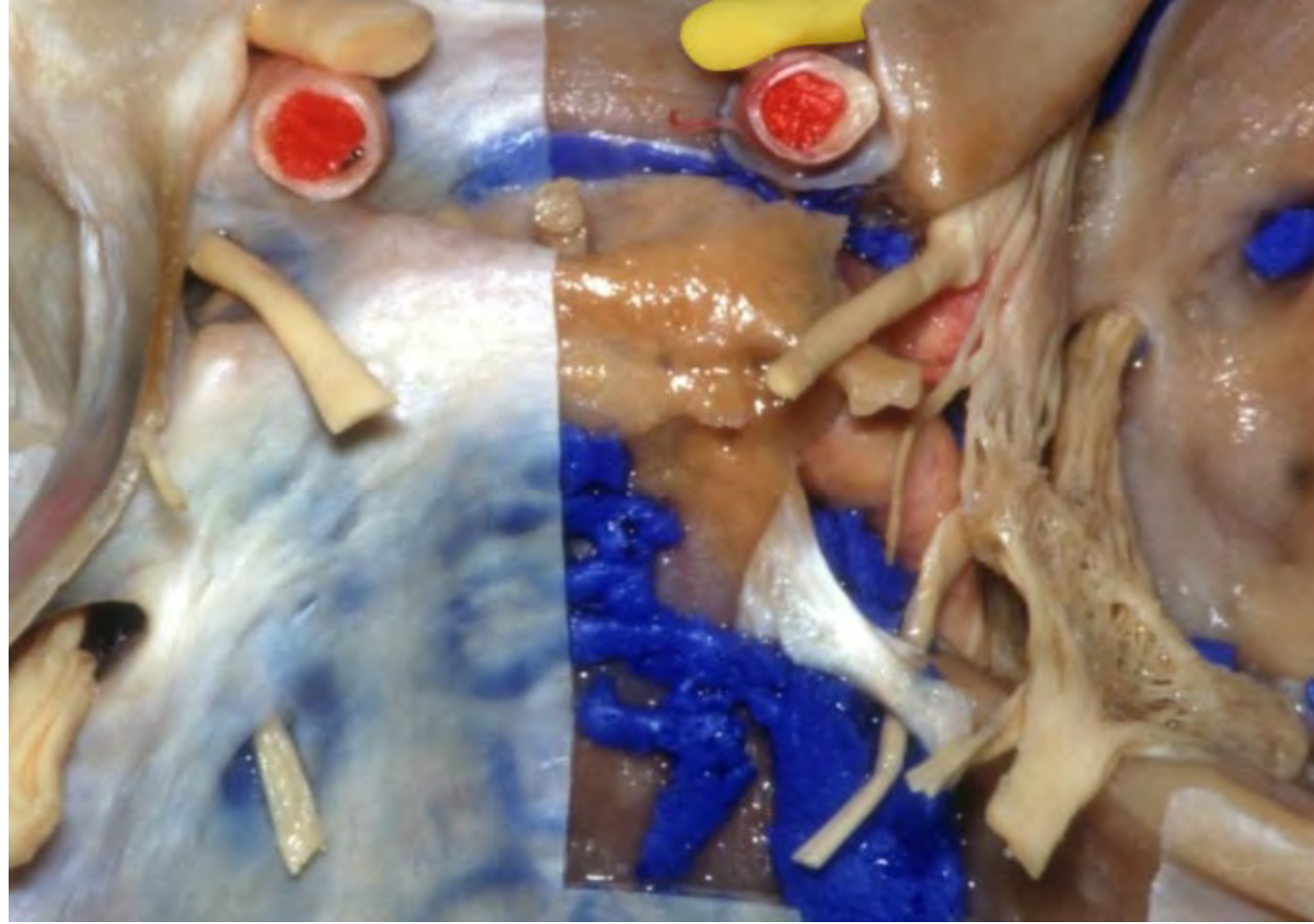

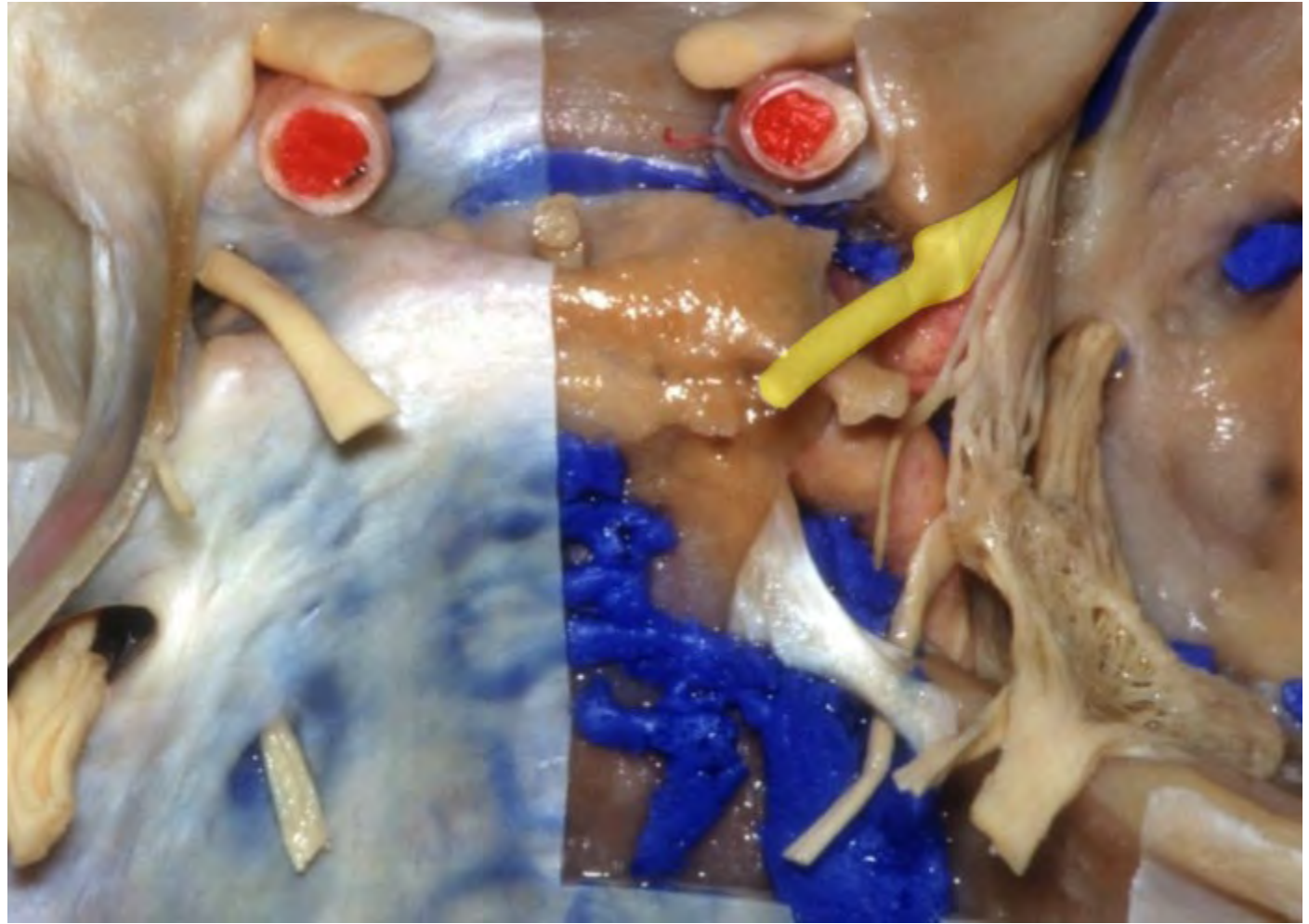
**Anterior intercavernous sinus**

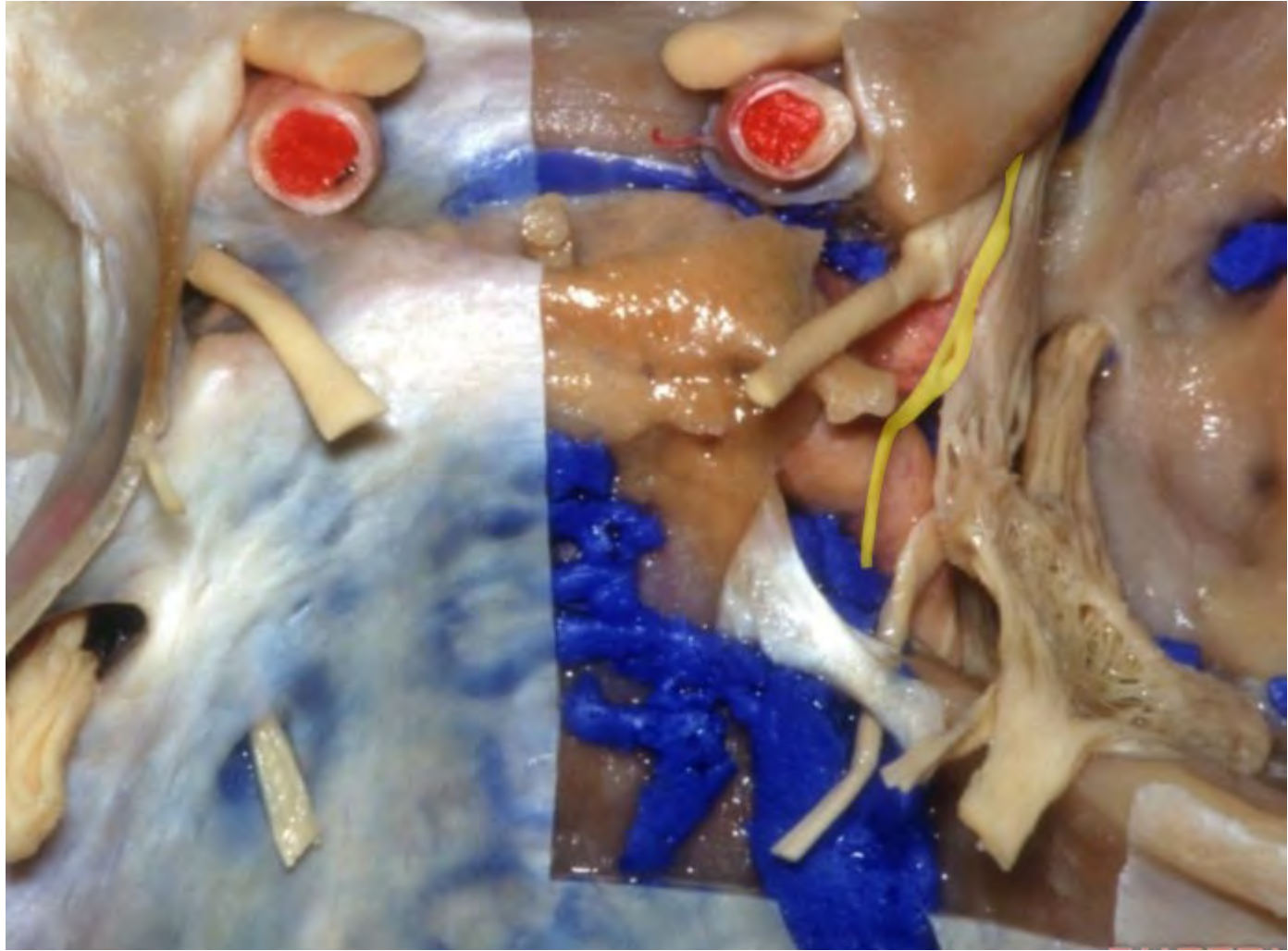

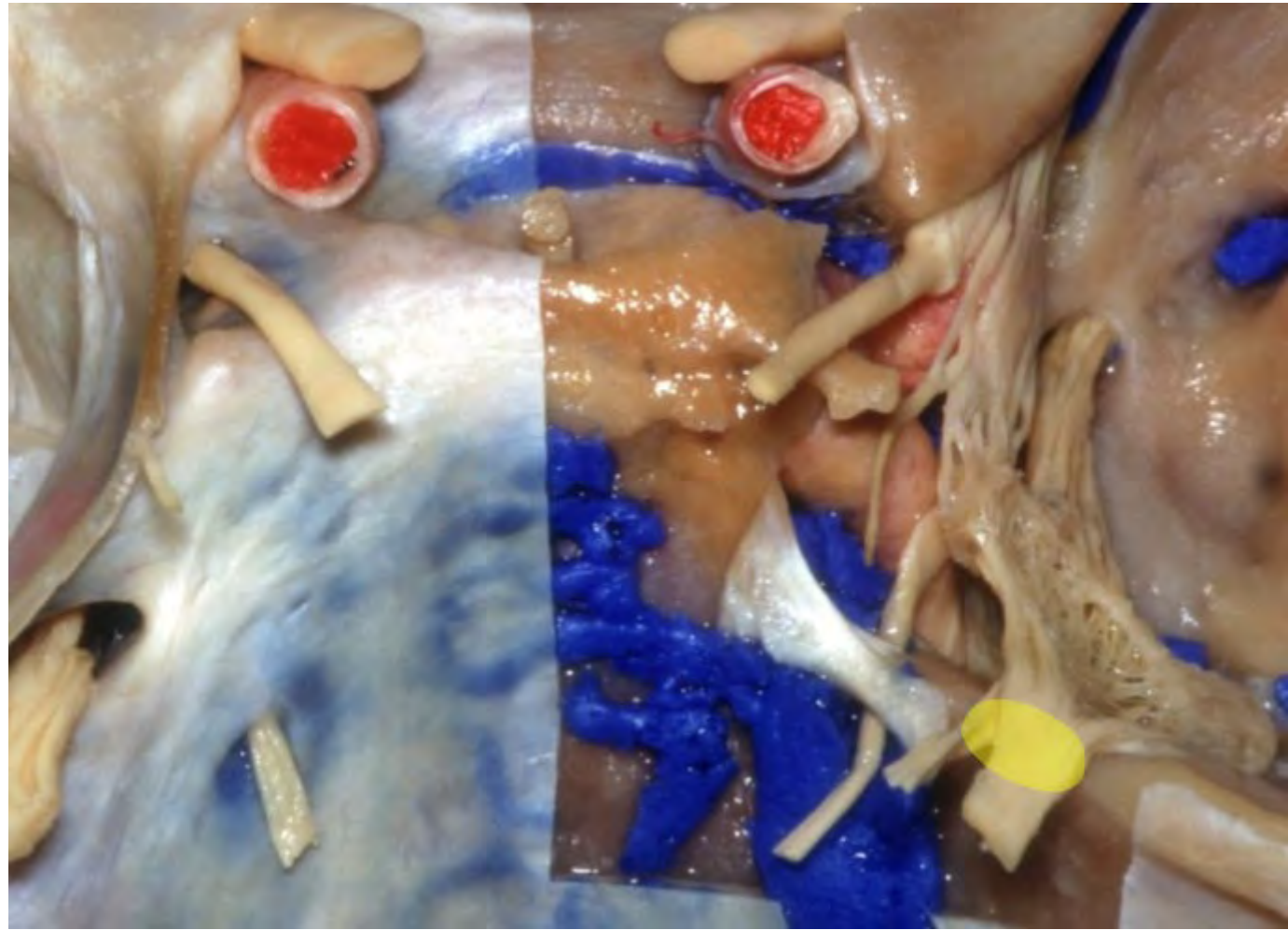**Basilar sinus**

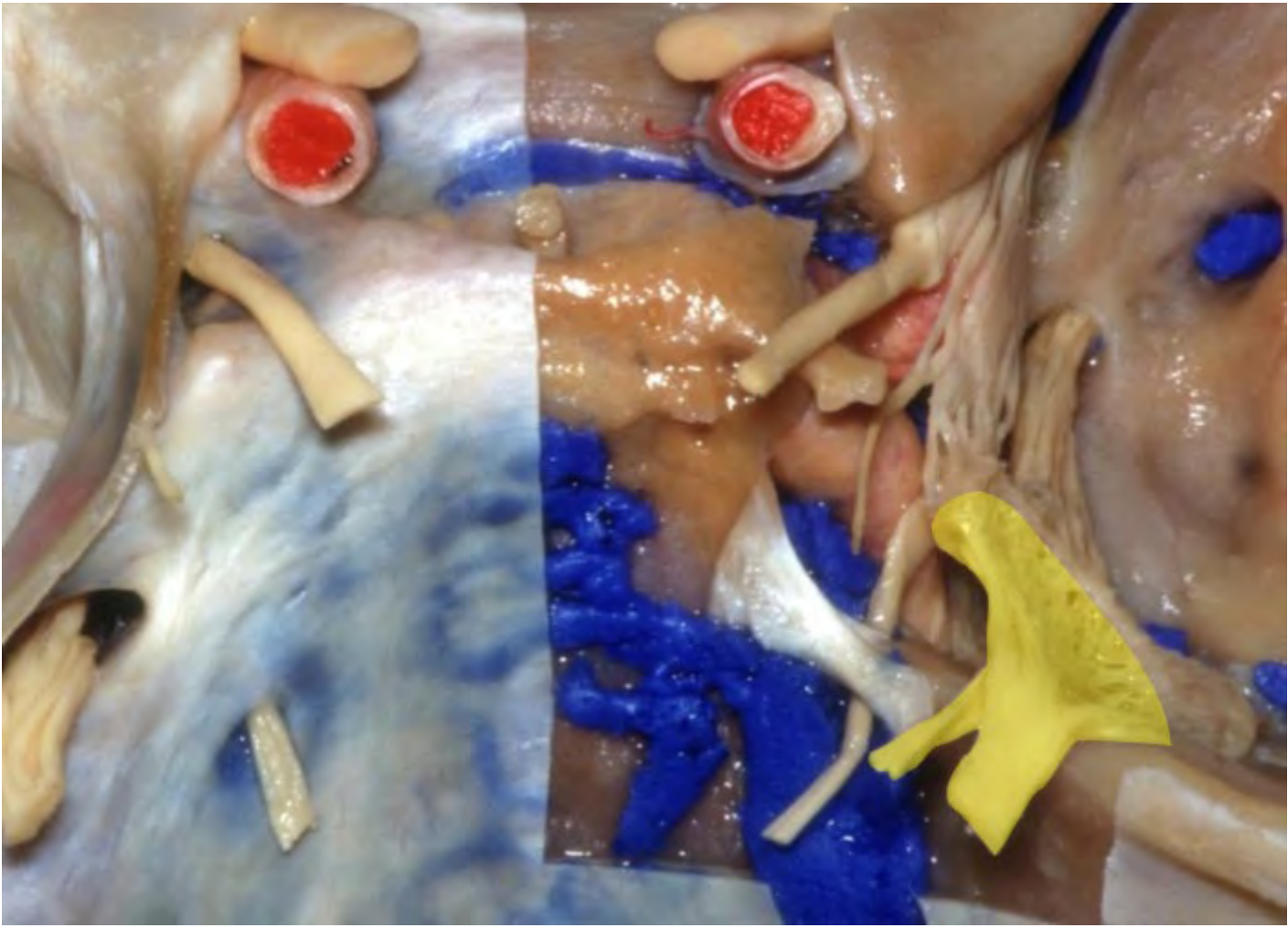**Inferior petrosal sinus**



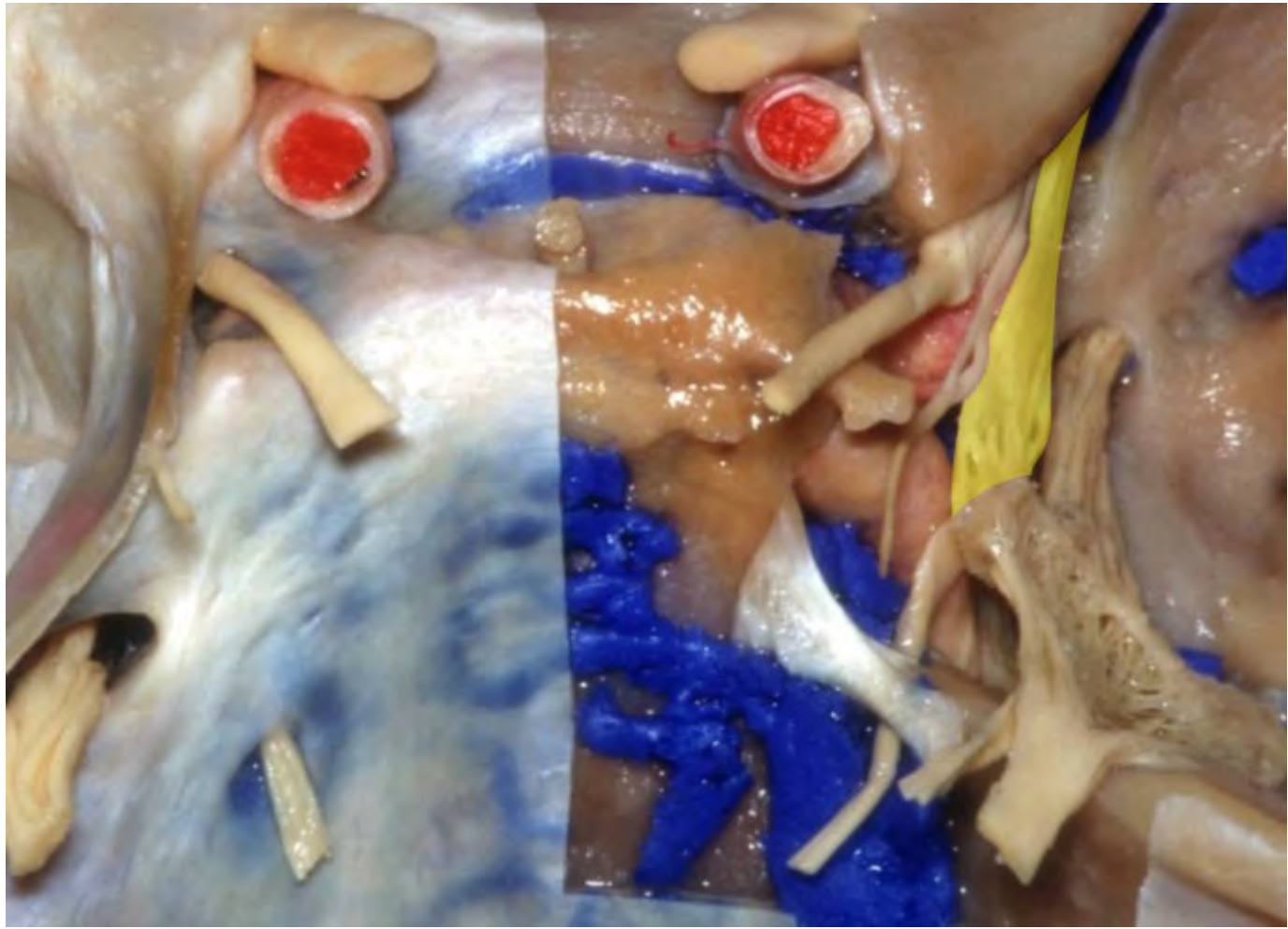


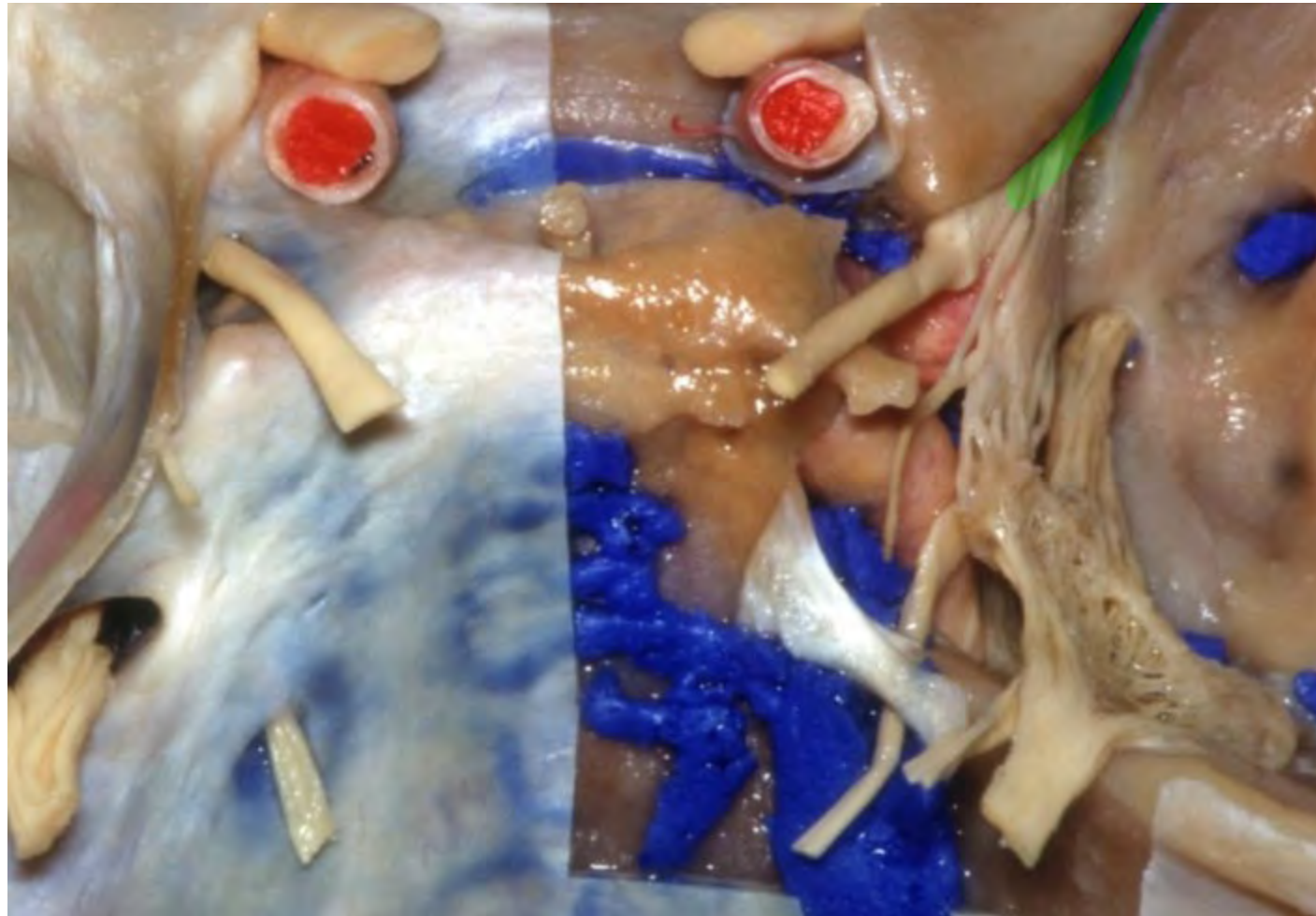

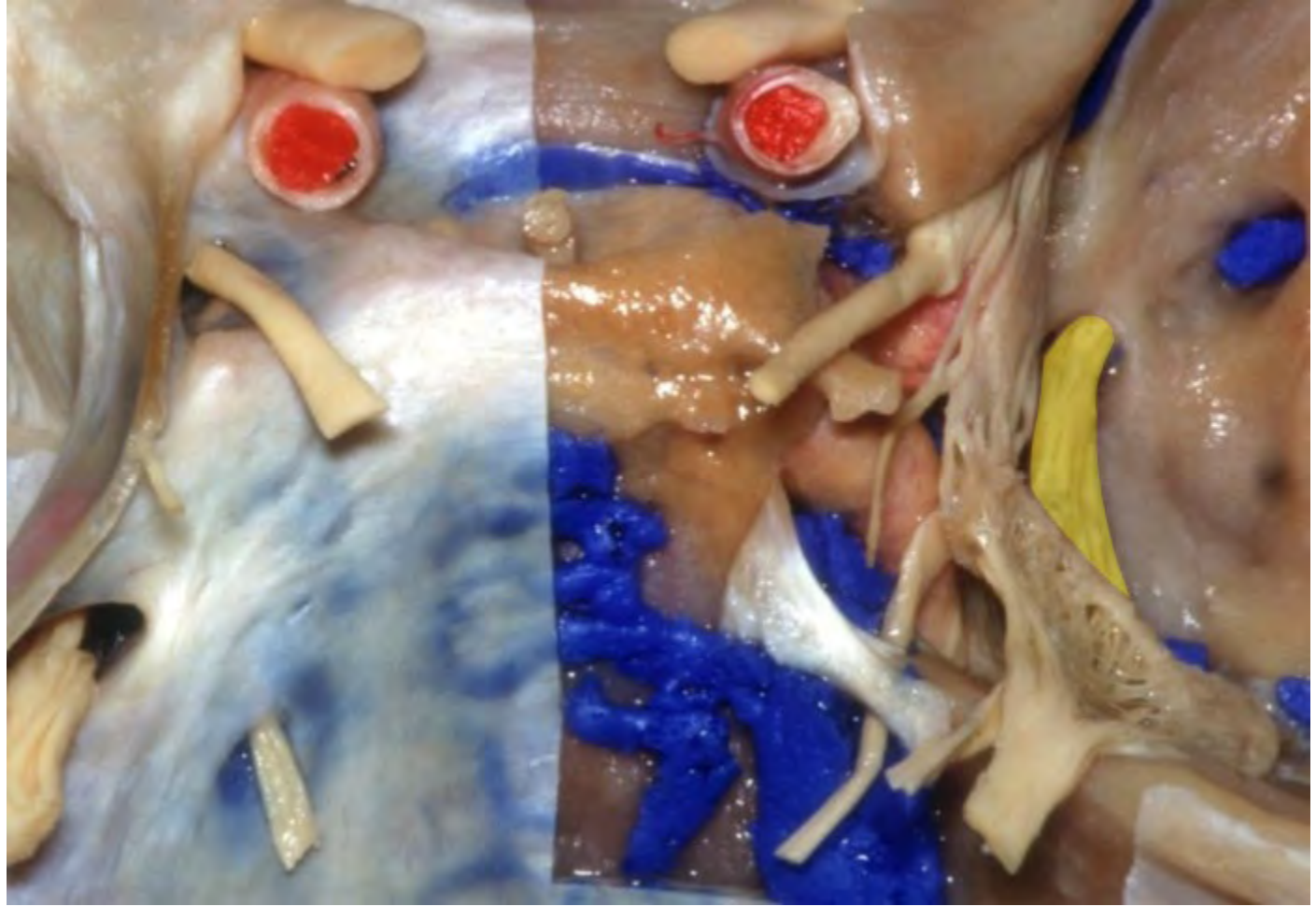


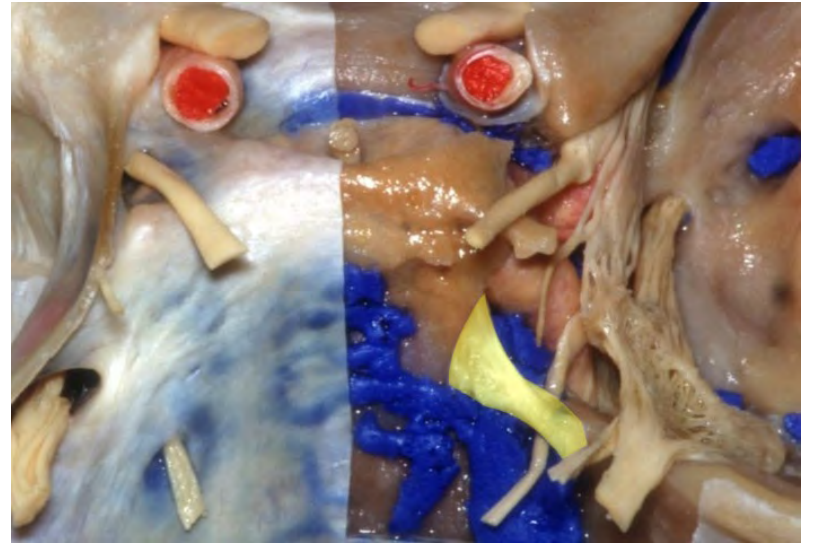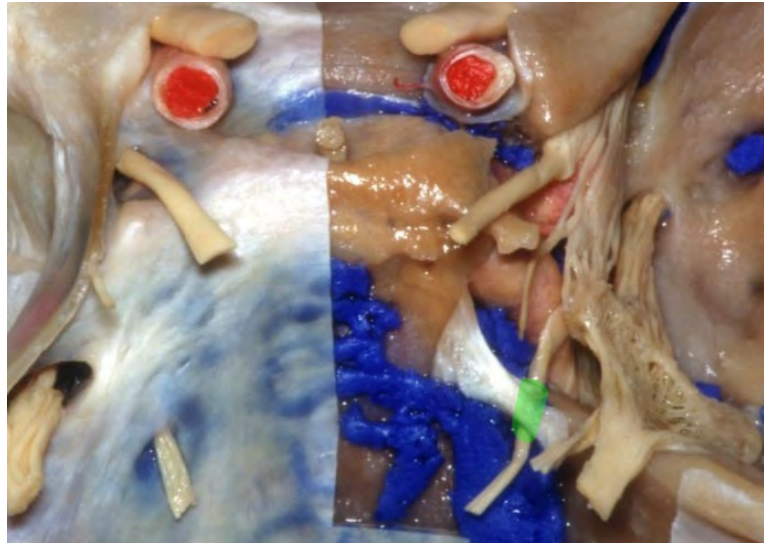
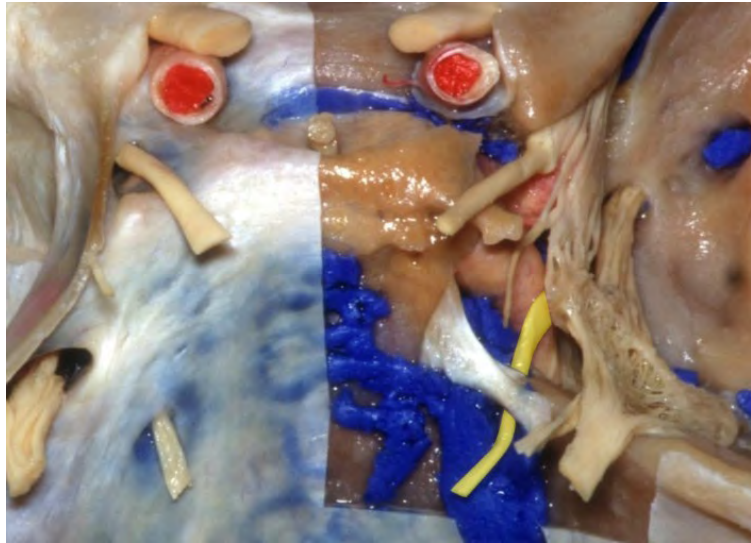


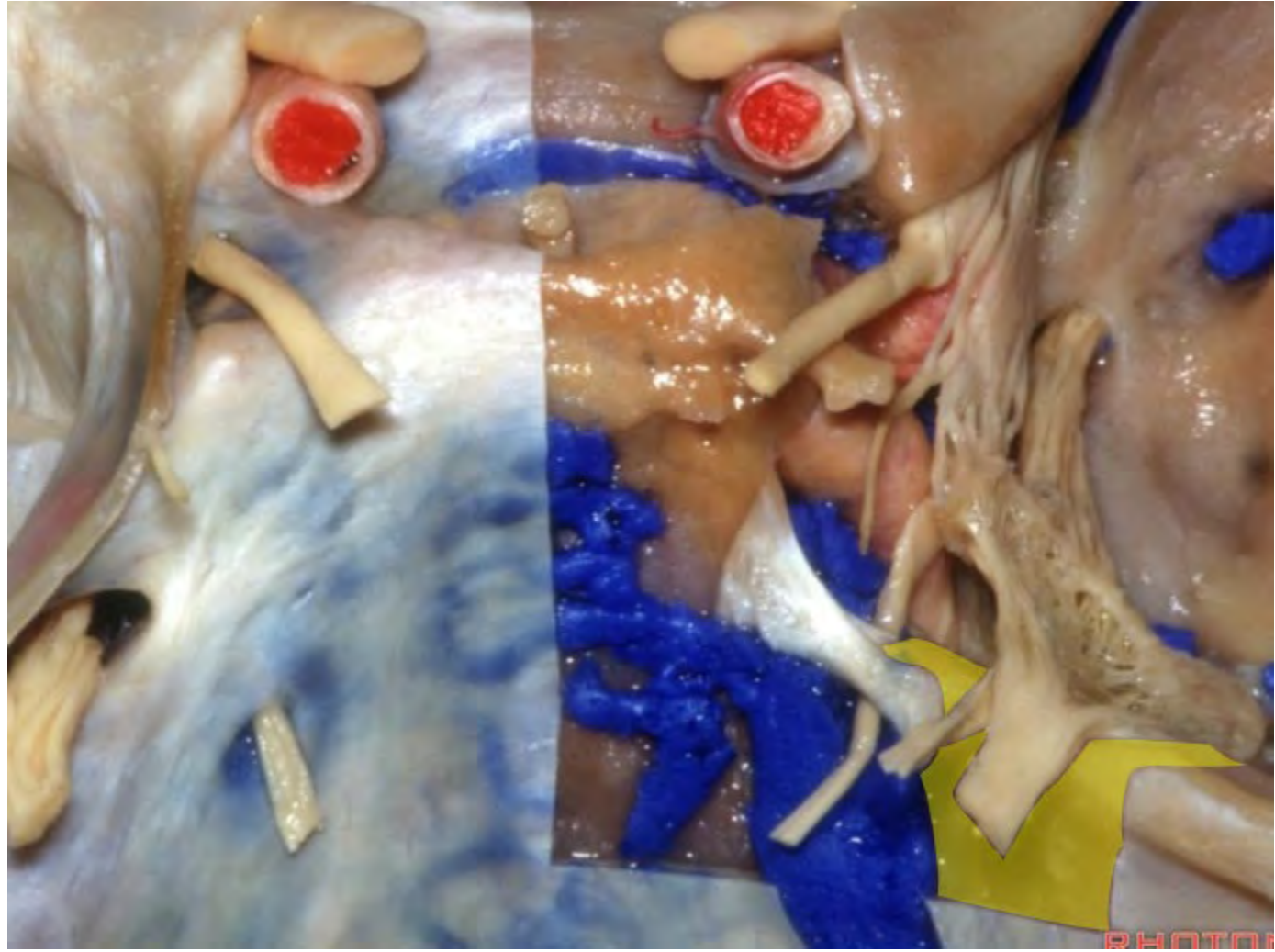


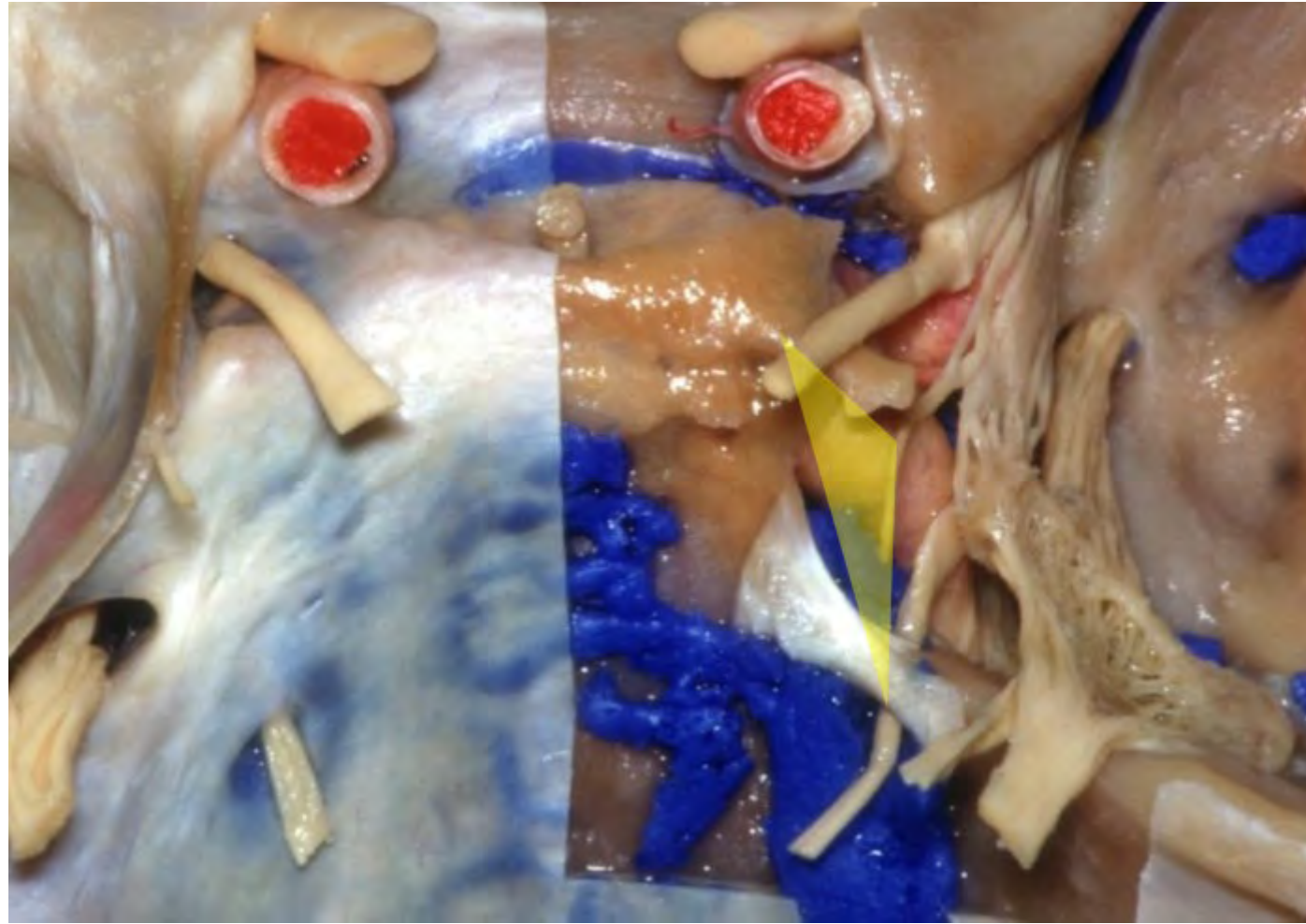




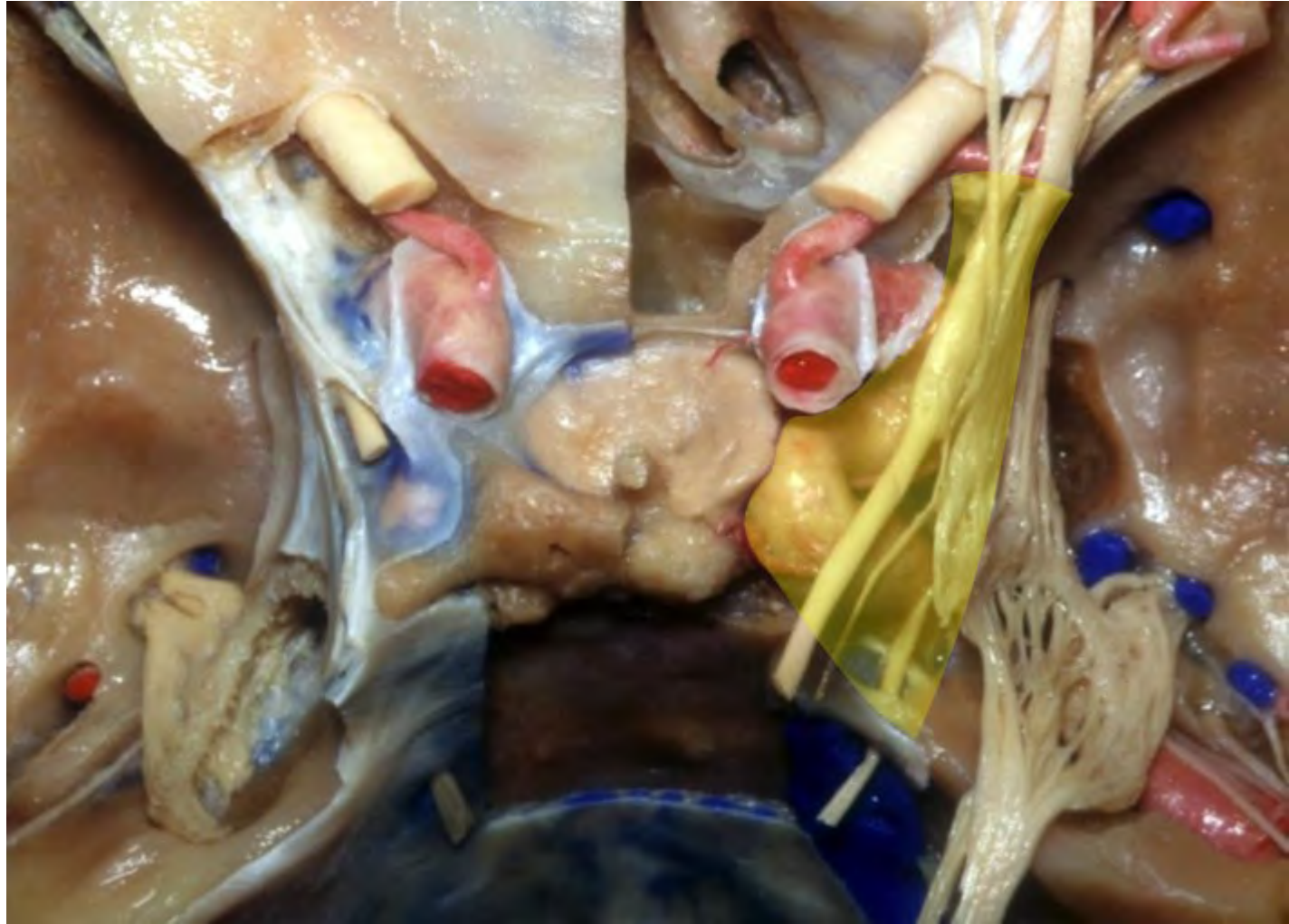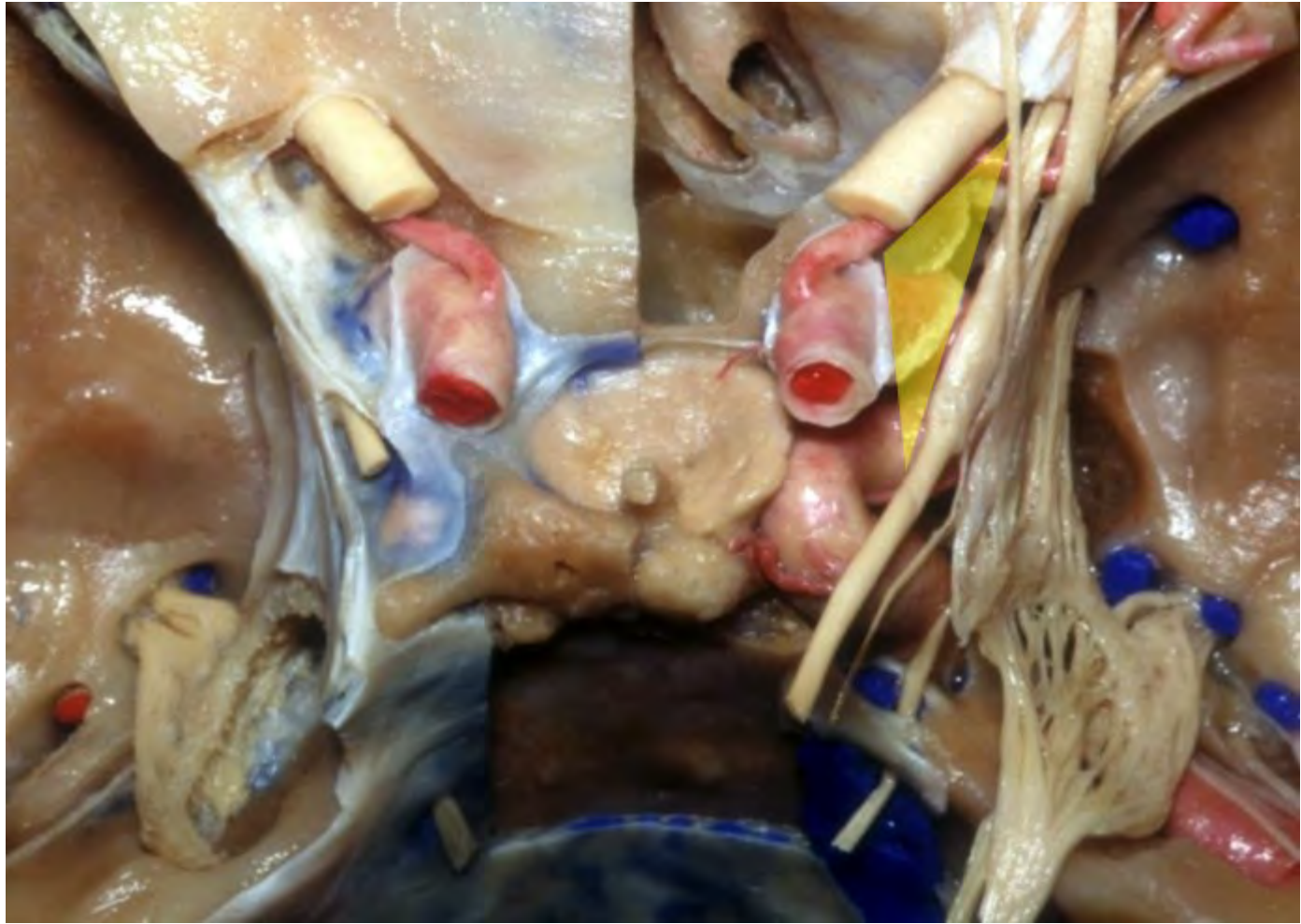




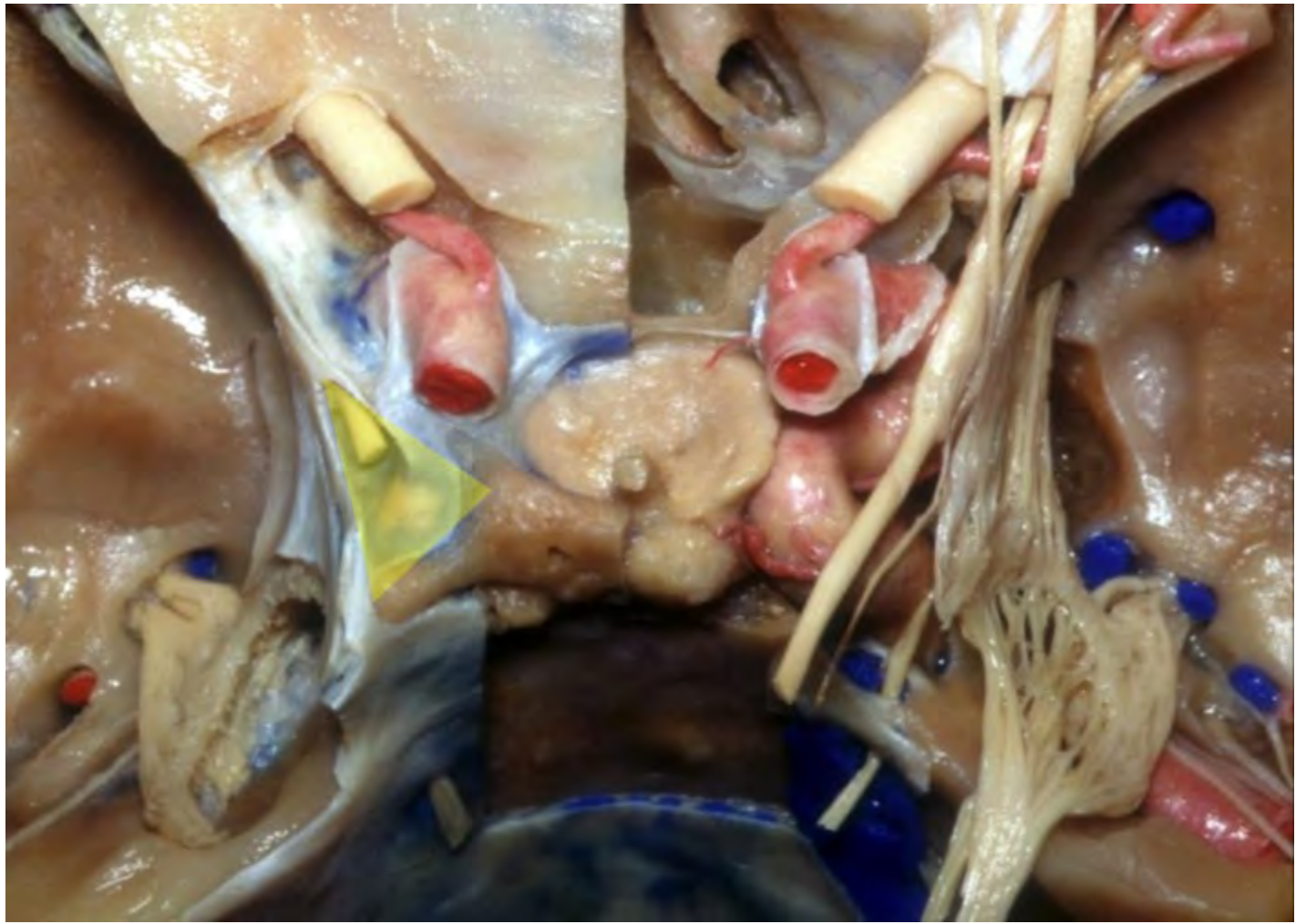




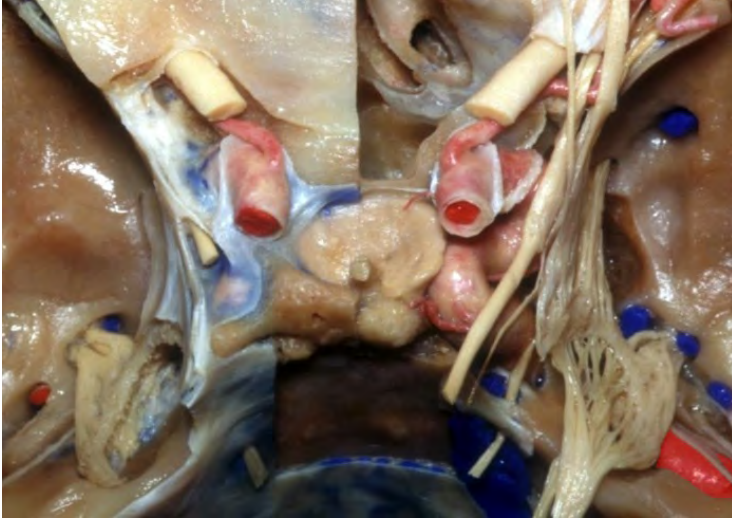




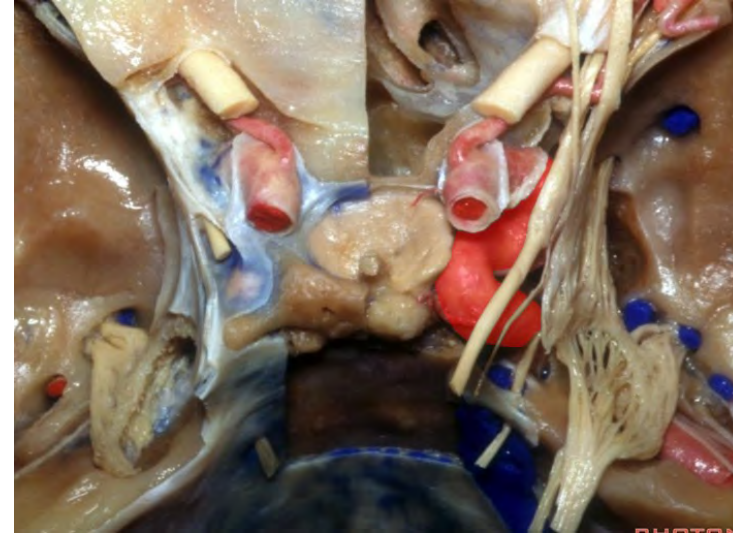




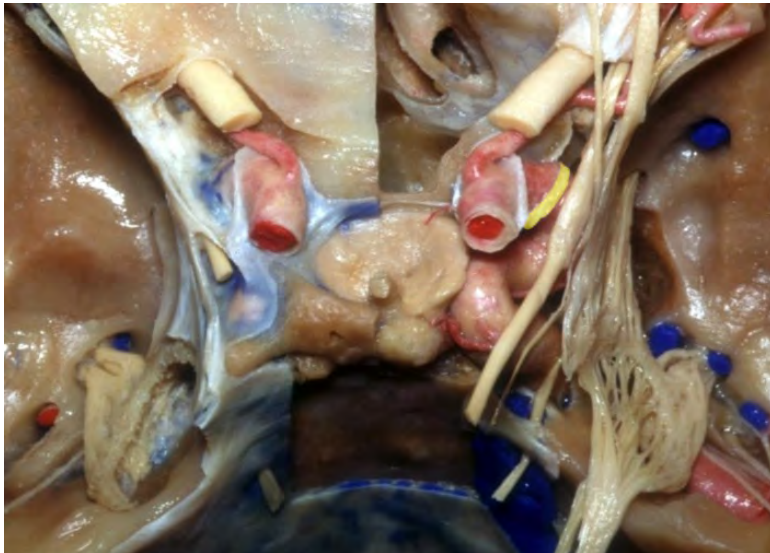**Petrous segment of the ICA**




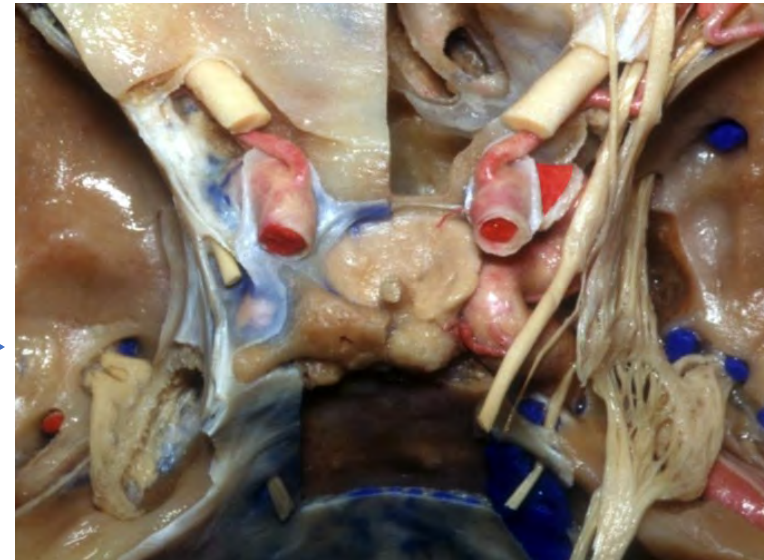
**Cavernous segment of the ICA**



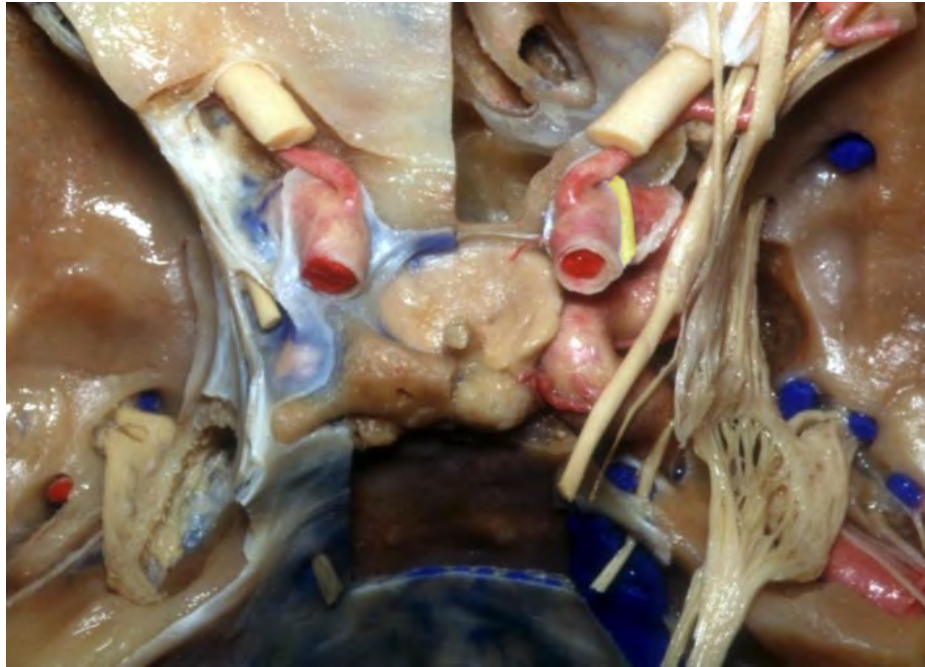**Proximal dural ring**



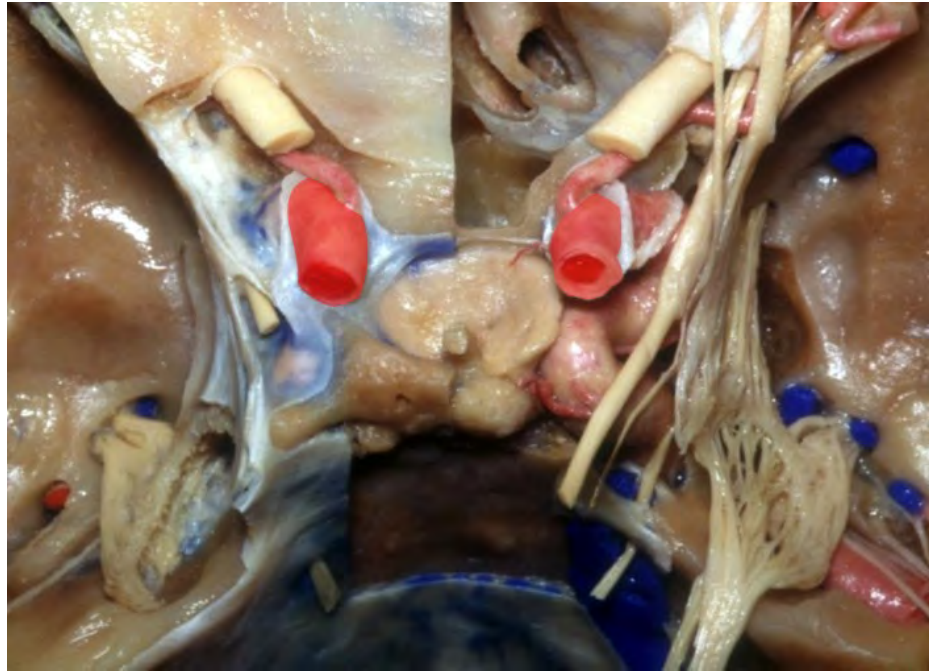
**Clinoidal segment of the ICA**

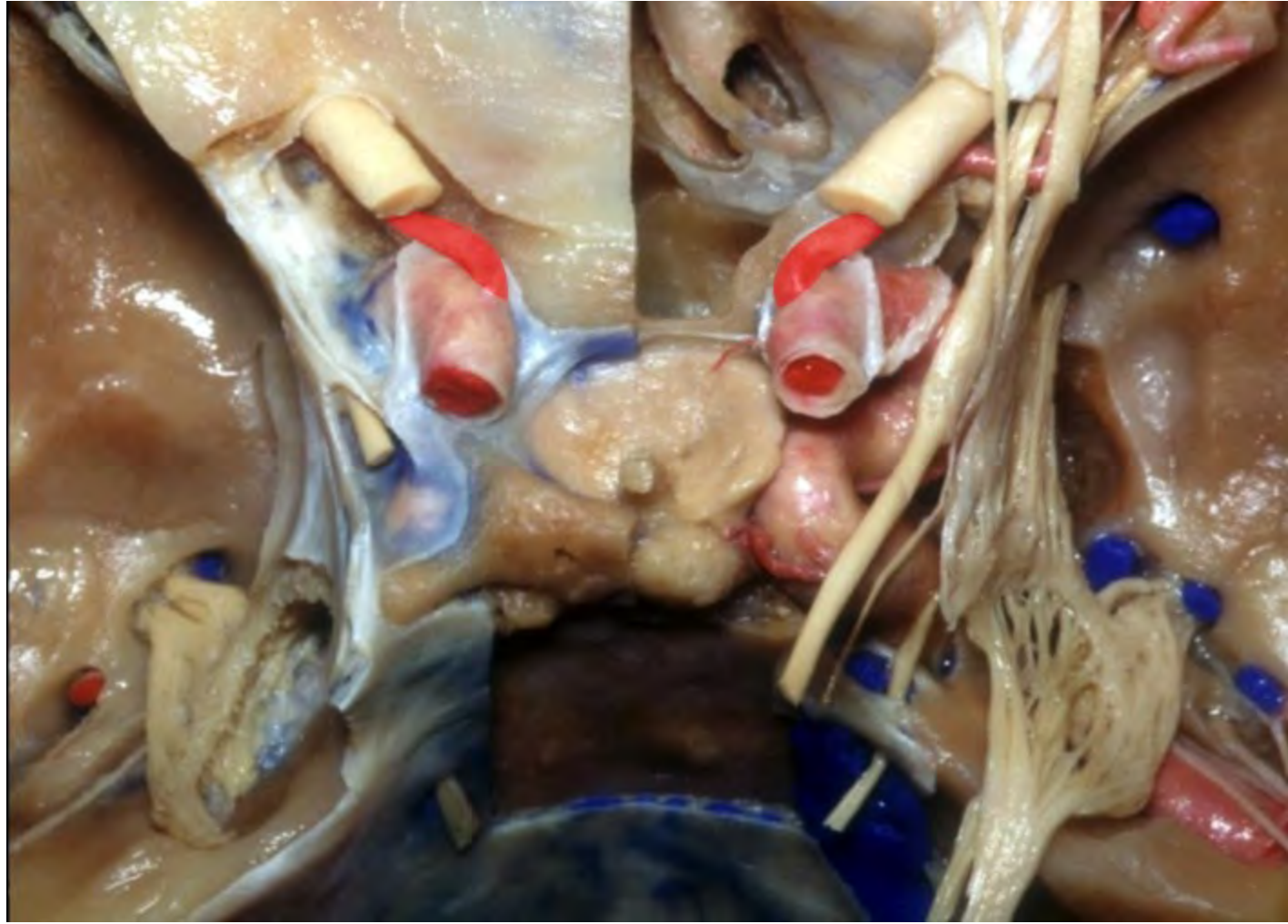


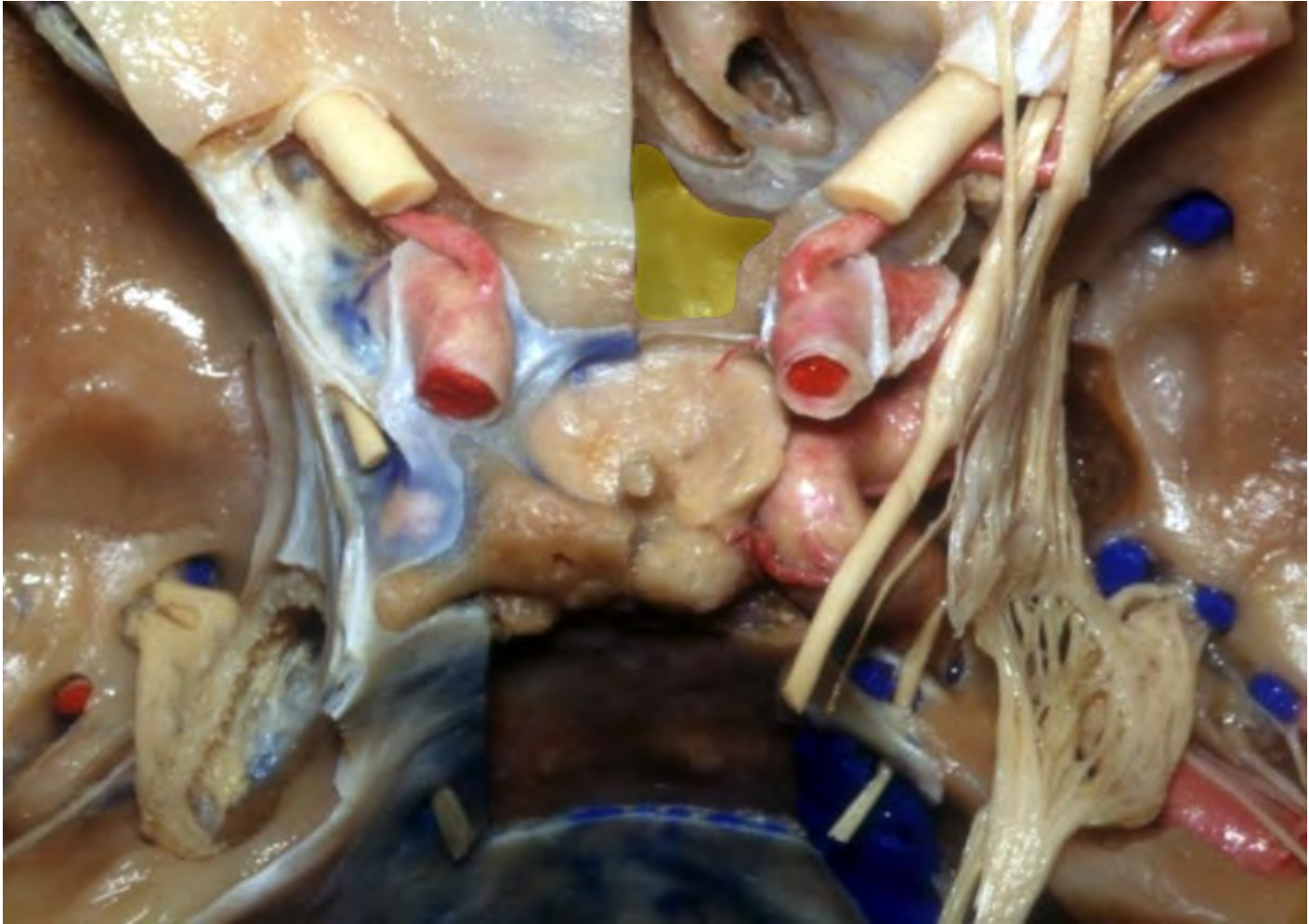
**Distal dural ring**

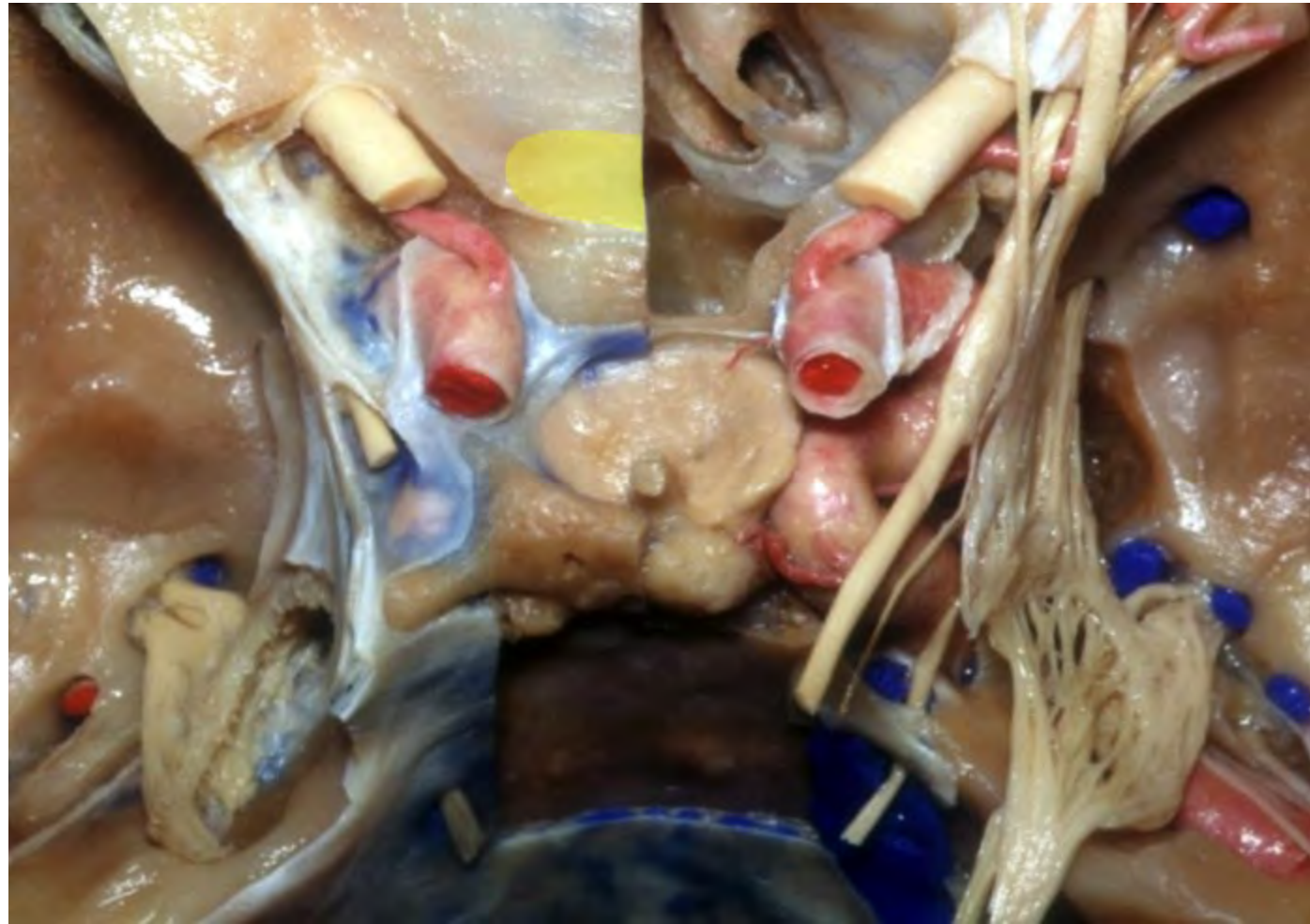


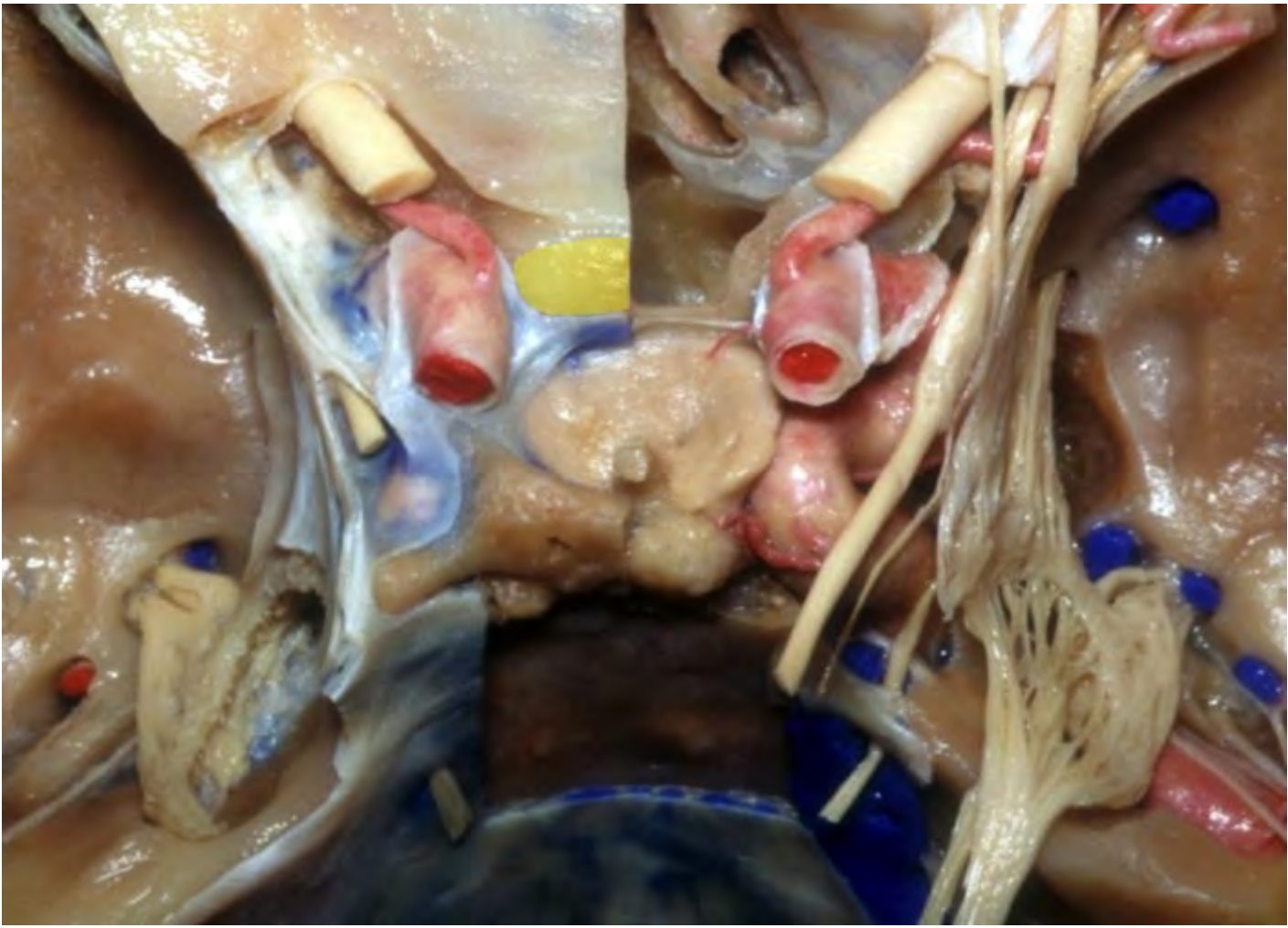**Ophthalmic segment of ICA**

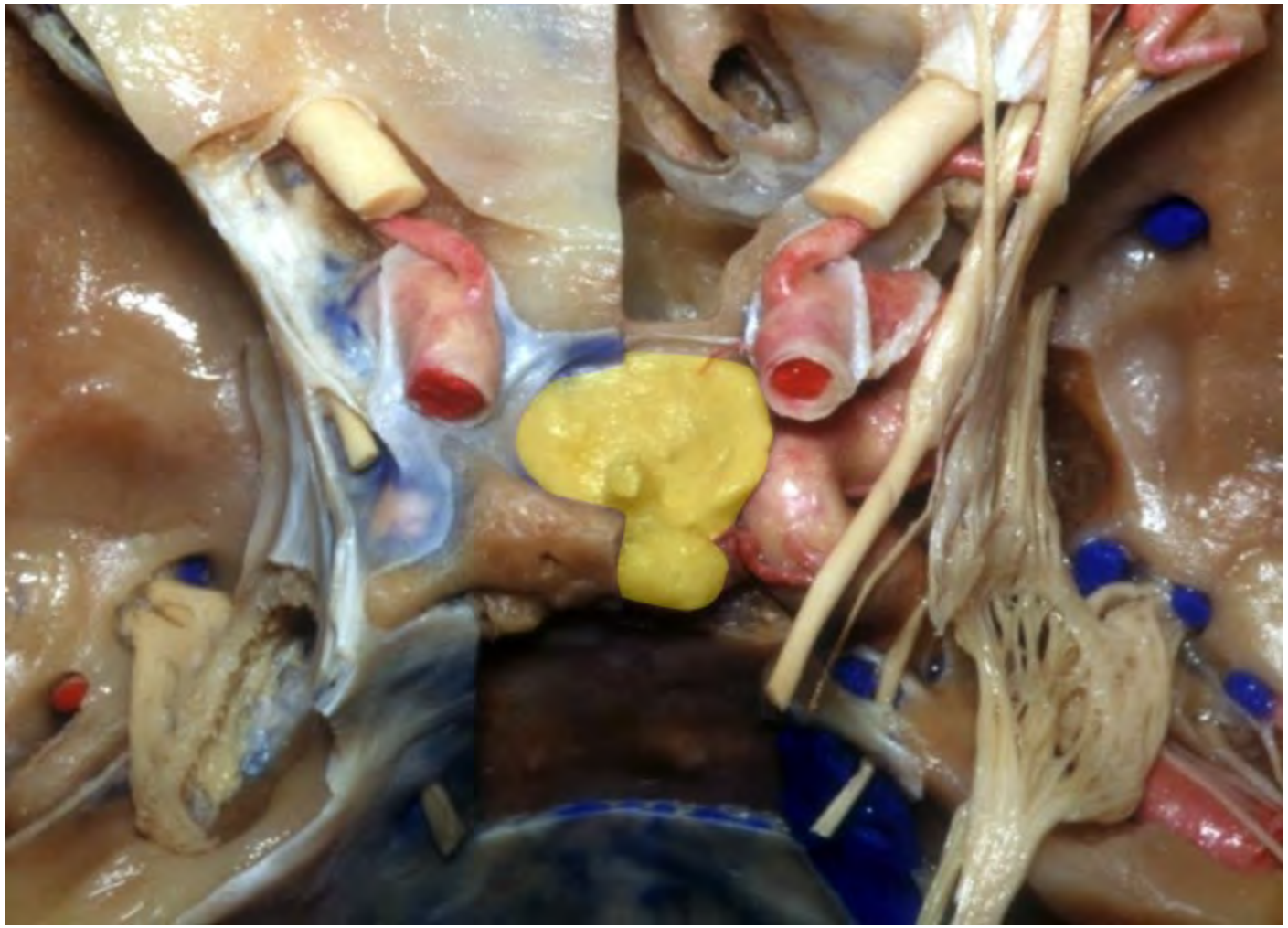



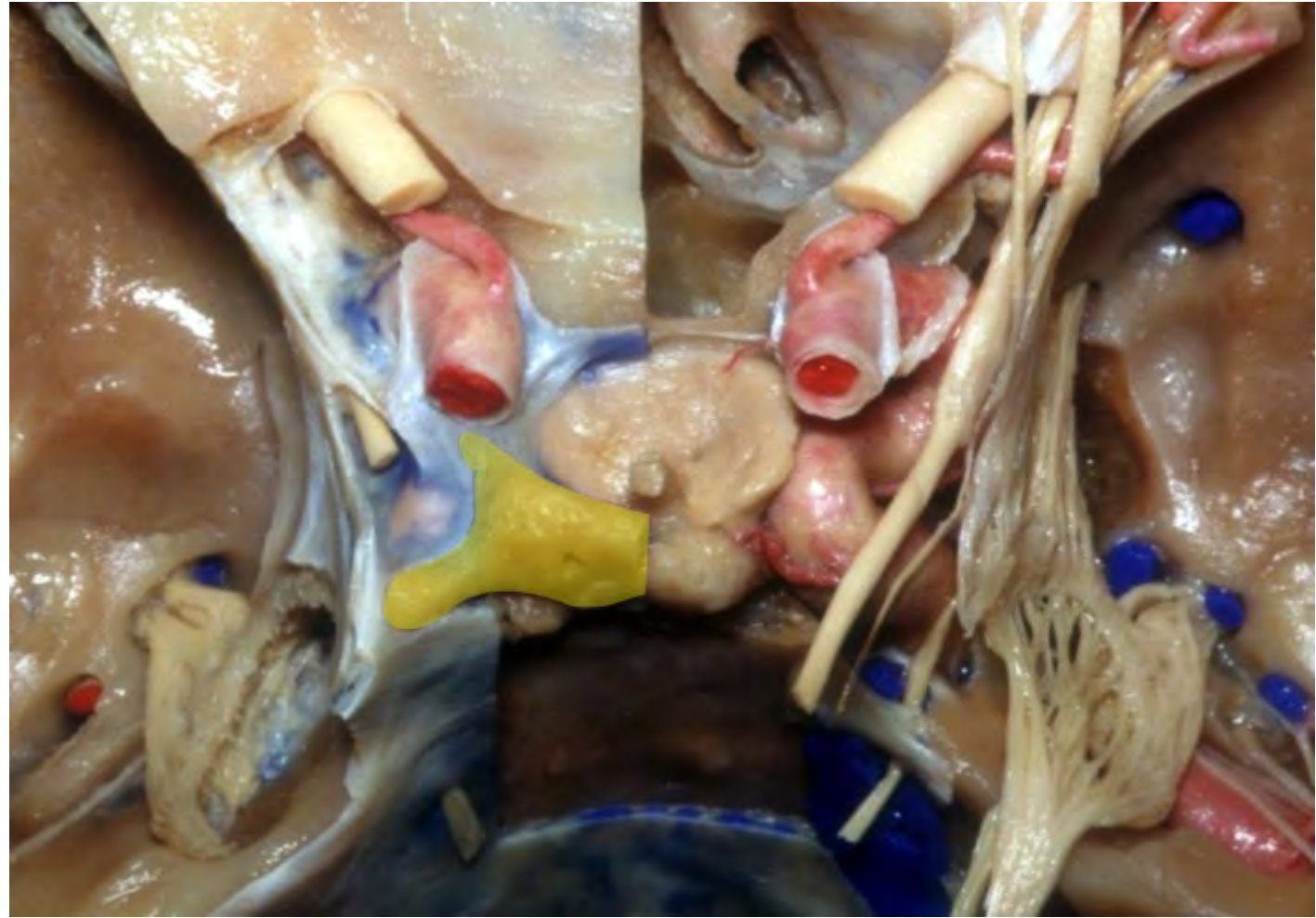


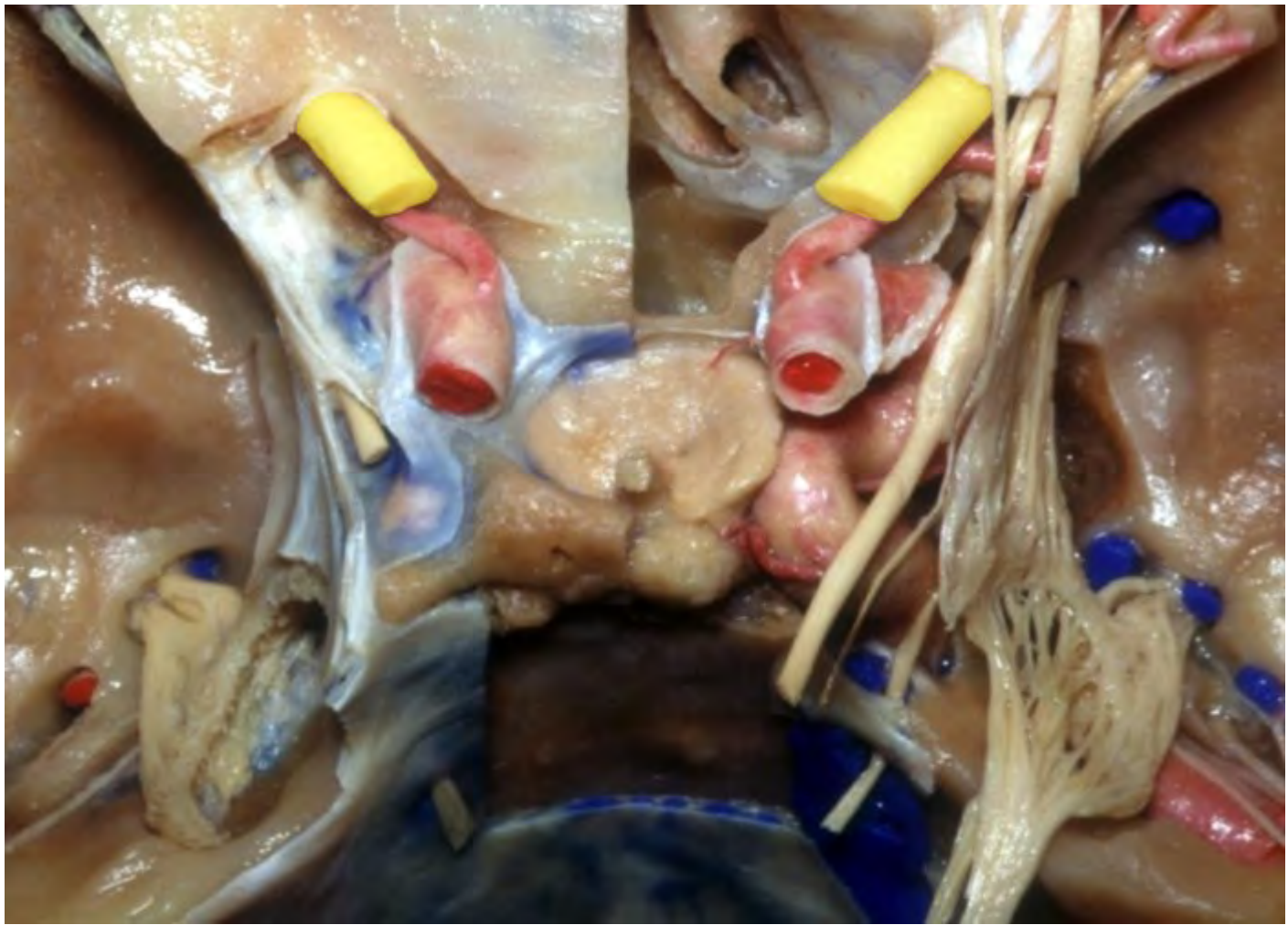


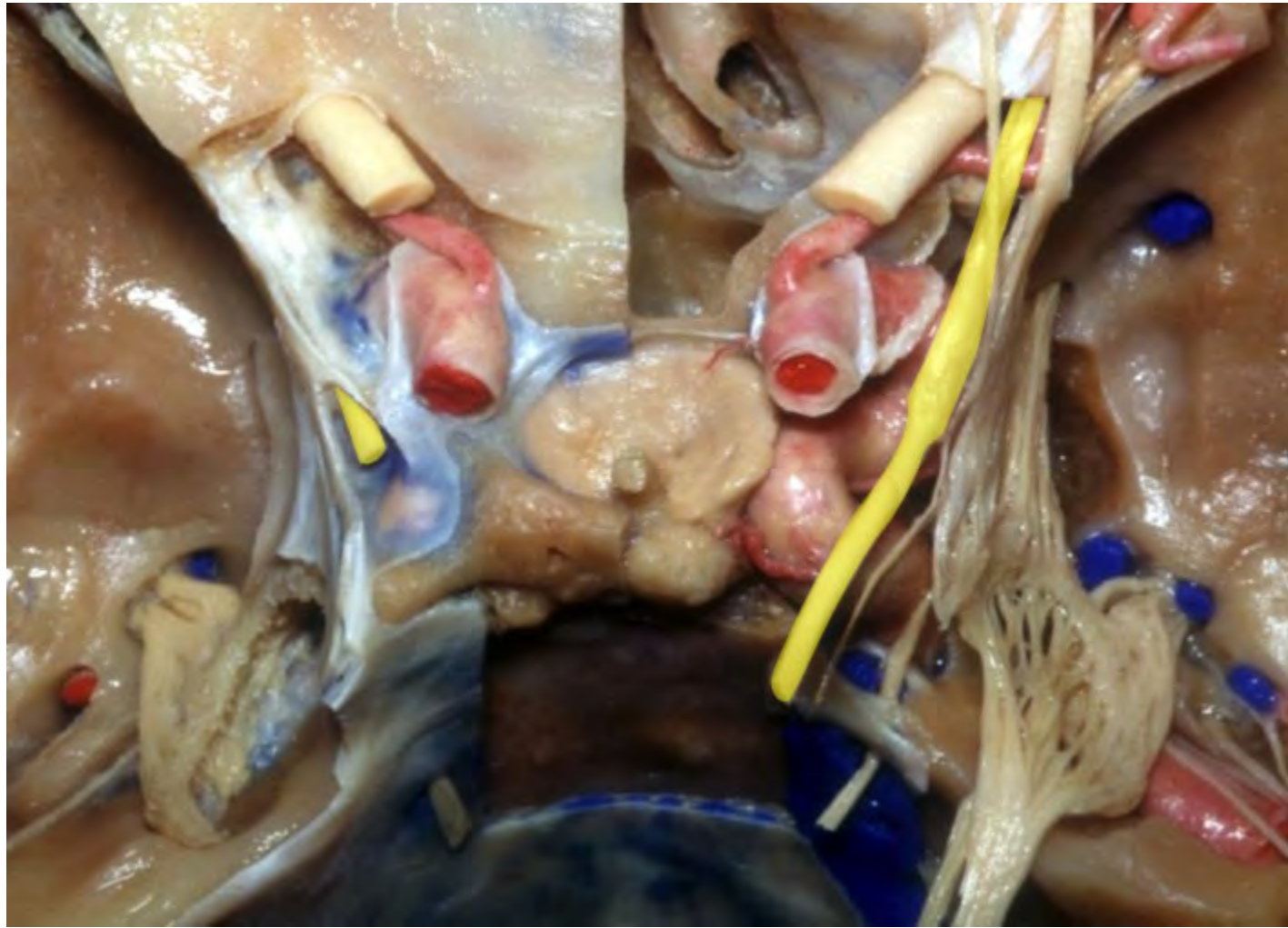


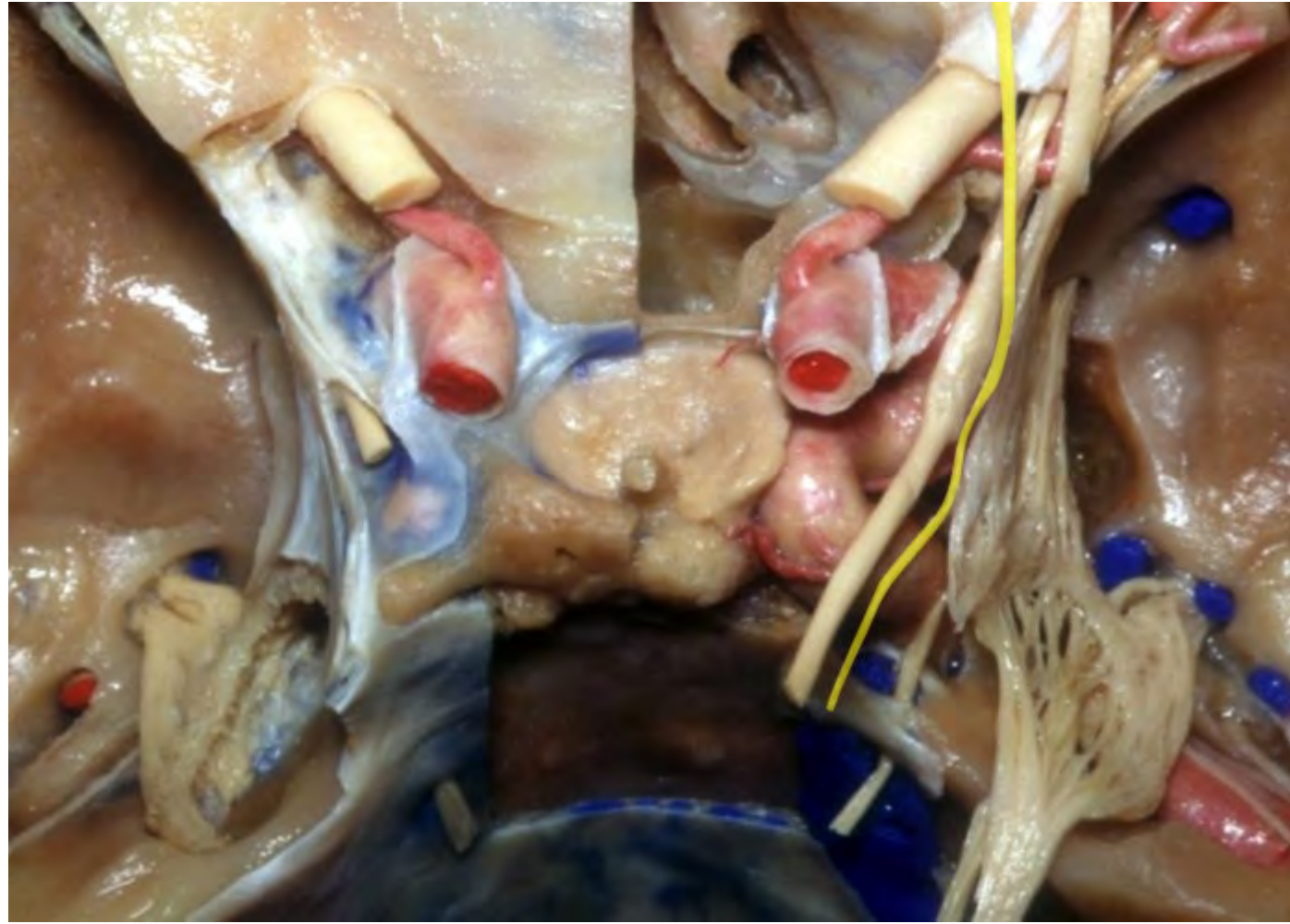


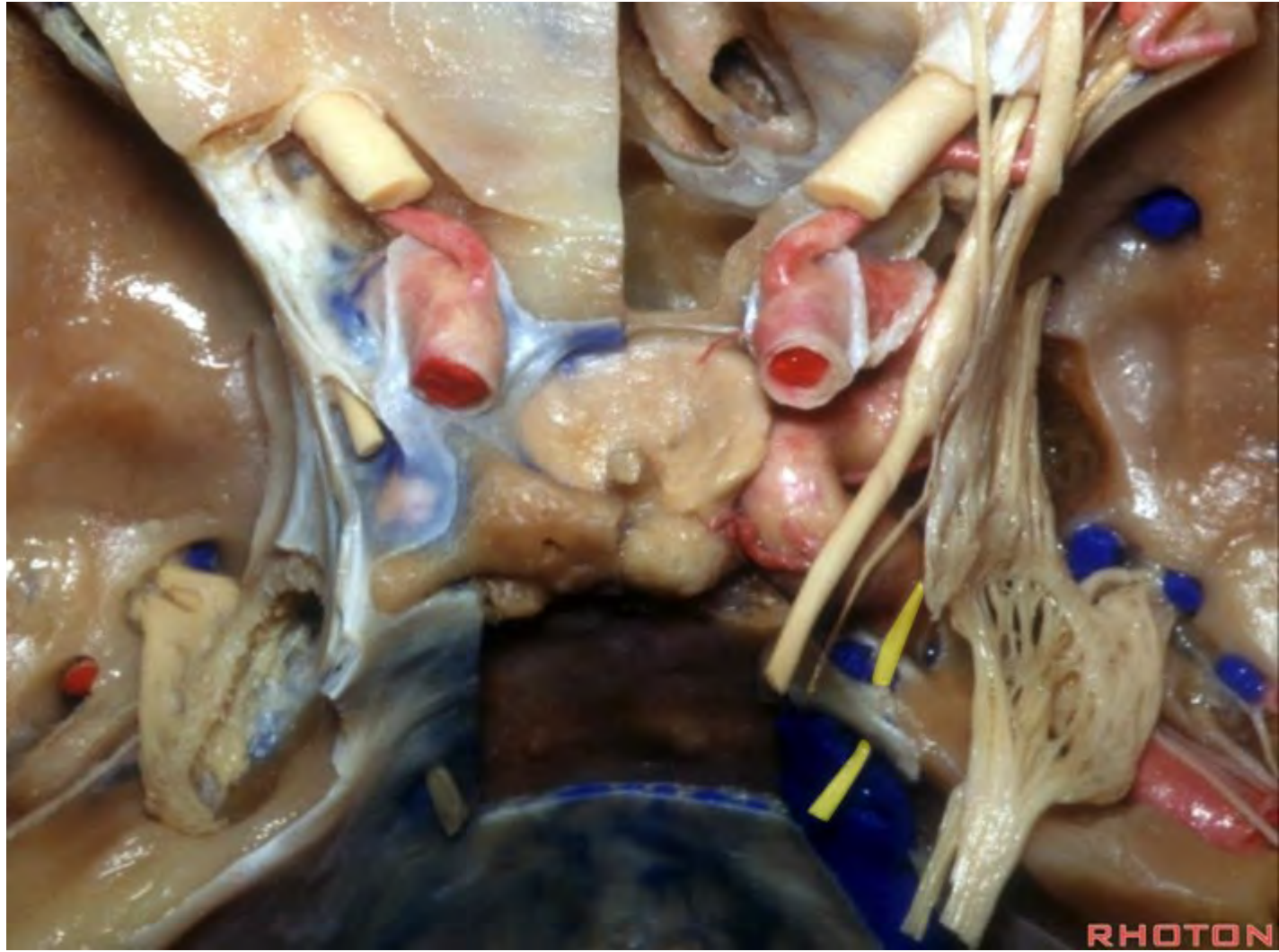


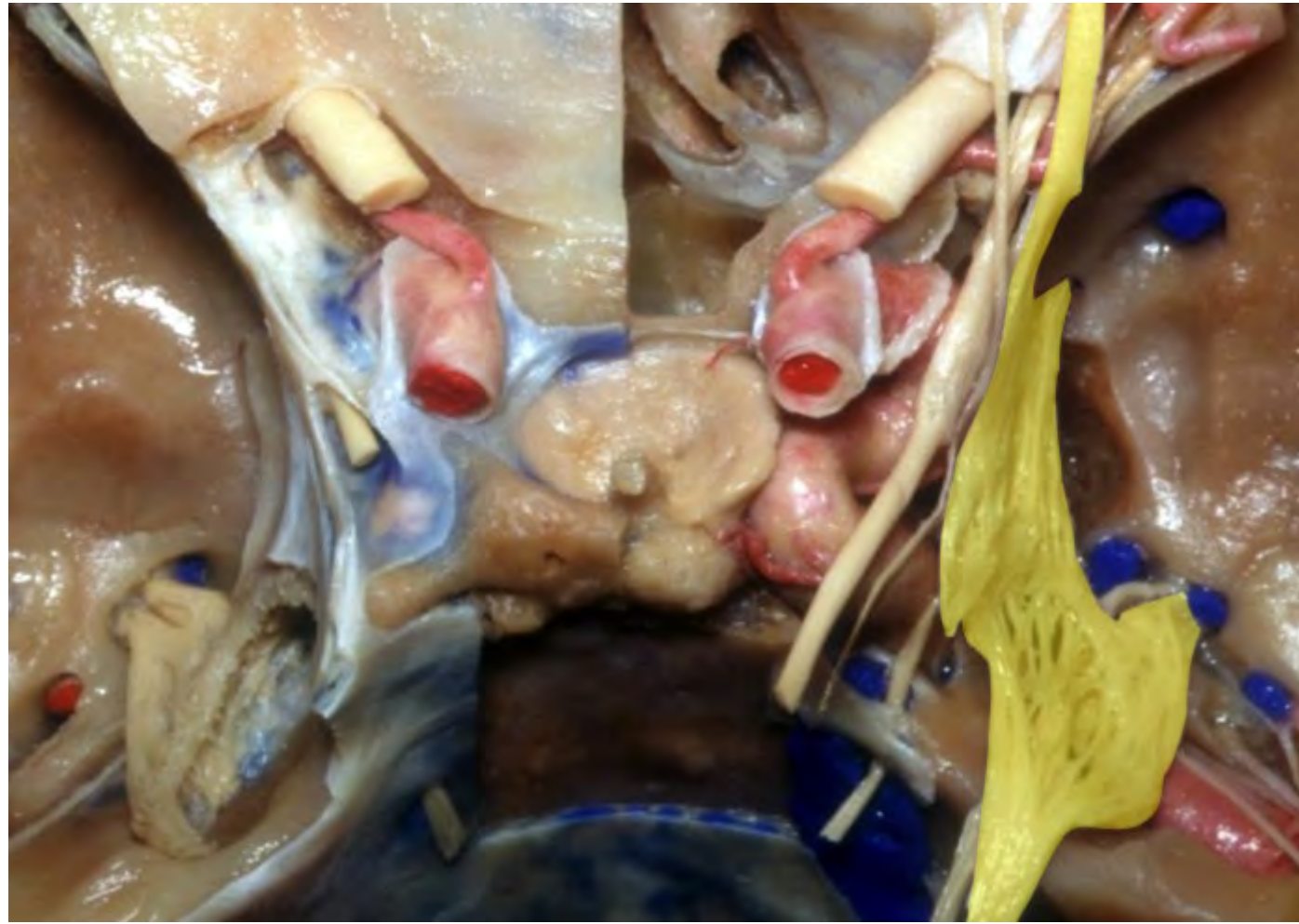


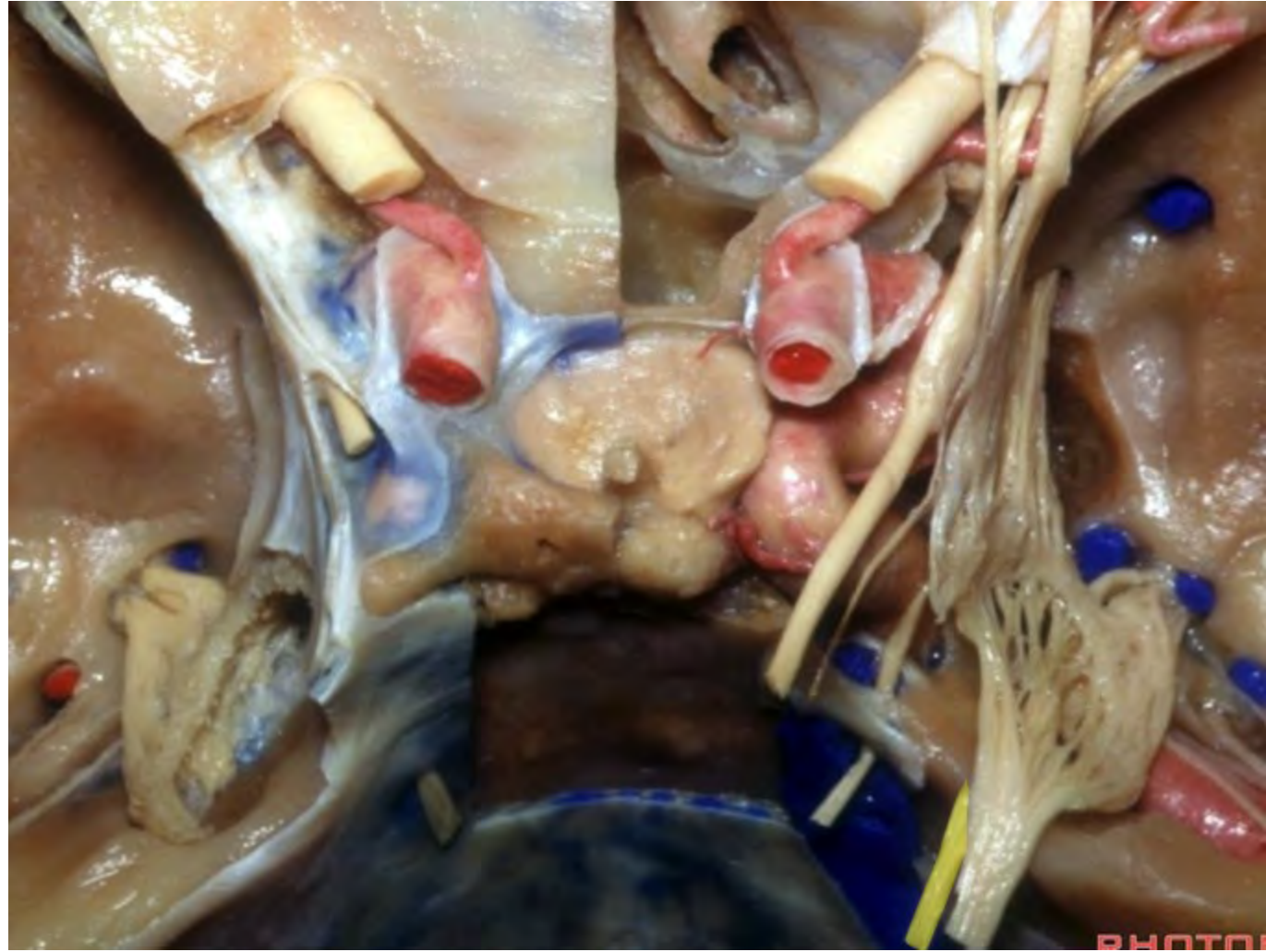




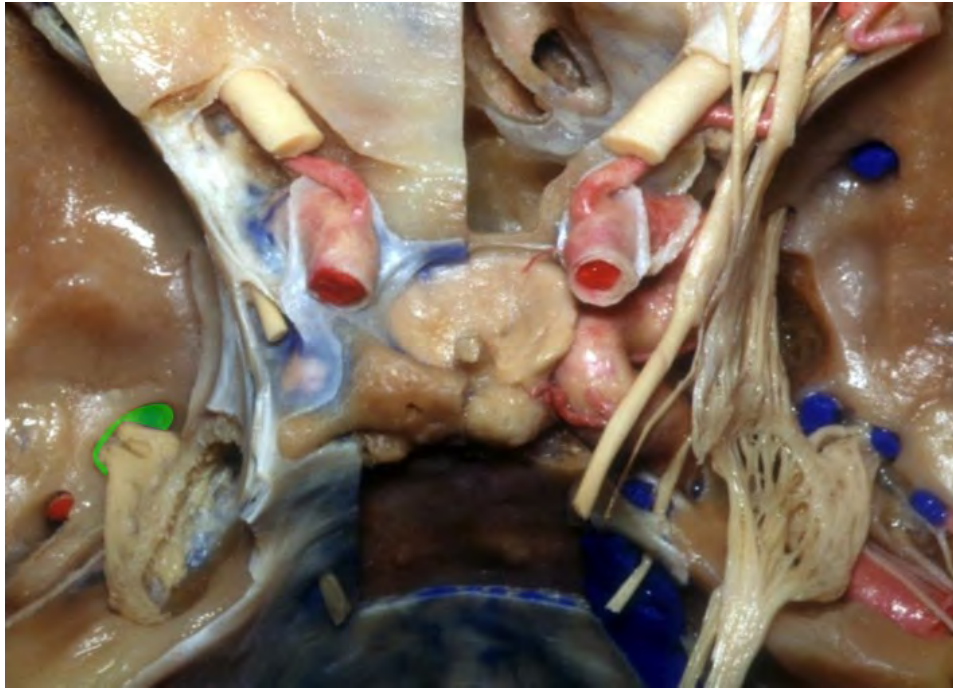




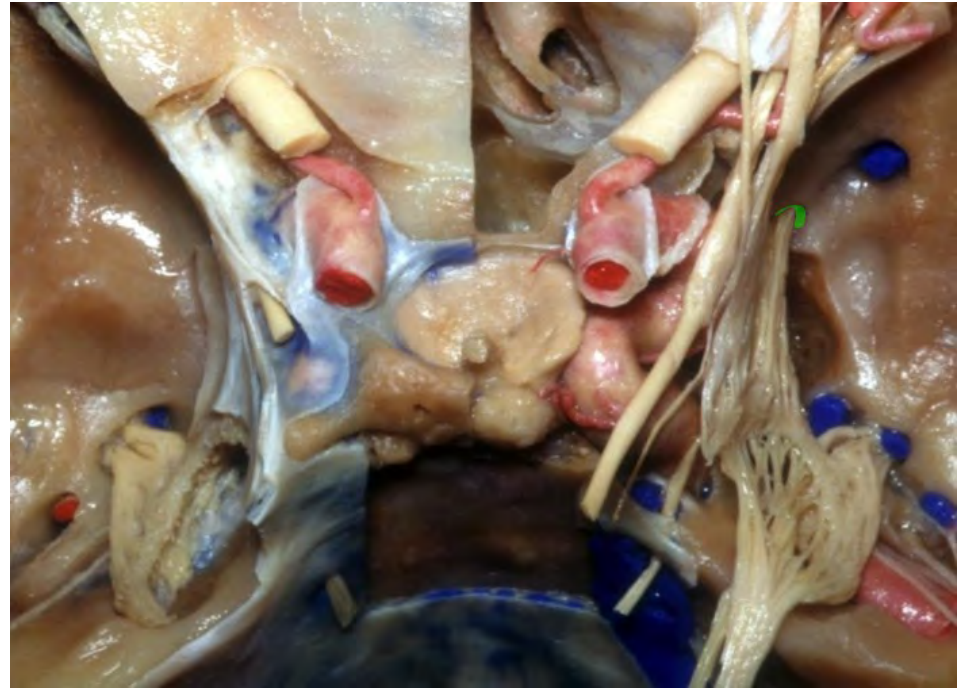




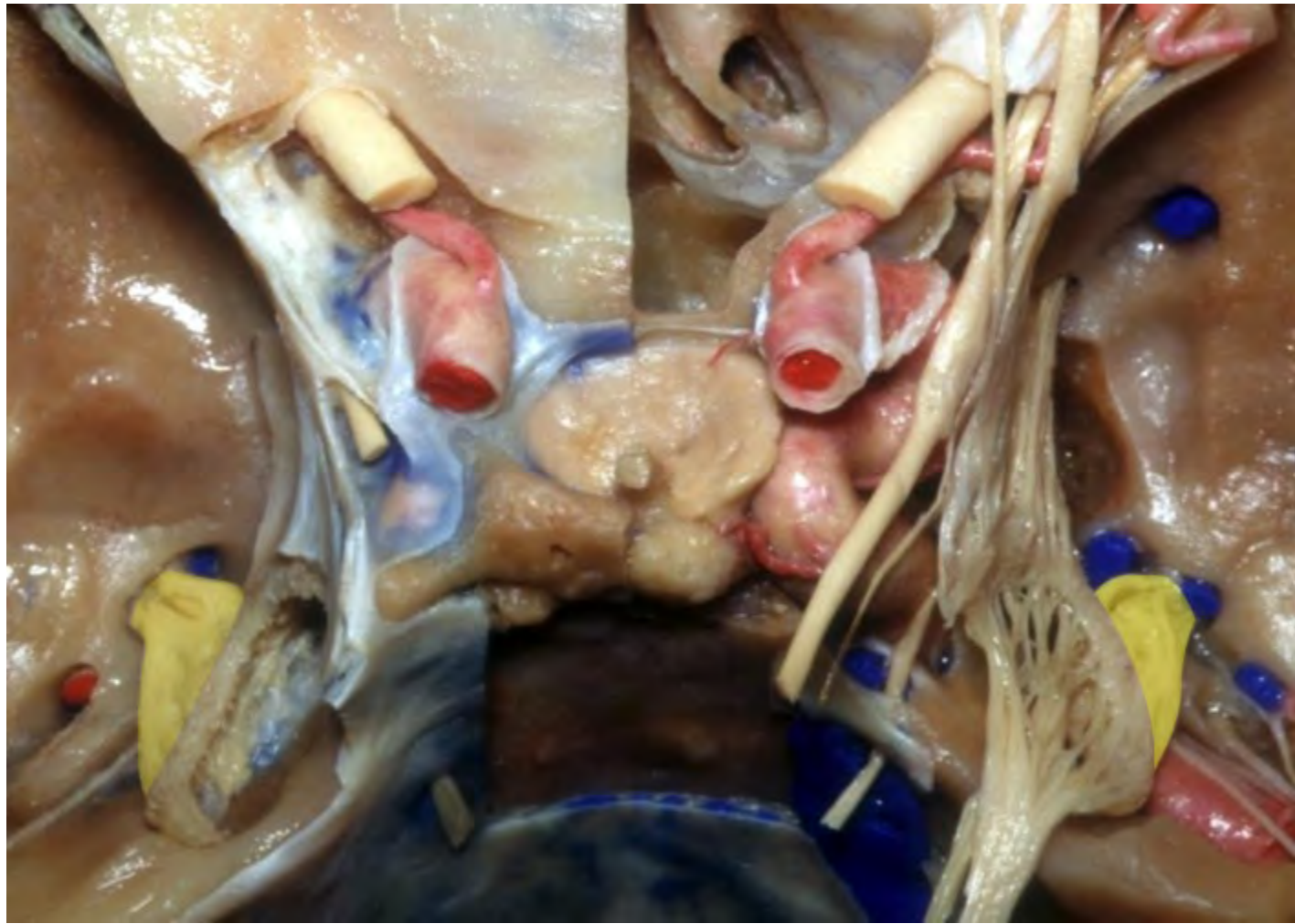
**Foramen ovale**

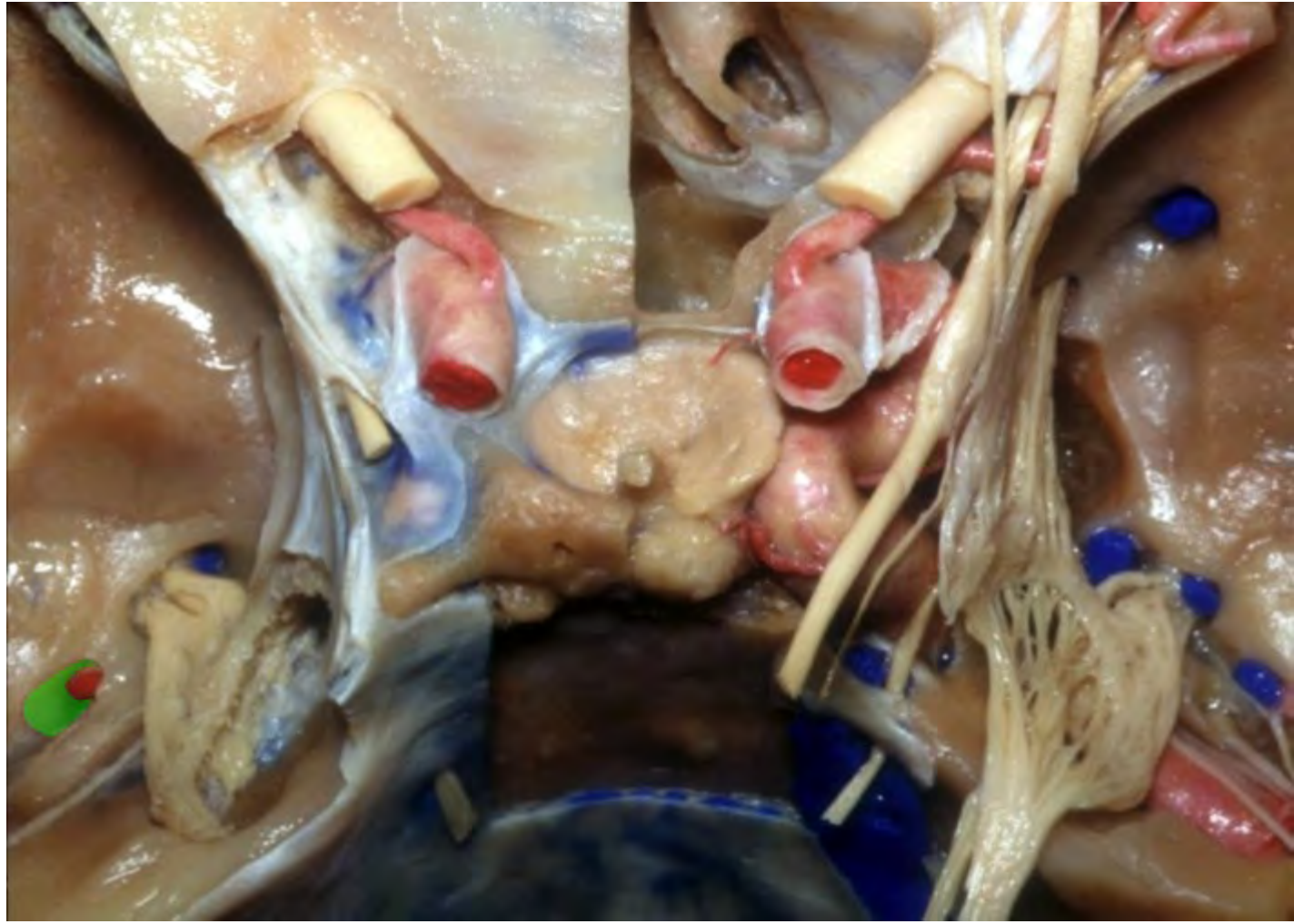

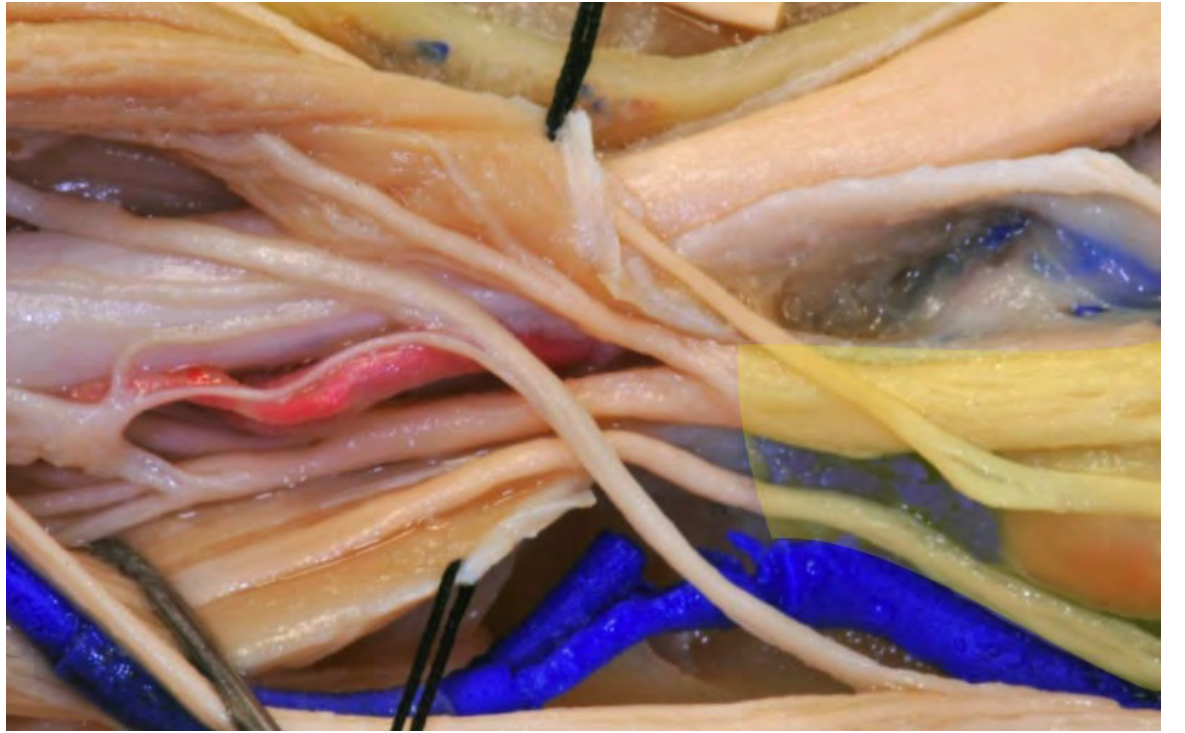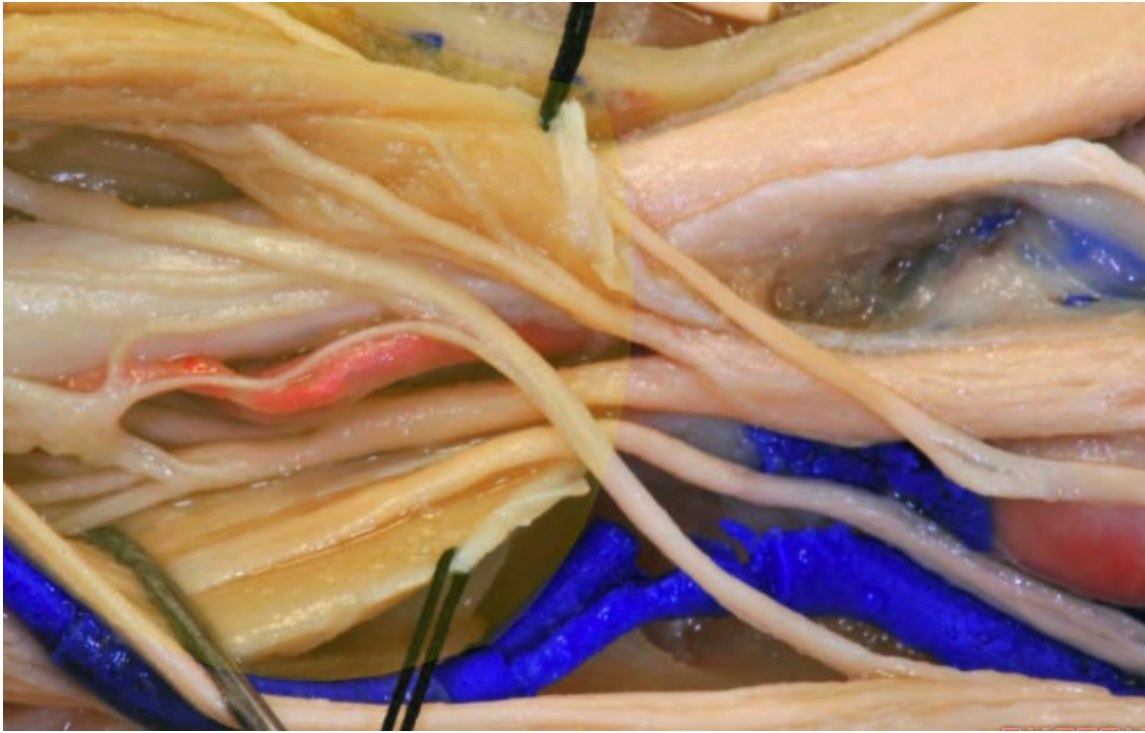**Foramen rotundum**

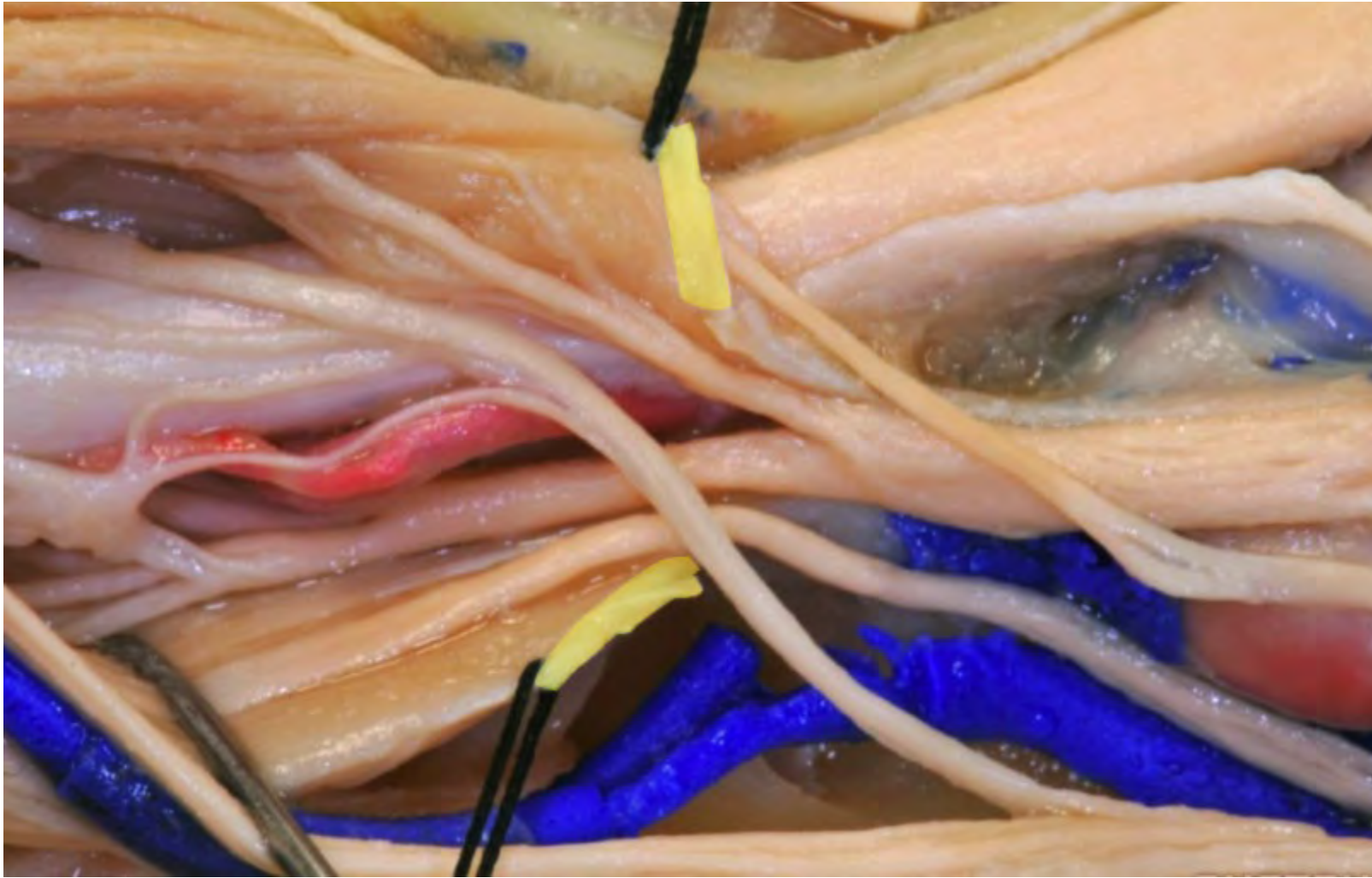


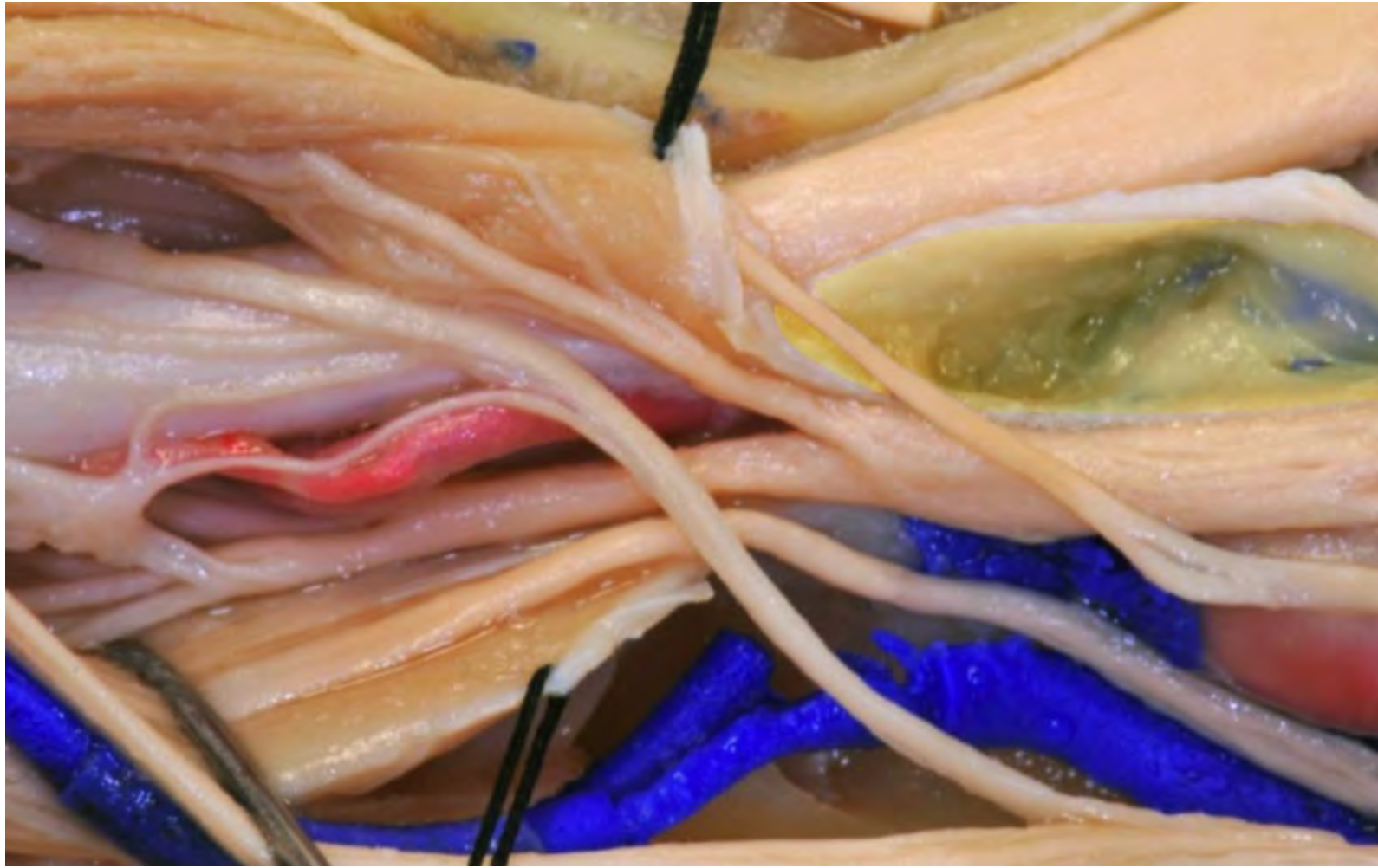

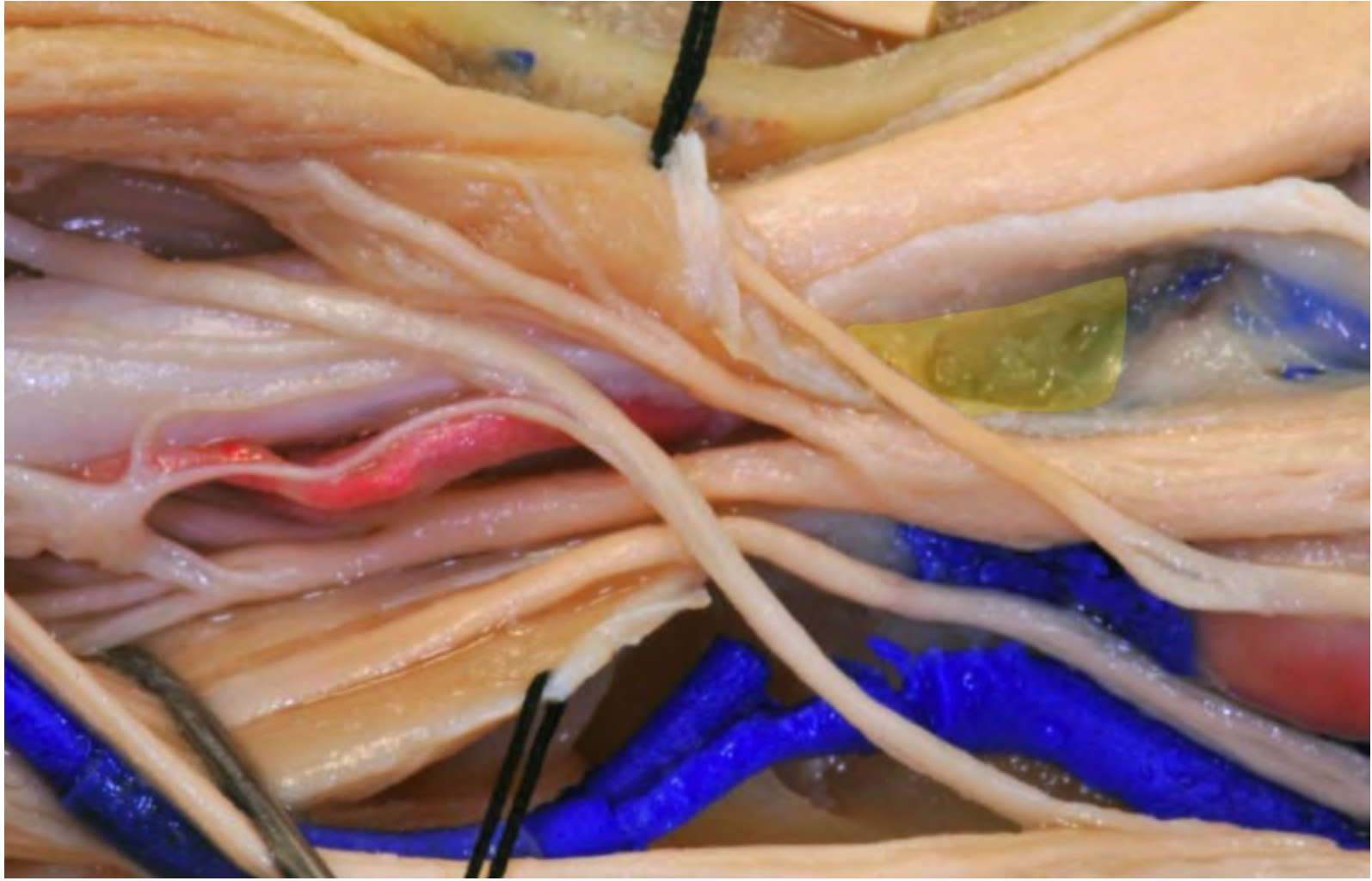



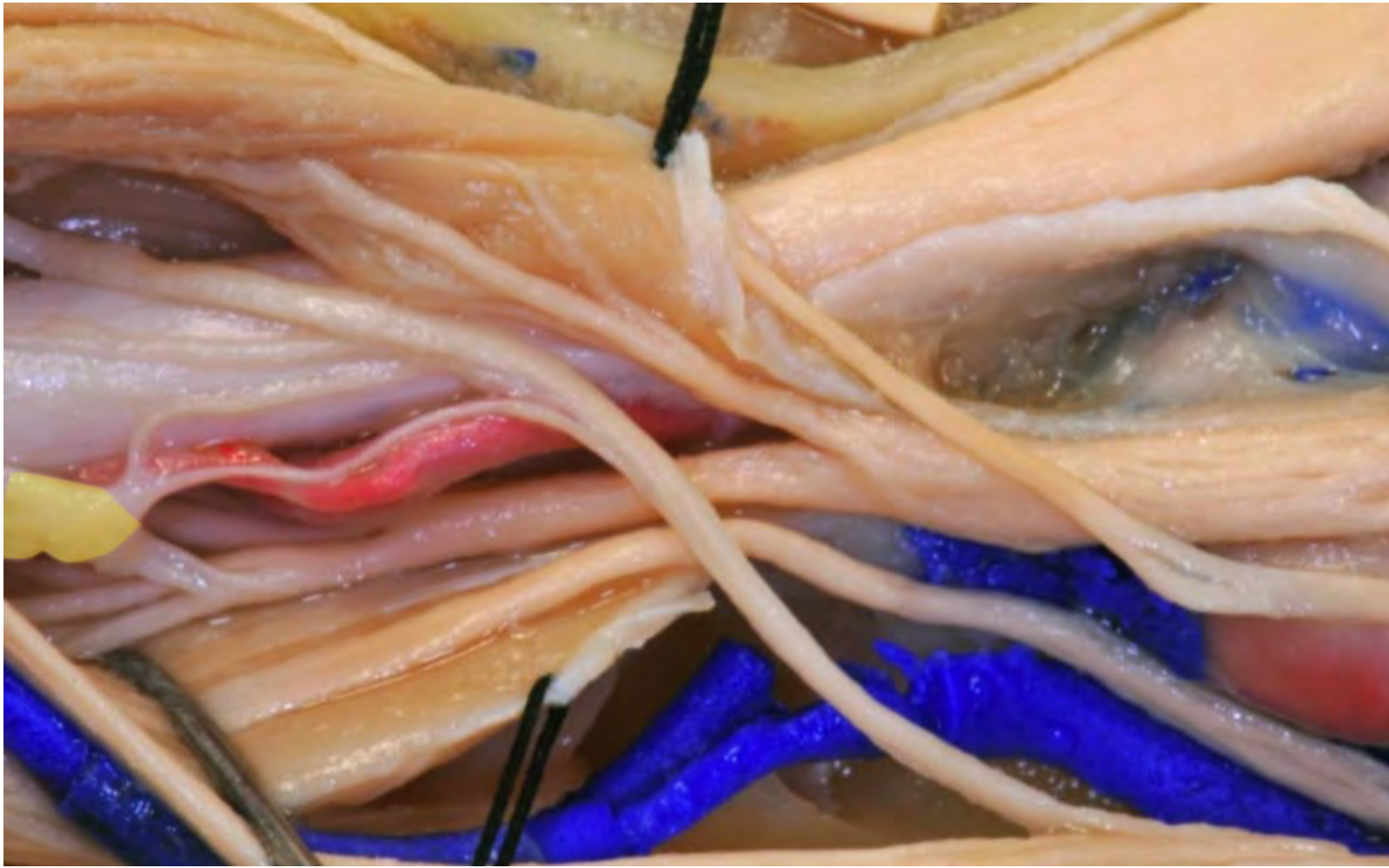


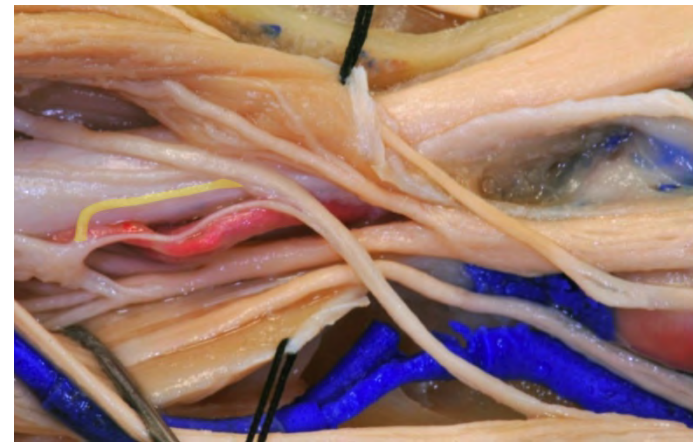






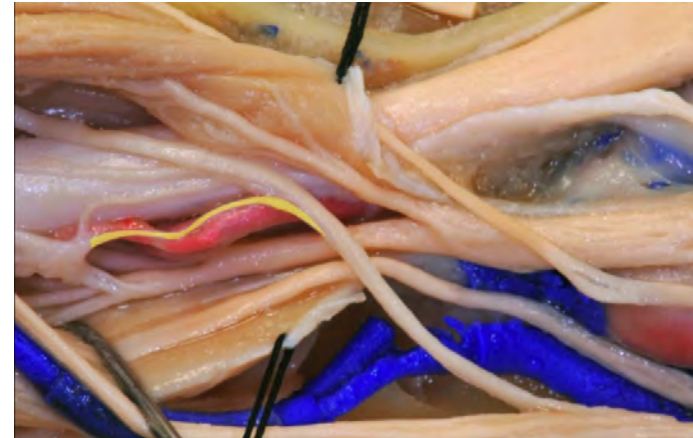

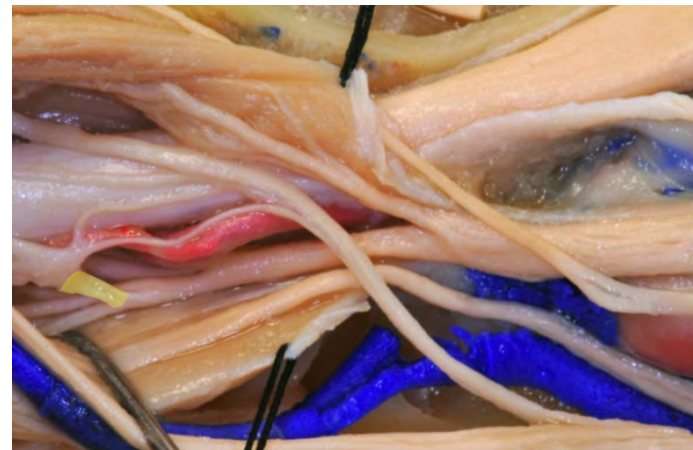**Sympathetic root of ciliary ganglion**



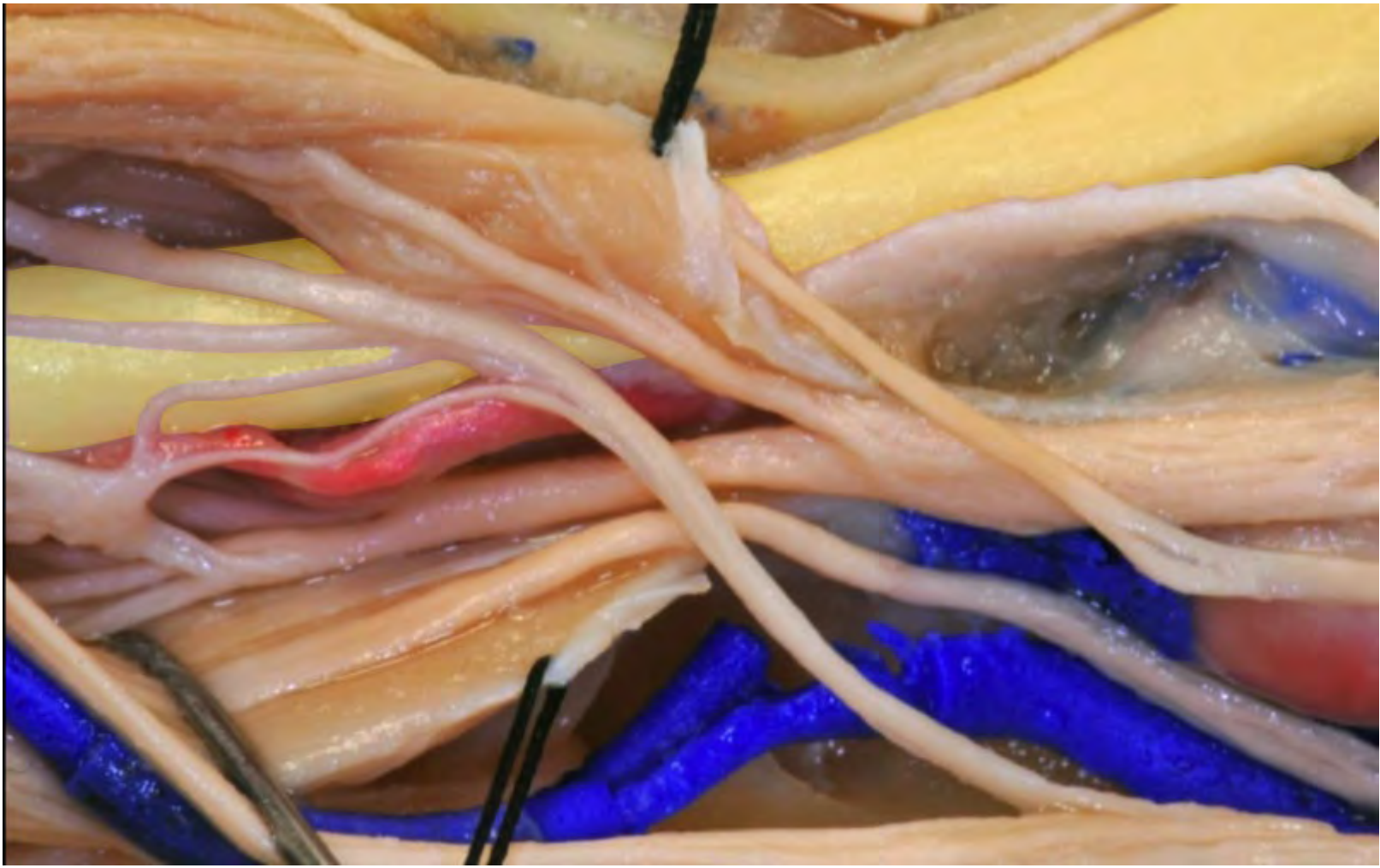**Sensory root of the ciliary ganglion**

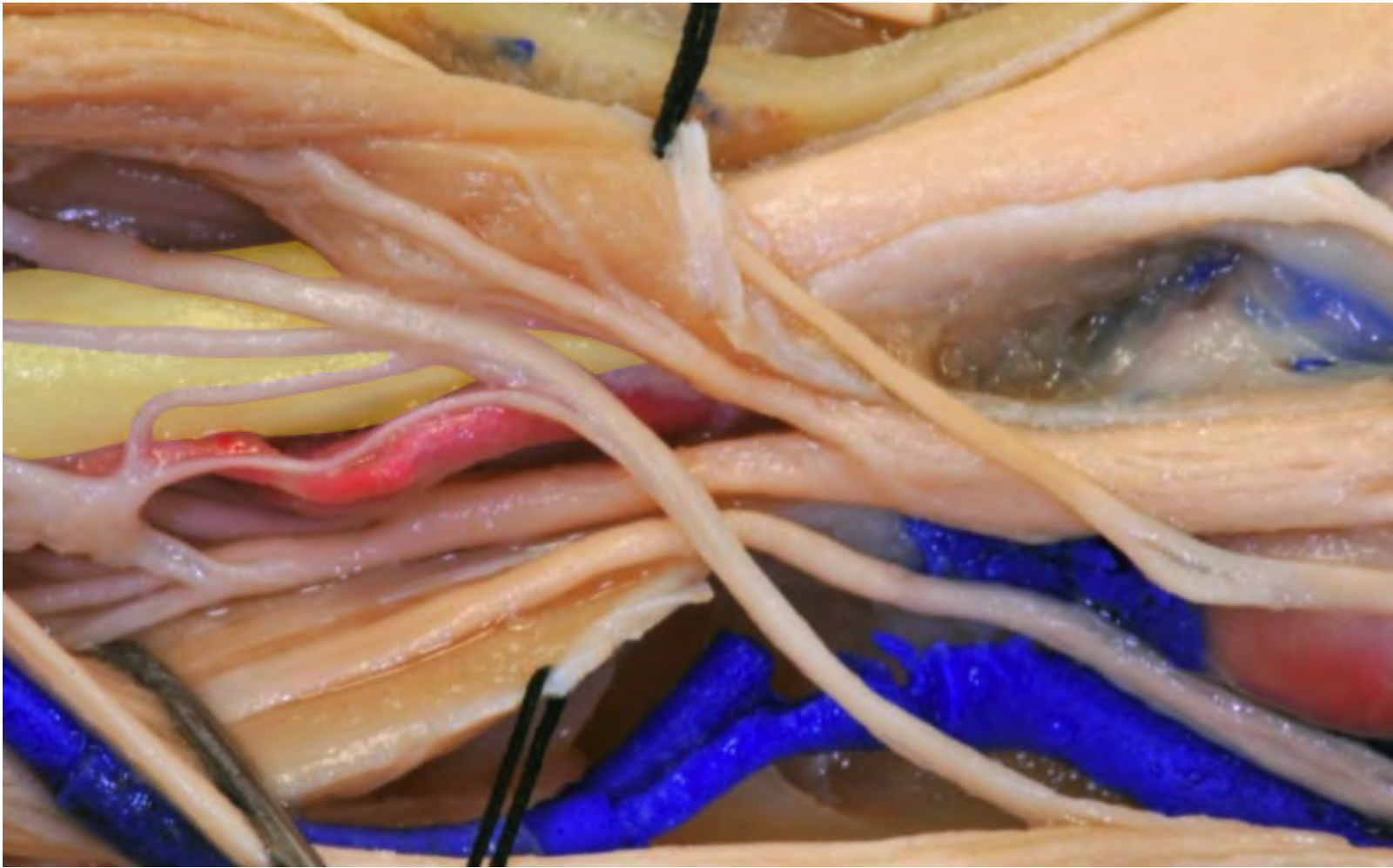


**Parasympathetic root of the ciliary ganglion**

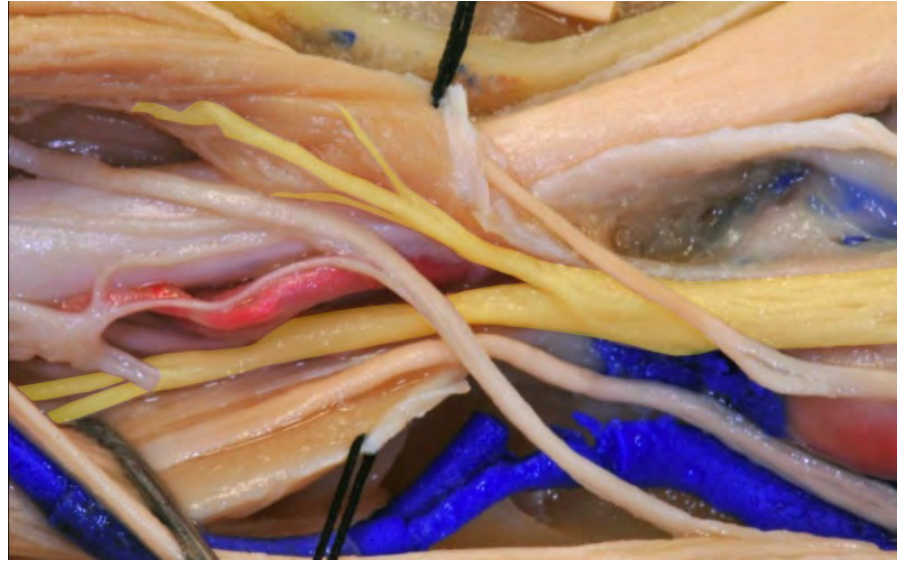




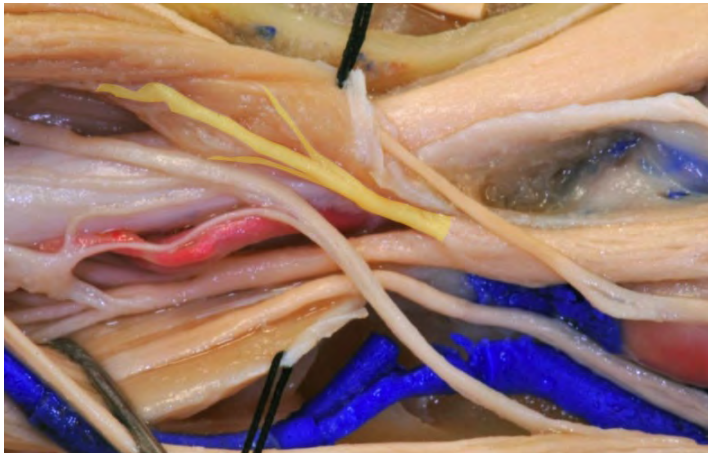


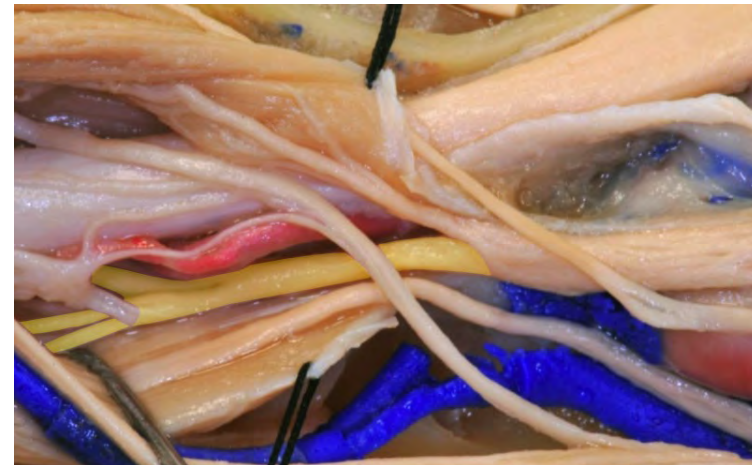**Oculomotor nerve**

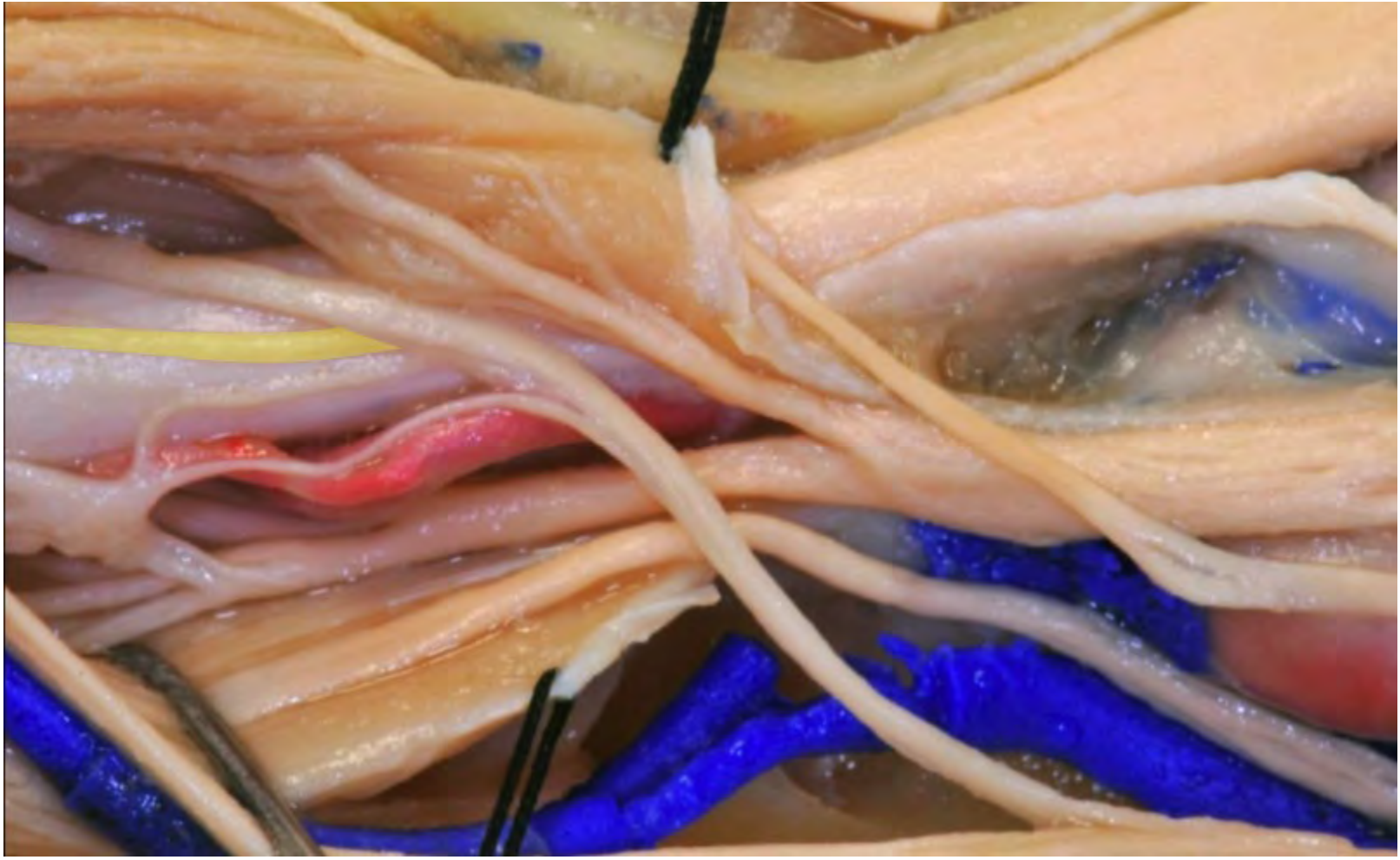

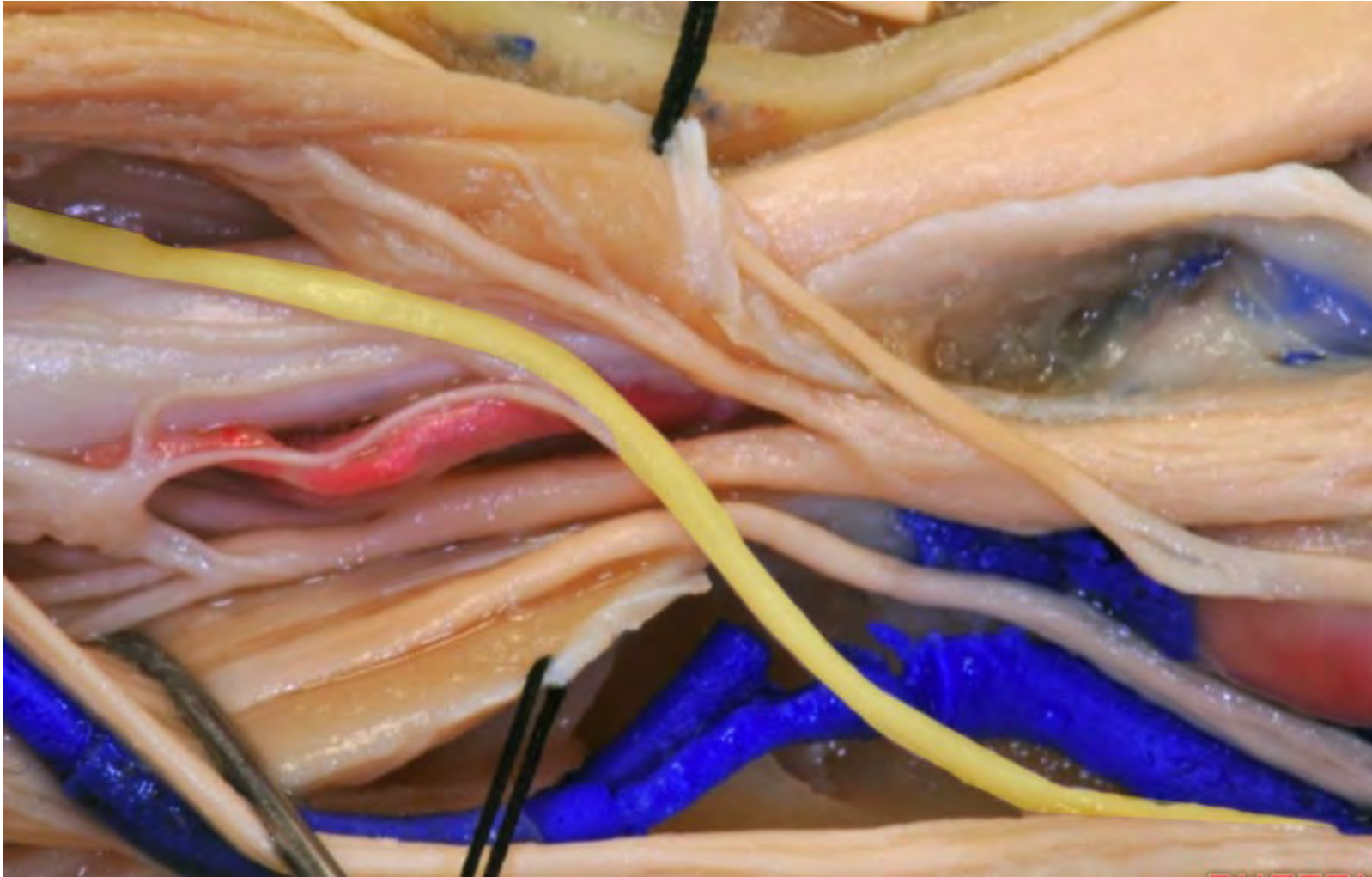
**Superior division of the oculomotor nerve**

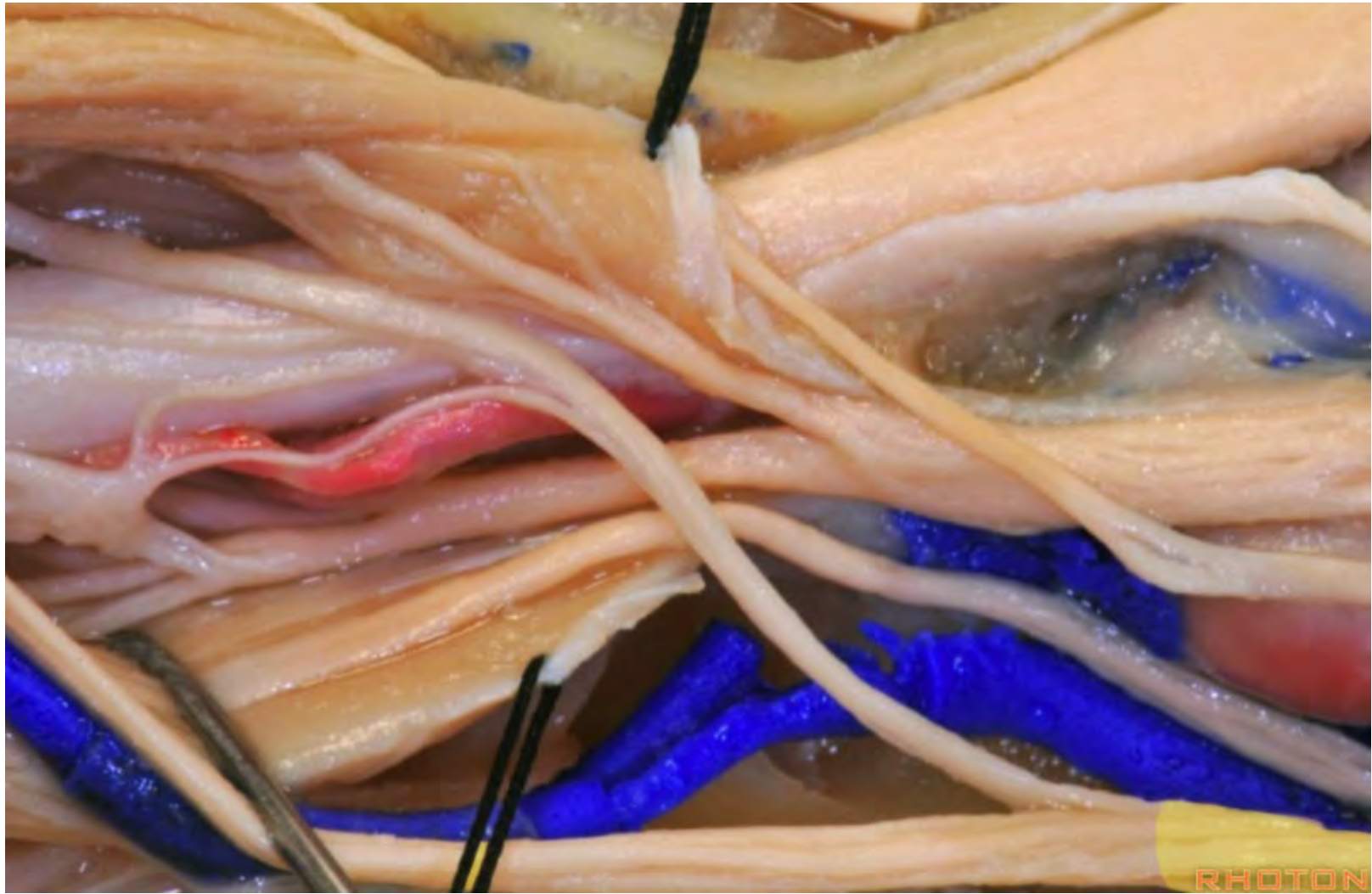


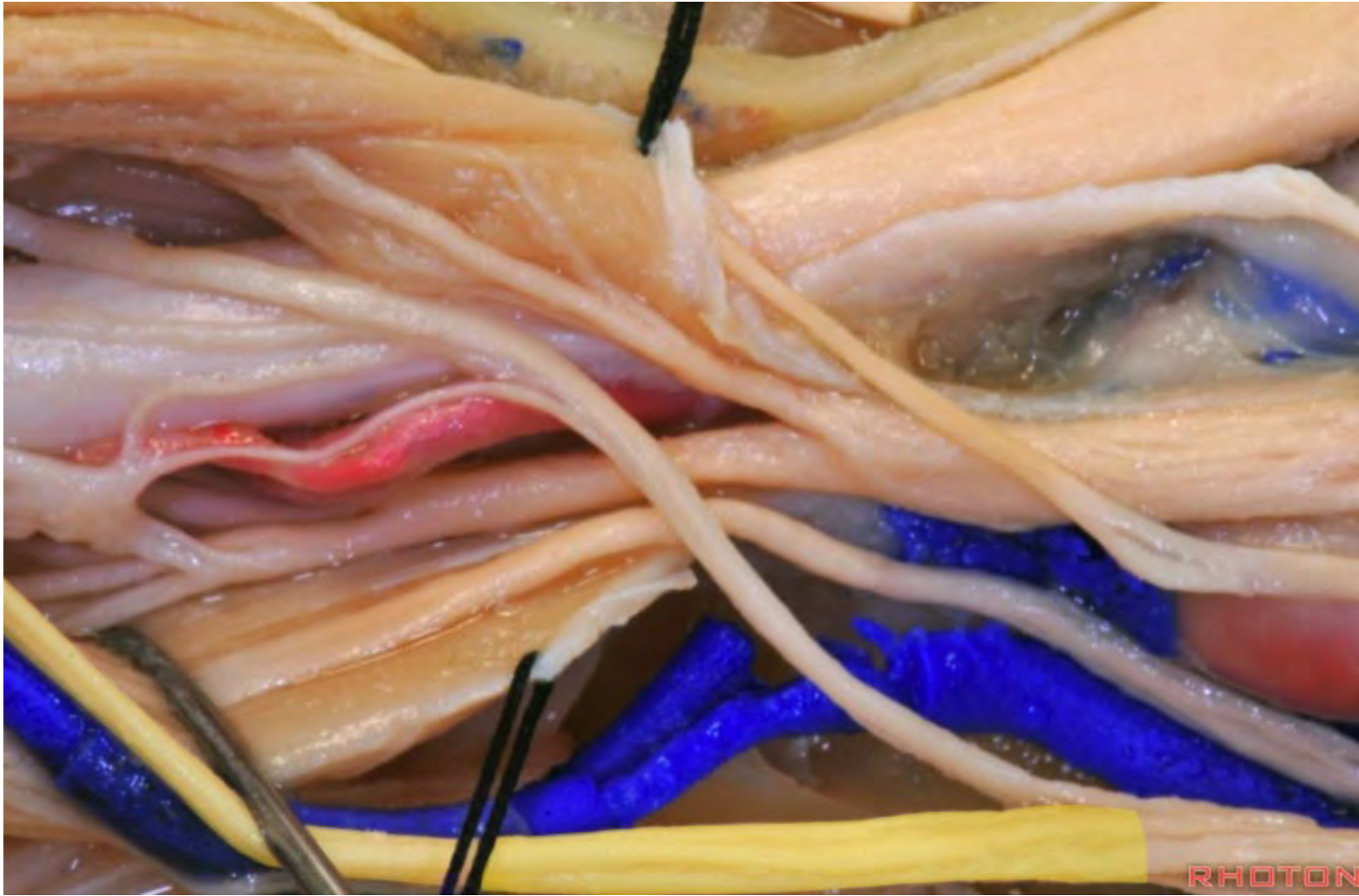
**Inferior division of the oculomotor nerve**

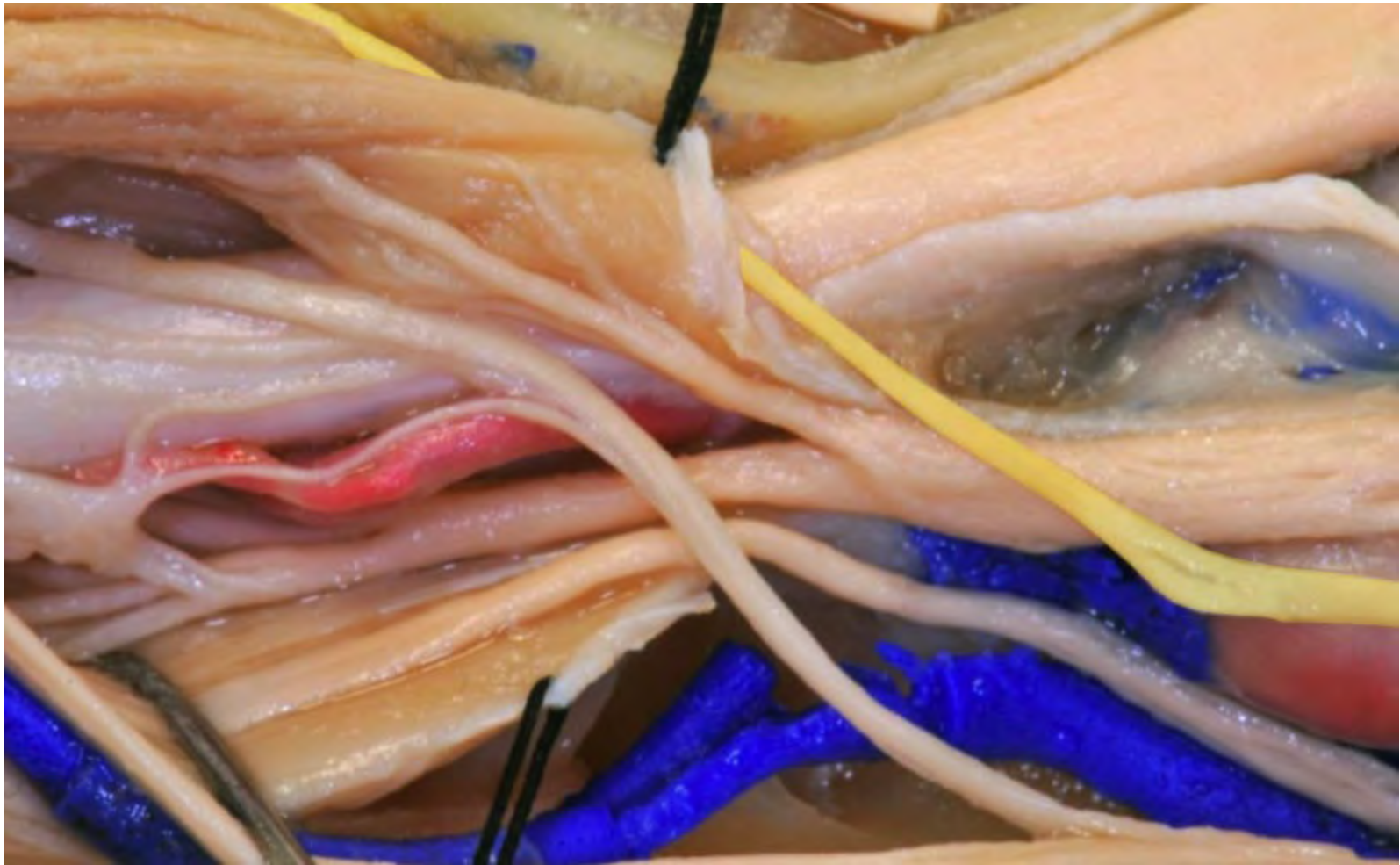




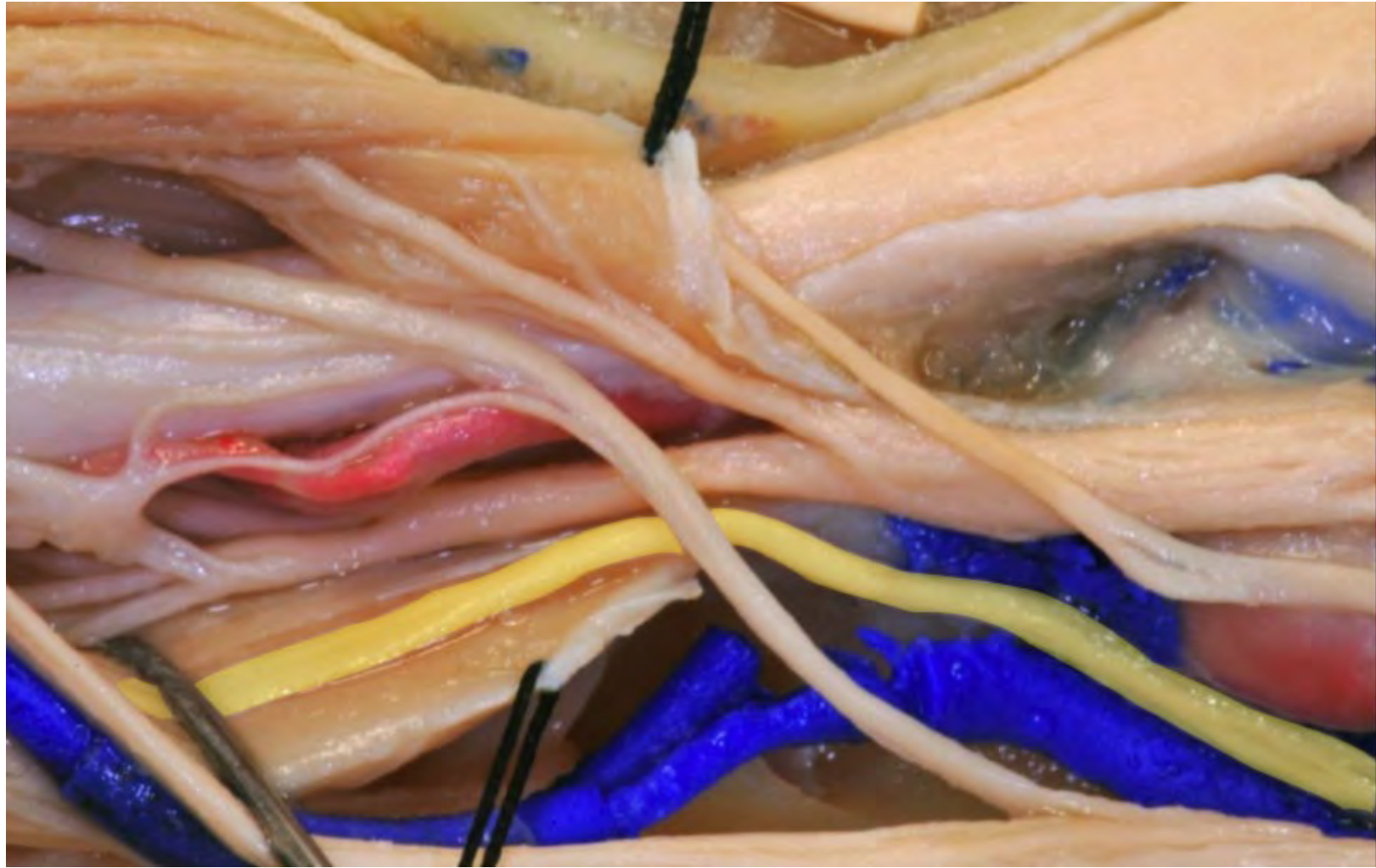


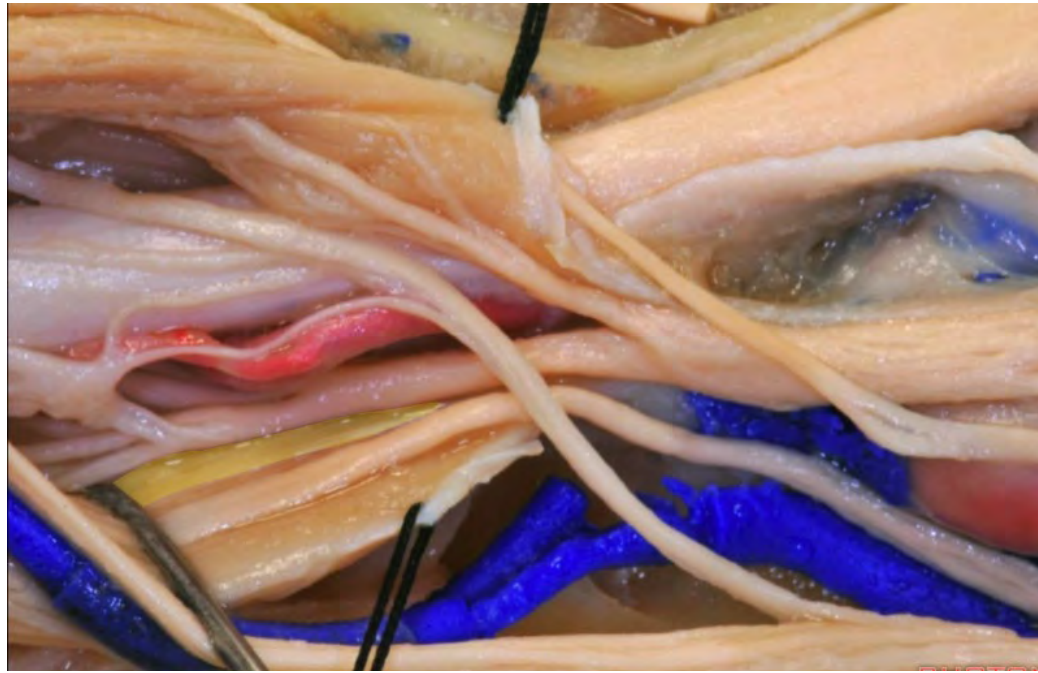






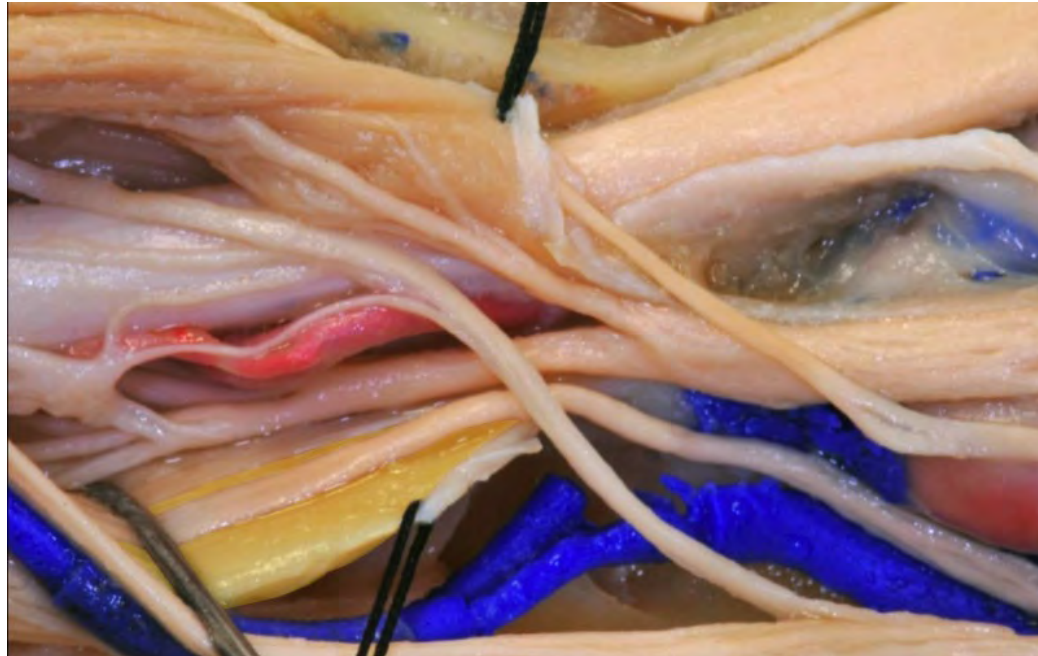

**Inferior rectus**



**Lateral rectus**

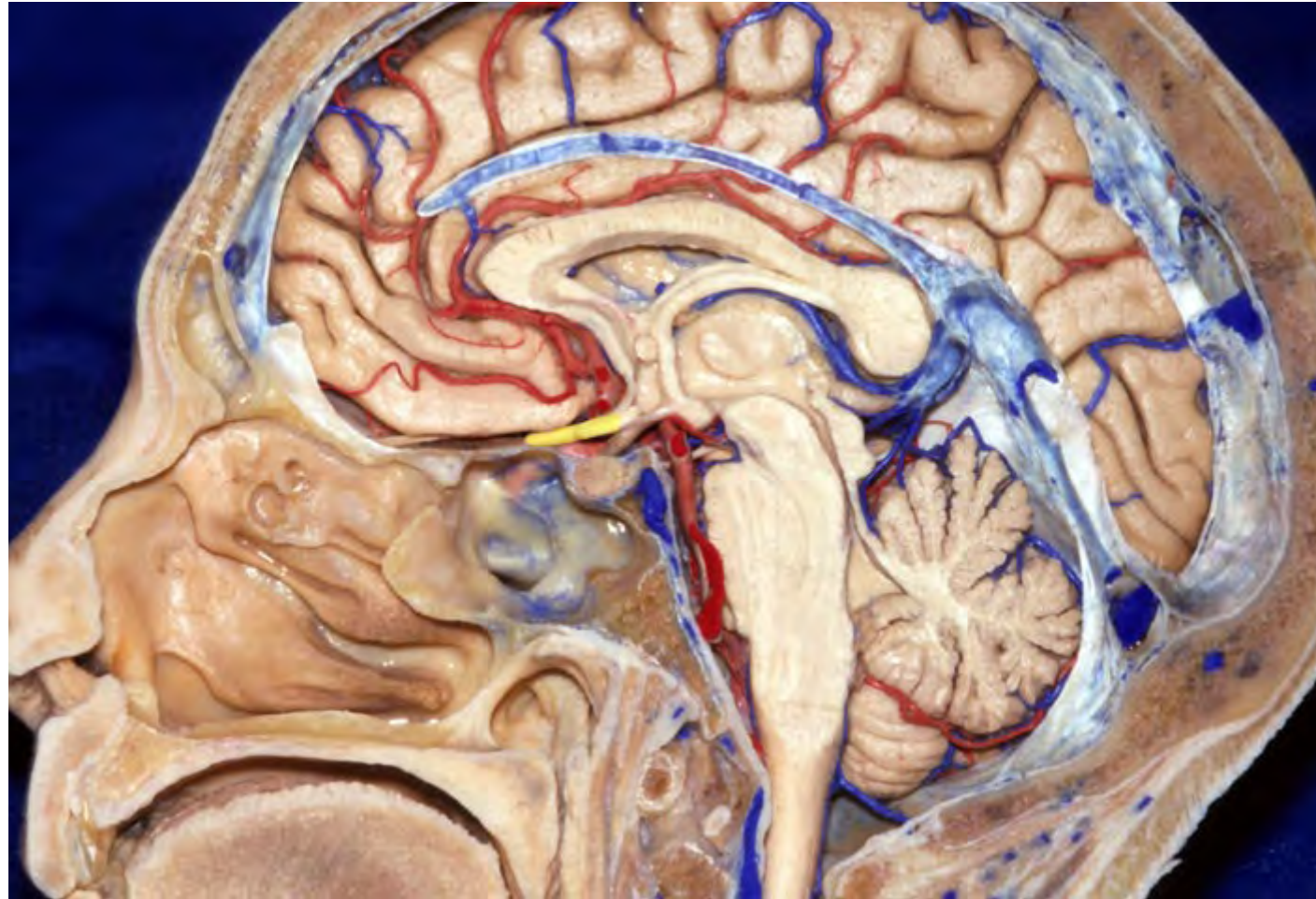


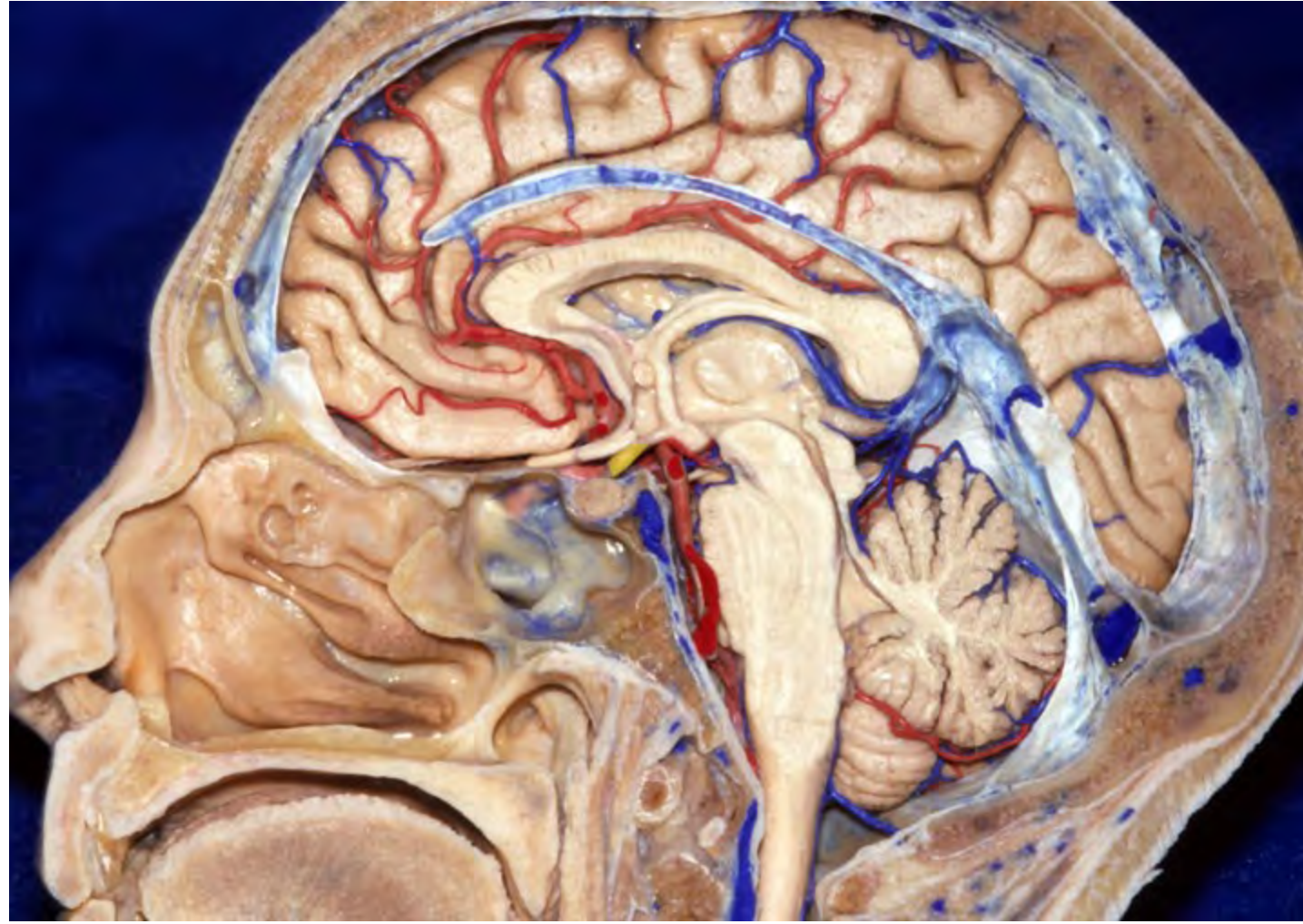
**Superior rectus**

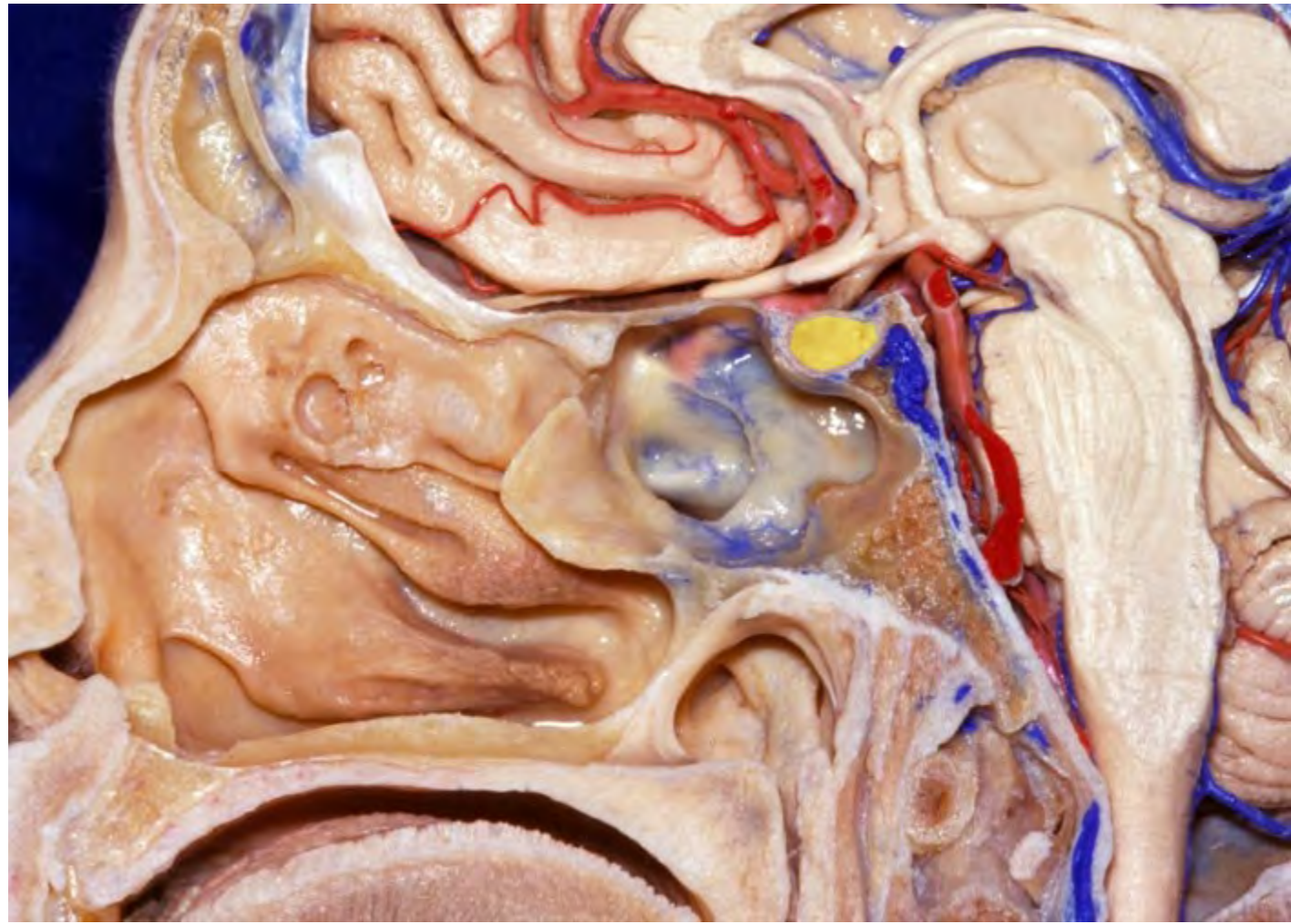


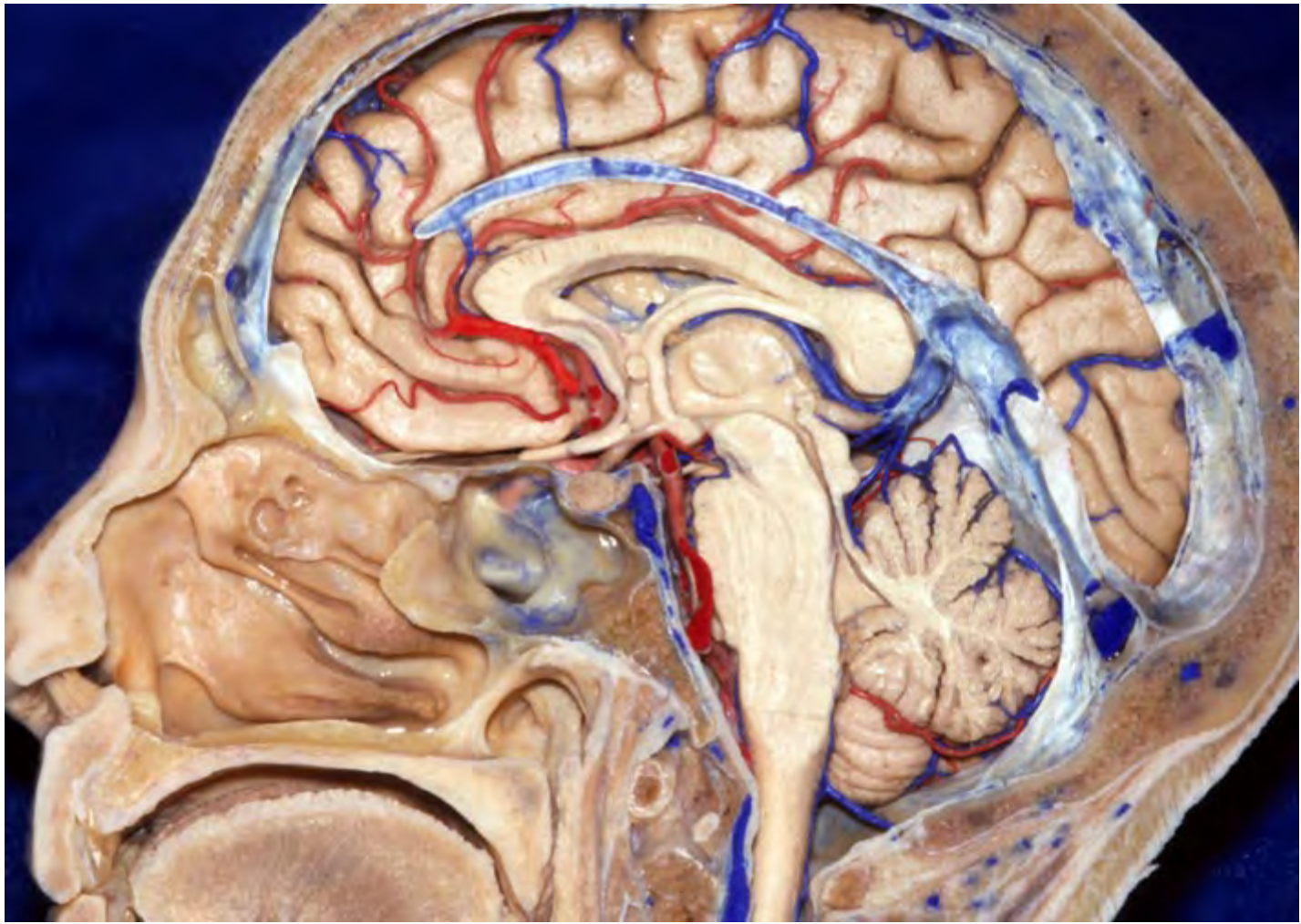
**Levator palpebrae superioris**

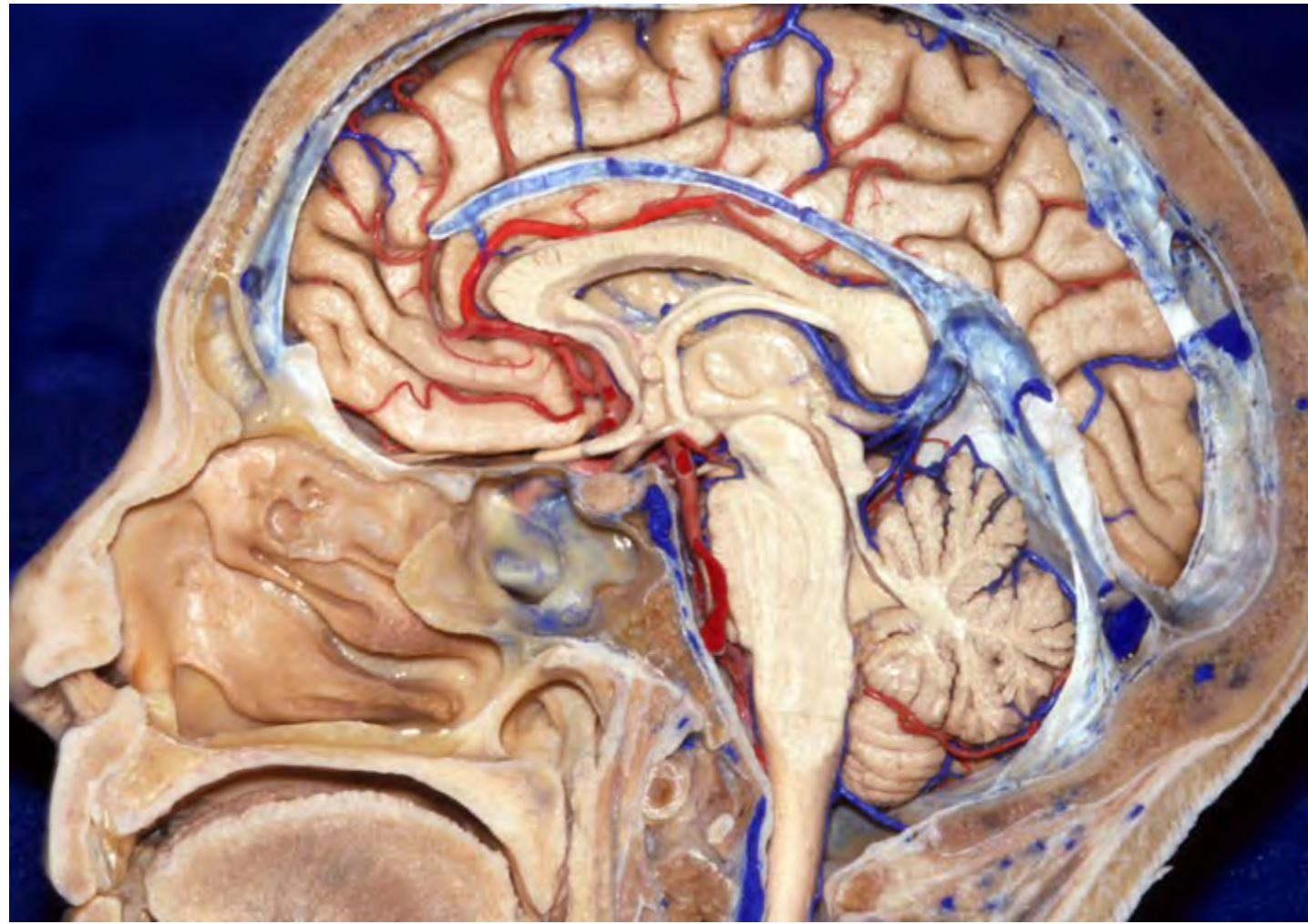




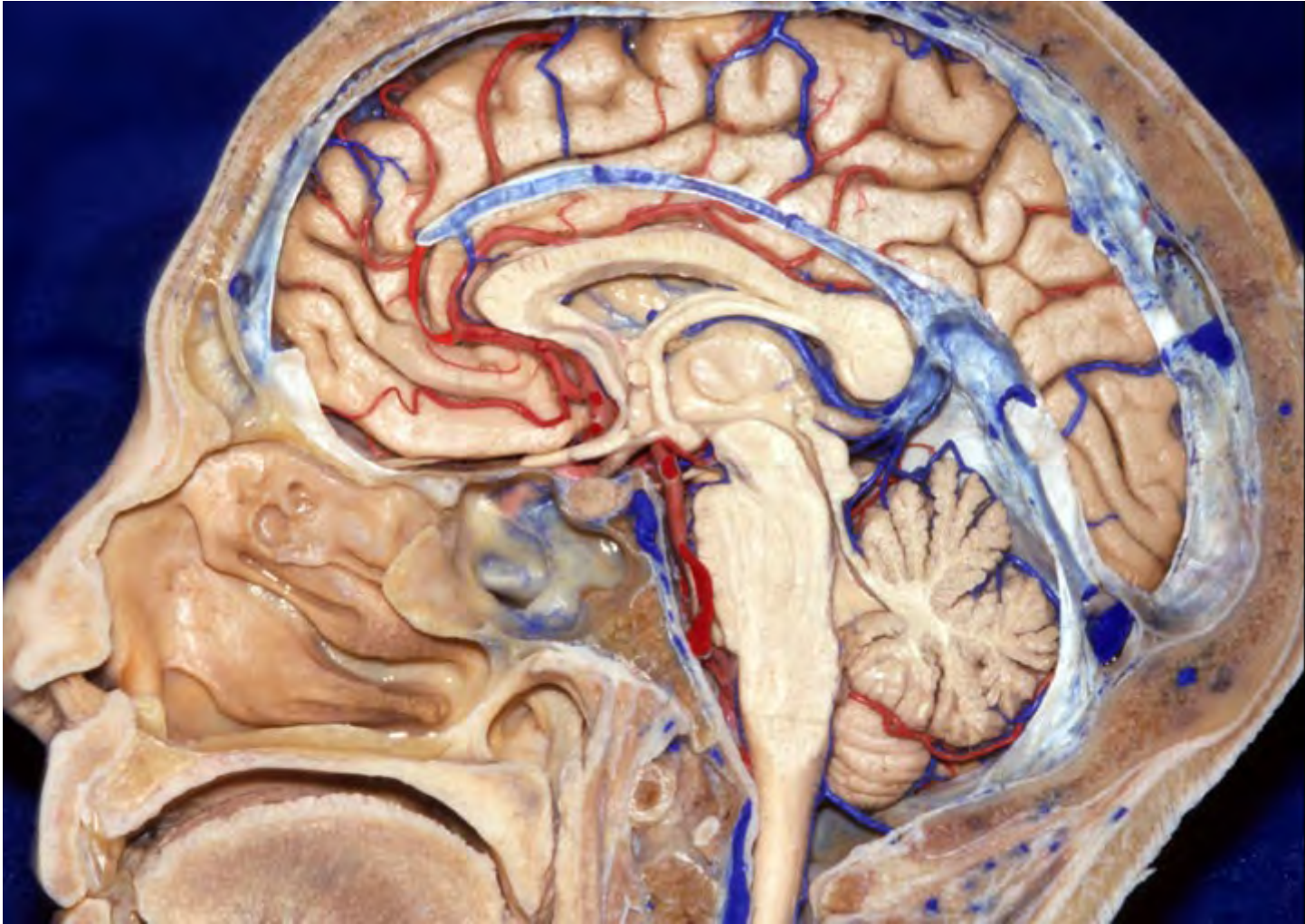

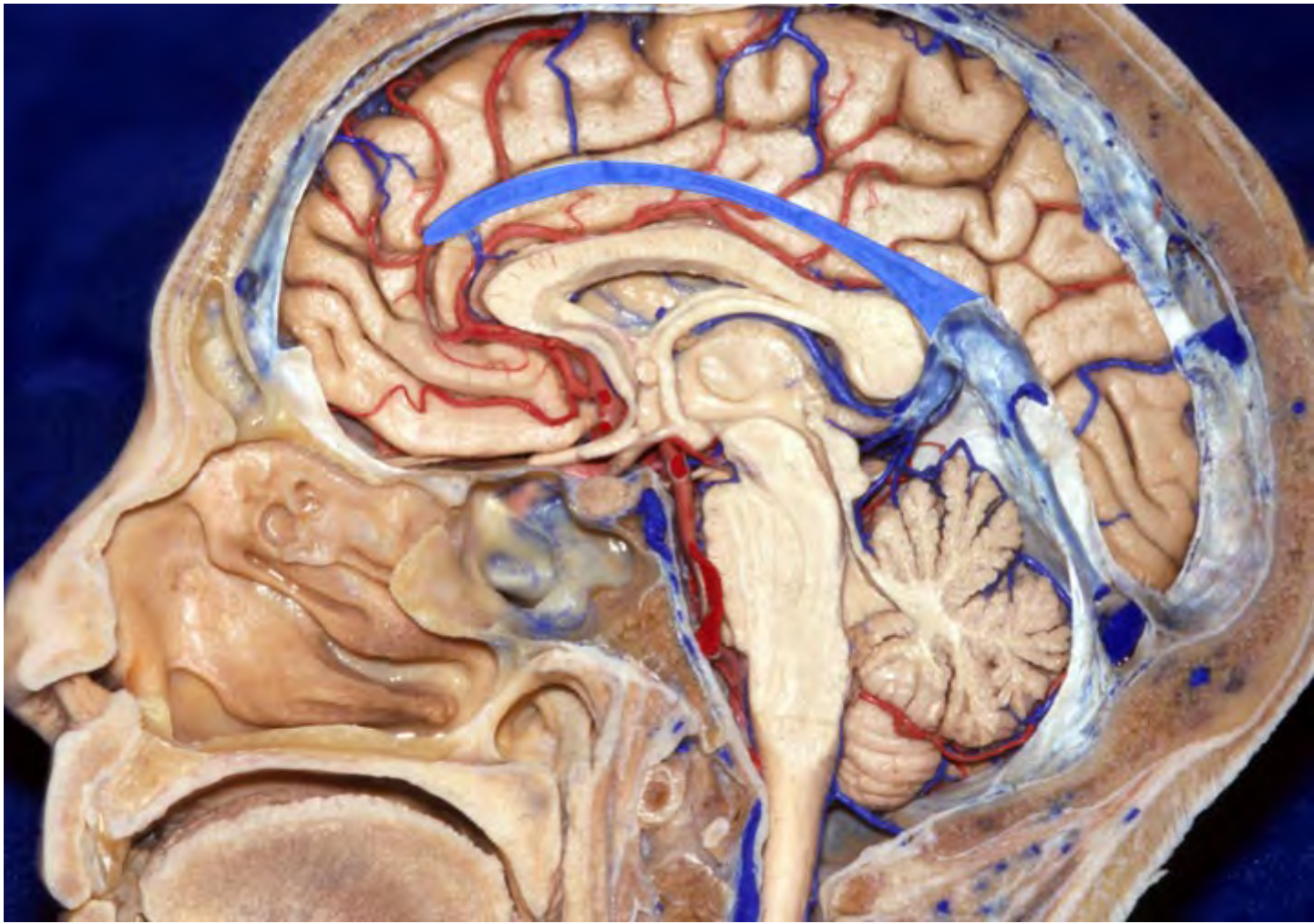



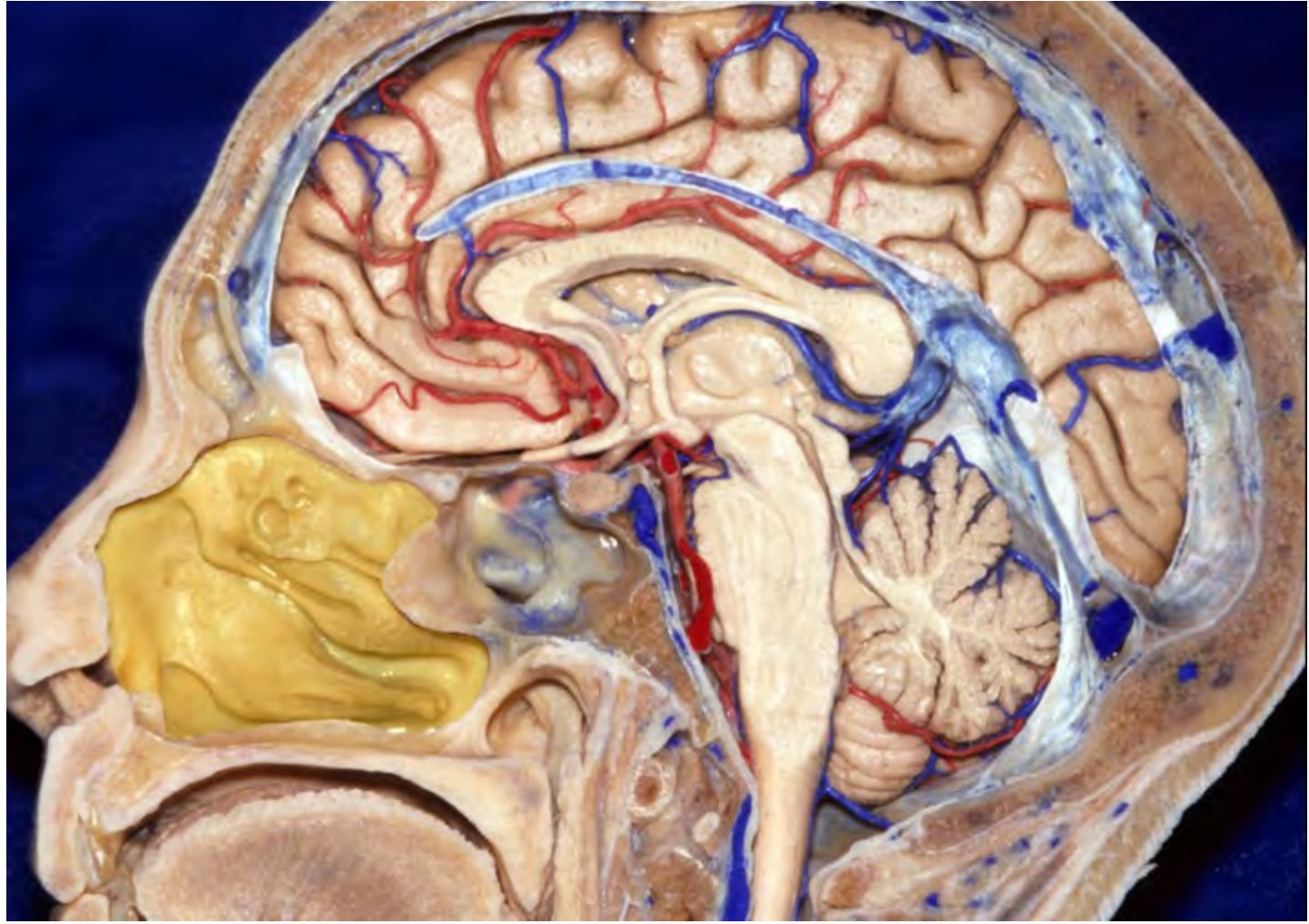


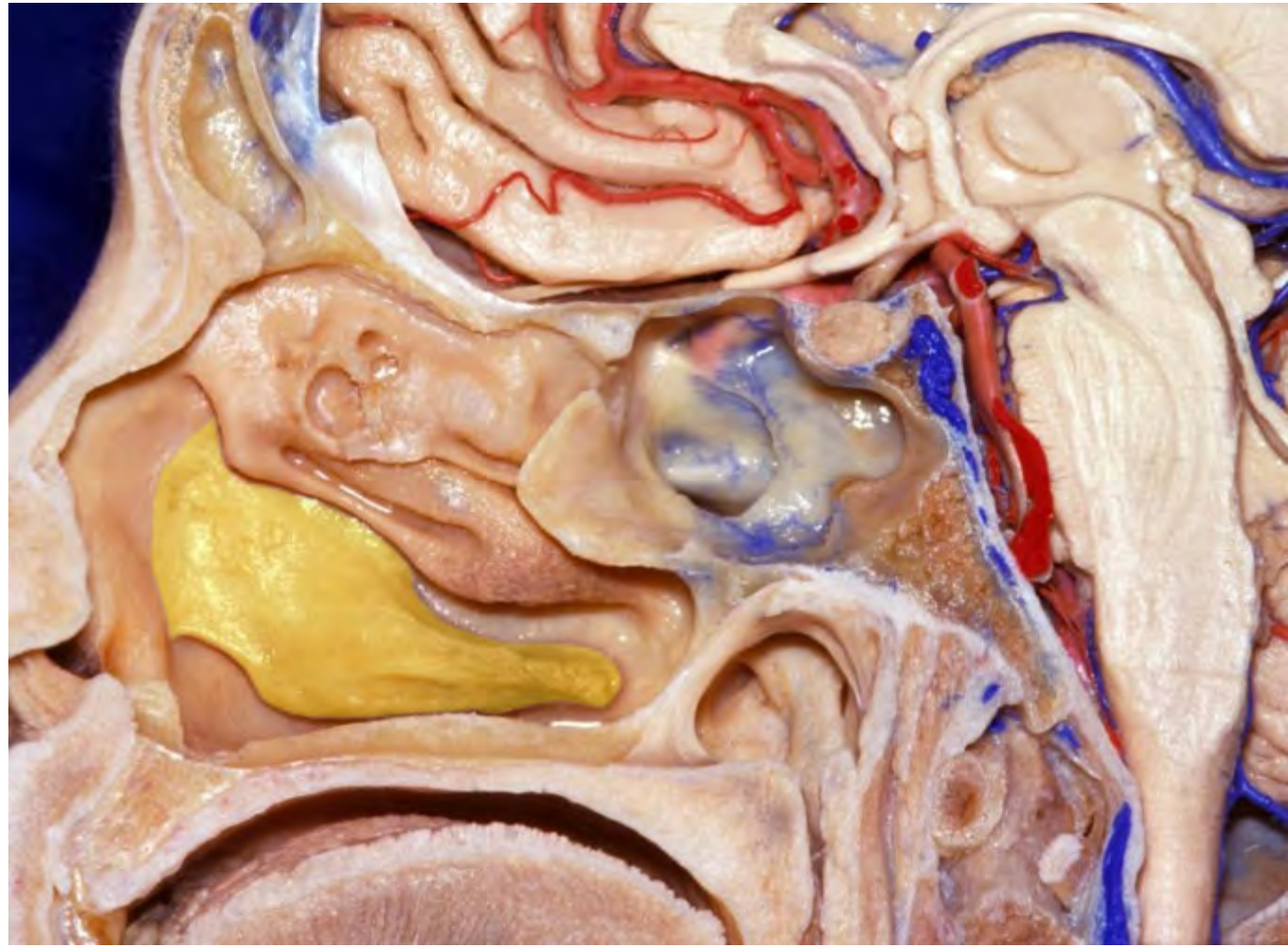


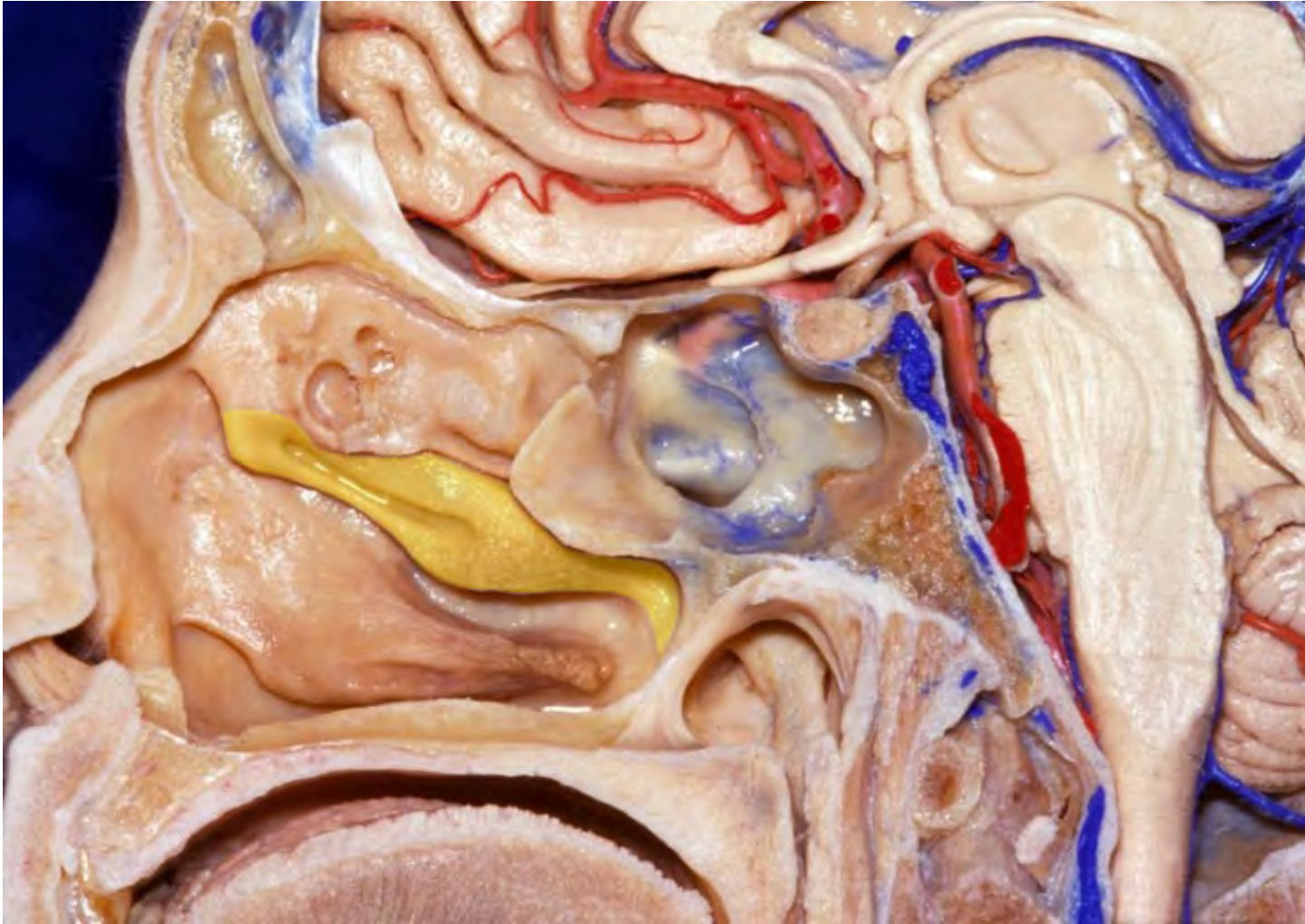
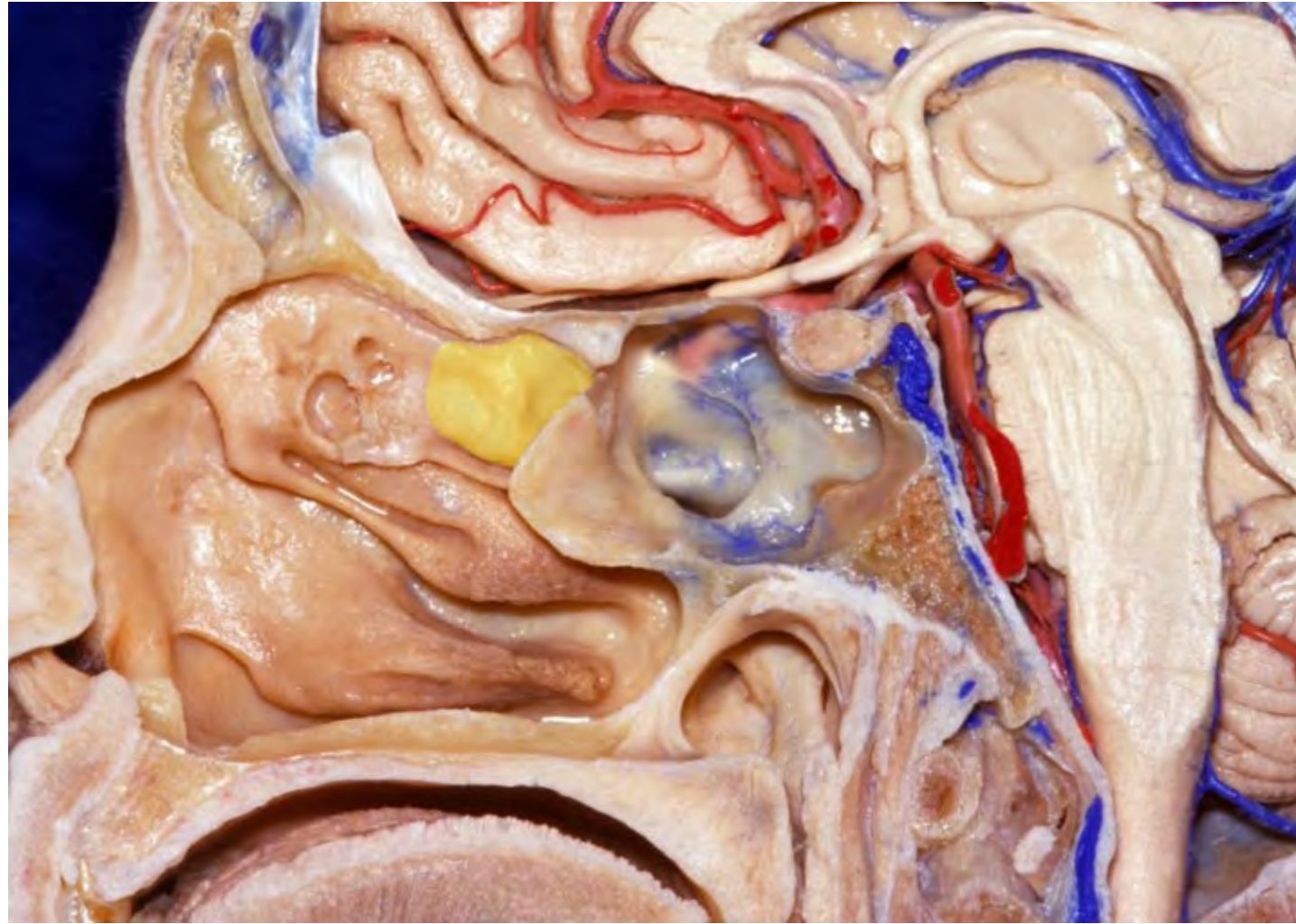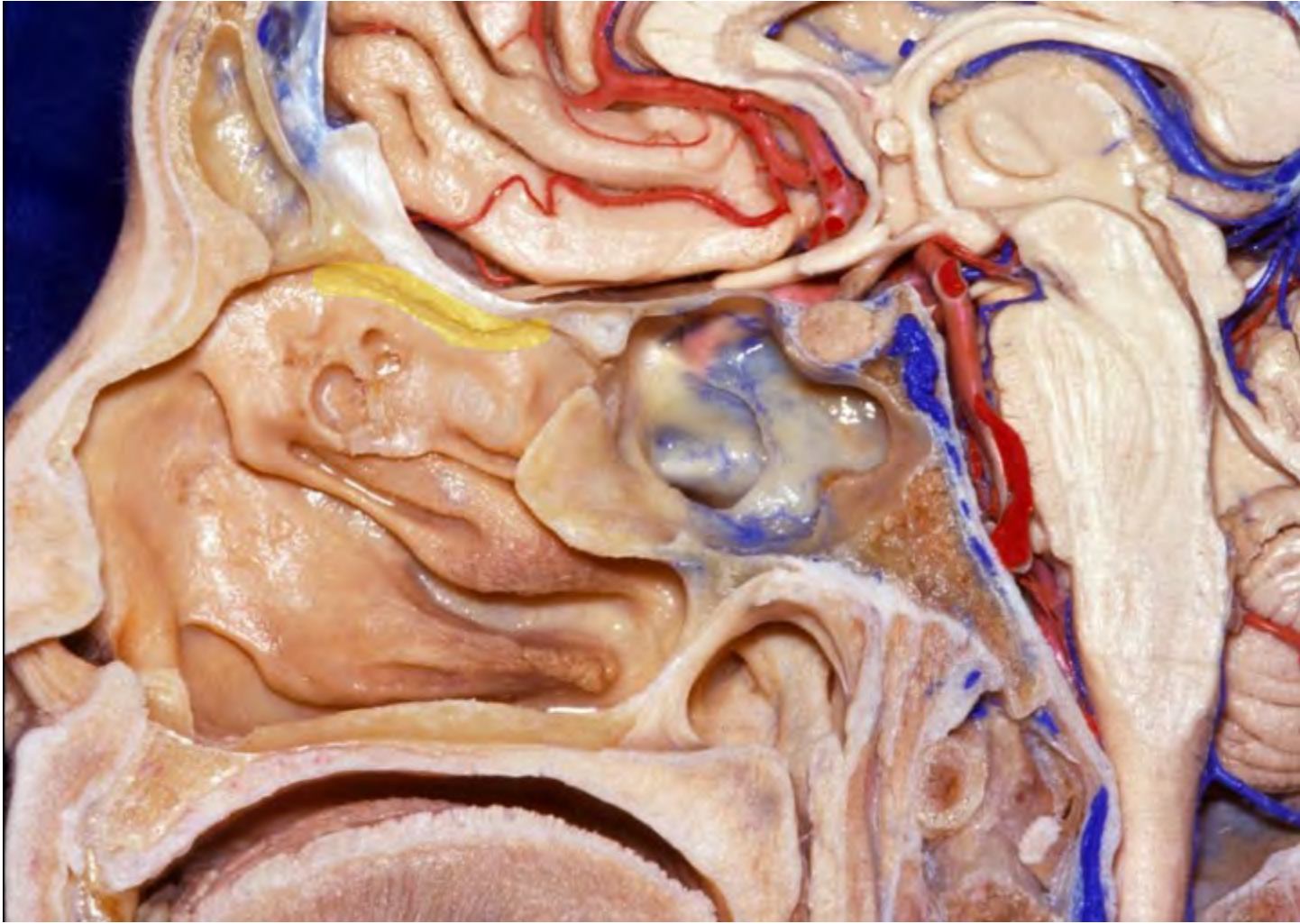







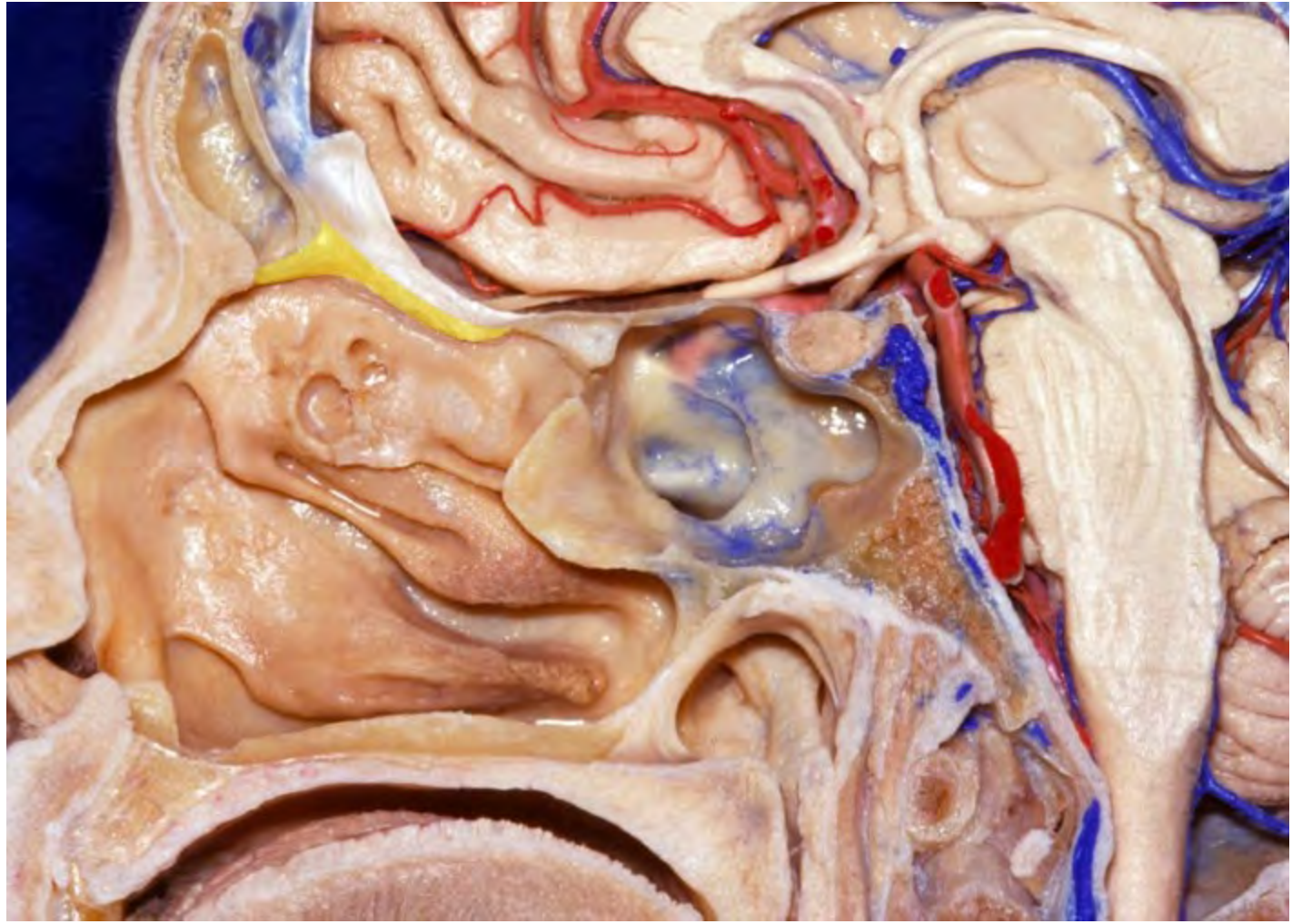




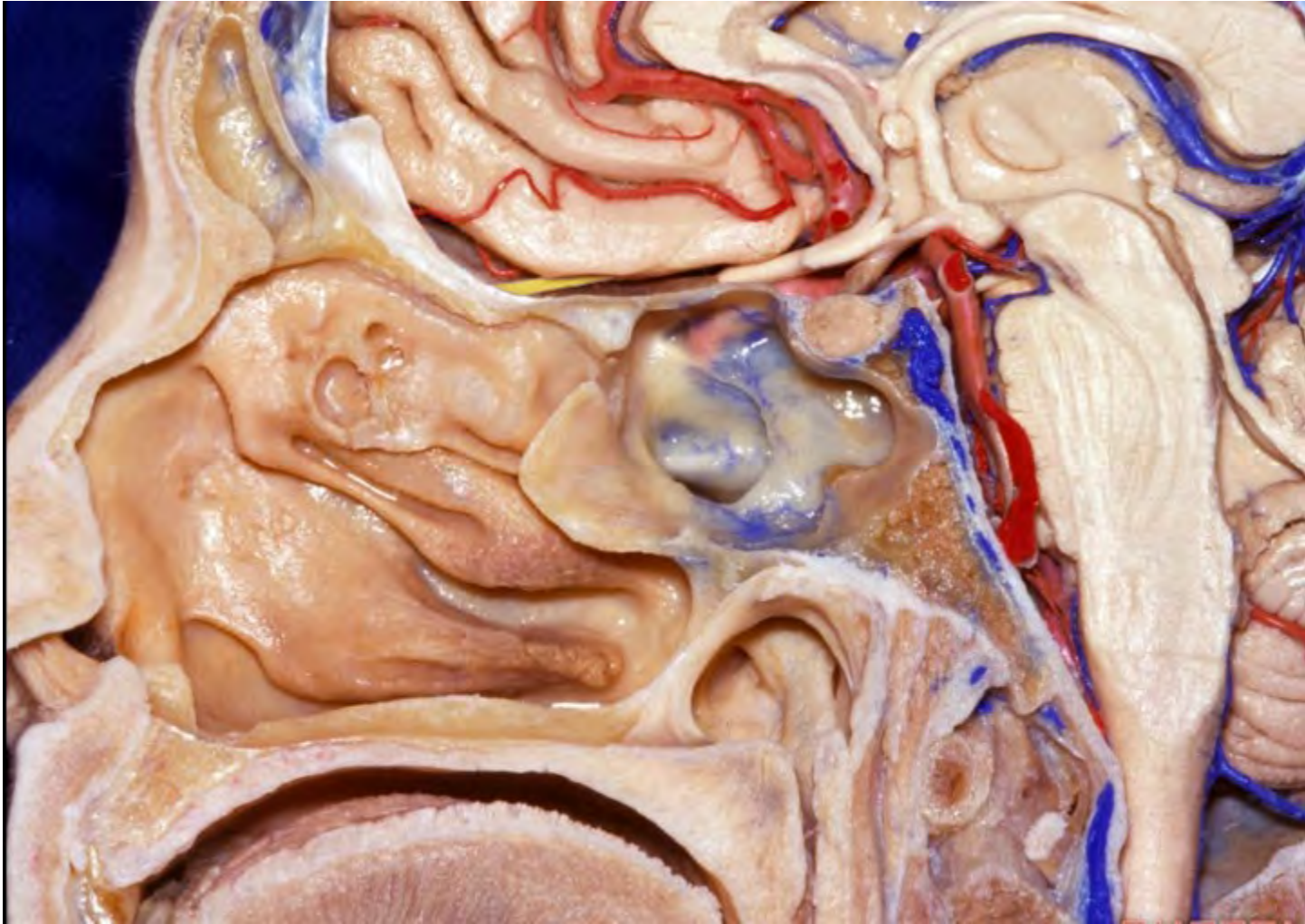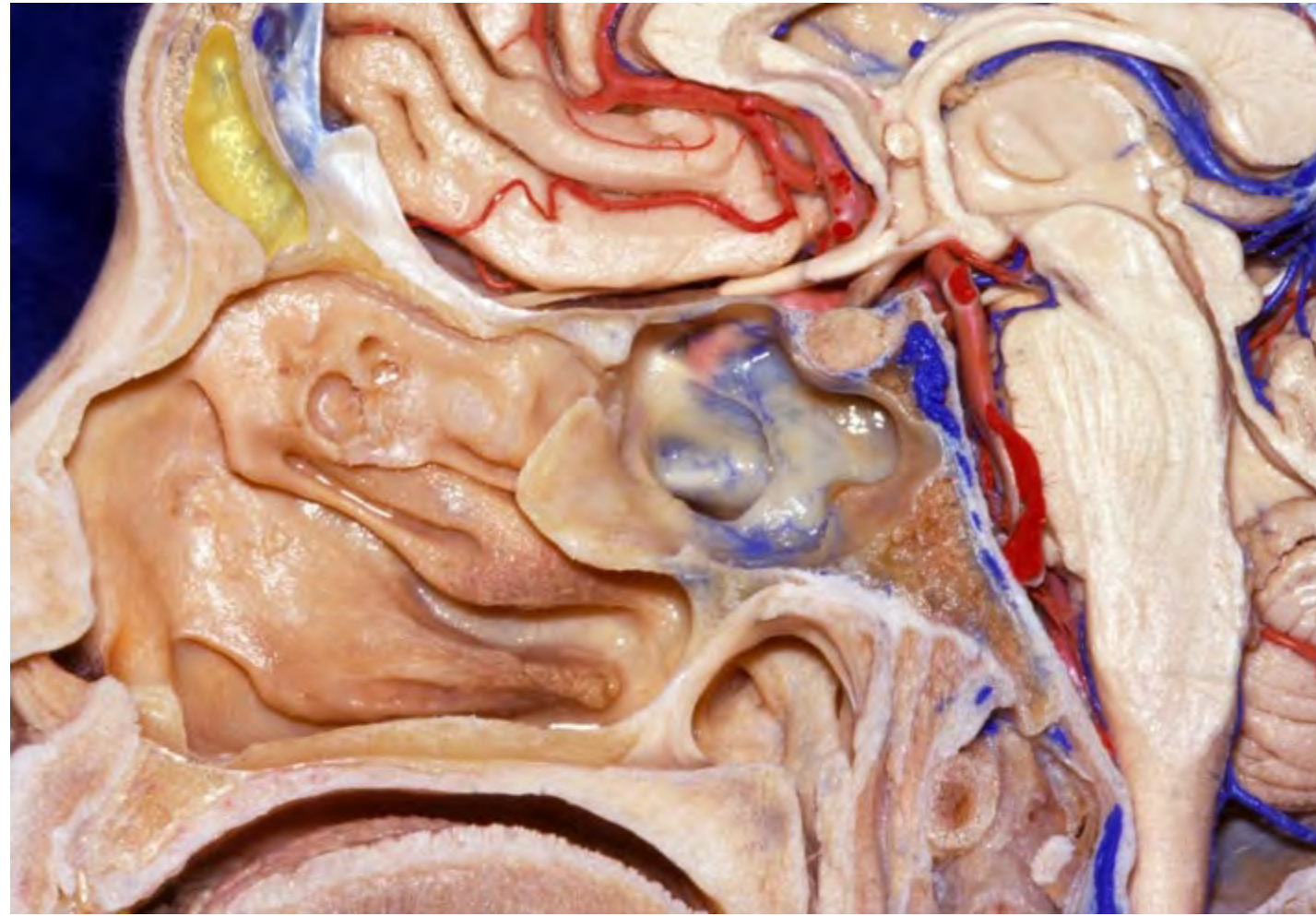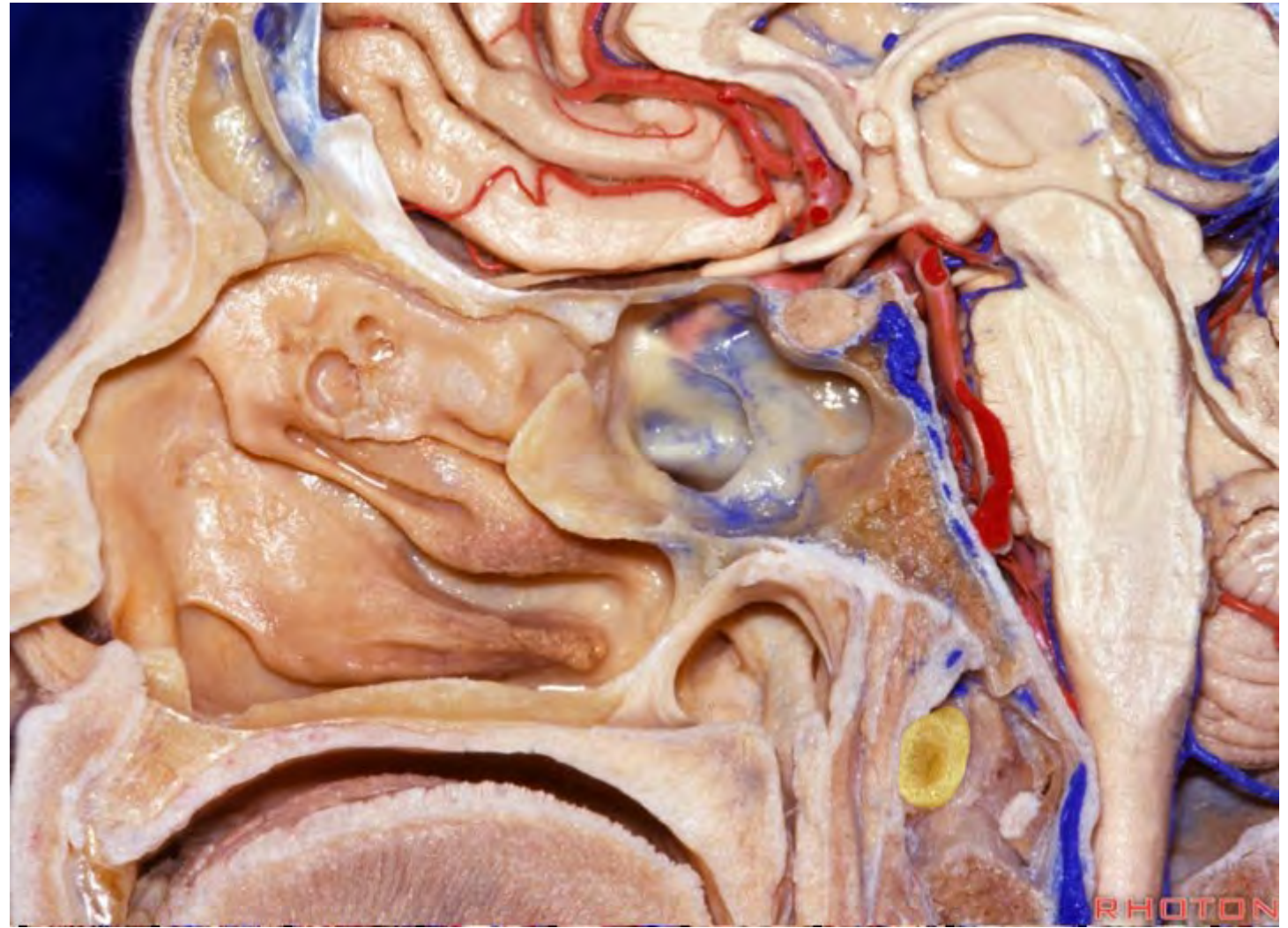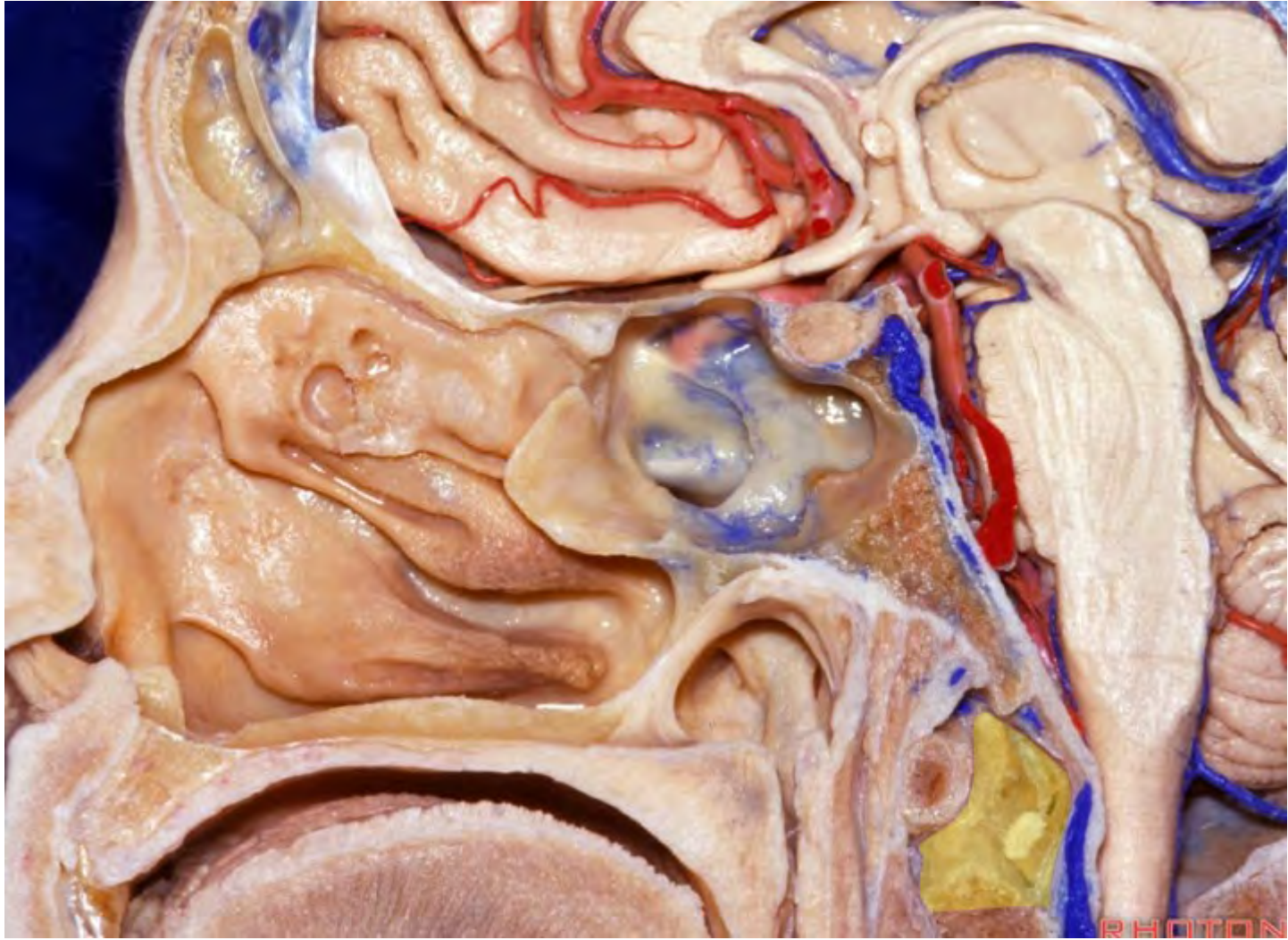


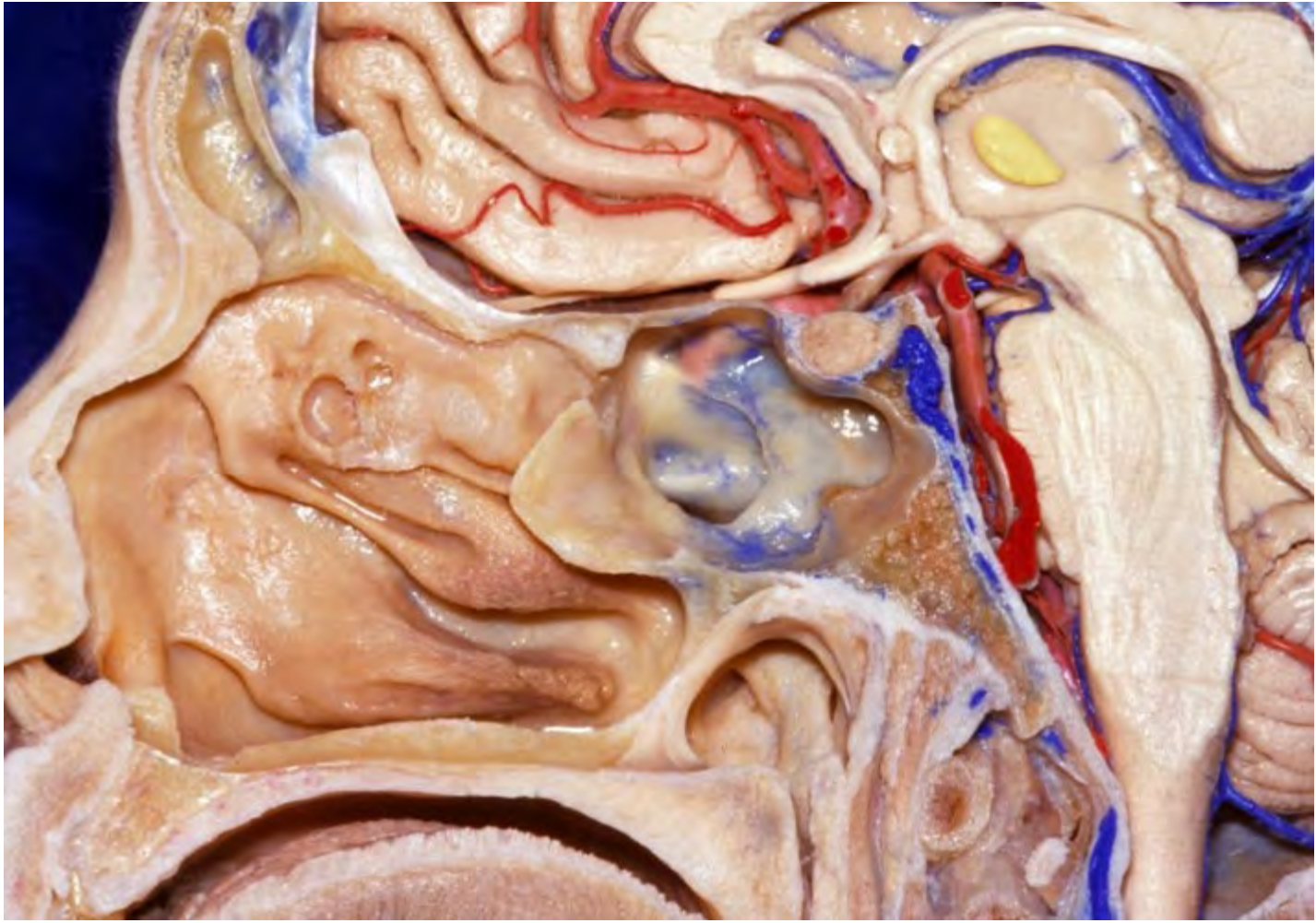


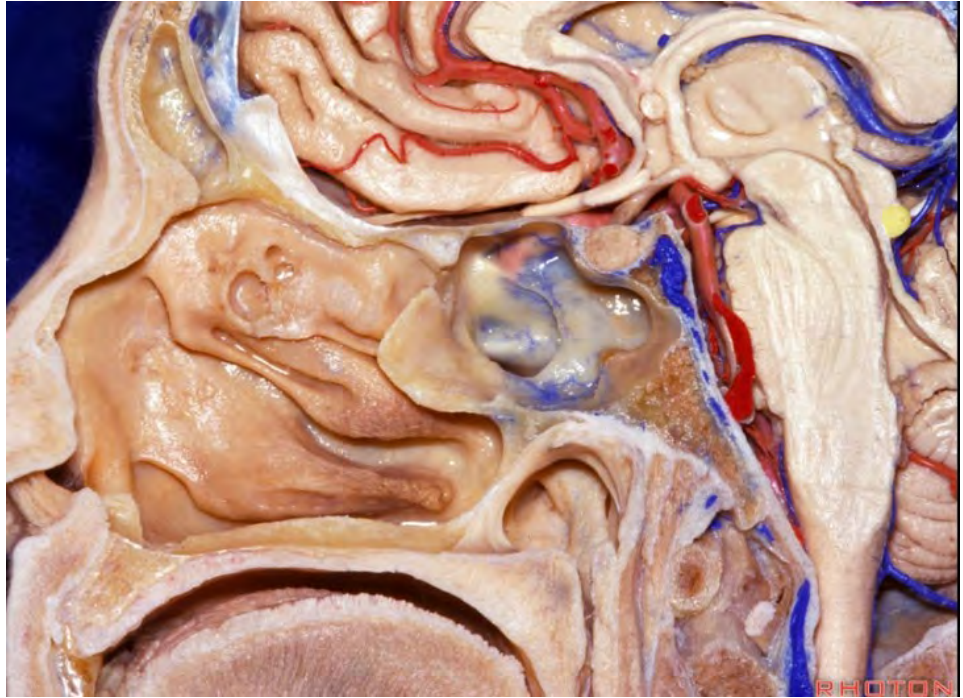




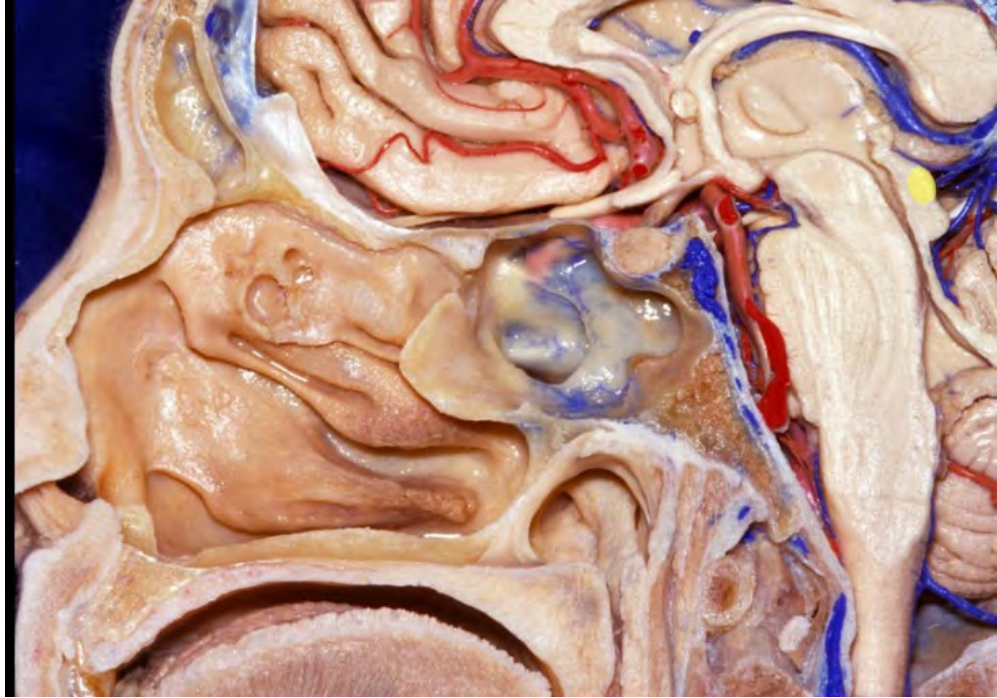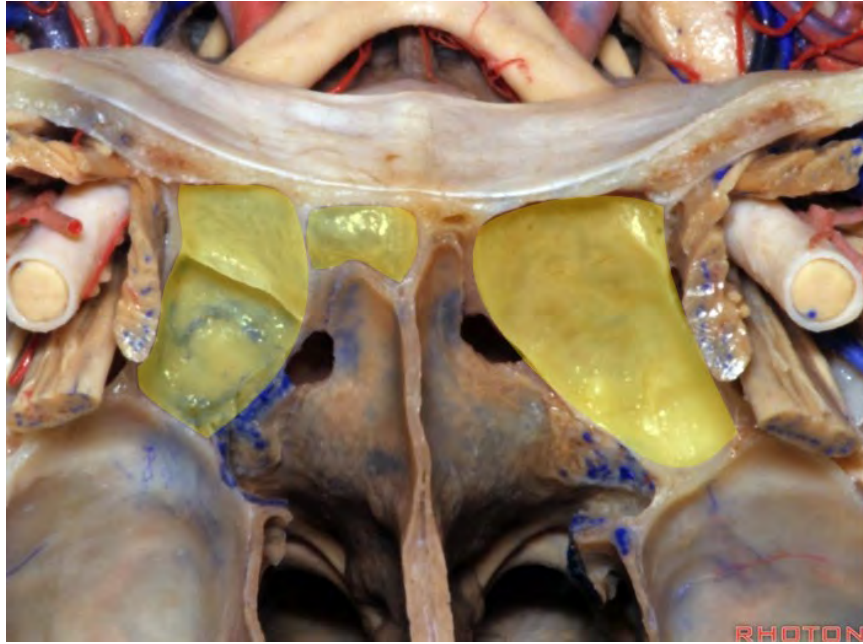




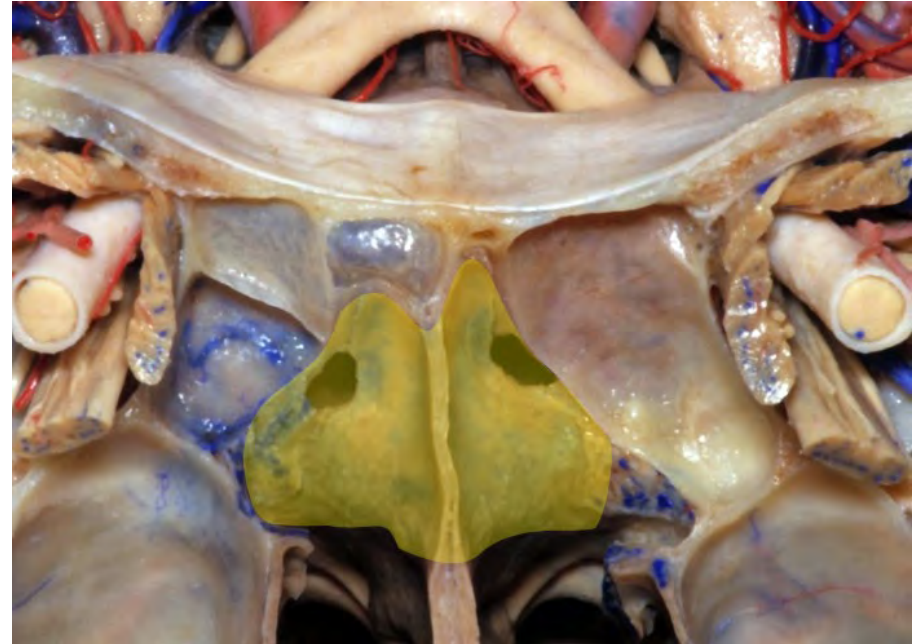




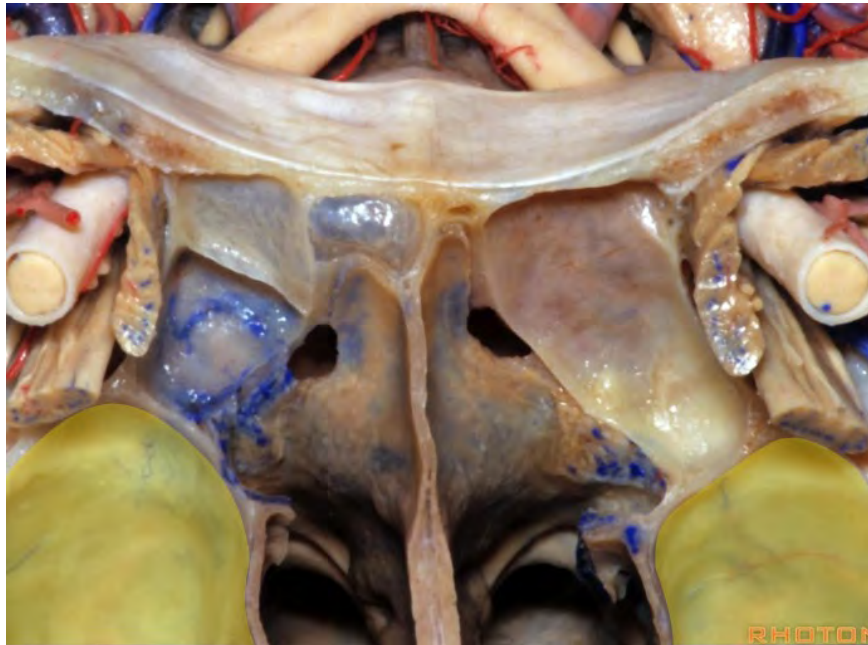
**Ethmoid sinus**



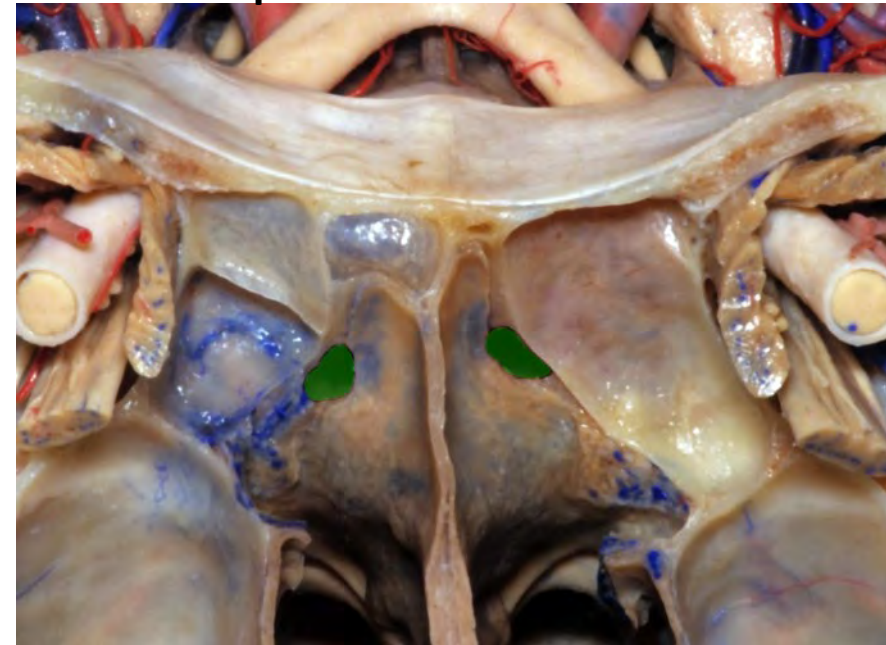
**Sphenoid sinus**

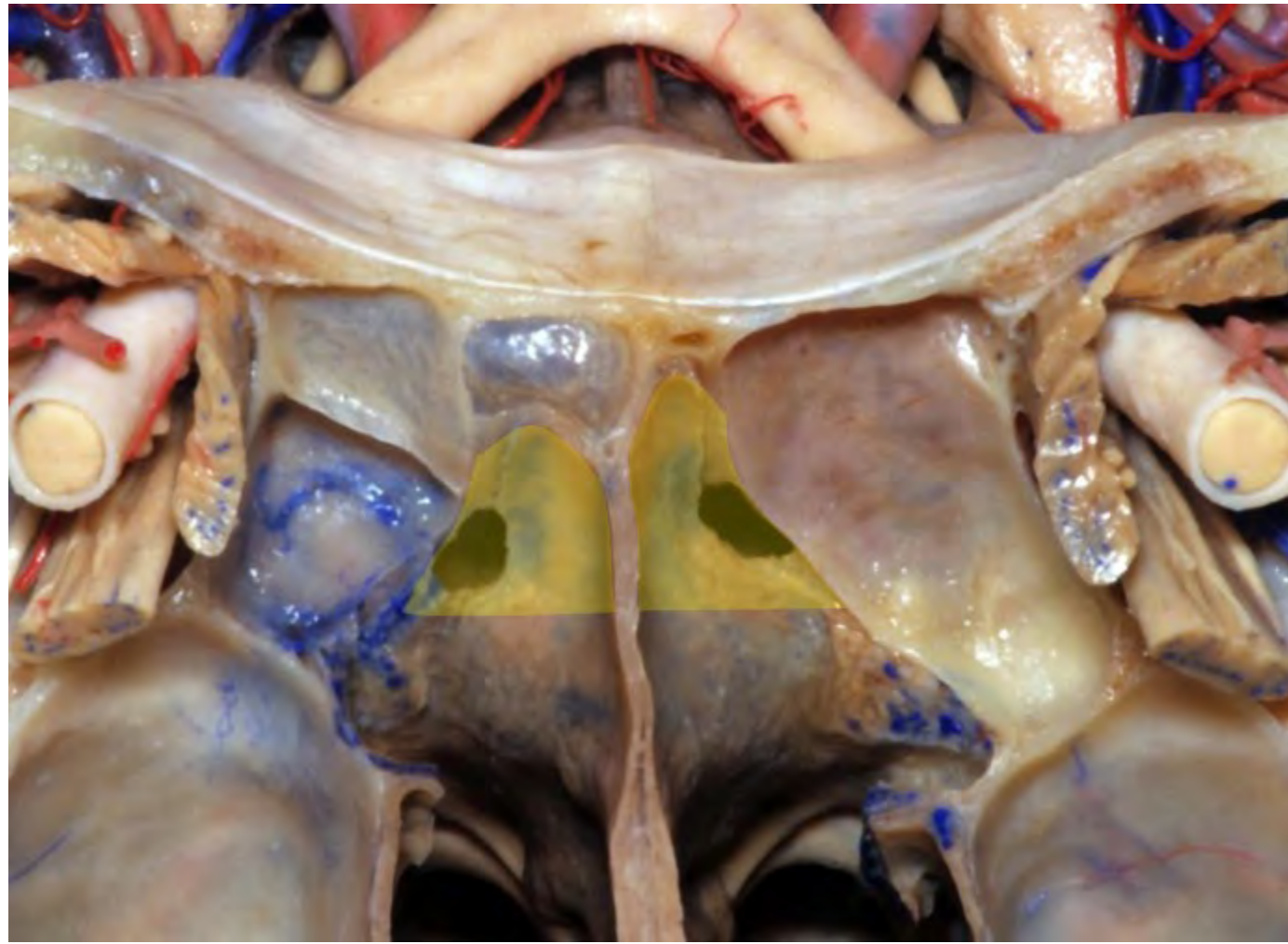


**Maxillary sinus**

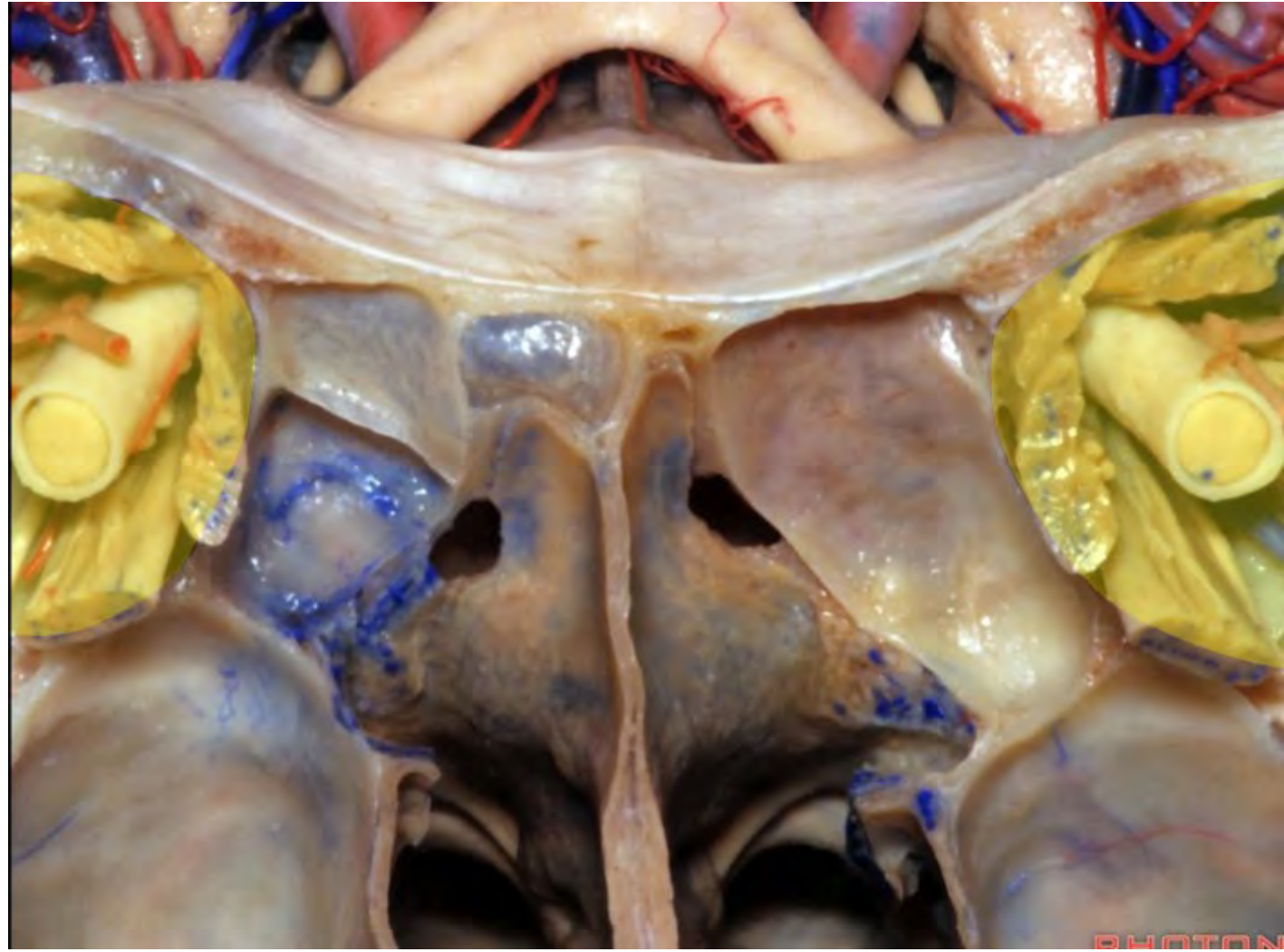


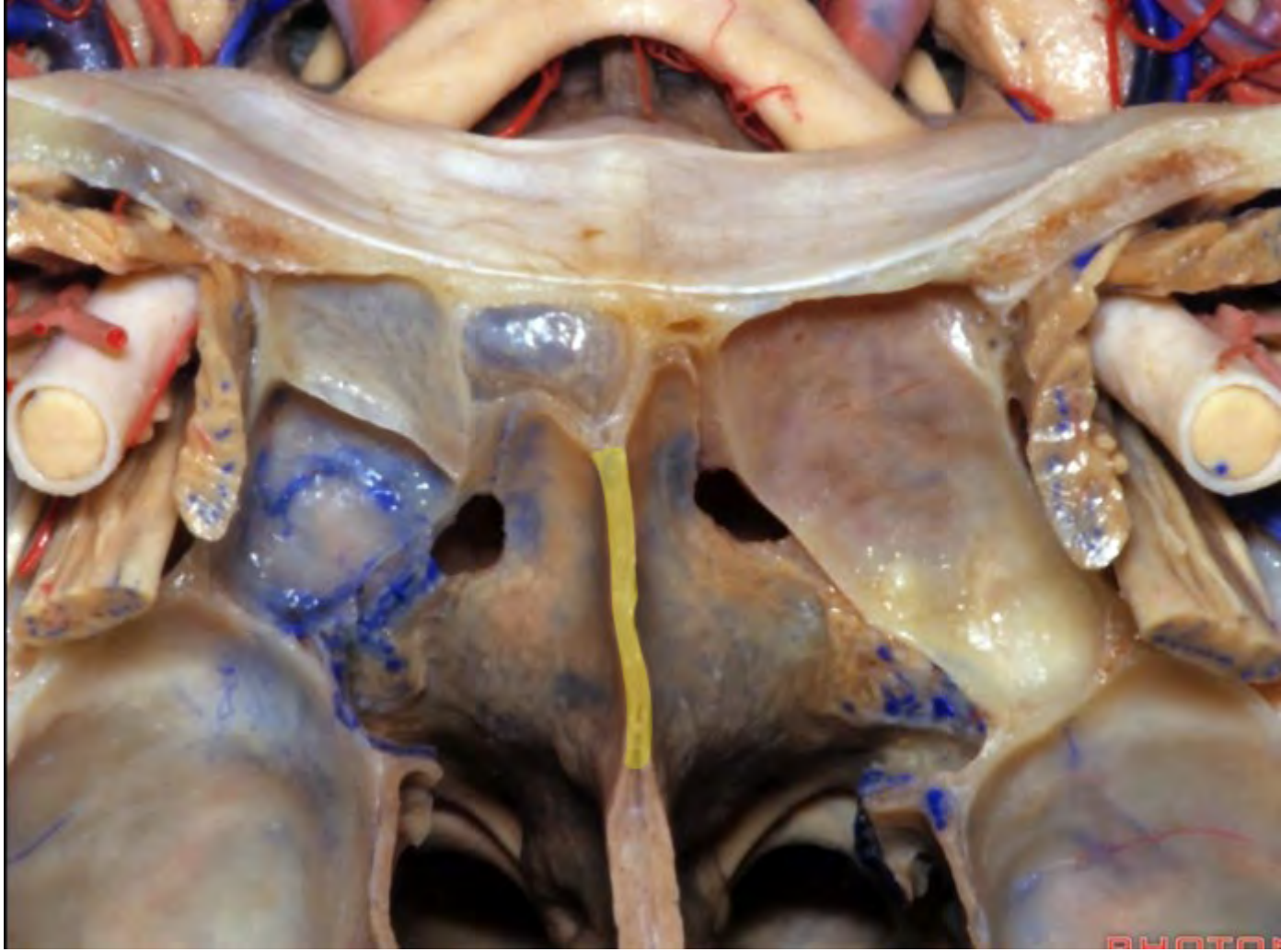
**Sphenoid sinus ostium**

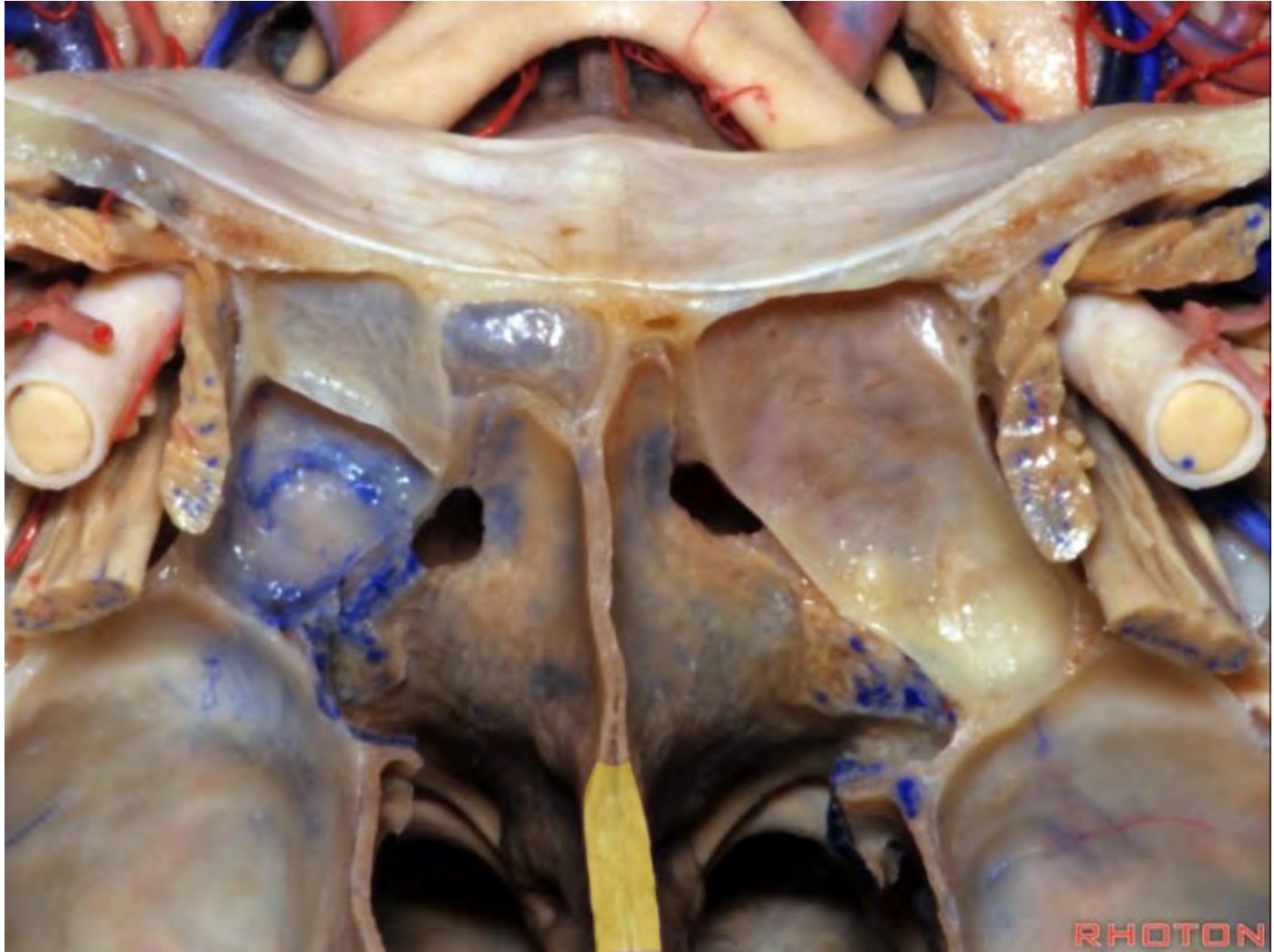


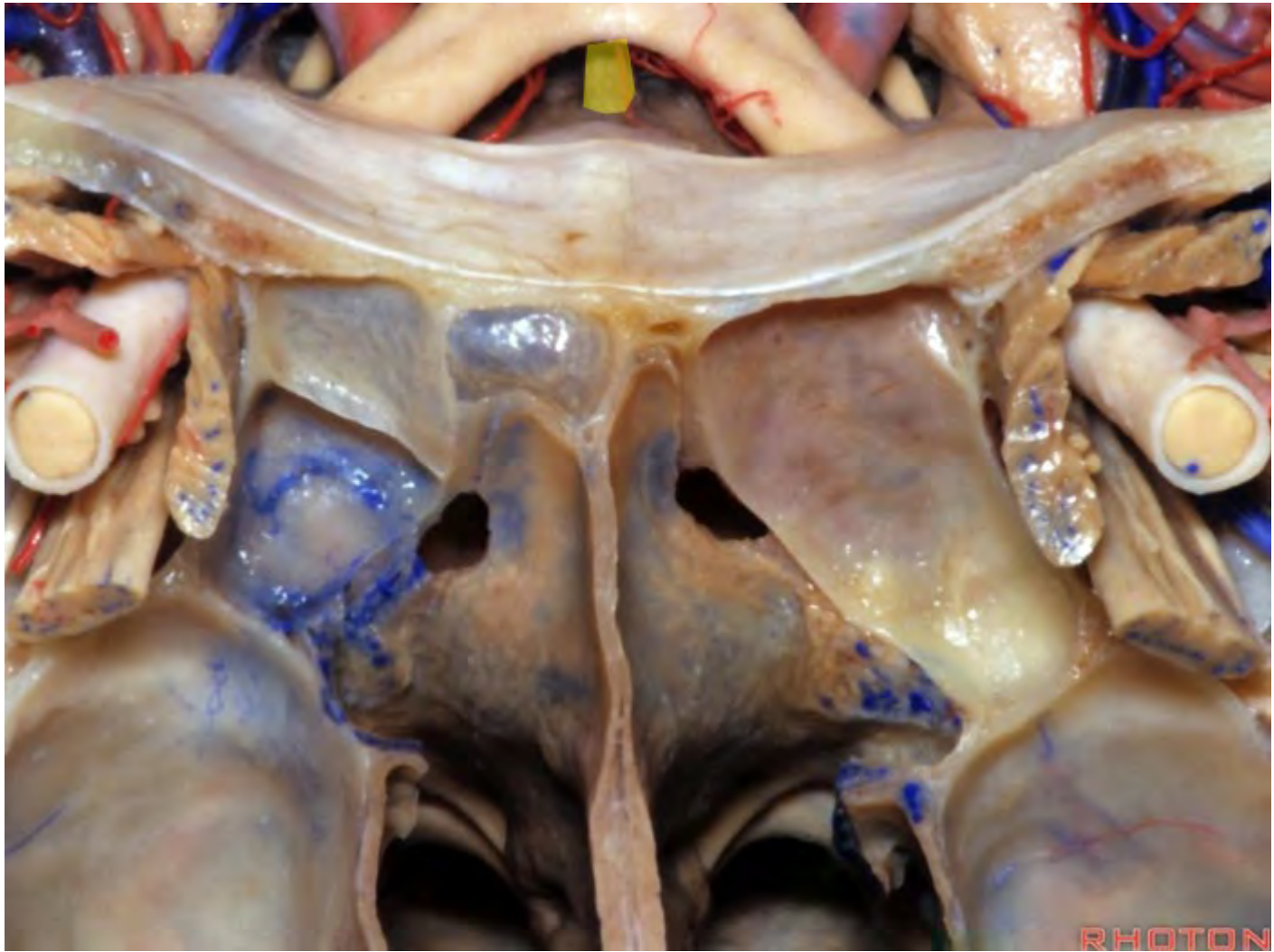




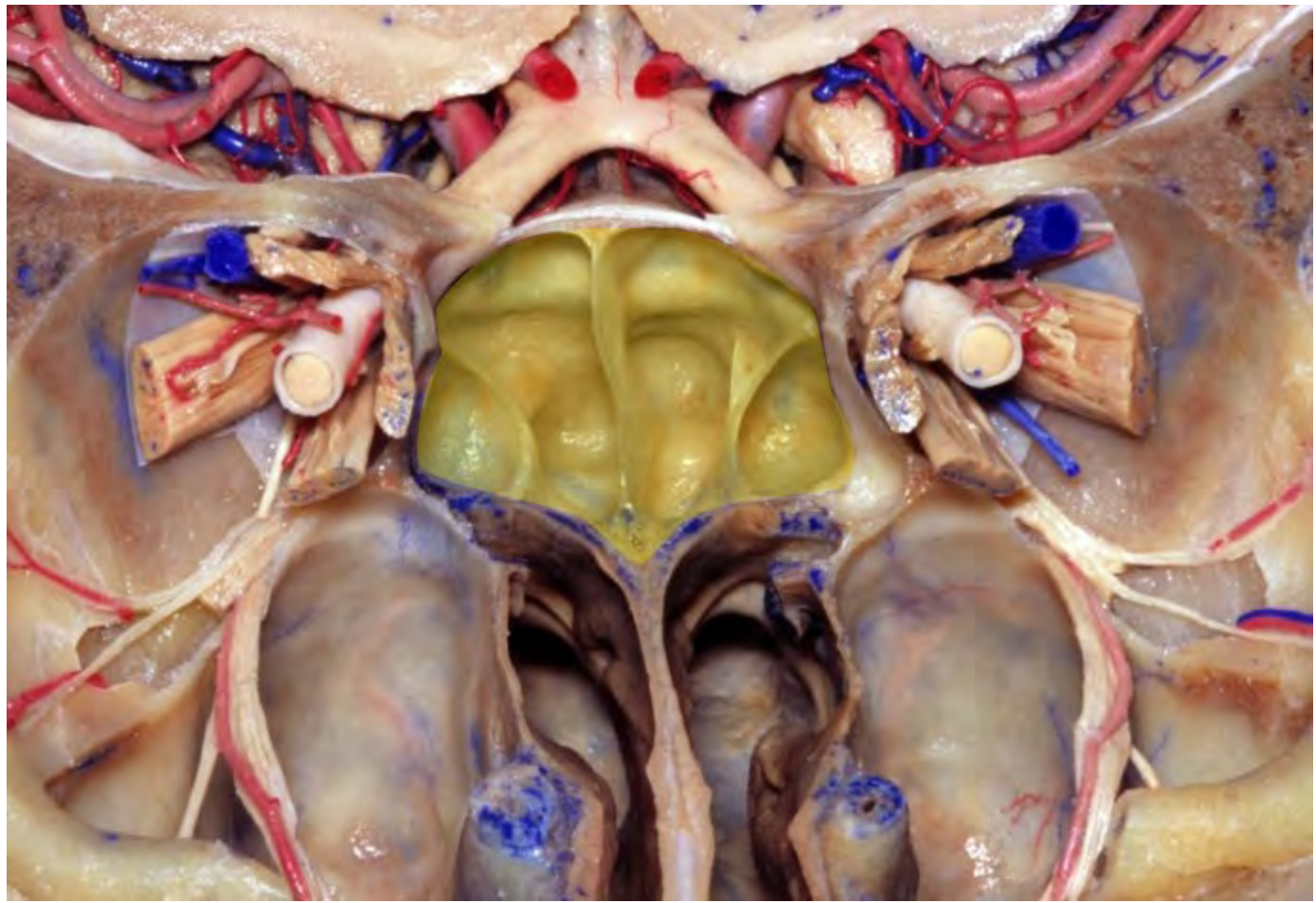


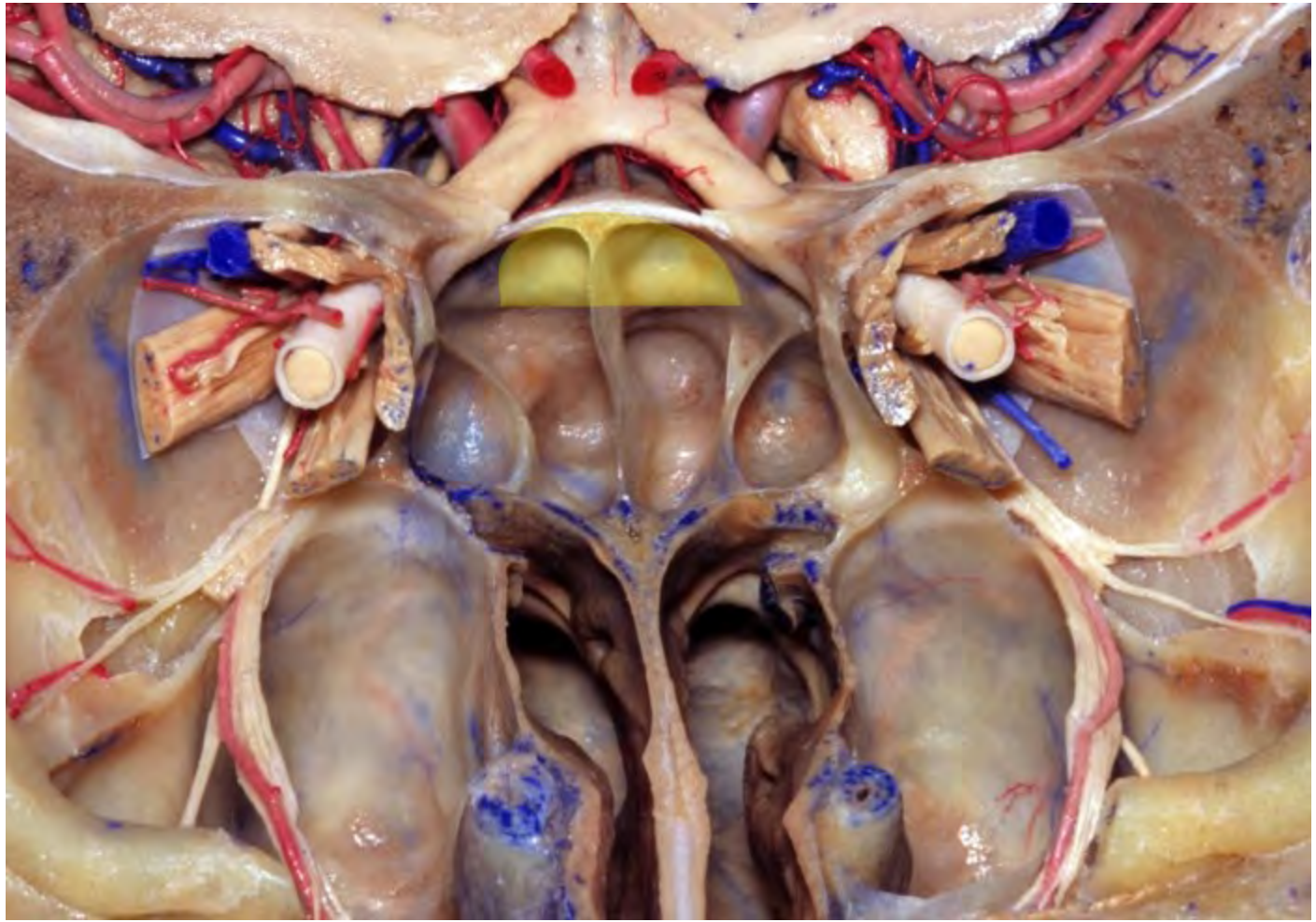


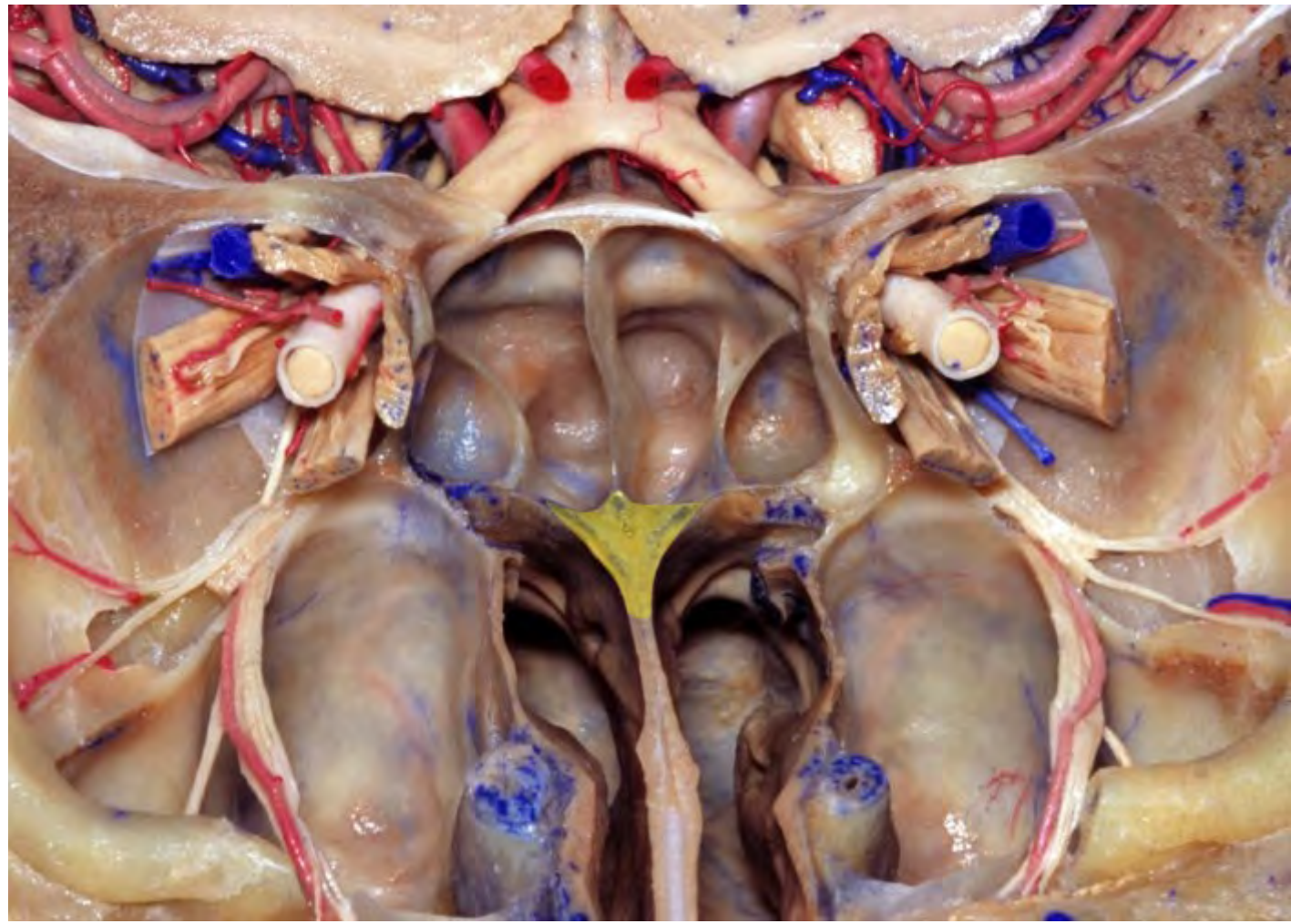






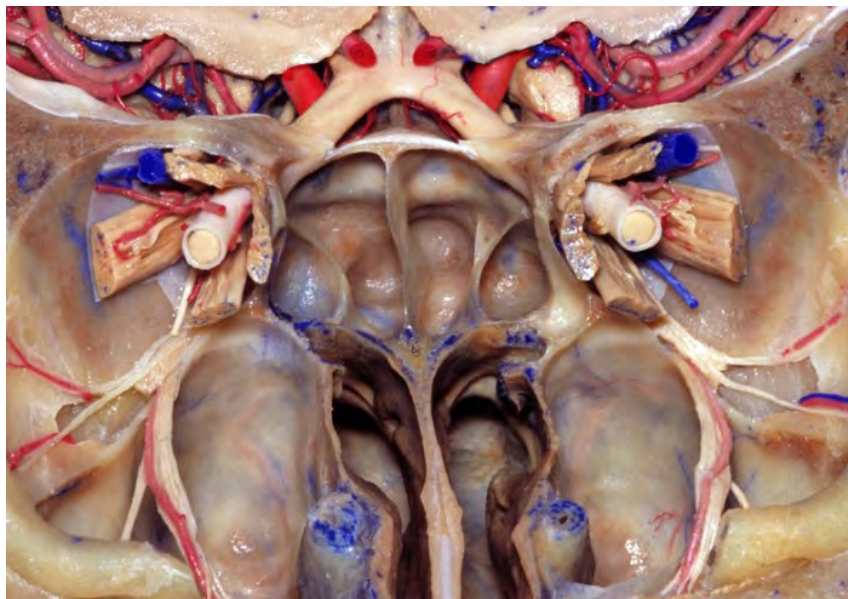



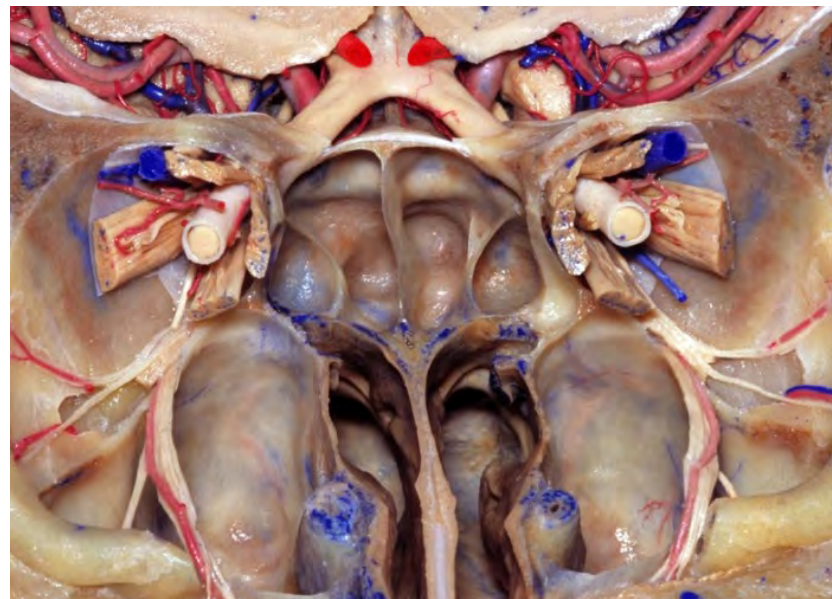


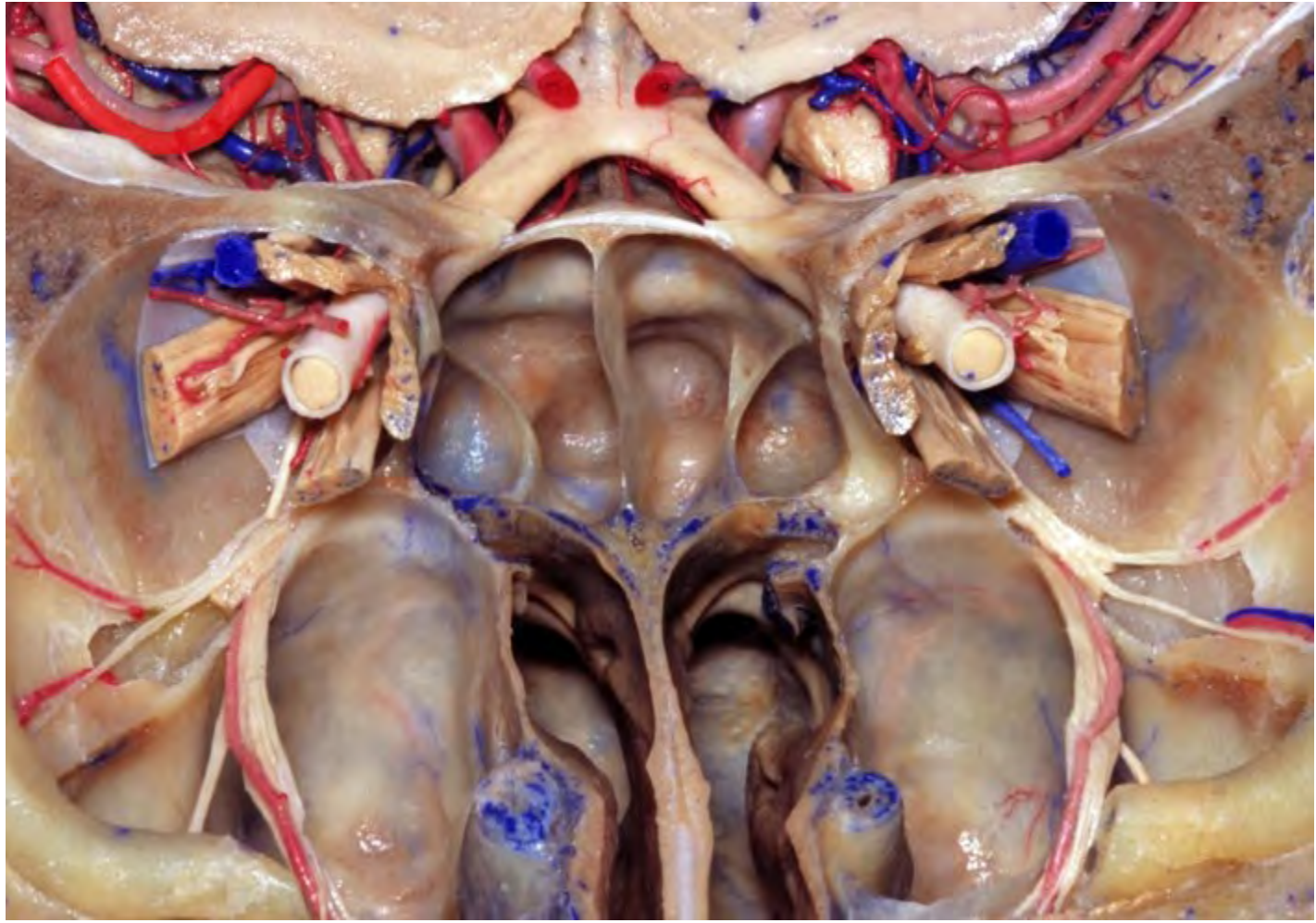


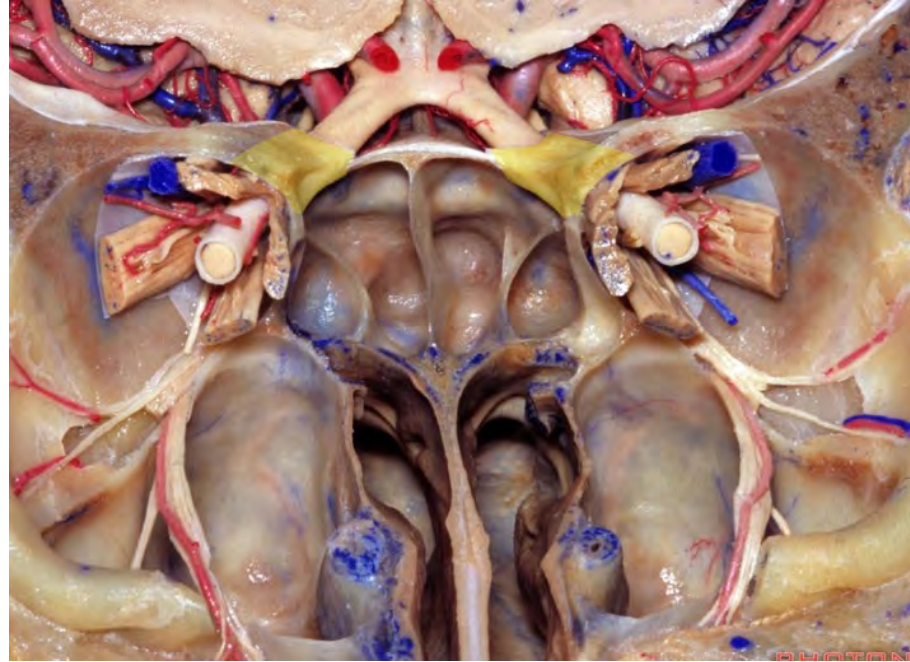
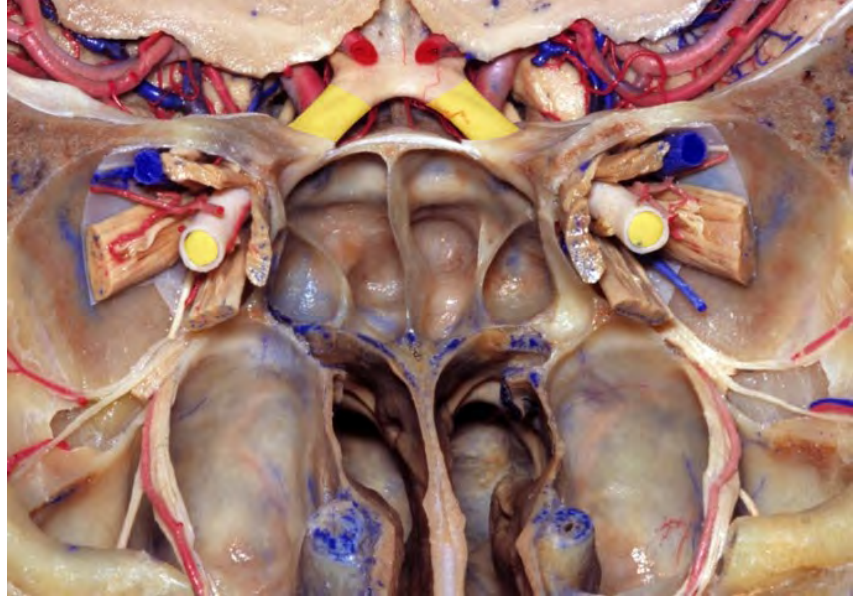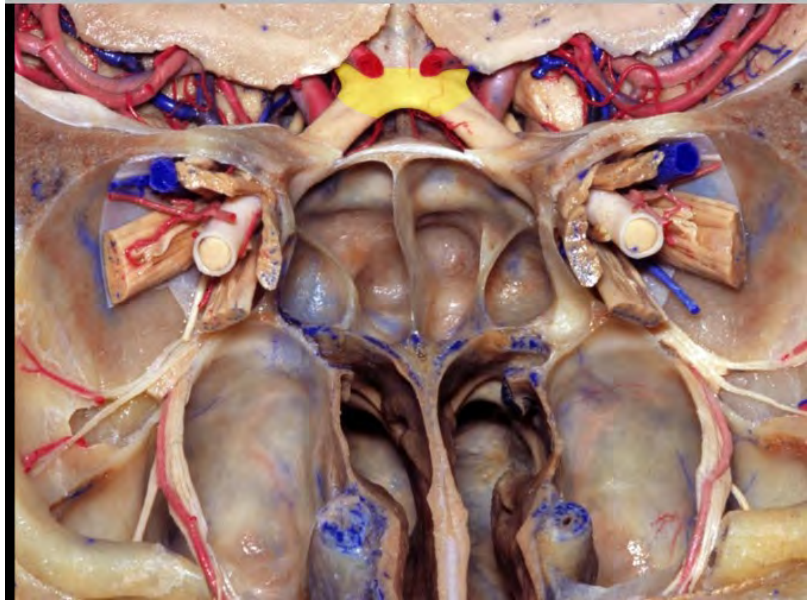
**Internal carotid artery**

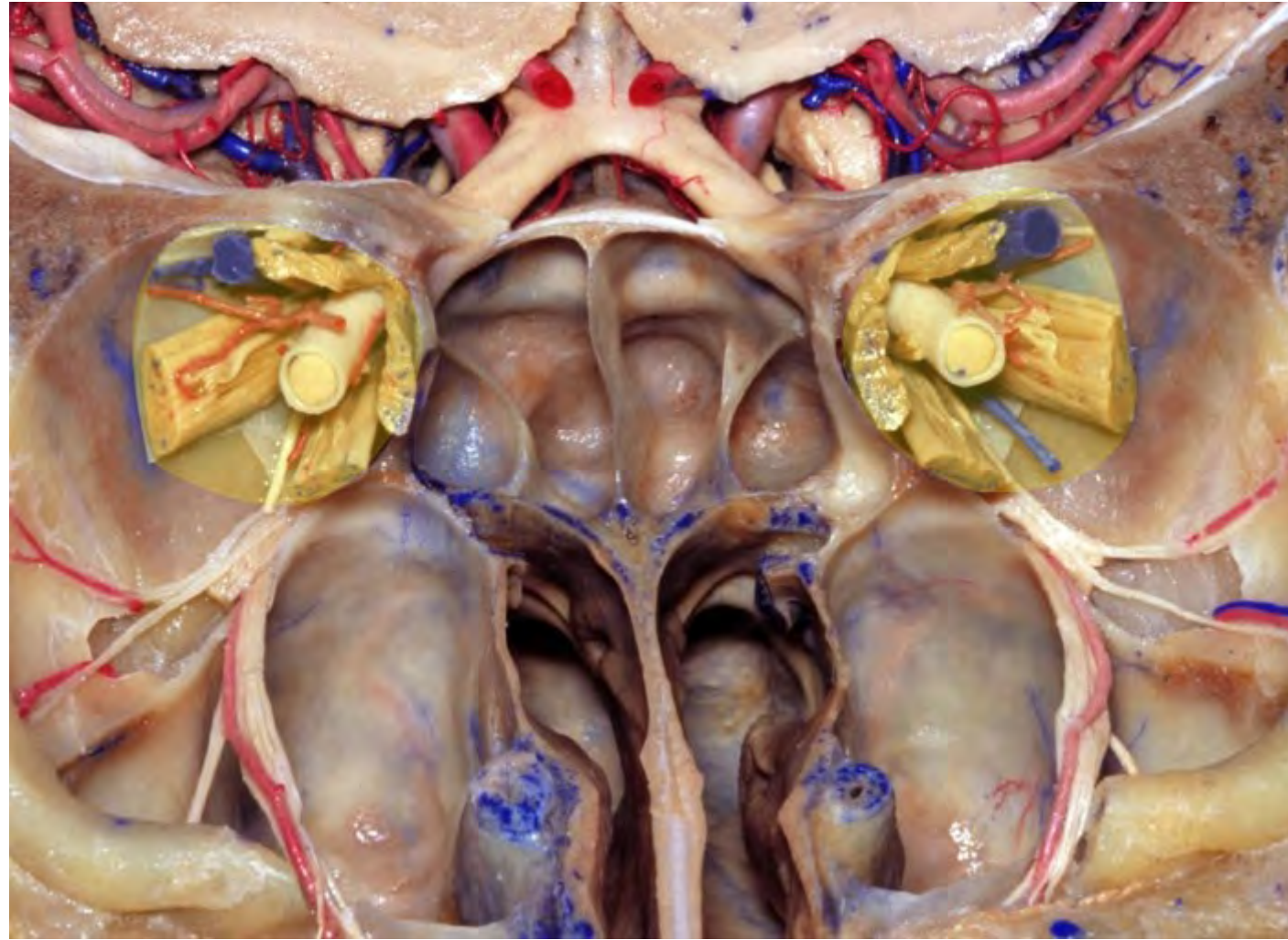


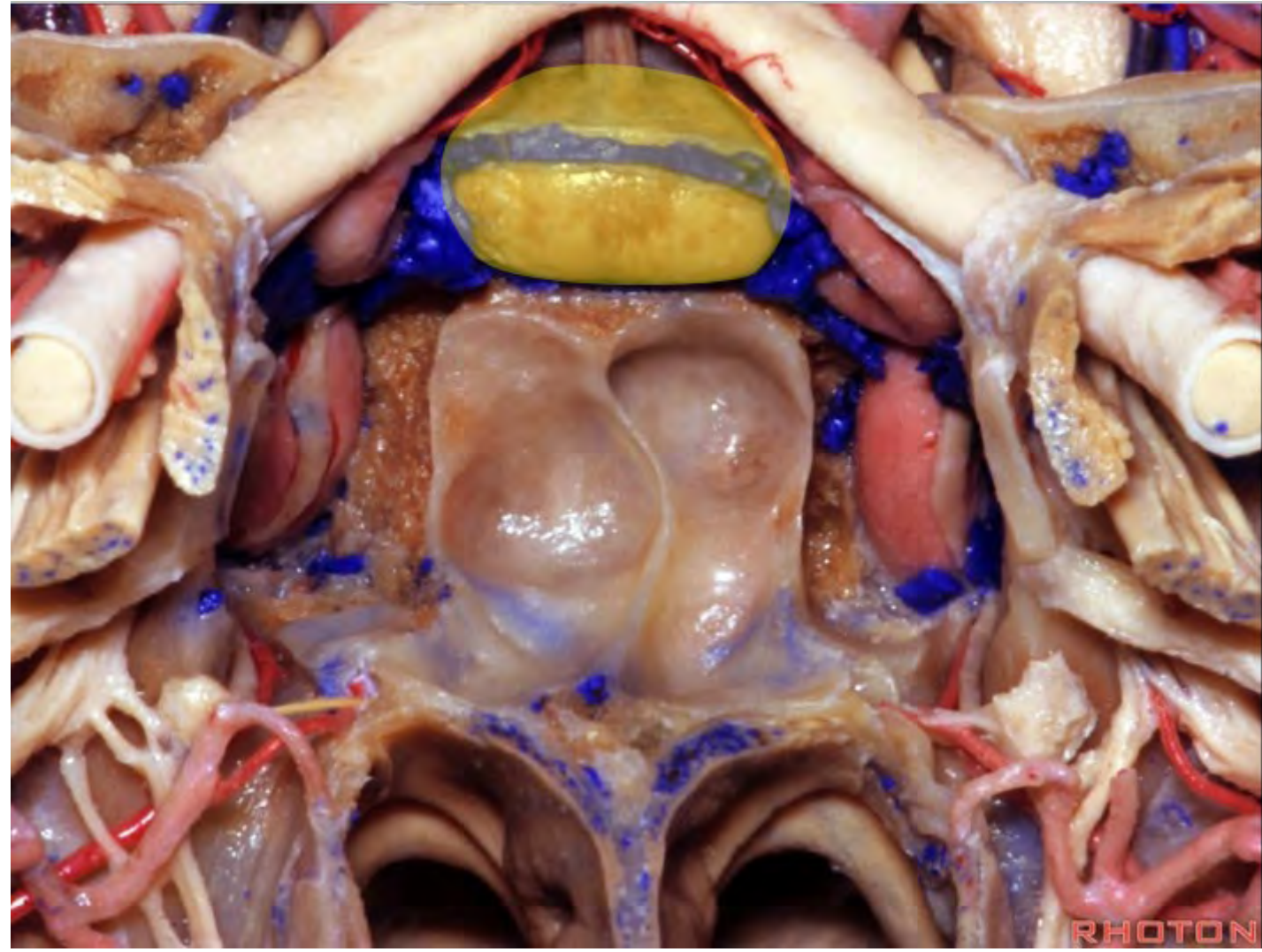
**Anterior cerebral artery**



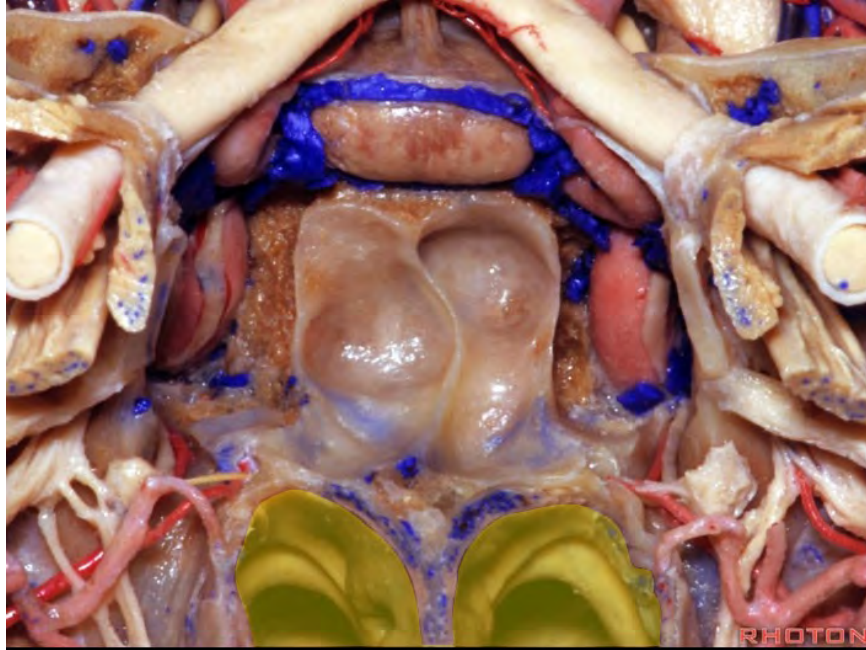




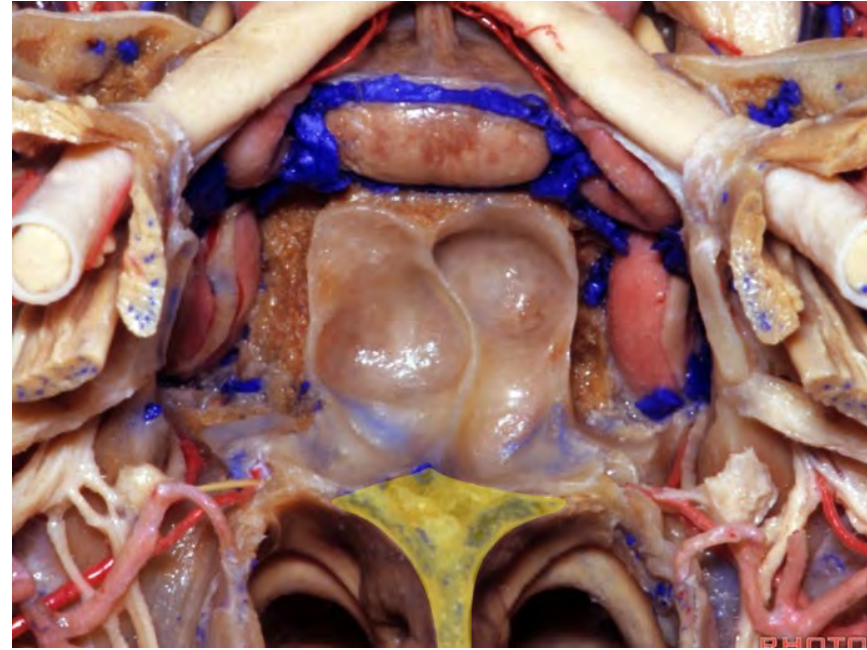


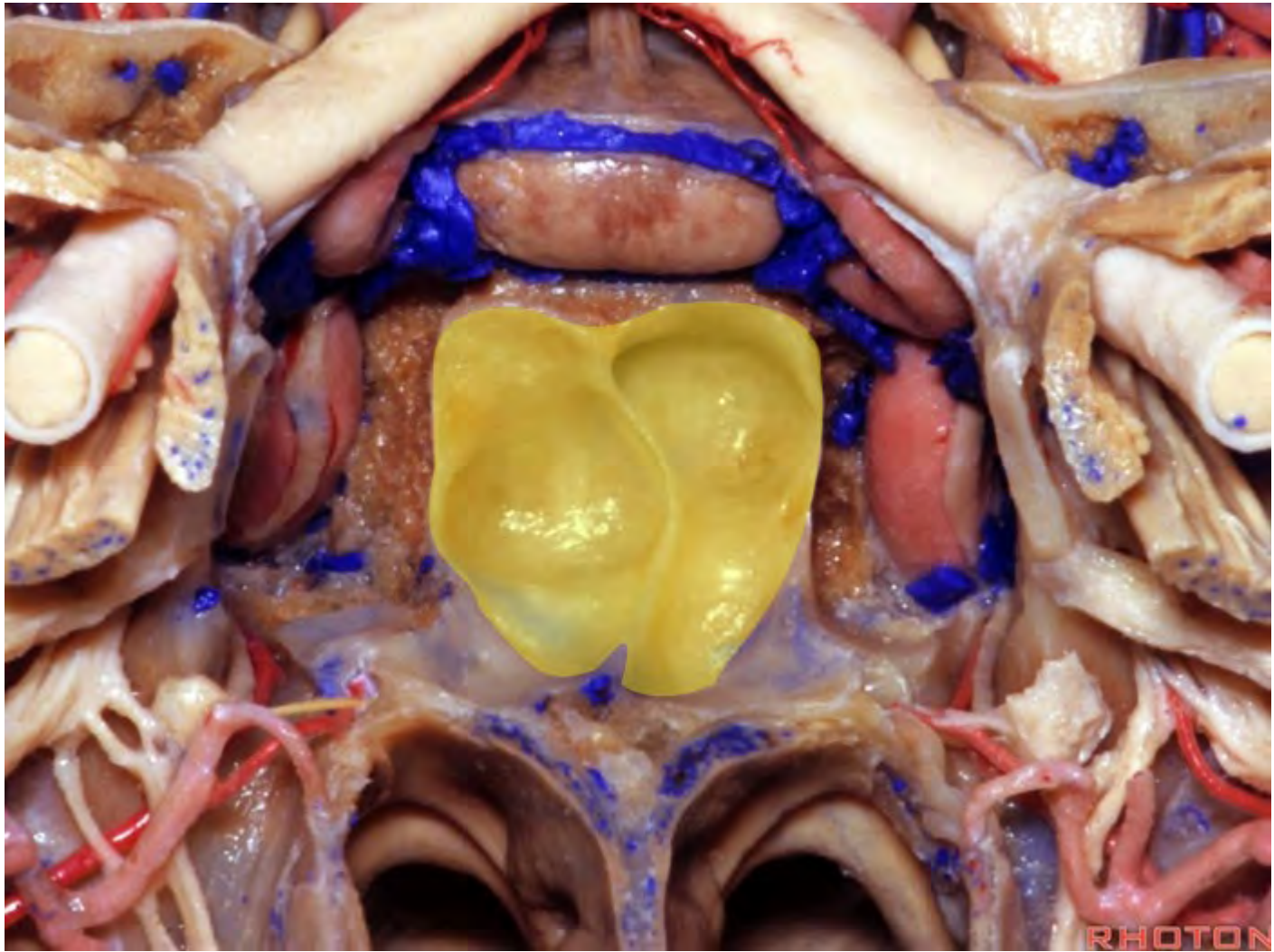


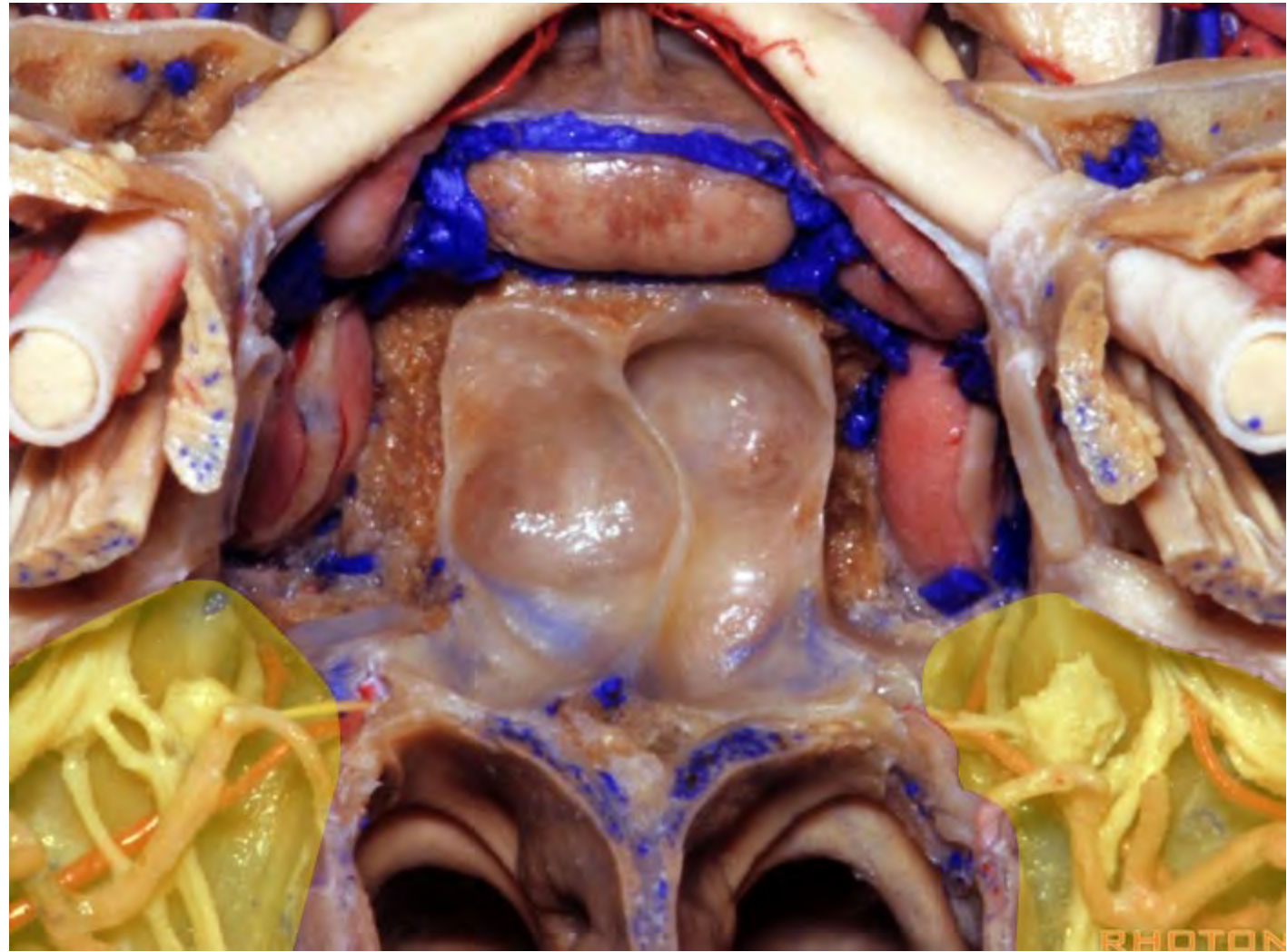
**Nasal cavity**



**Nasal septum**

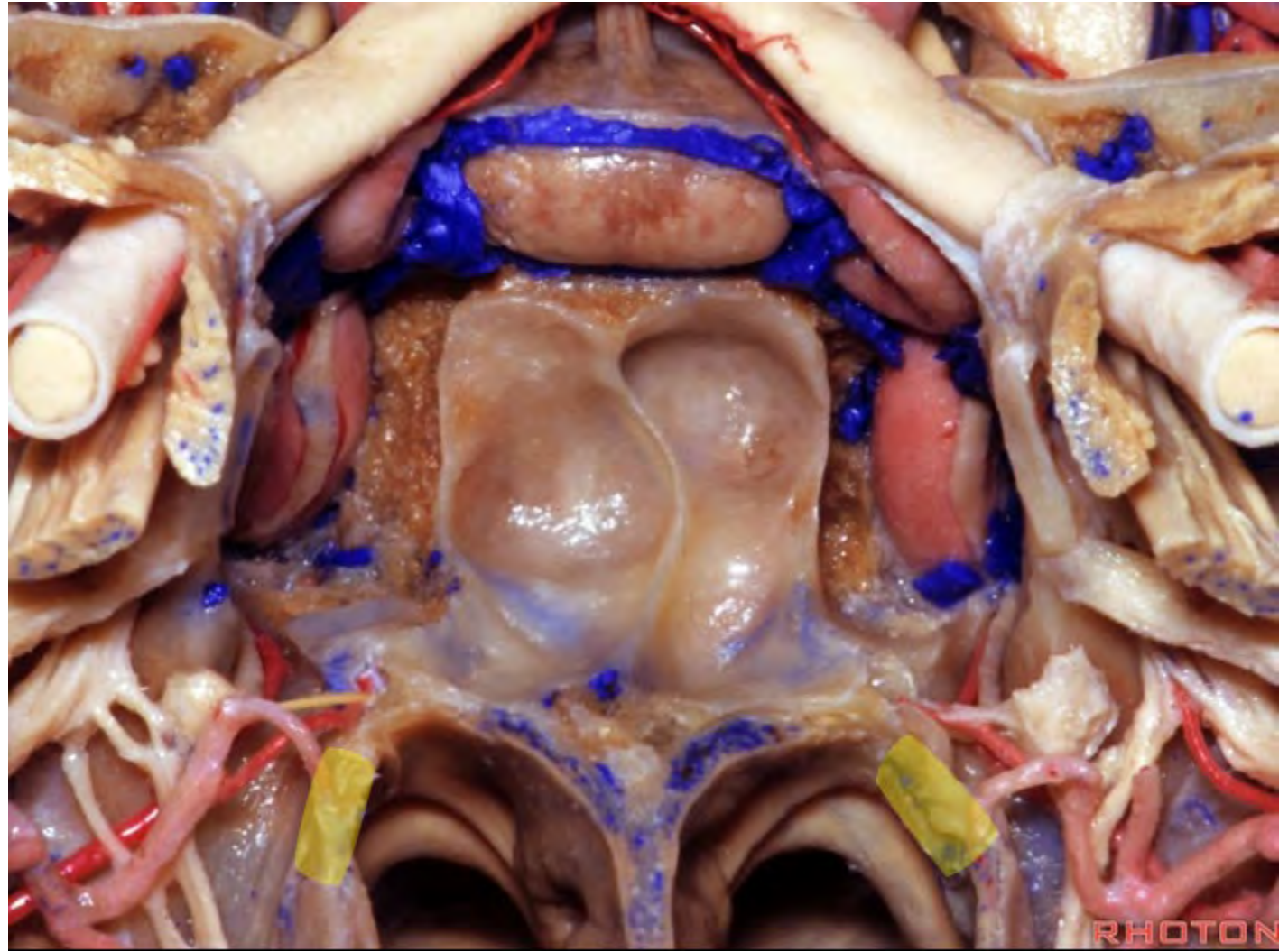


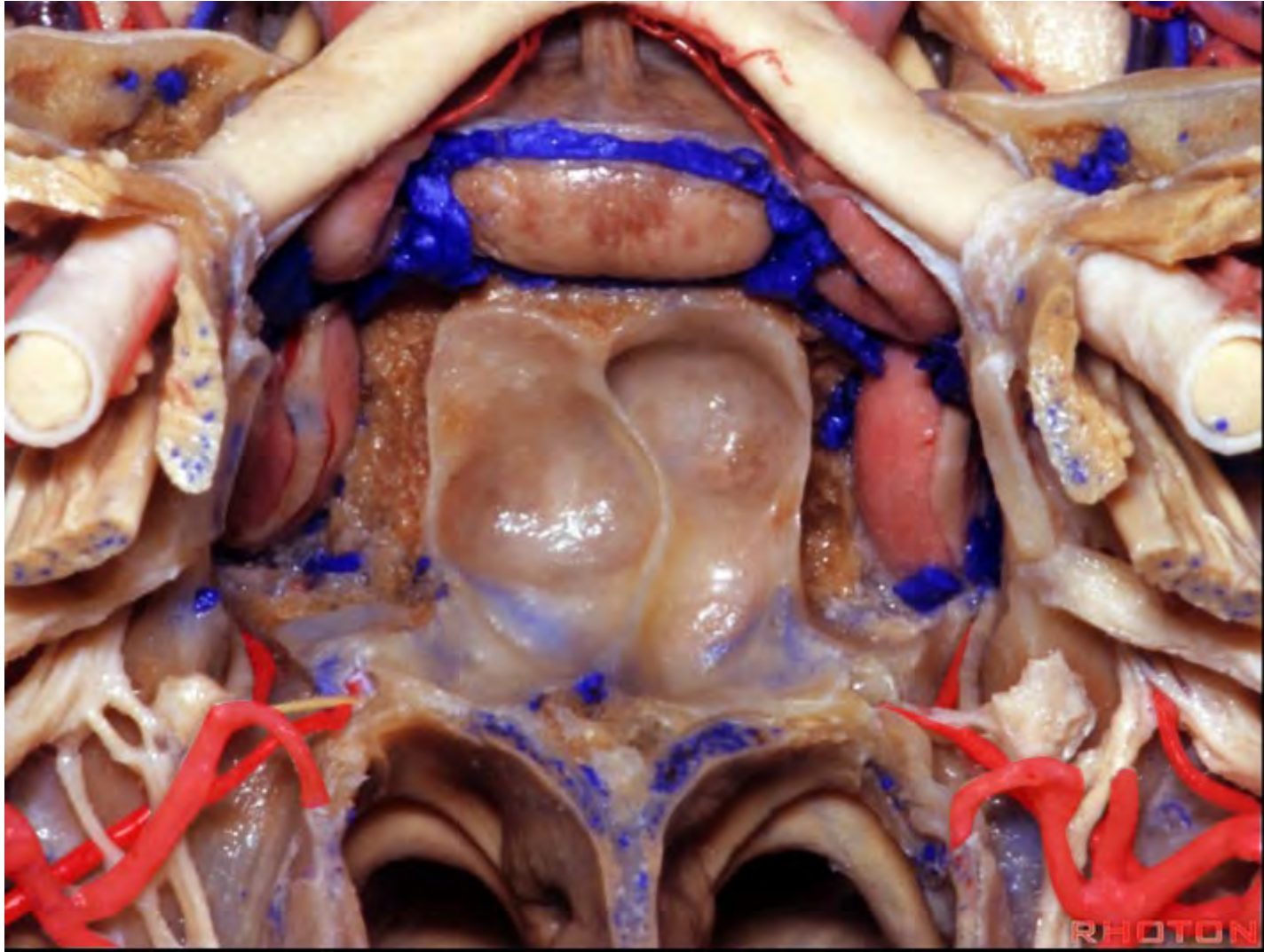


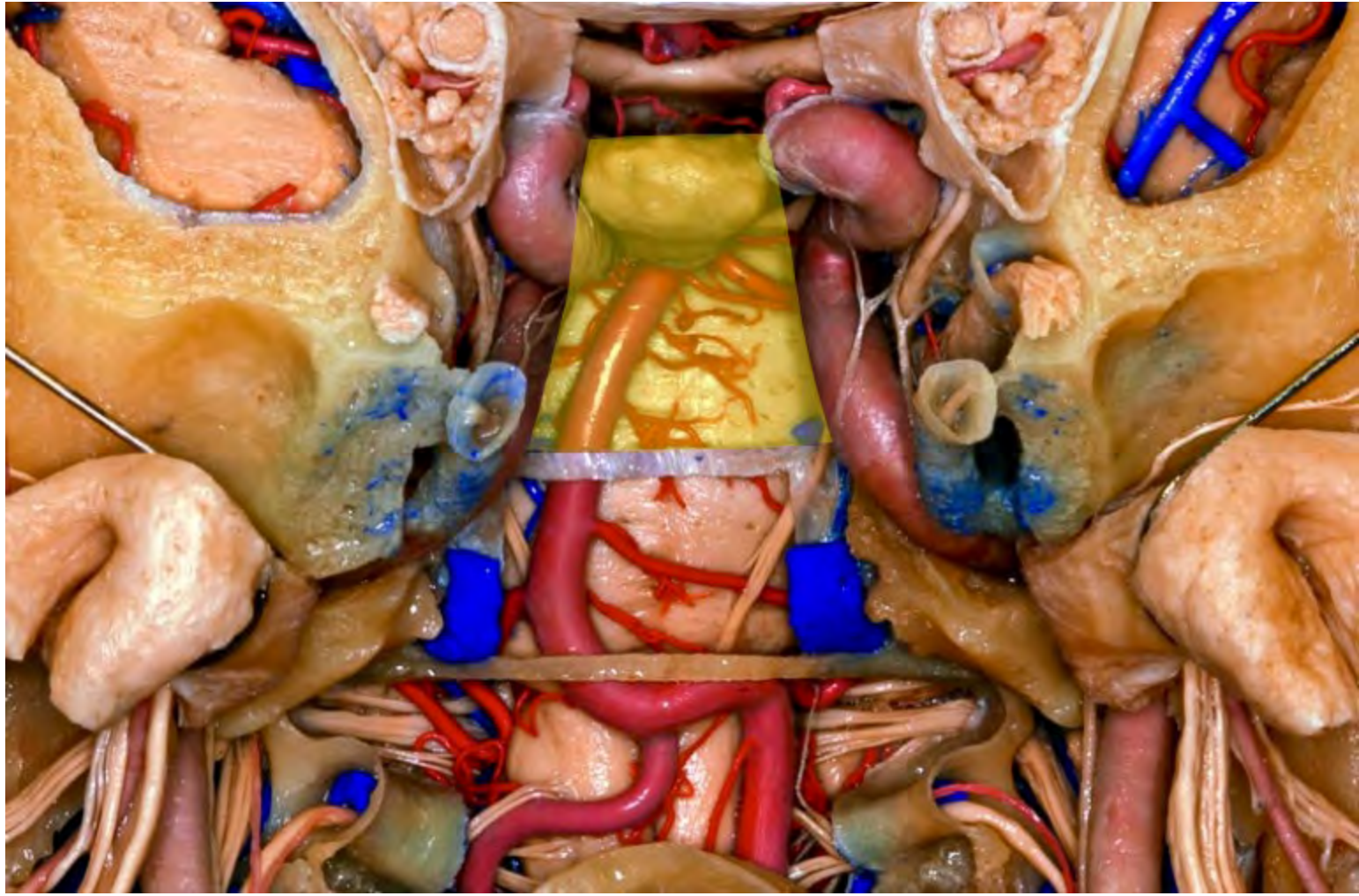


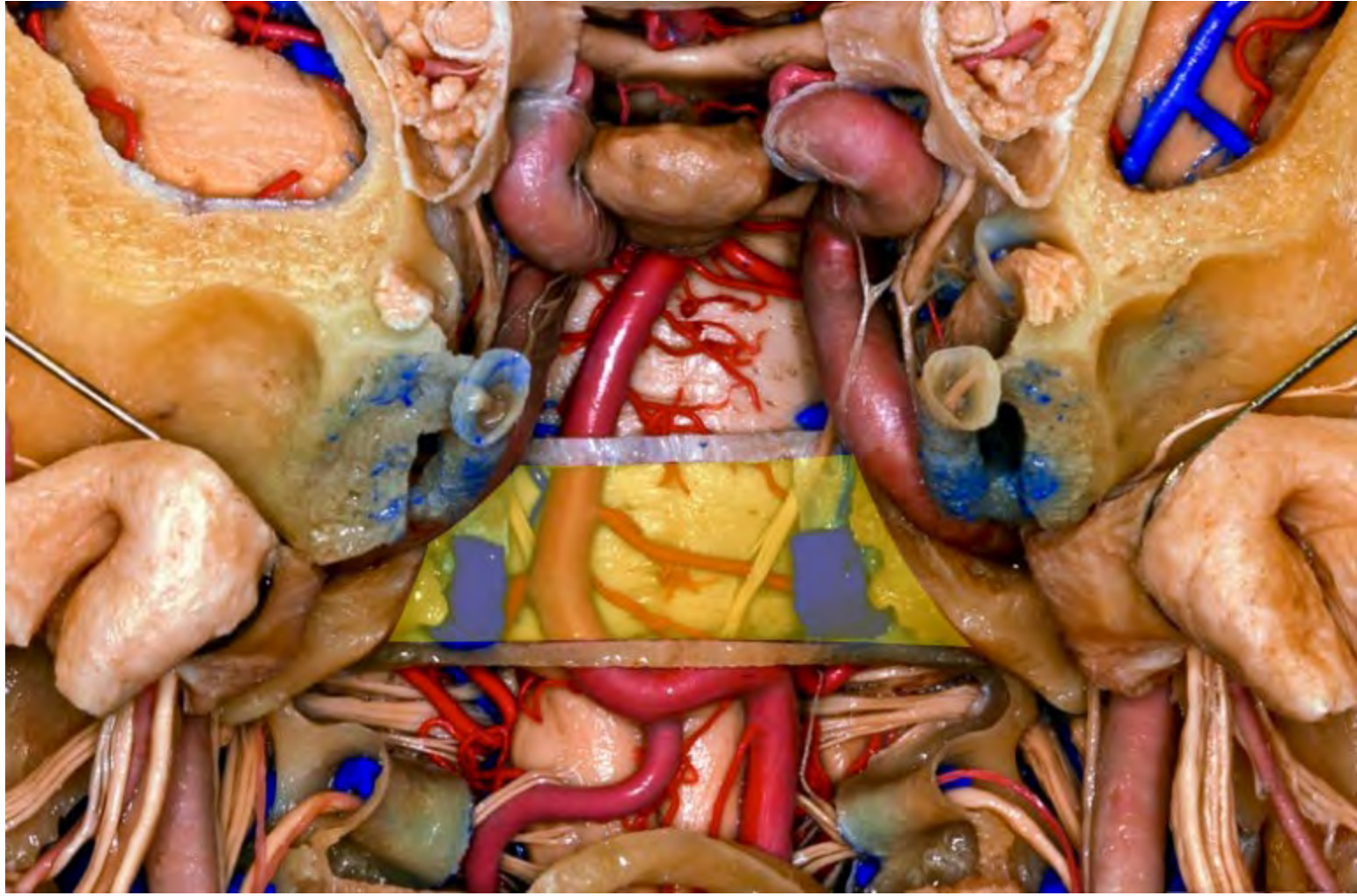PHOTON

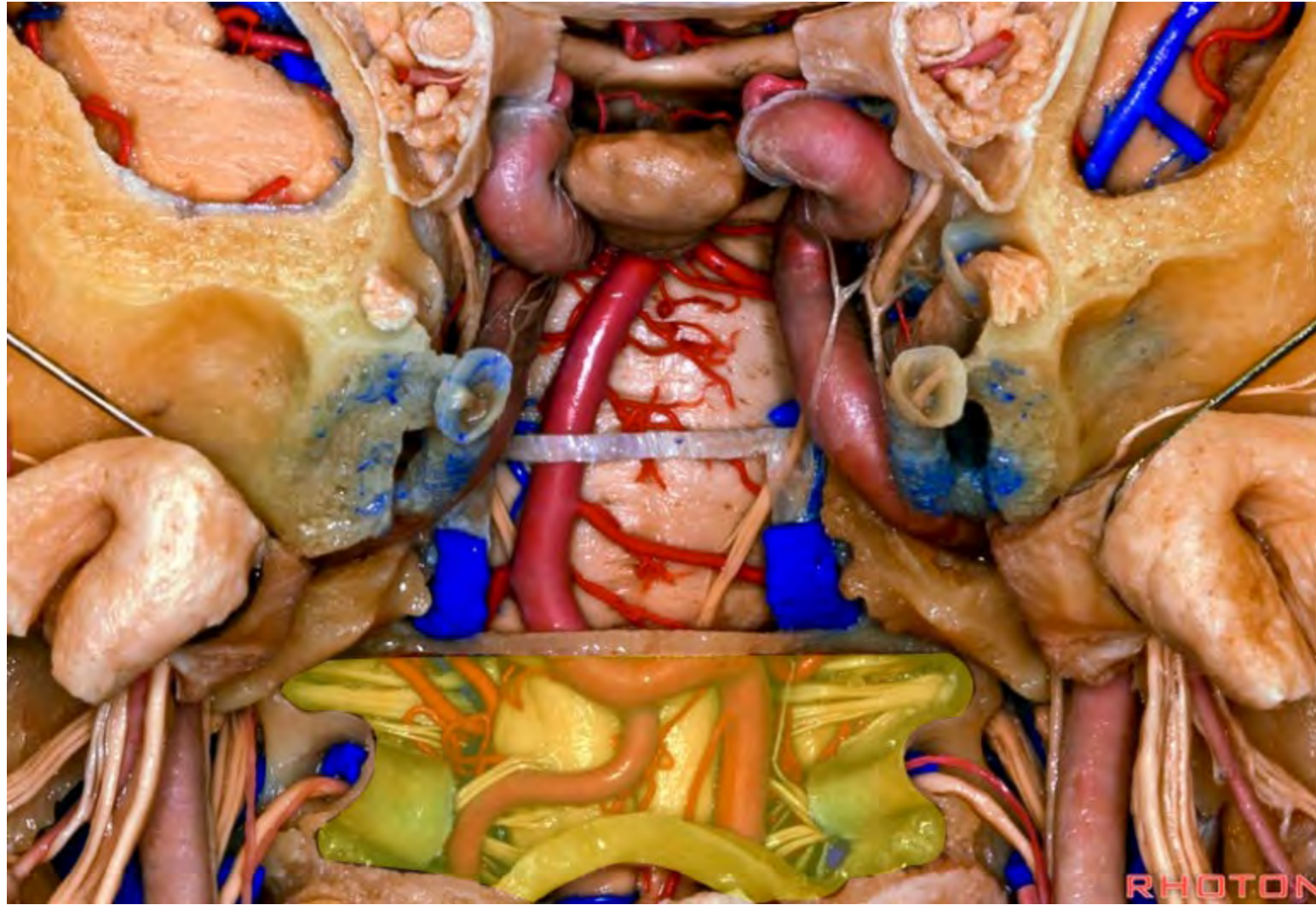


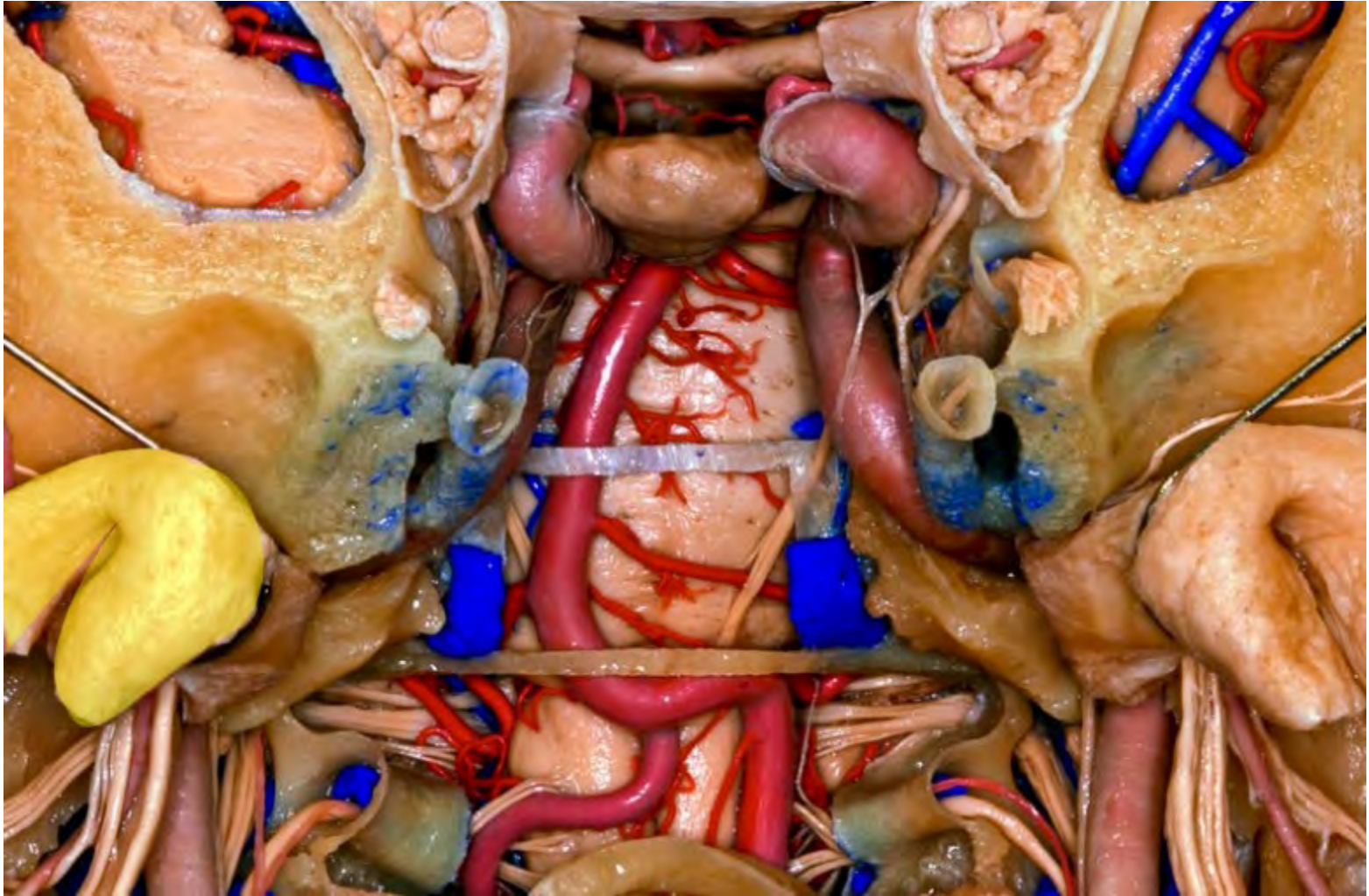


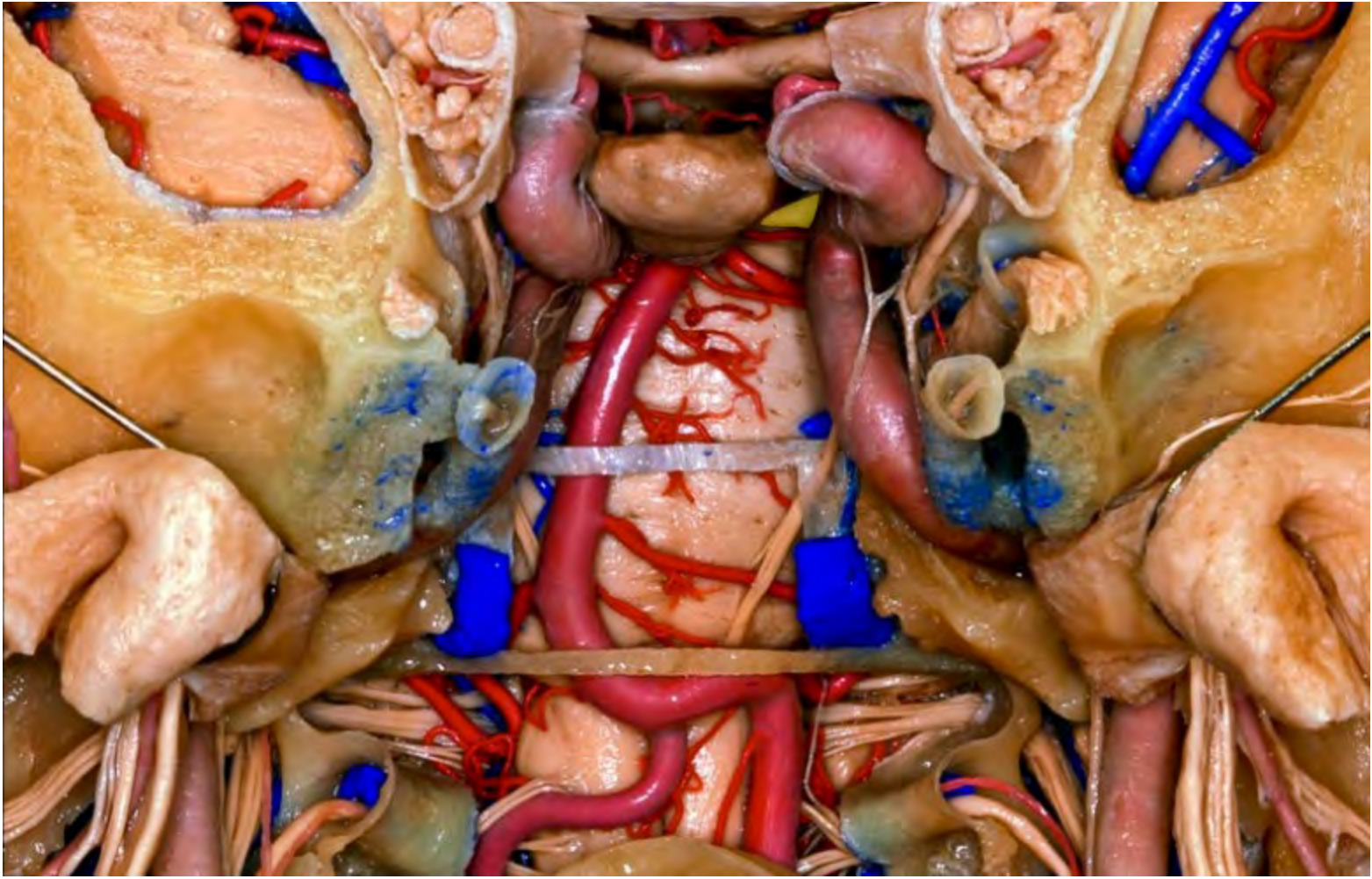


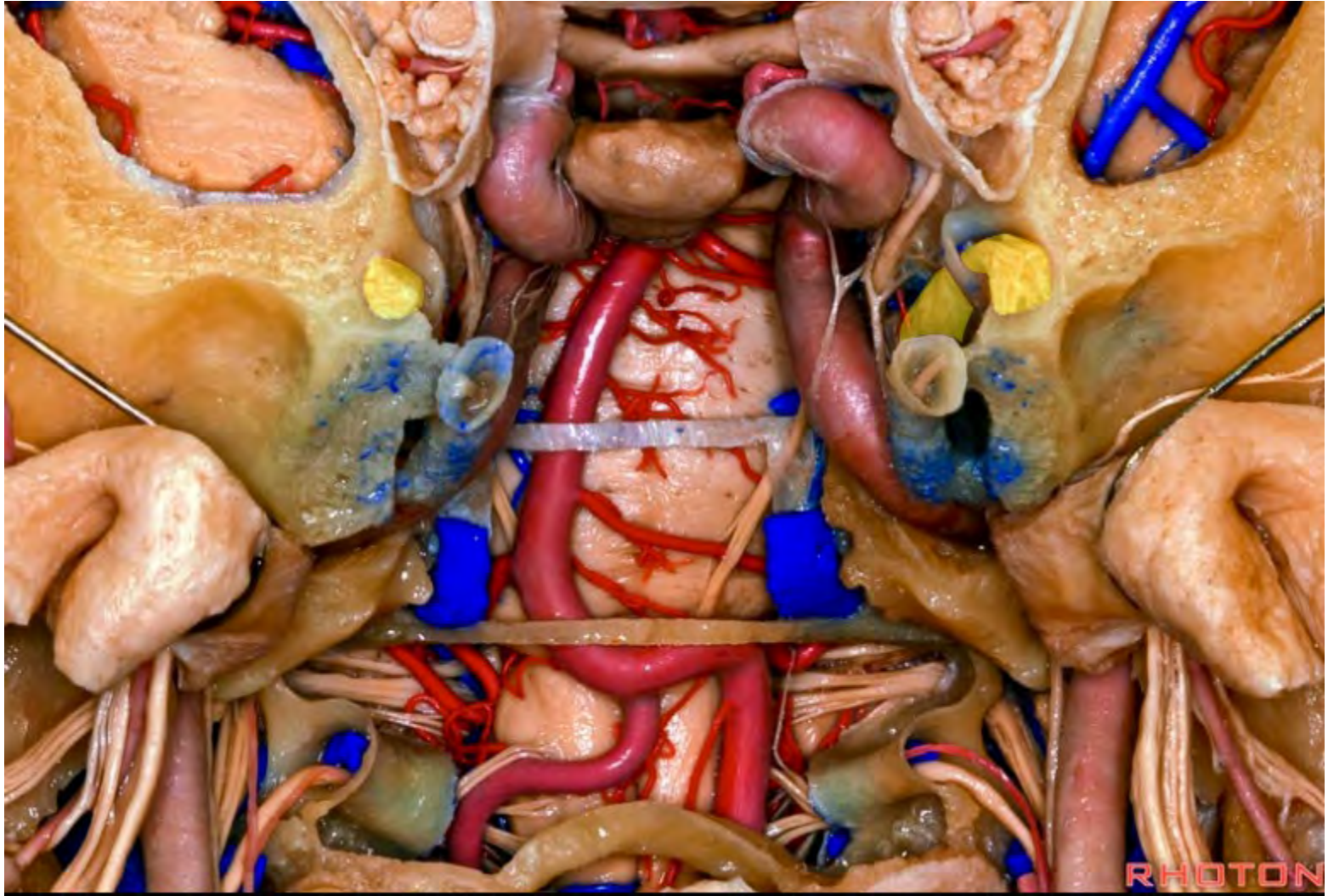




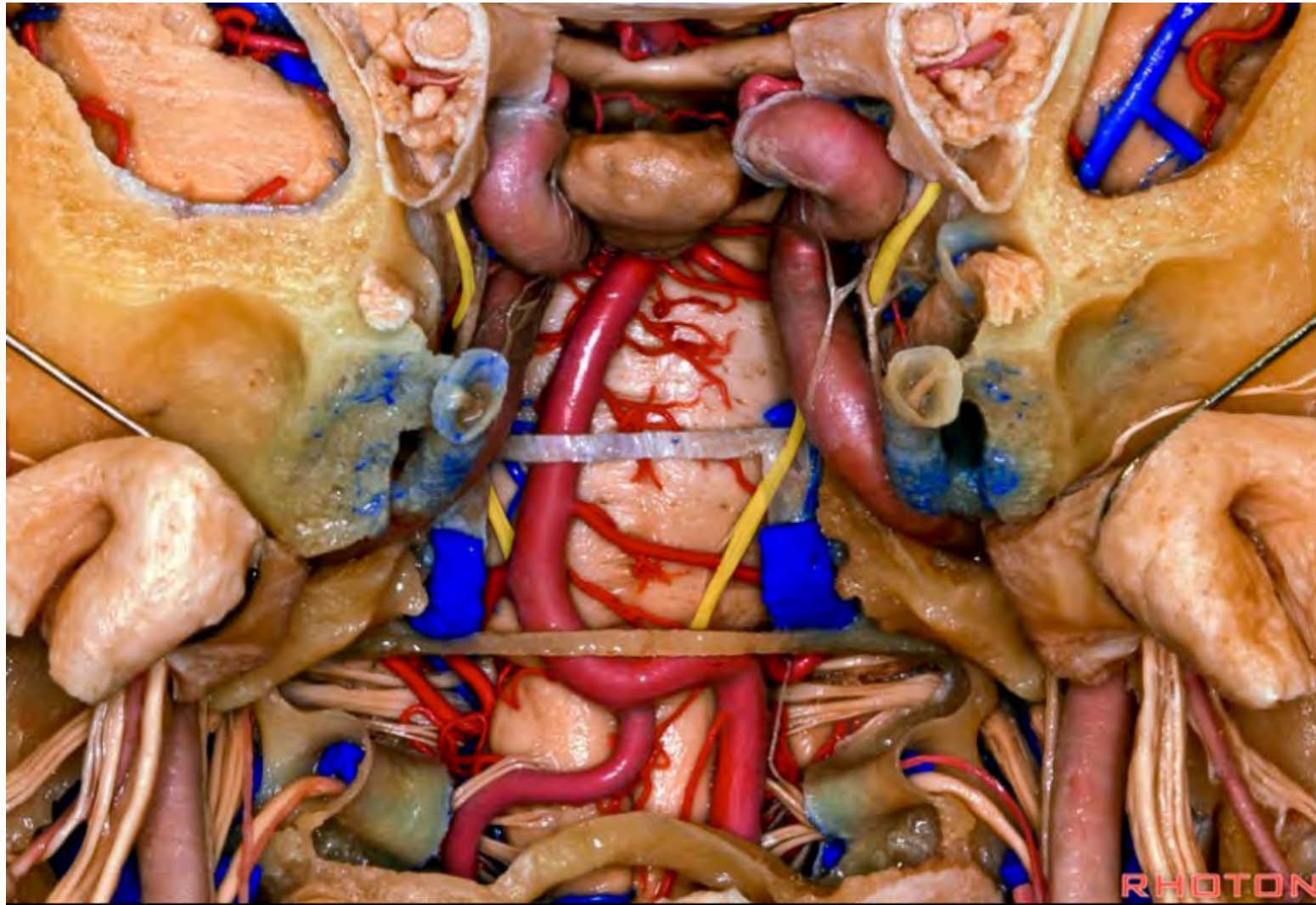


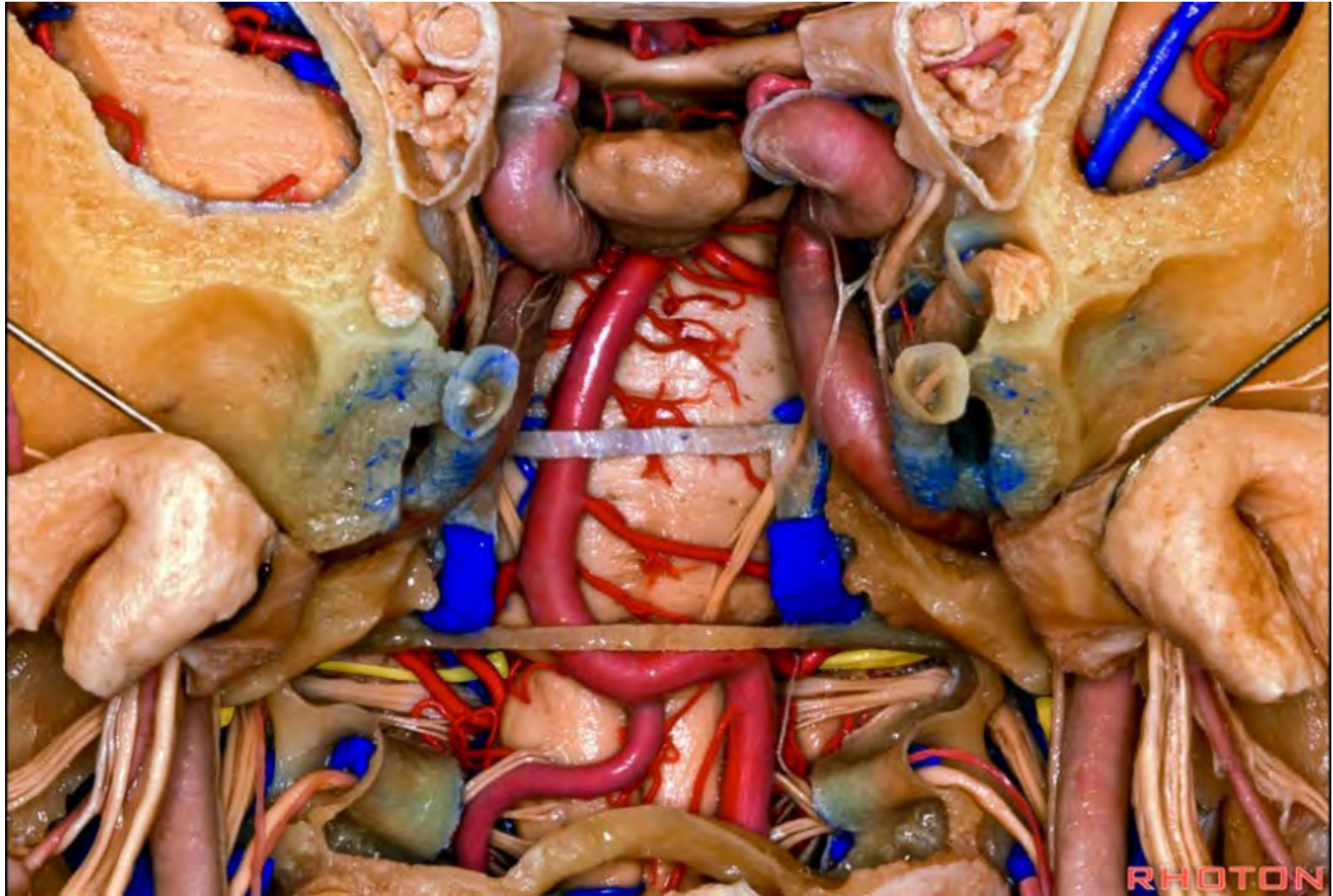


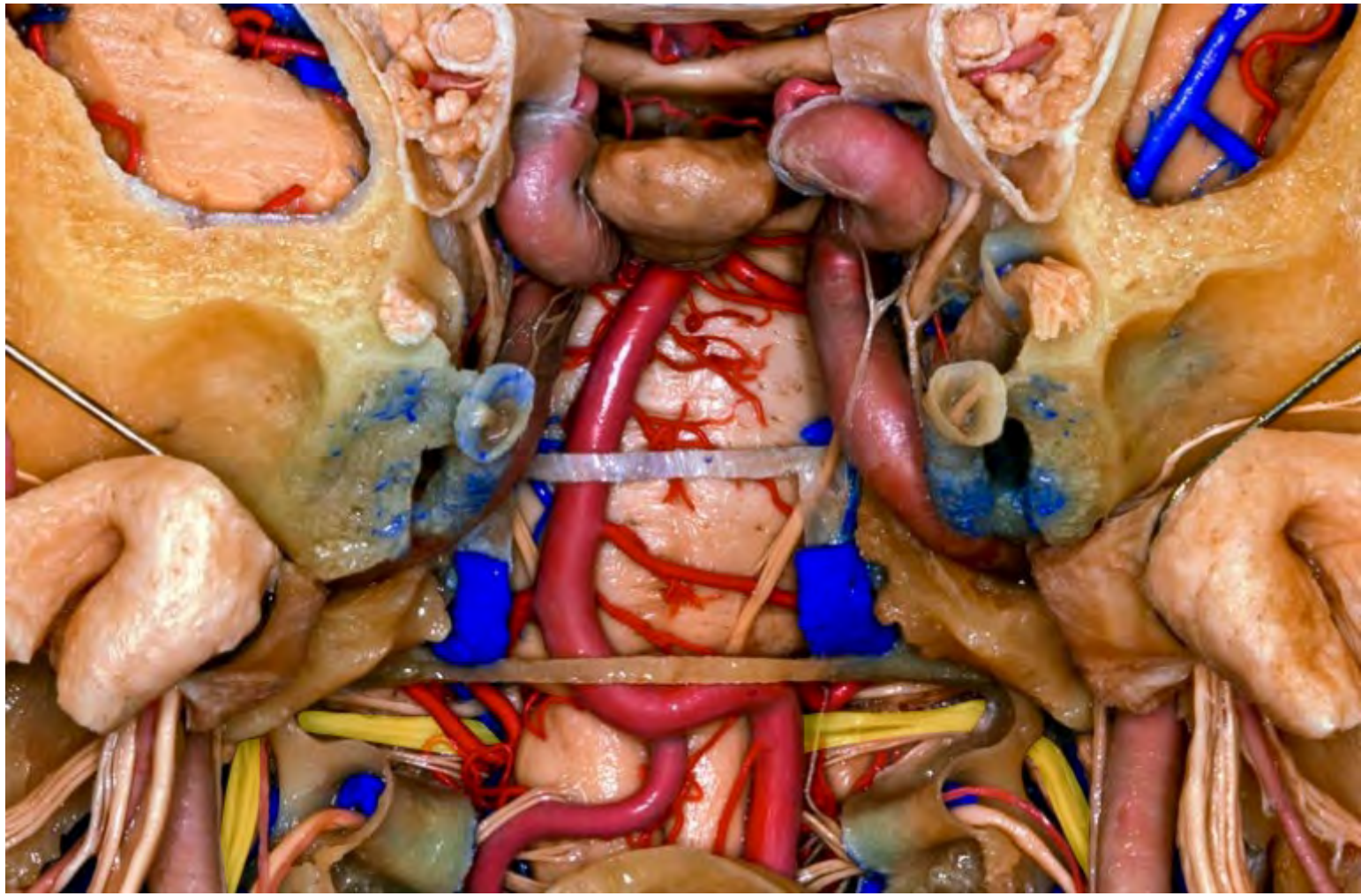


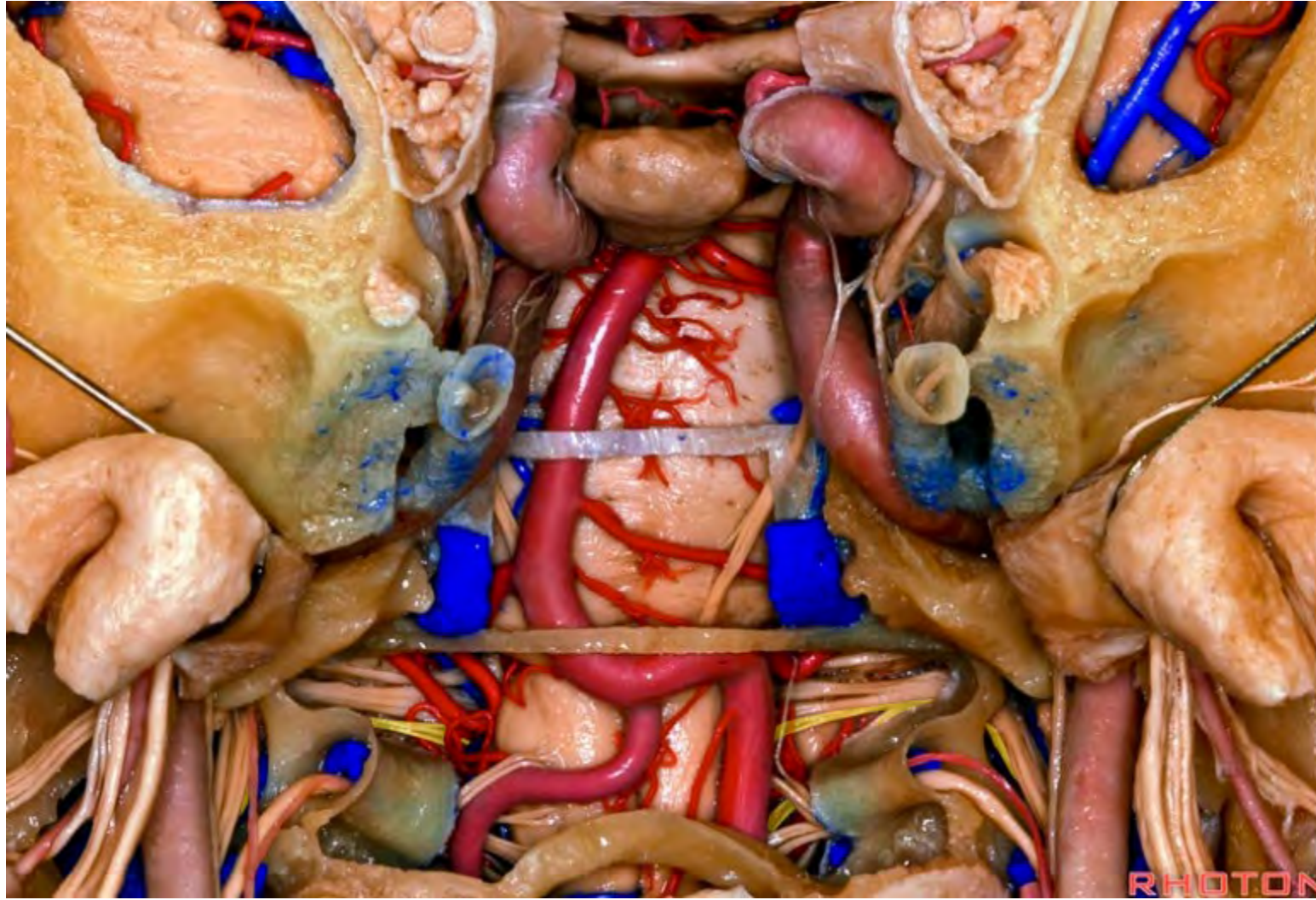


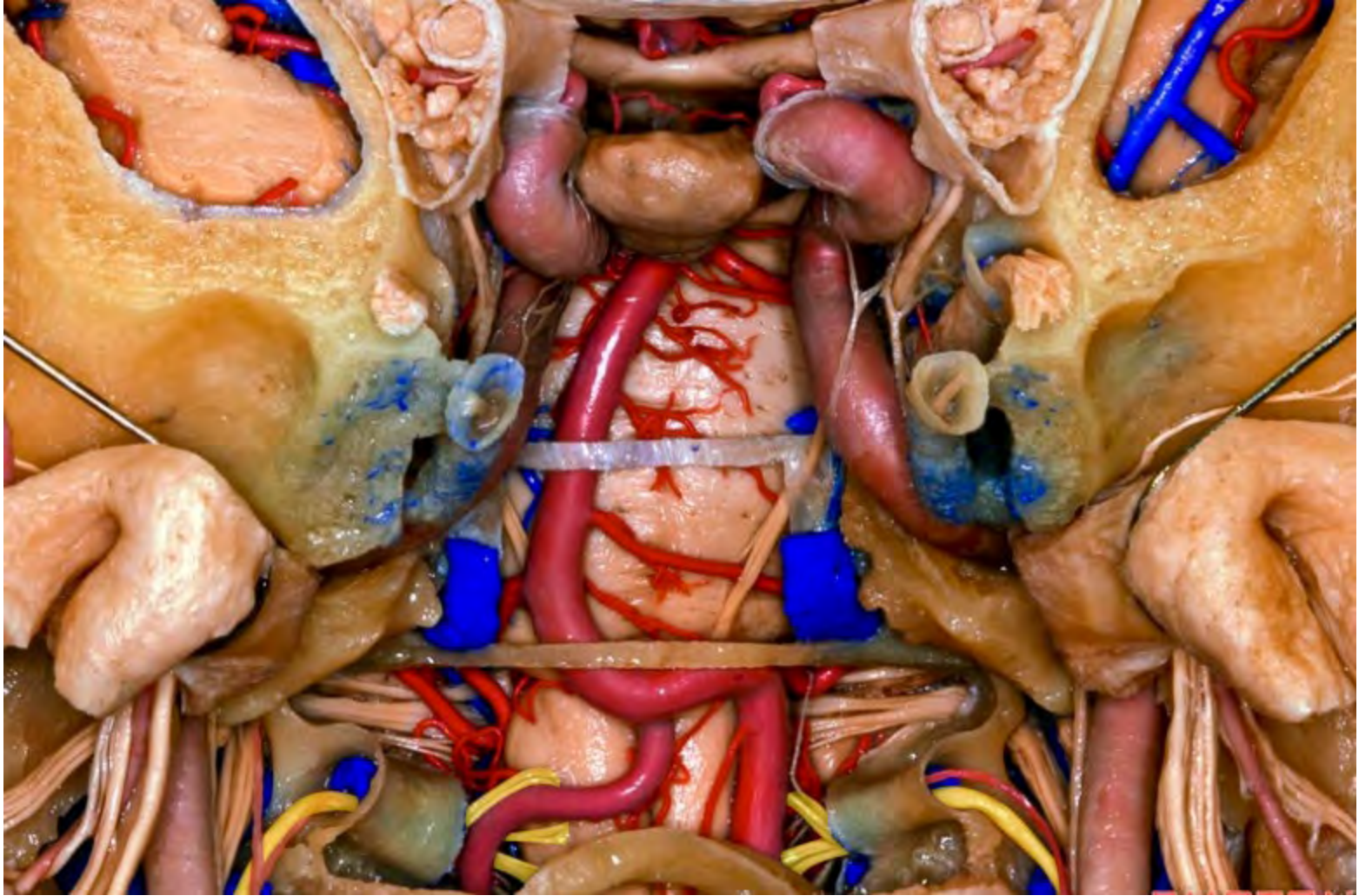


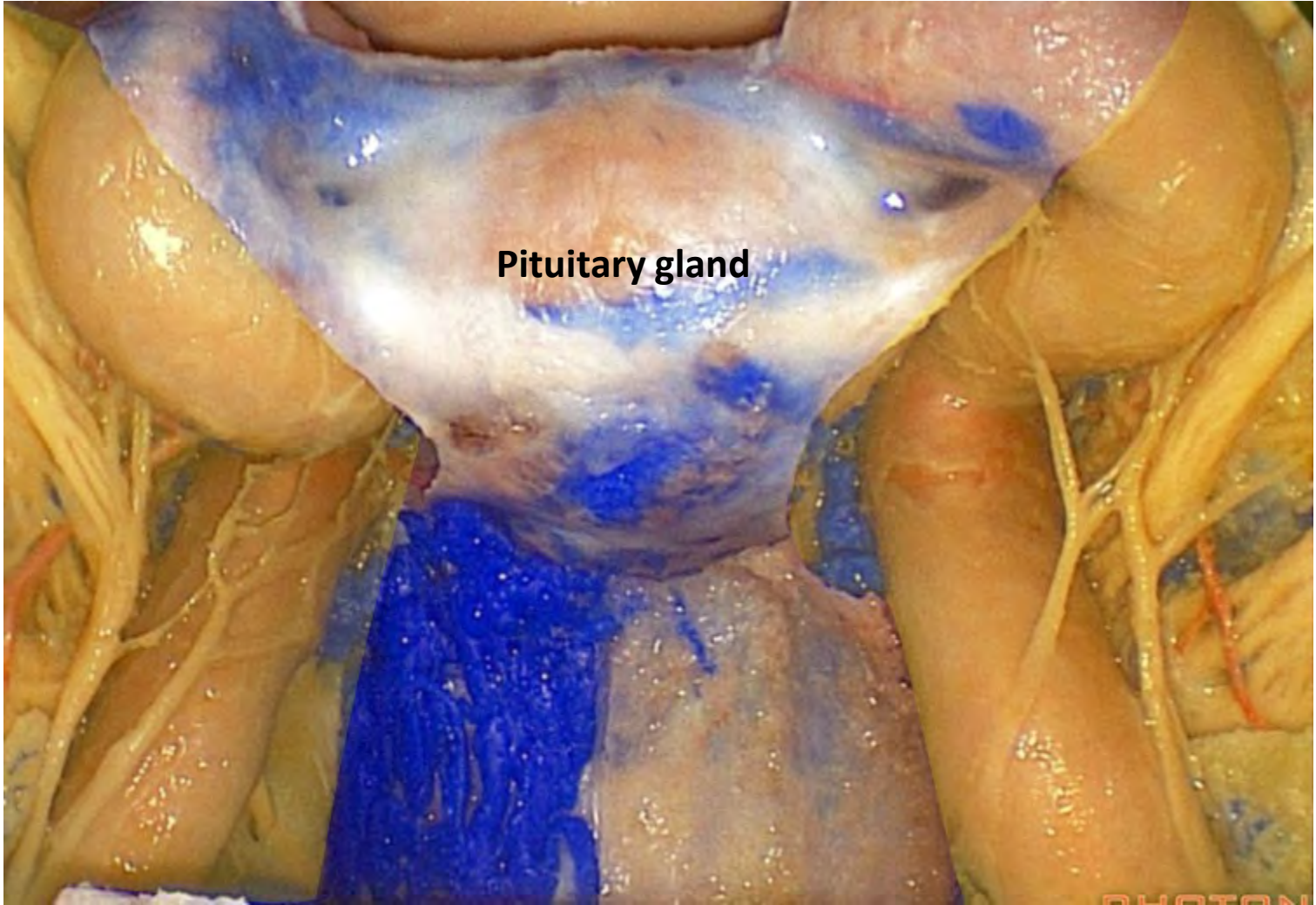


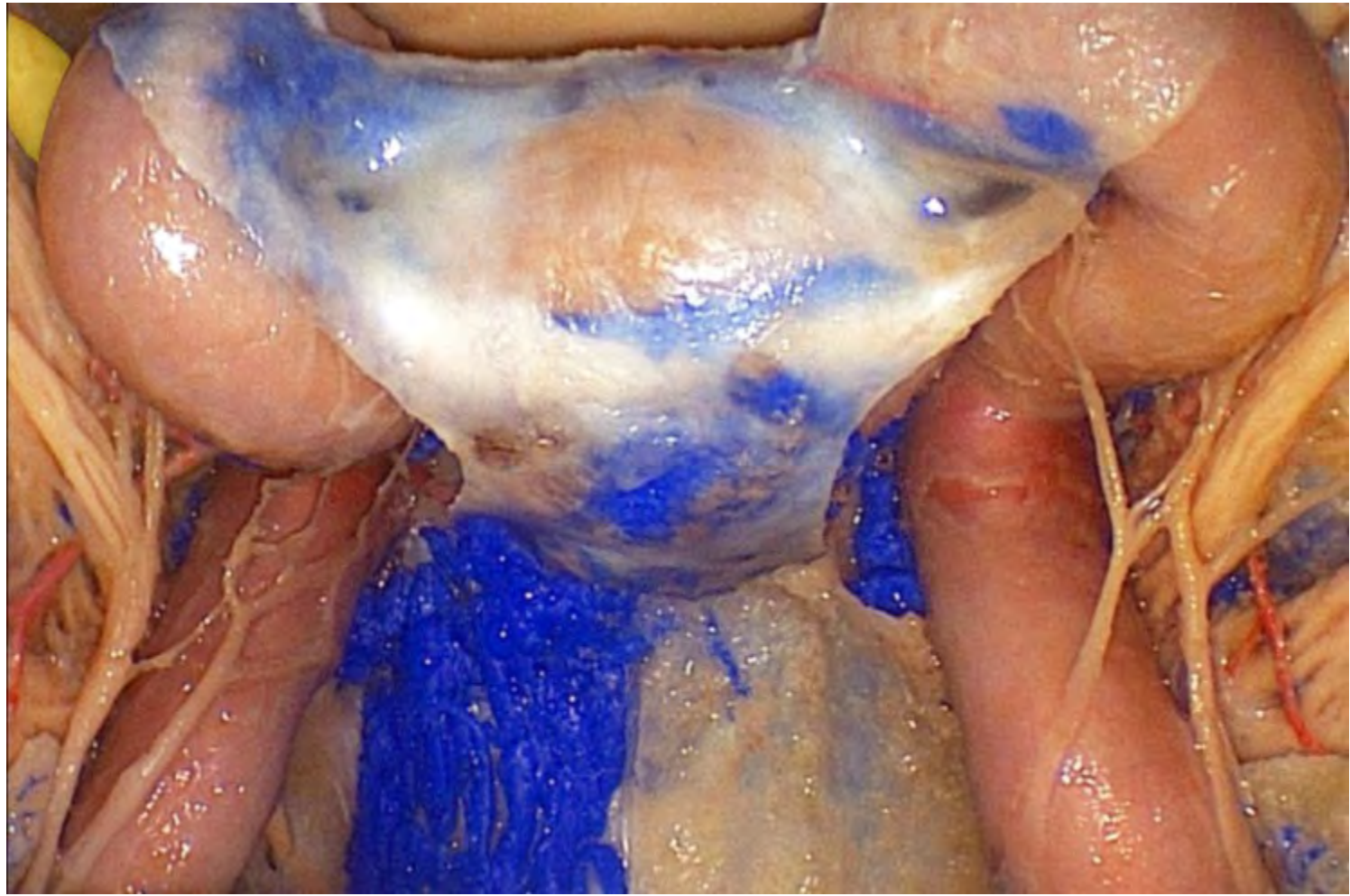


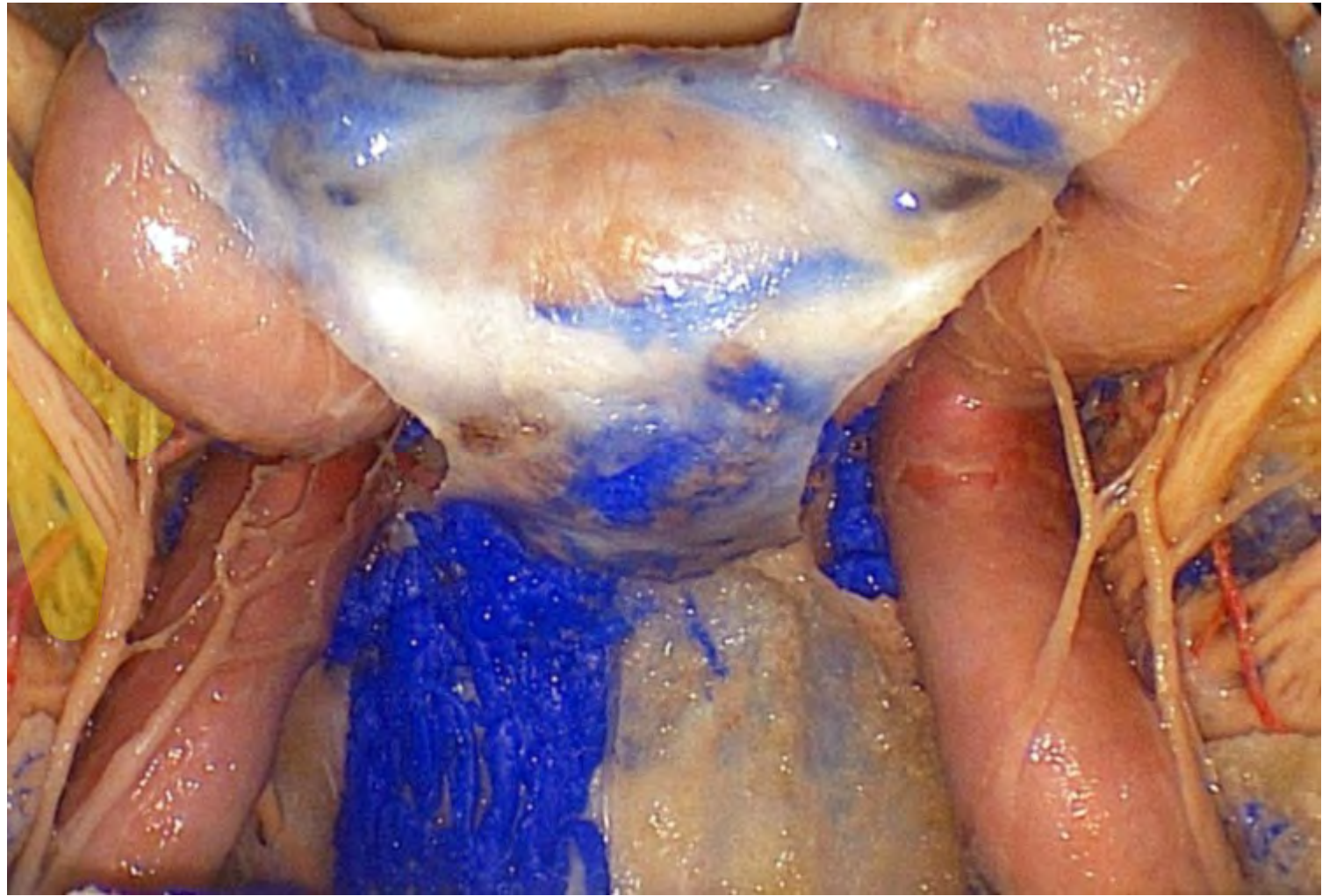




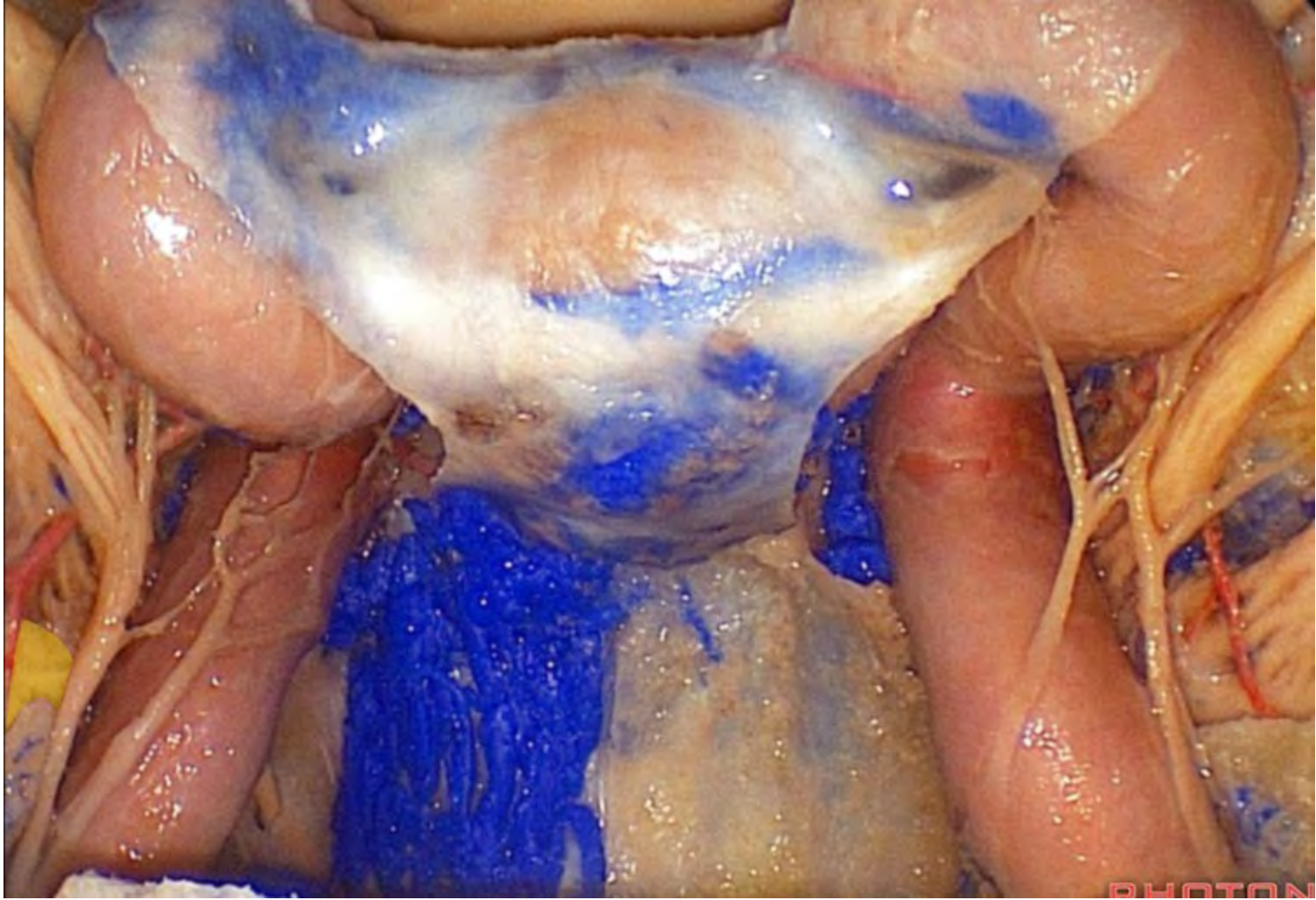
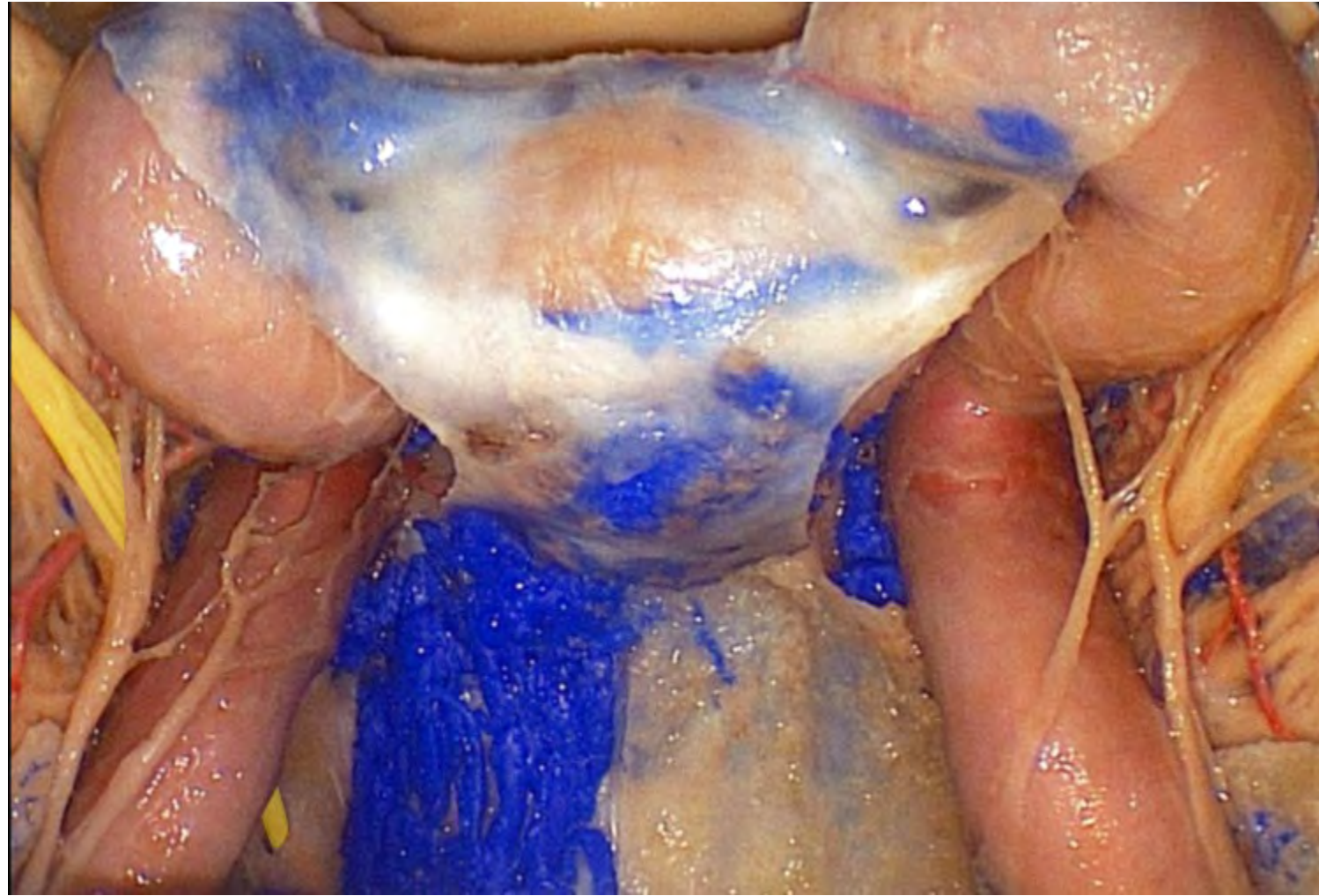


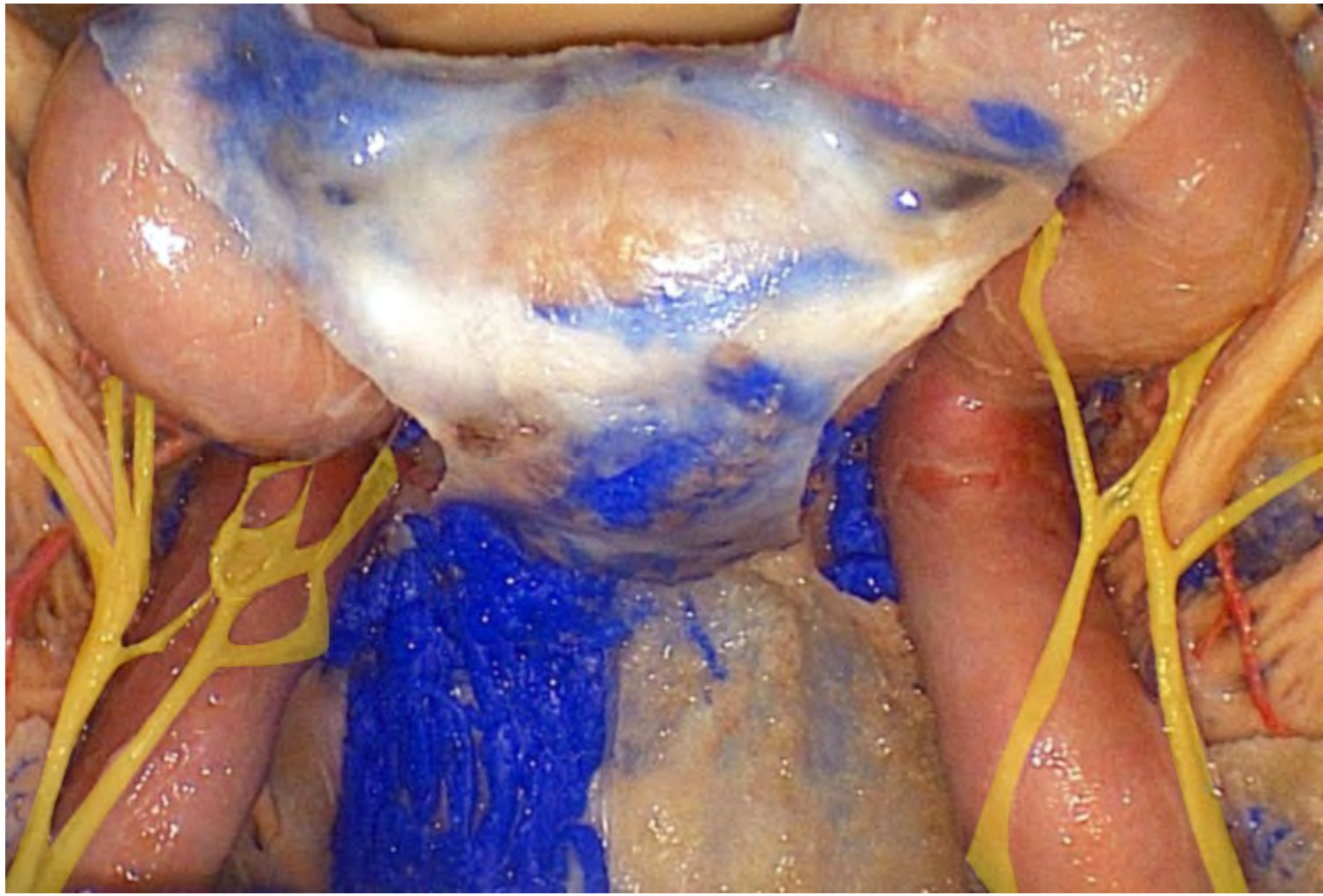




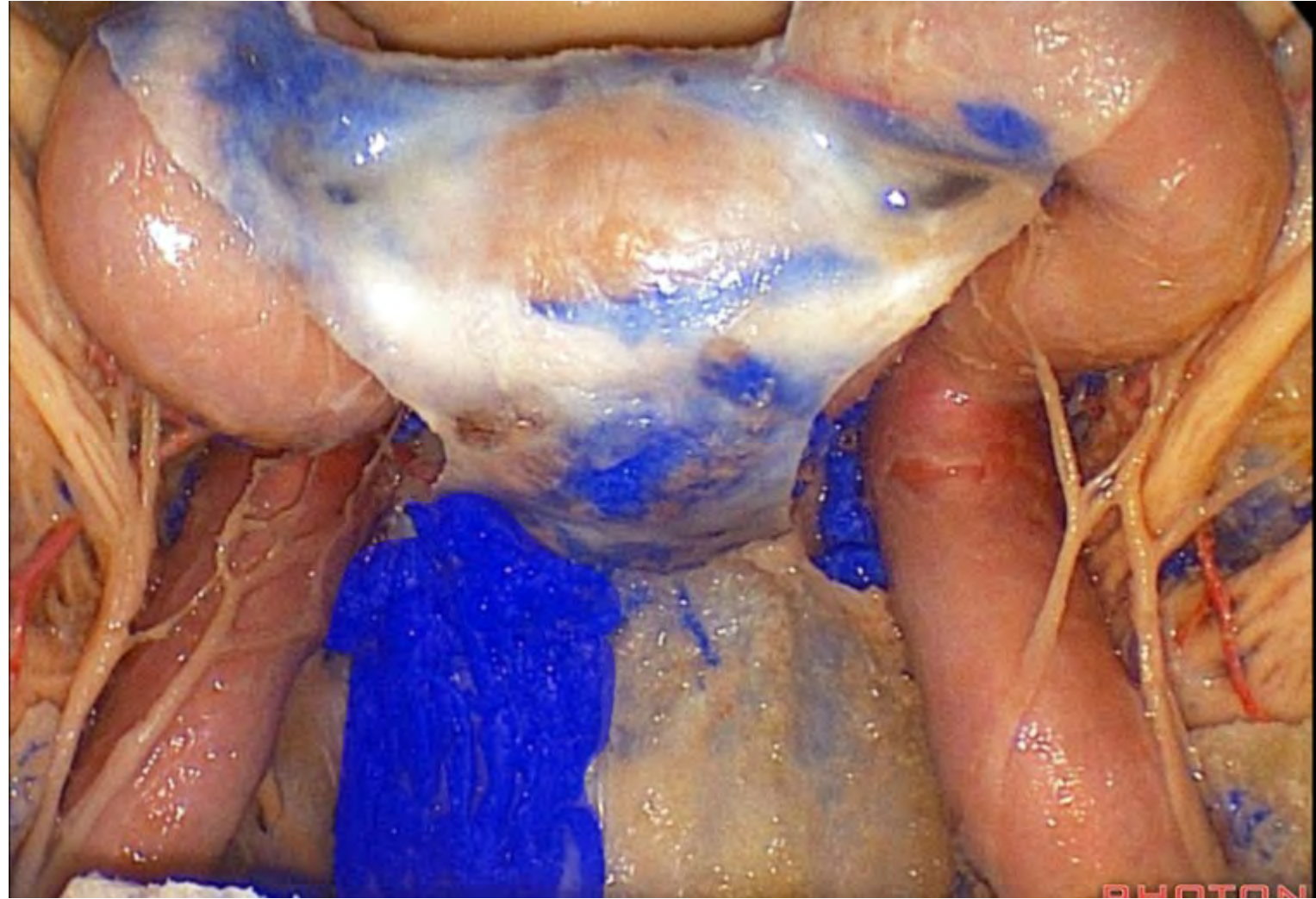


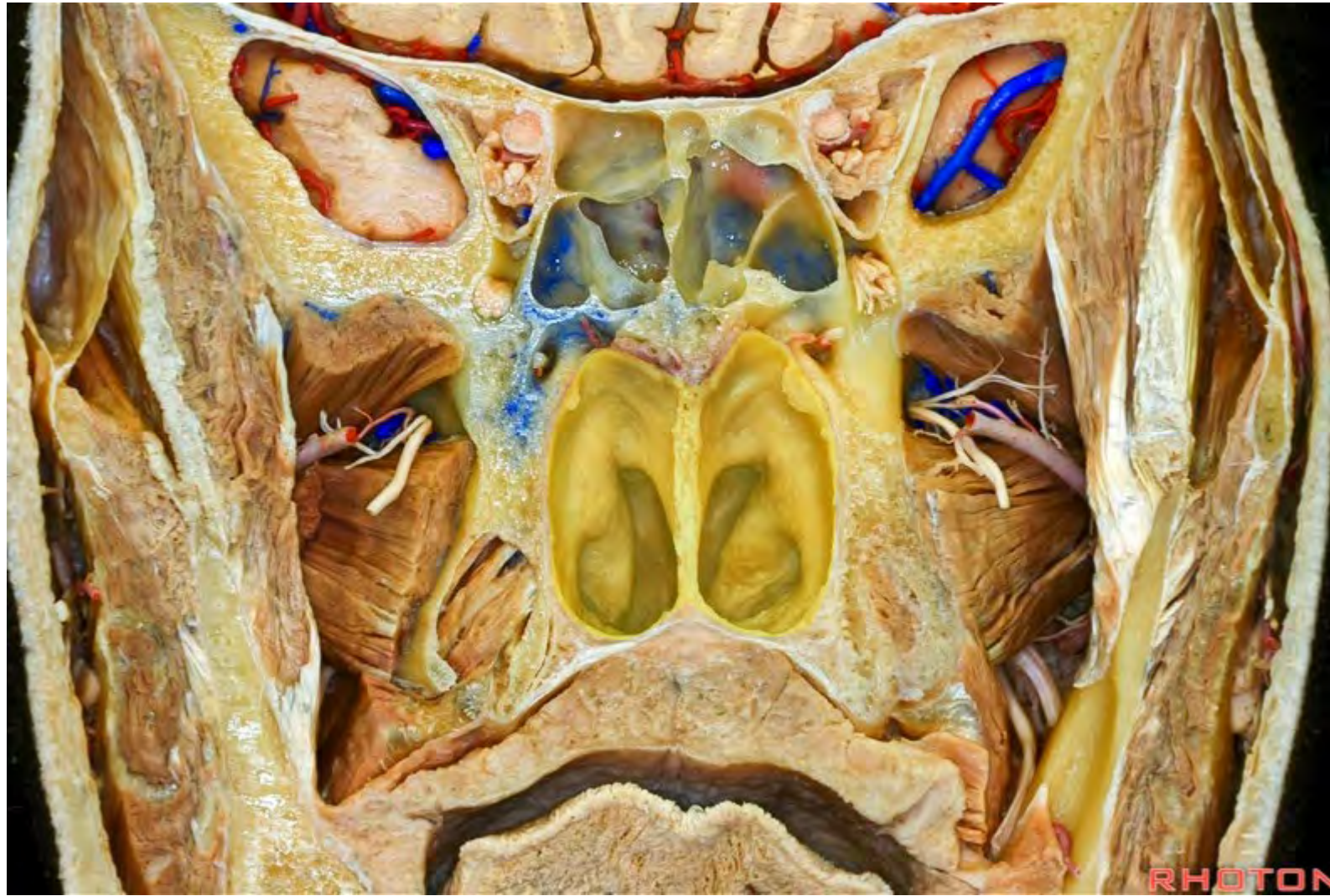




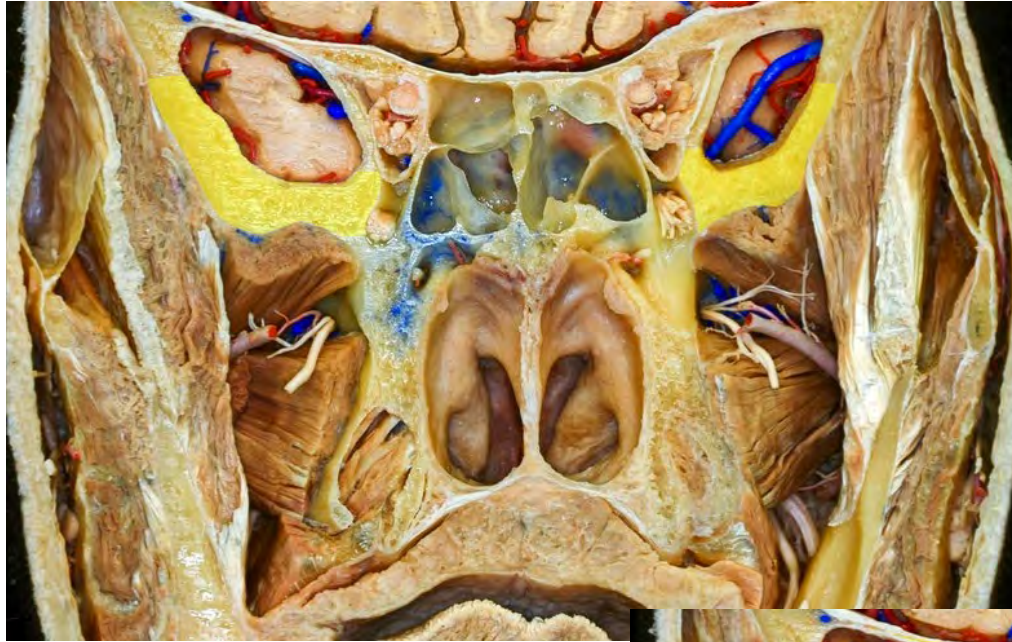



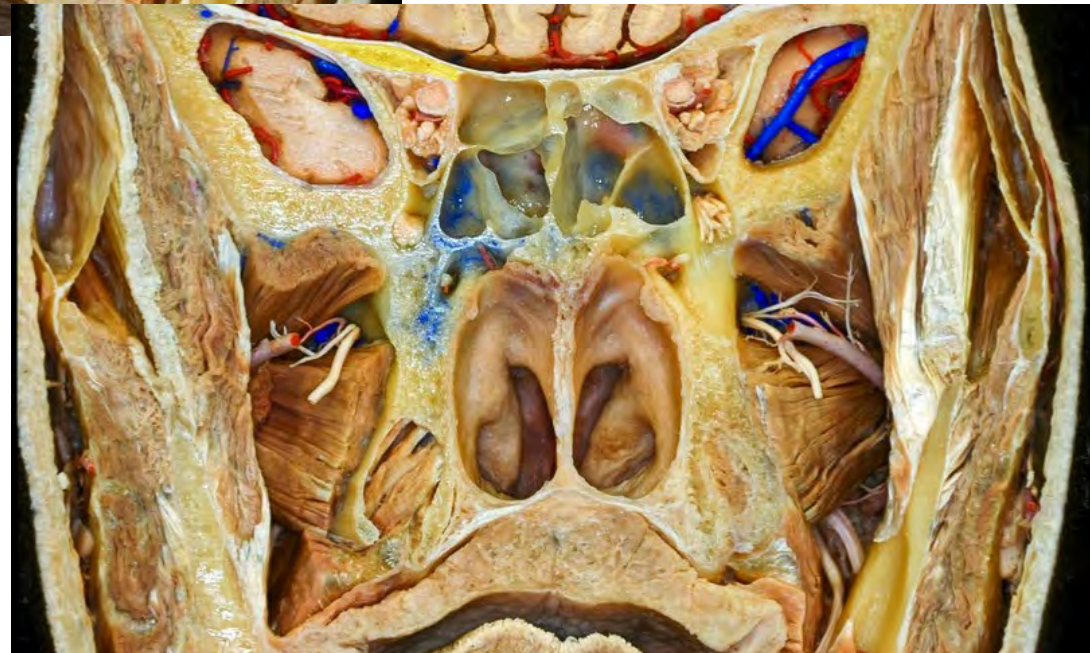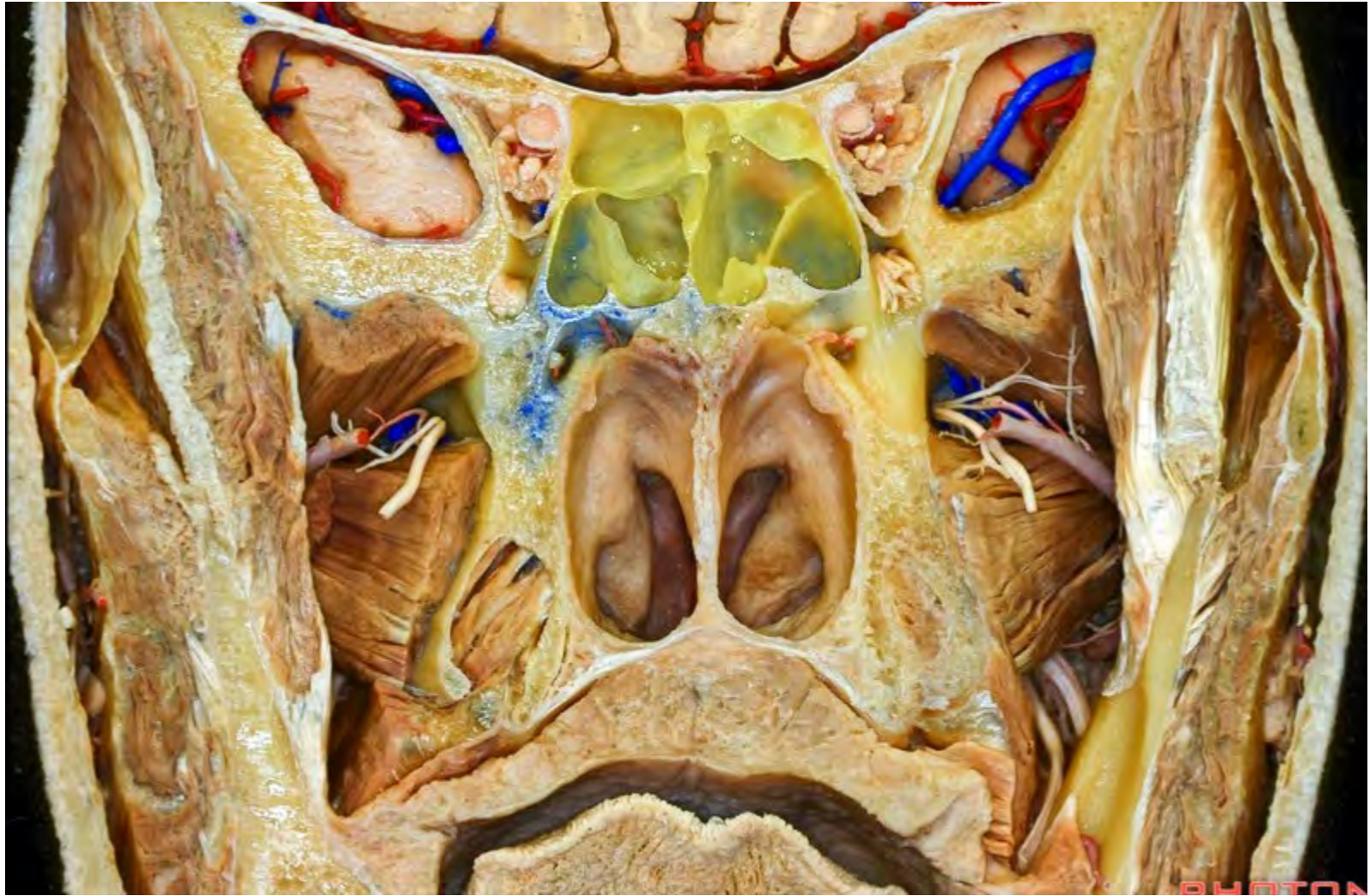**Greater wing of sphenoid**

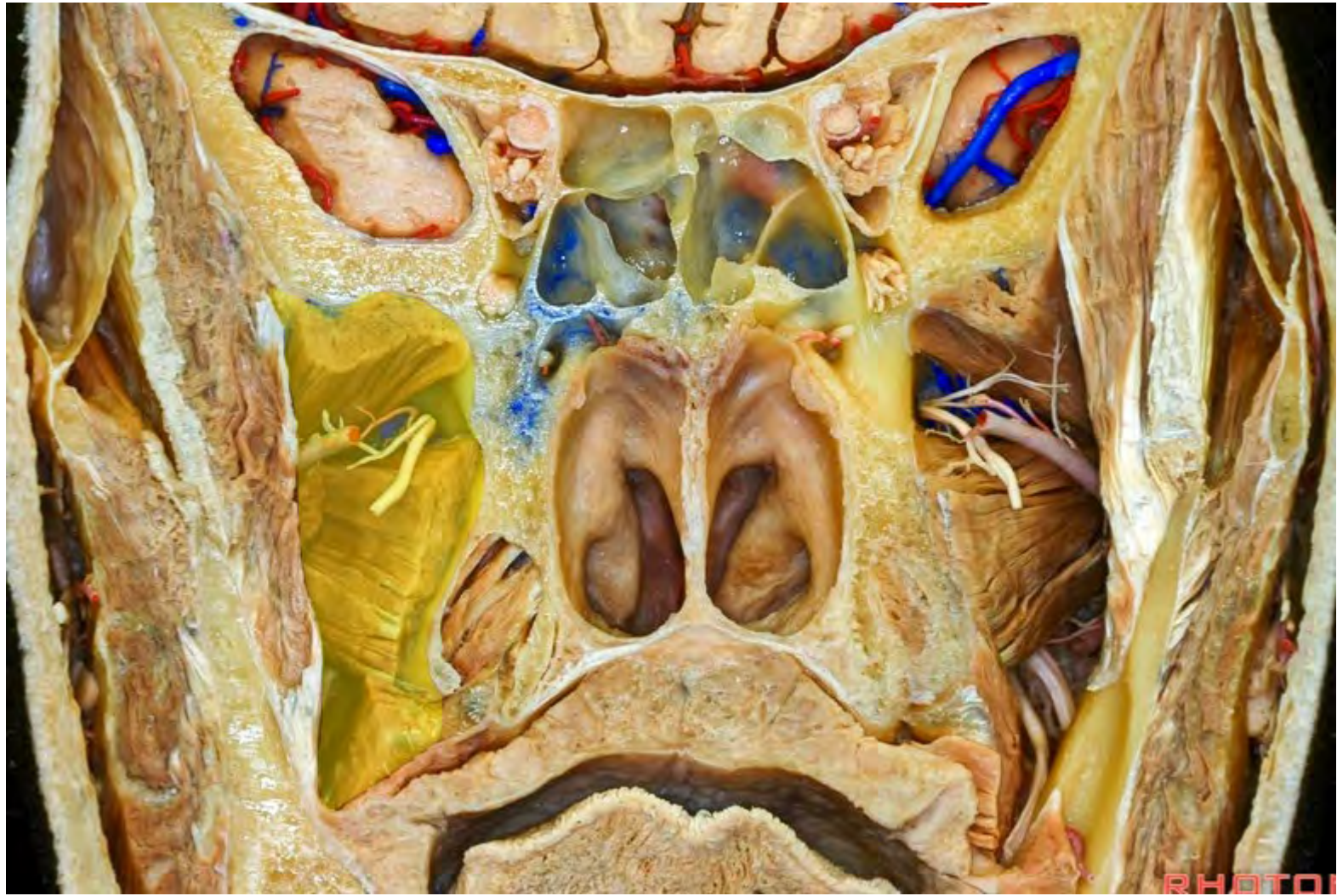

**Lesser wing of sphenoid**

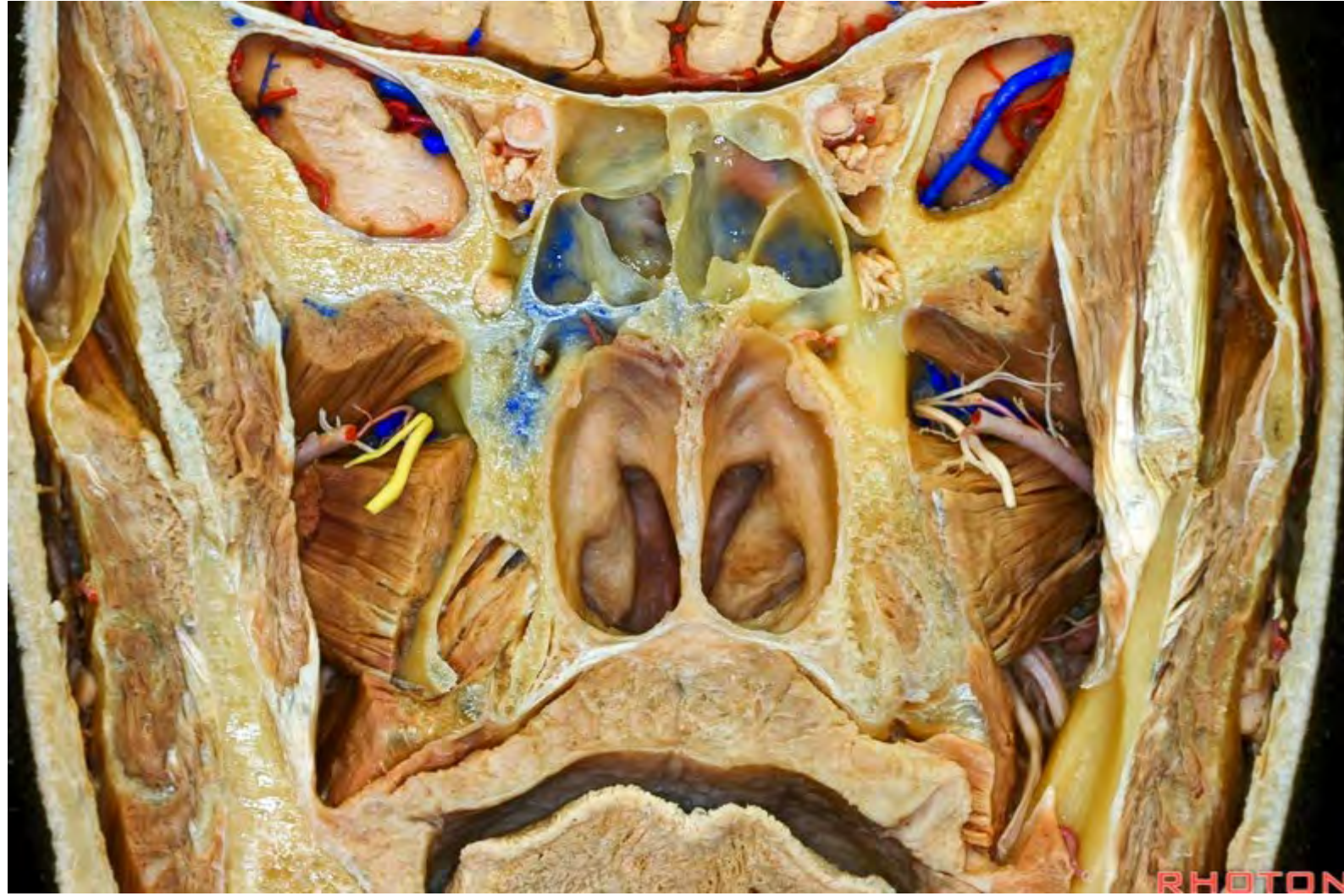

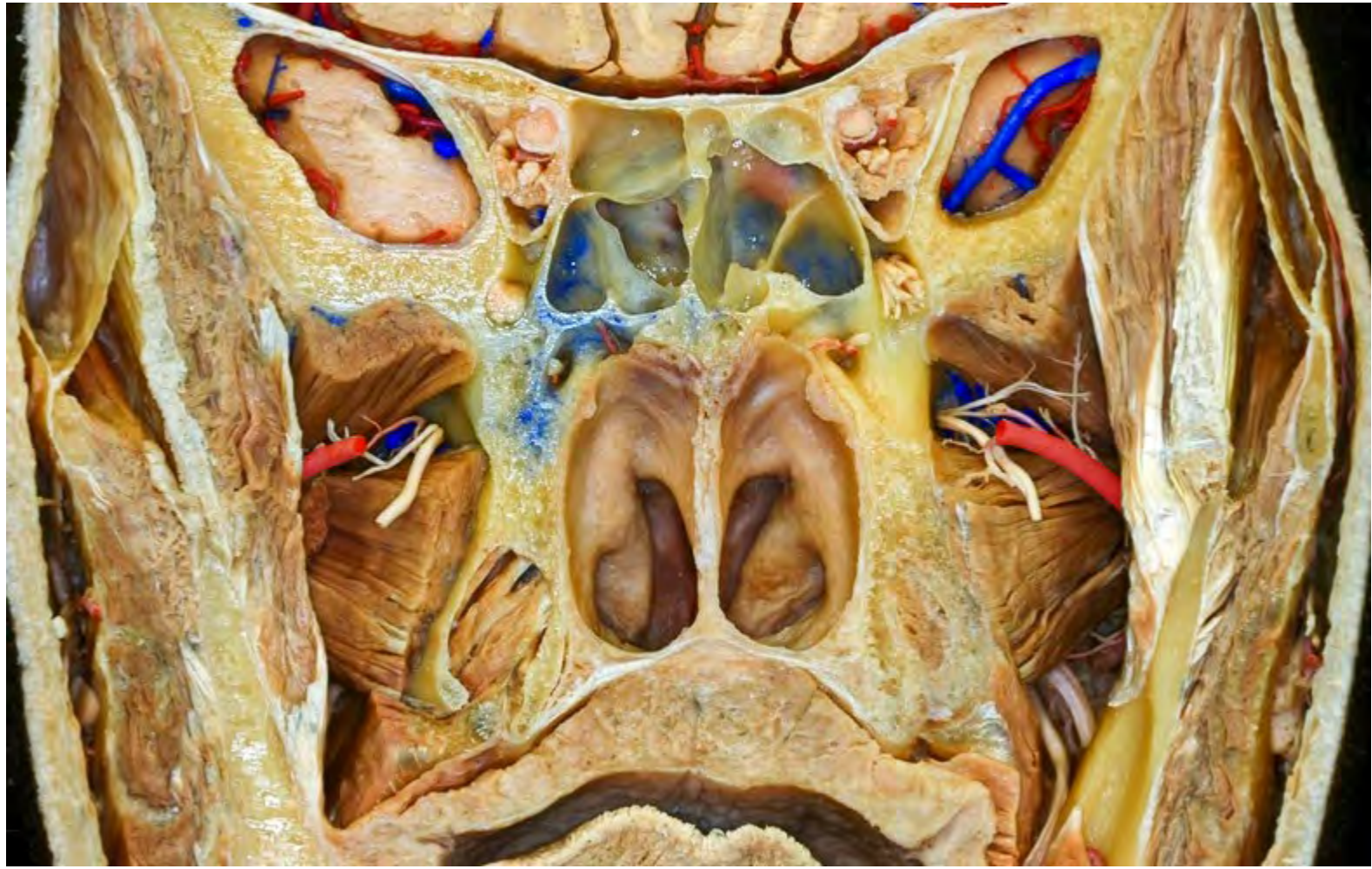


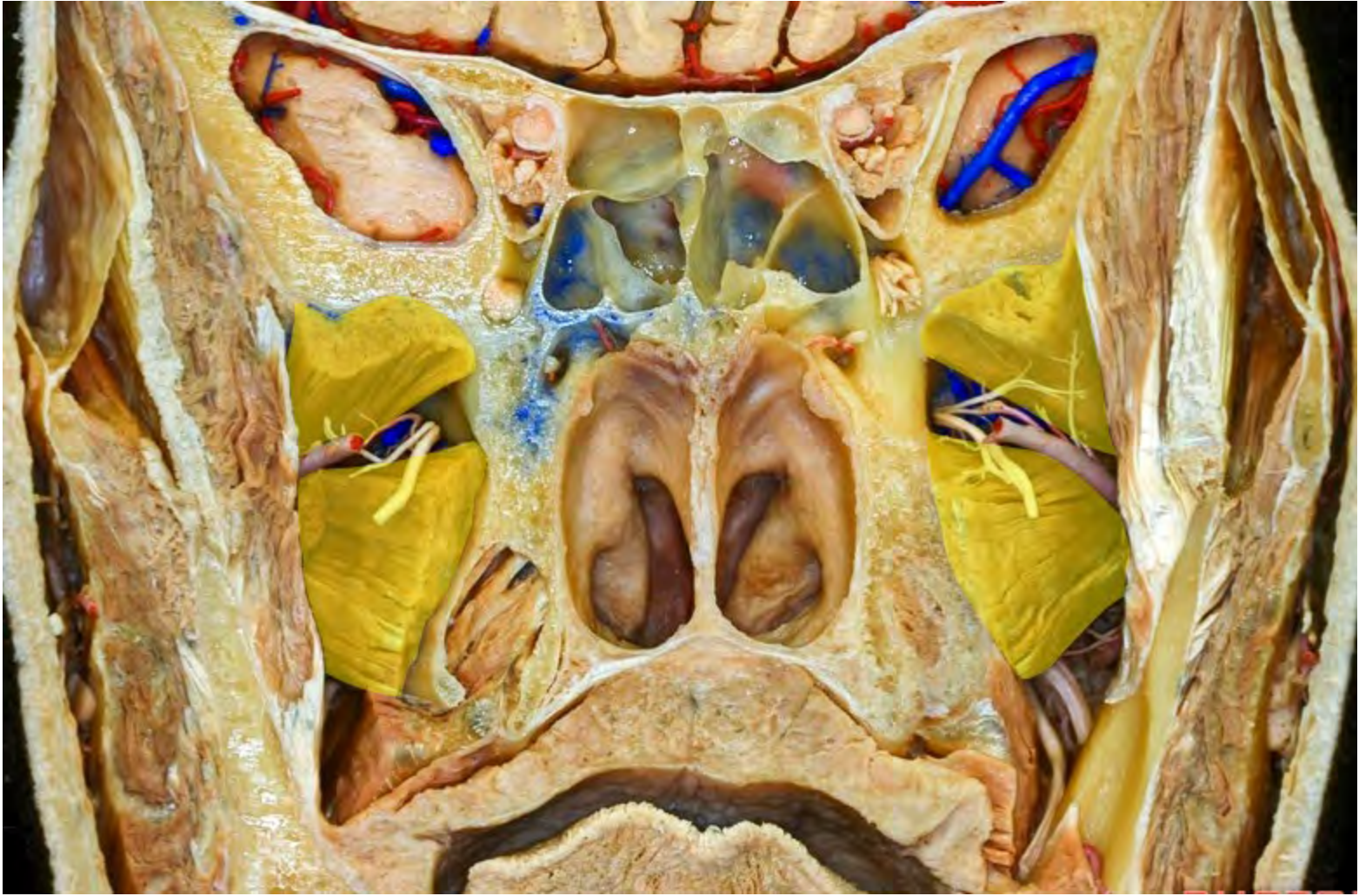PHOTON

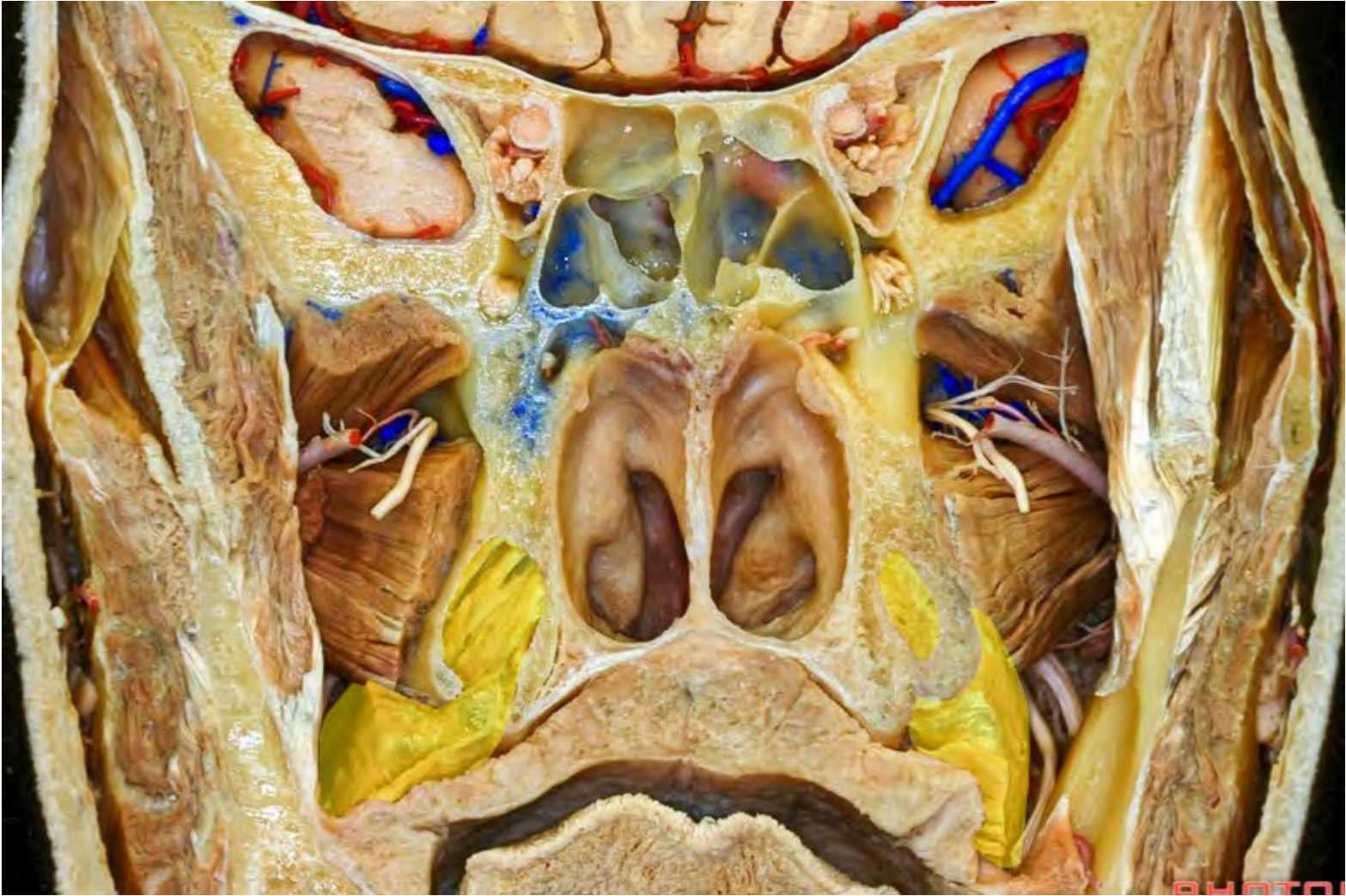


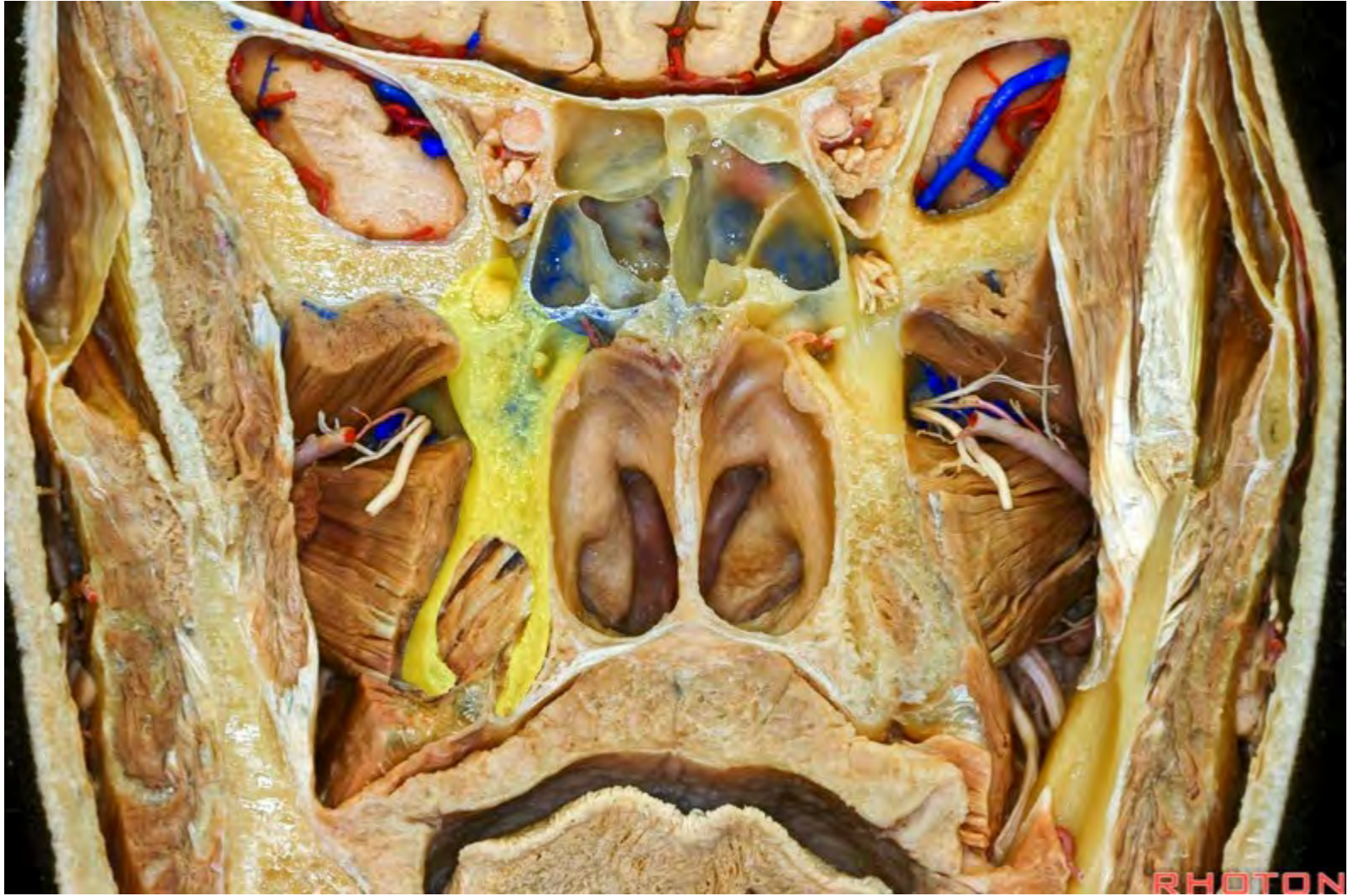


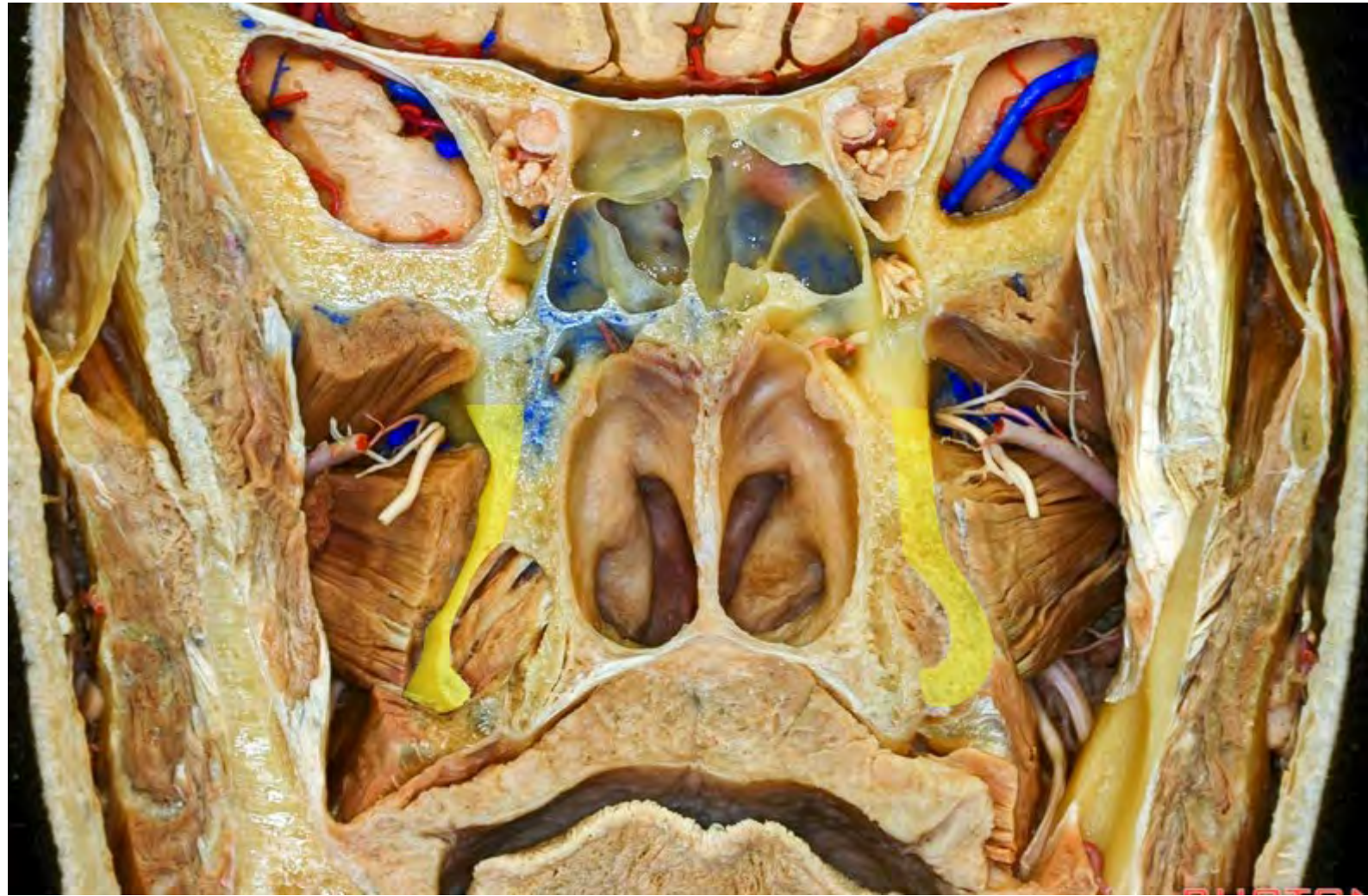




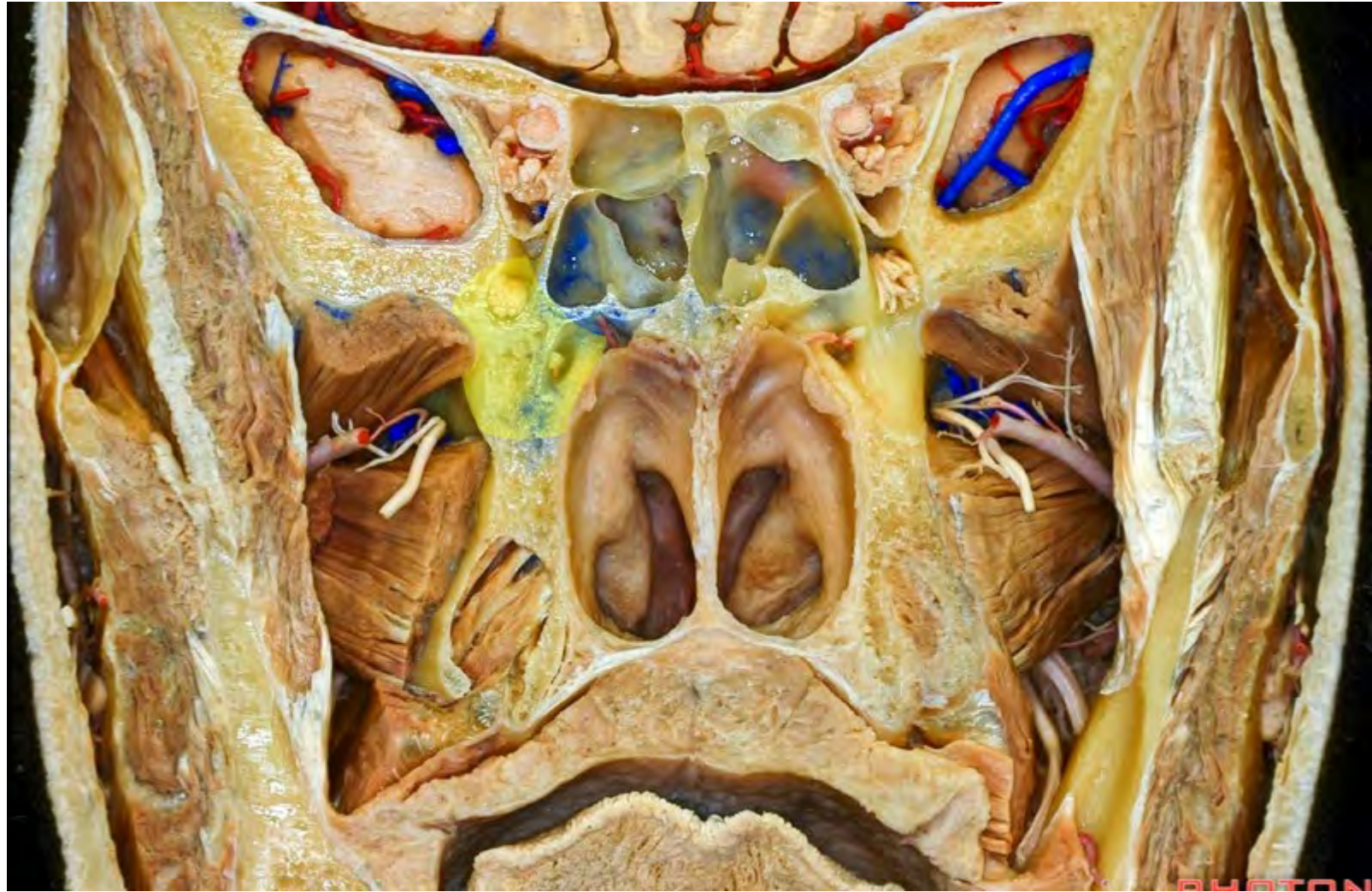



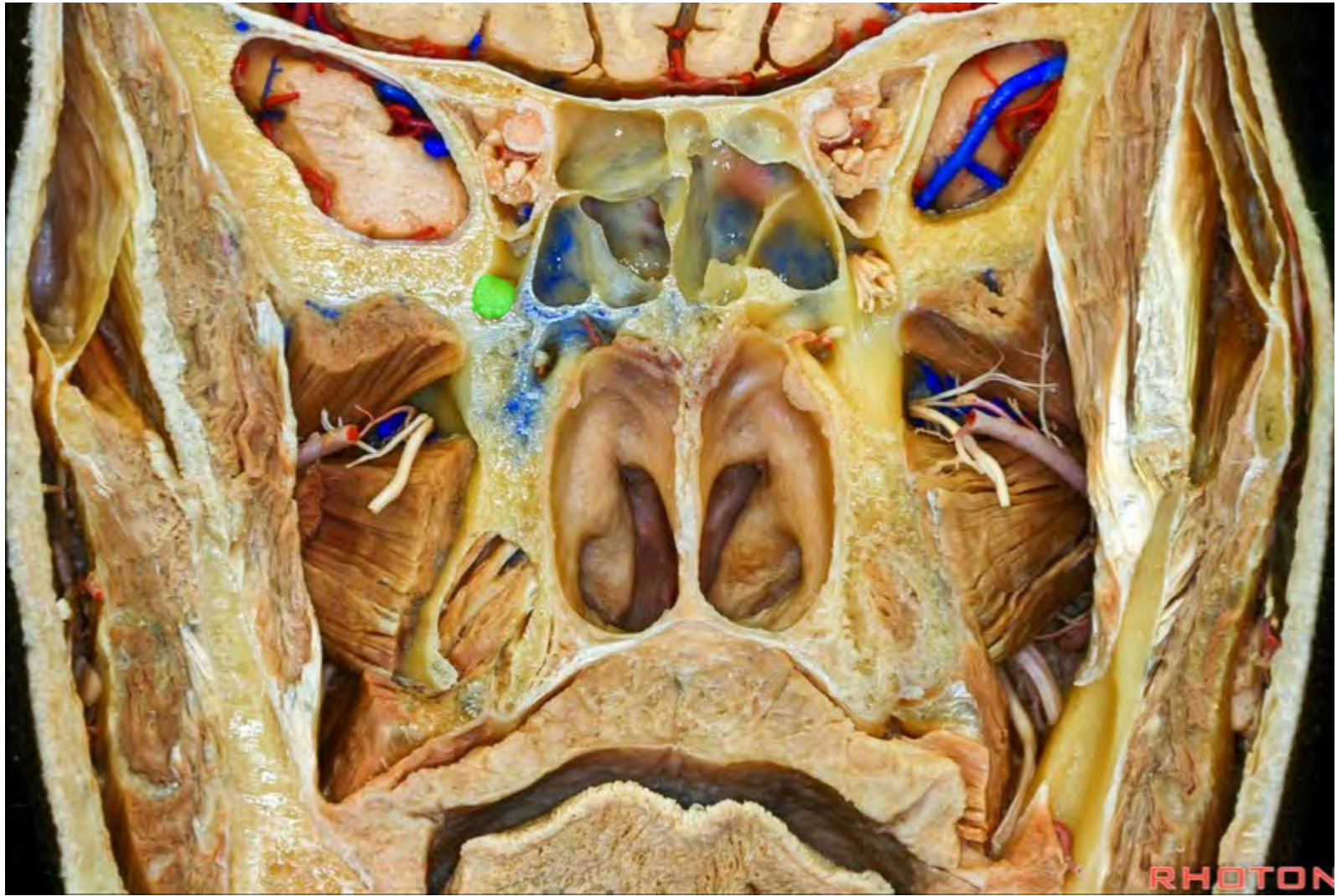RHOTO

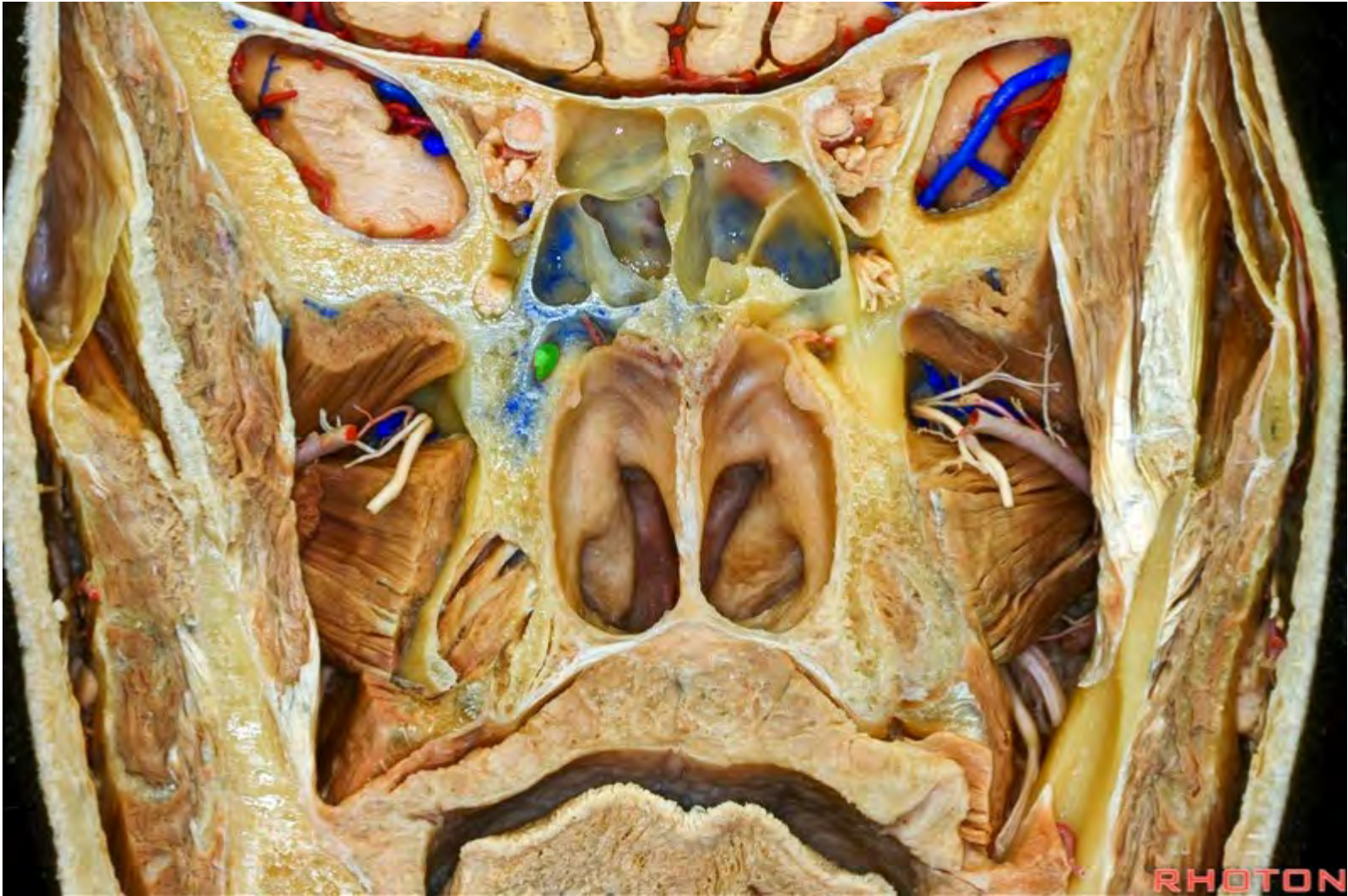


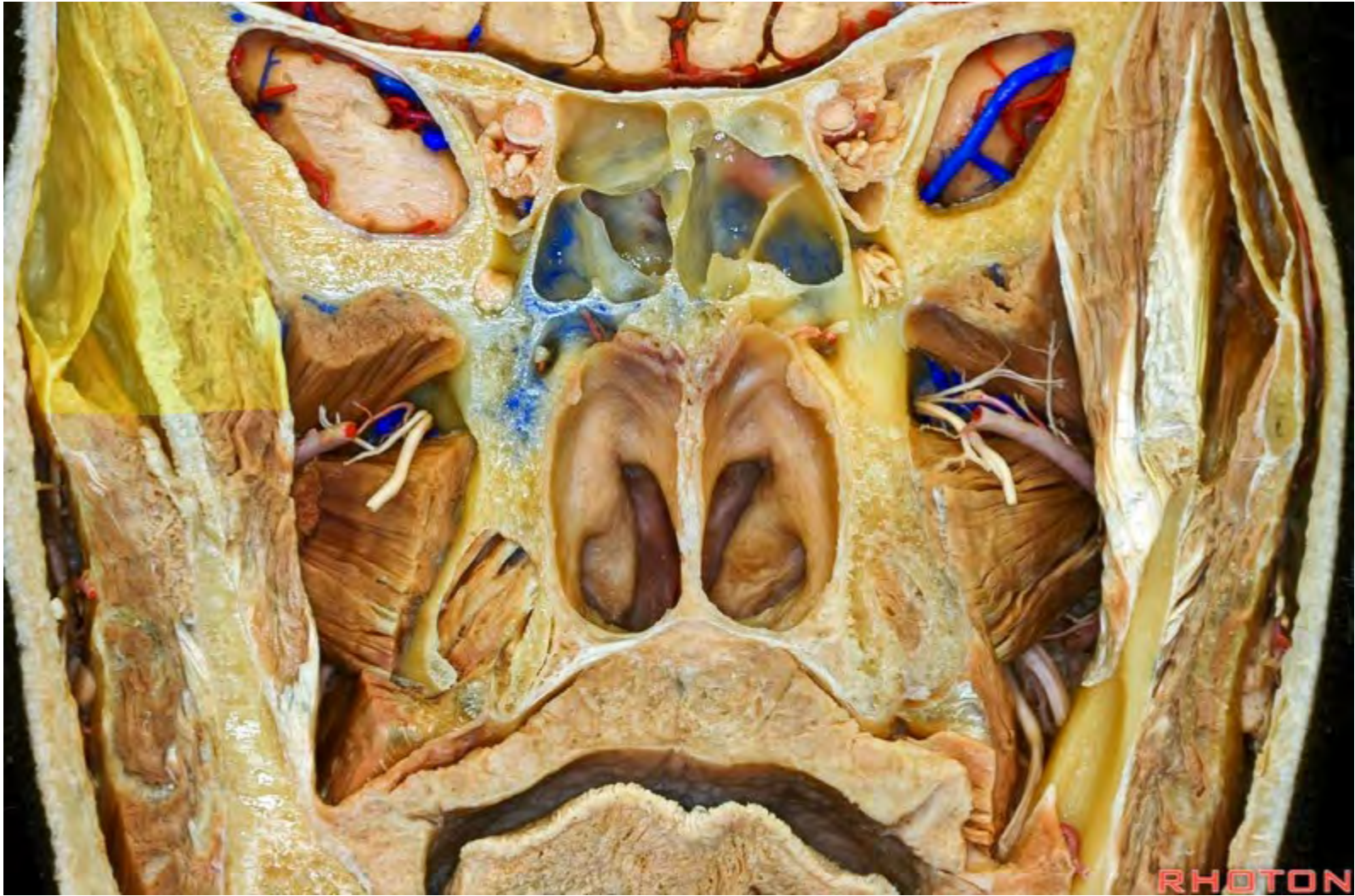
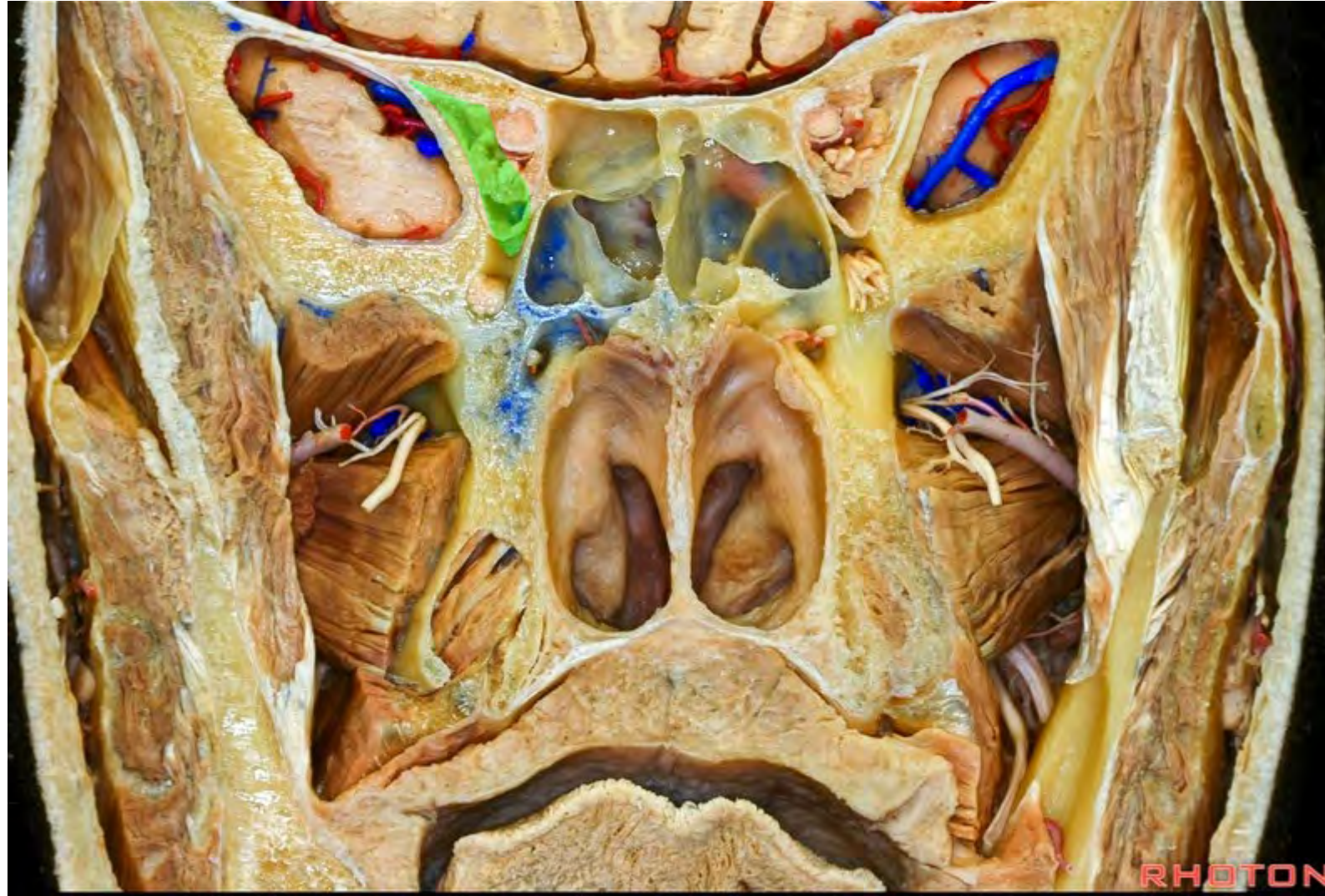PHOTON

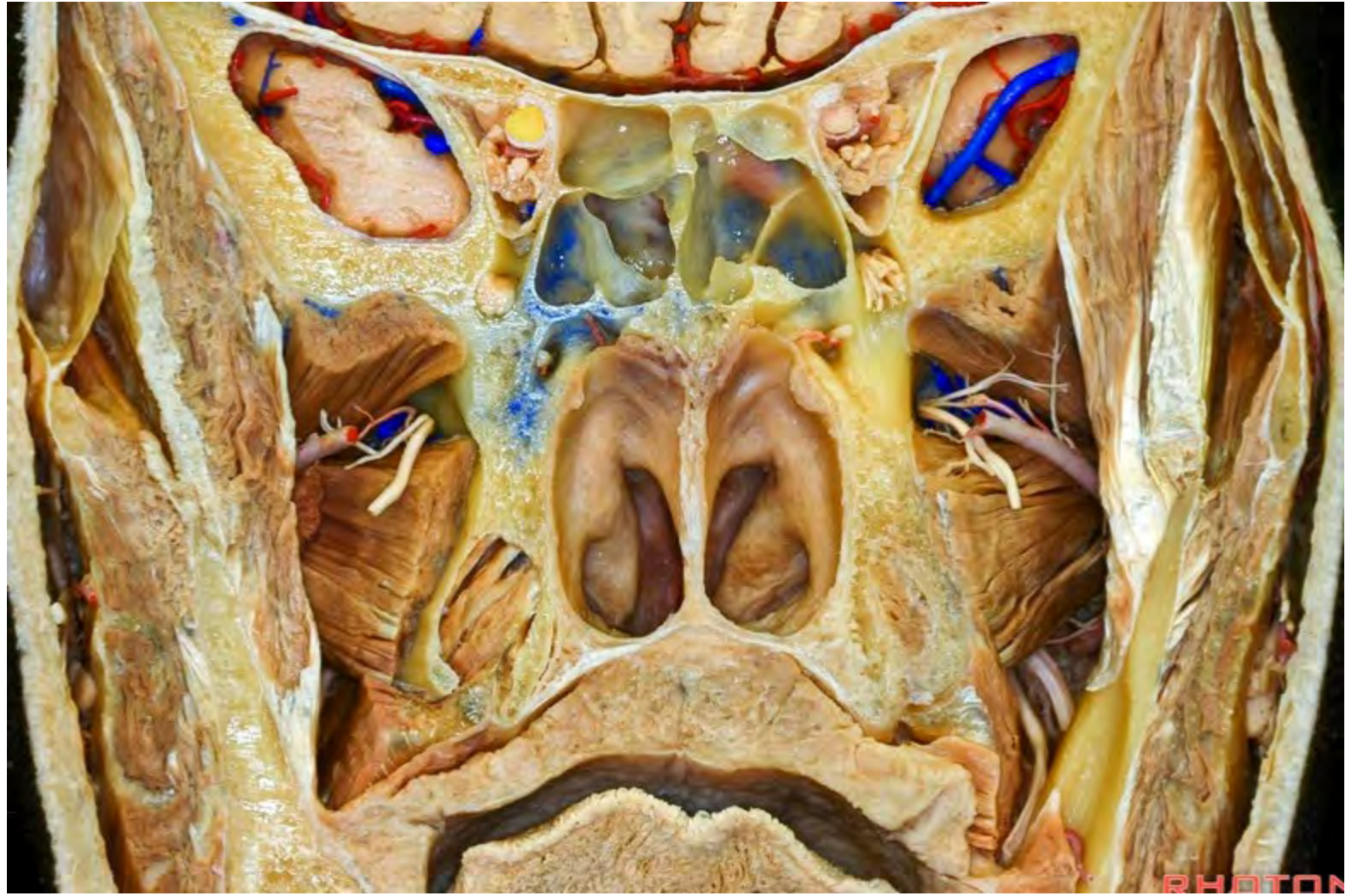

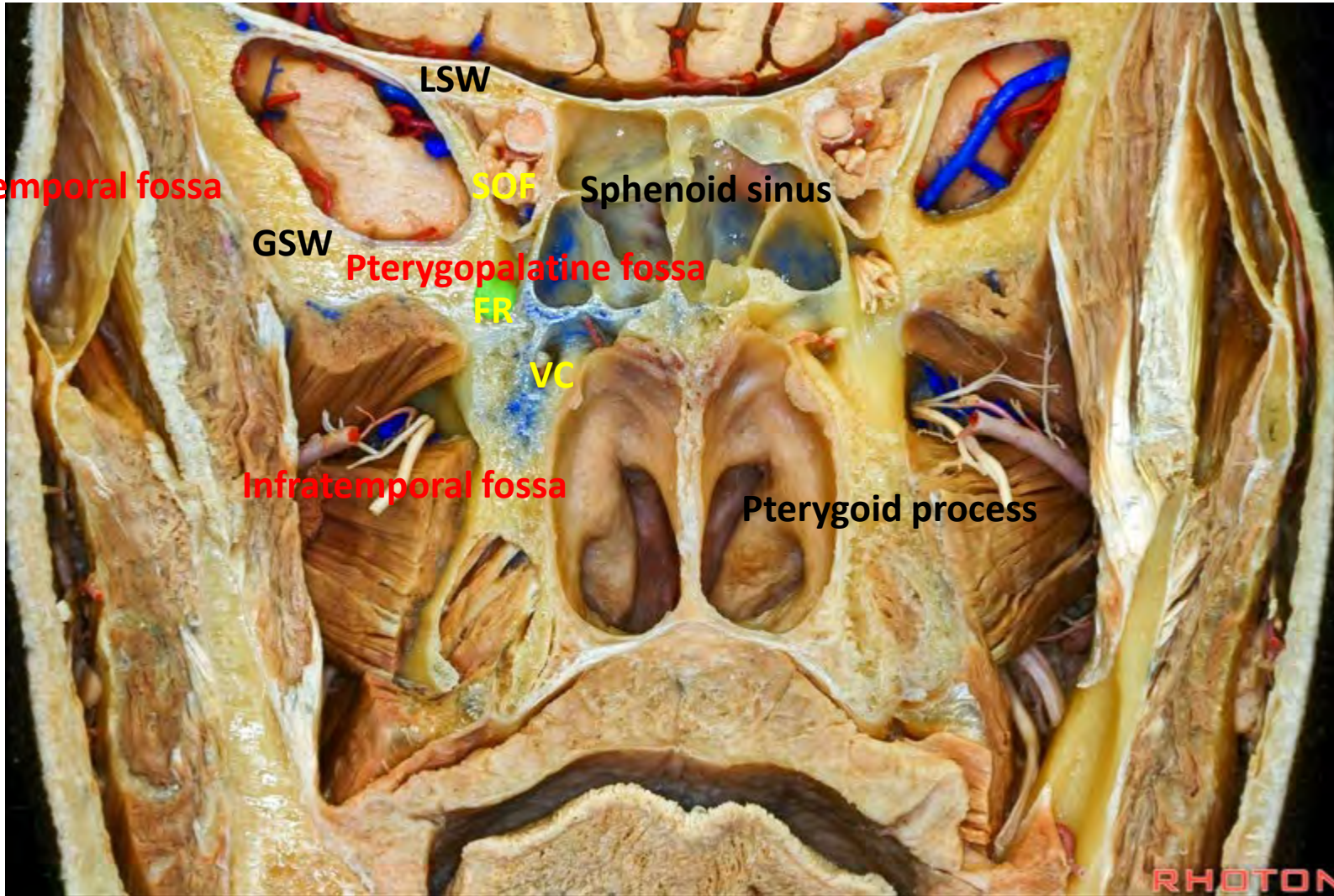


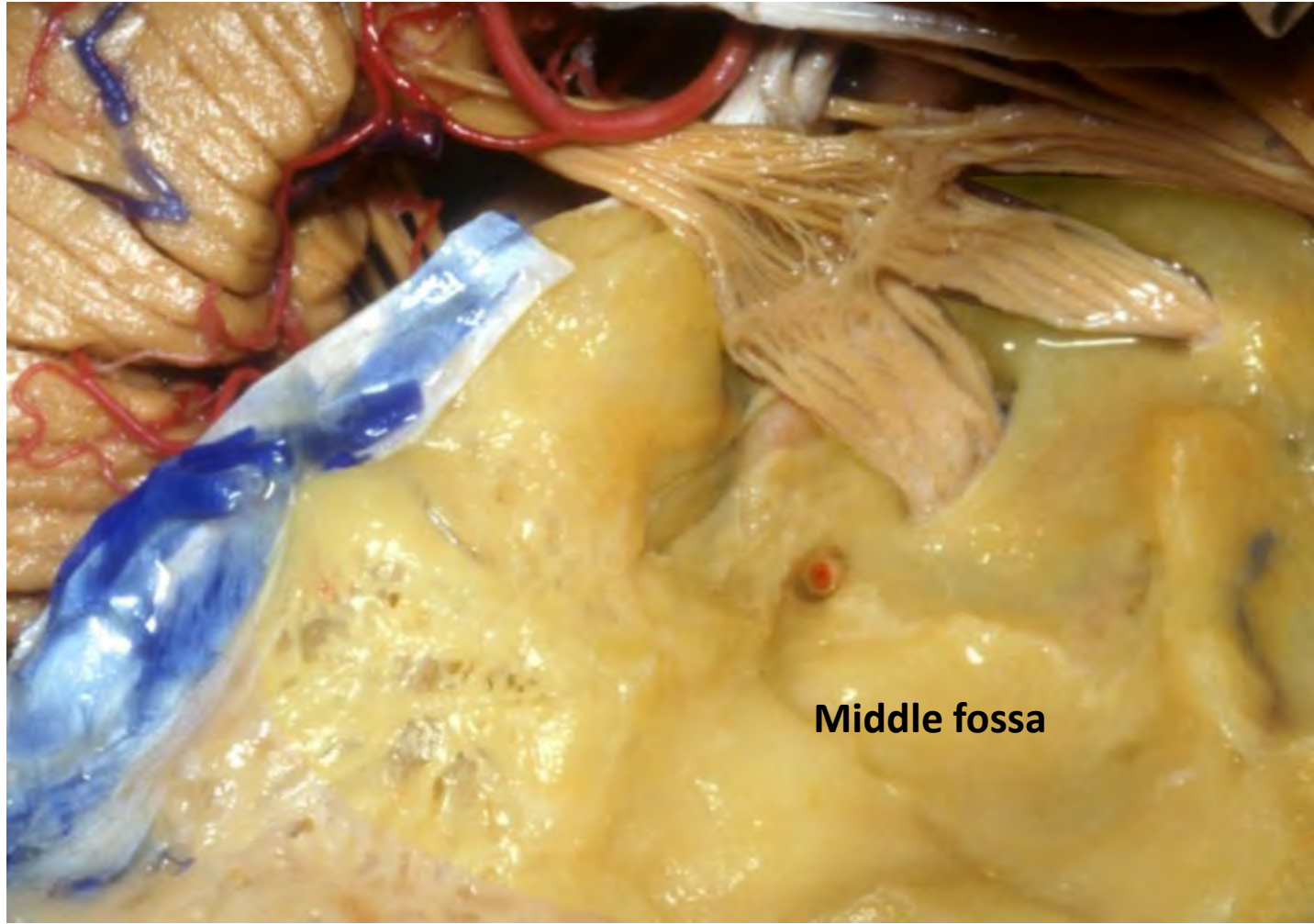




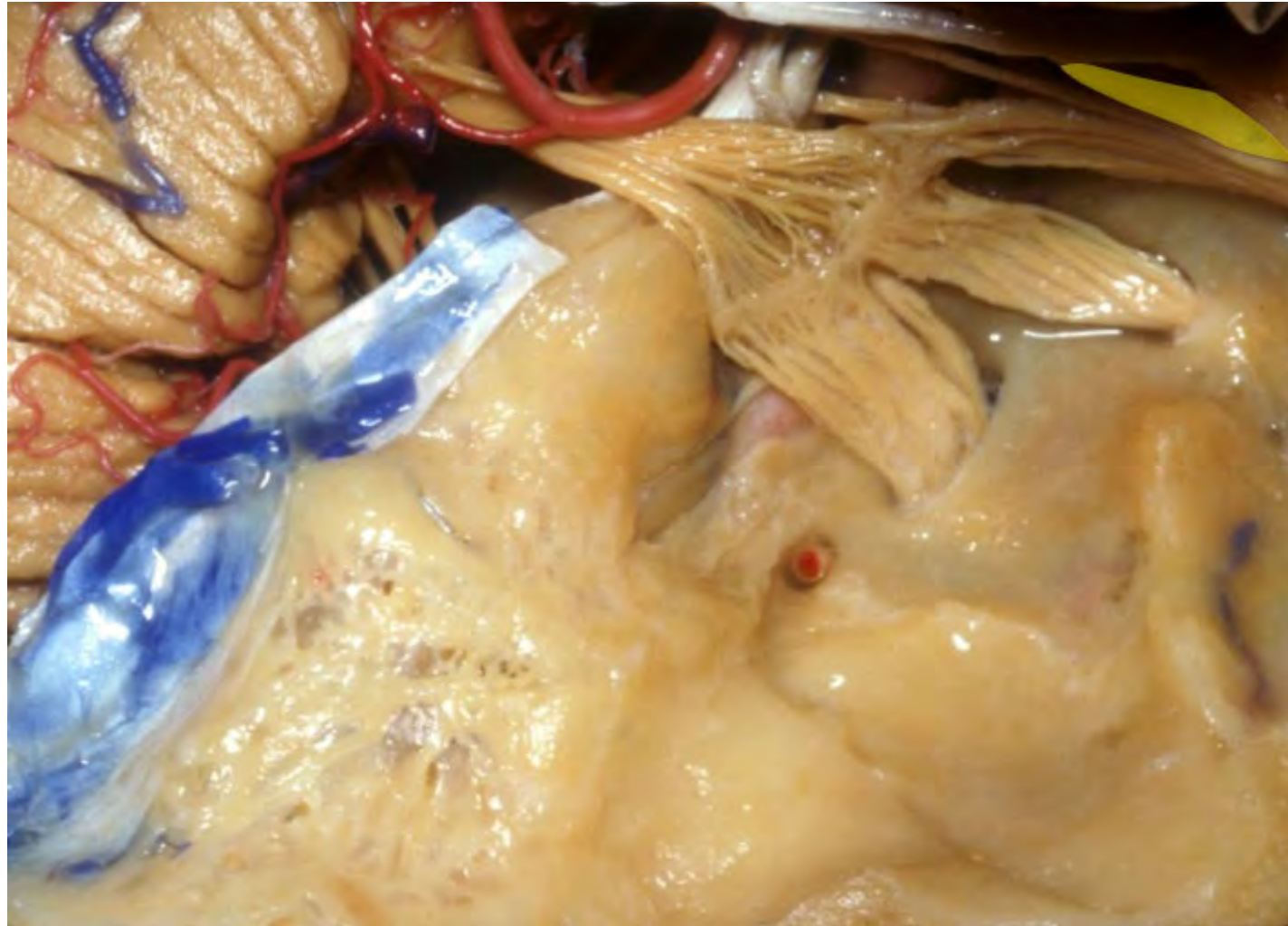


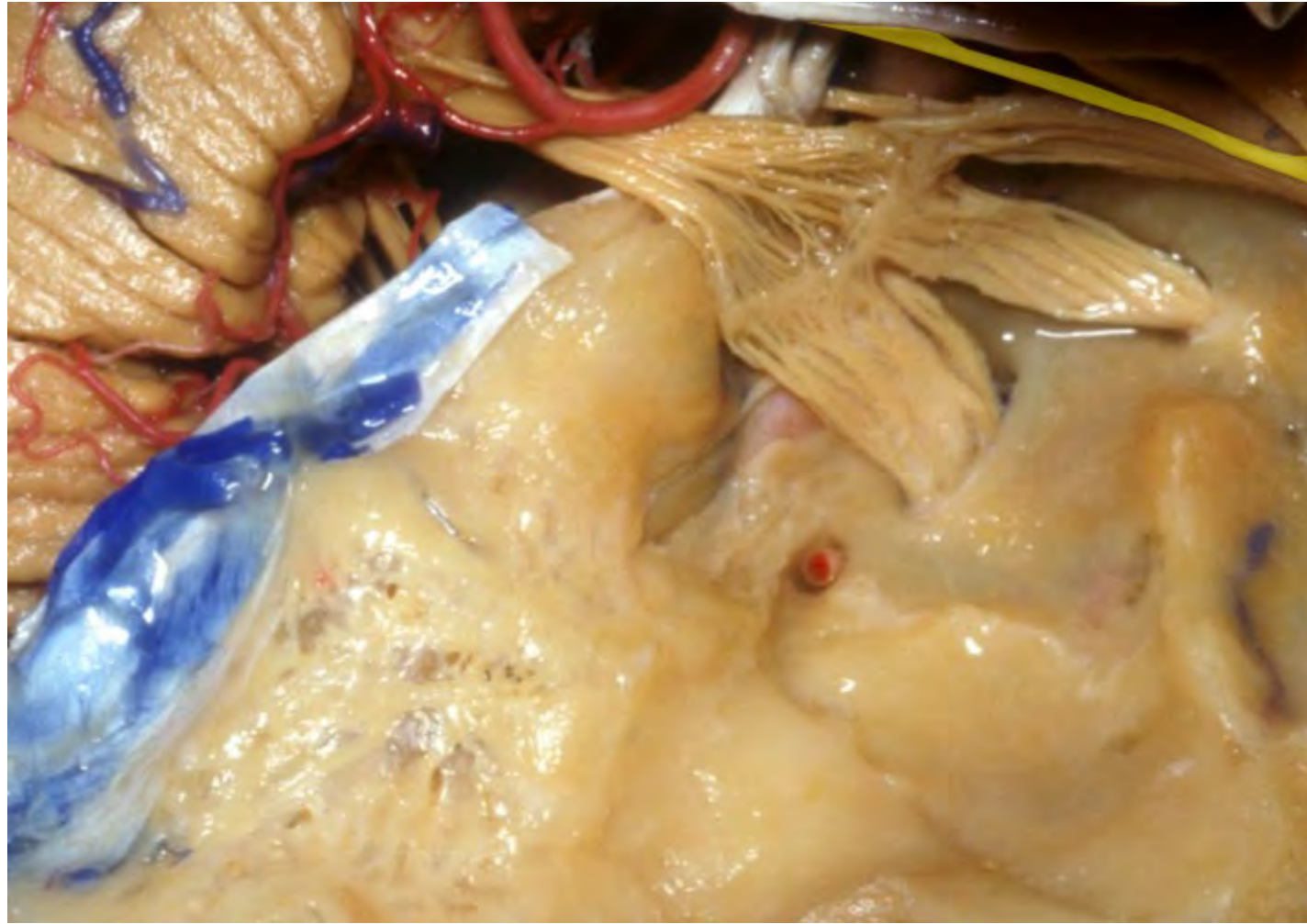




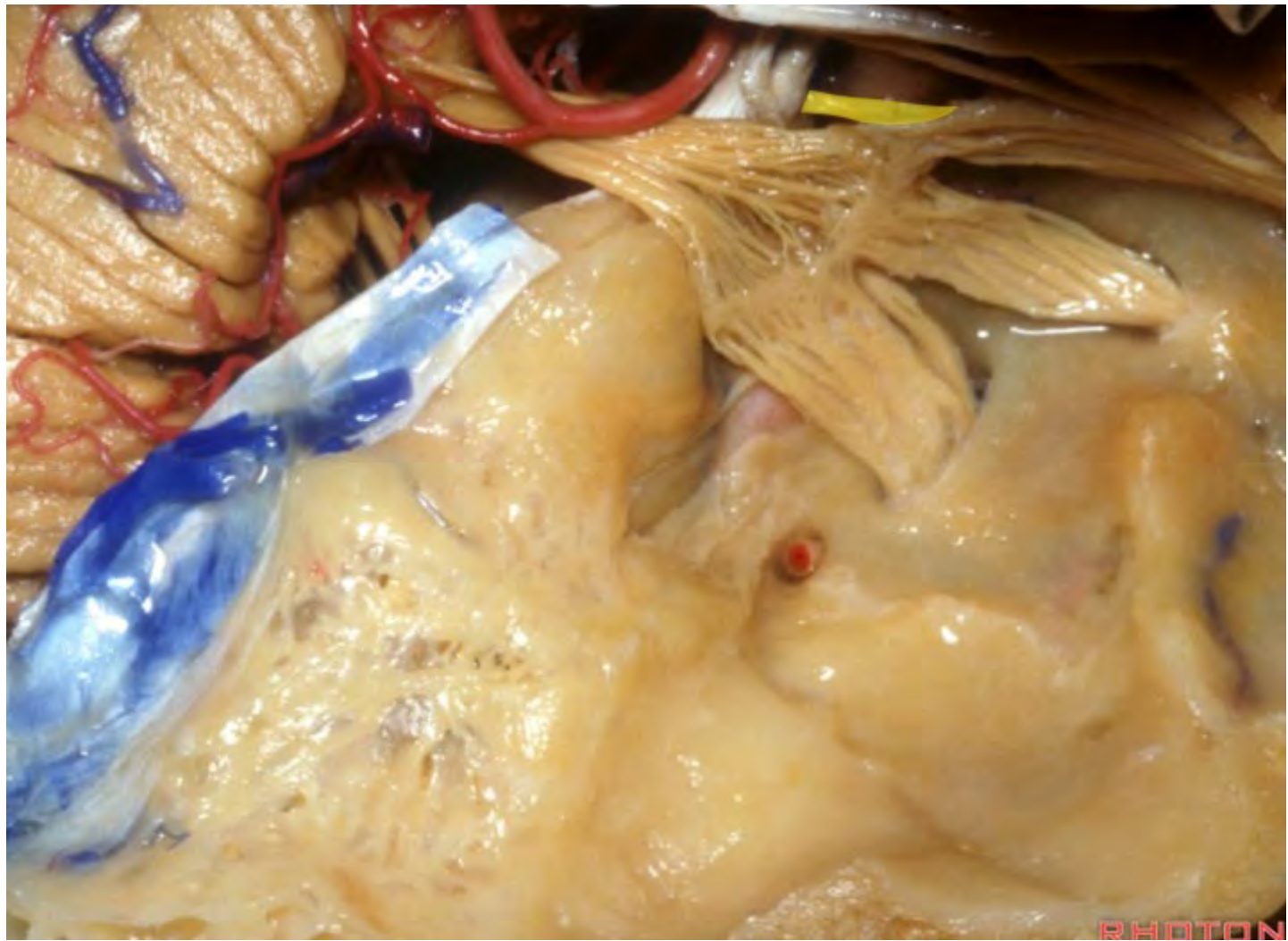


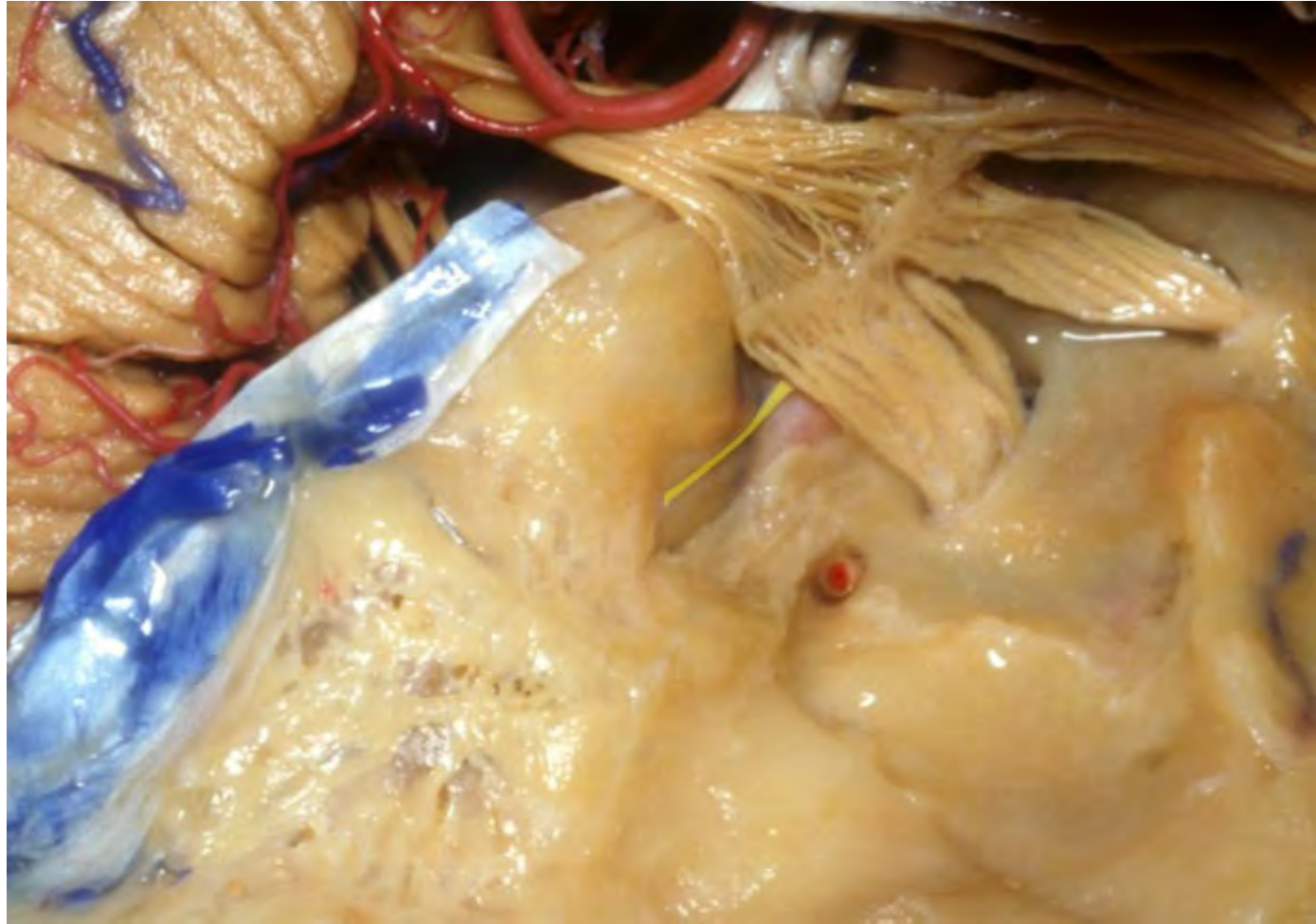**Middle fossa**

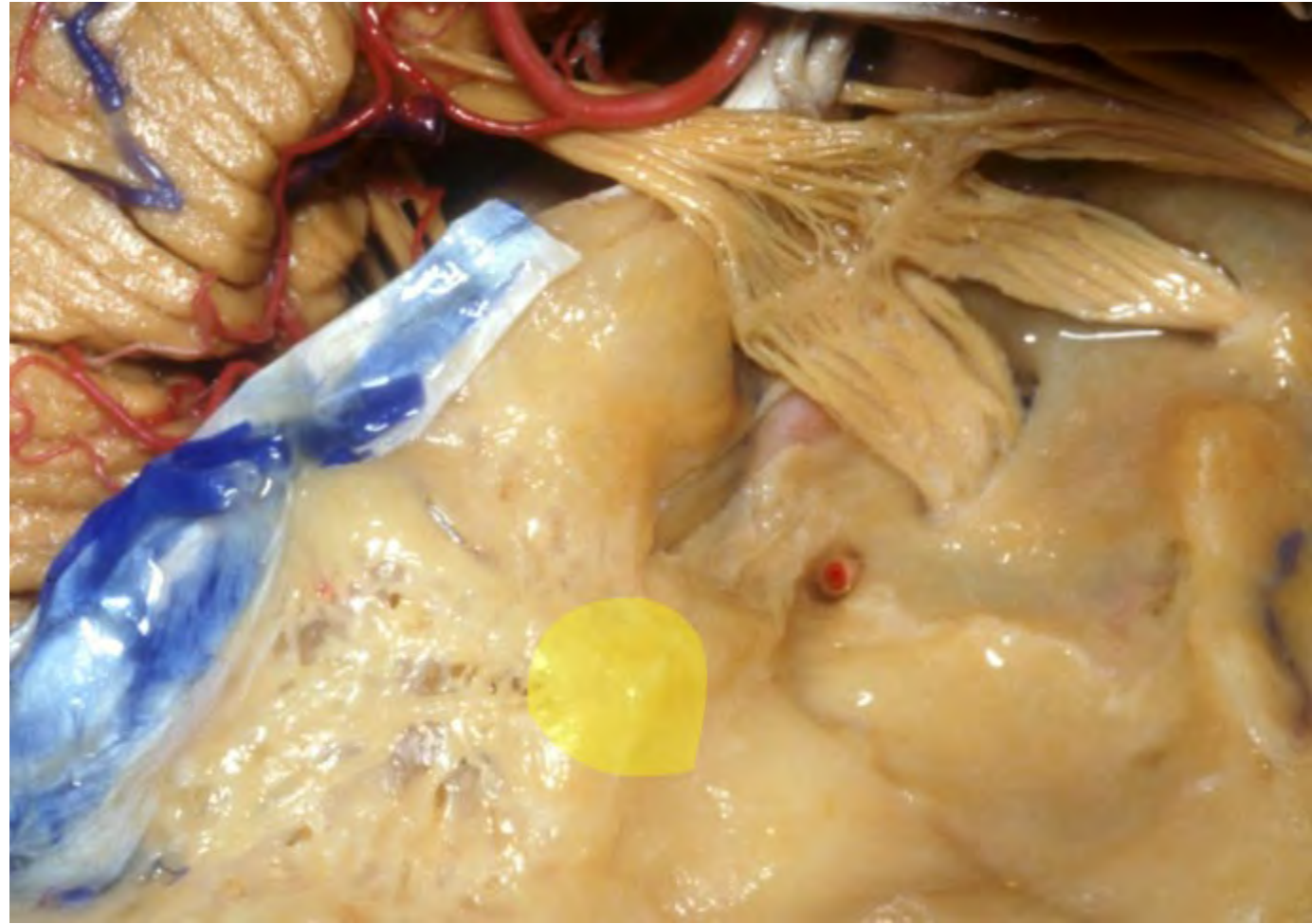




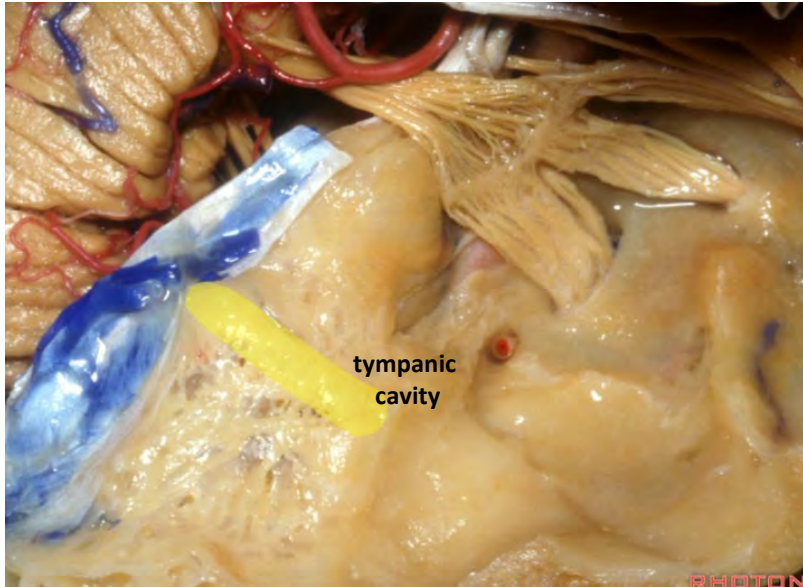




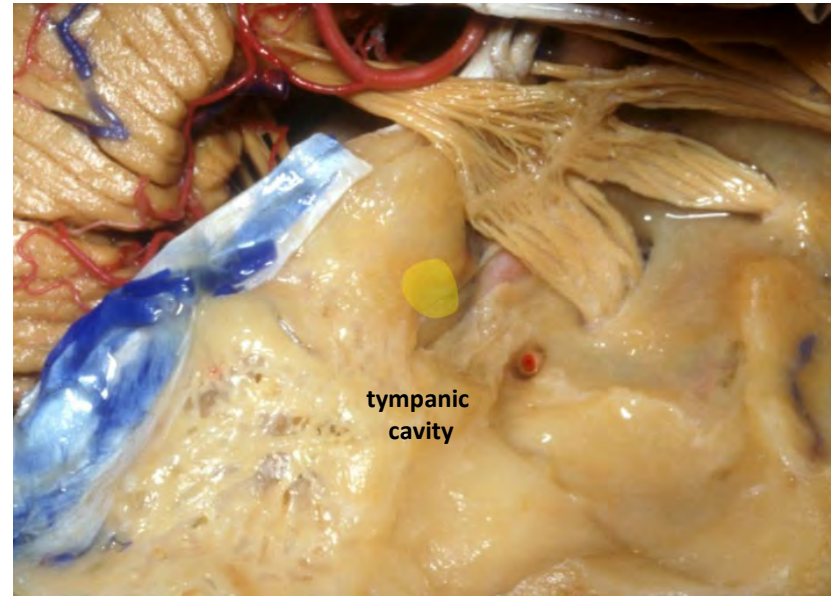




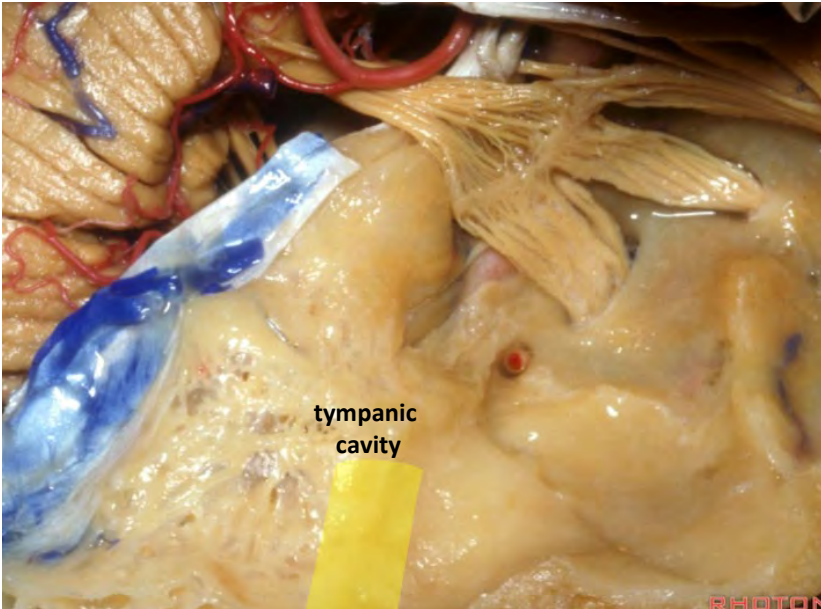
**Arcuate eminence**



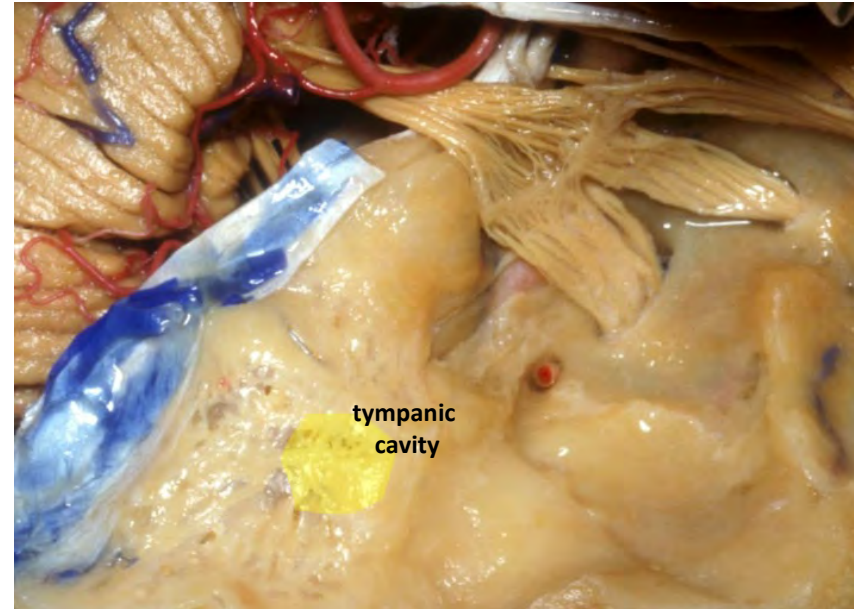
**Cochlea**



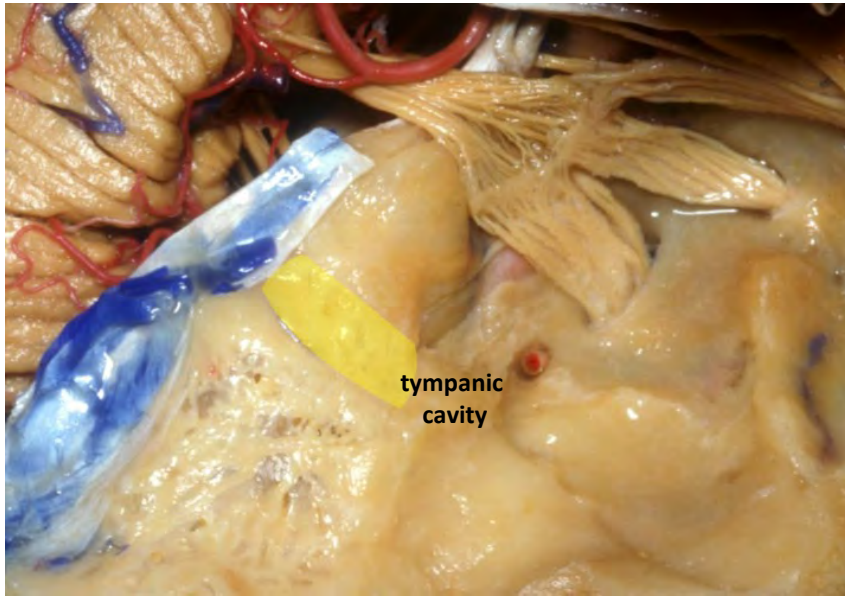
**External aud. canal**



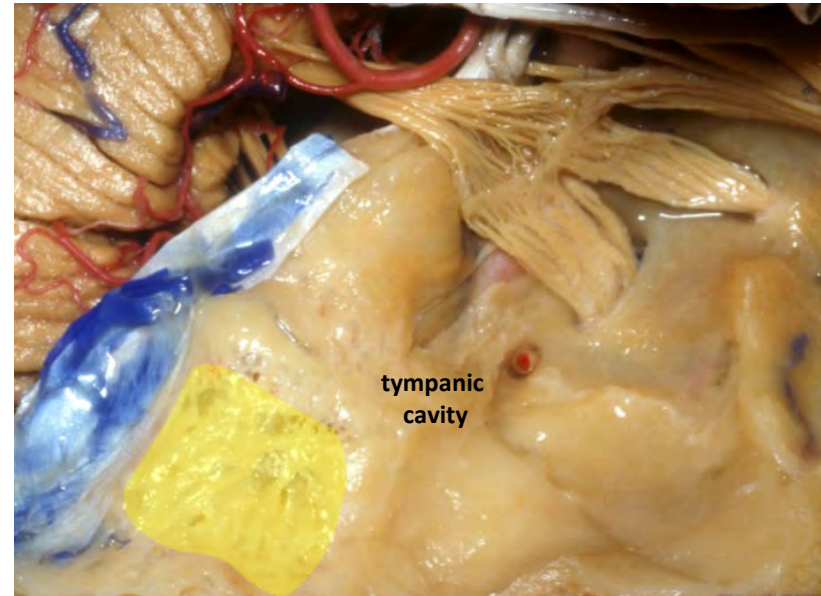
**Mastoid antrum**



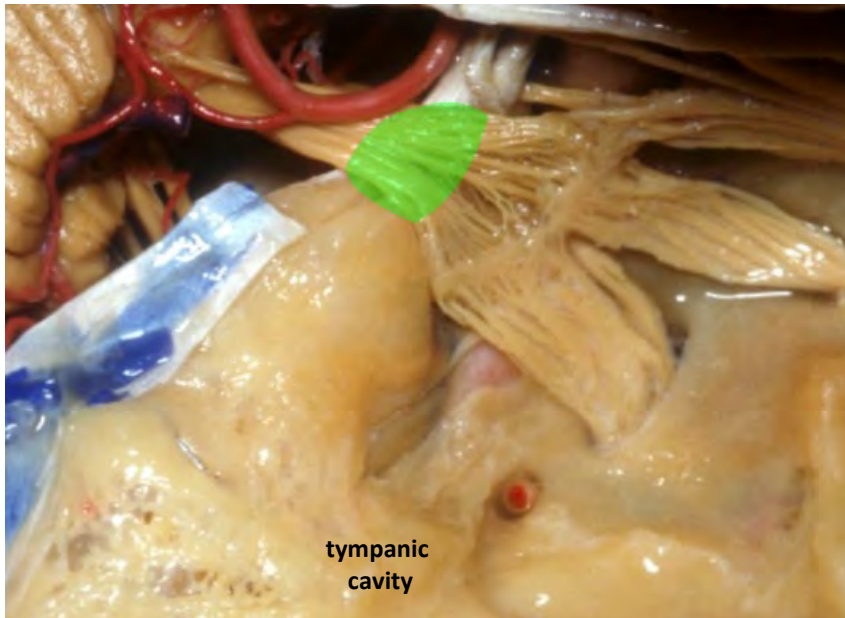
**Meatal depression**



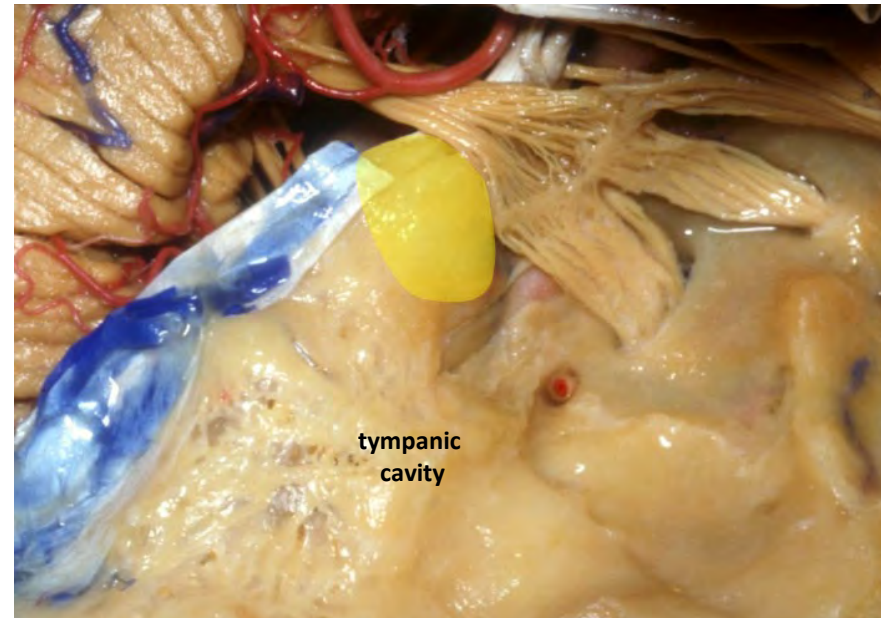
**Tegmen**



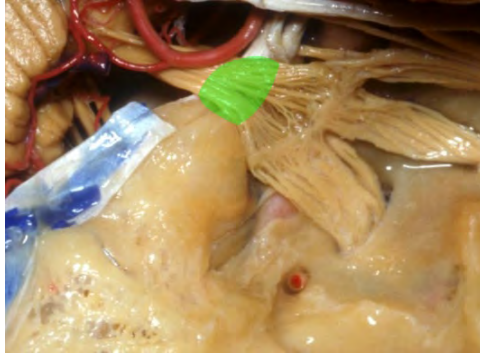
**Trigeminal depression**



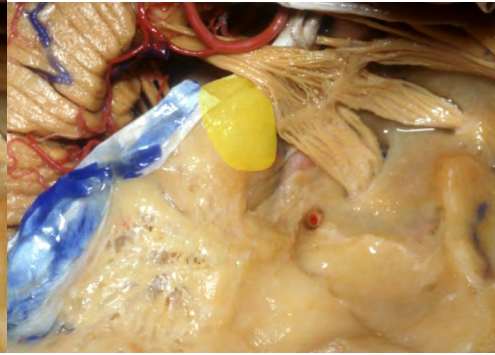
**Trigeminal prominence**



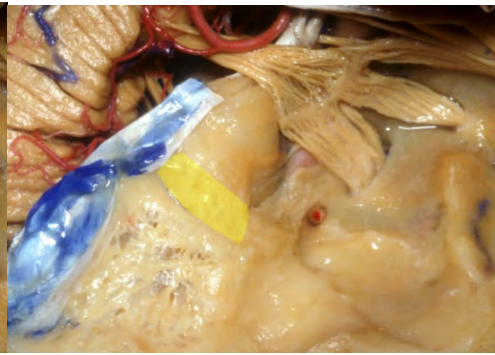
Trigeminal depression



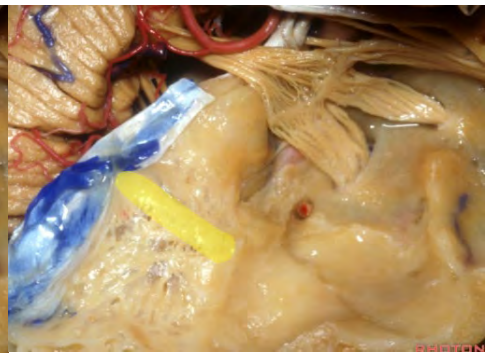
Trigeminal prominence



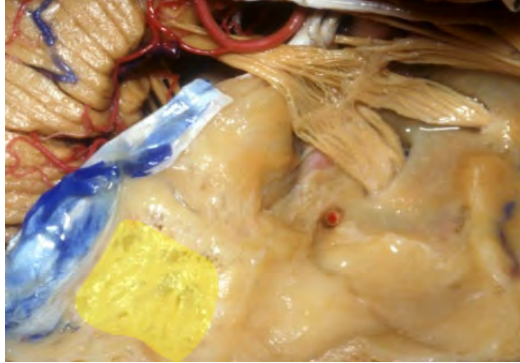
Meatal depression



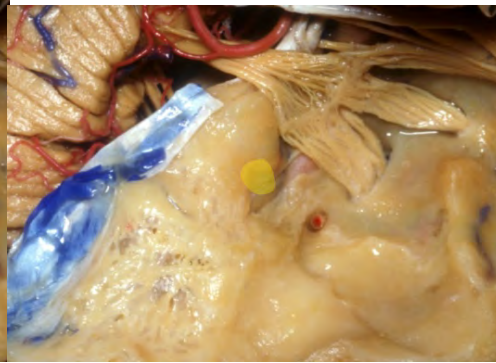Arcuate eminence



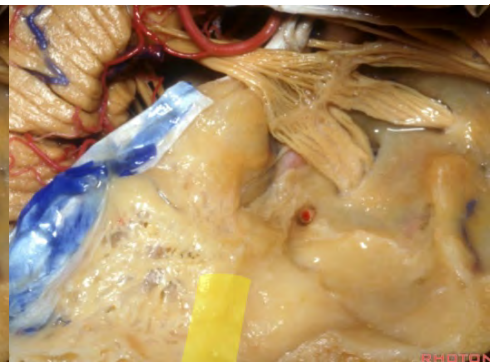
Tegmen



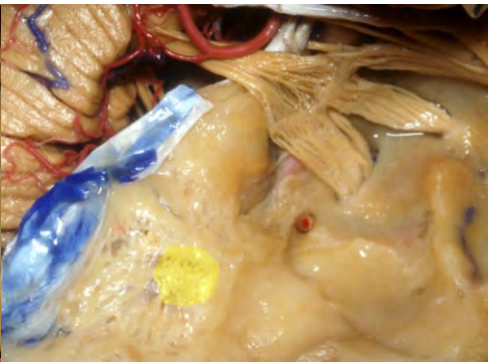
Cochlea

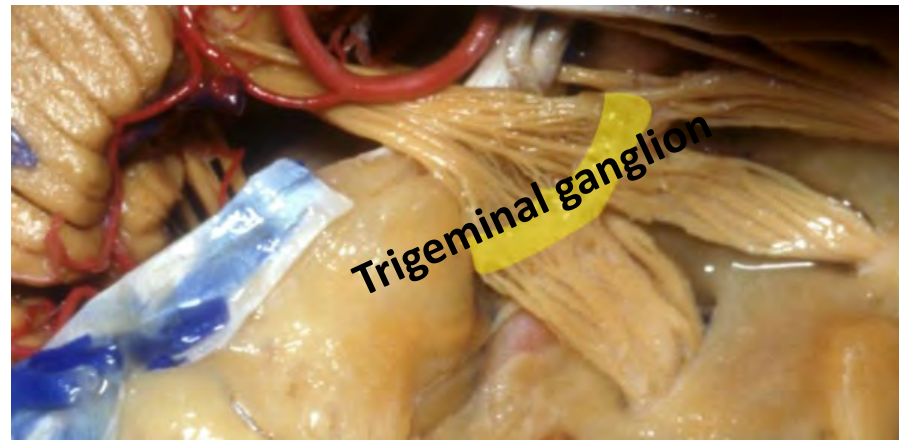
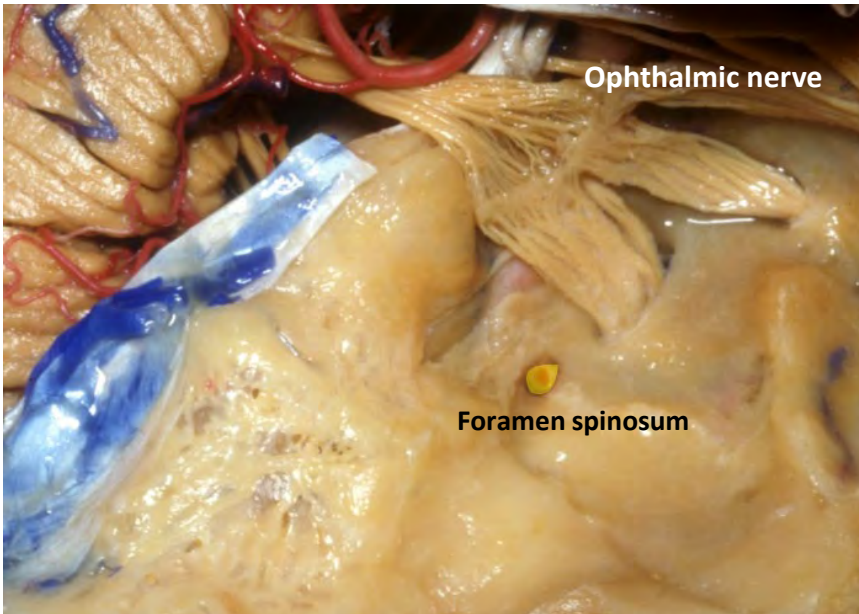
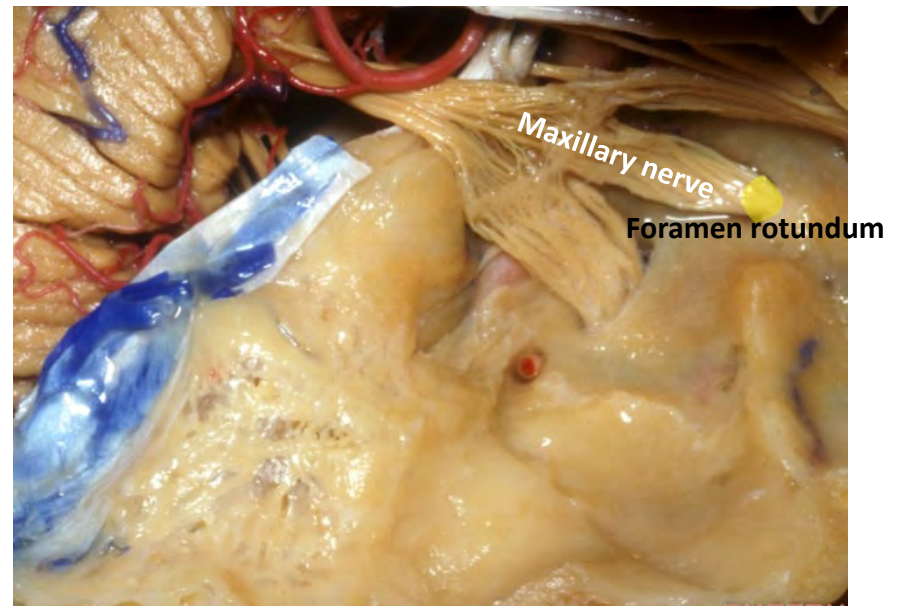
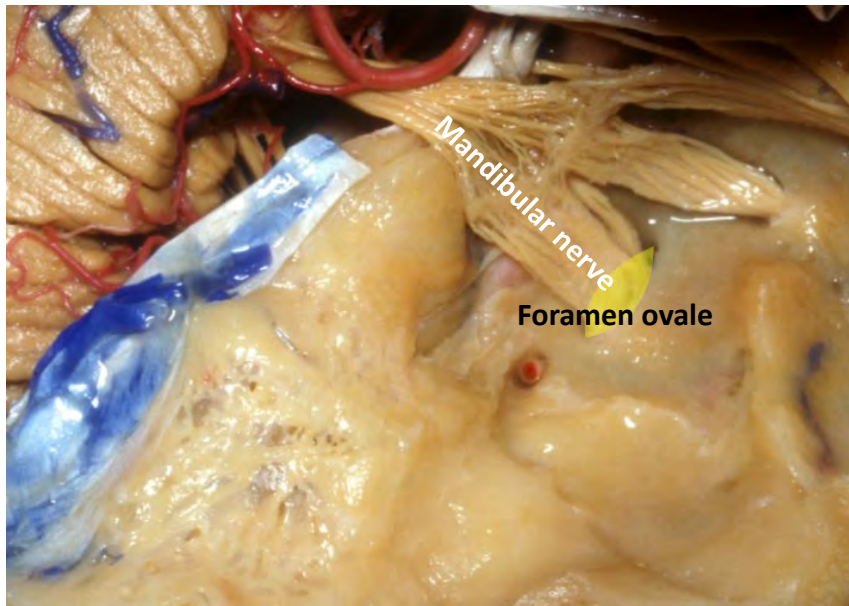


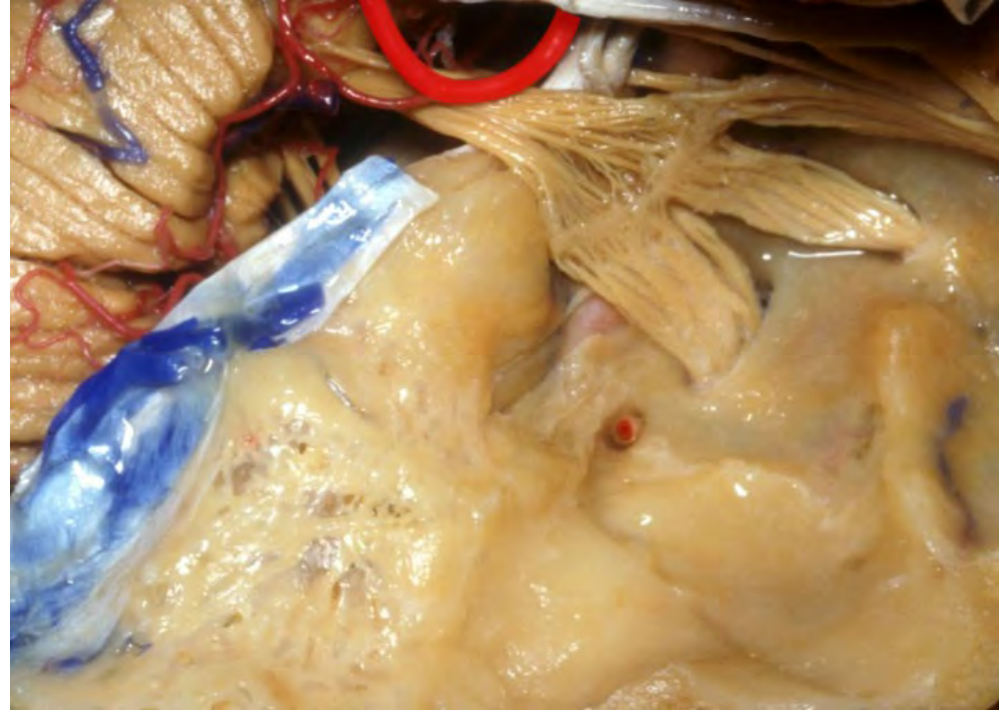
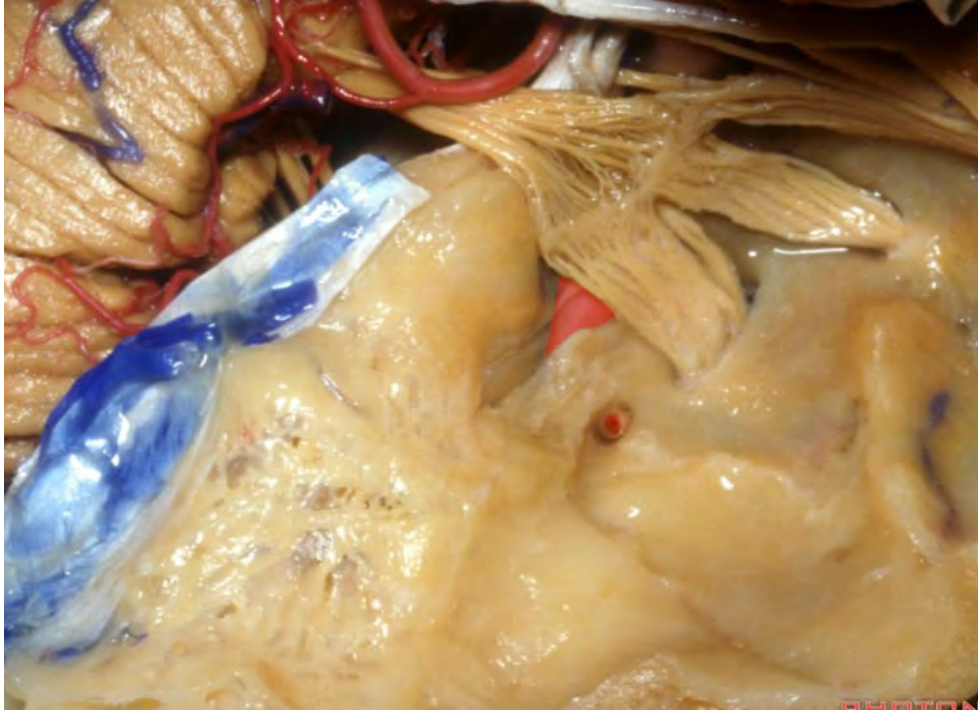
External aud. canal



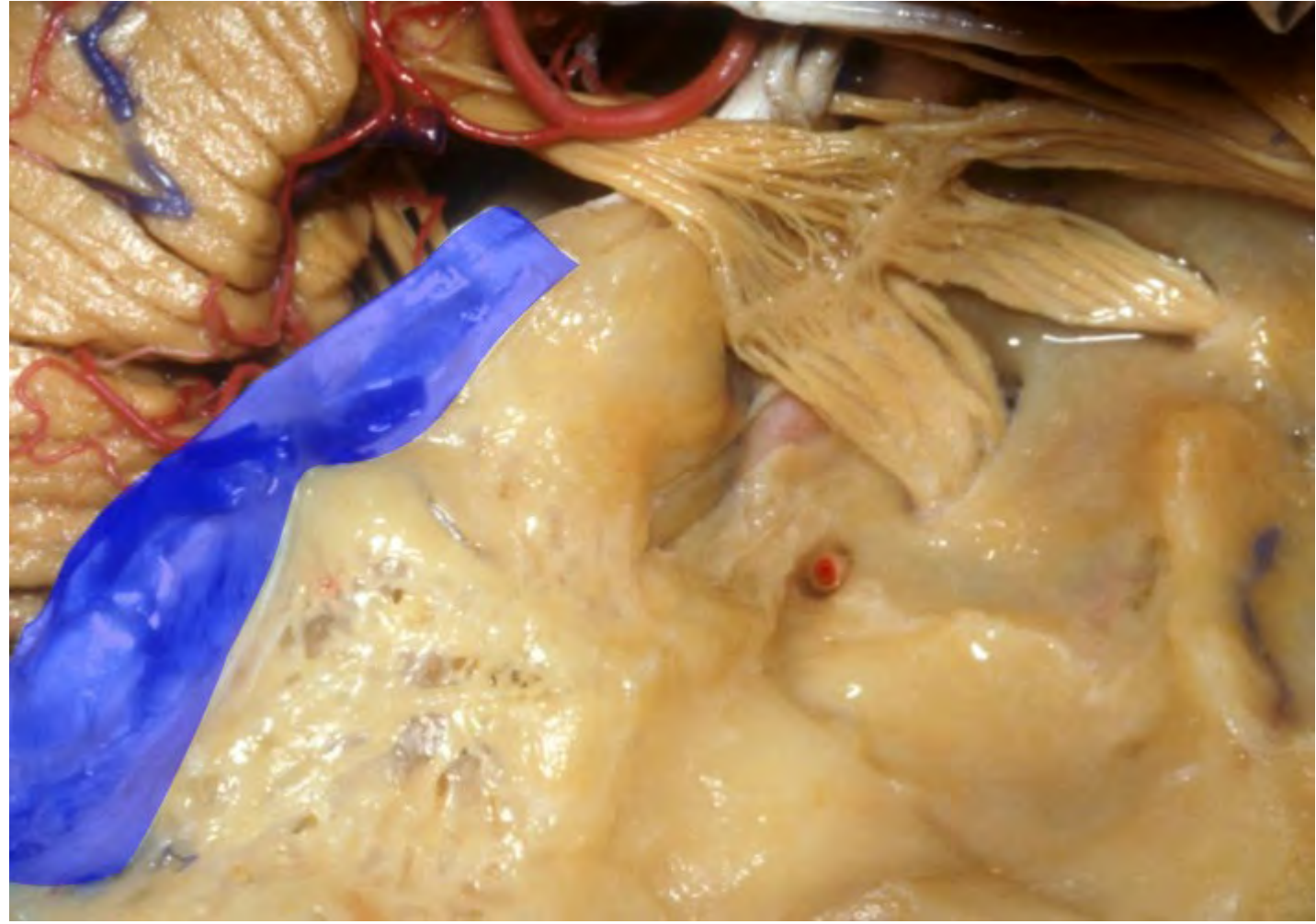
Mastoid antrum

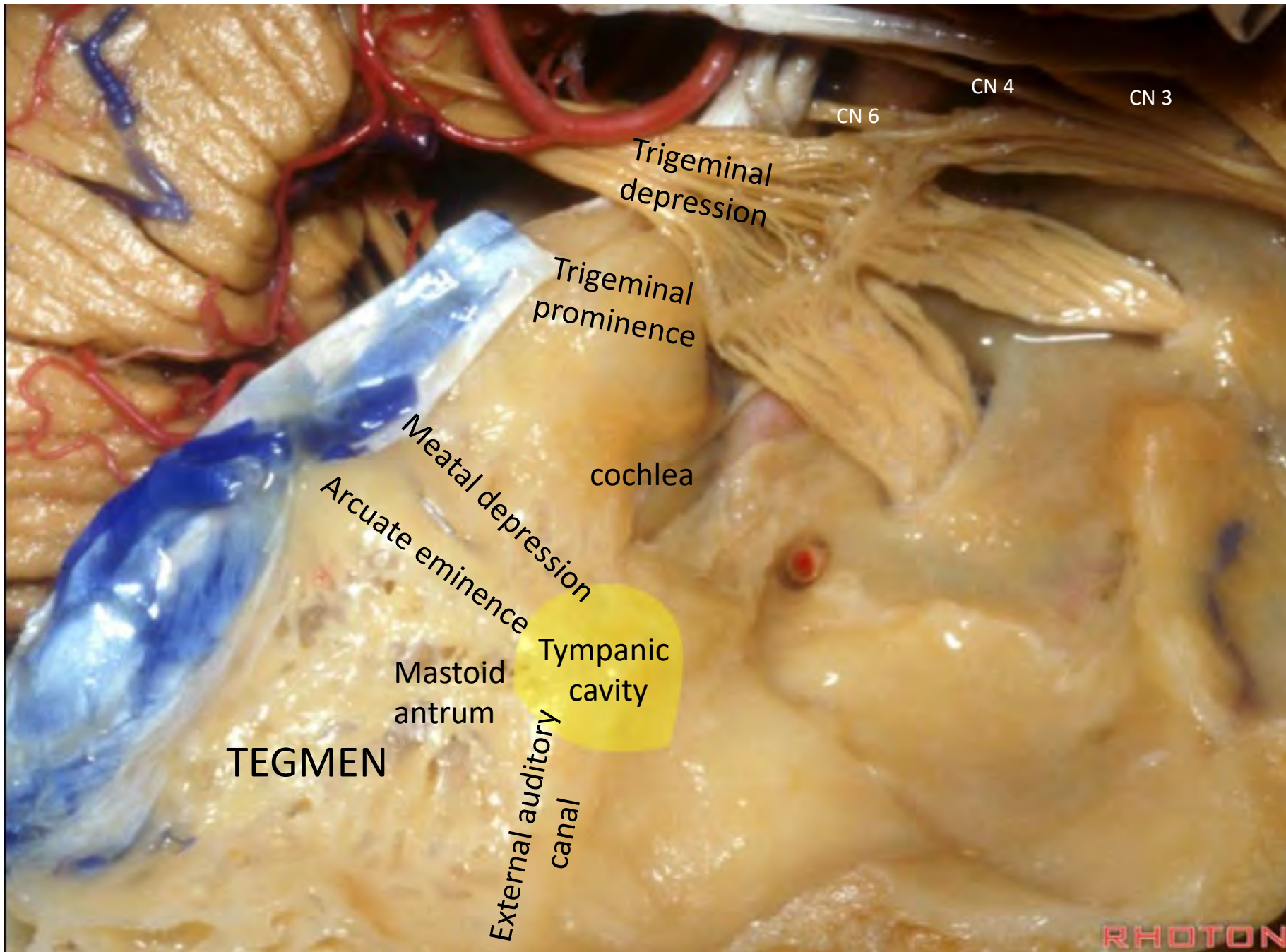












CN 4

CN 3

CN 6

Trigeminal depression

Trigeminal prominence

cochlea

Meatal depression

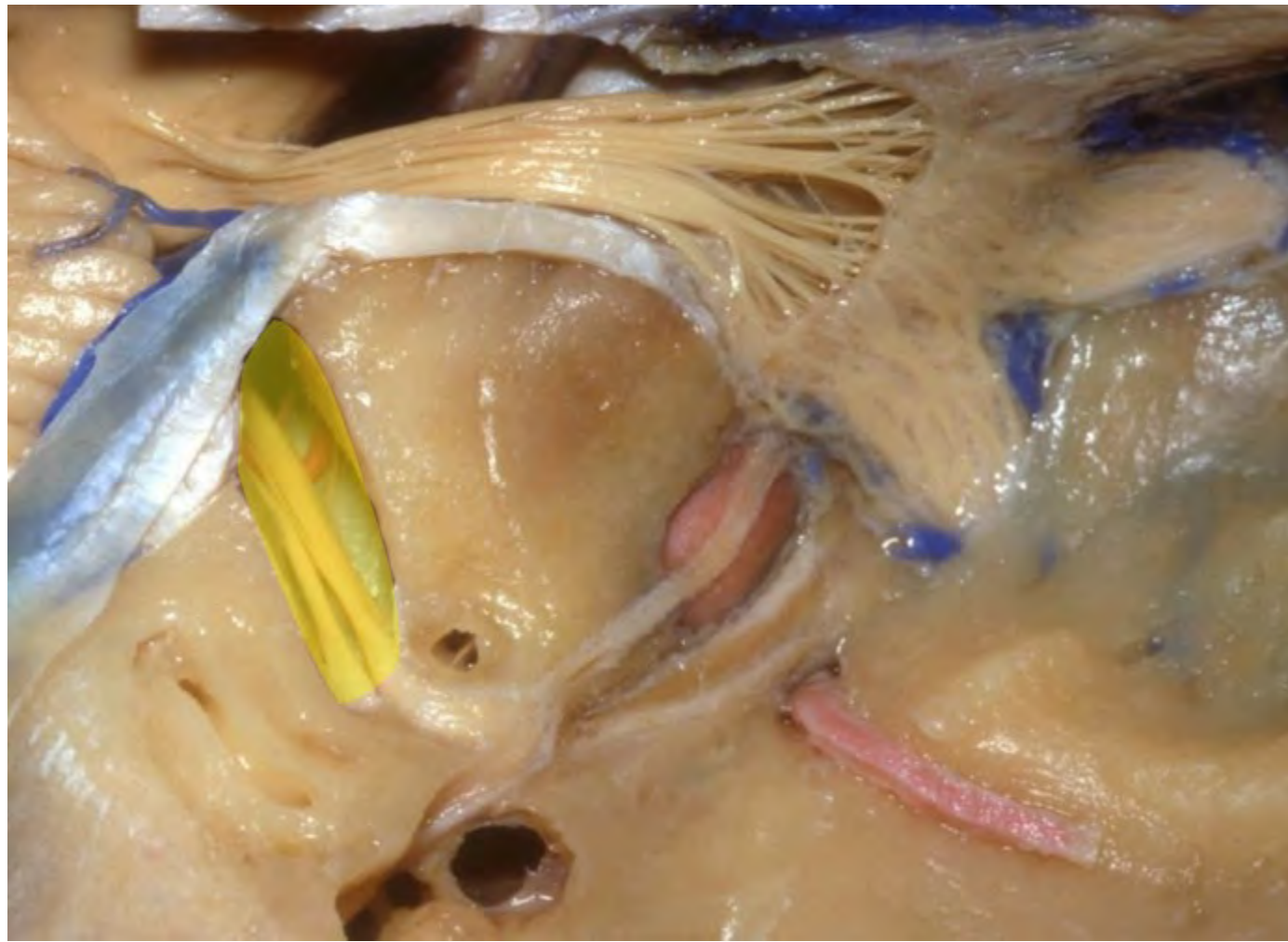
Arcuate eminence

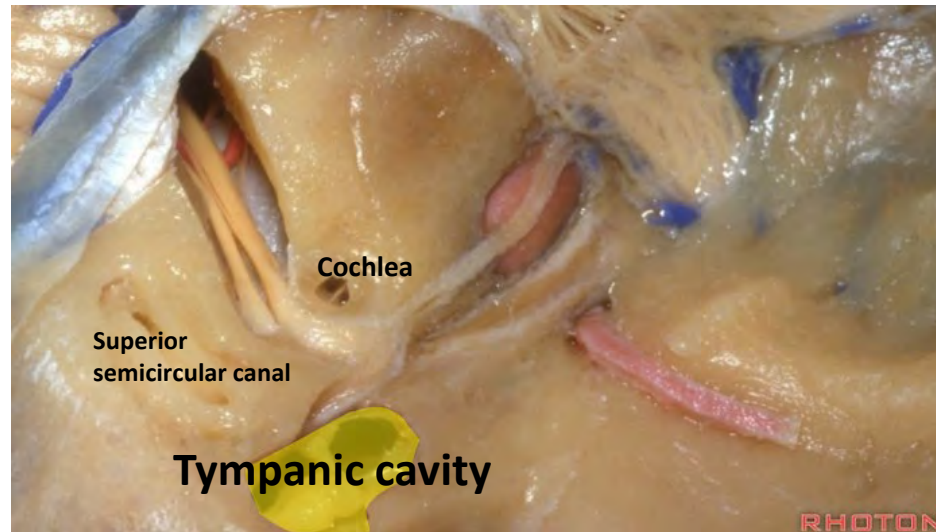
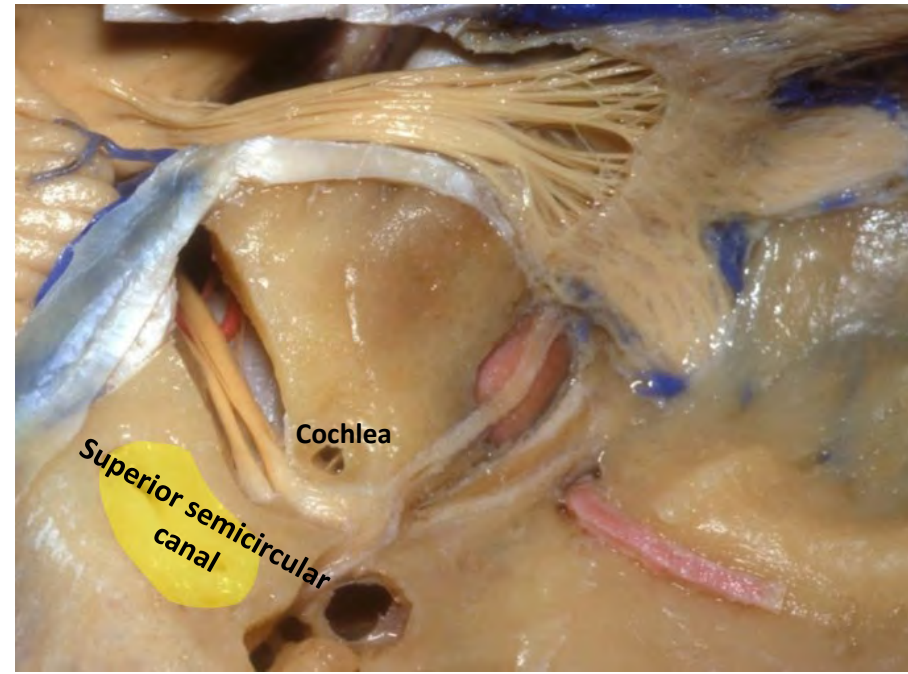
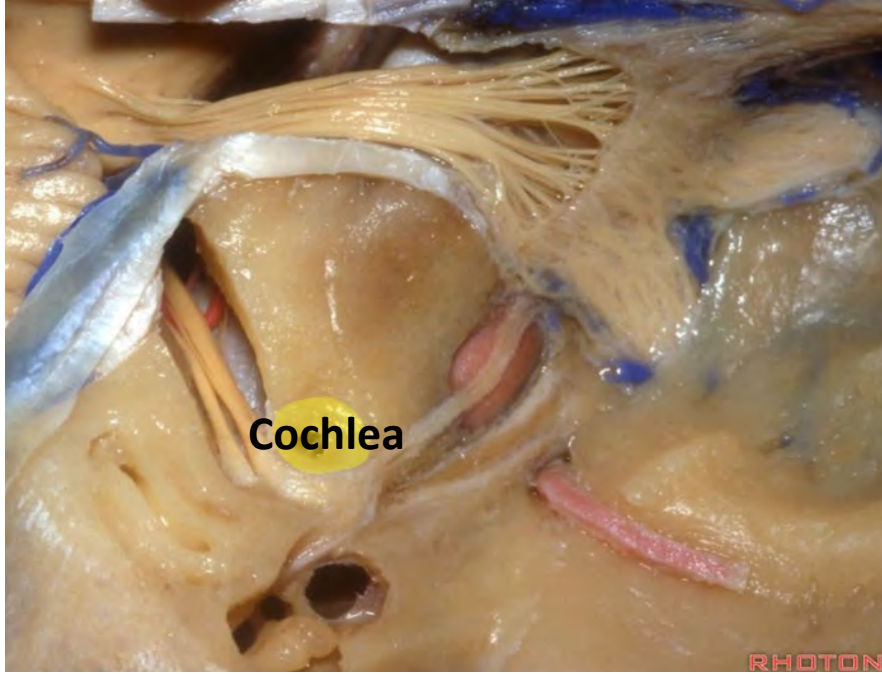
Tympanic cavity

Mastoid antrum

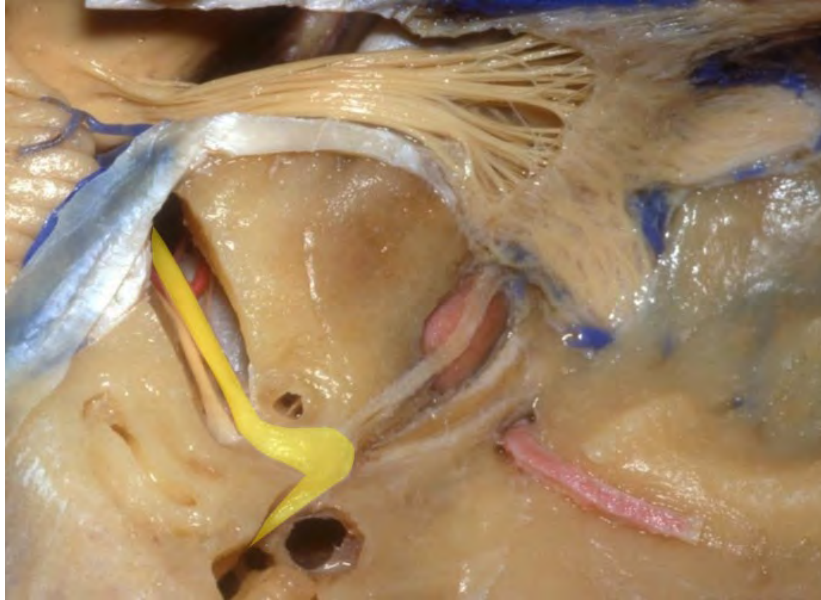TEGMEN

External auditory canal

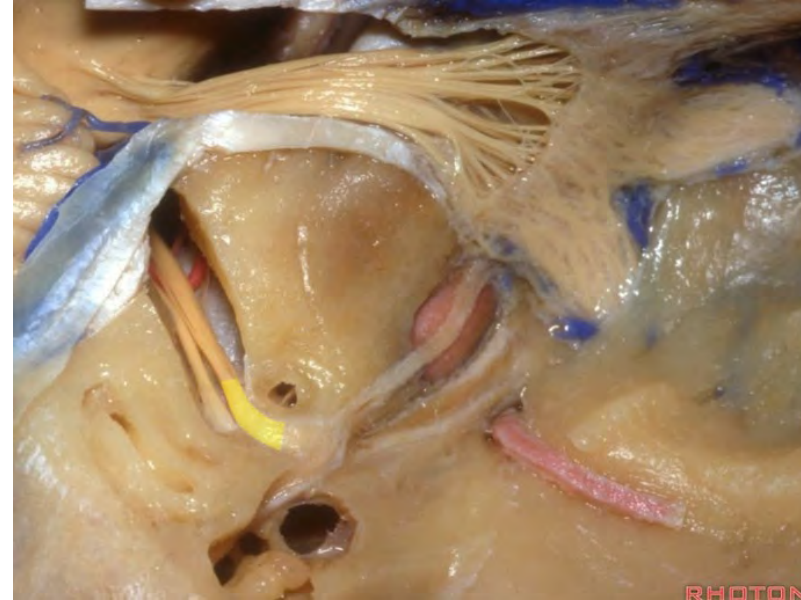



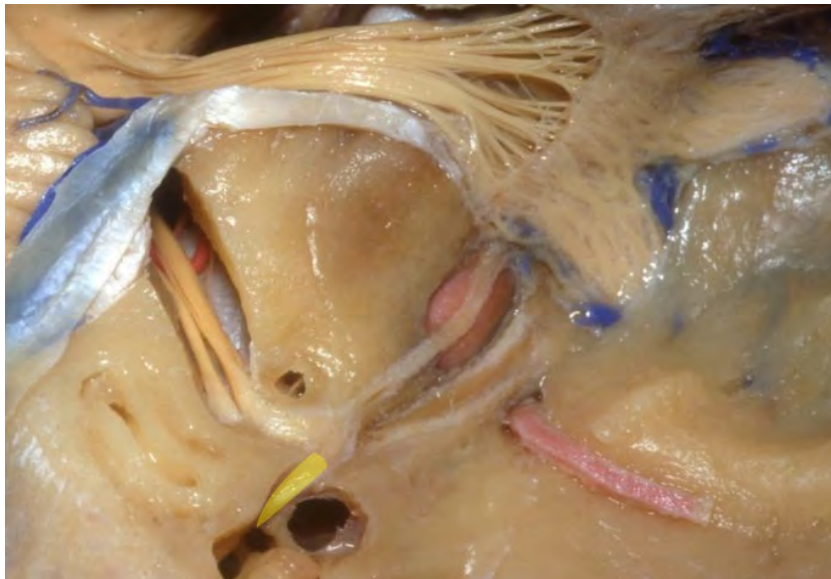**Facial nerve**



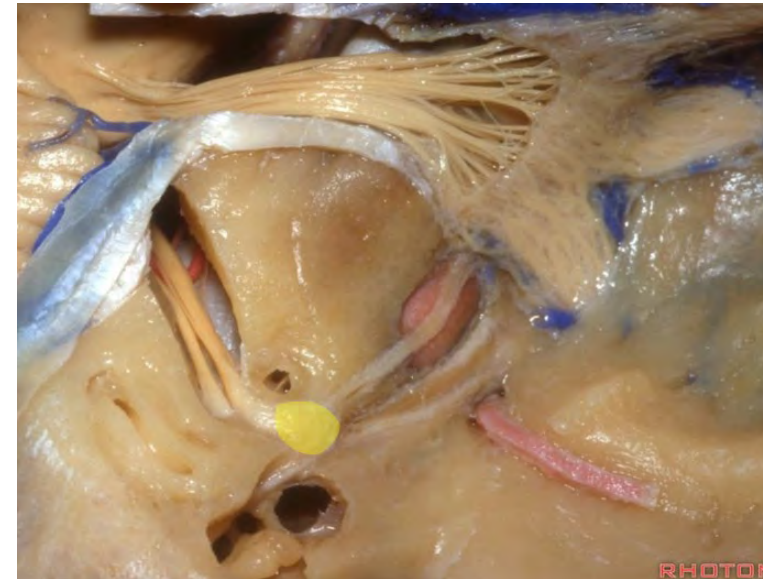**Labyrinthine segment of the facial nerve**

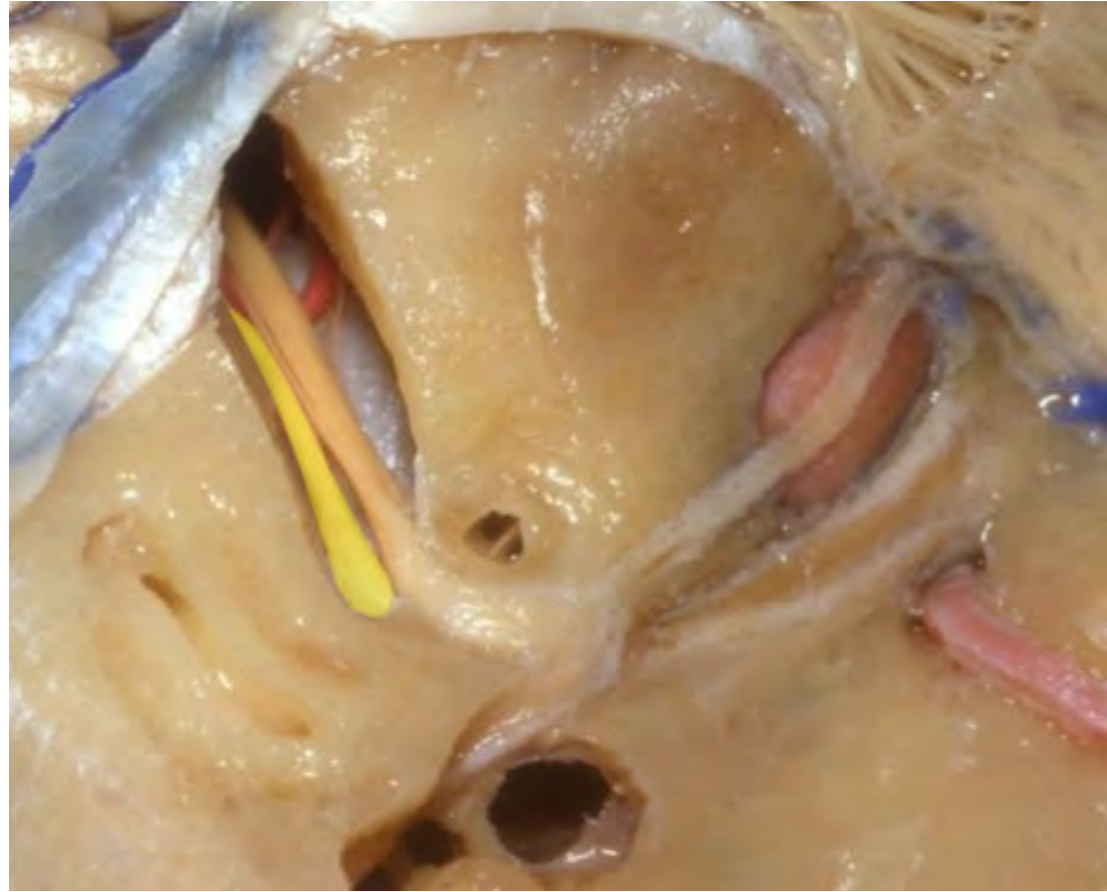


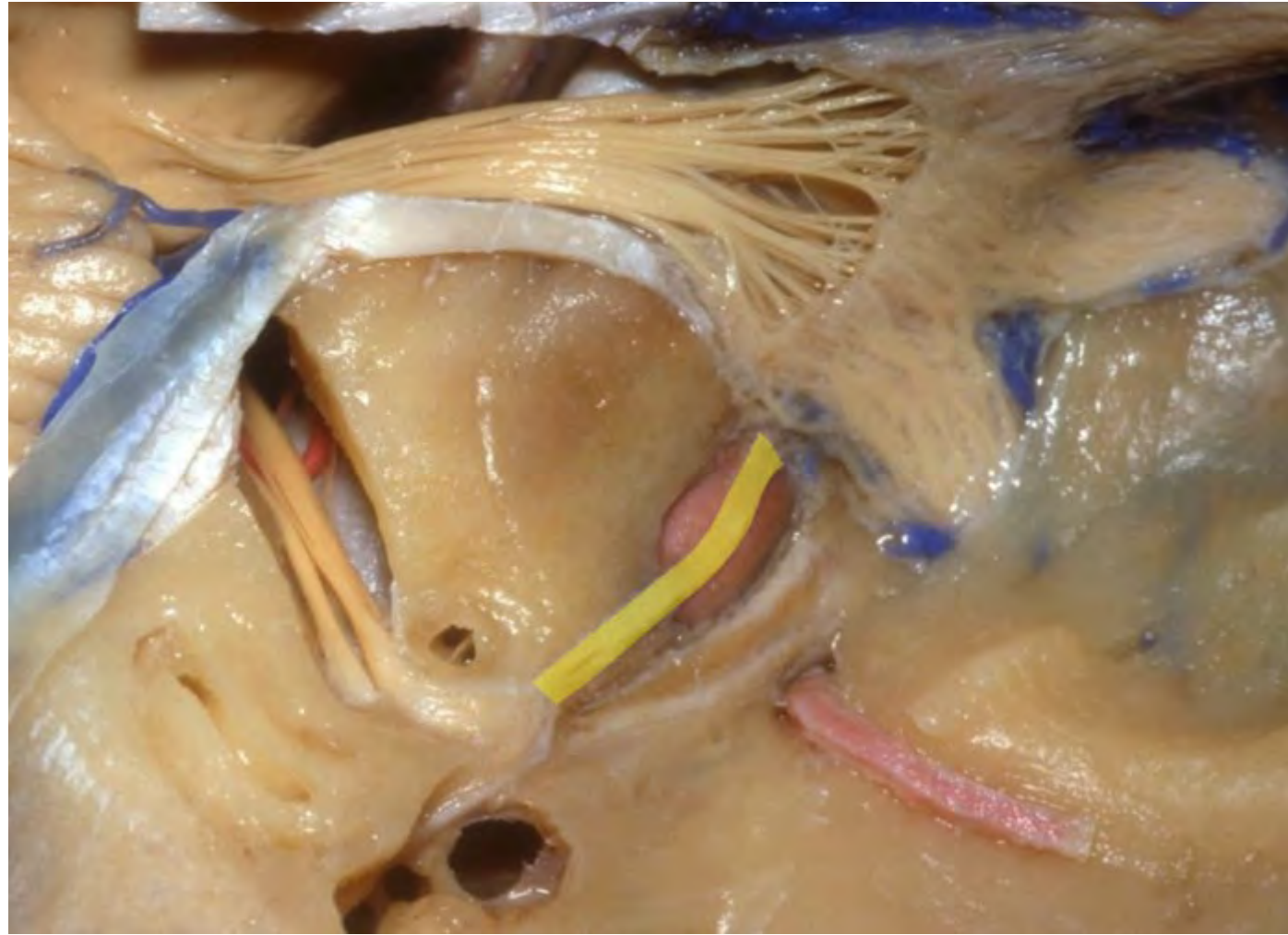
**Tympanic segment of the facial nerve**

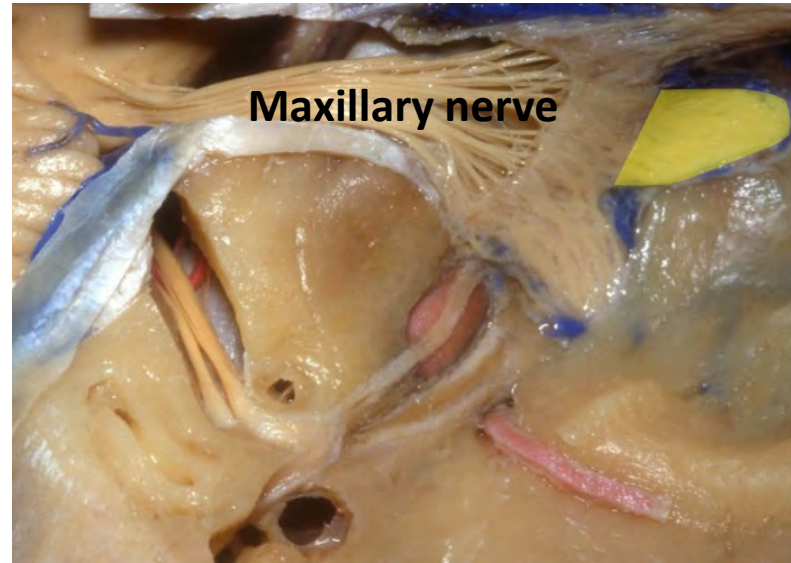
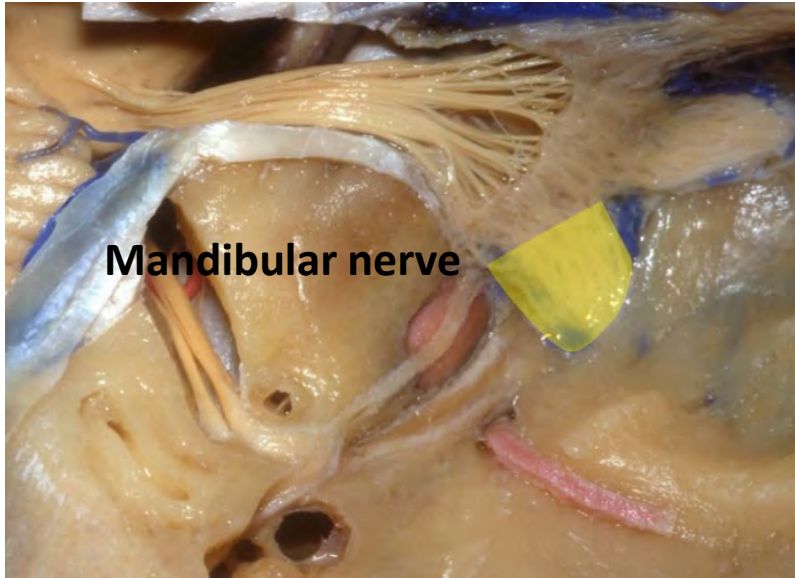


**Geniculate ganglion**

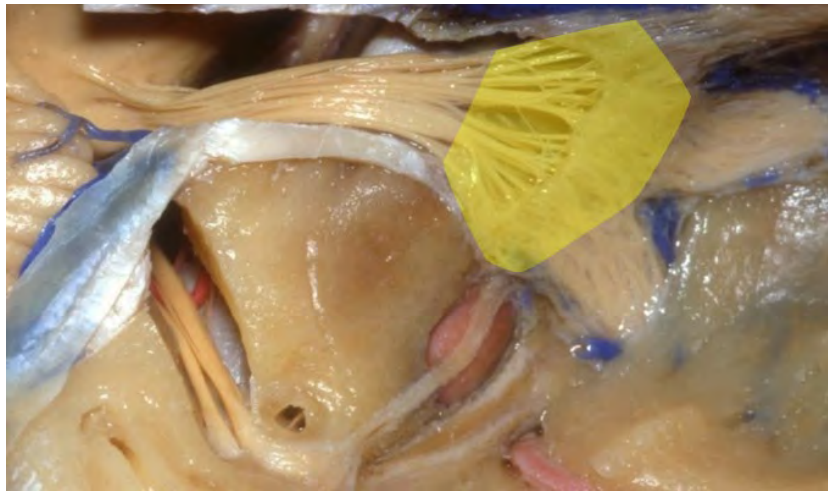




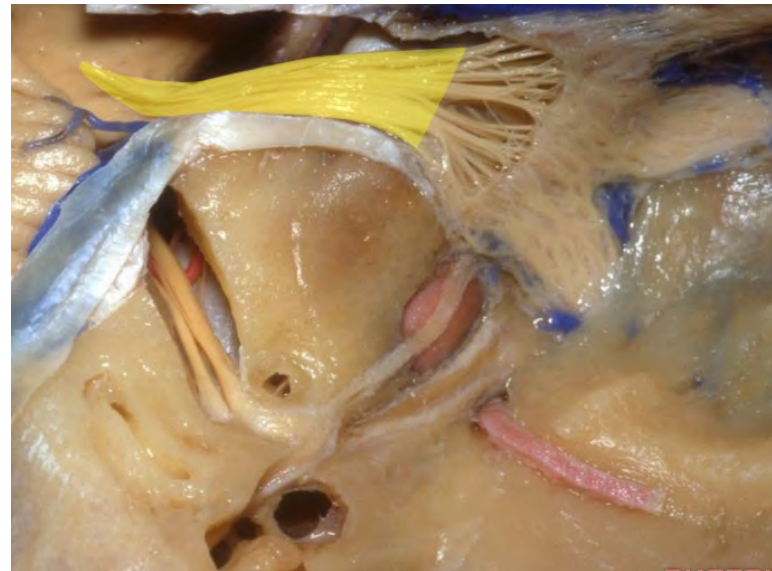


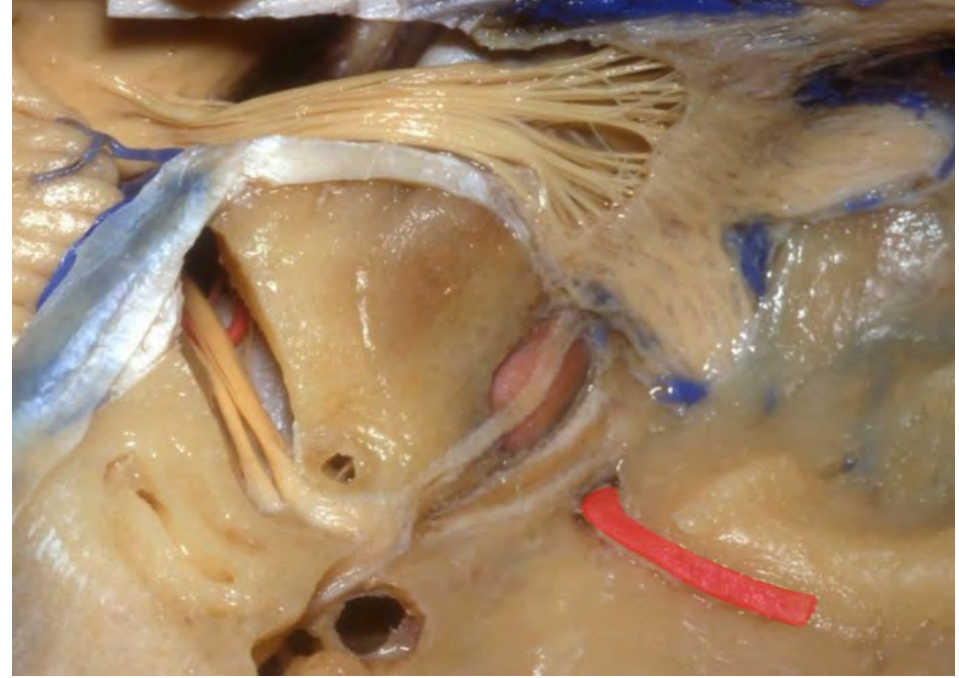
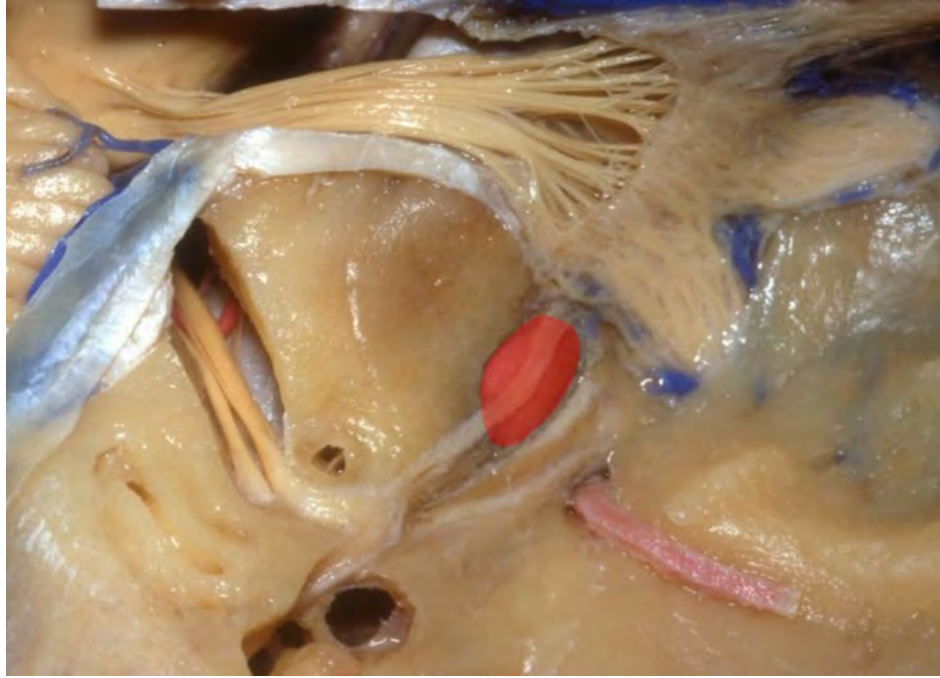
Trigeminal ganglion

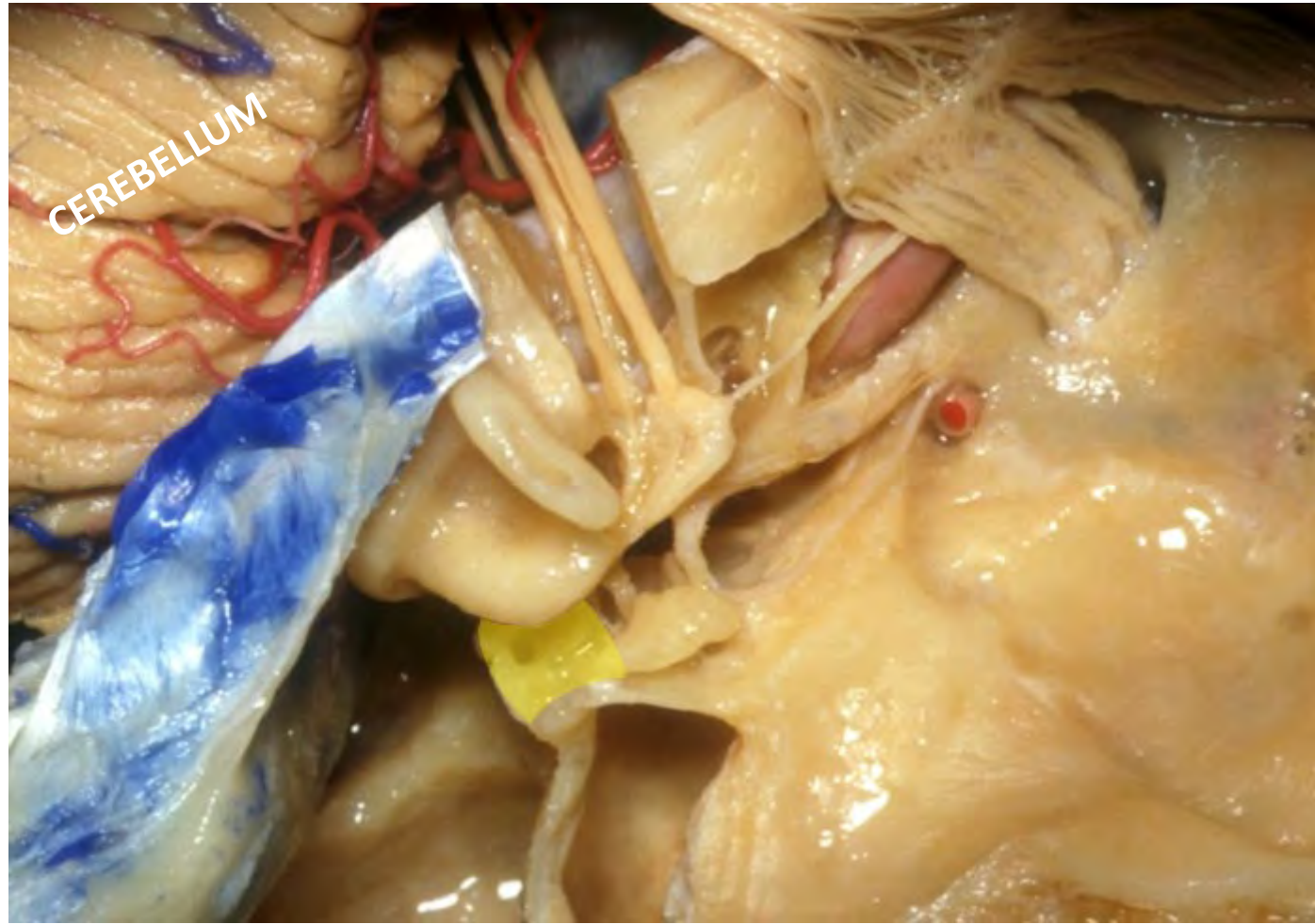

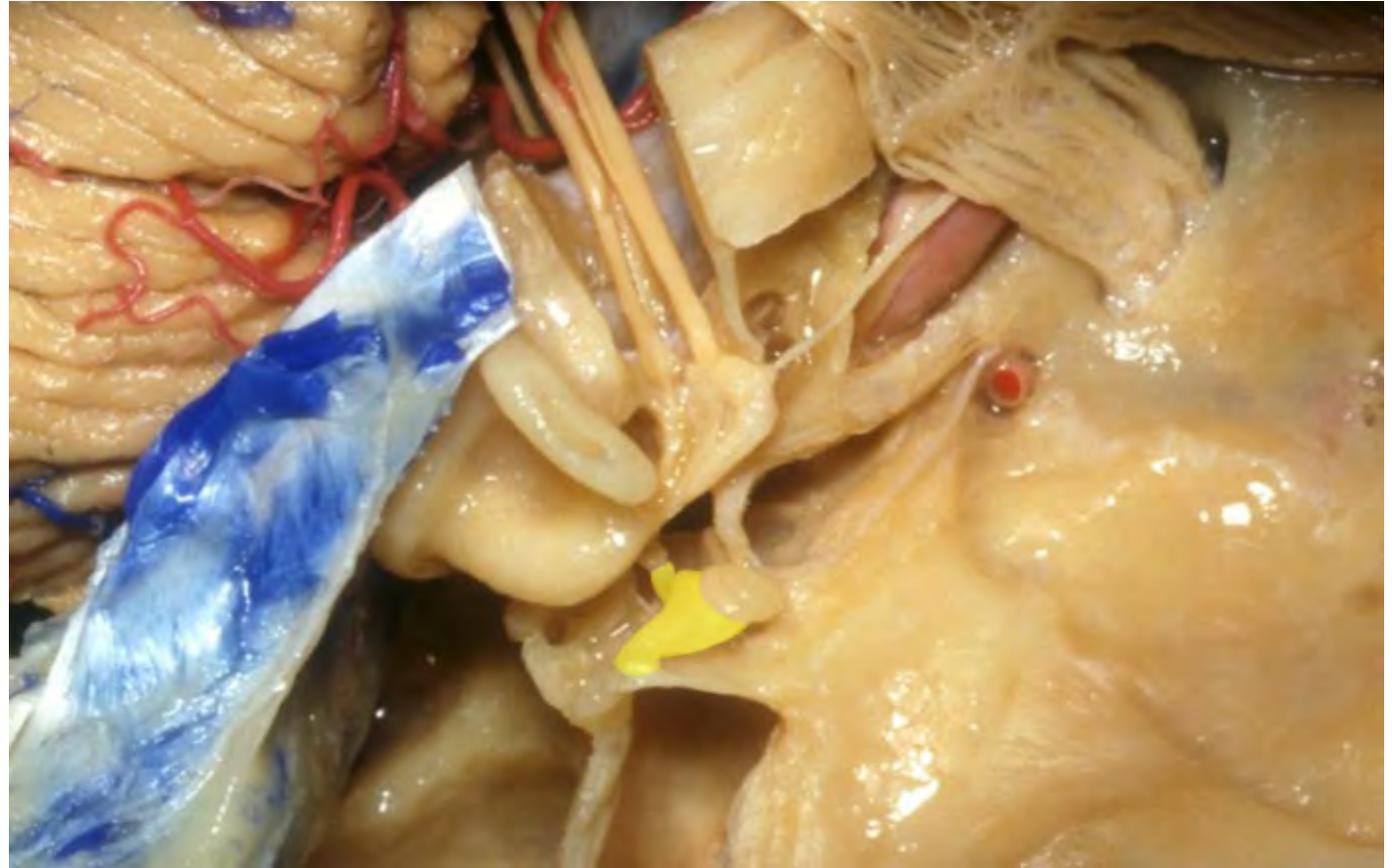
Trigeminal nerve

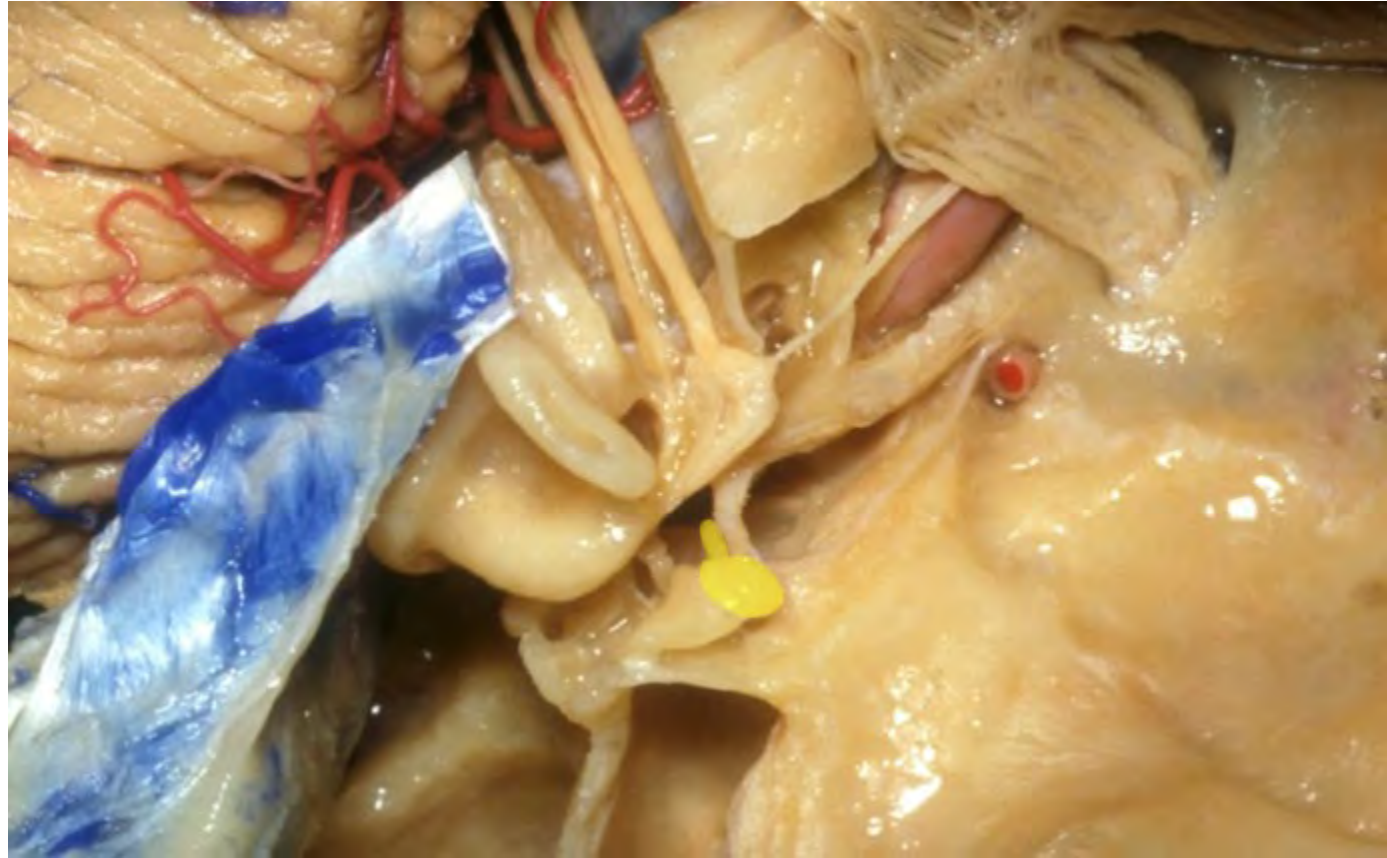


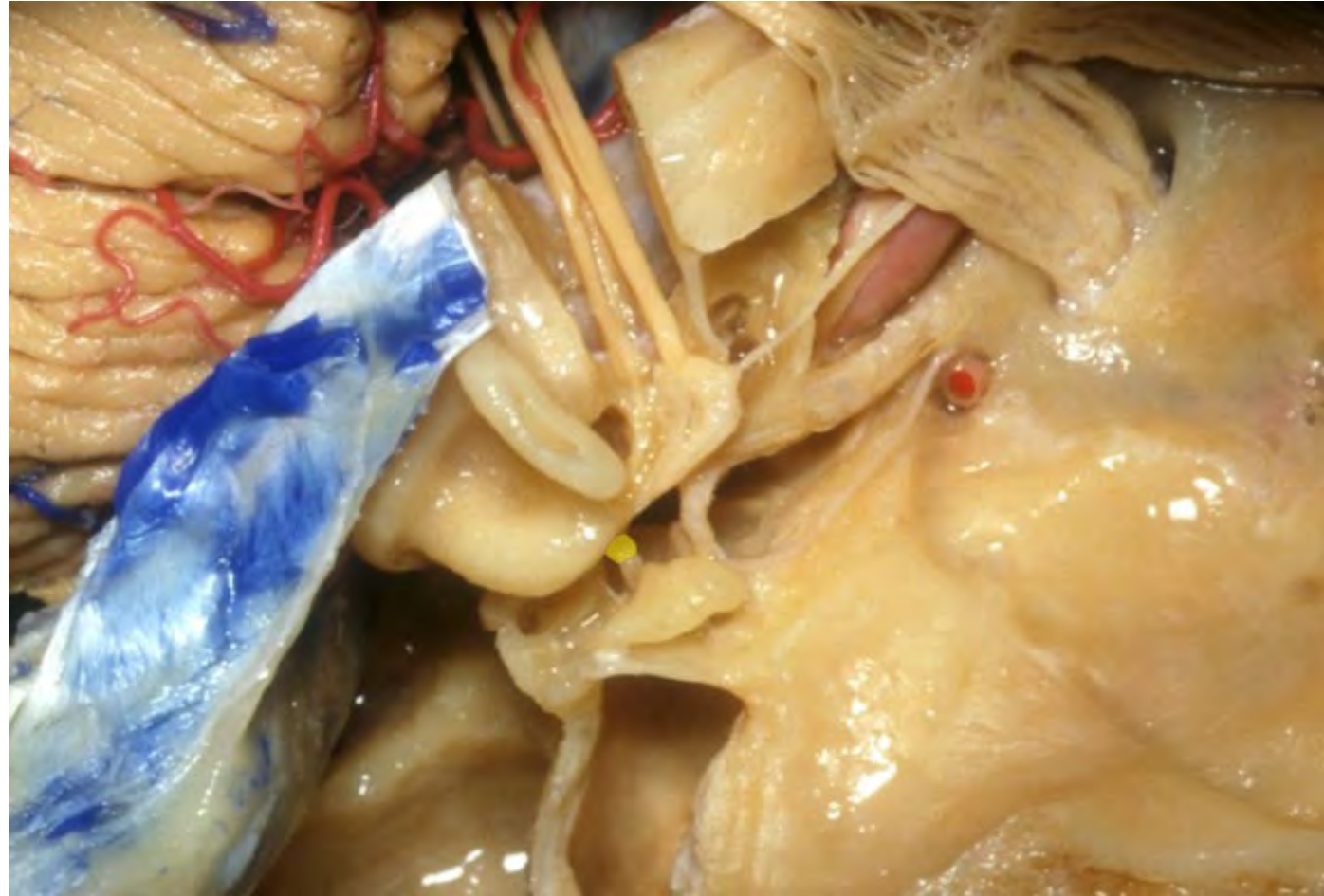


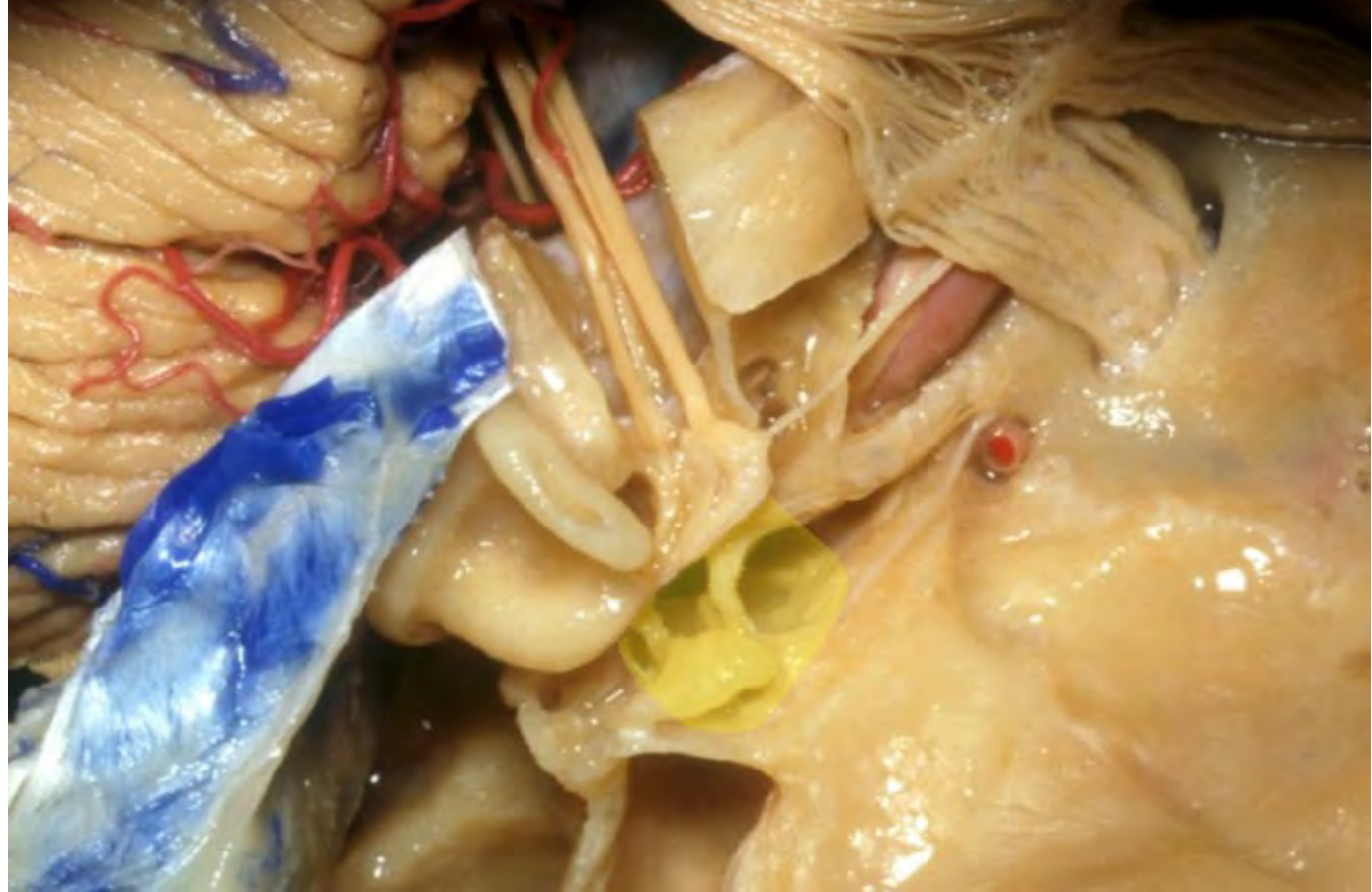


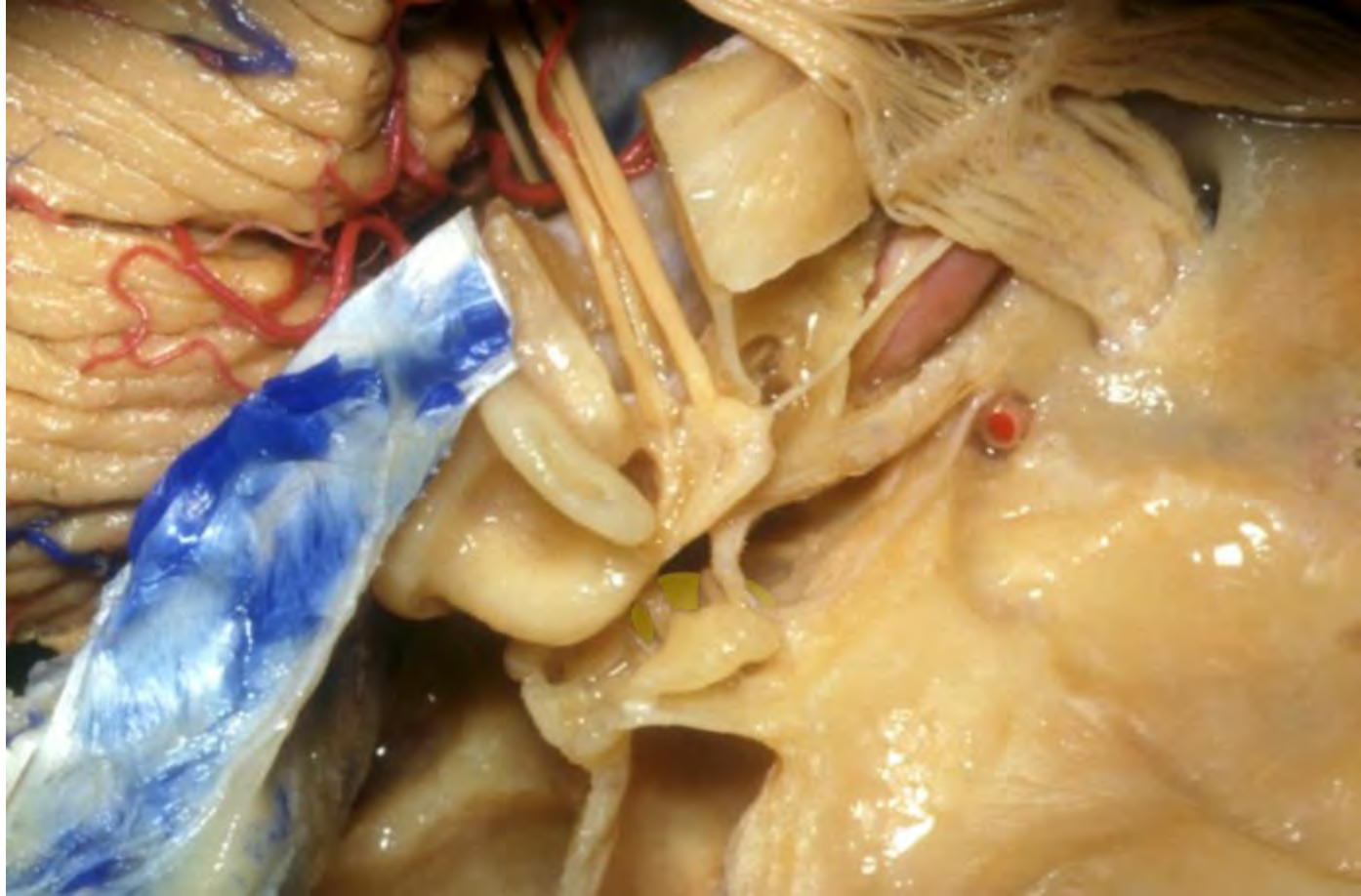




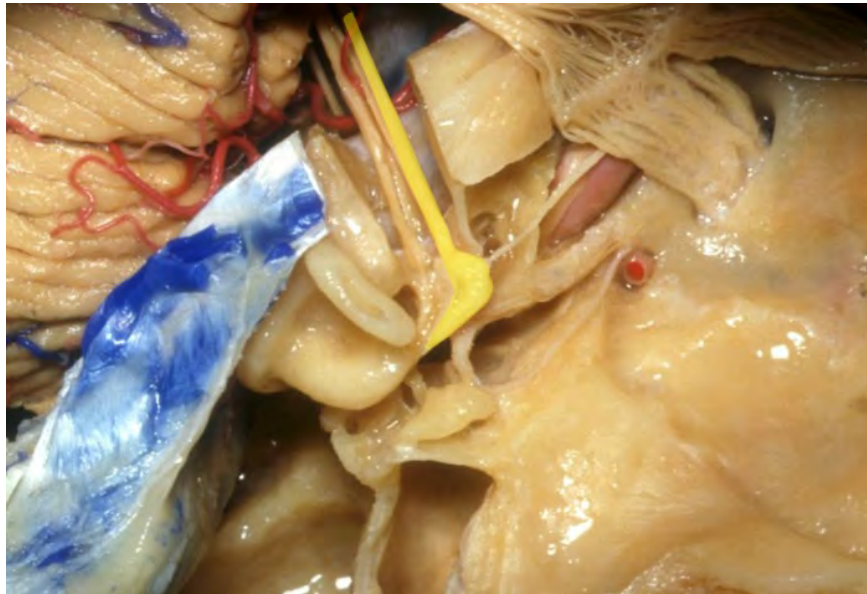




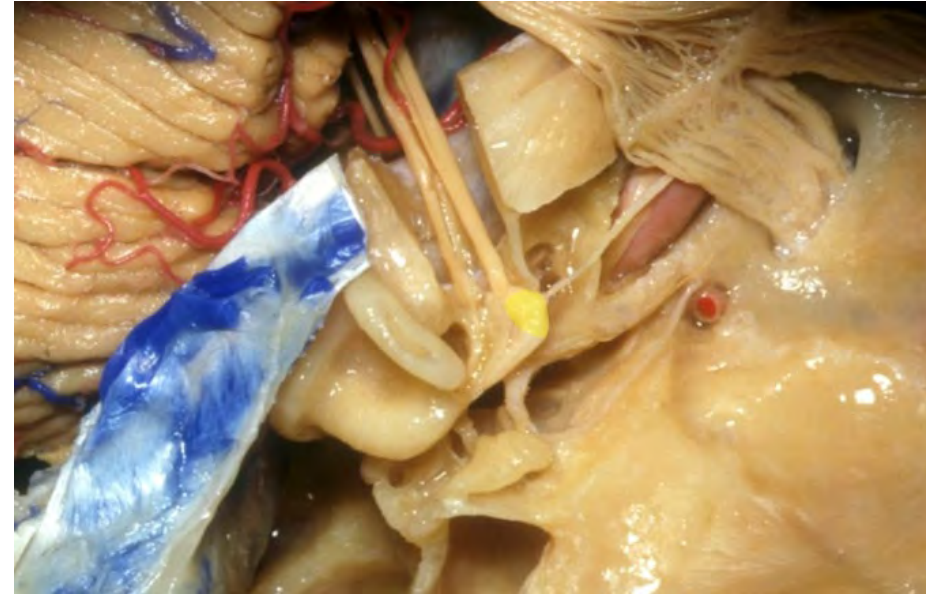
**Facial nerve**

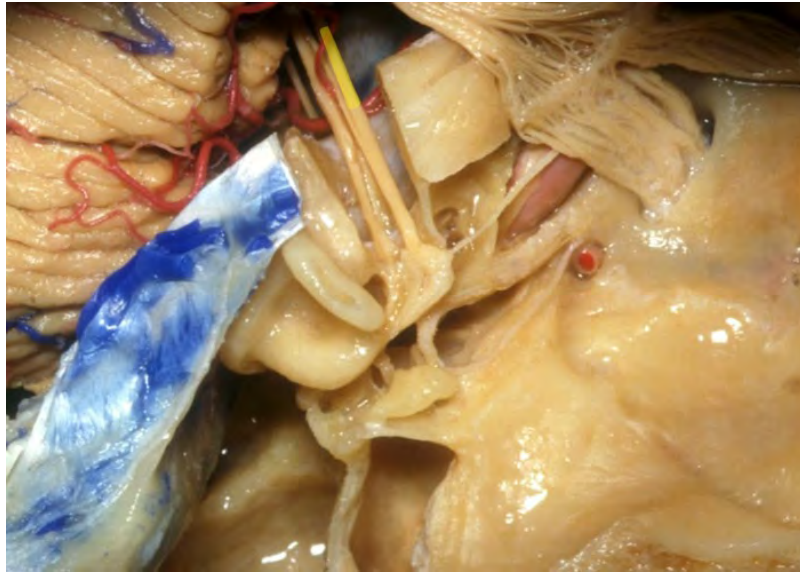


**Geniculate ganglion**

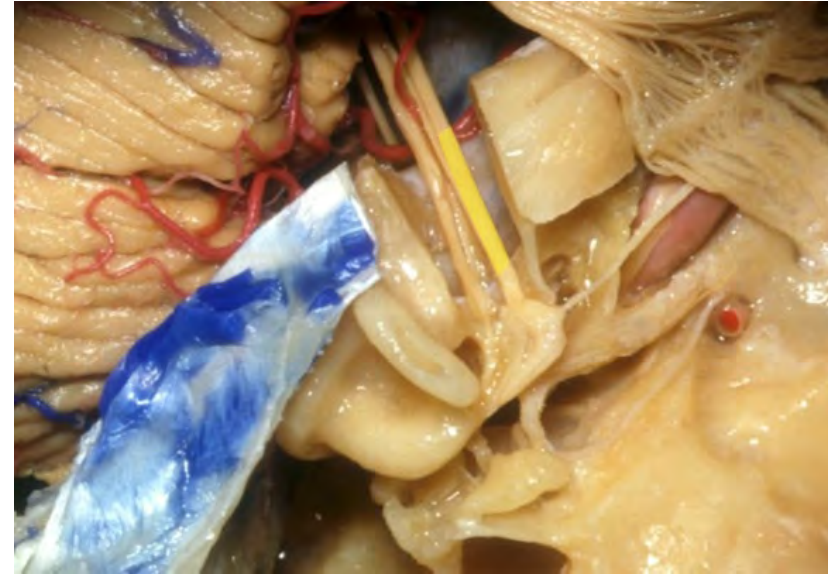




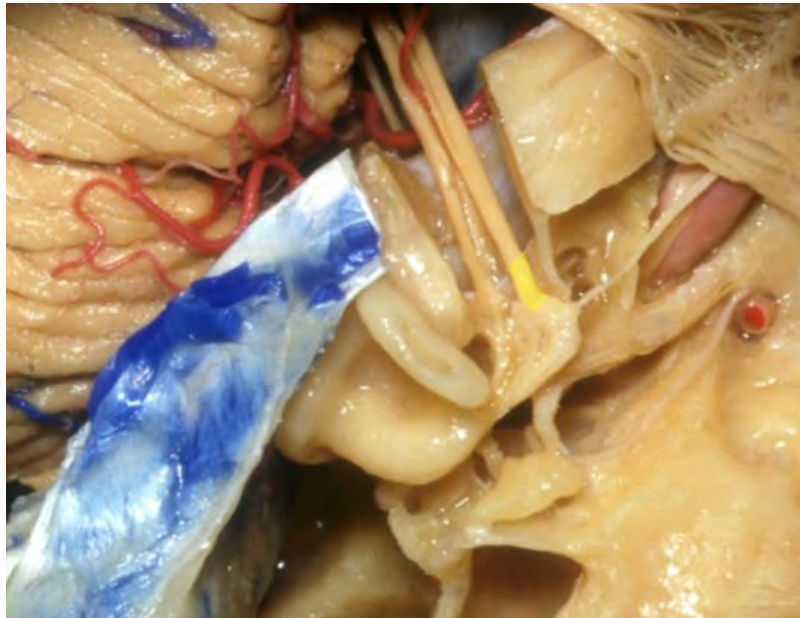**Cisternal segment of facial nerve**



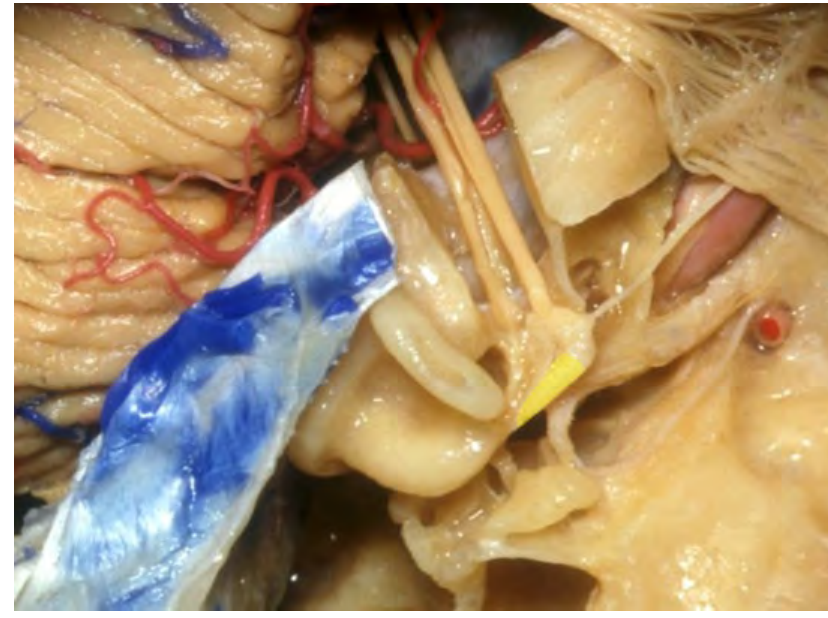
**Meatal segment of facial nerve**

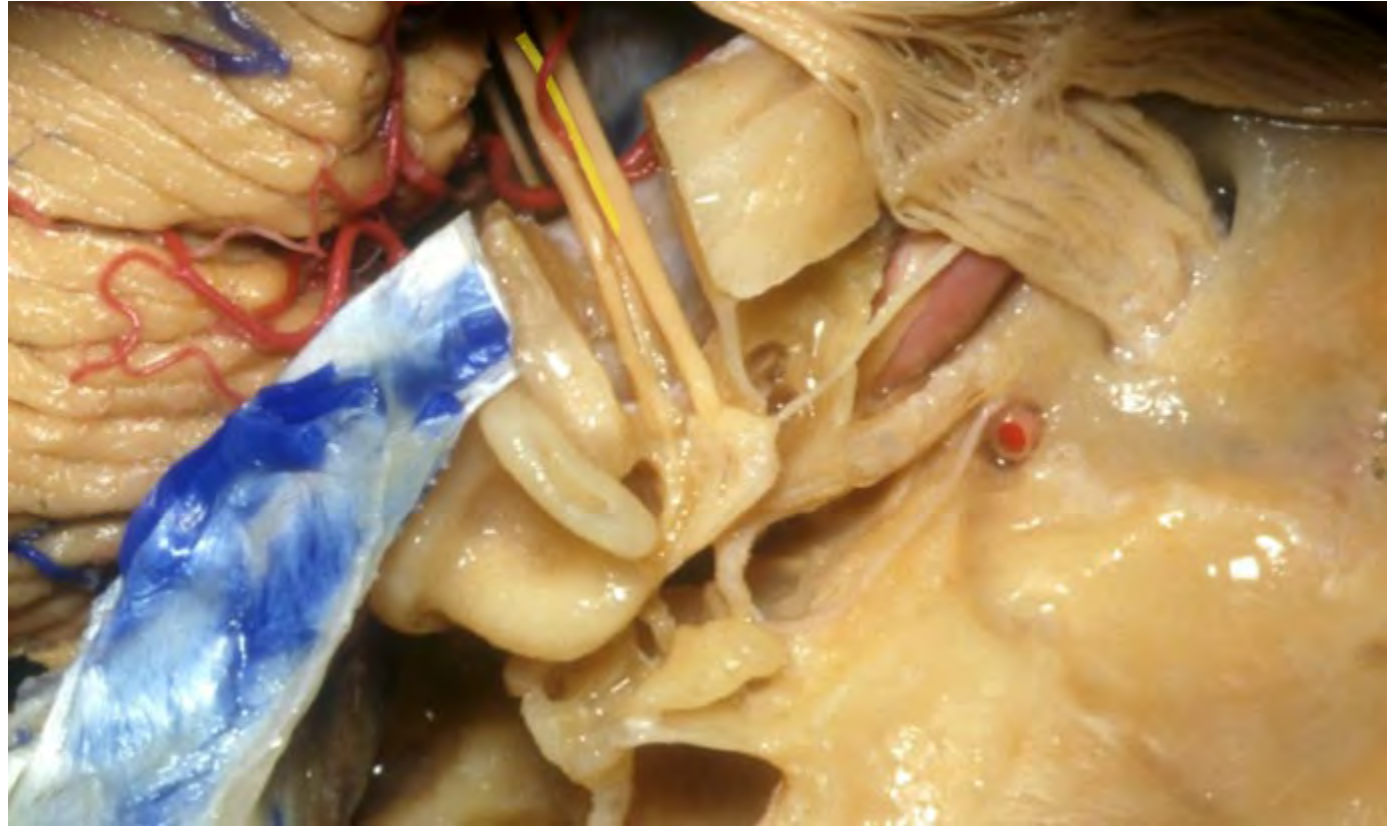

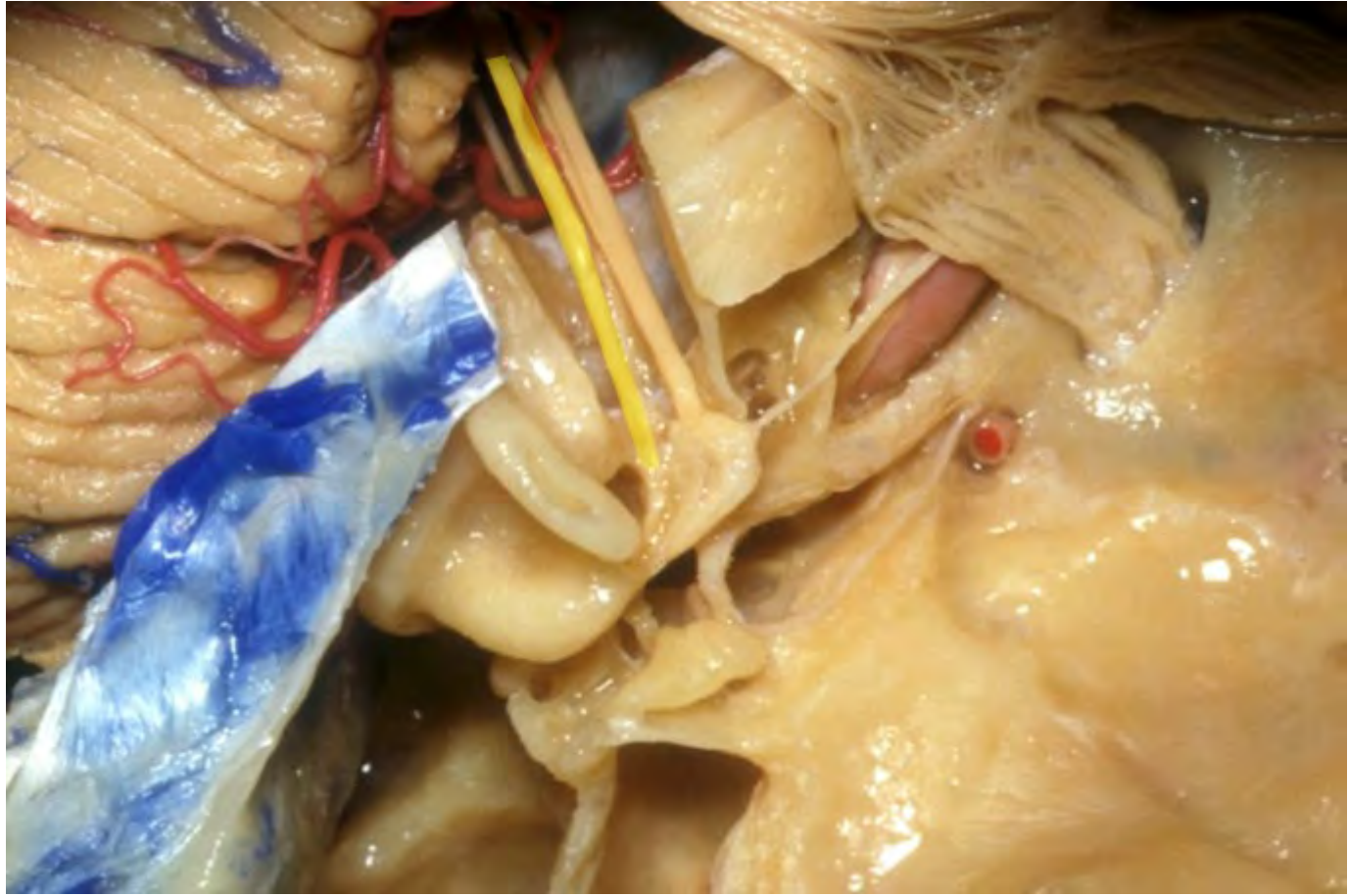
**Labyrinthine segment of facial nerve**

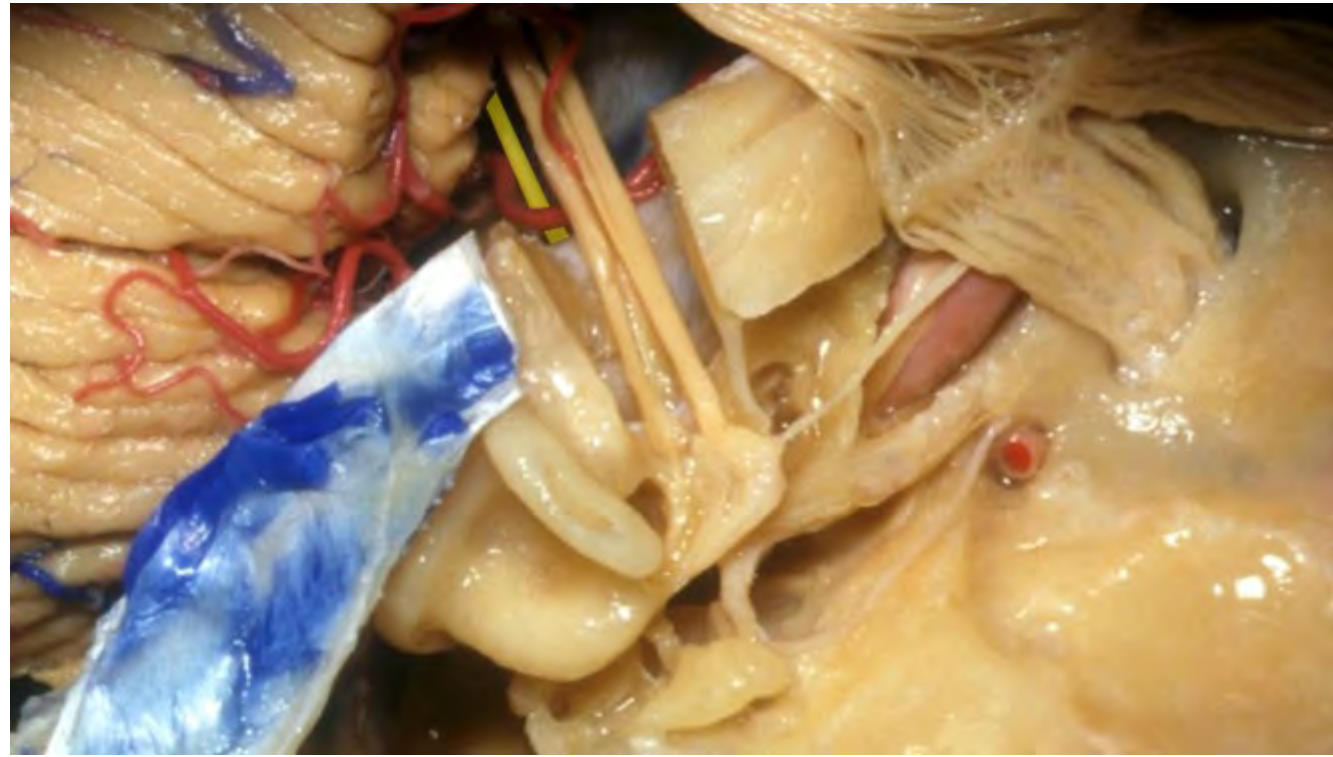

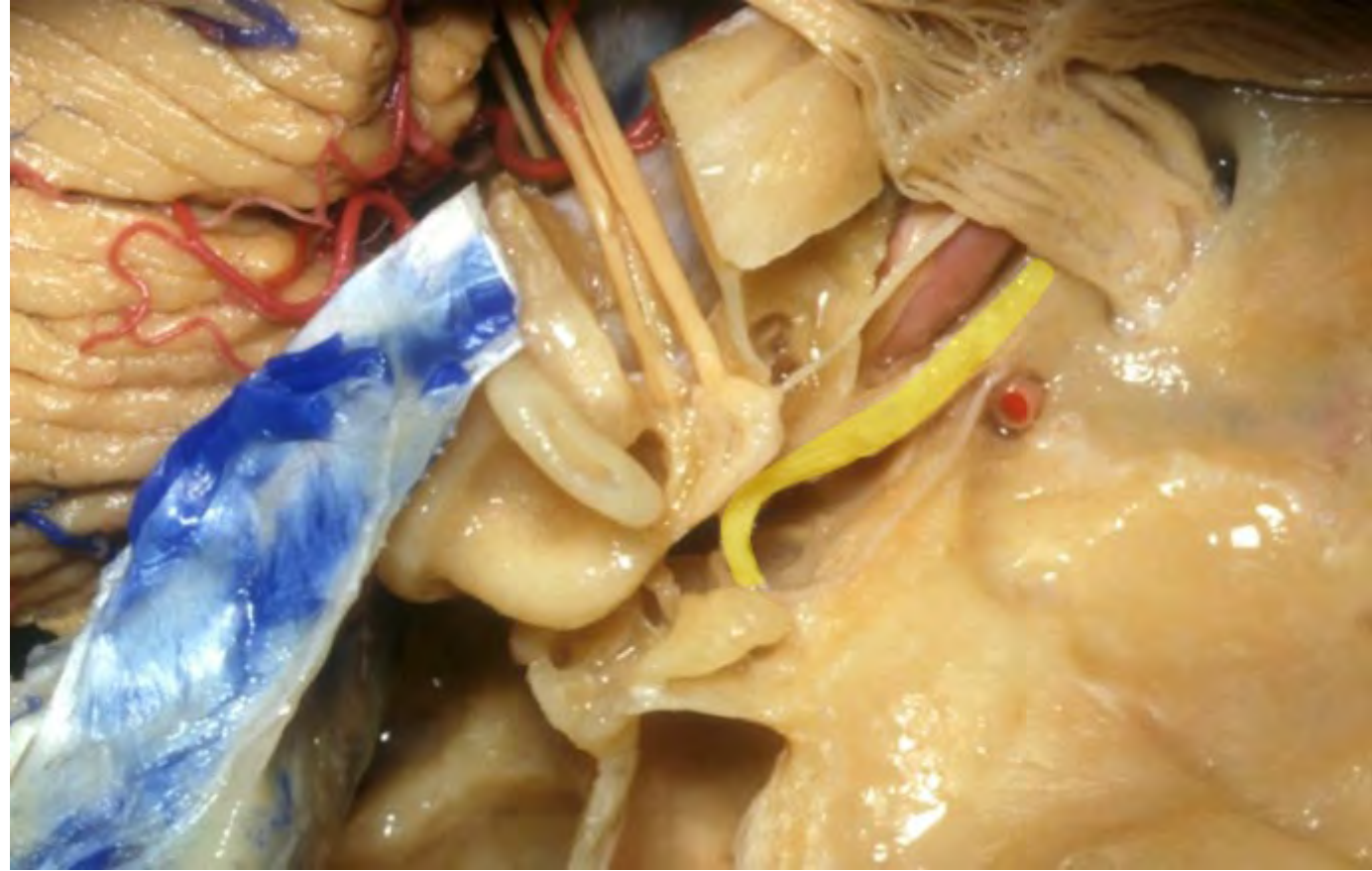
**Tympanic segment of facial nerve**

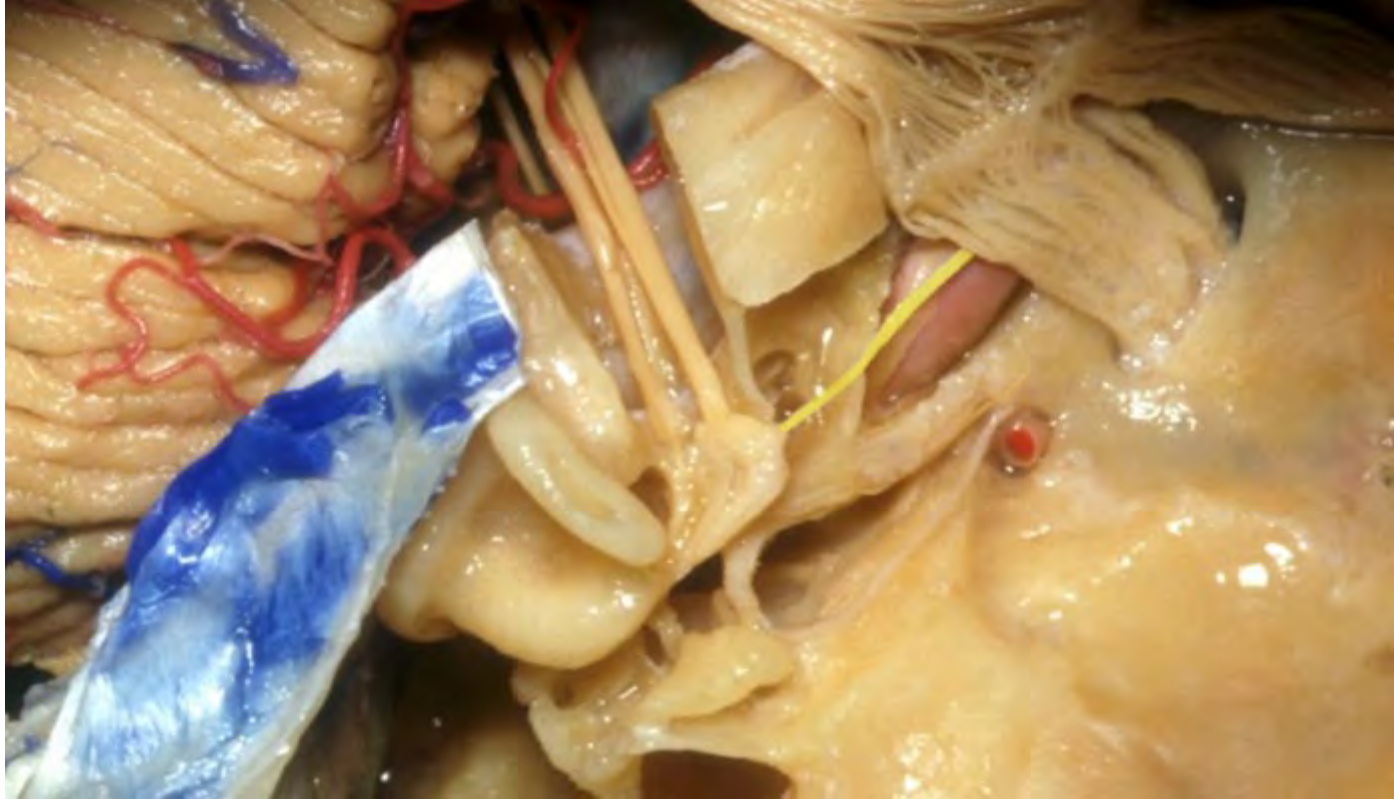

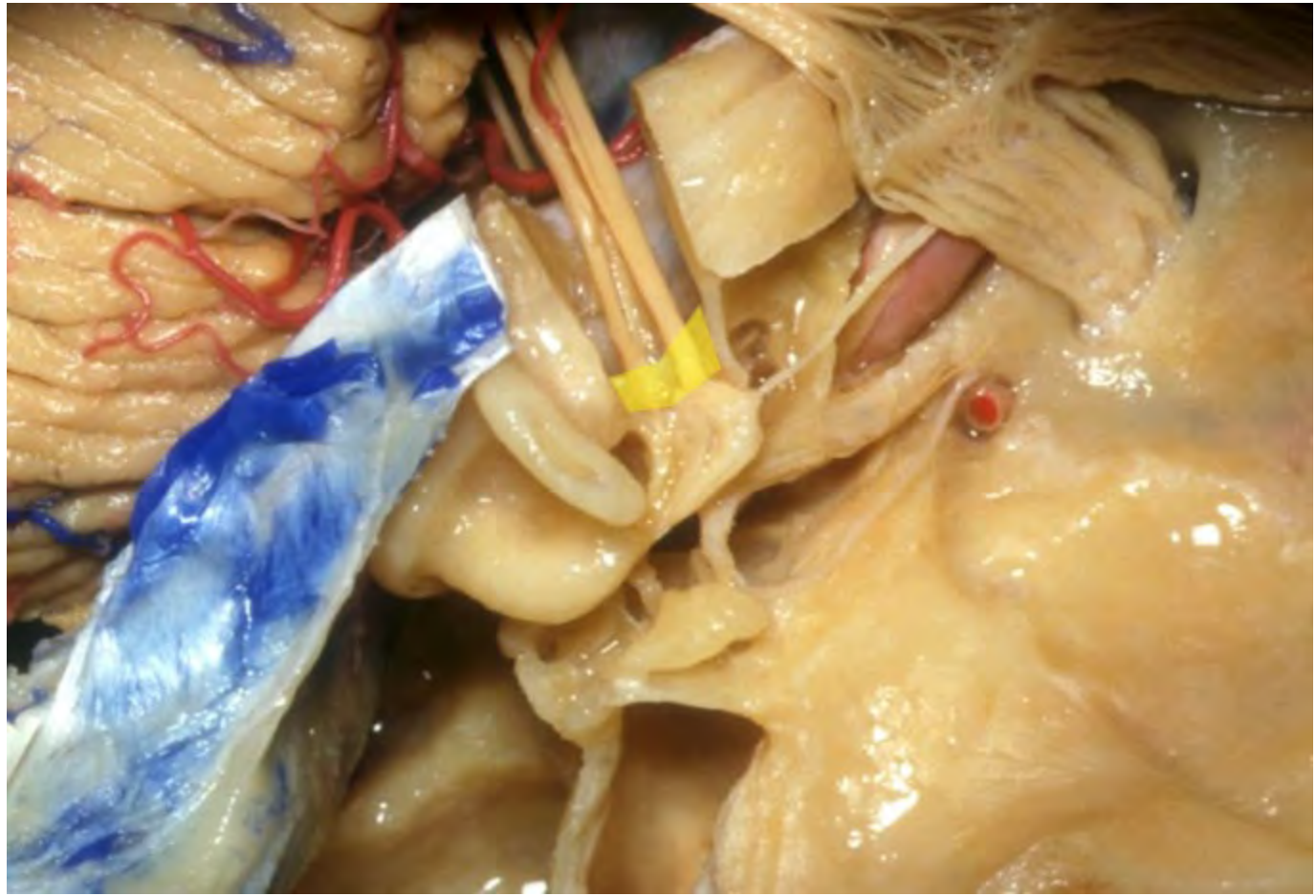


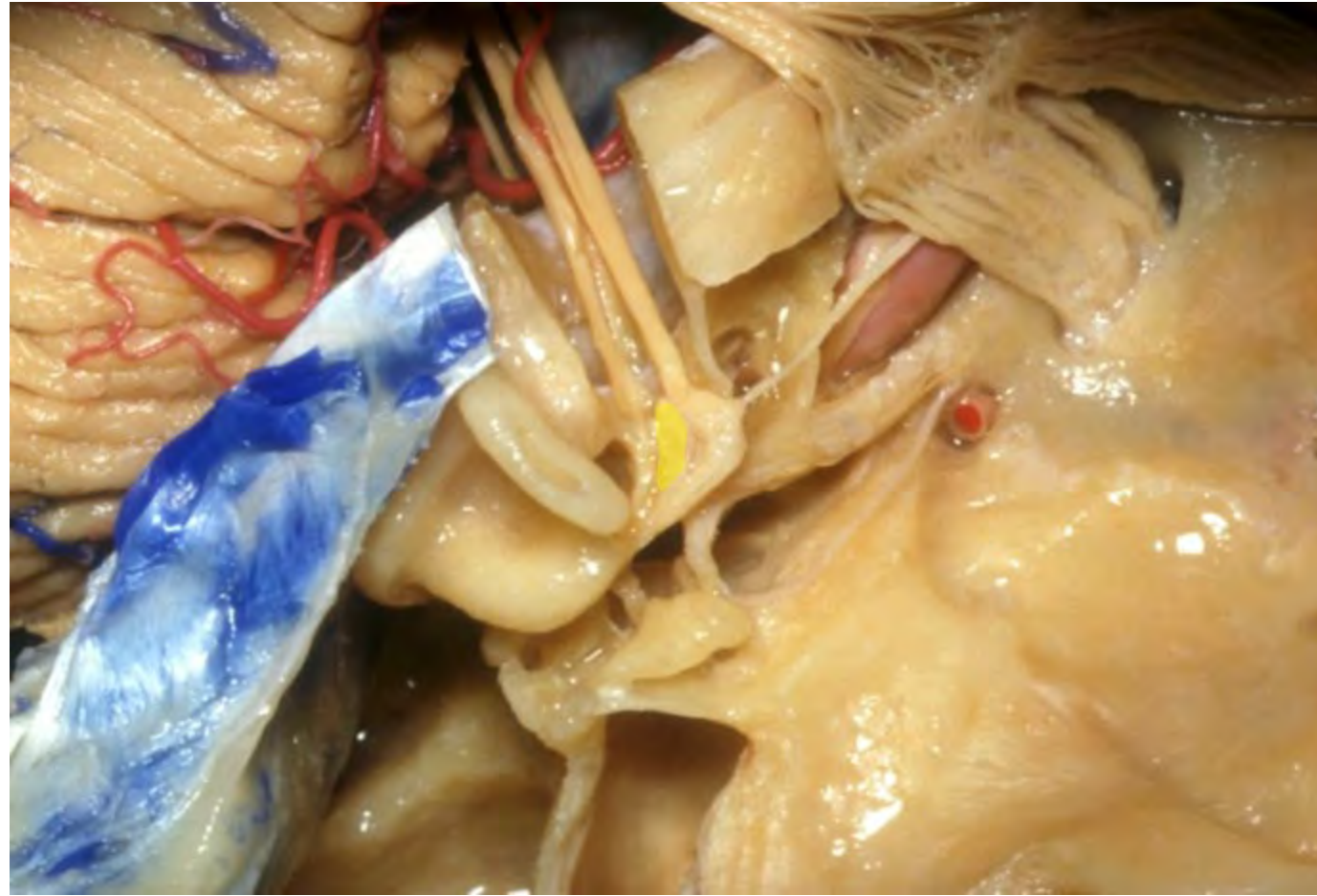





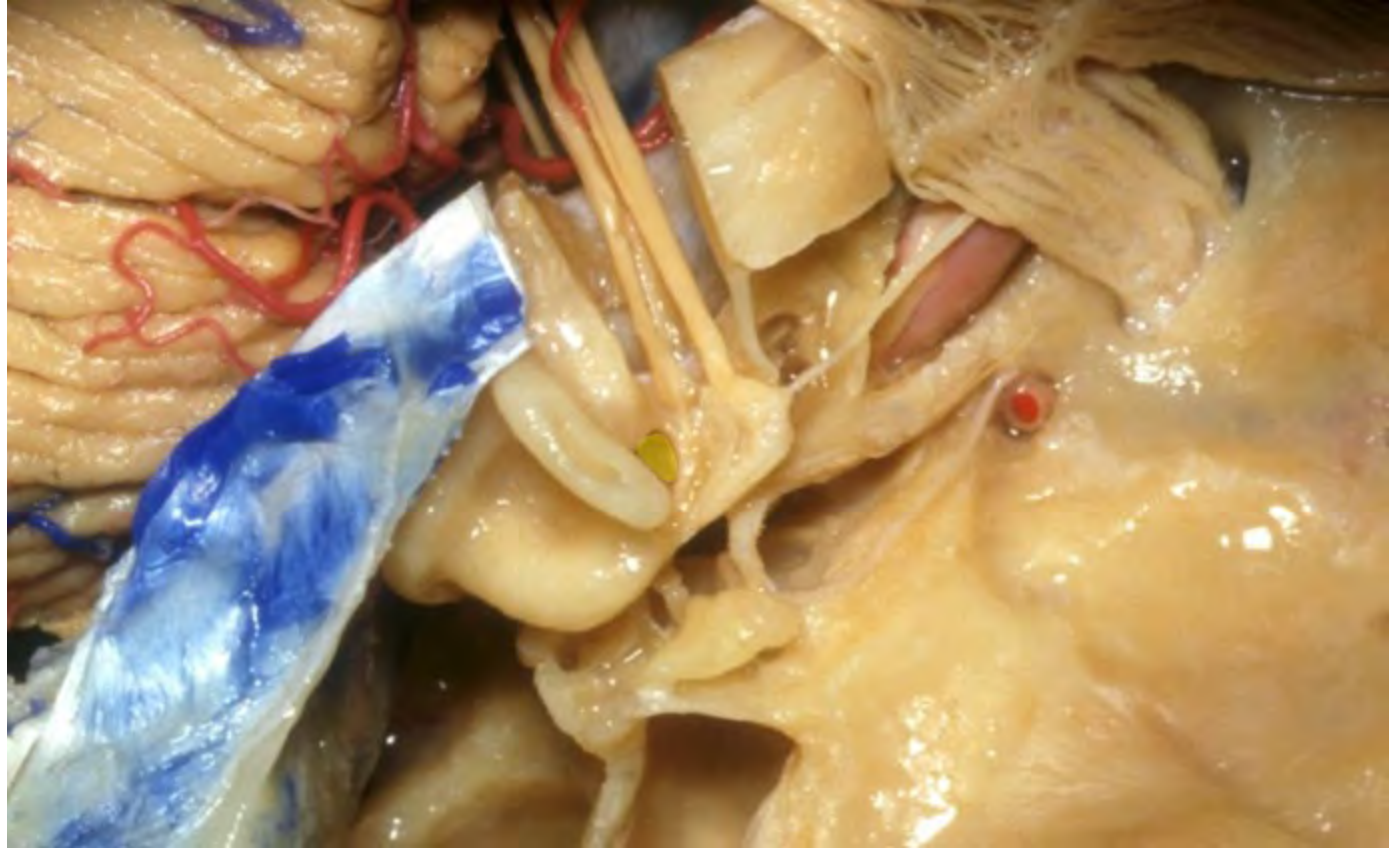


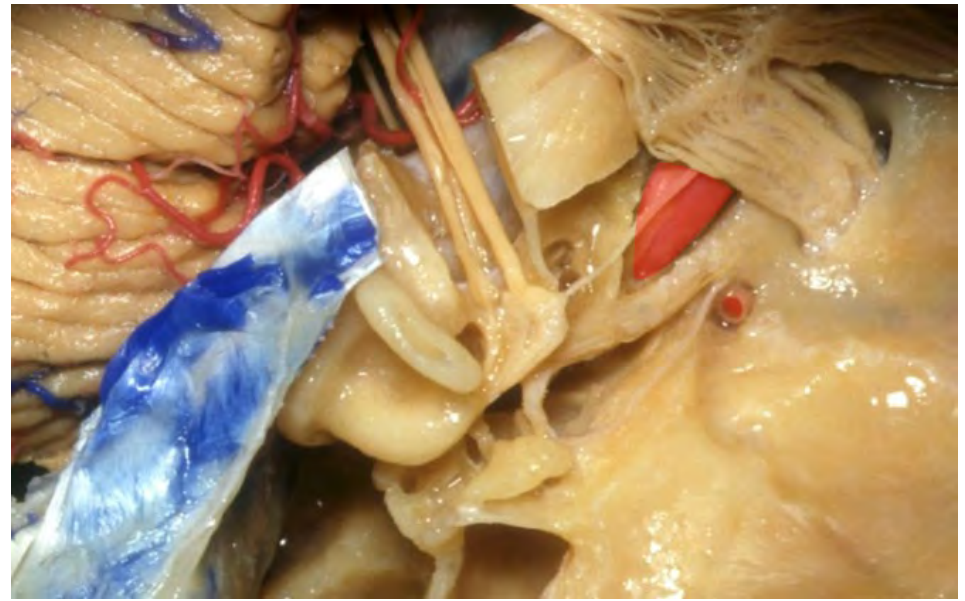
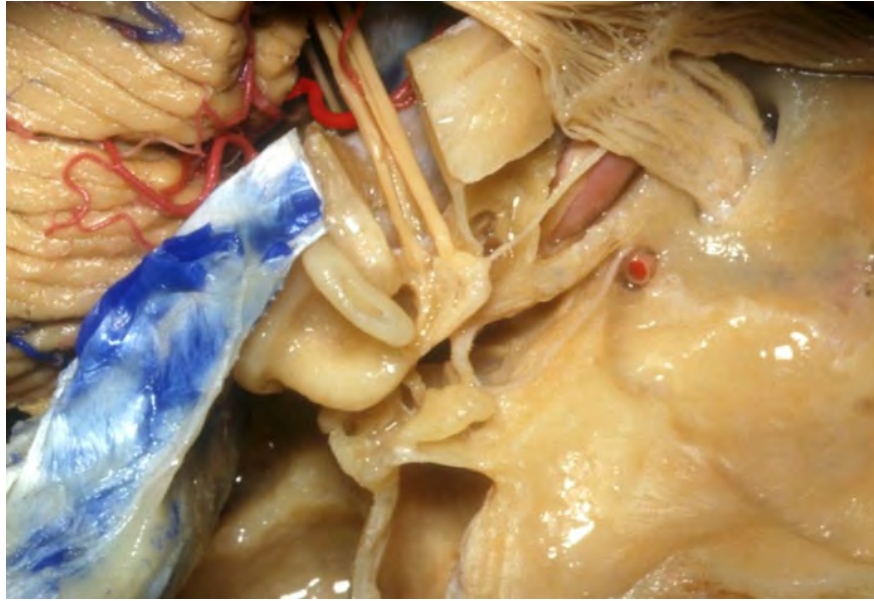


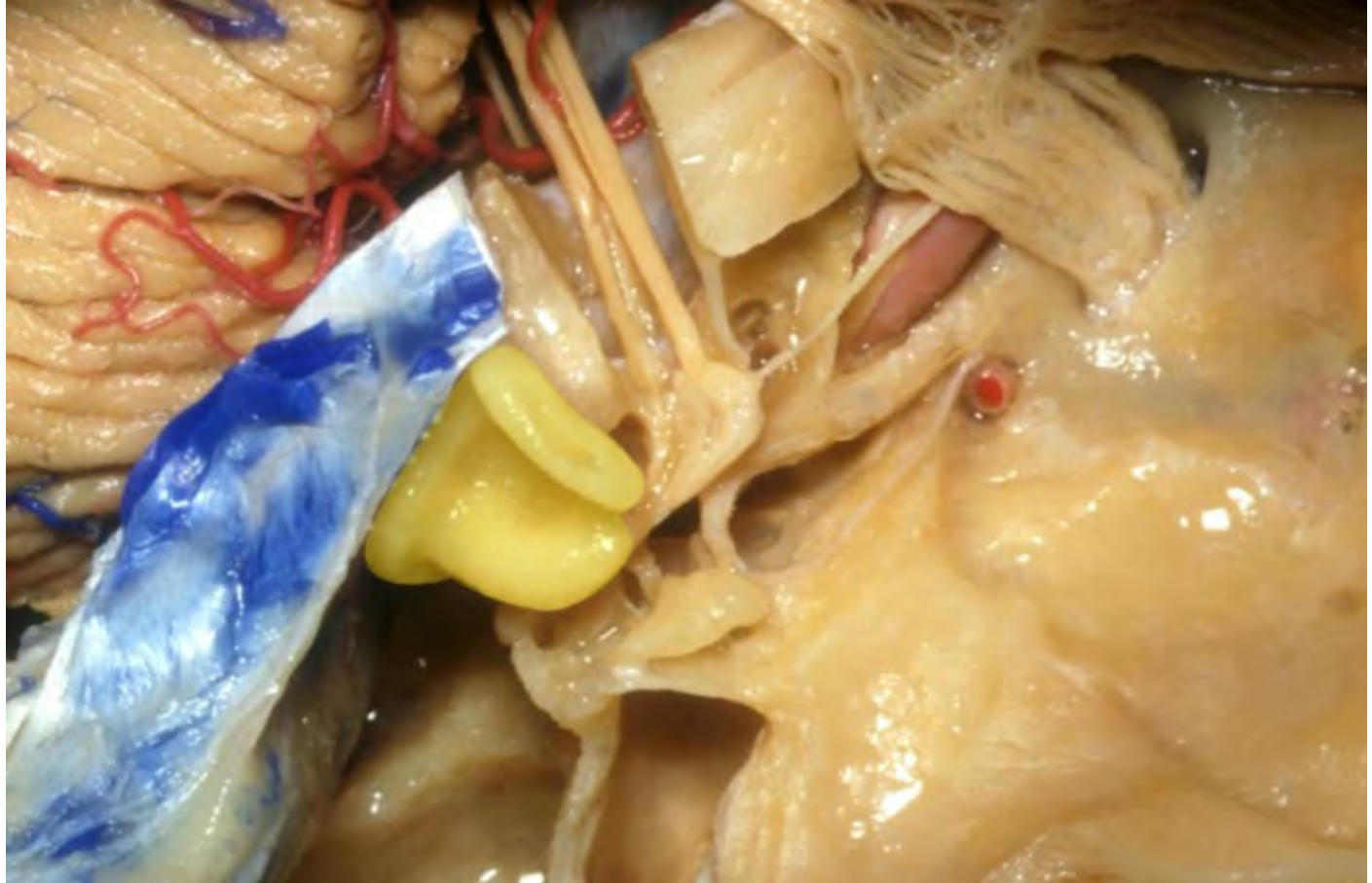


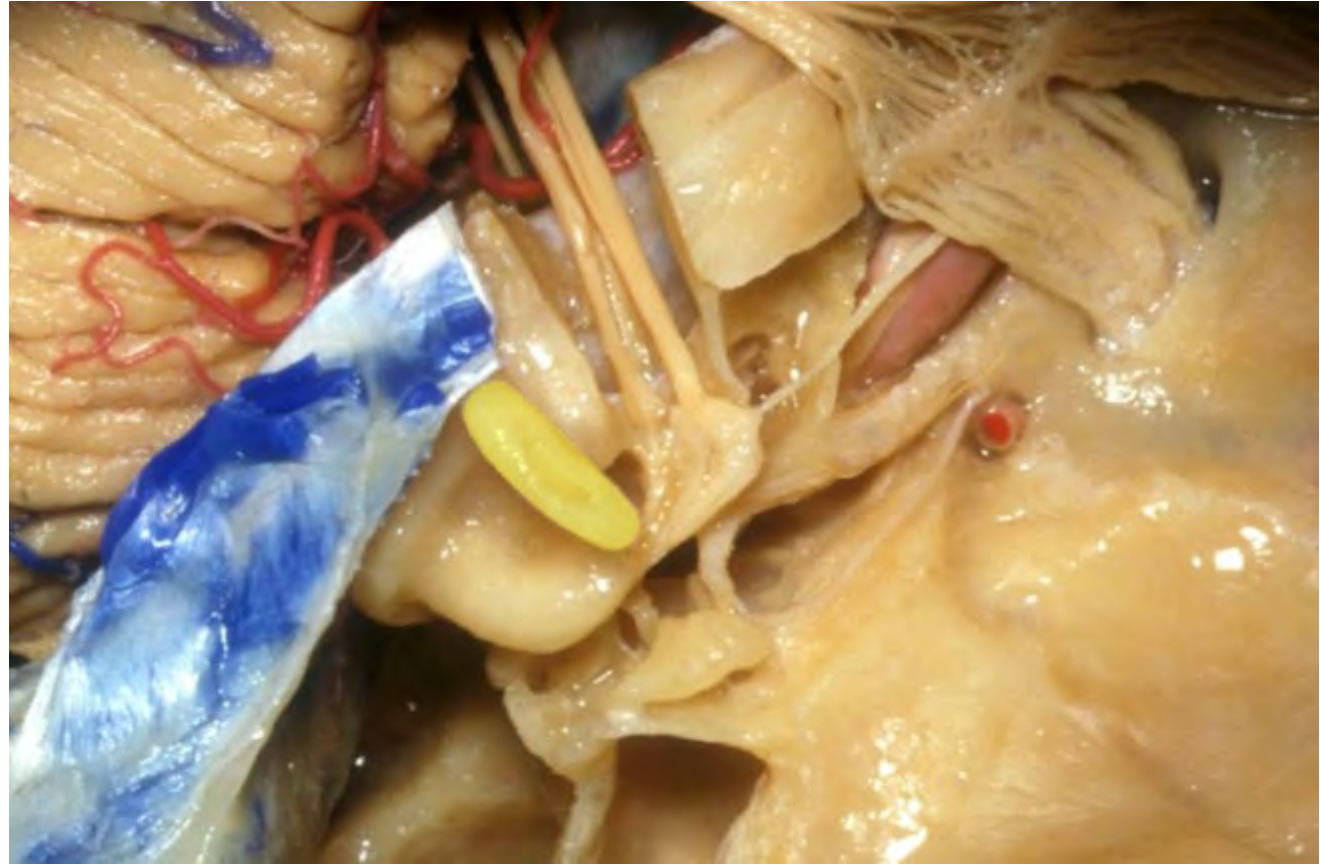
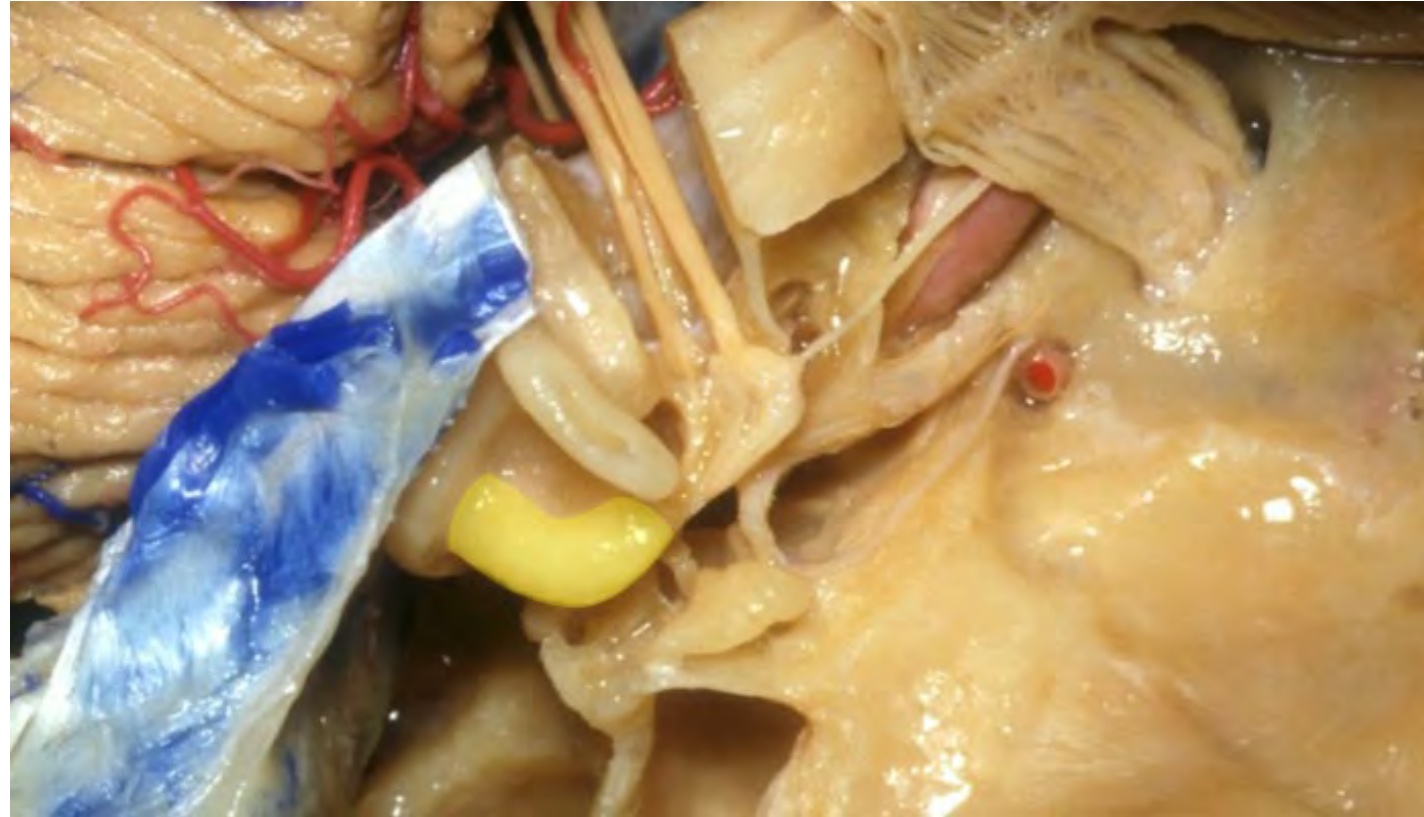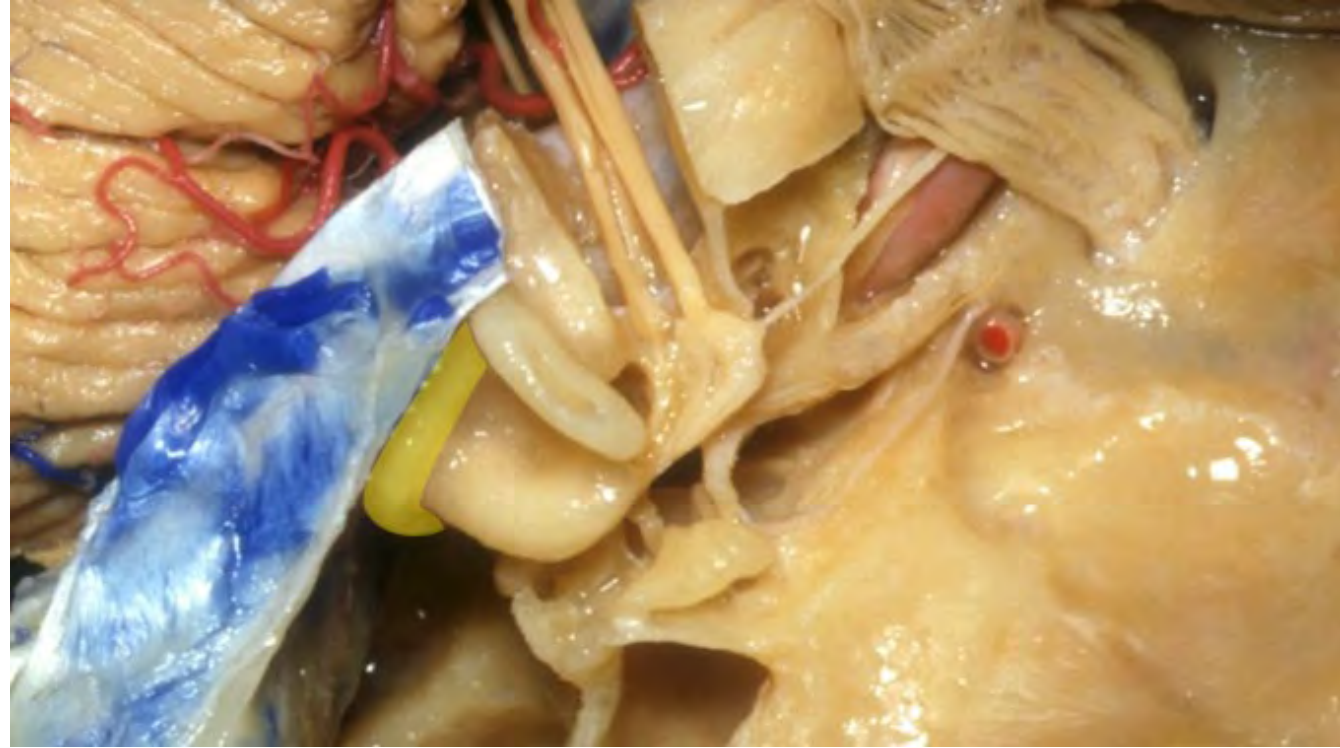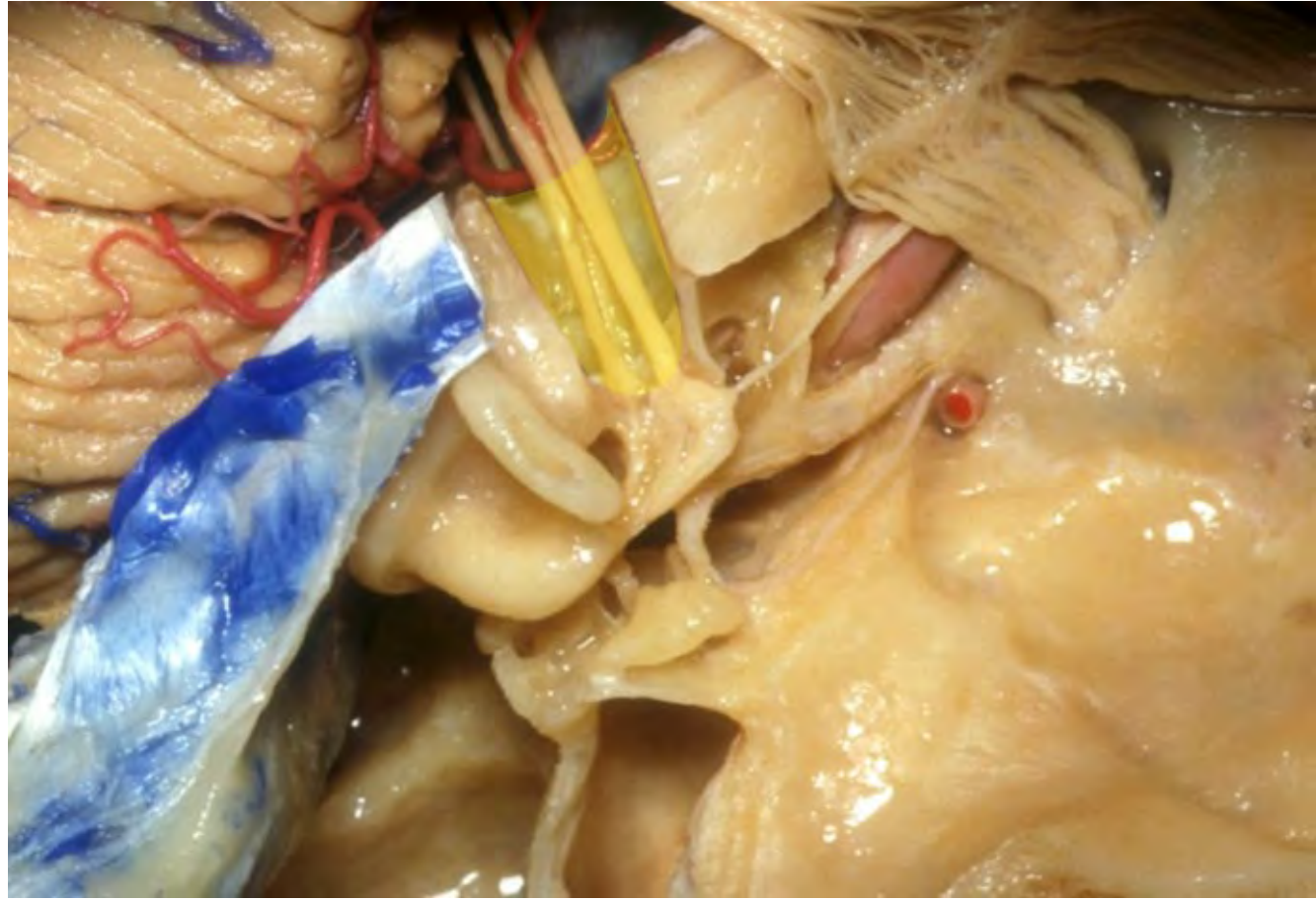








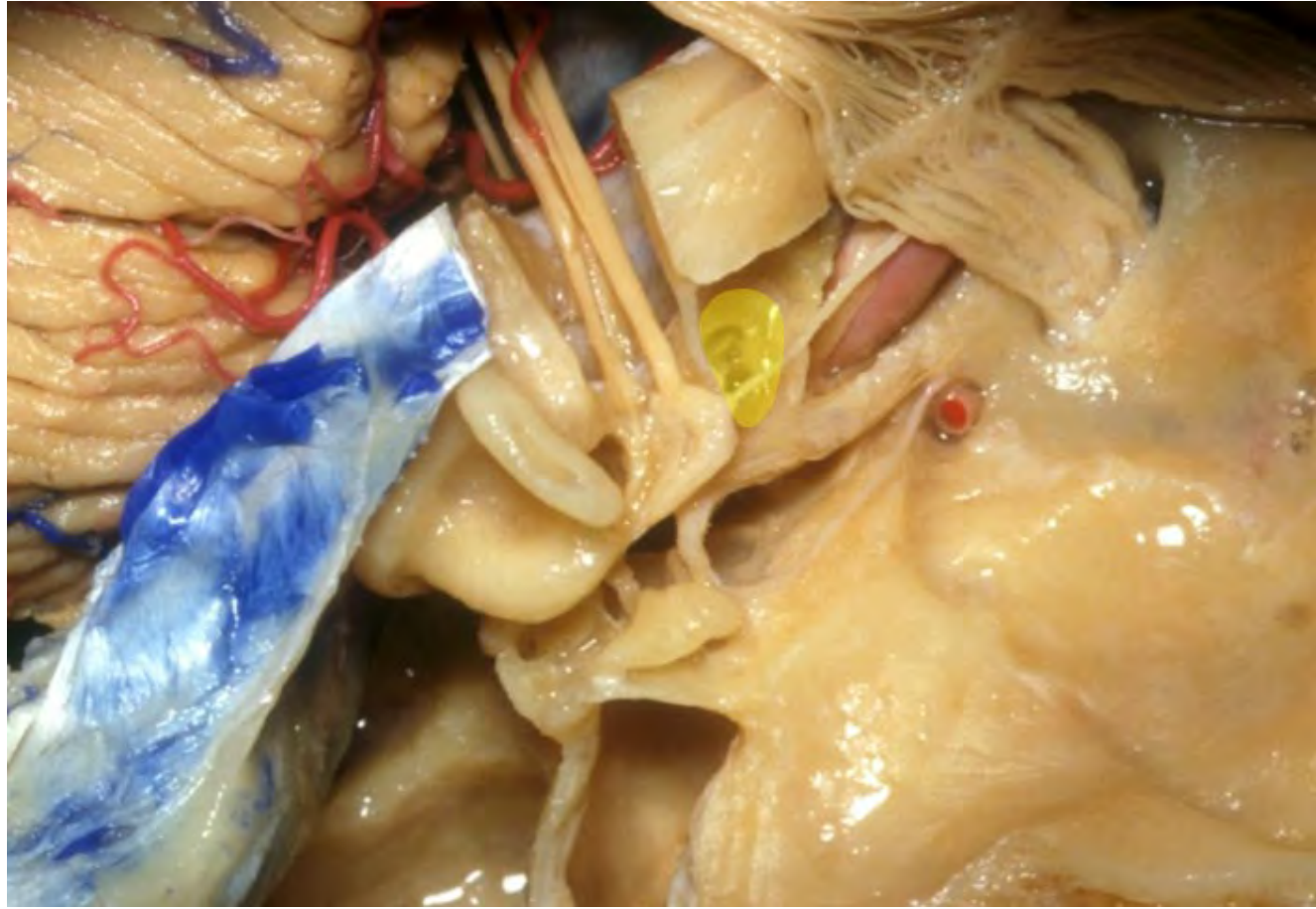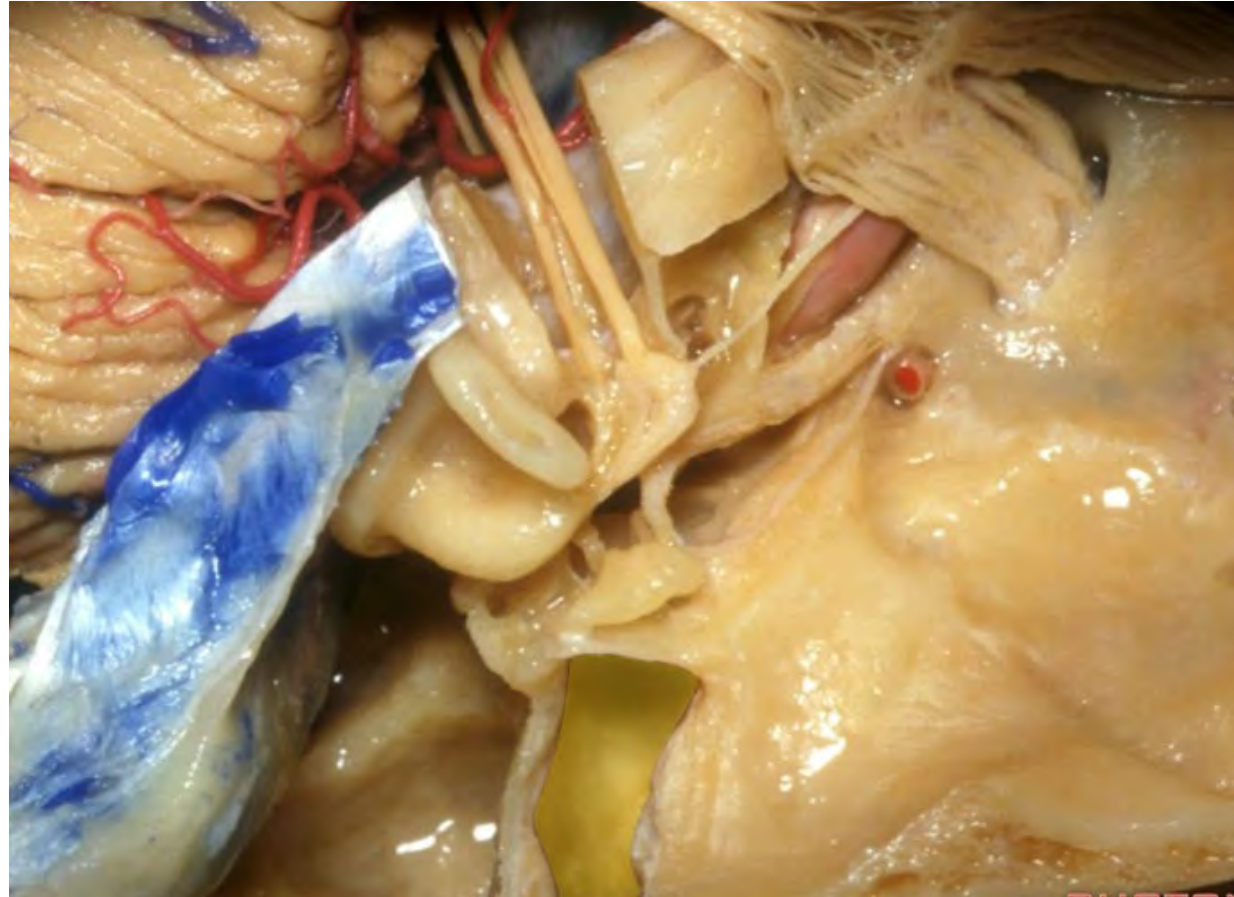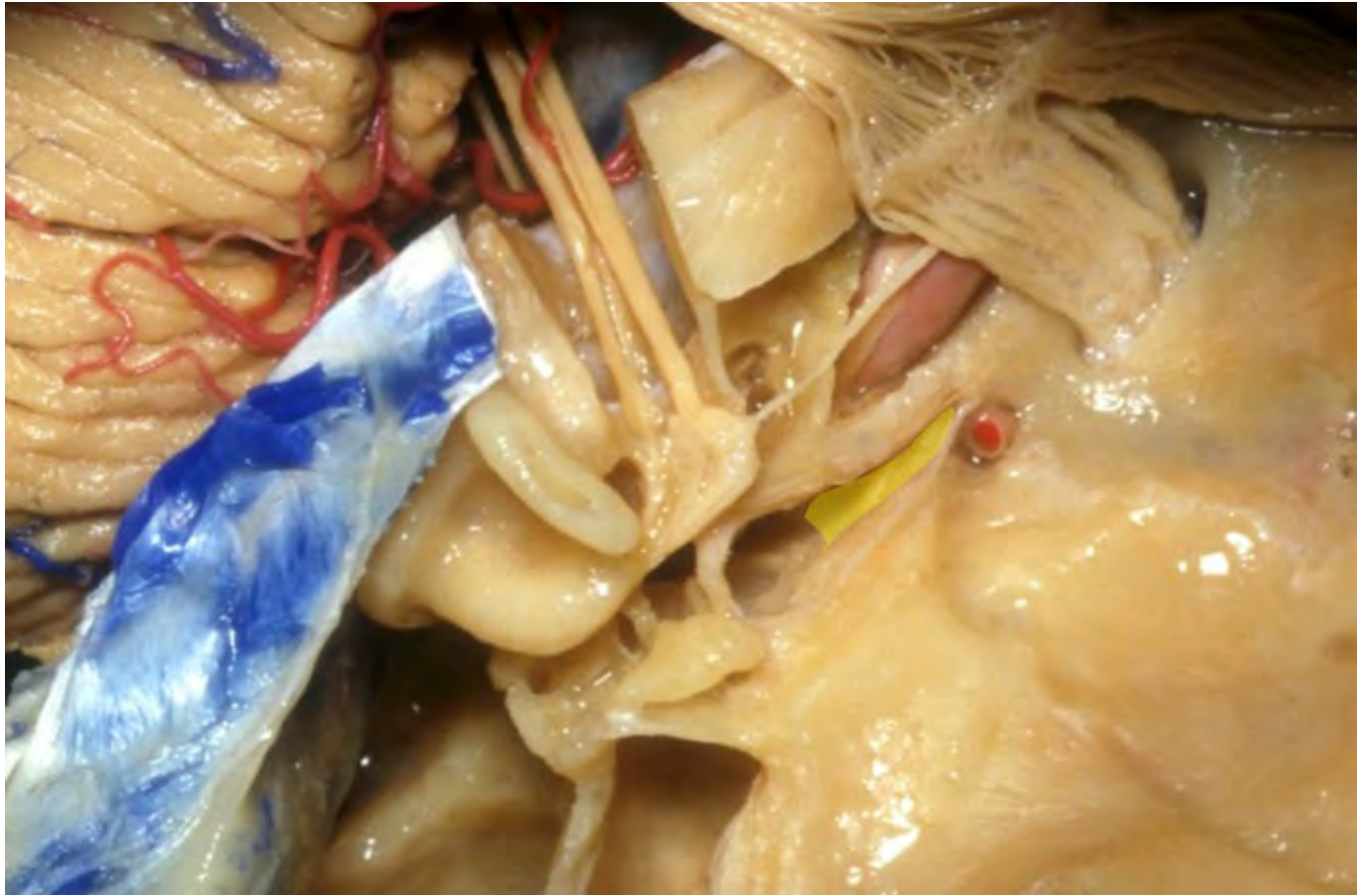




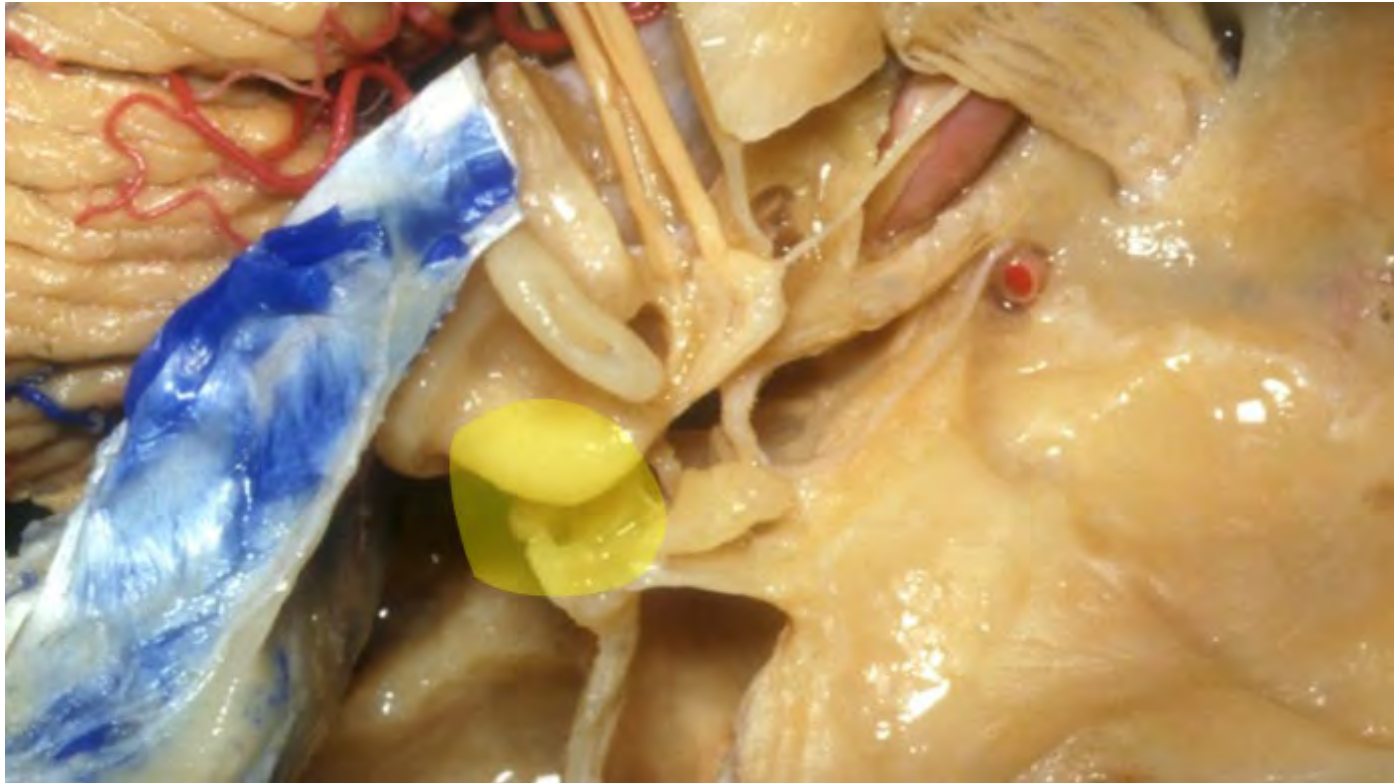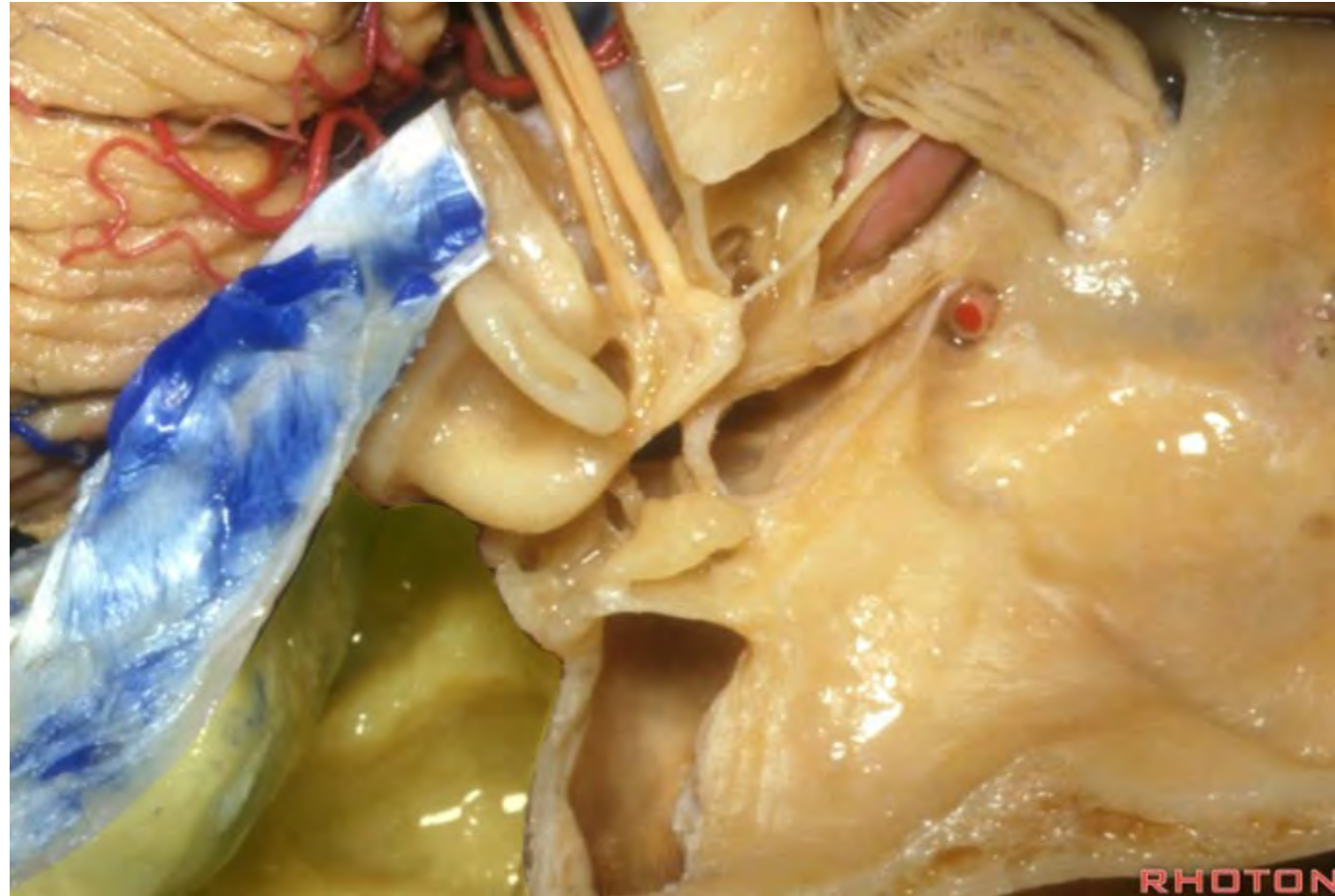




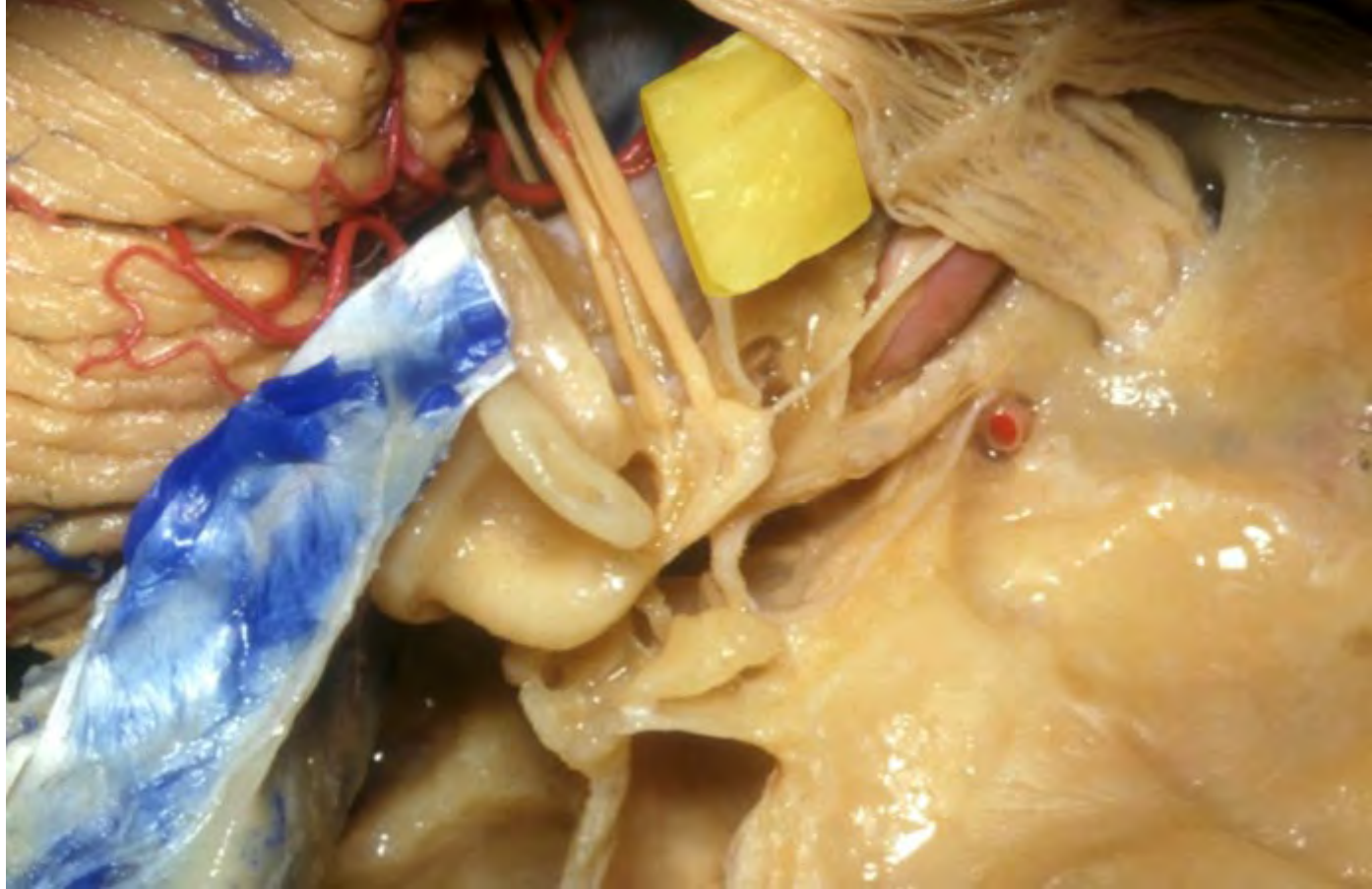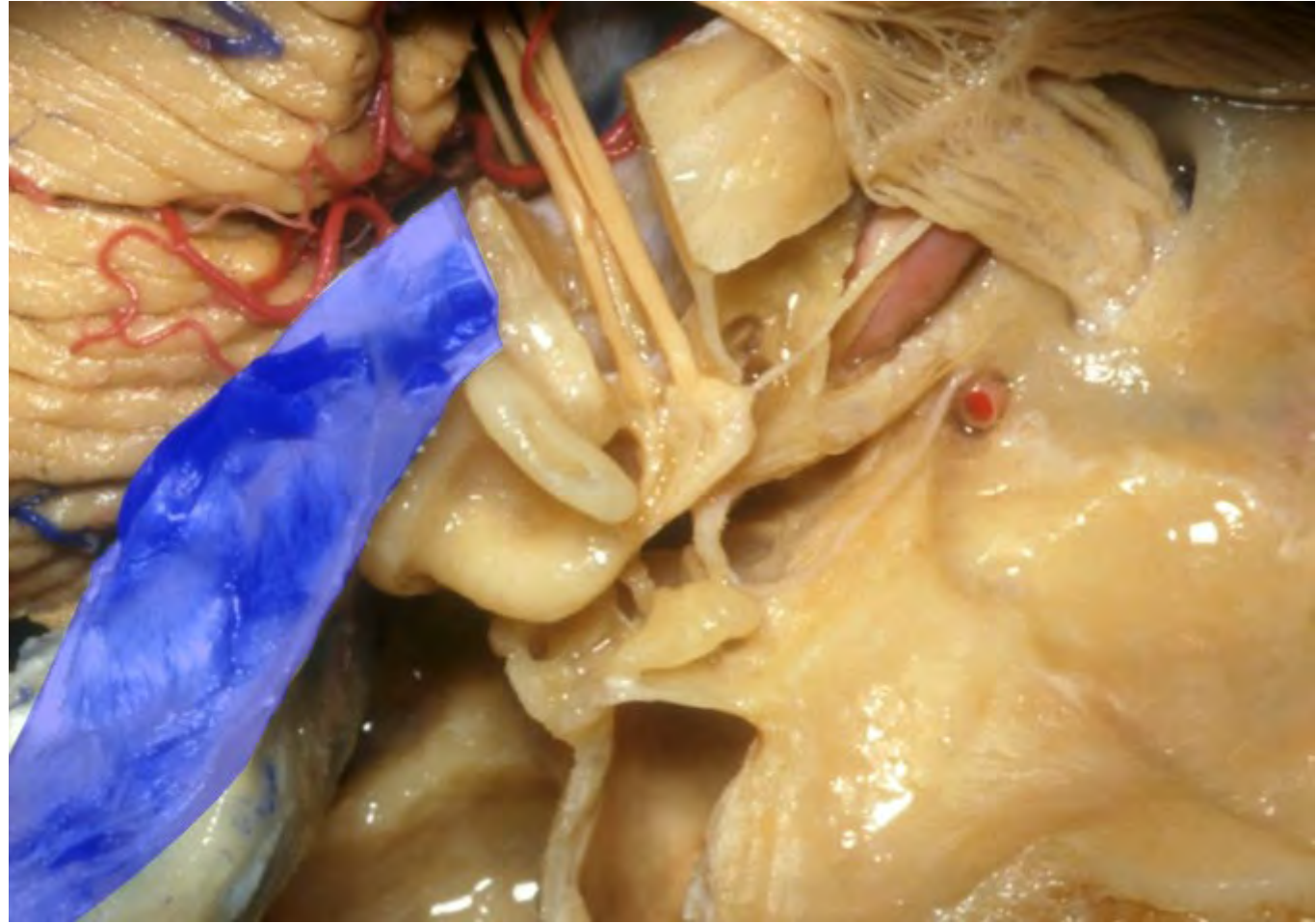


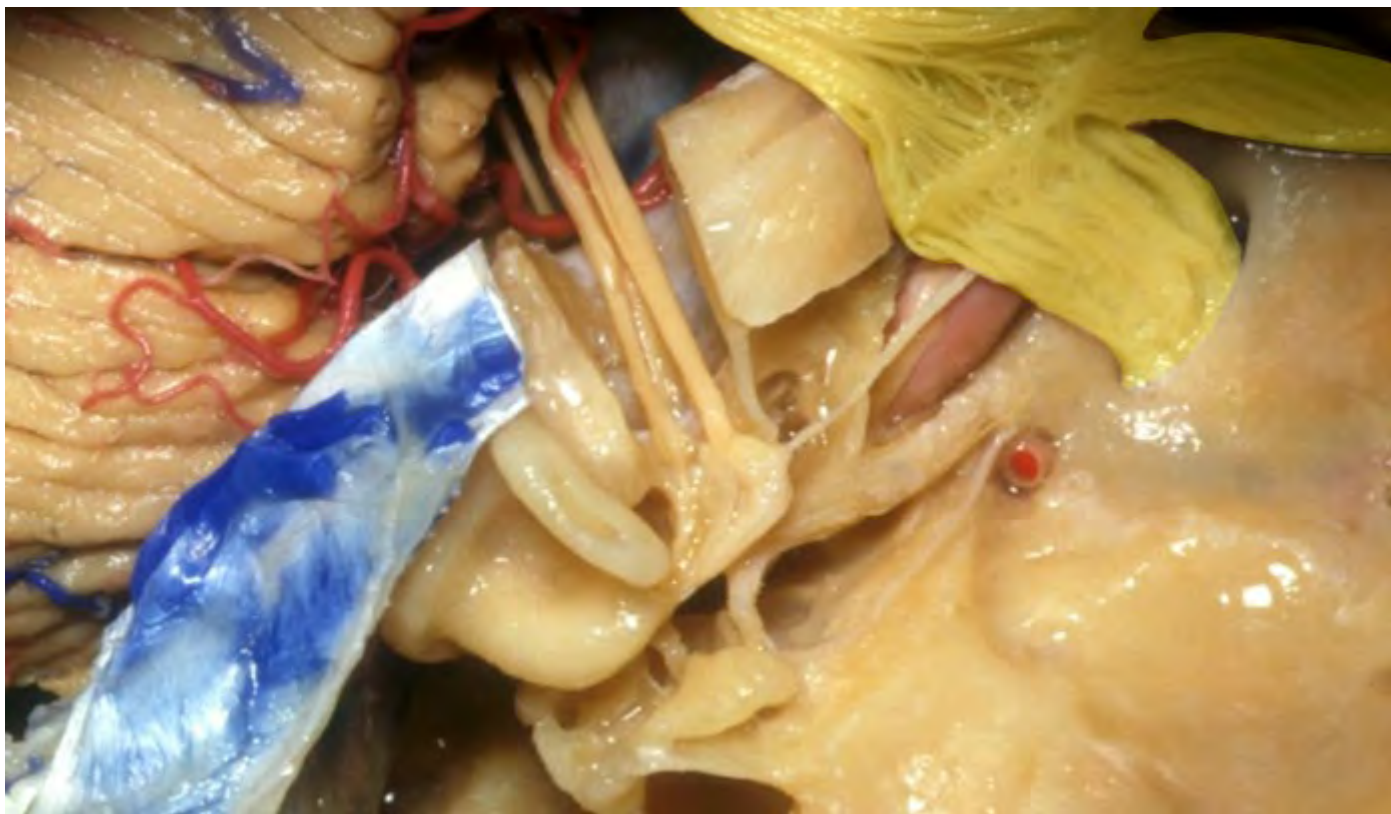


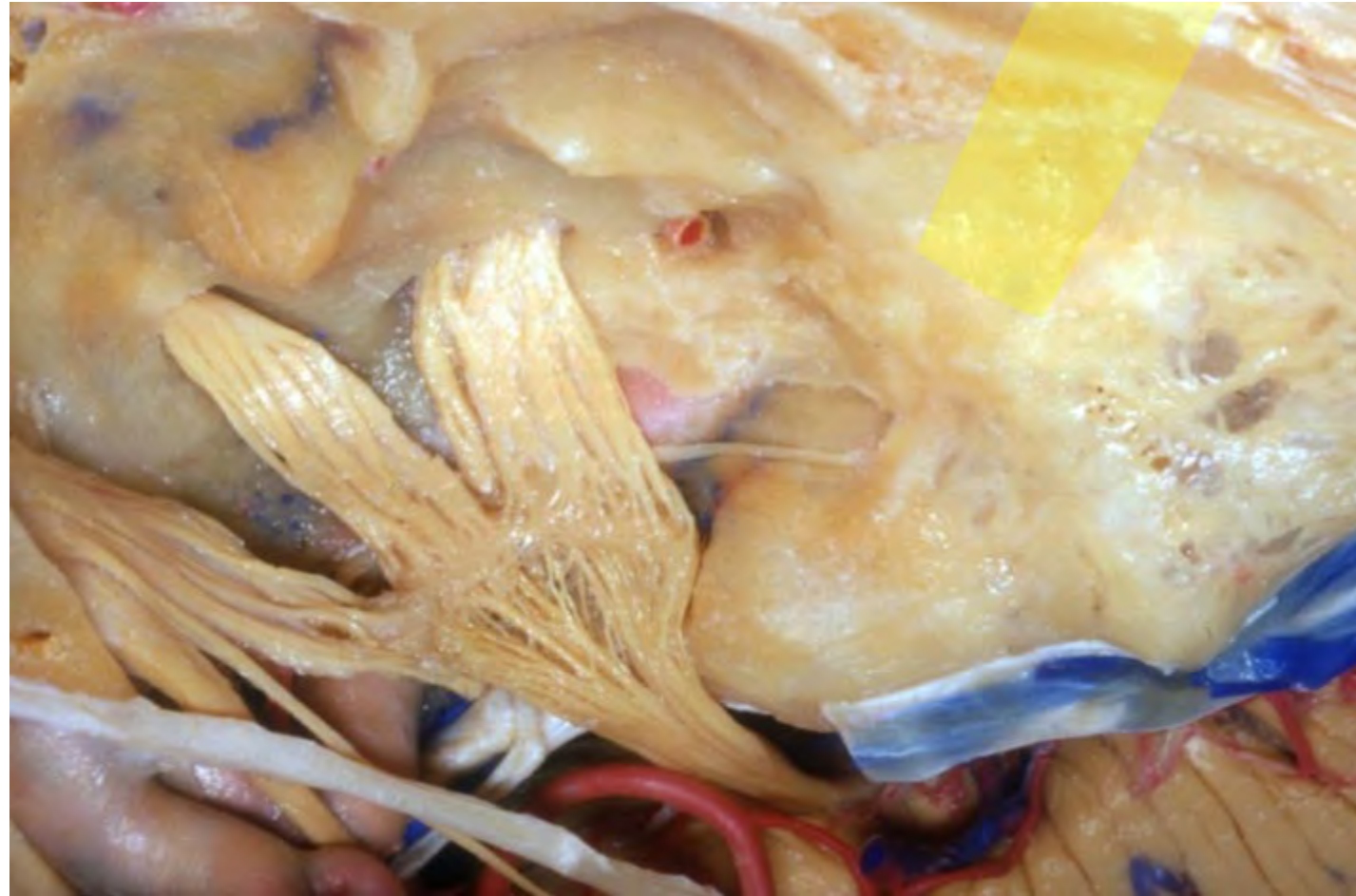




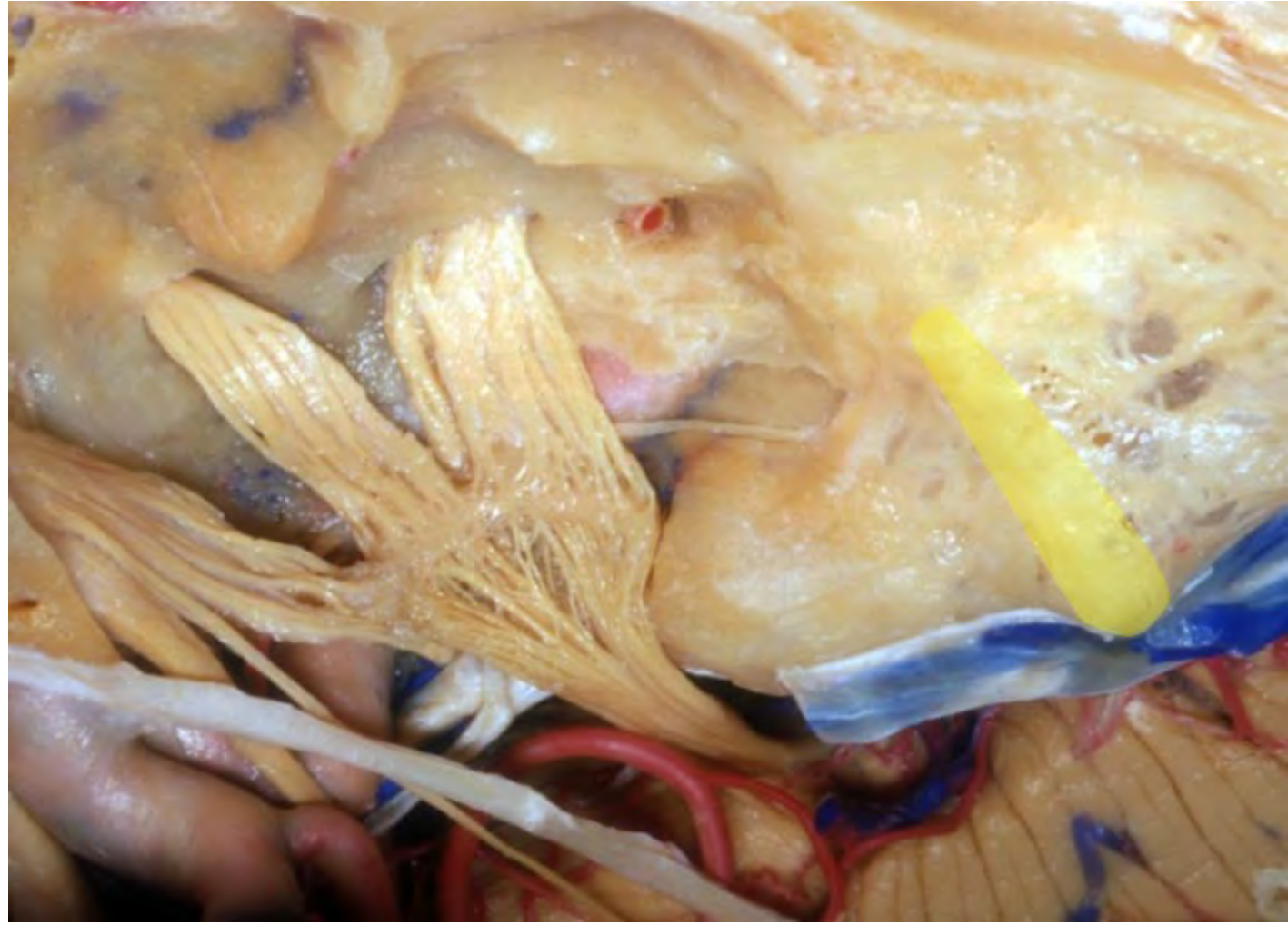




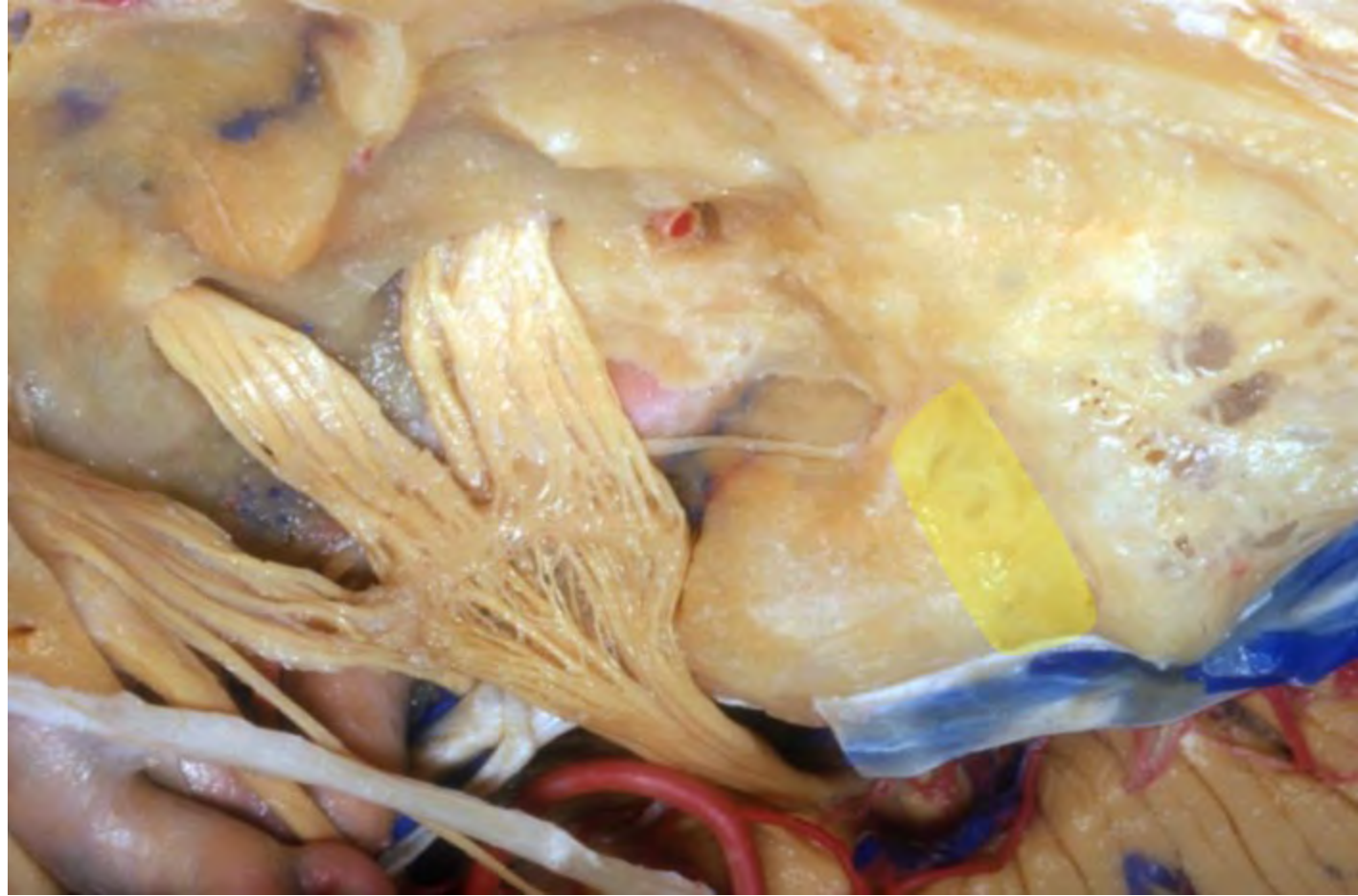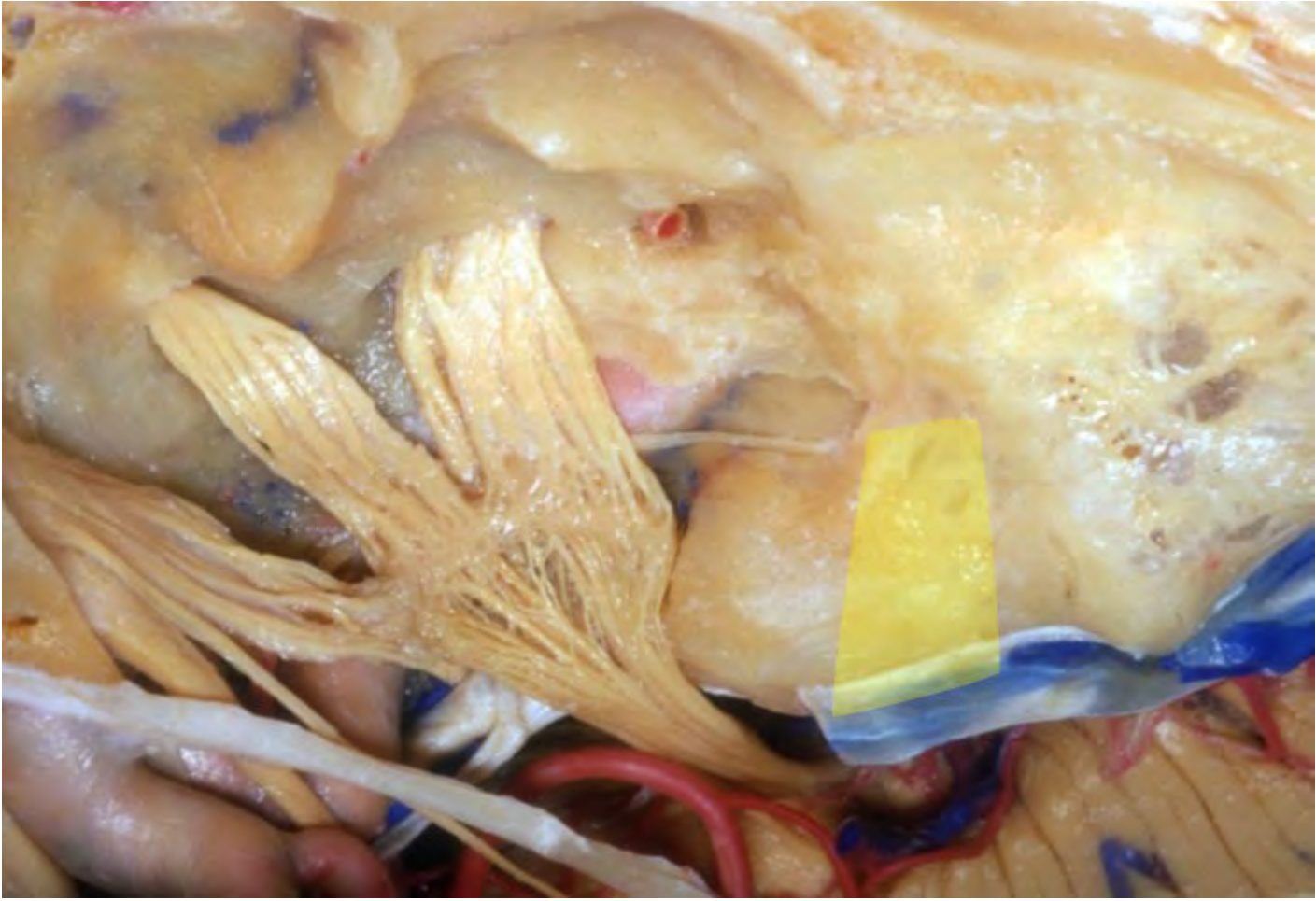




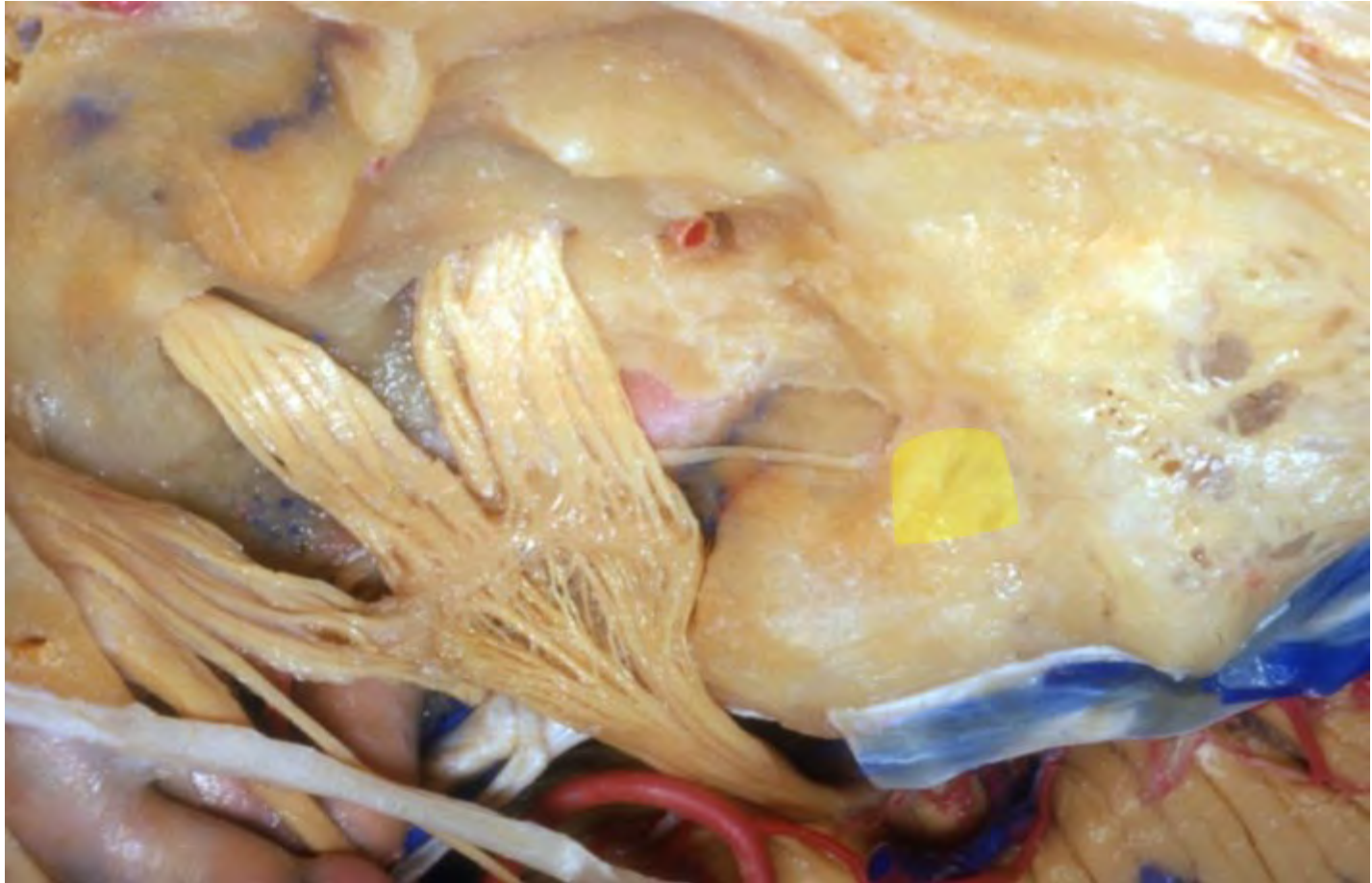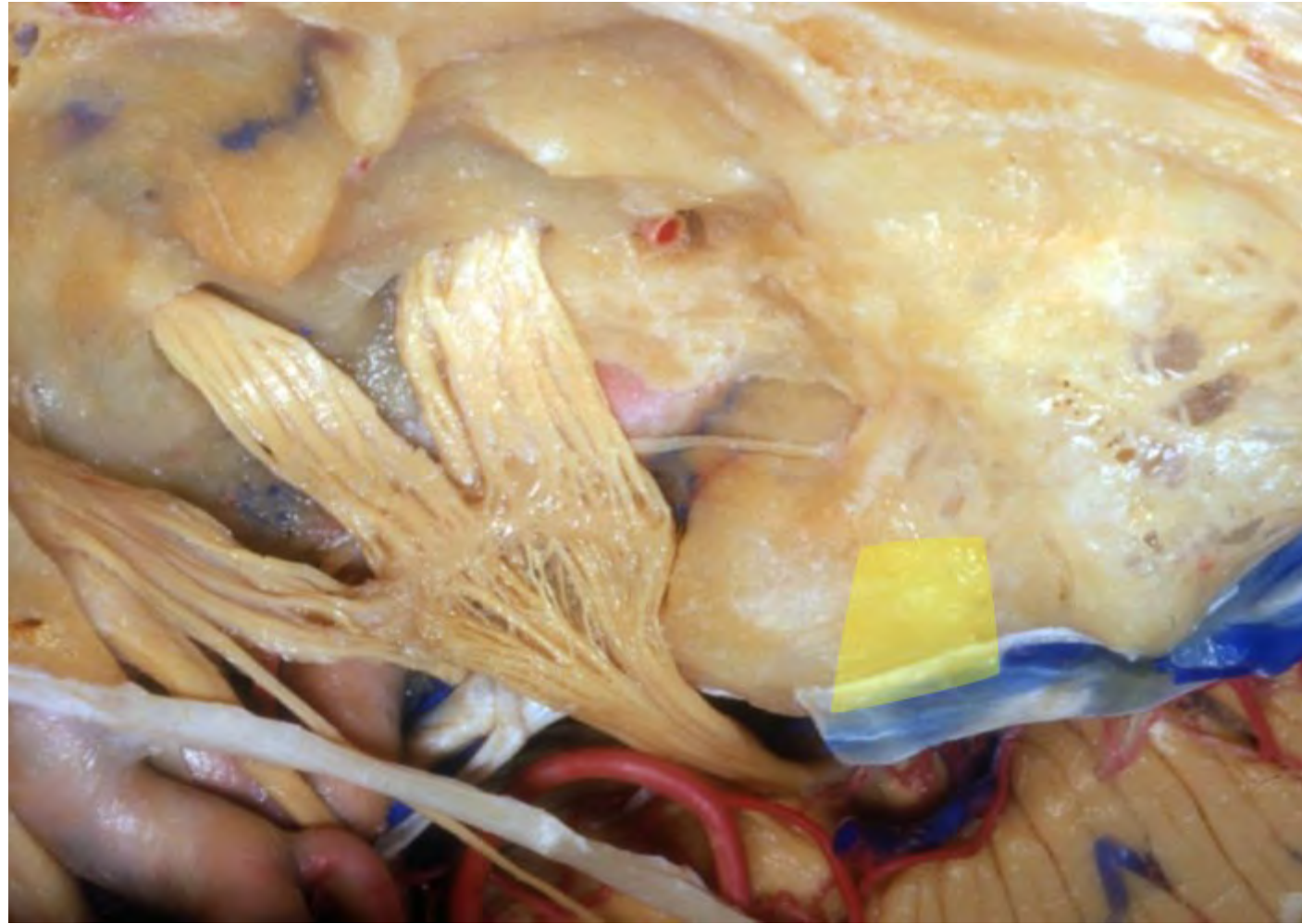






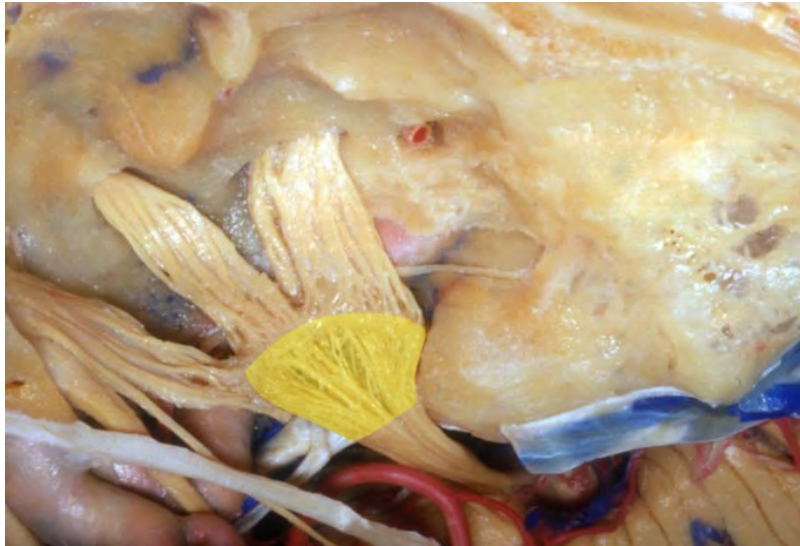




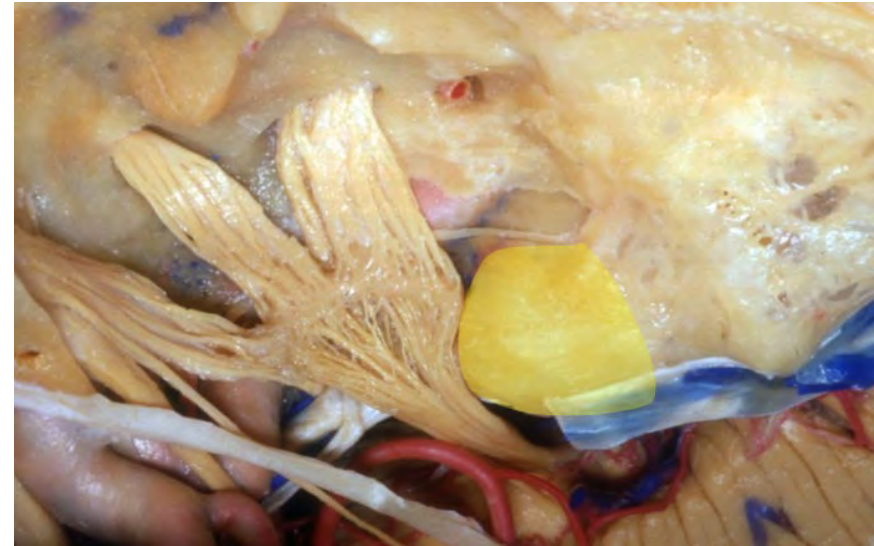


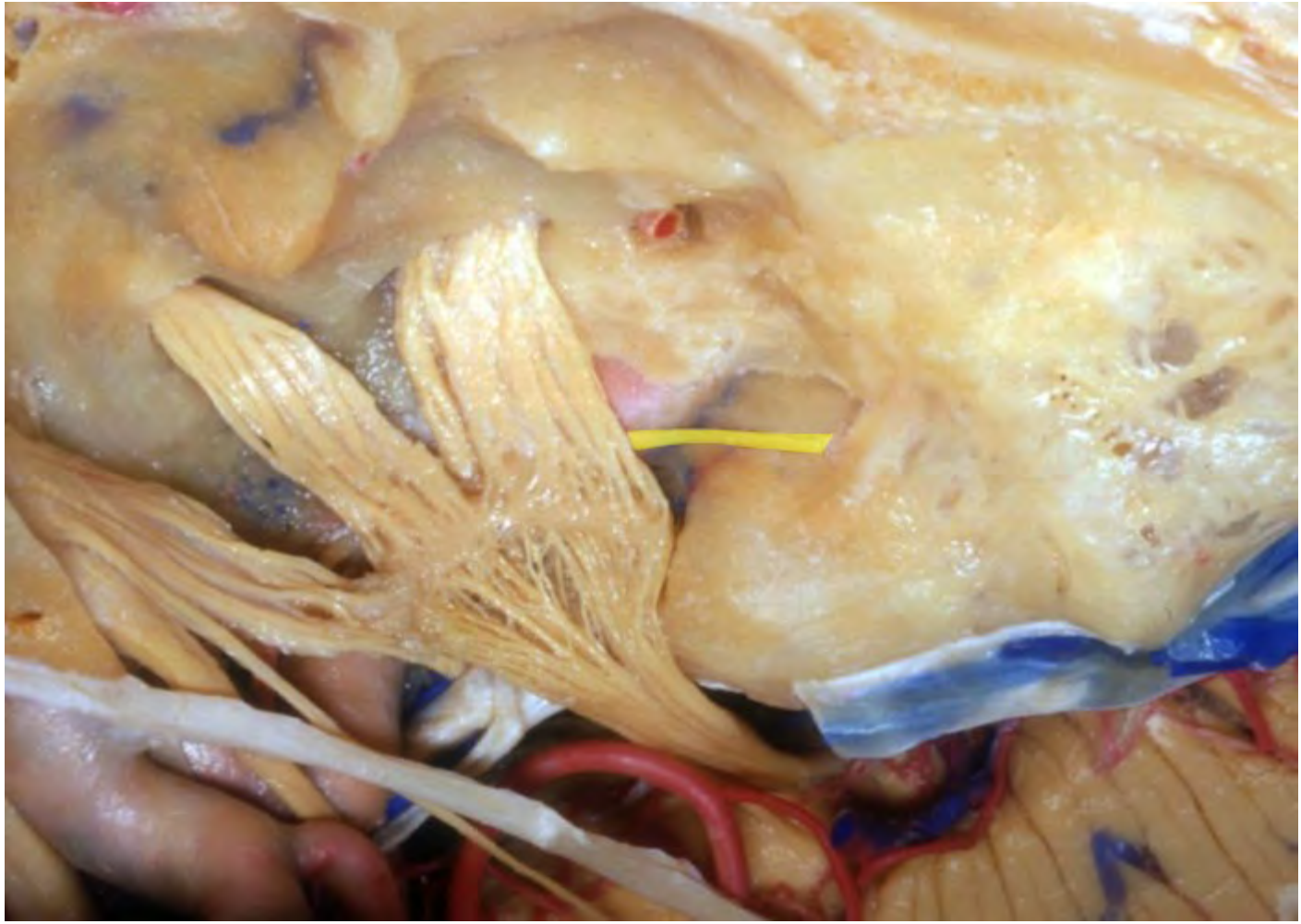


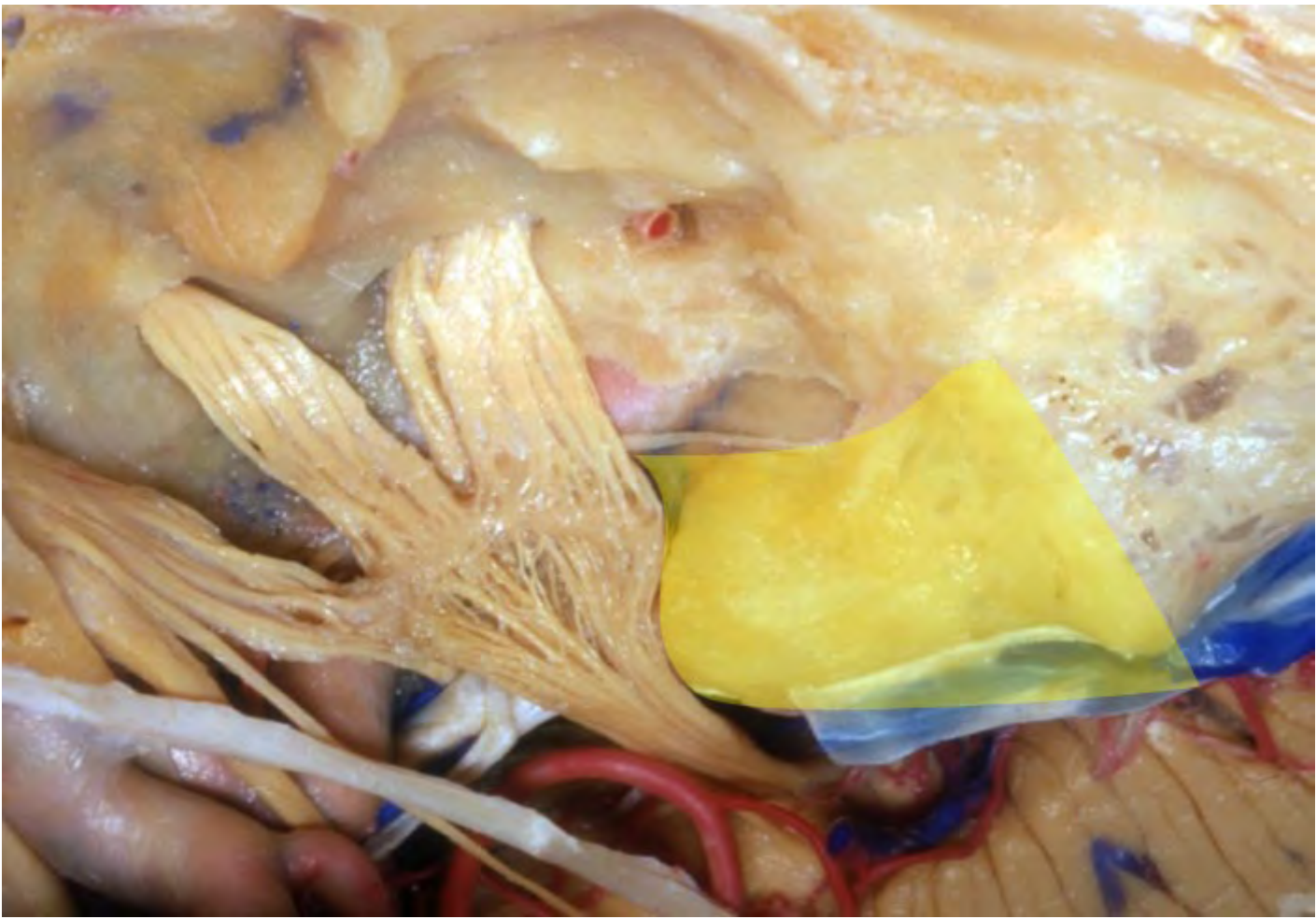
**Trigeminal ganglion**



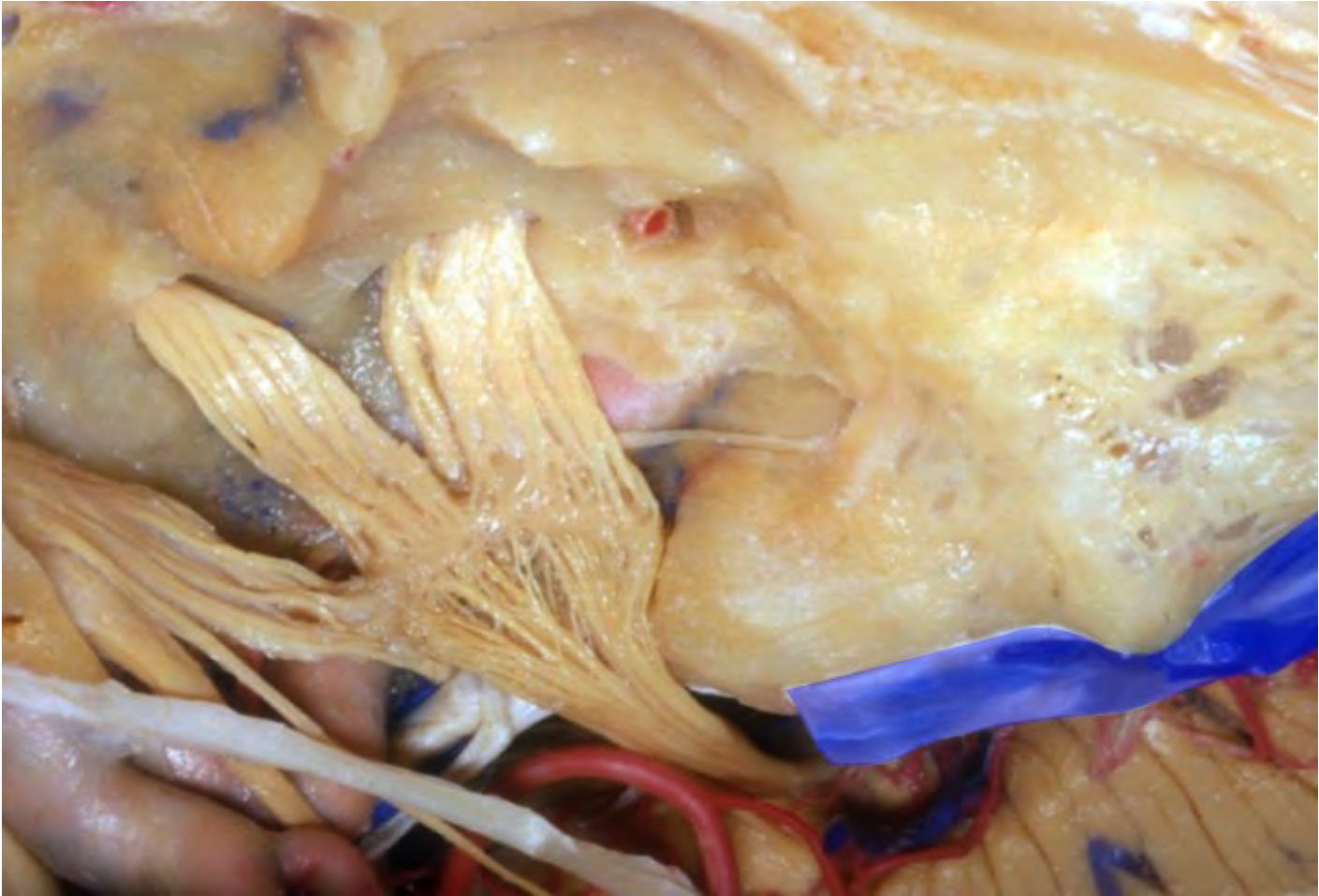**Trigeminal prominence**

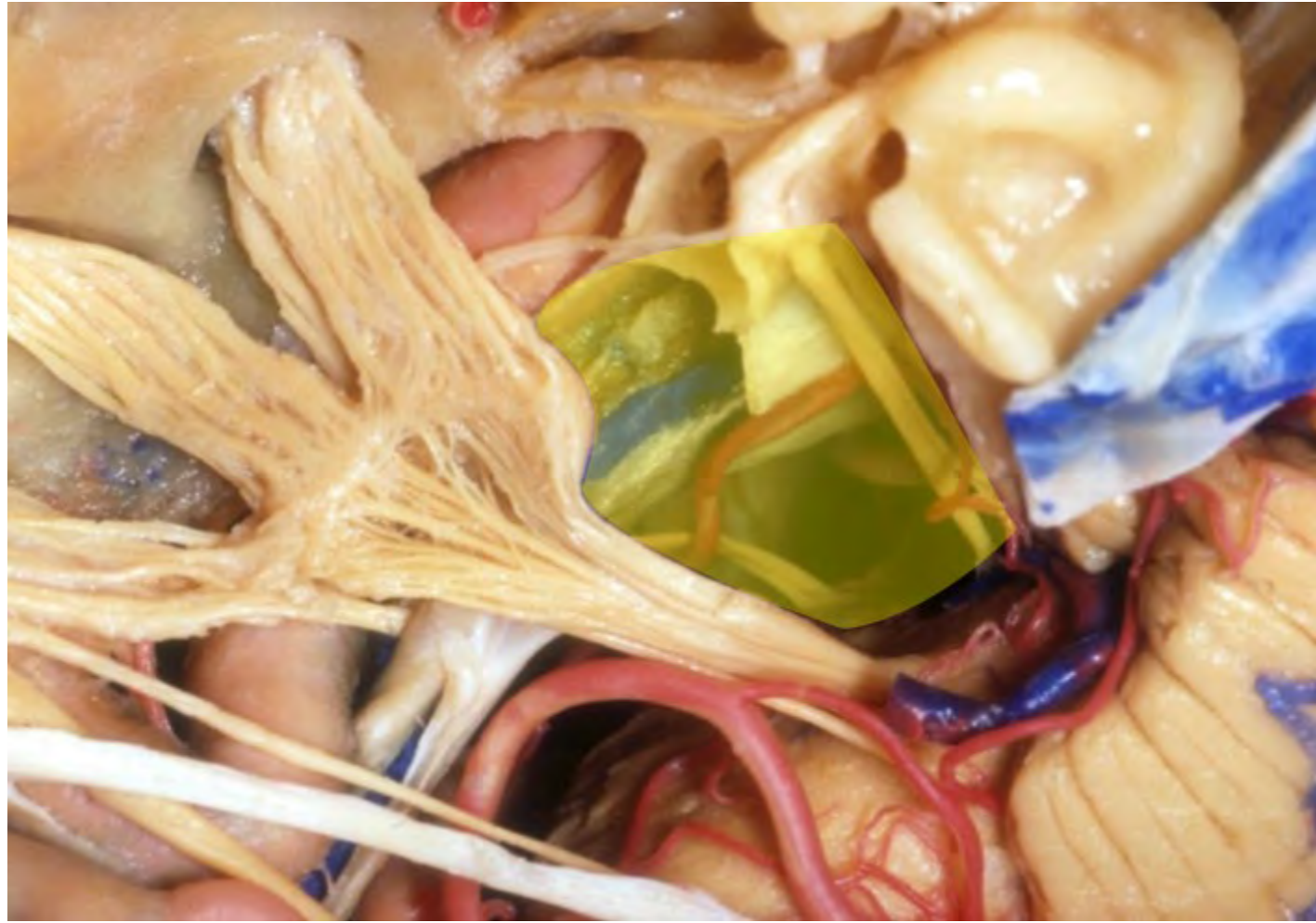


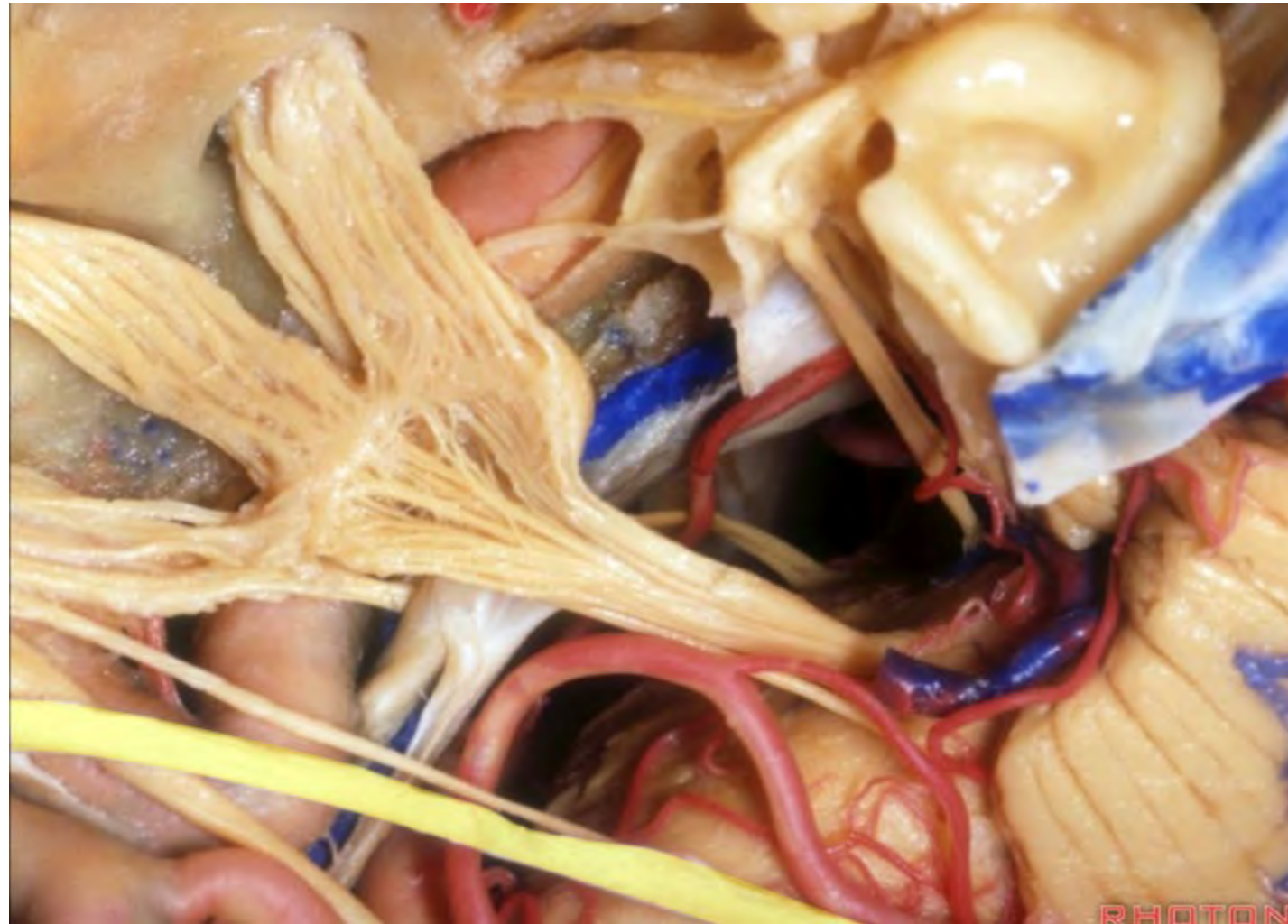
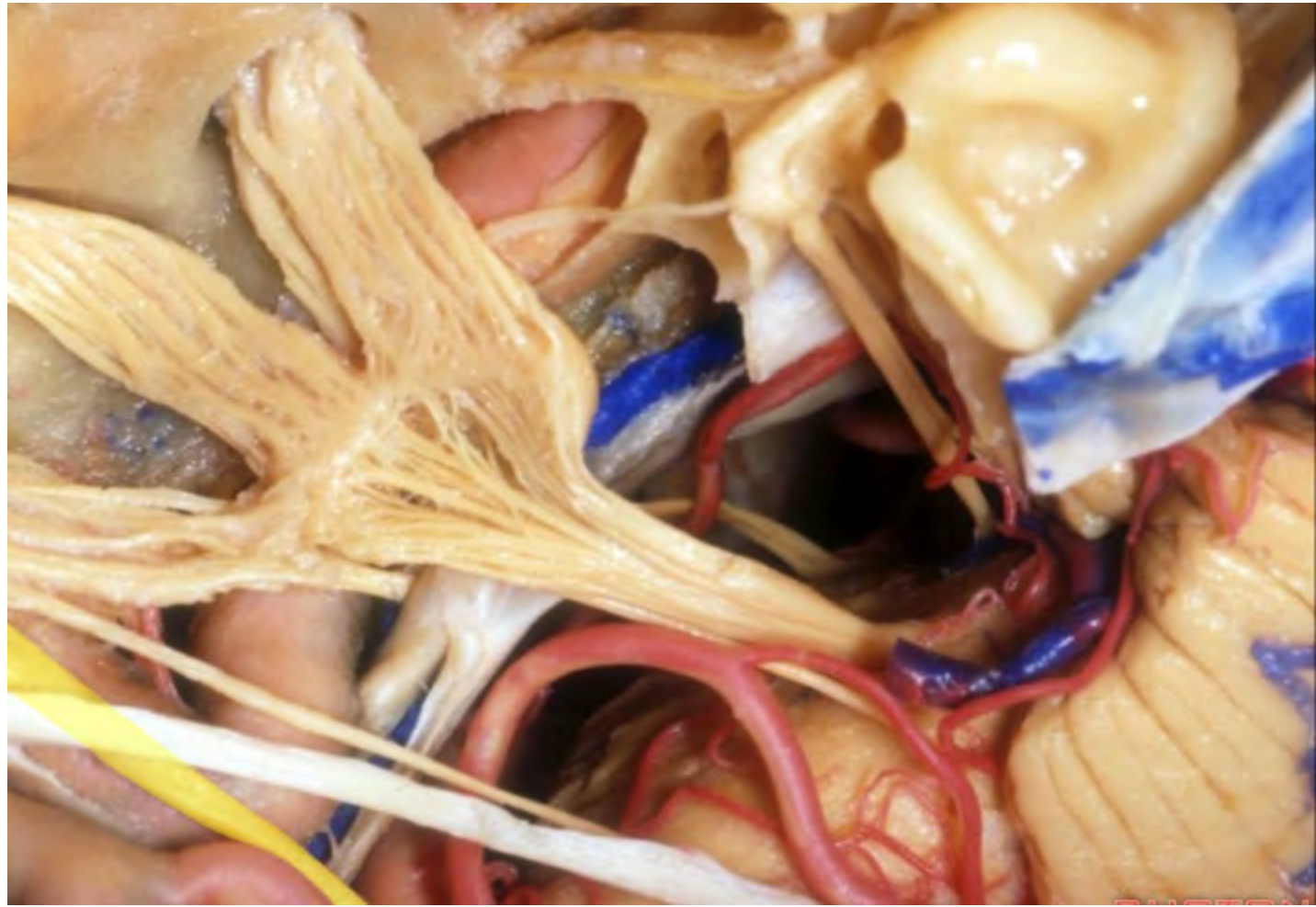


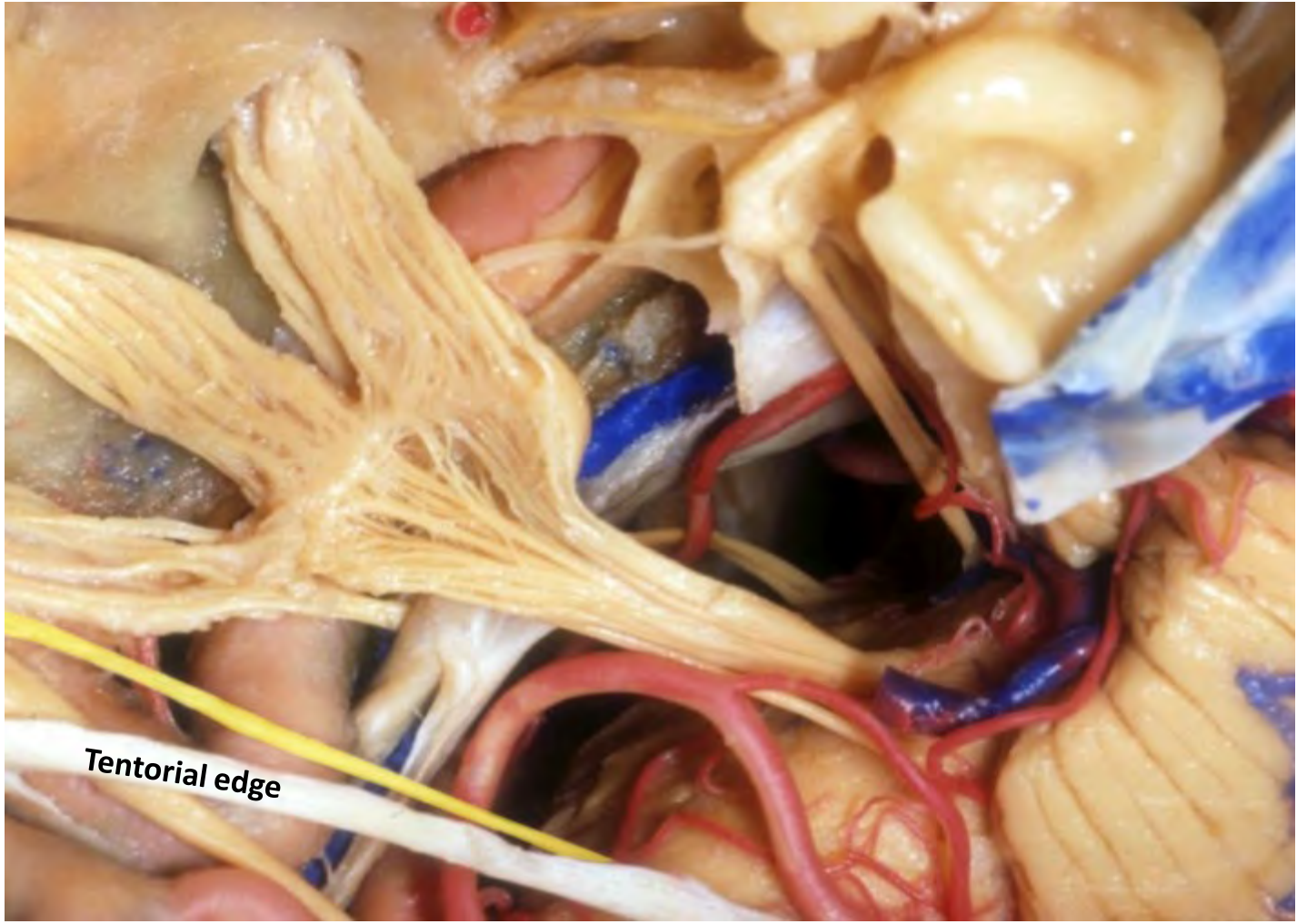




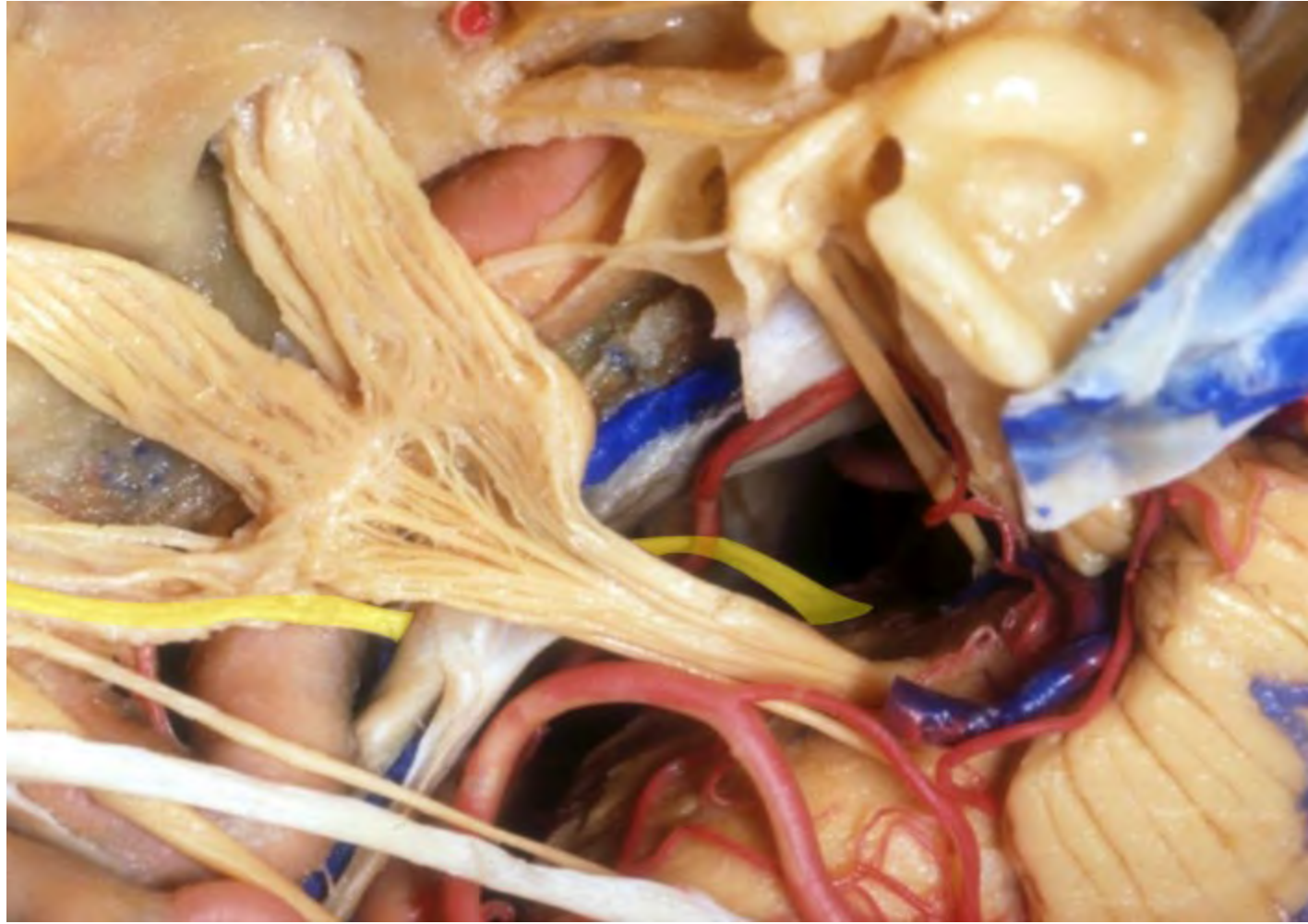


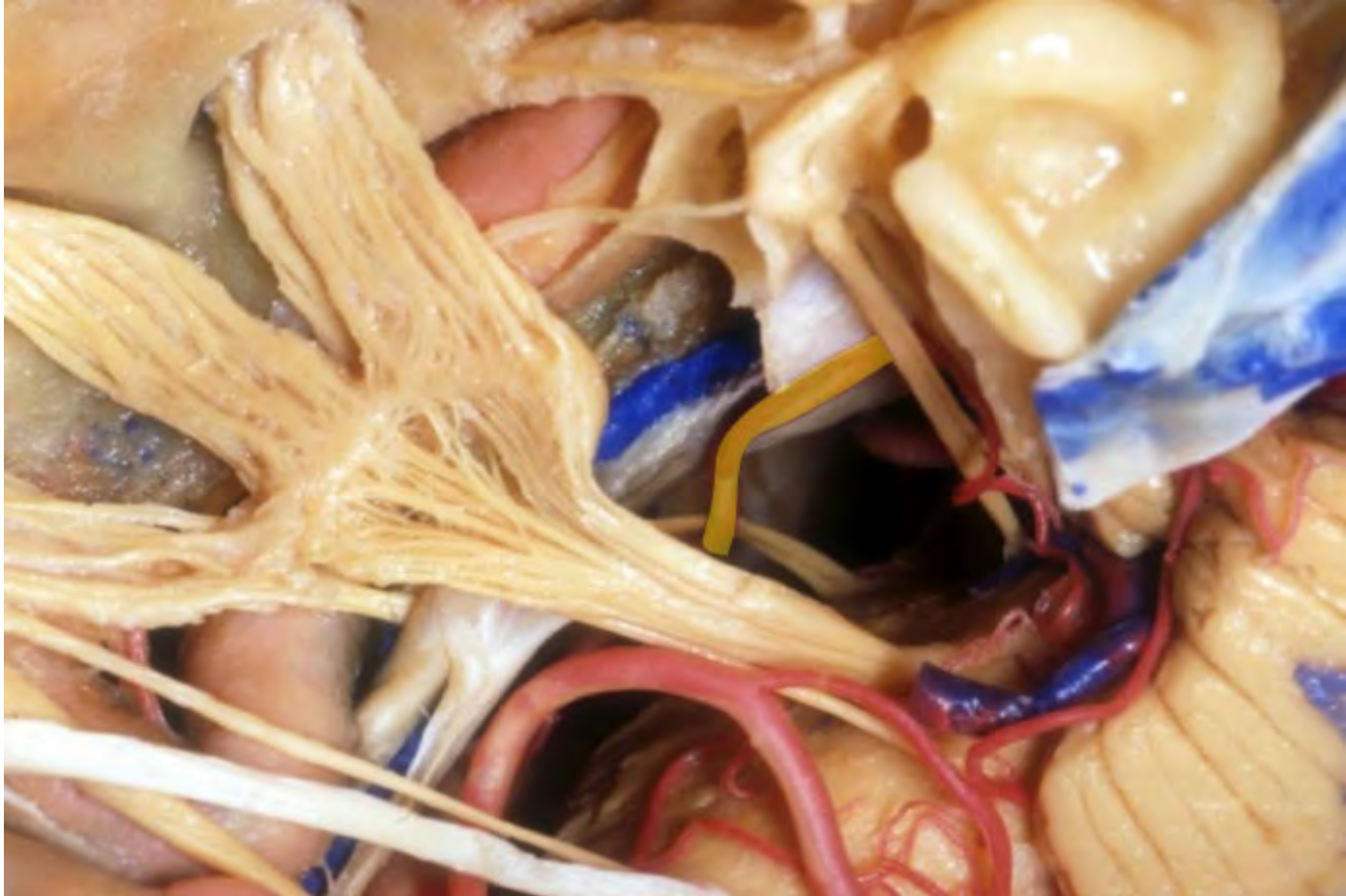




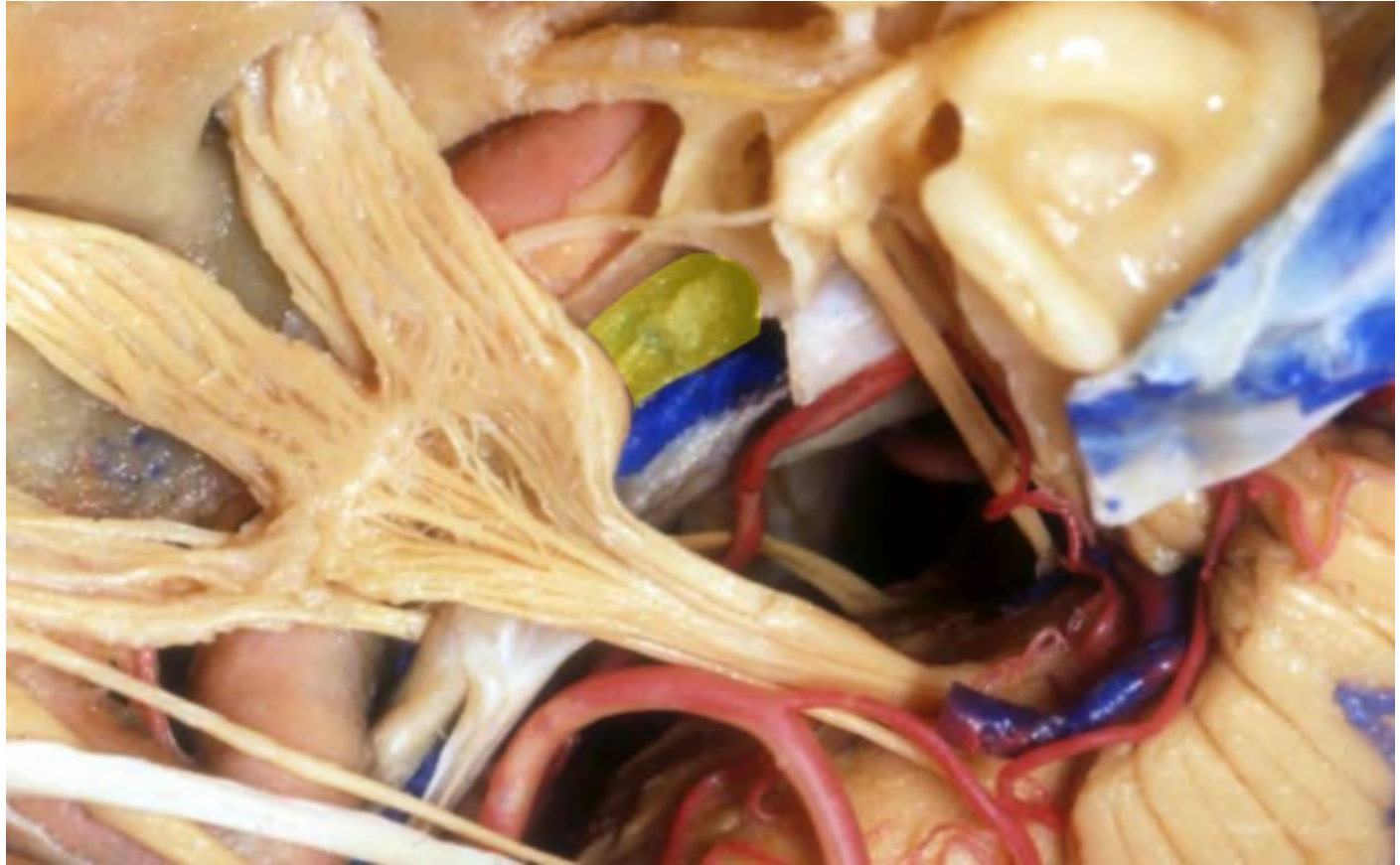


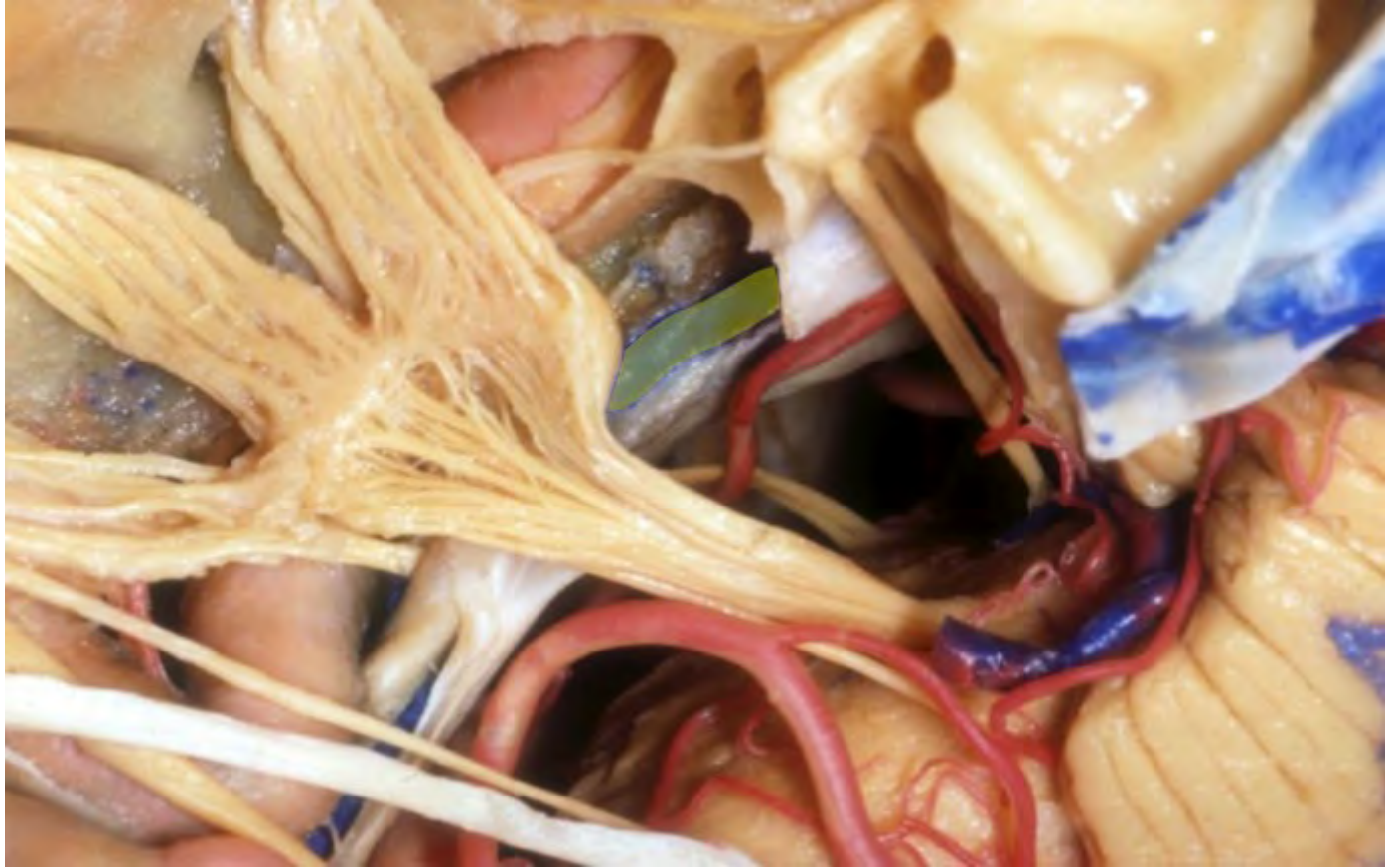






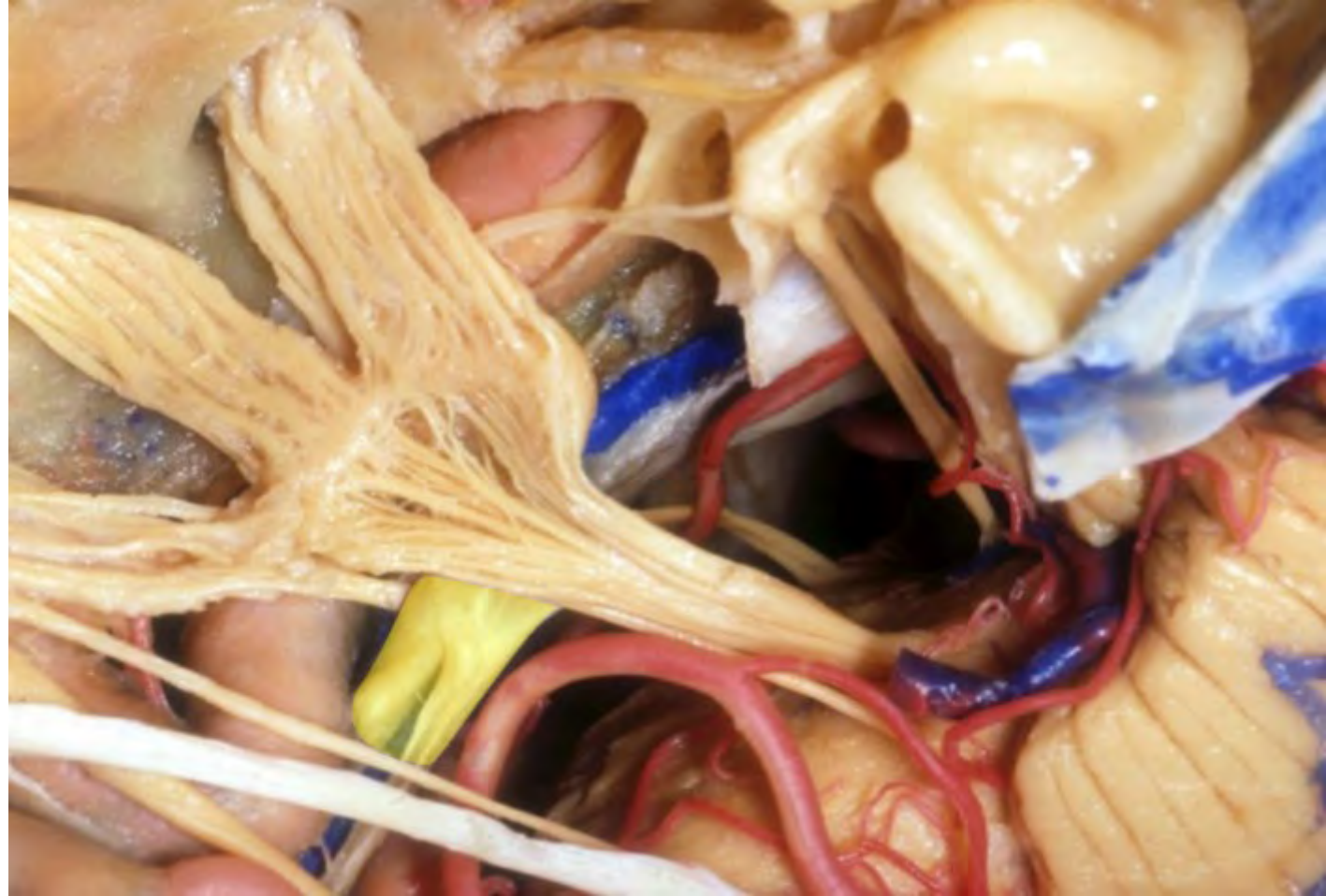


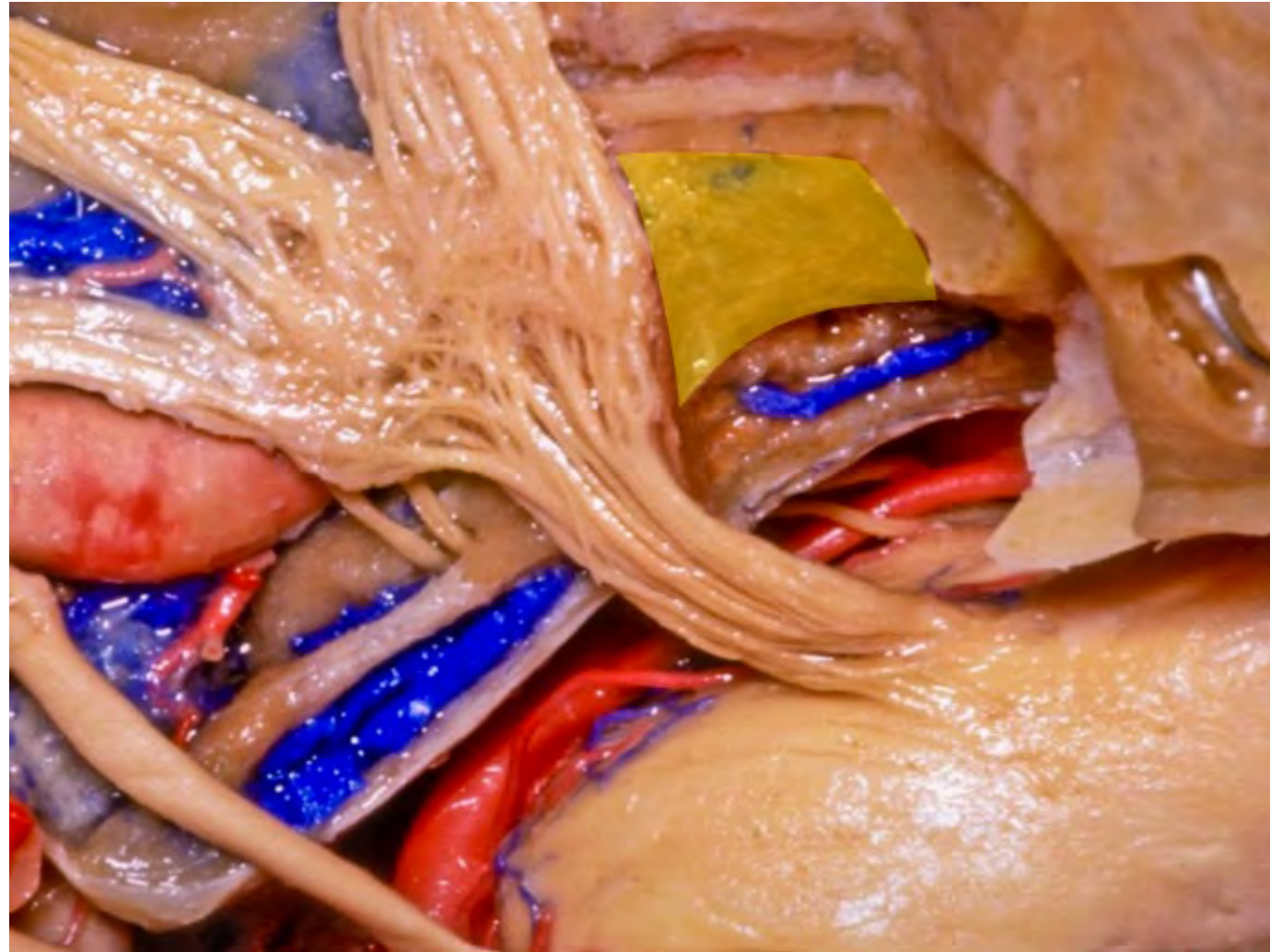


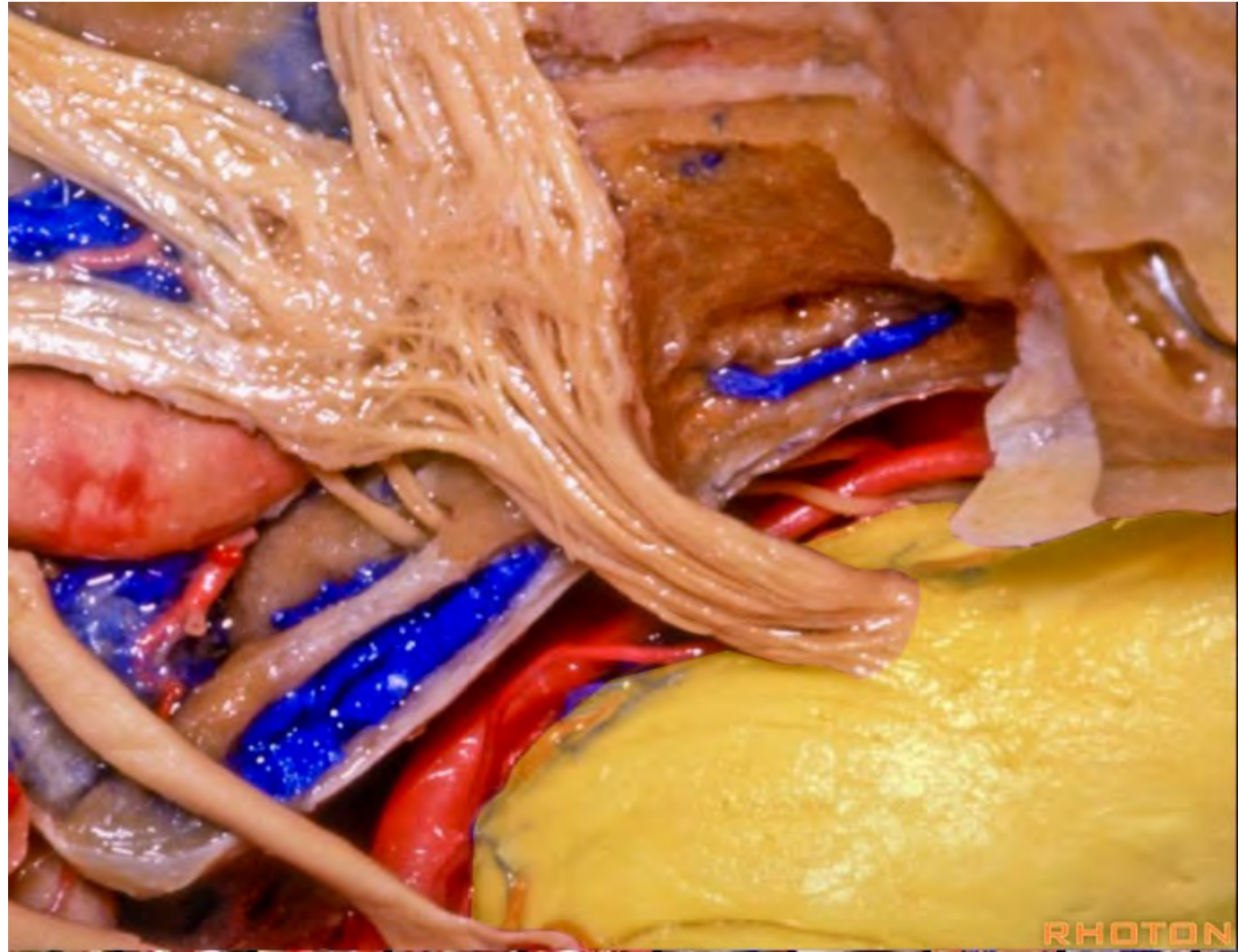


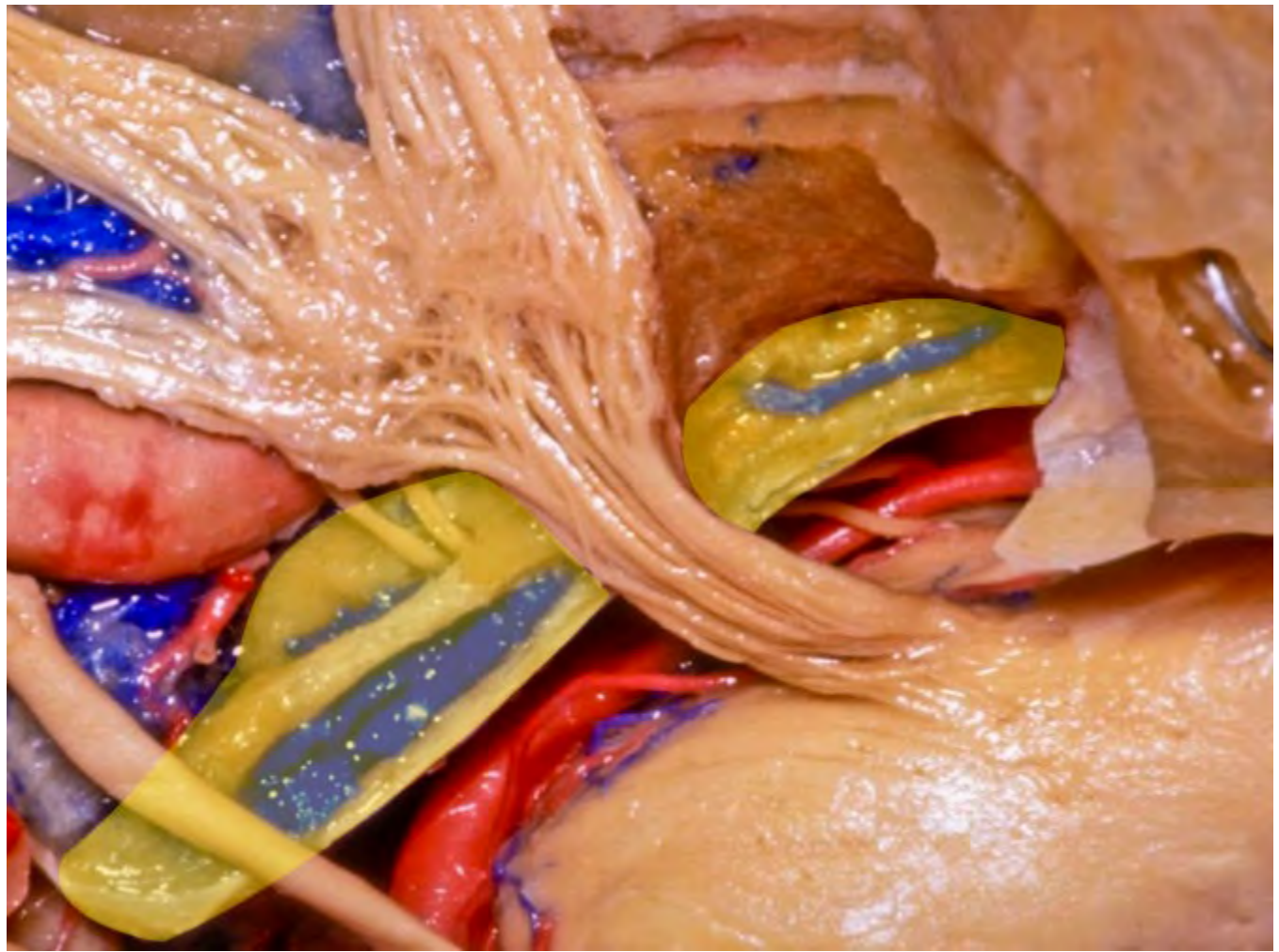


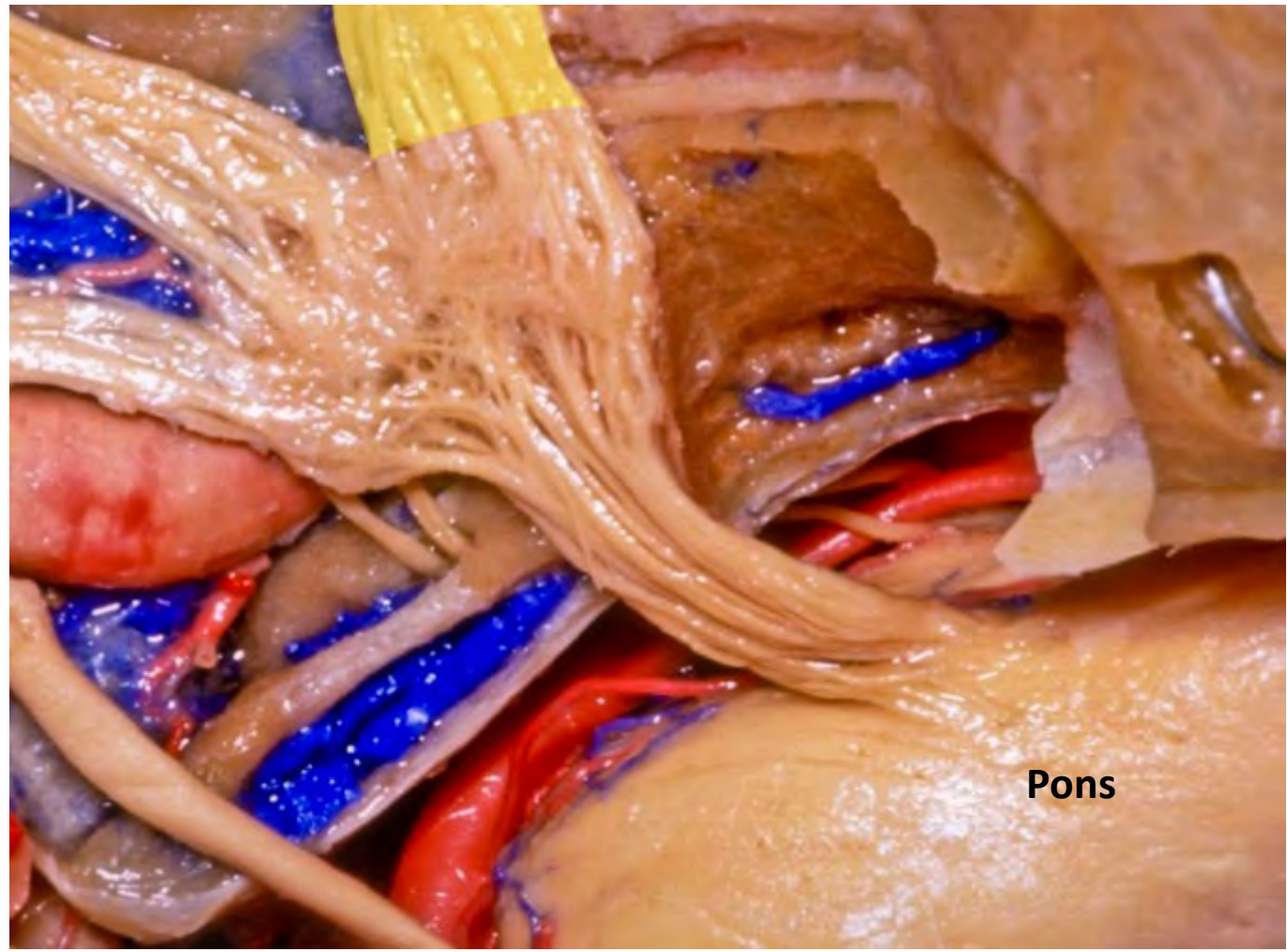

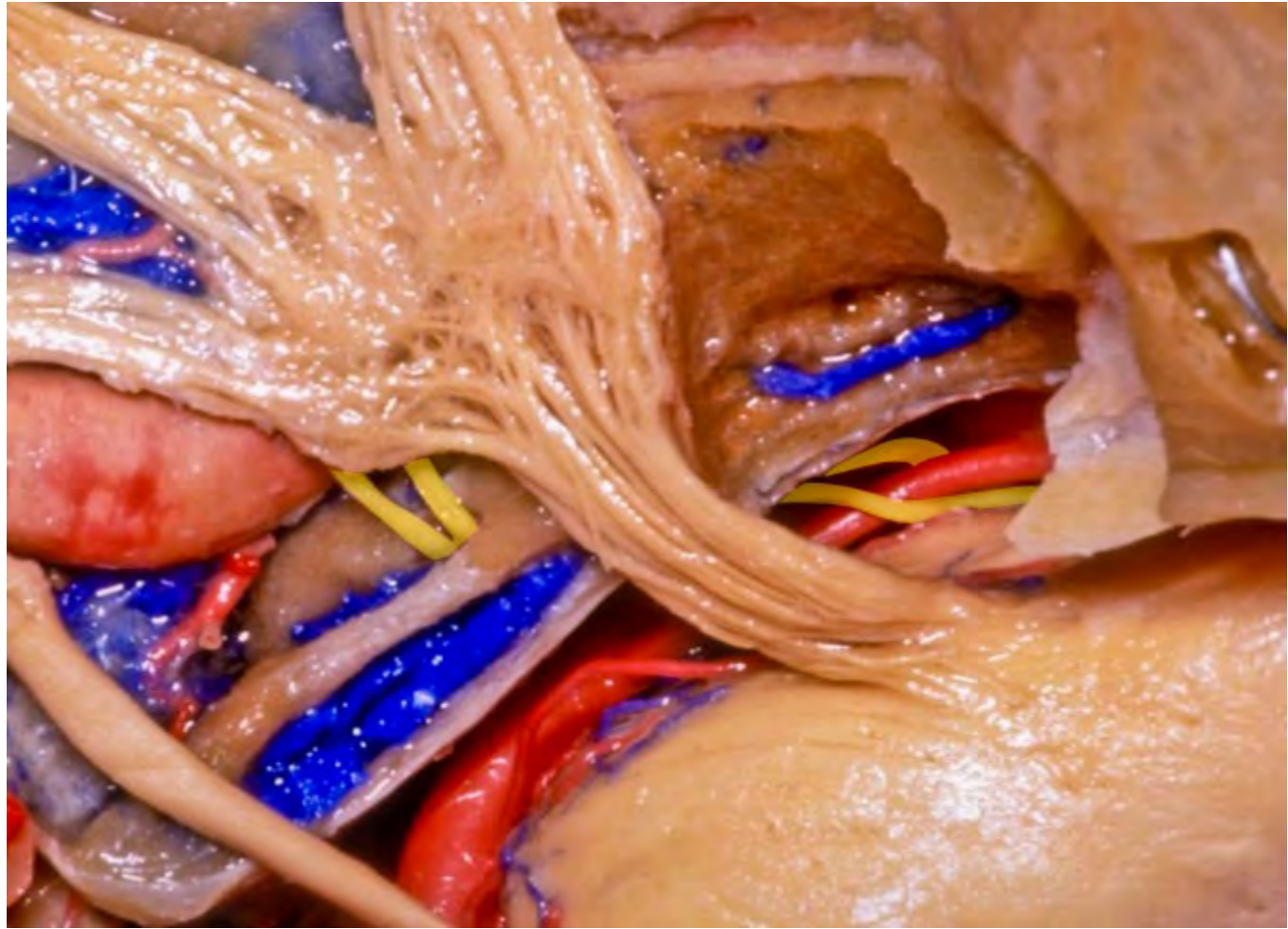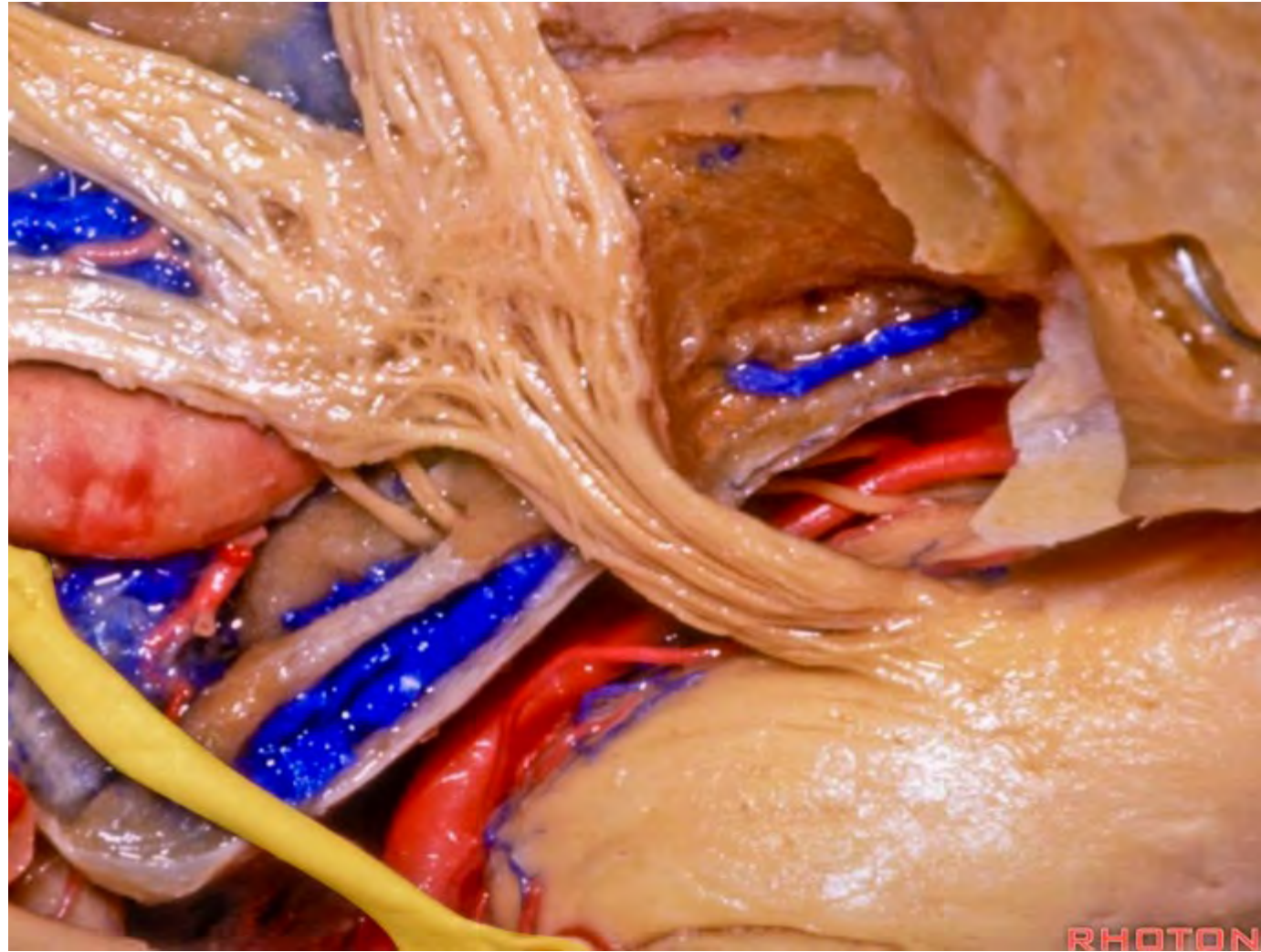


**Pons**

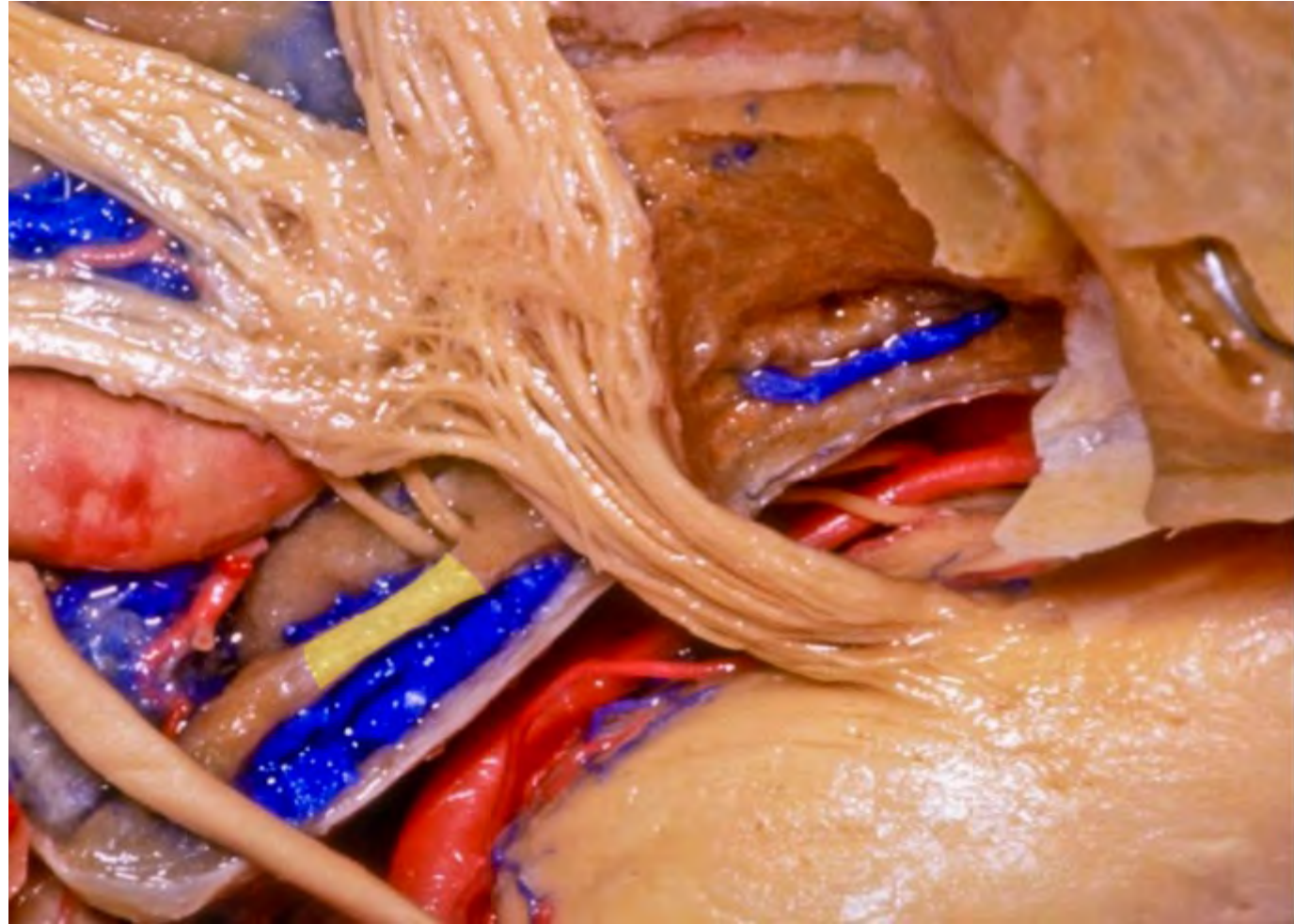

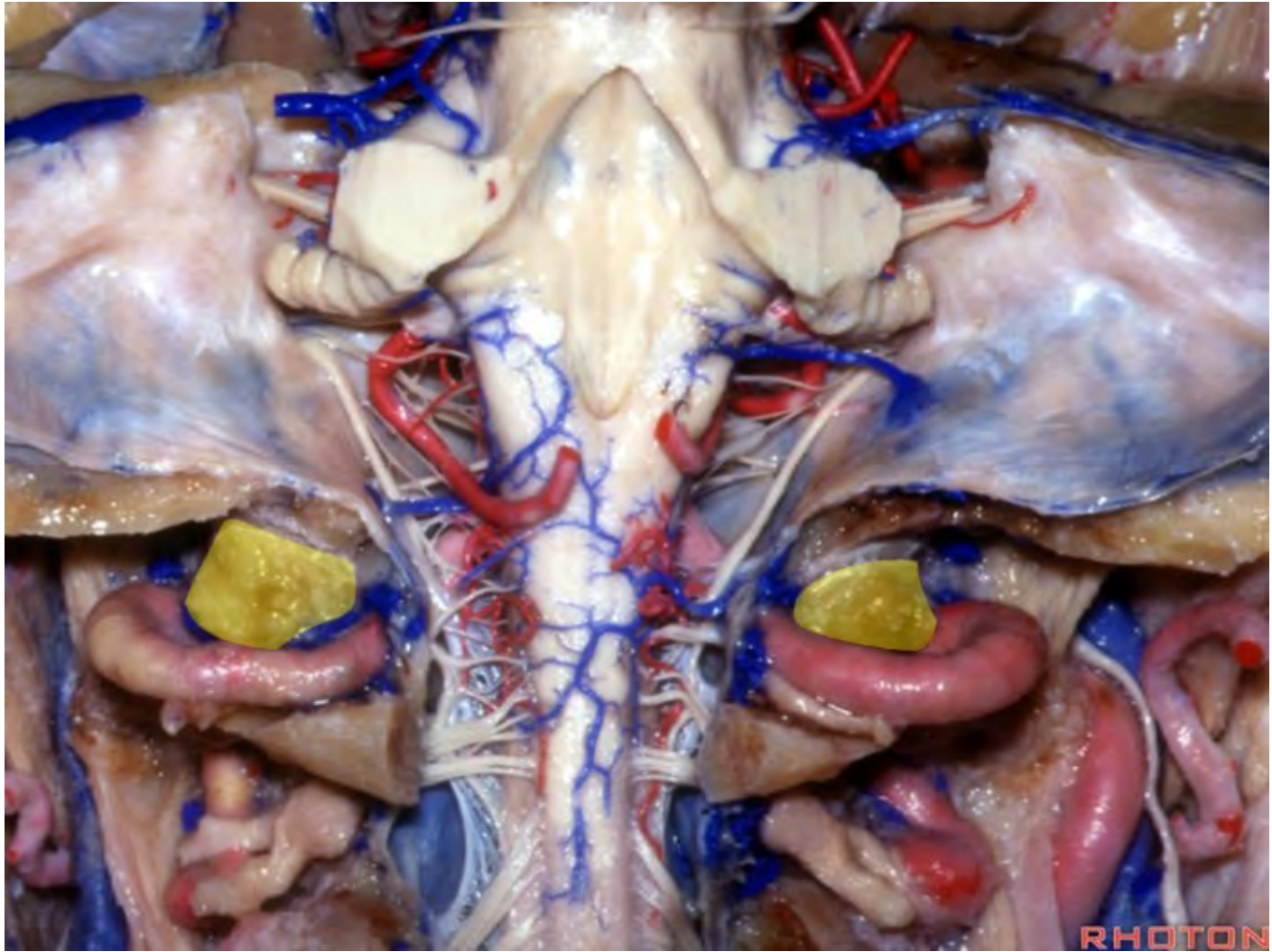


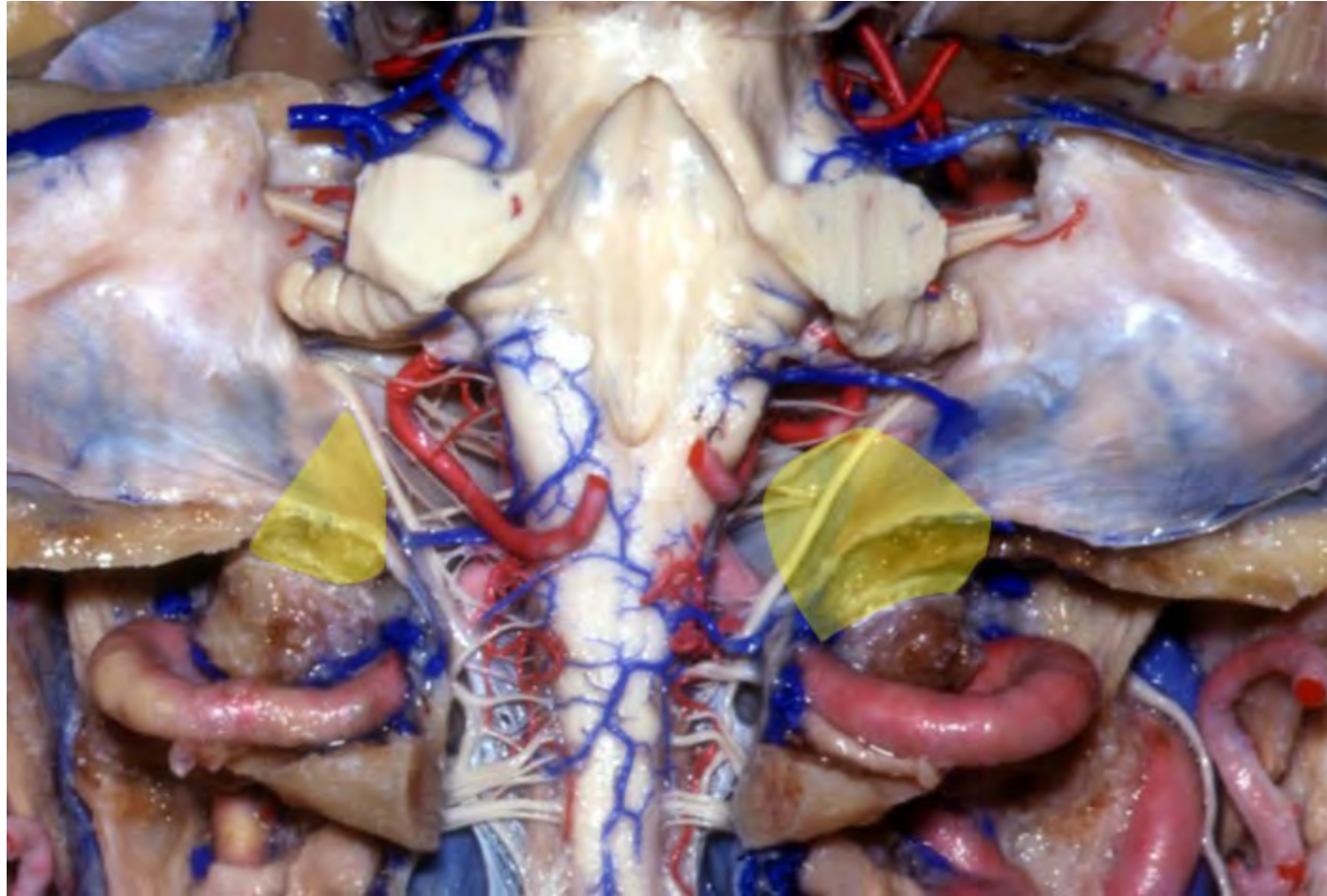


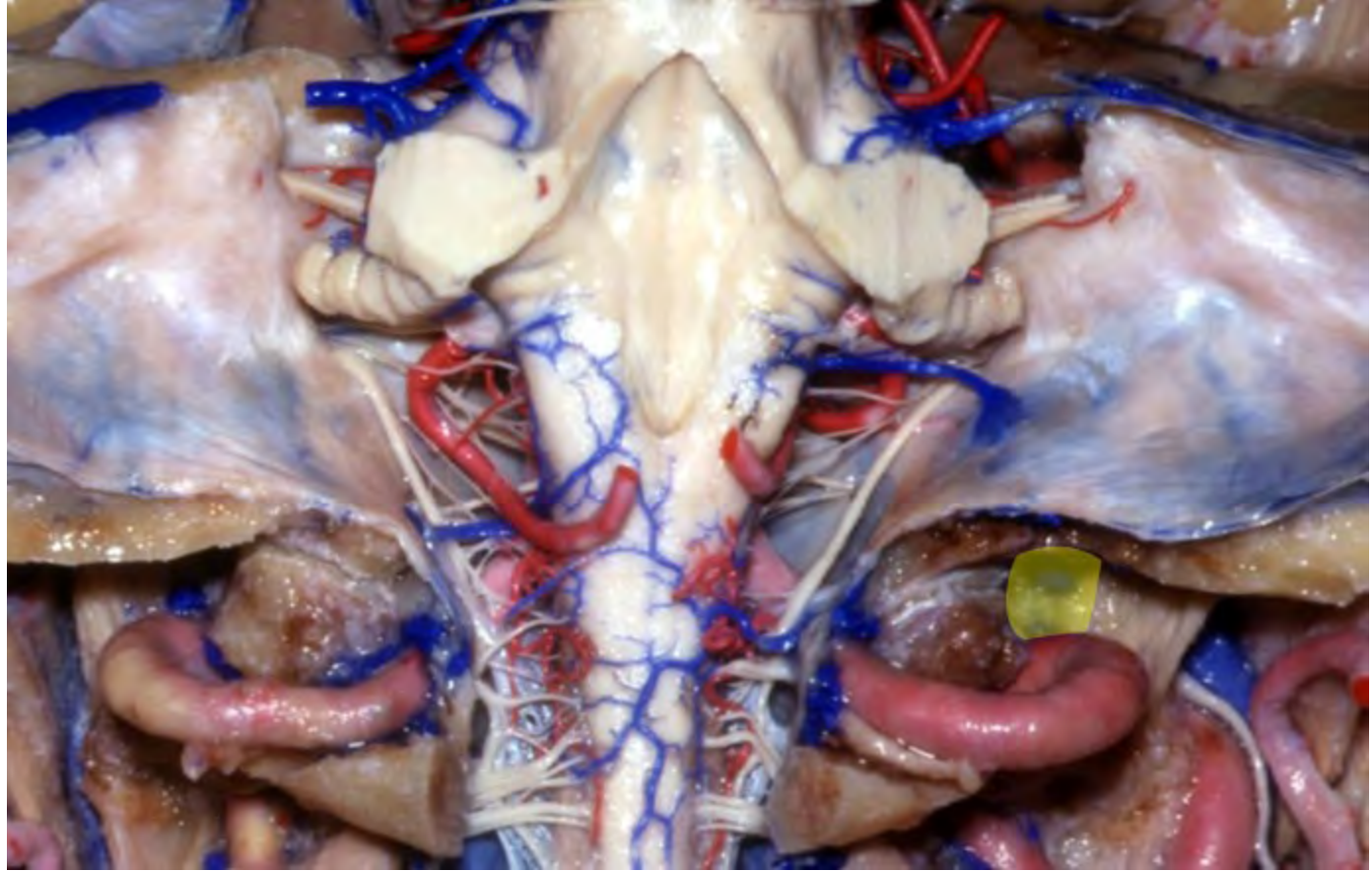




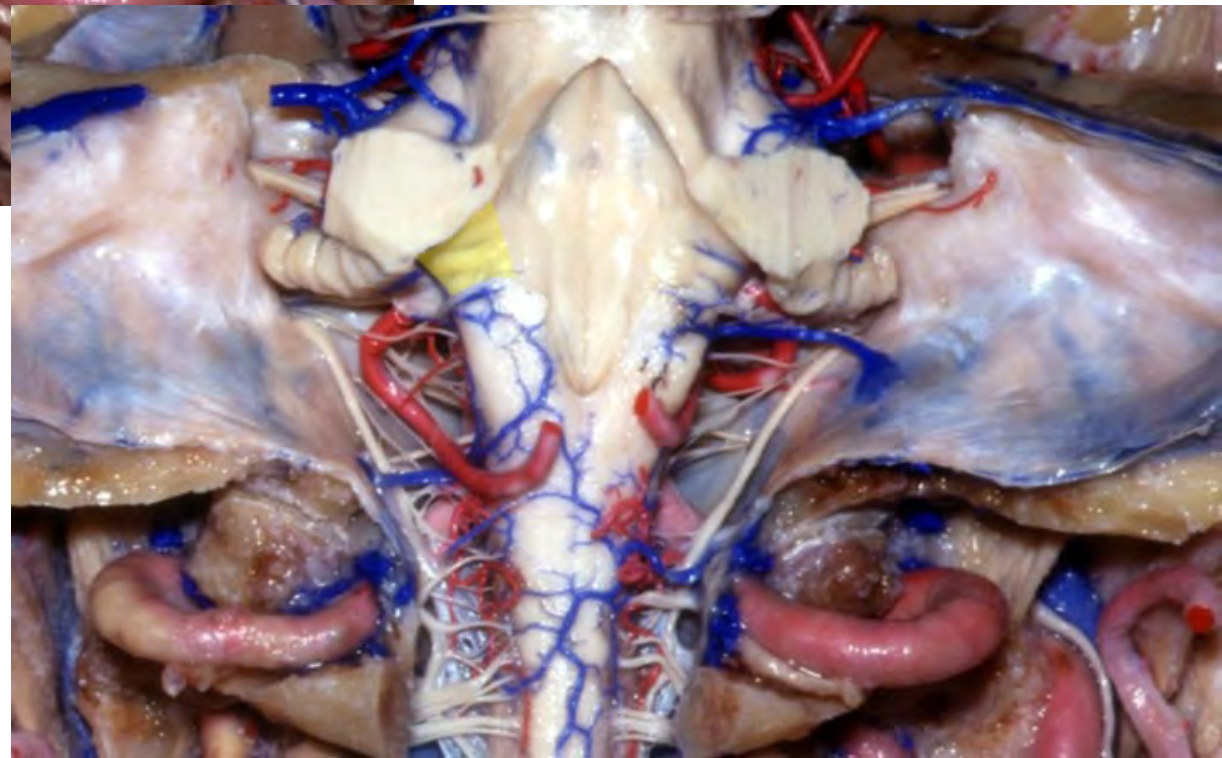
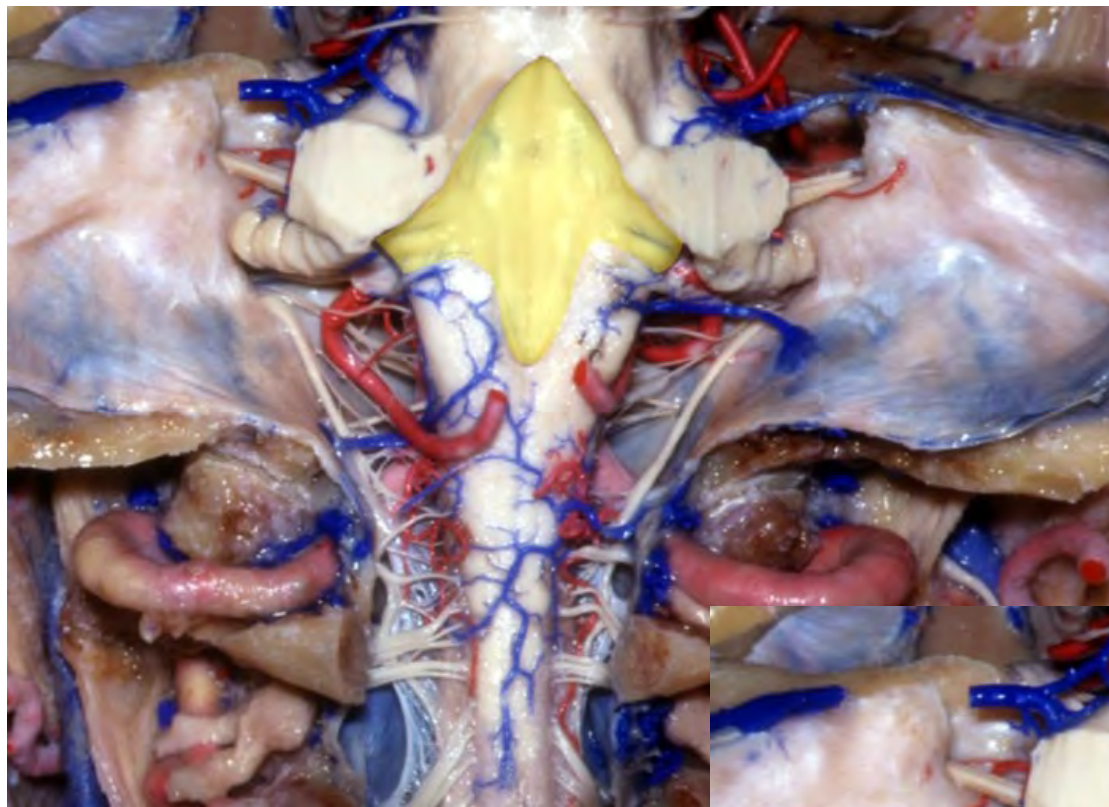


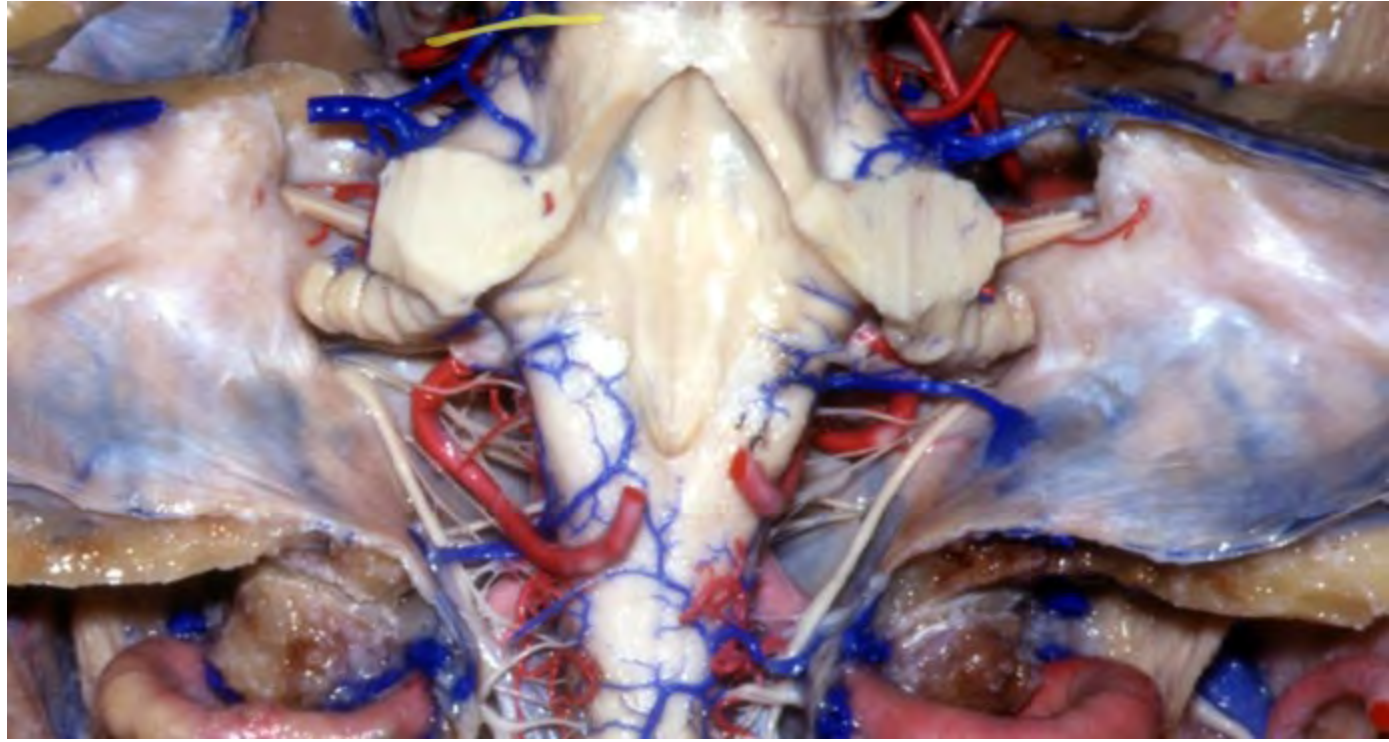


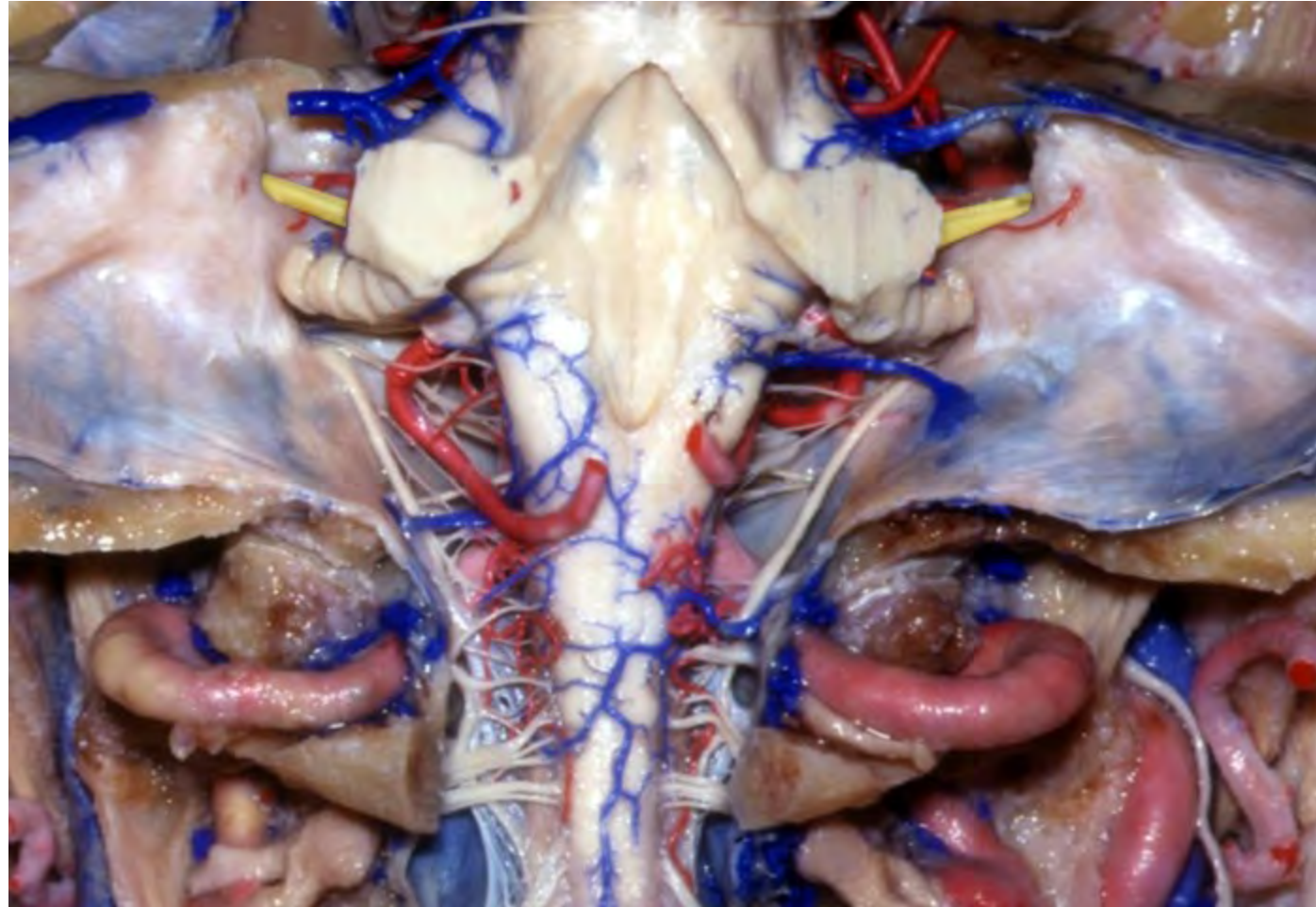


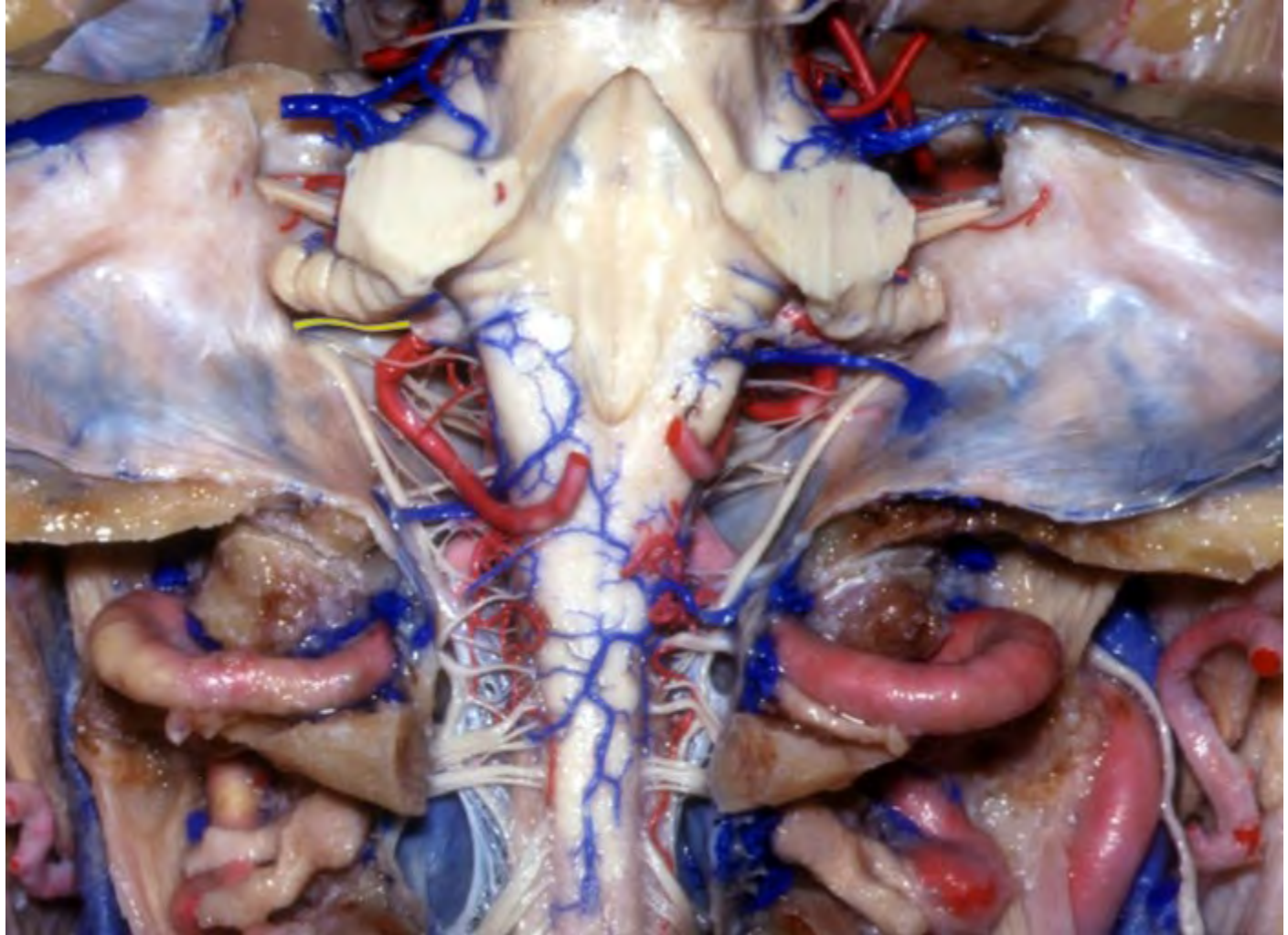



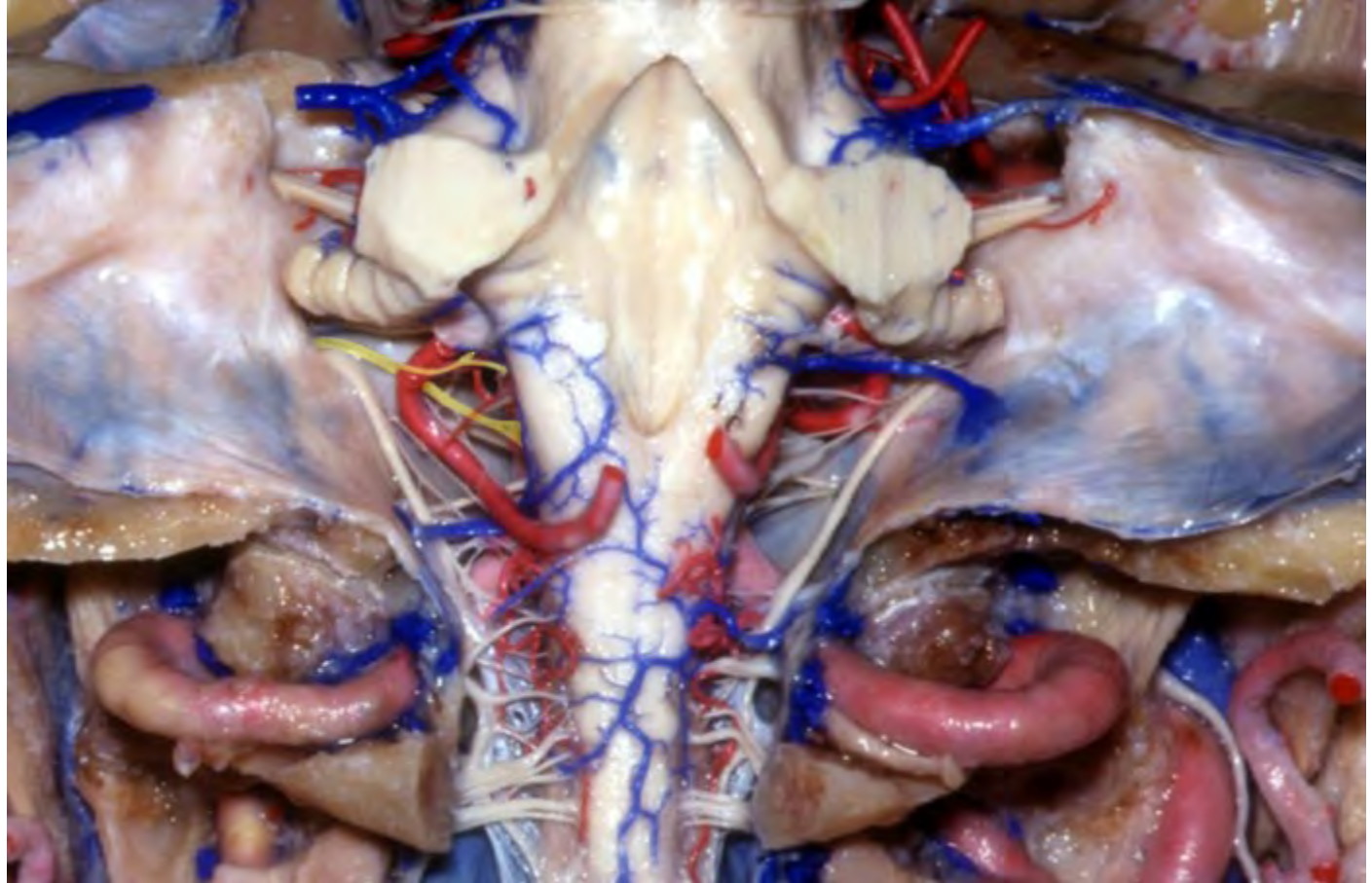
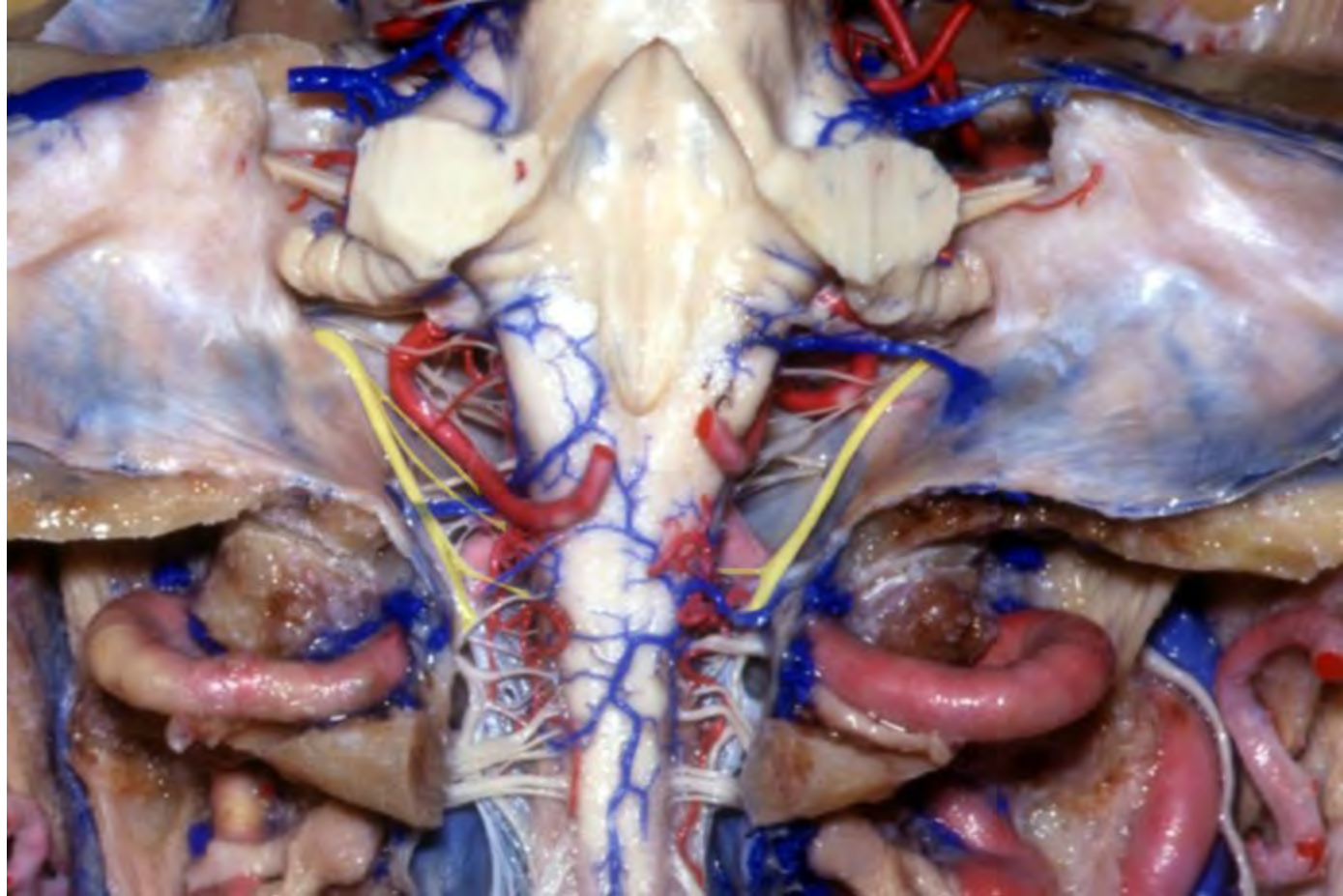


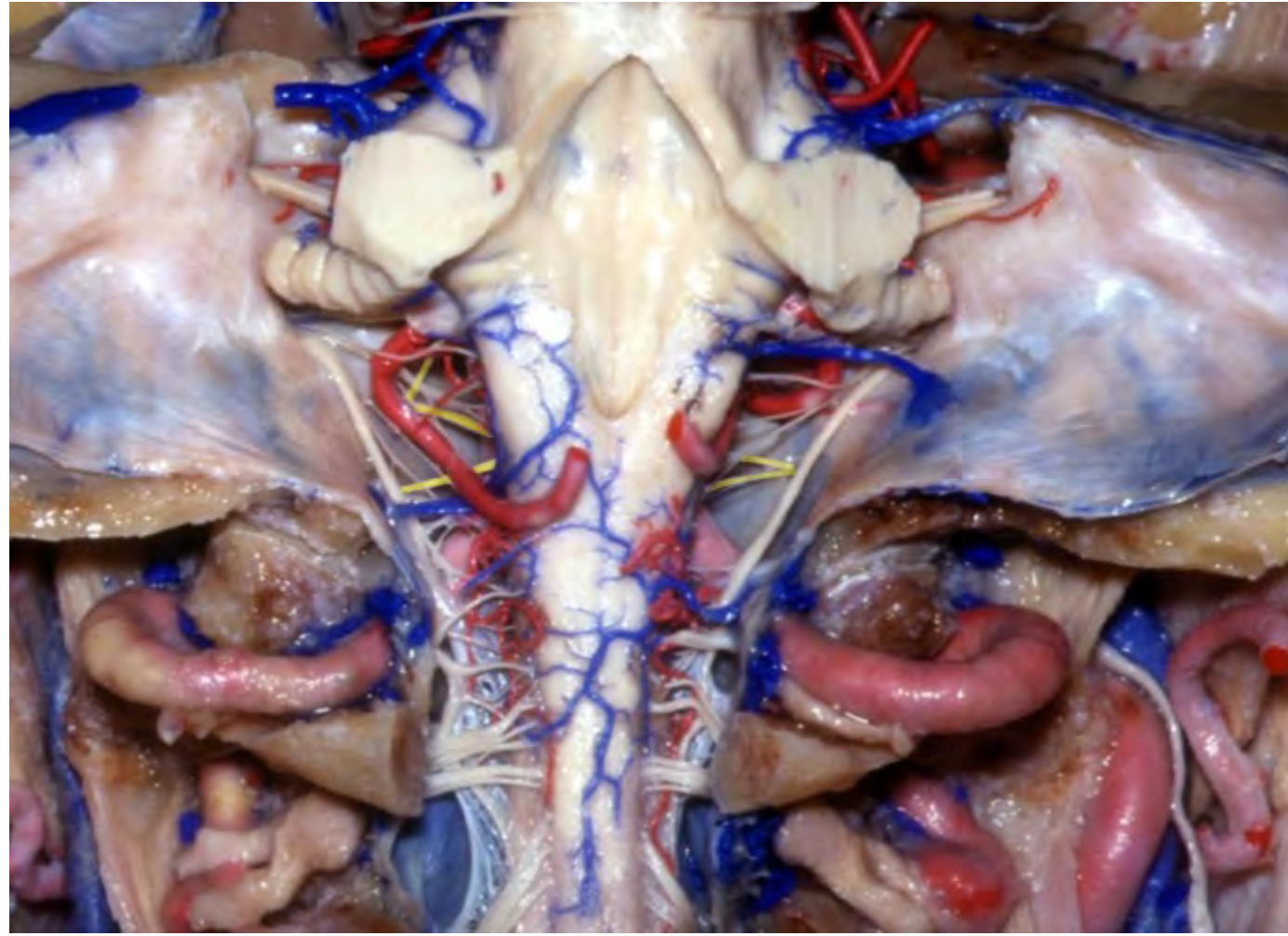






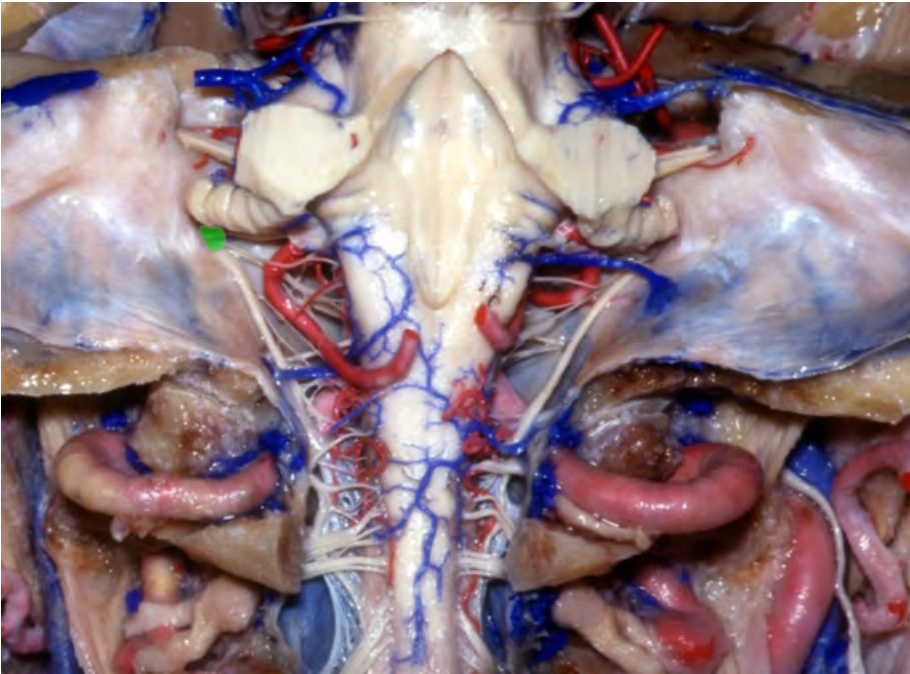




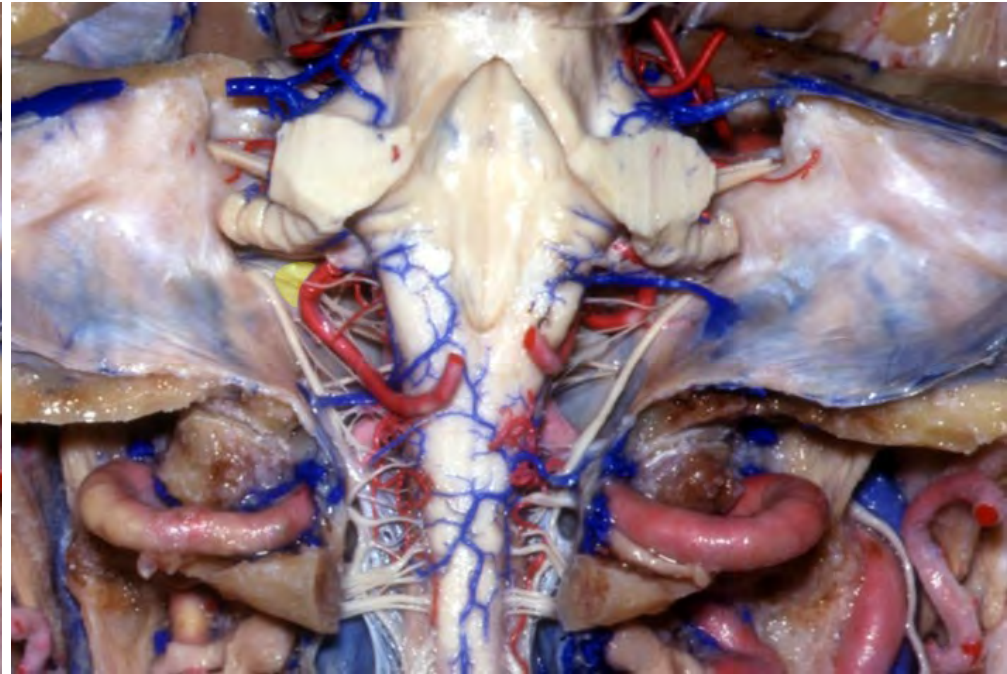




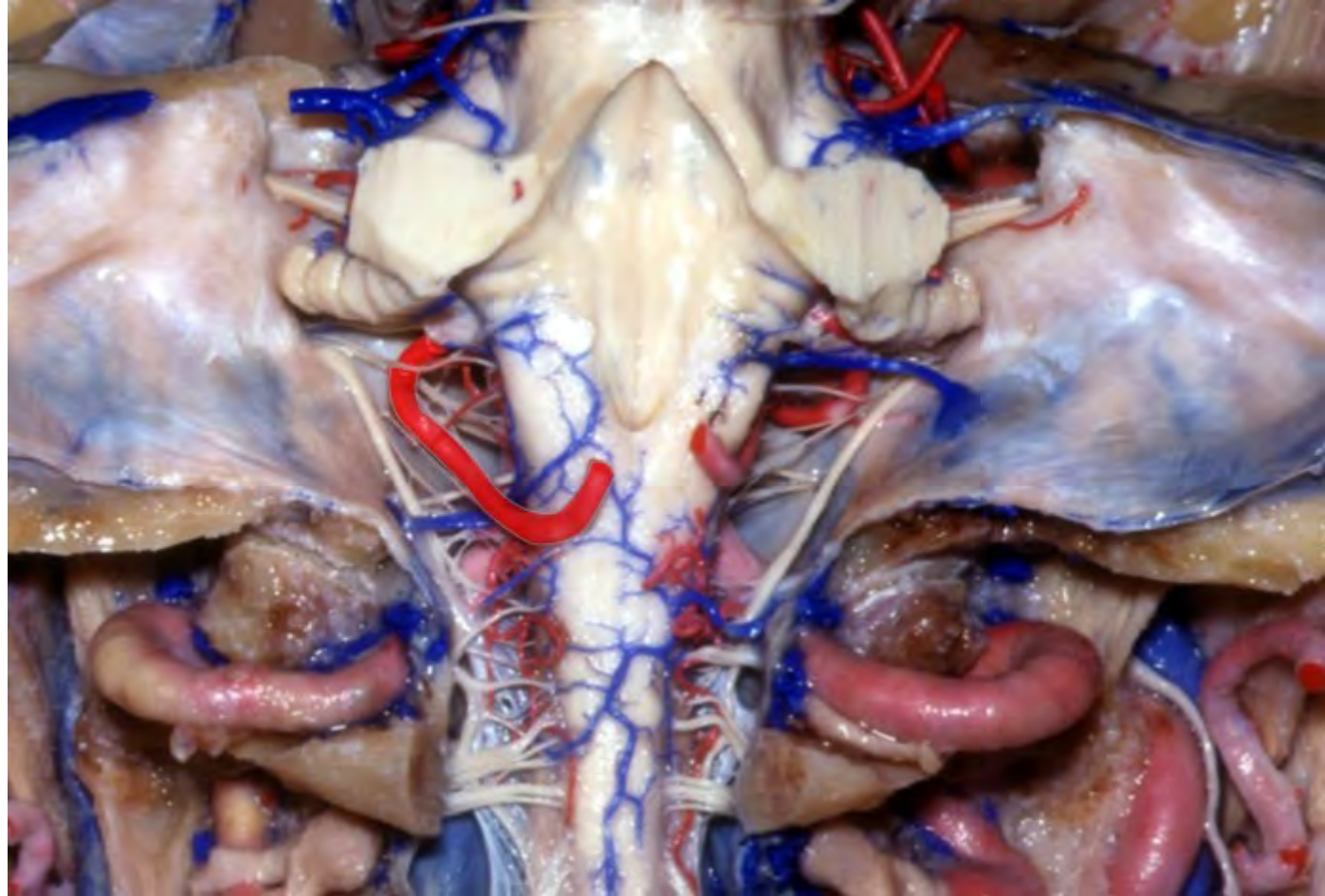
**Jugular foramen**

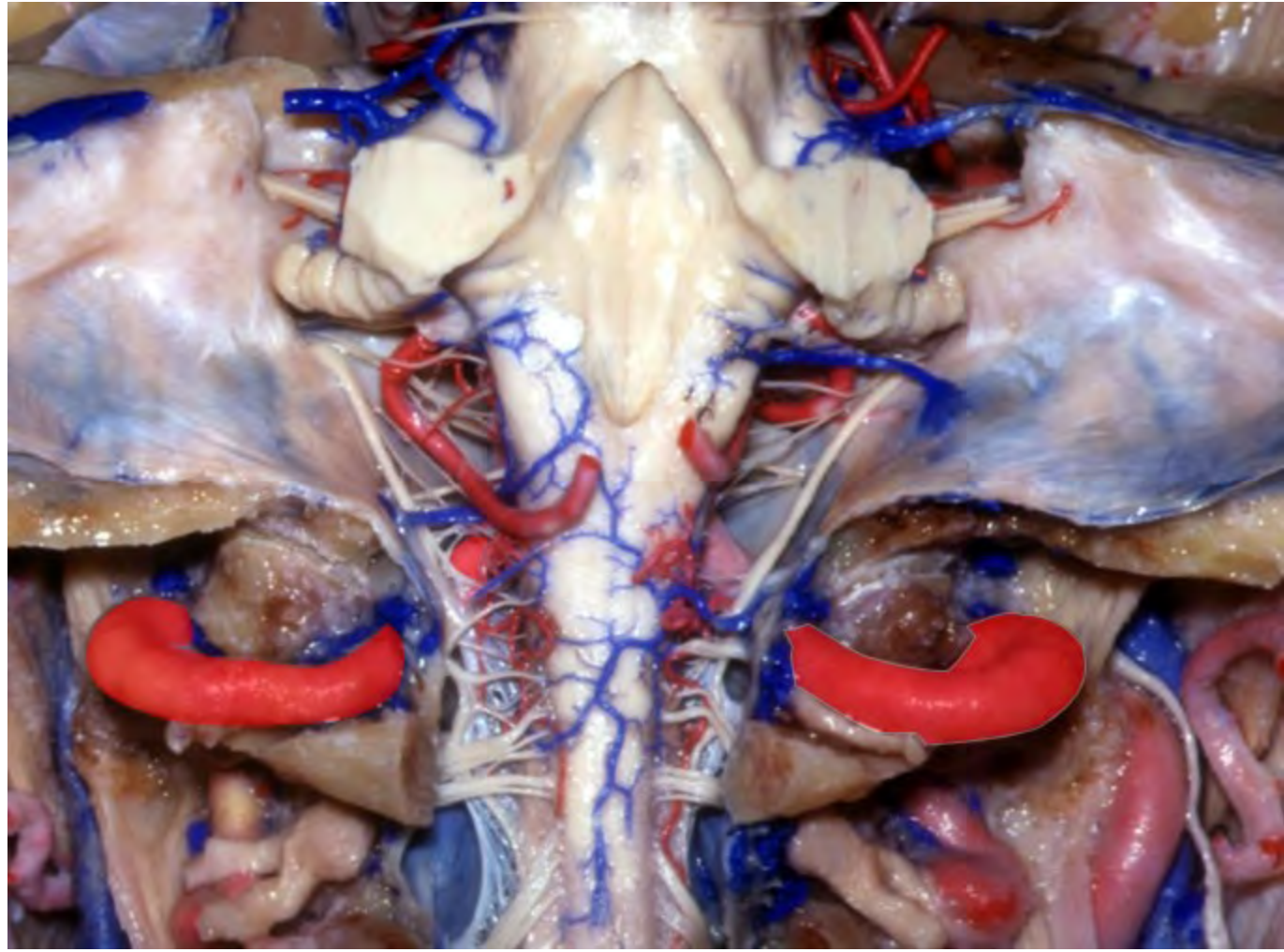


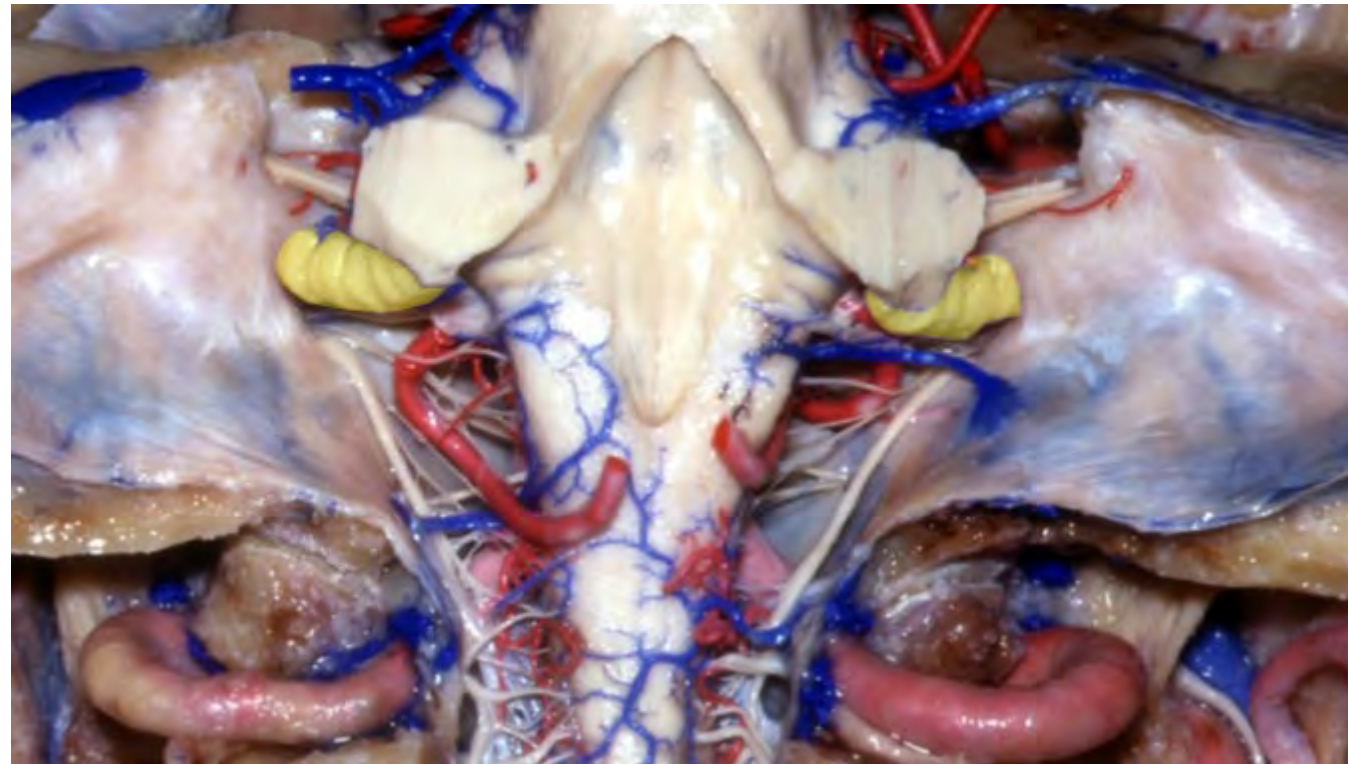**Jugular tubercle**

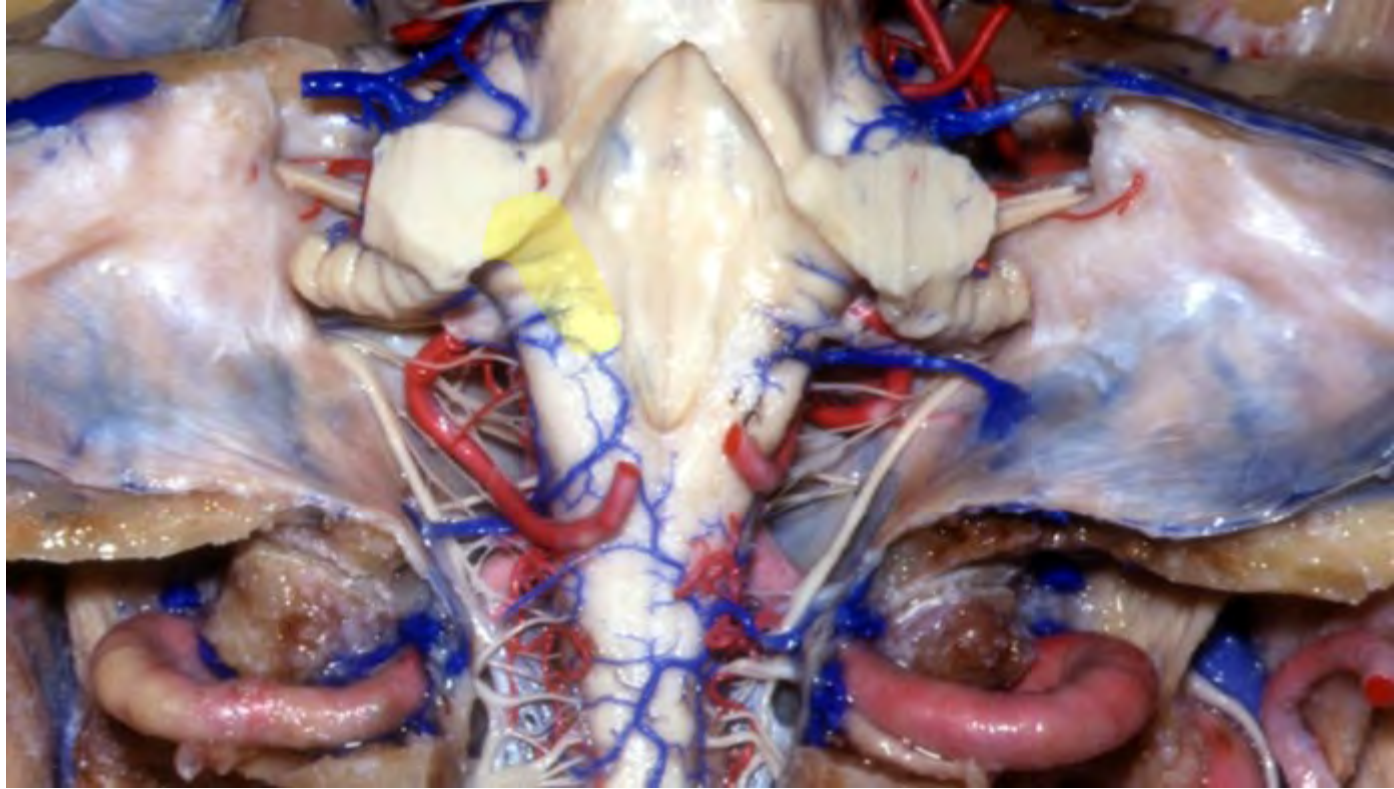


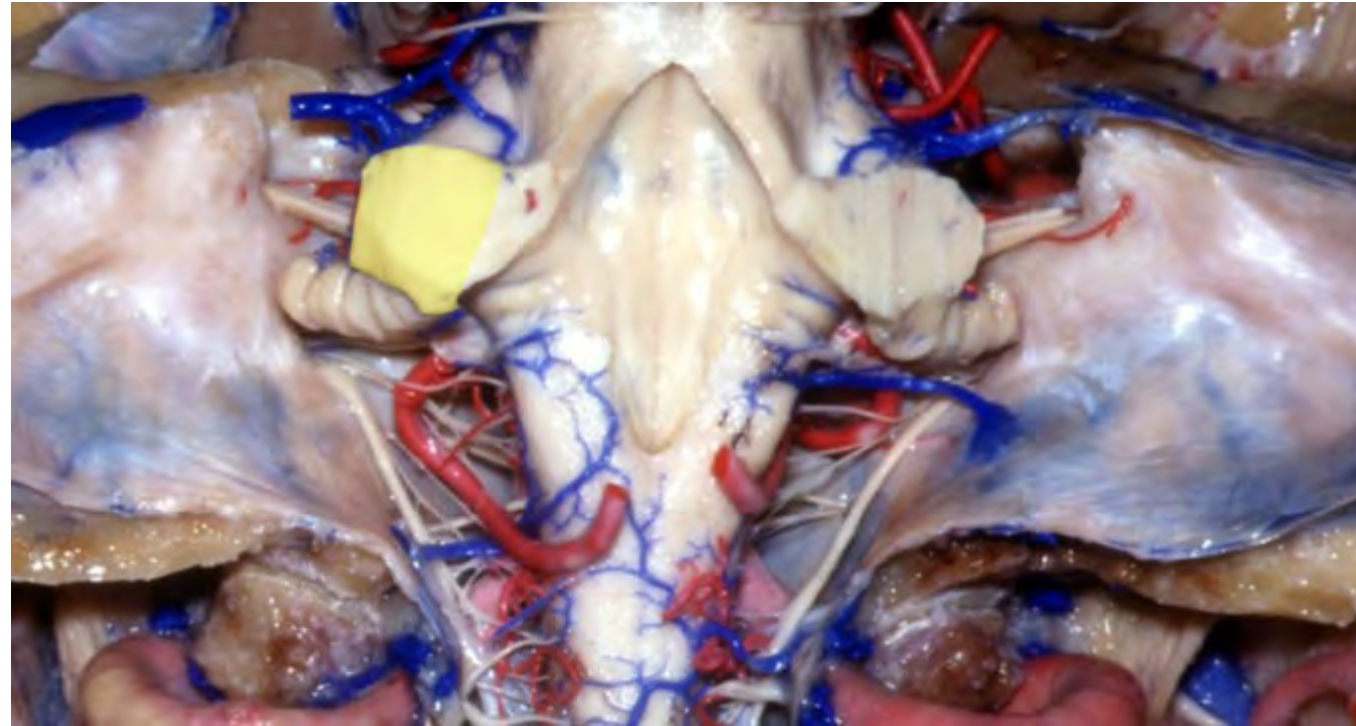


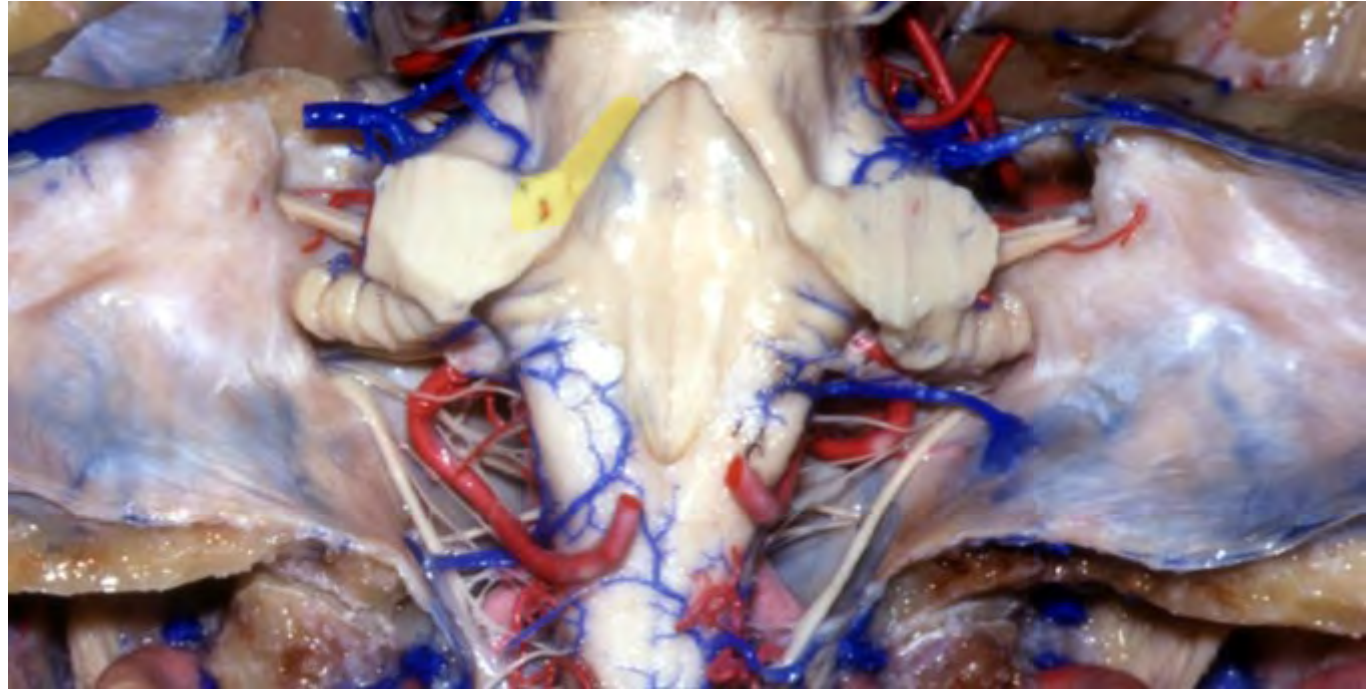


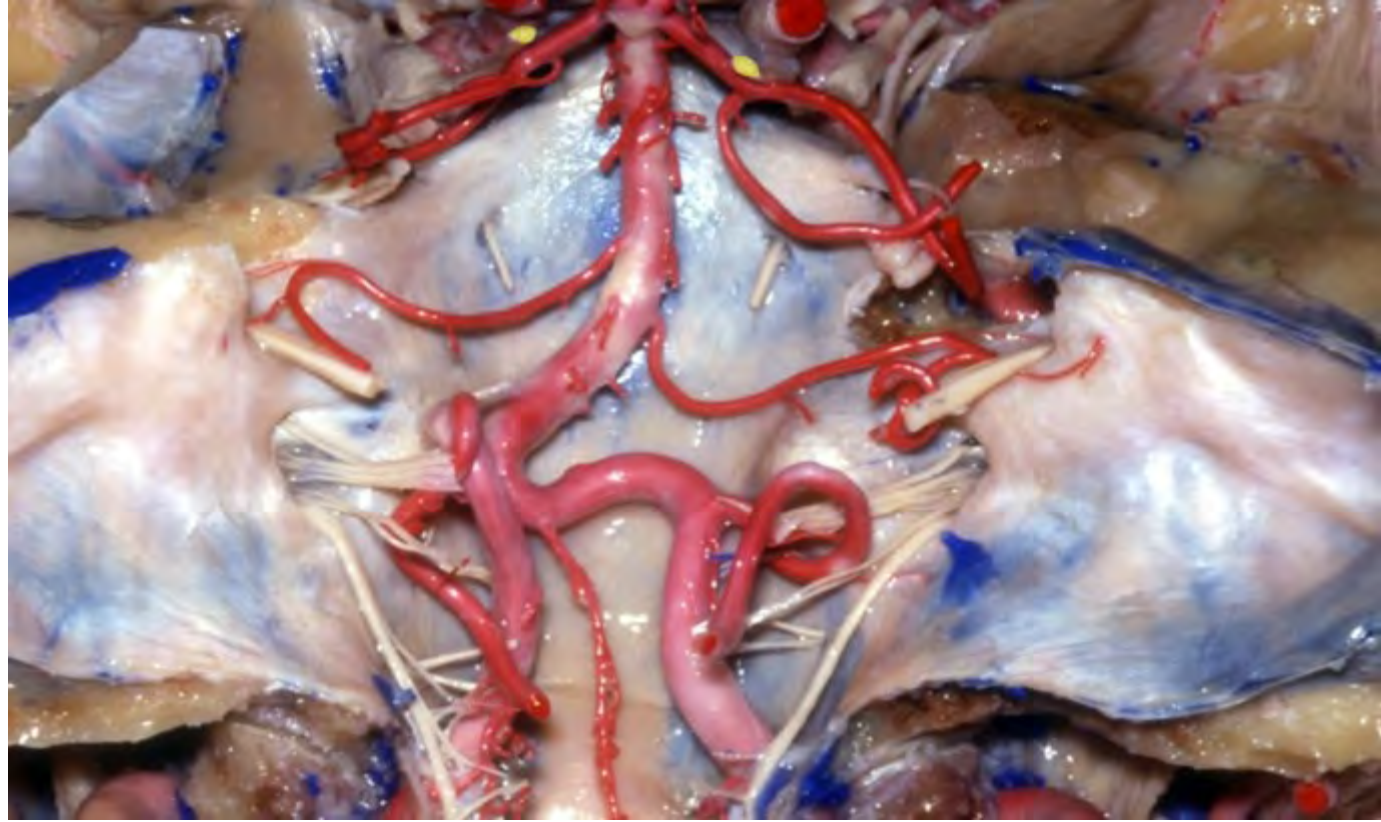


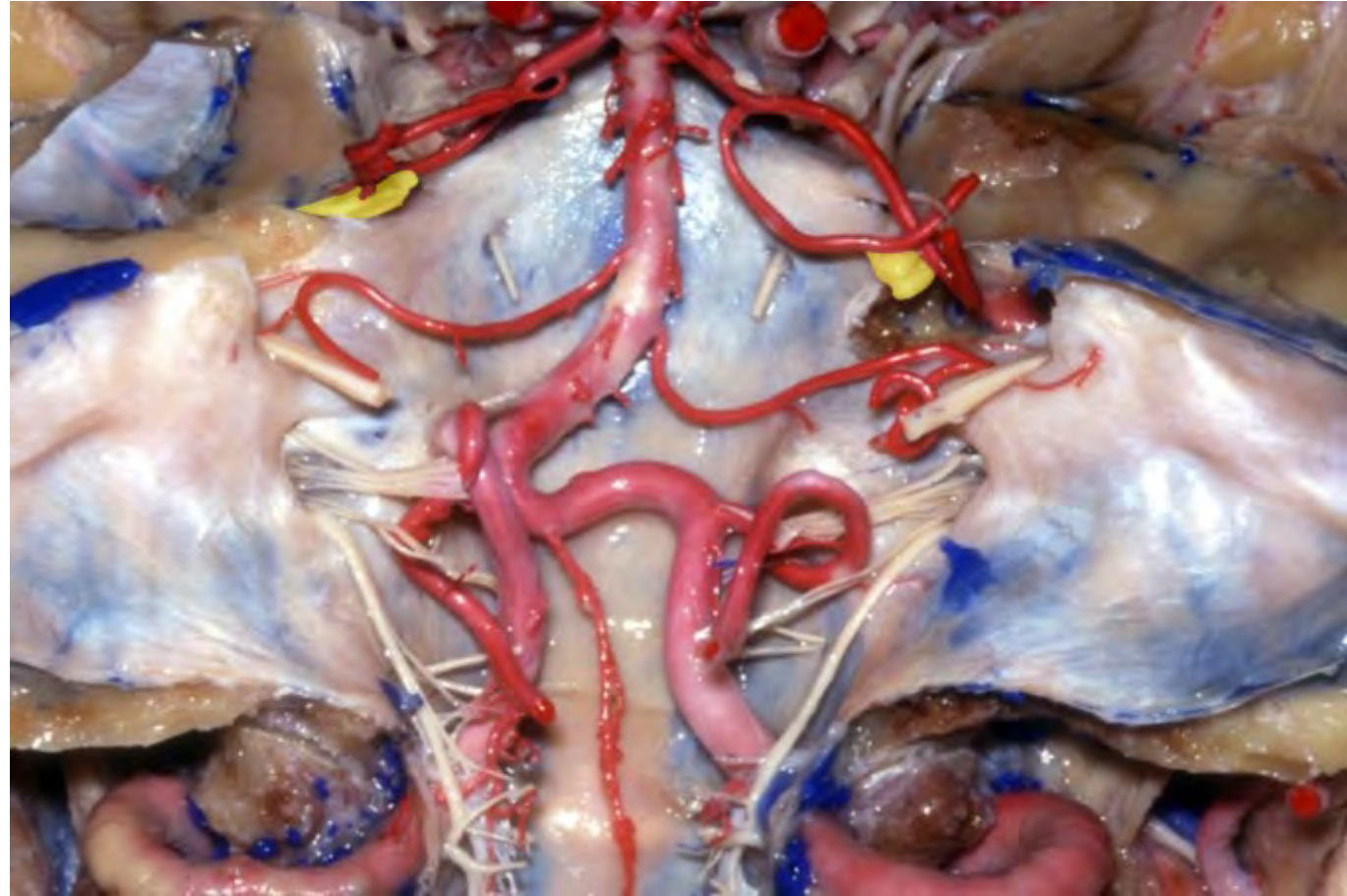




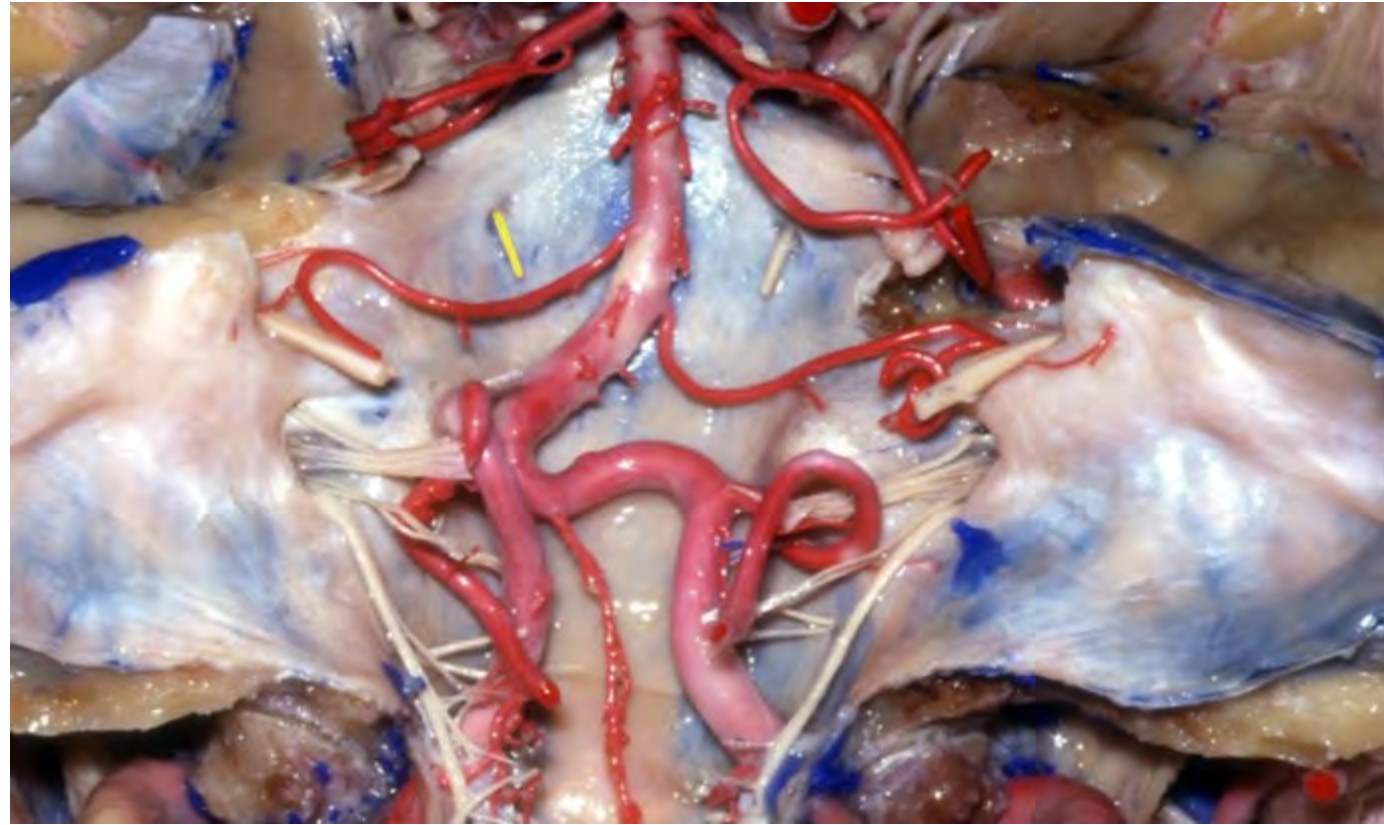


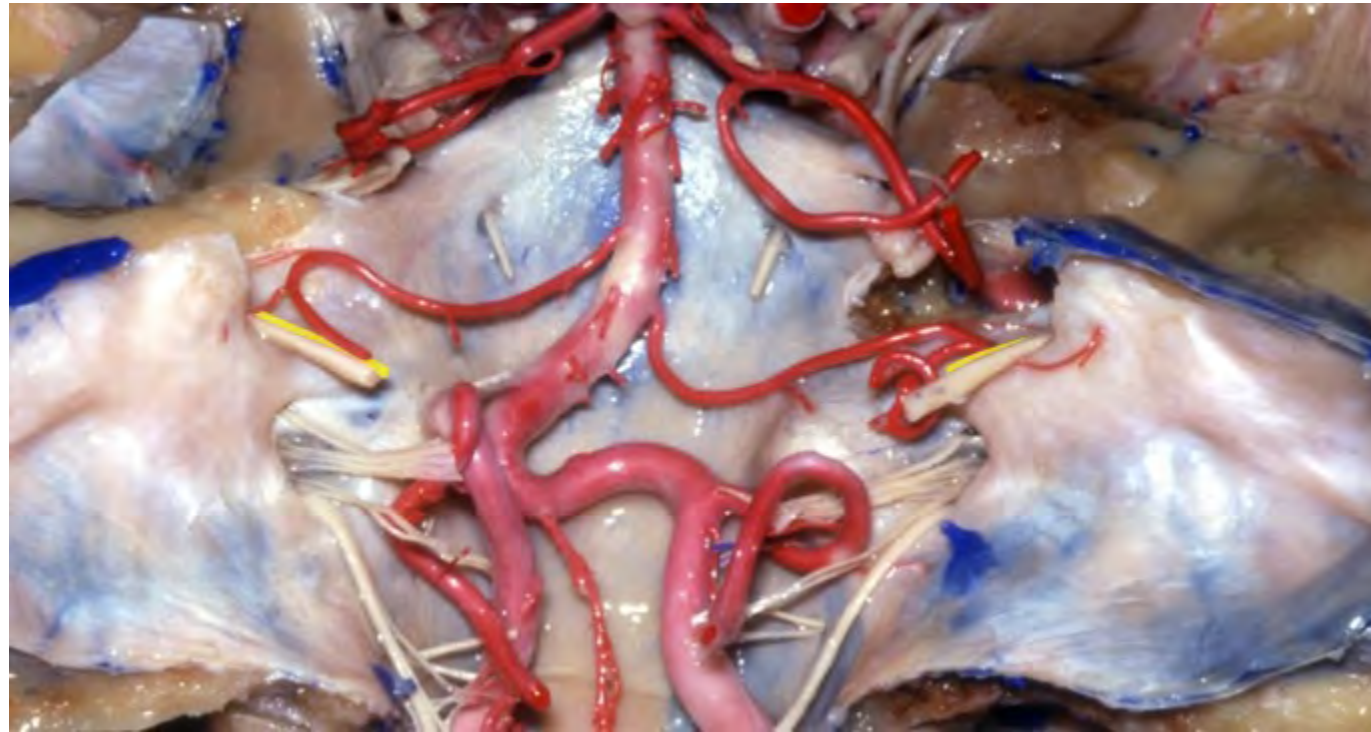


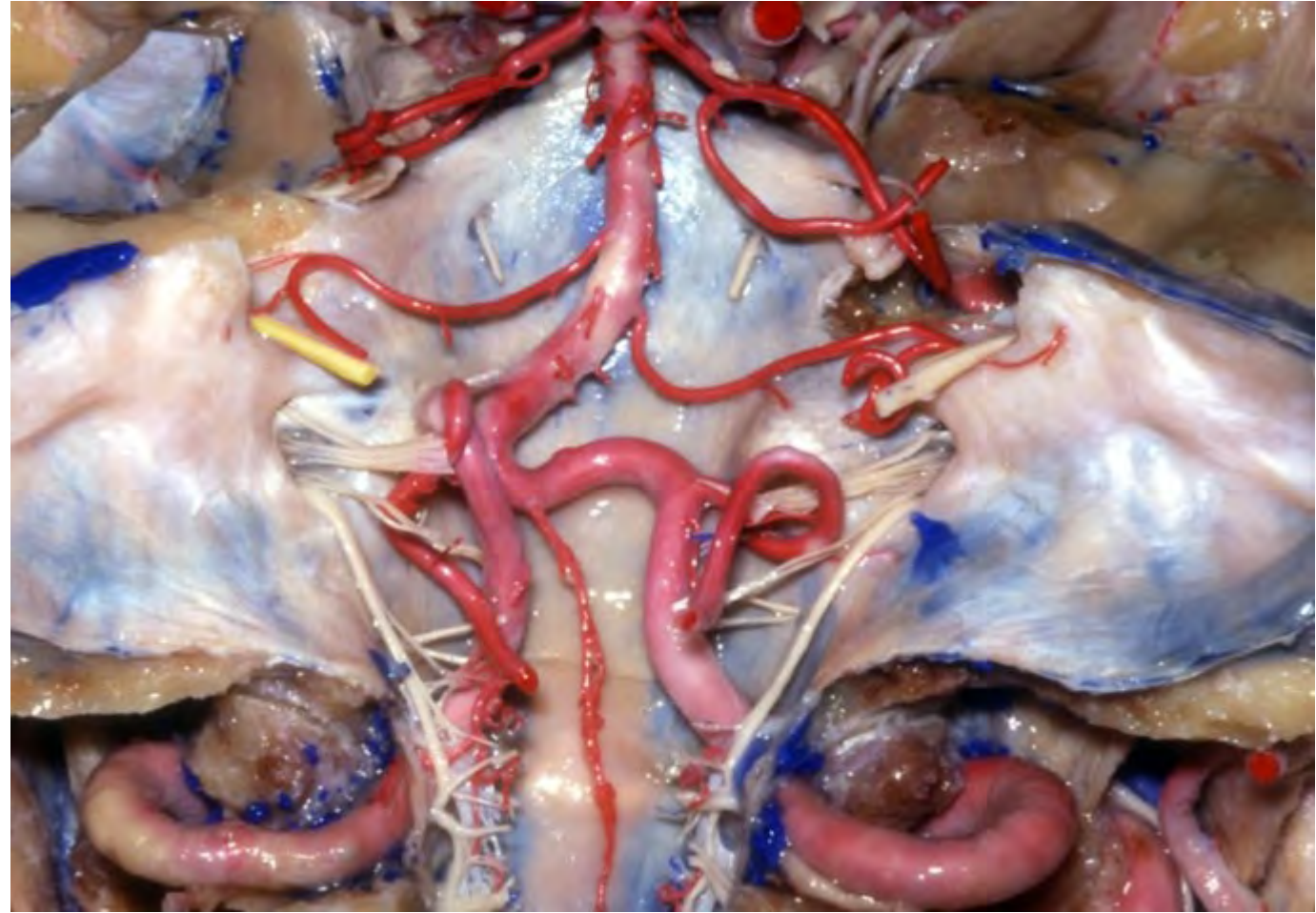


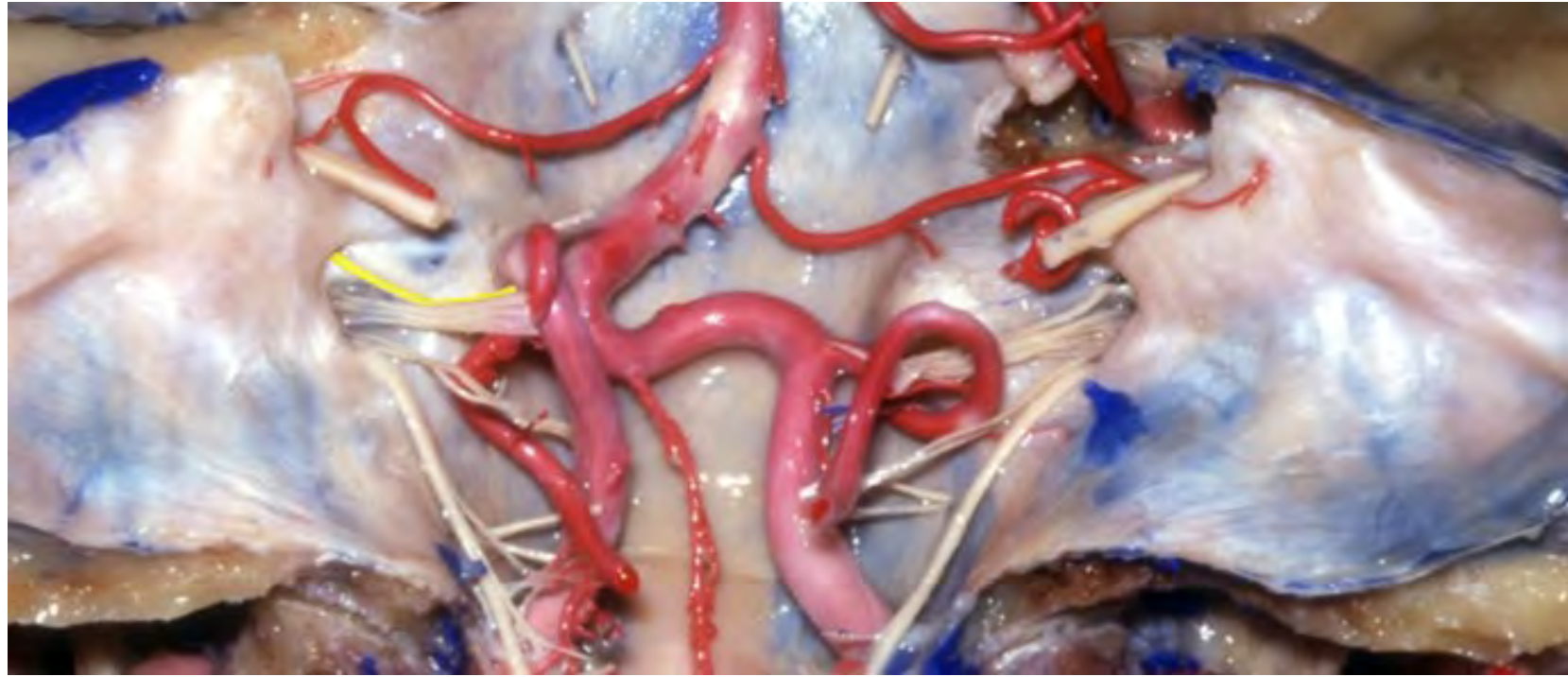


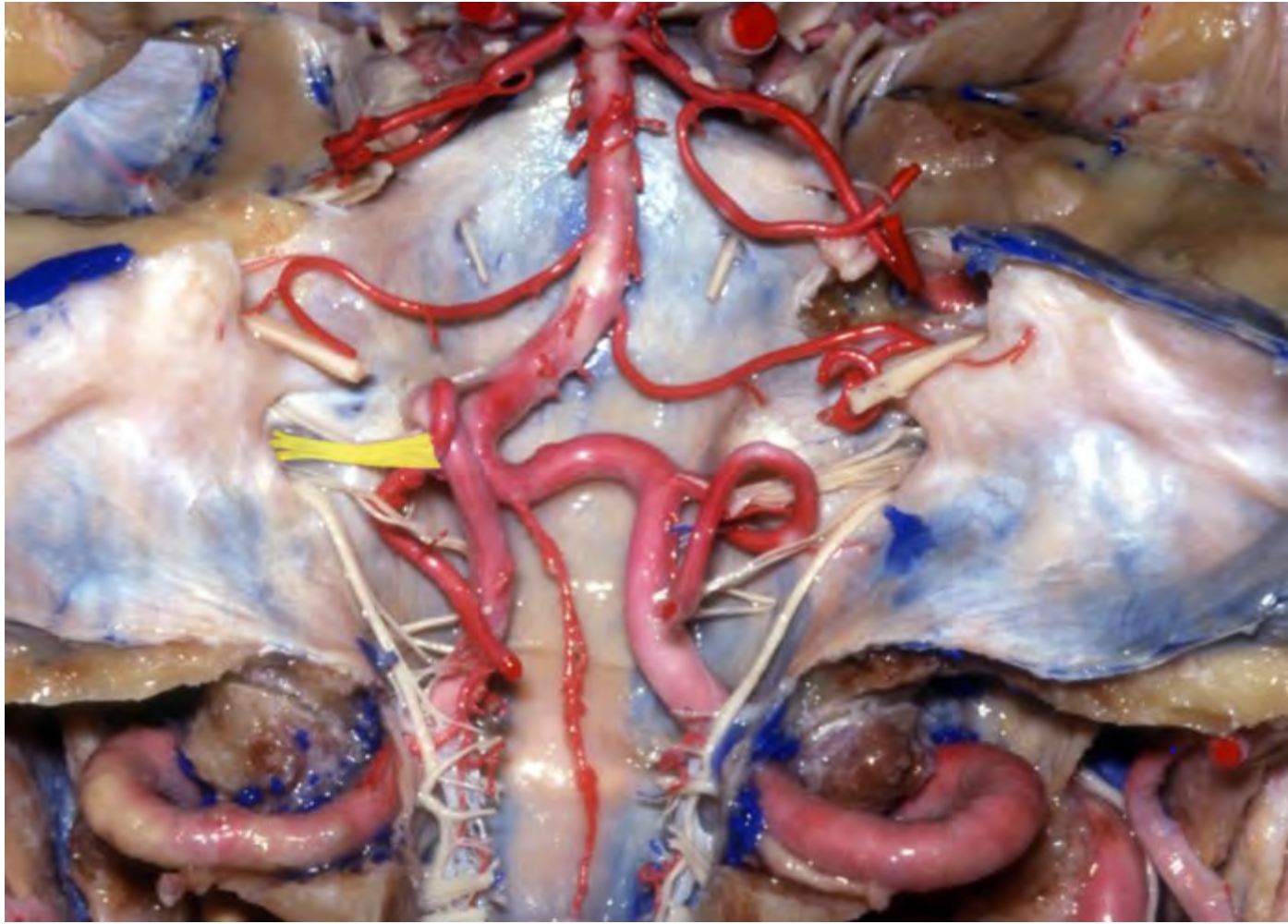


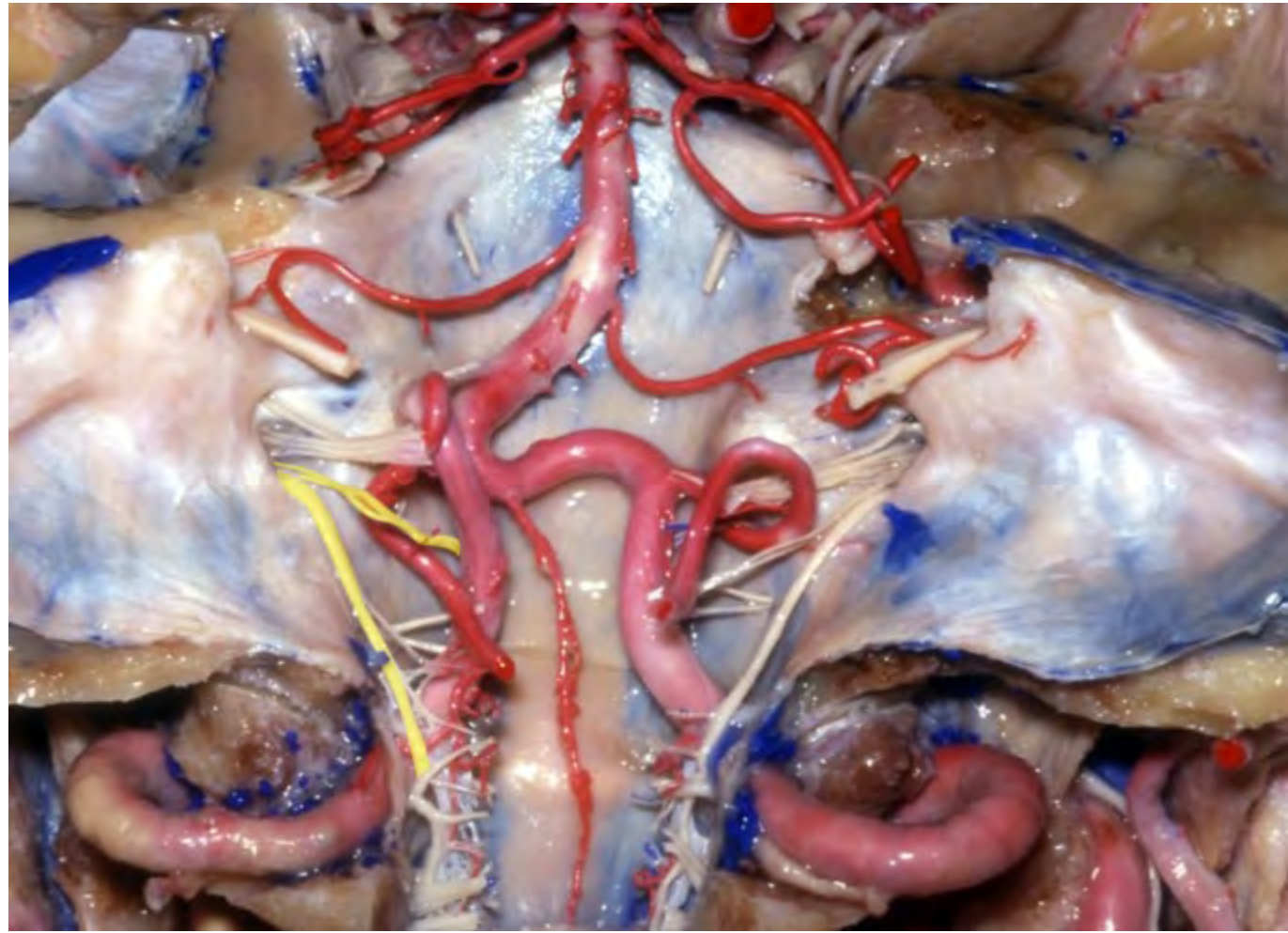


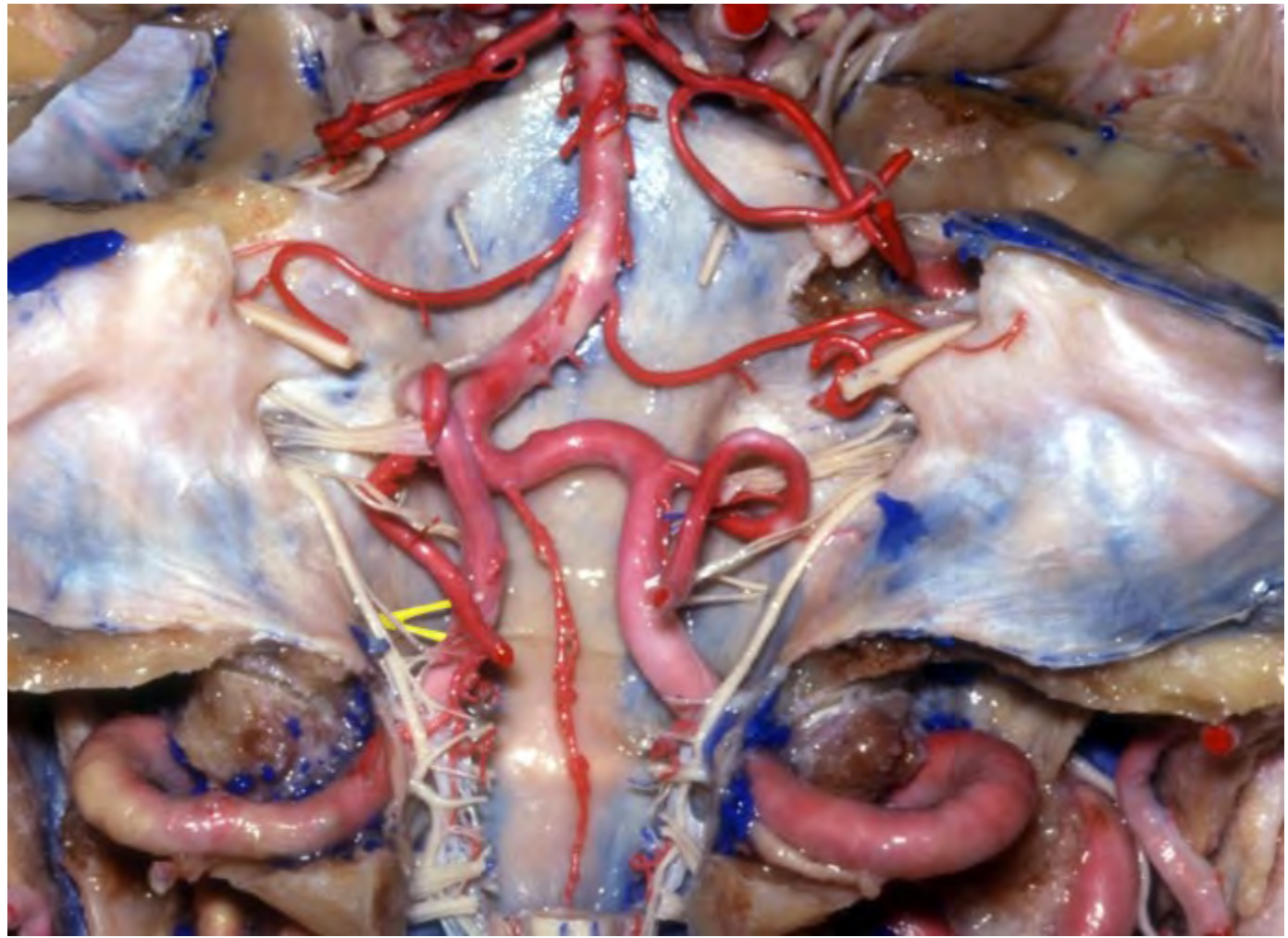


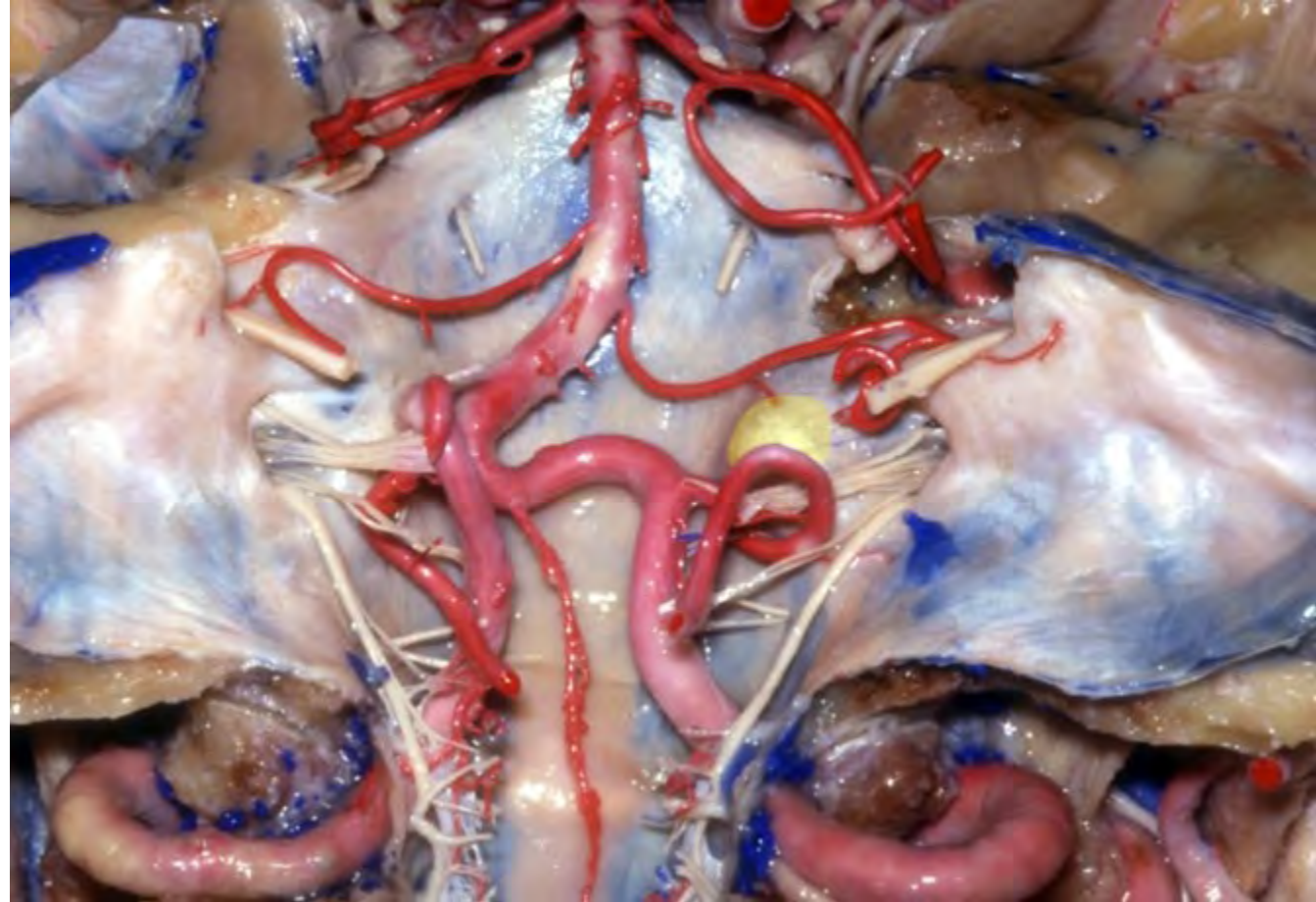



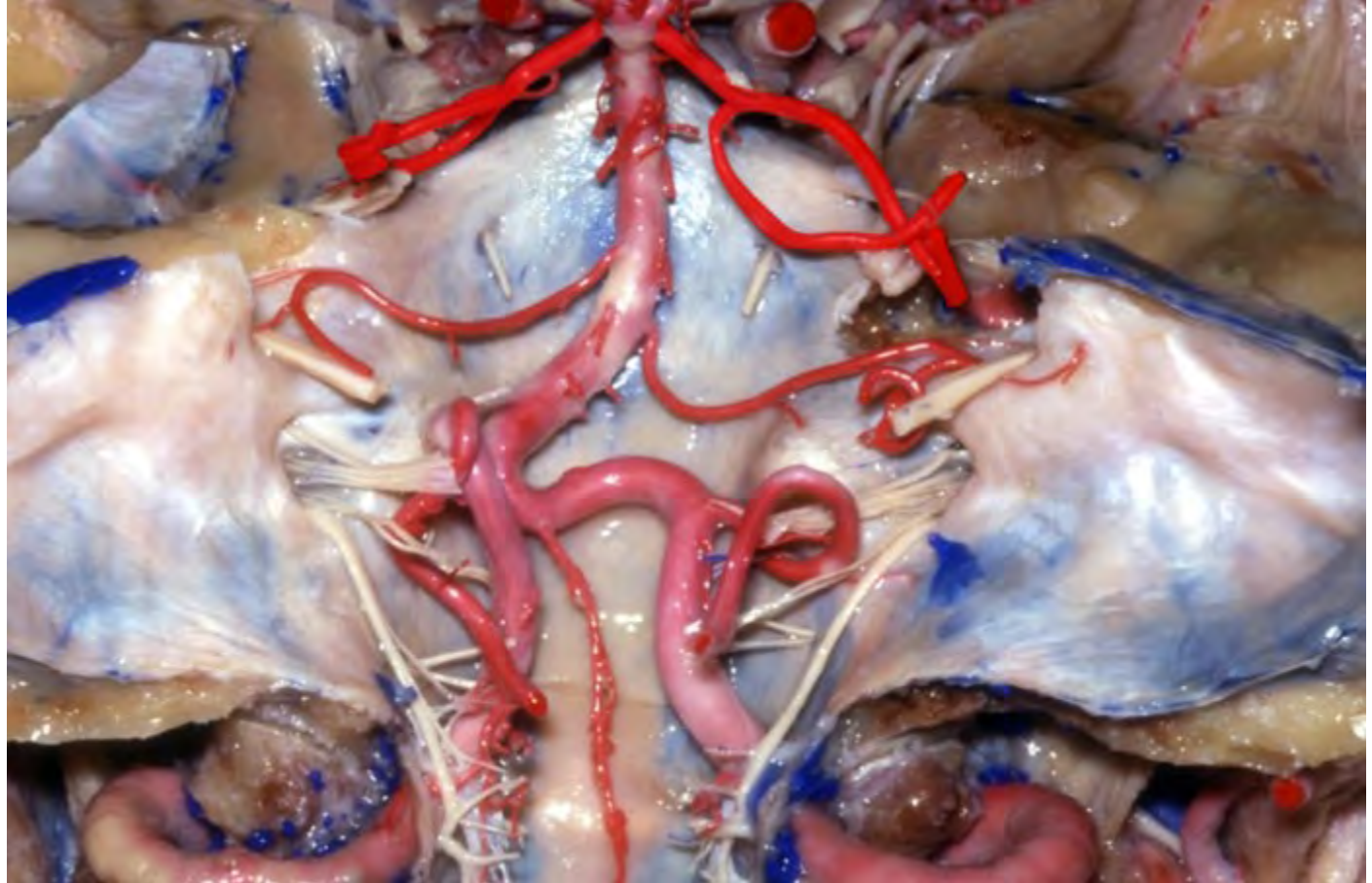


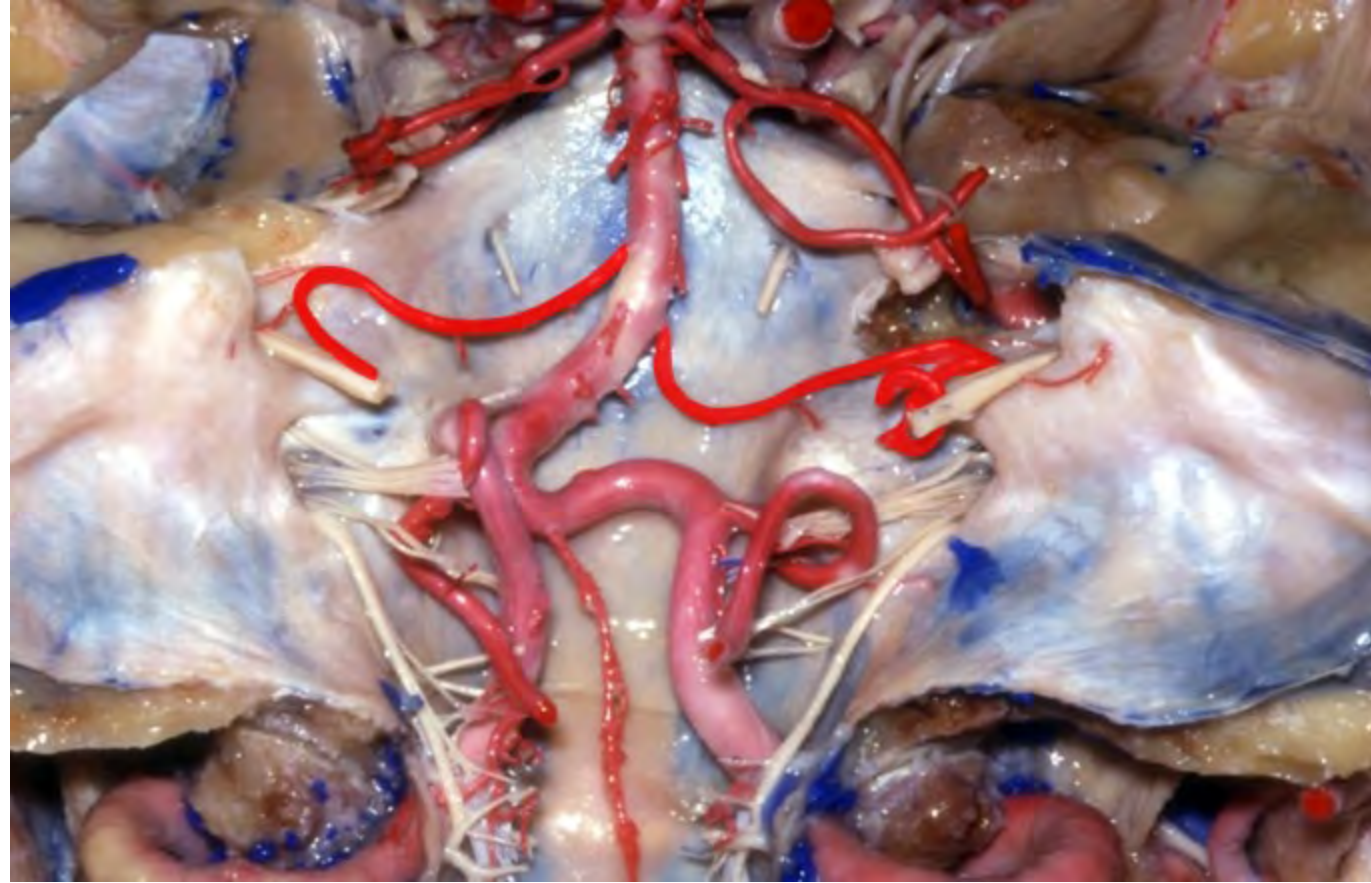


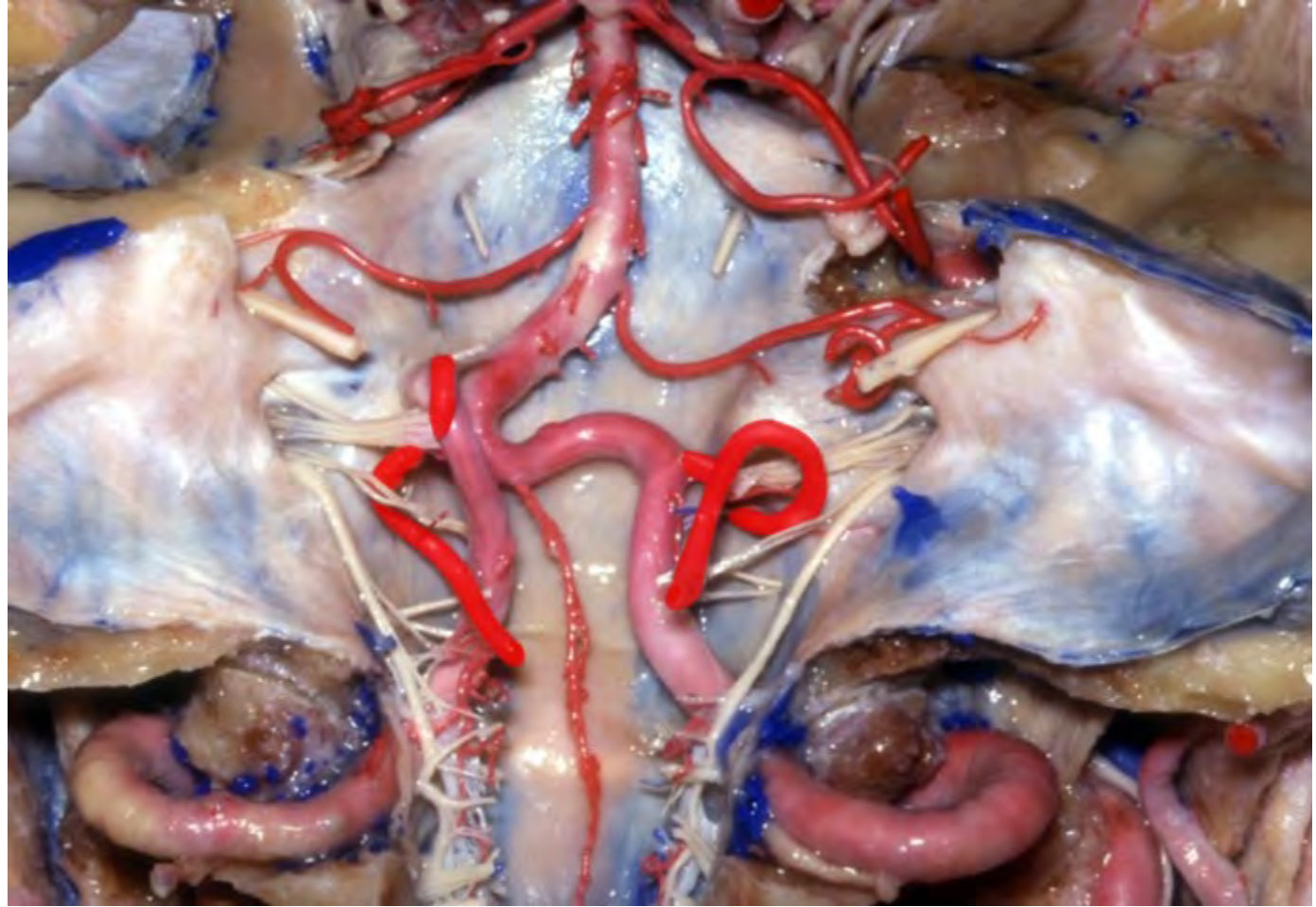


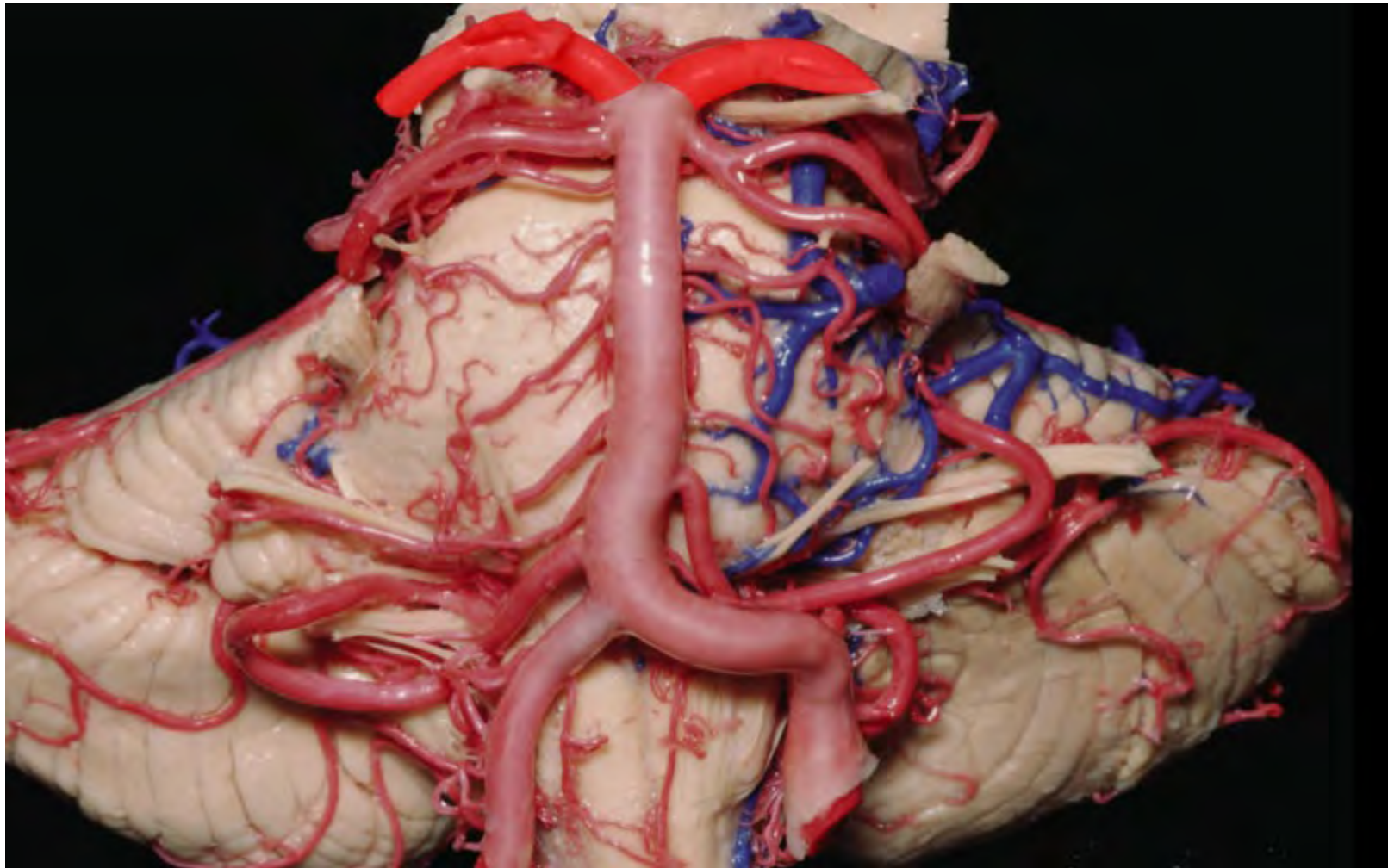


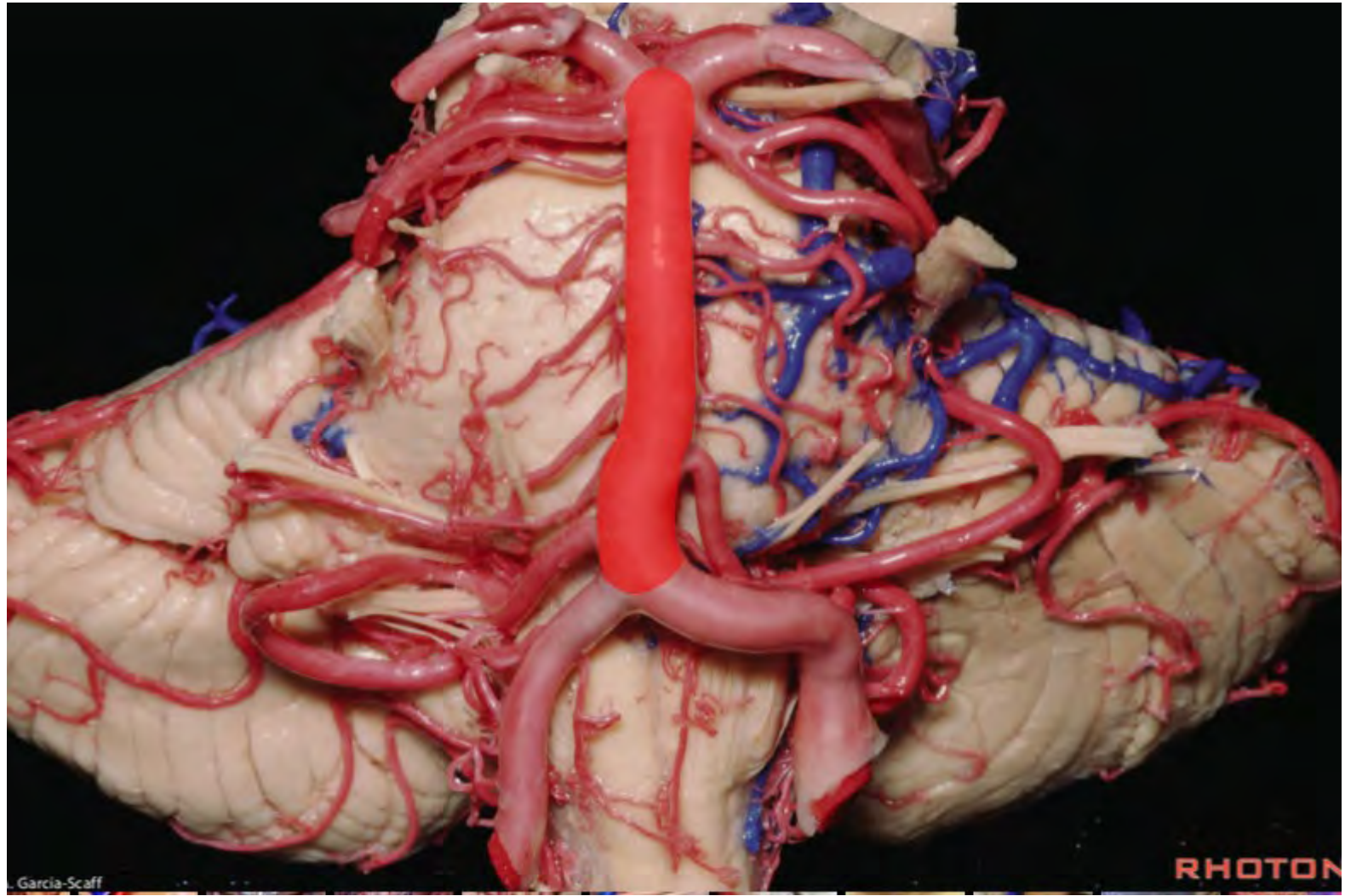


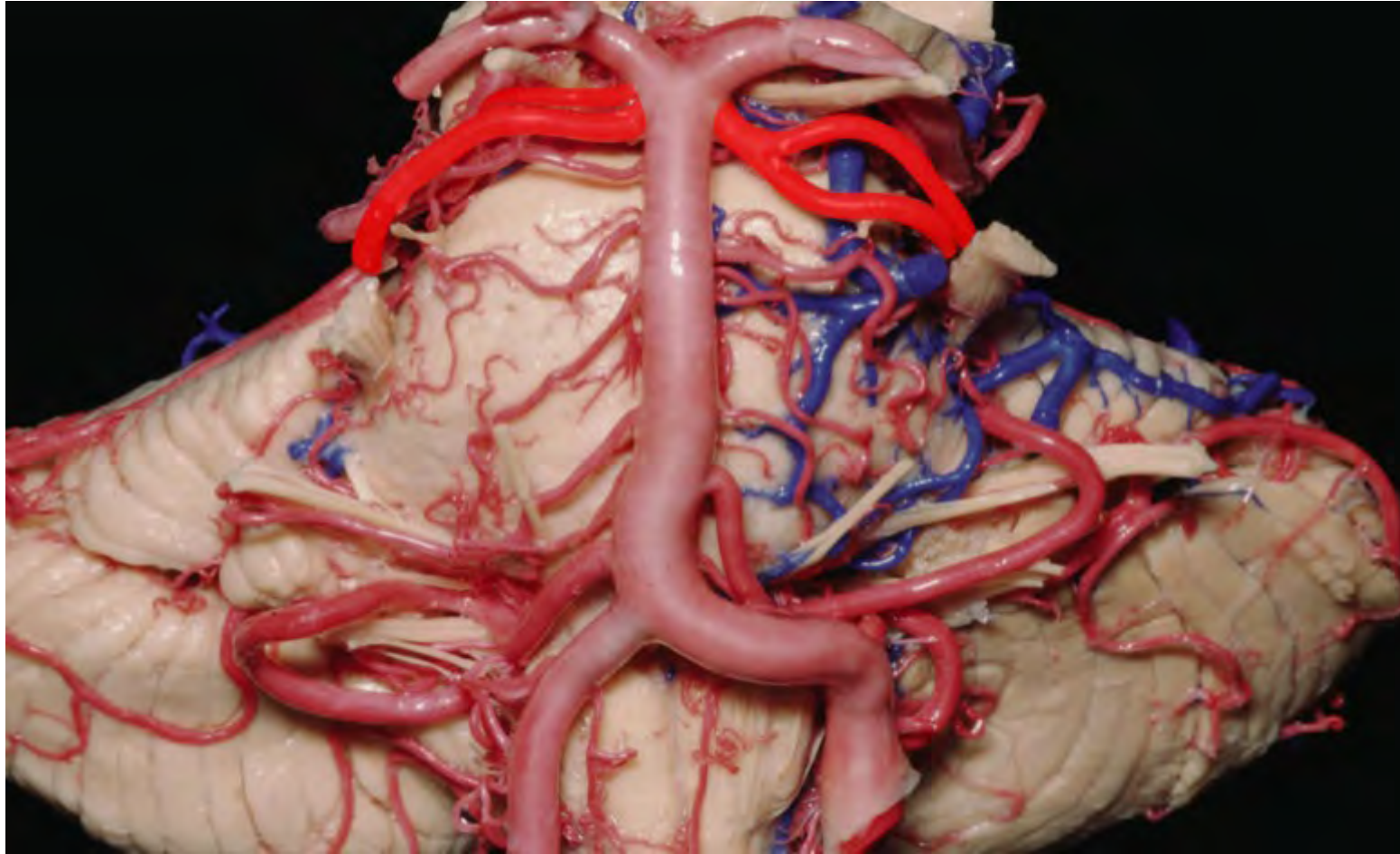


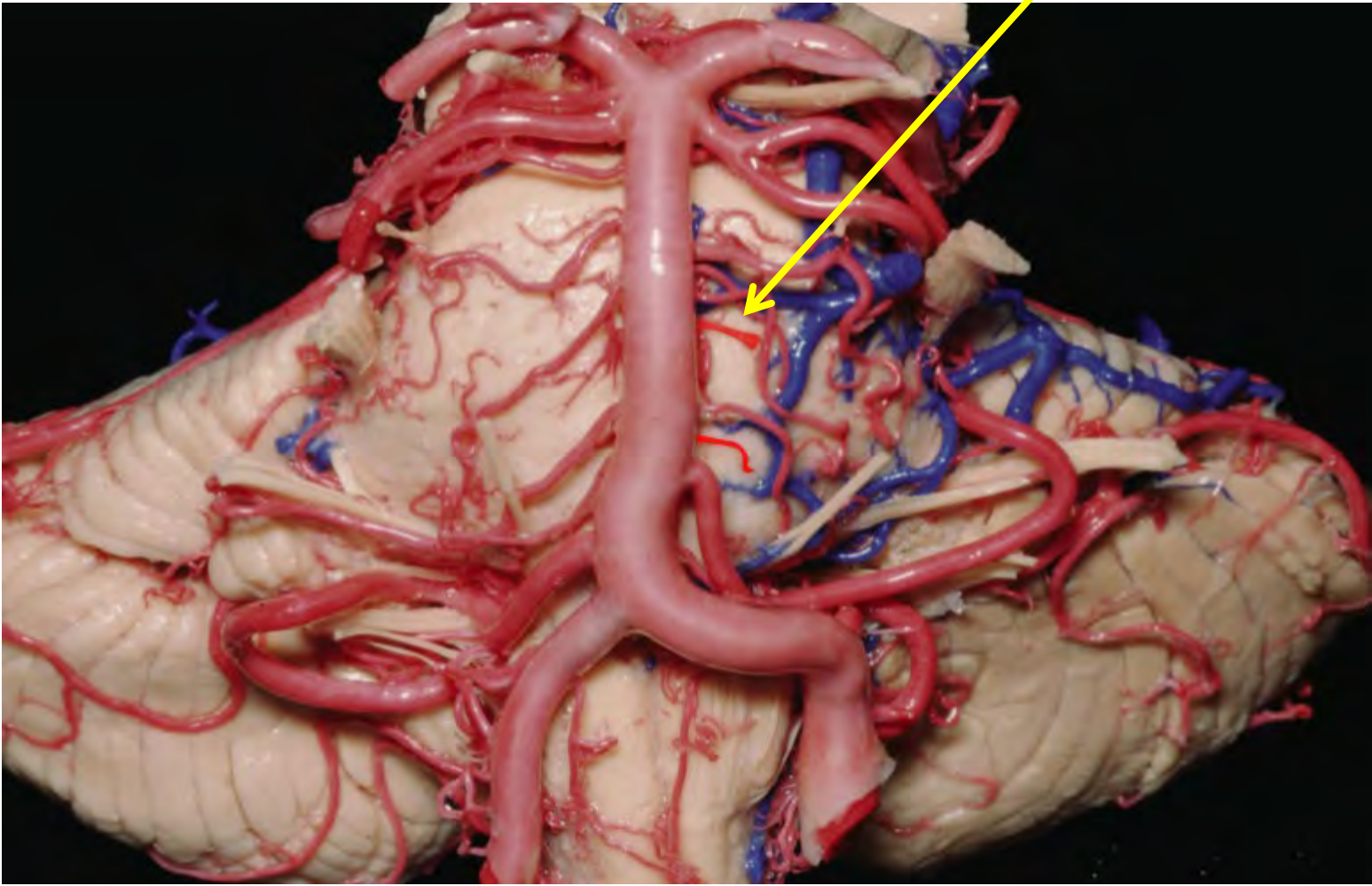


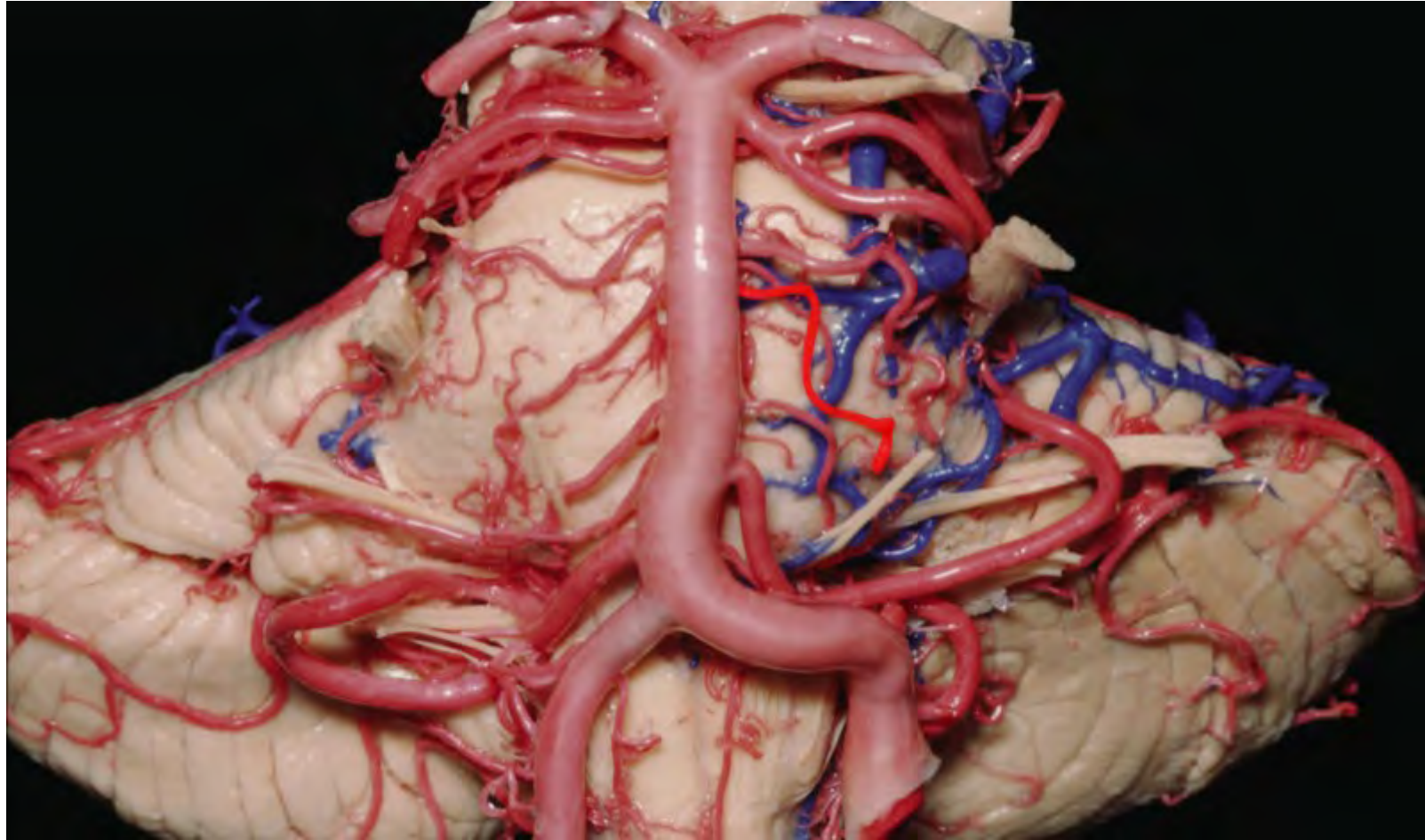




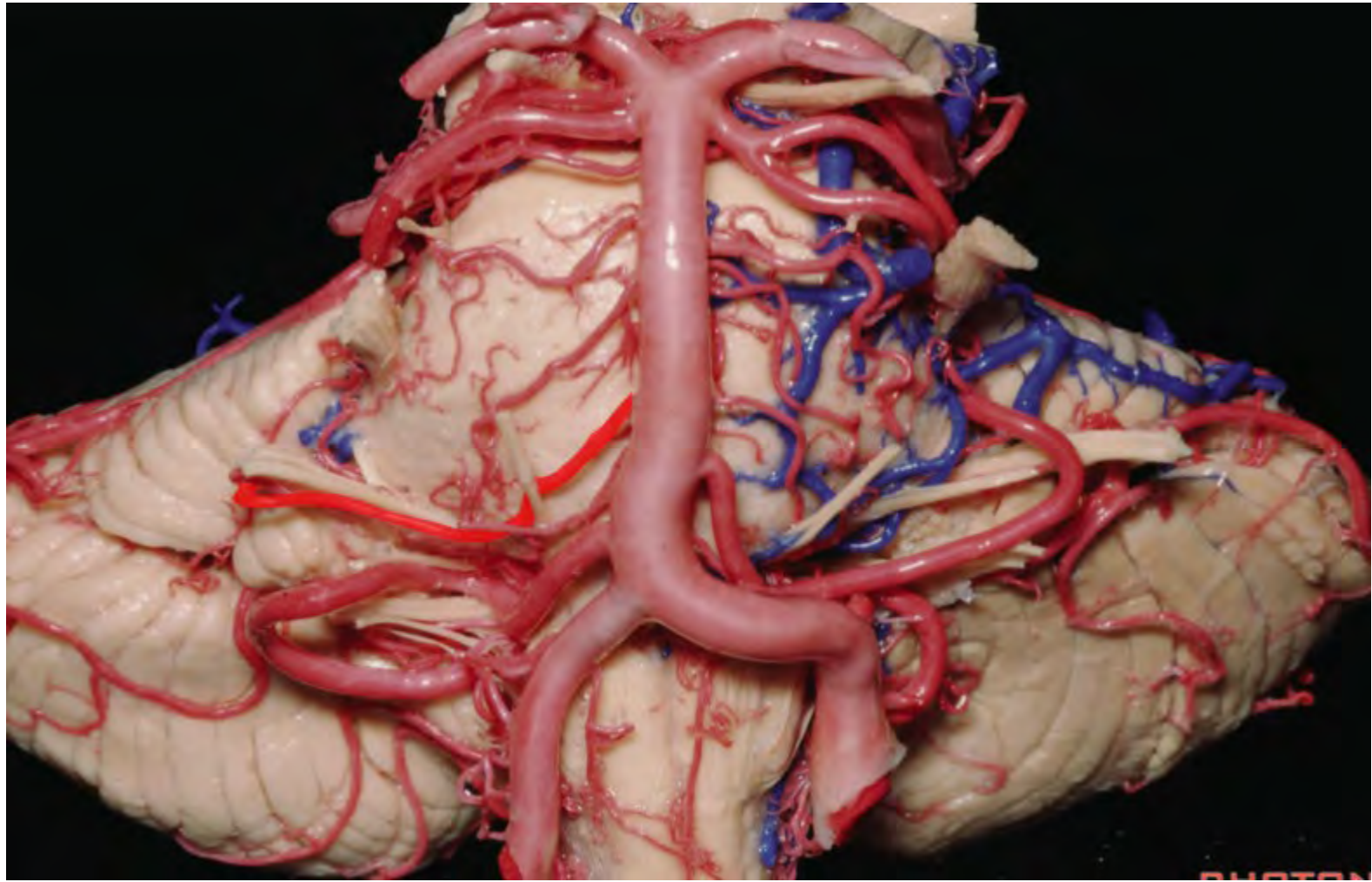


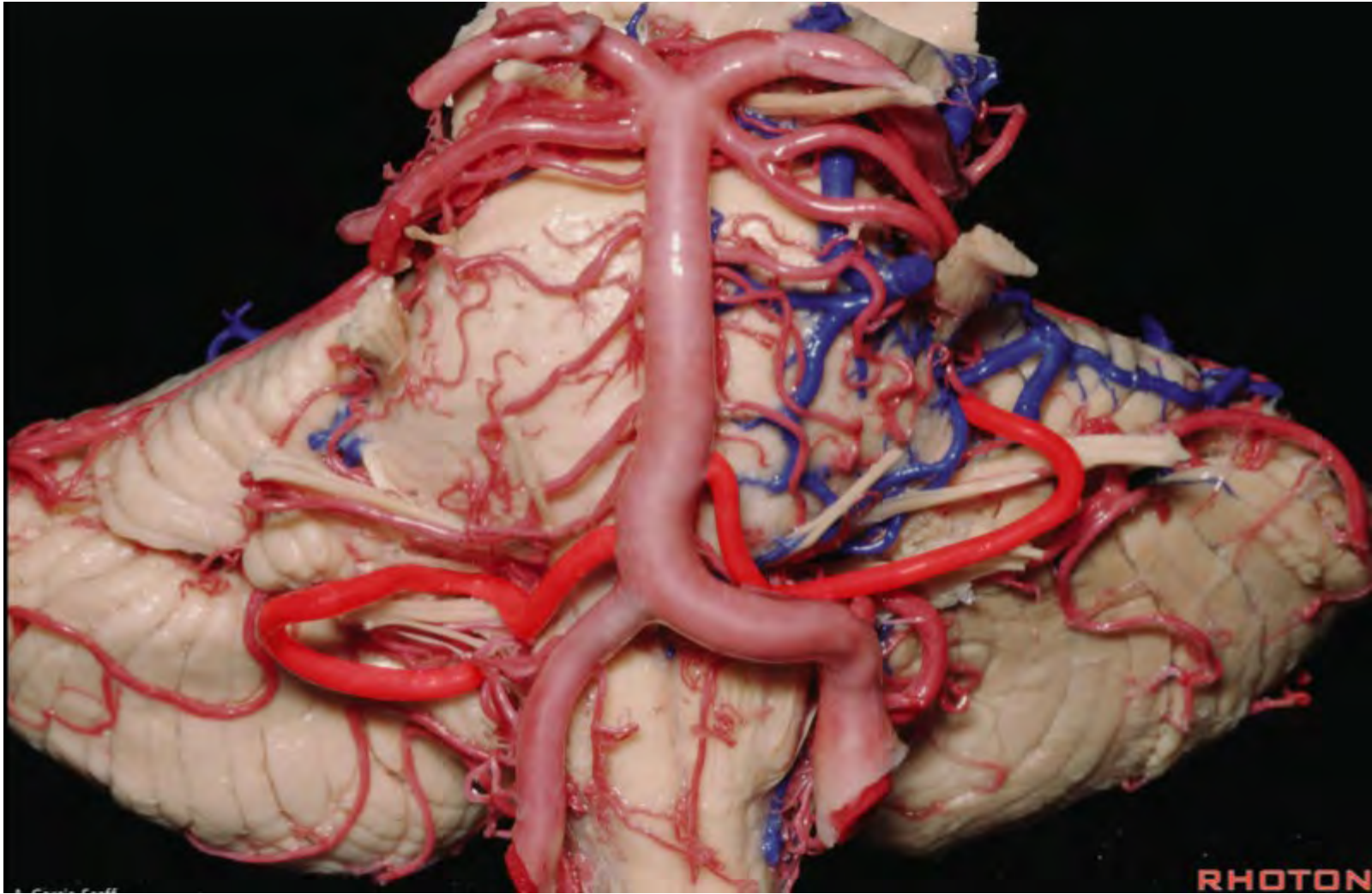


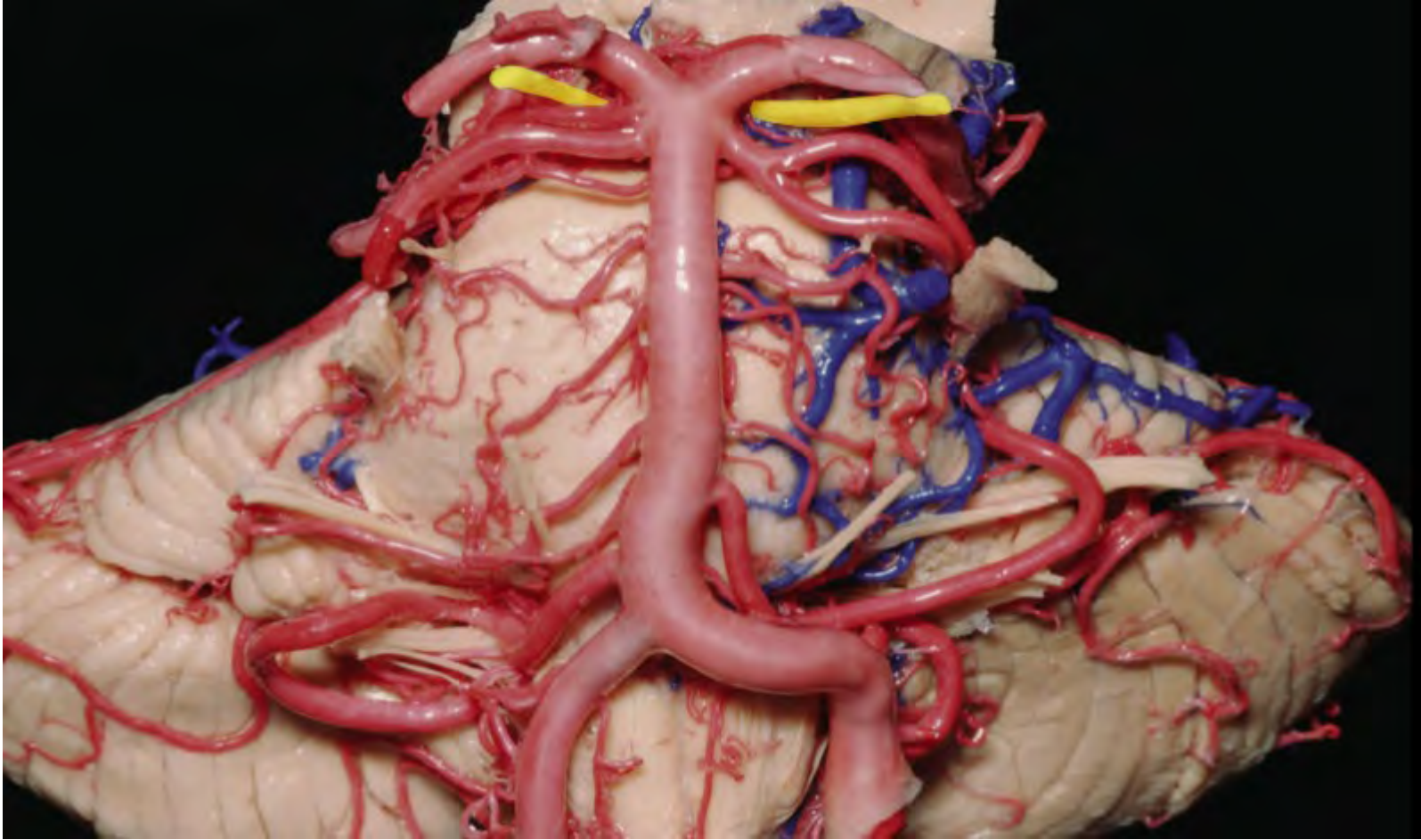


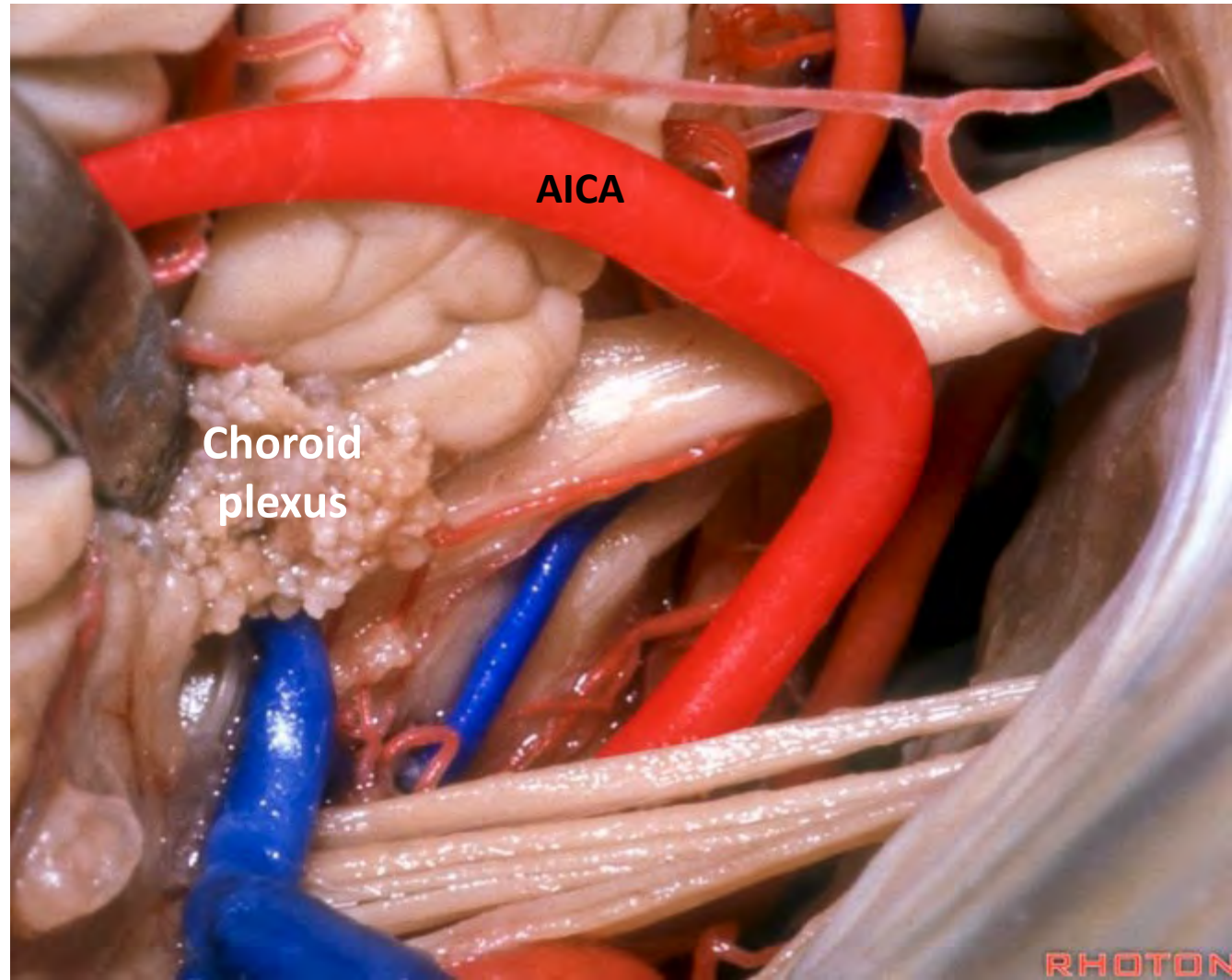


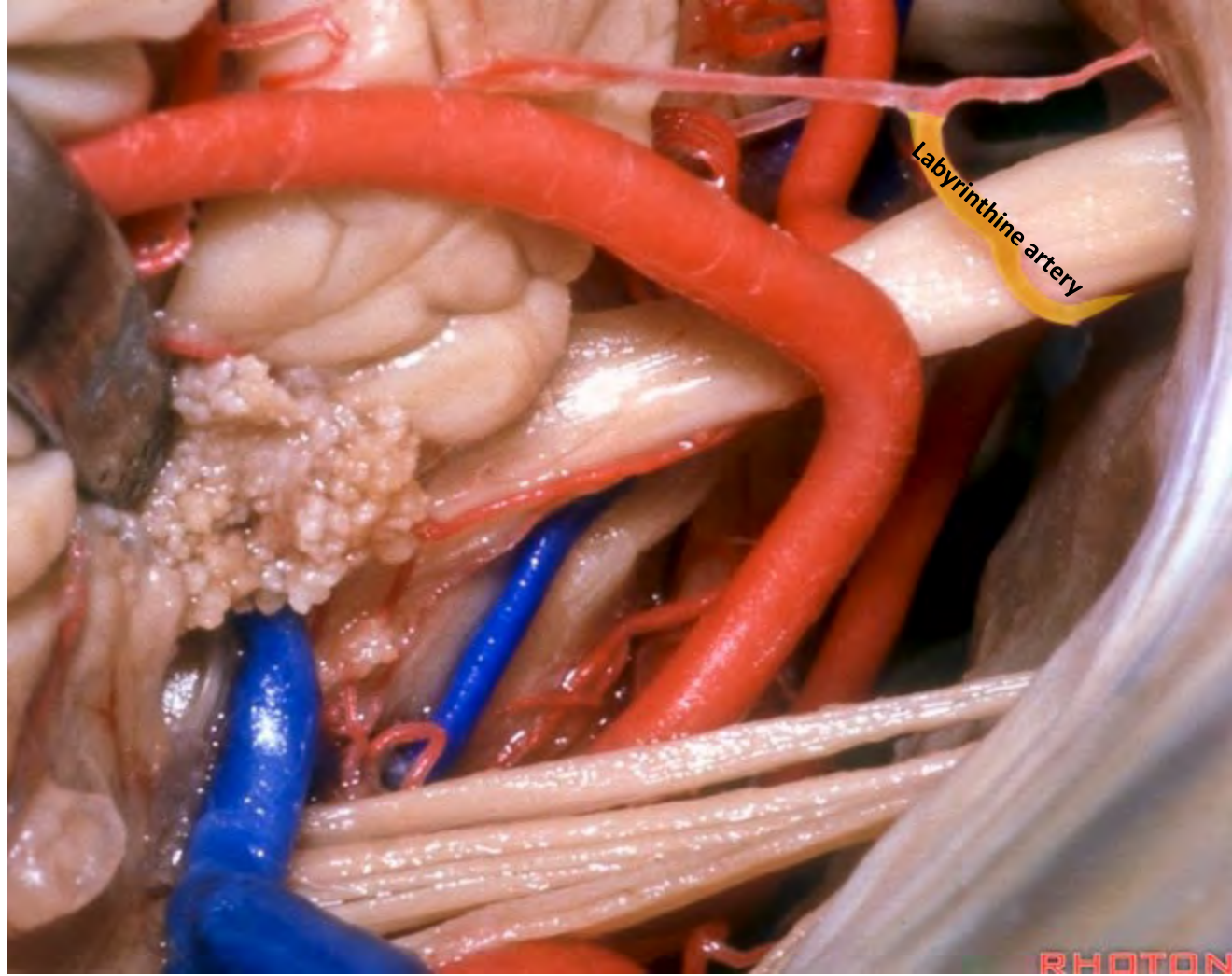


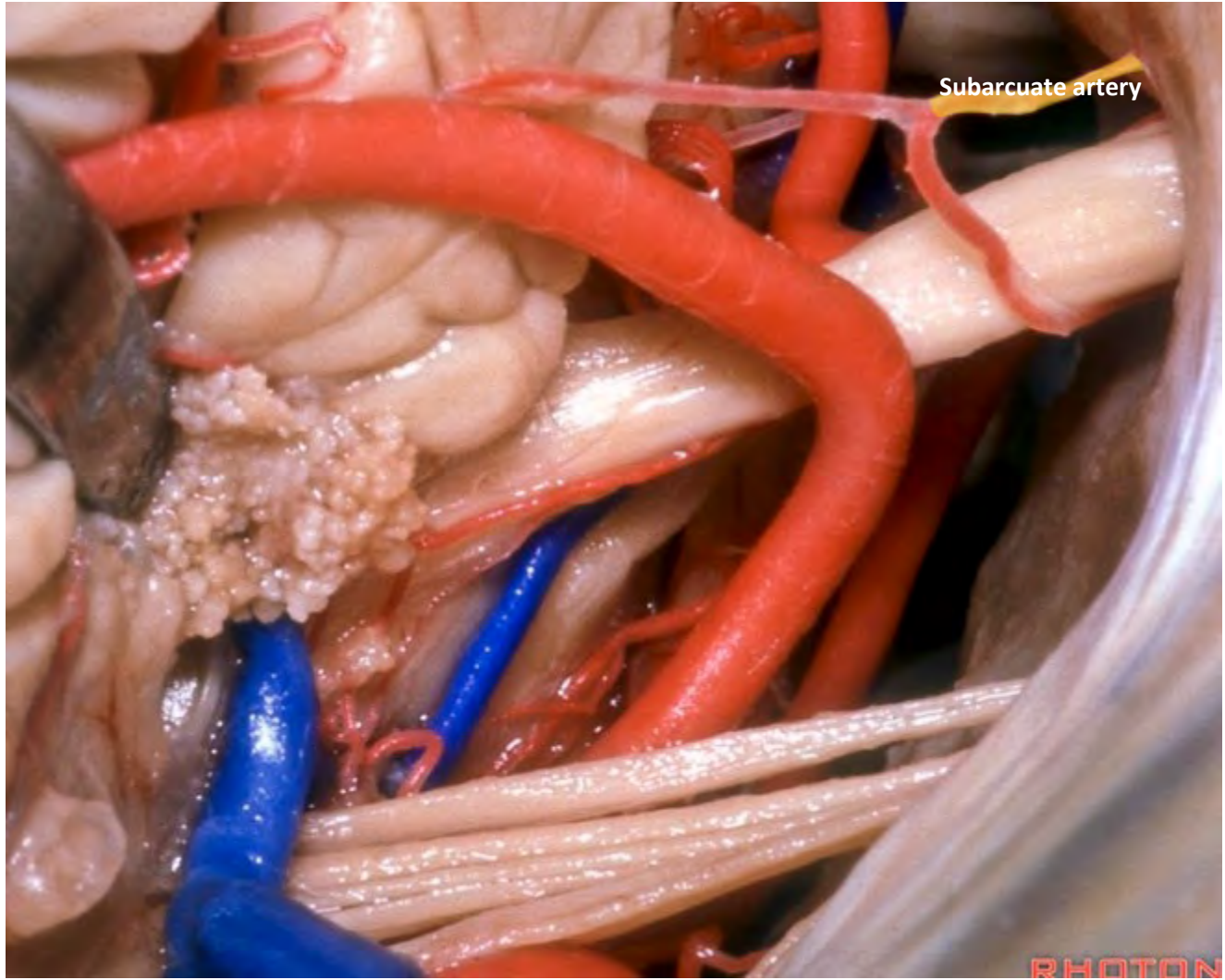


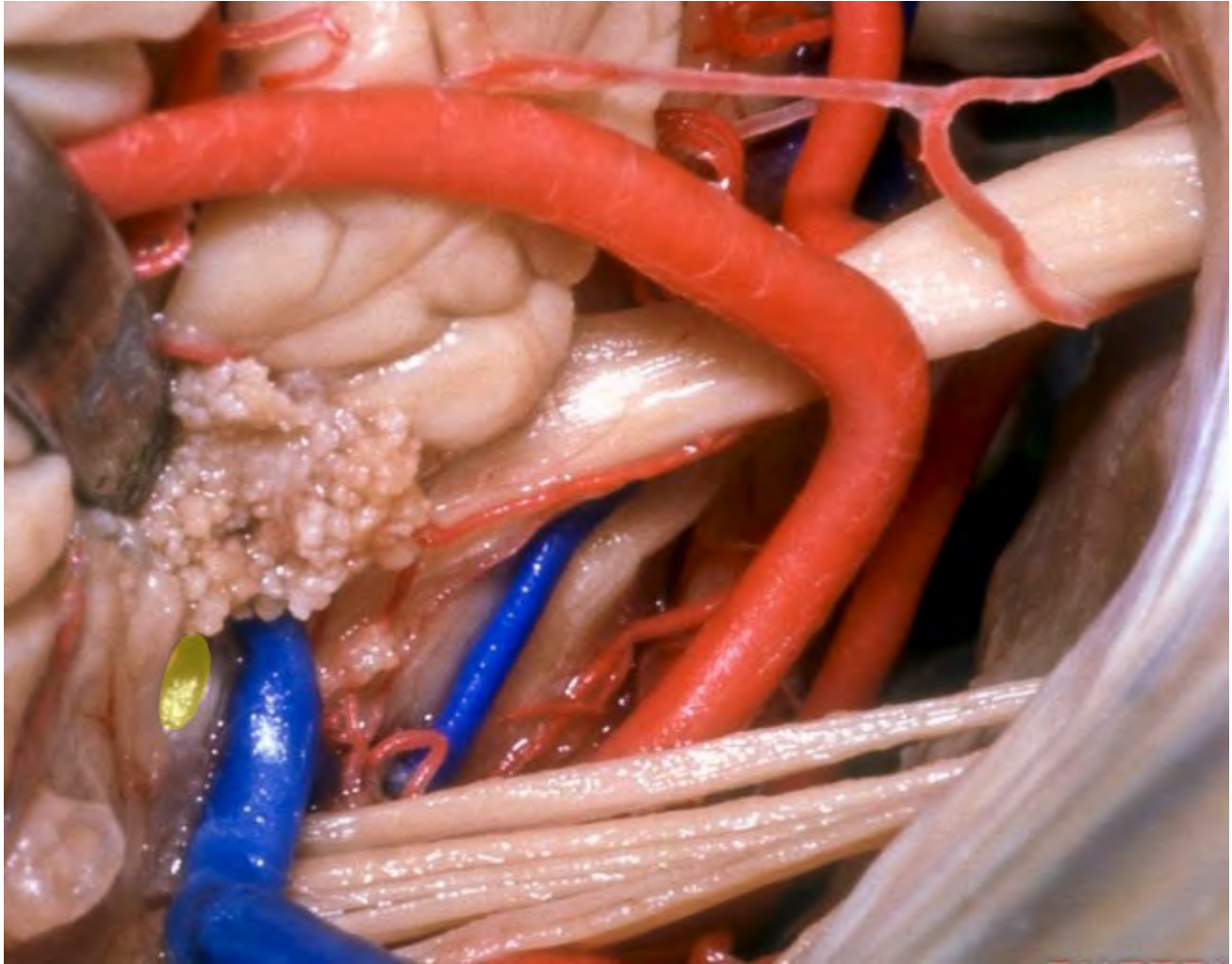


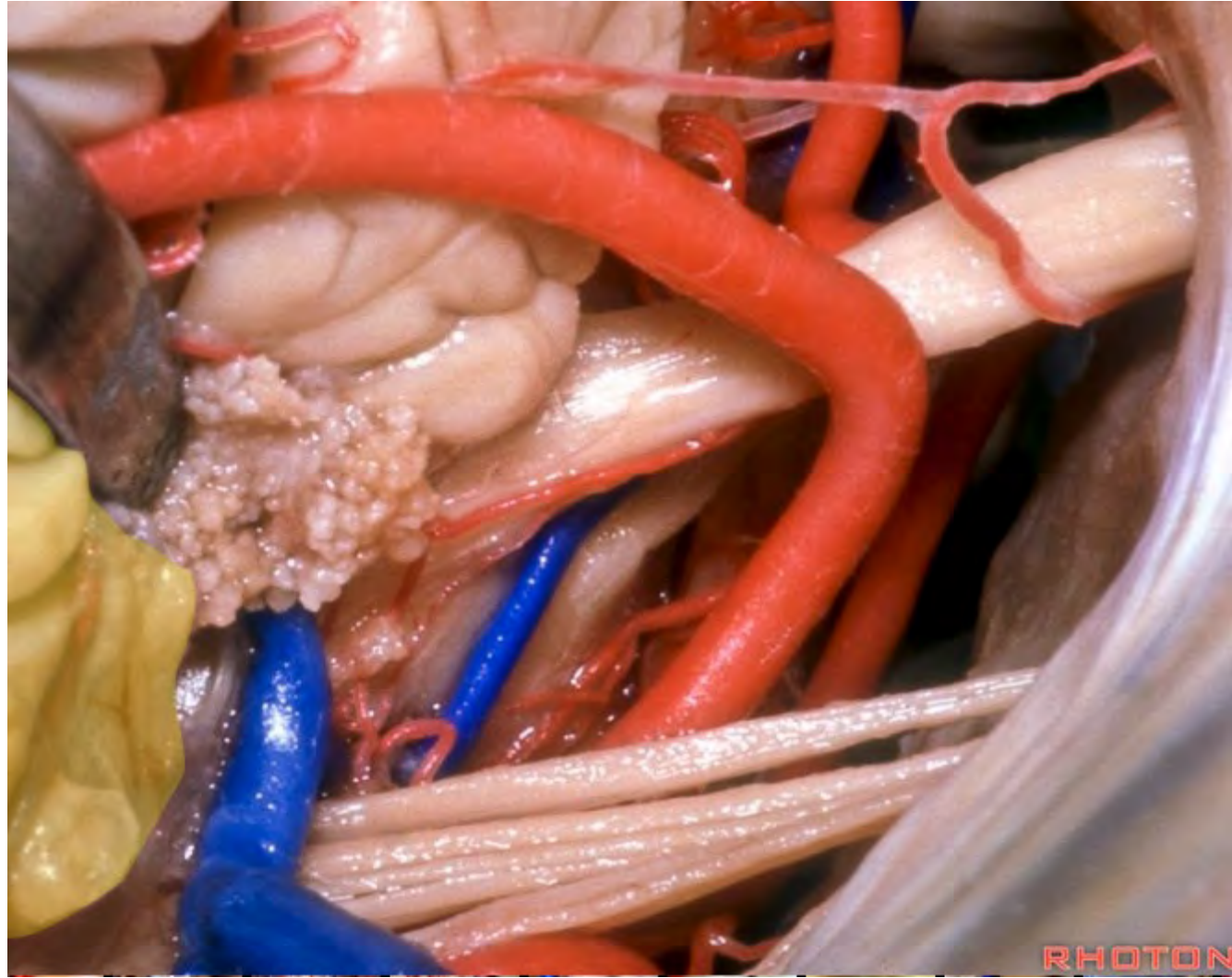




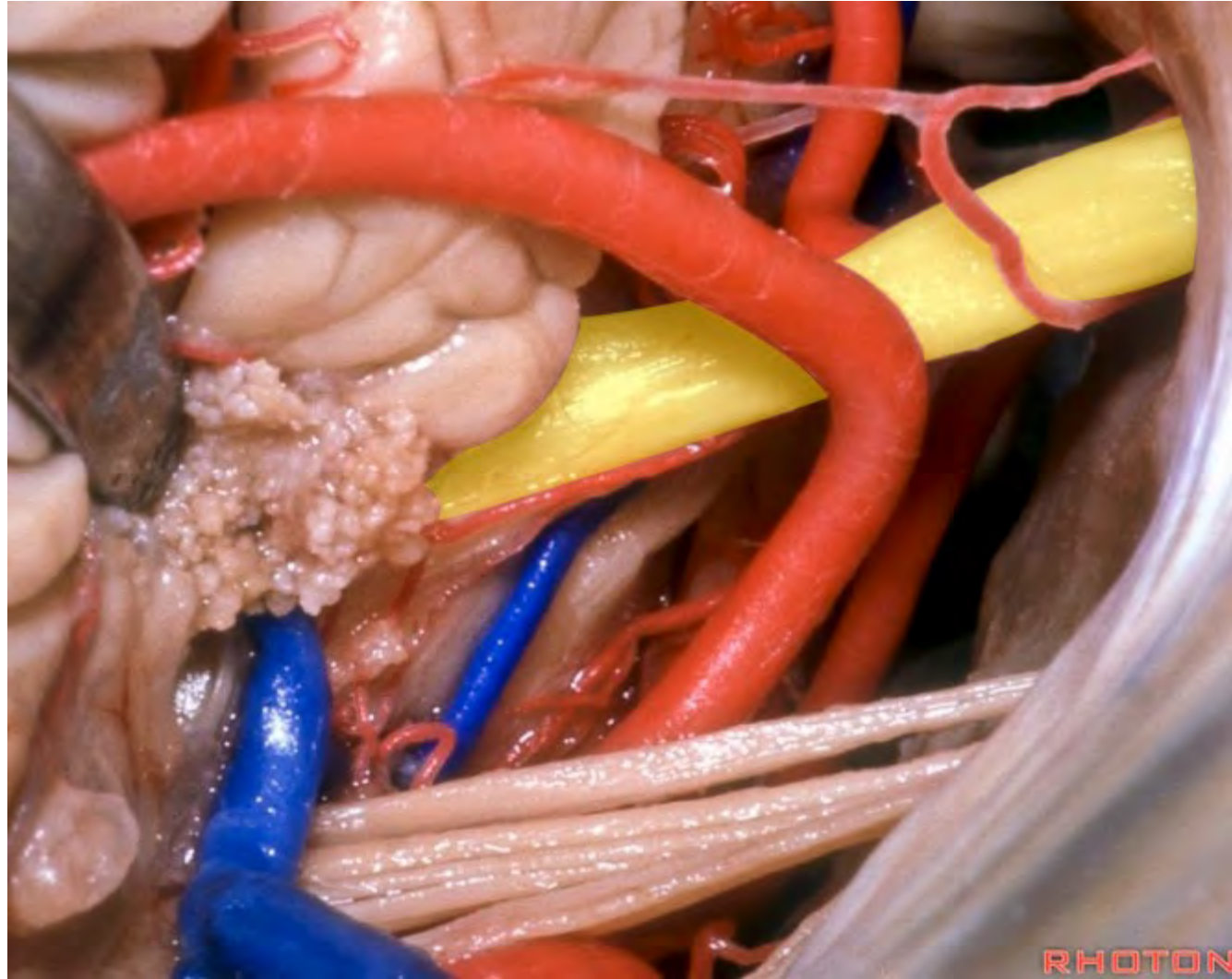


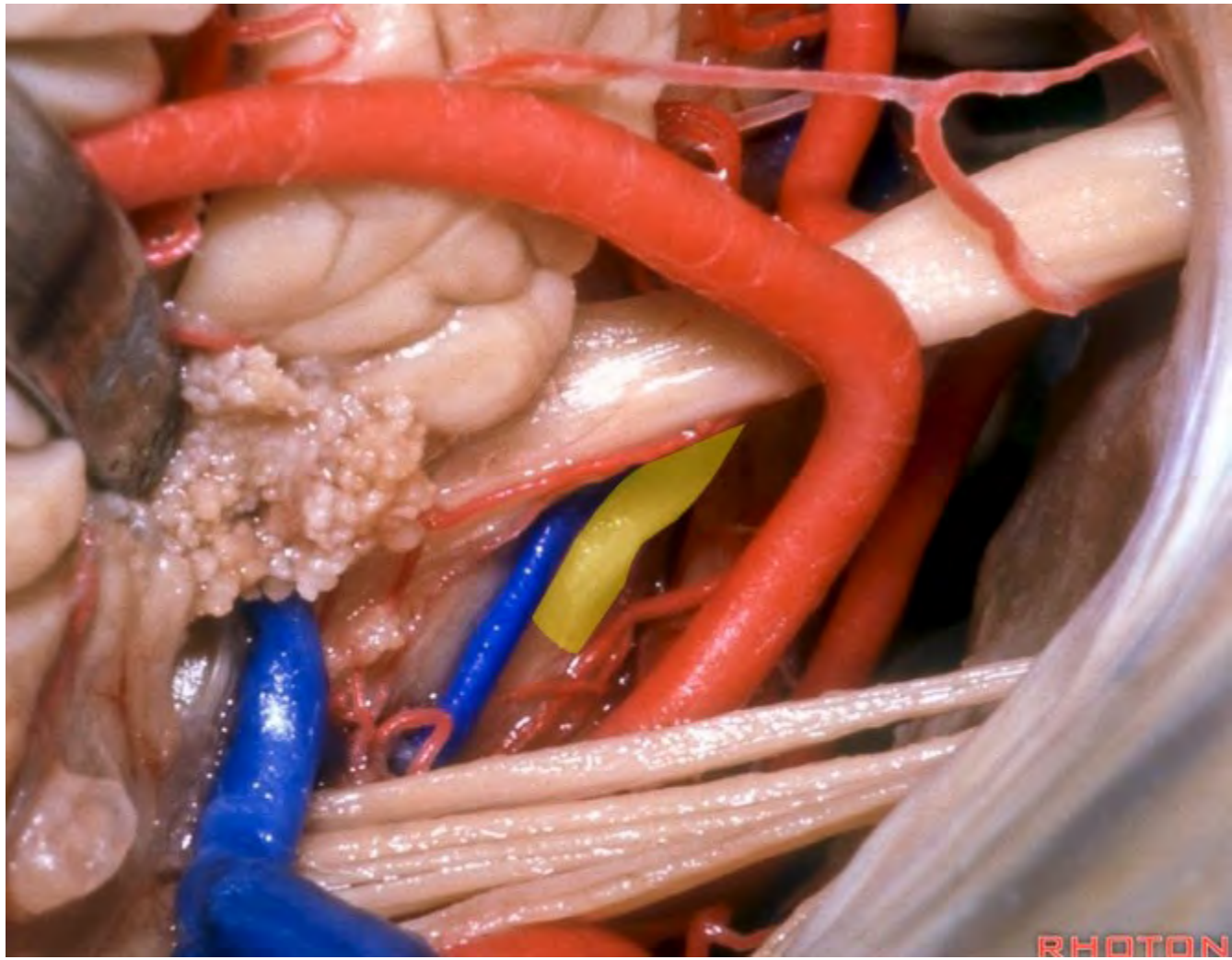


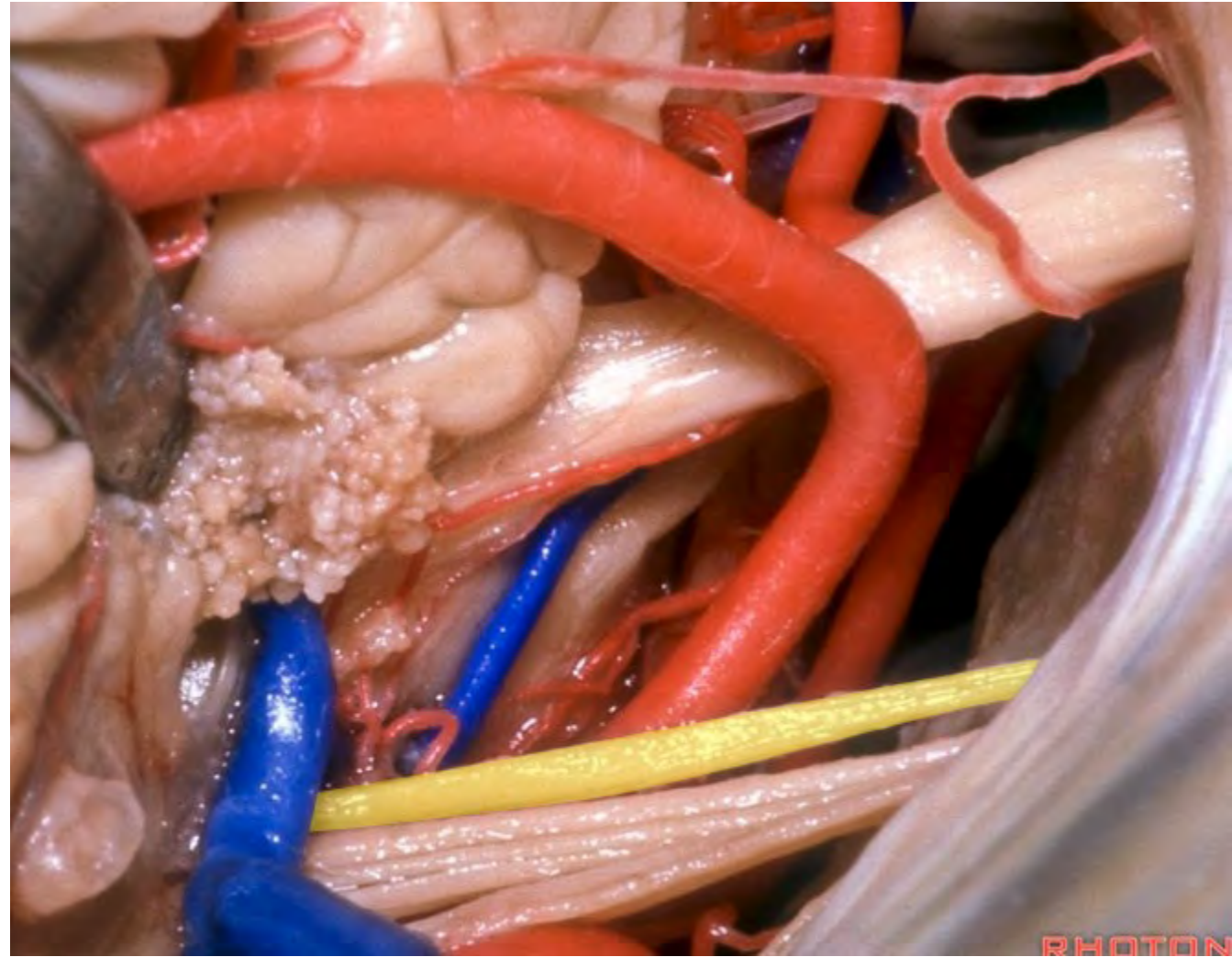


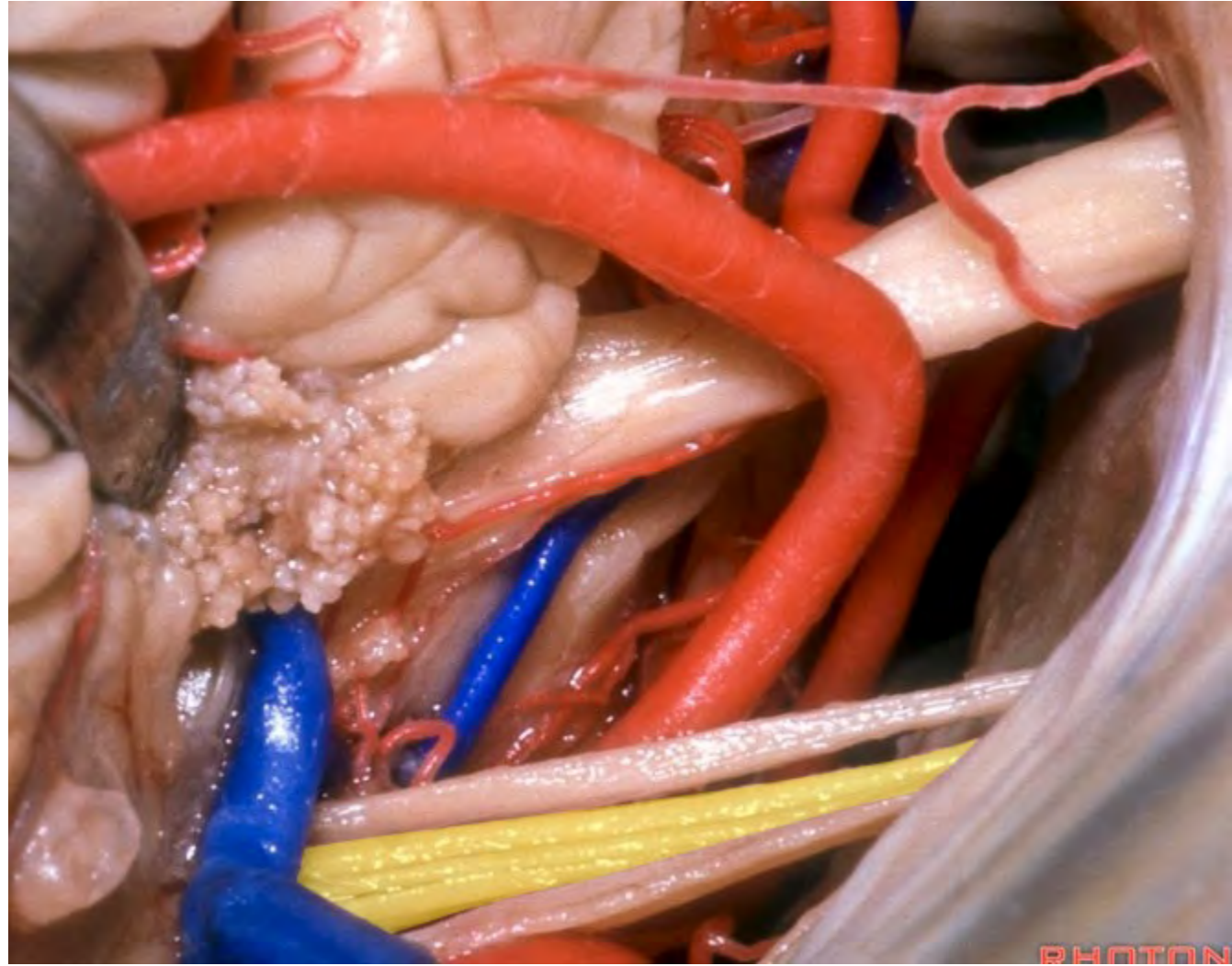


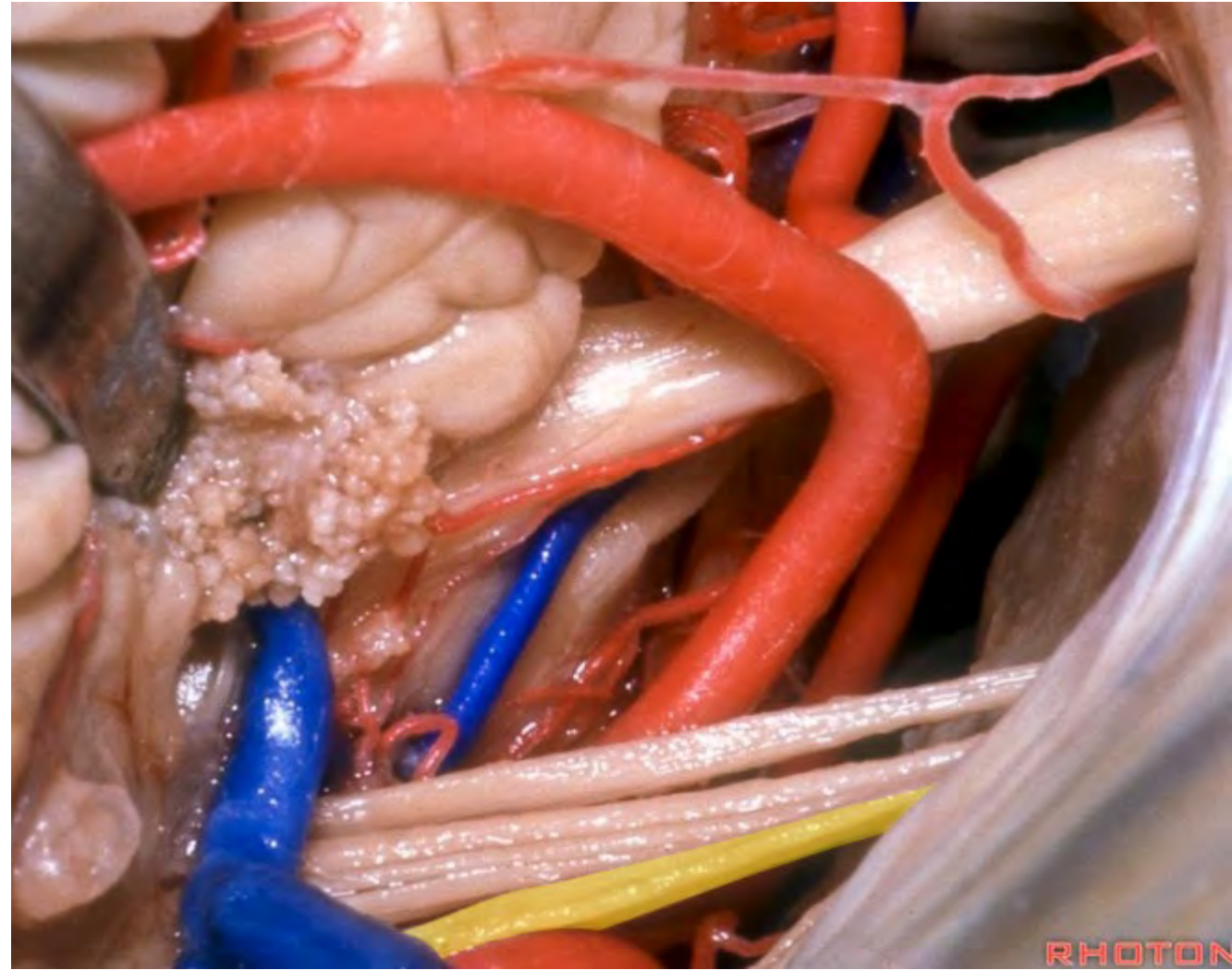




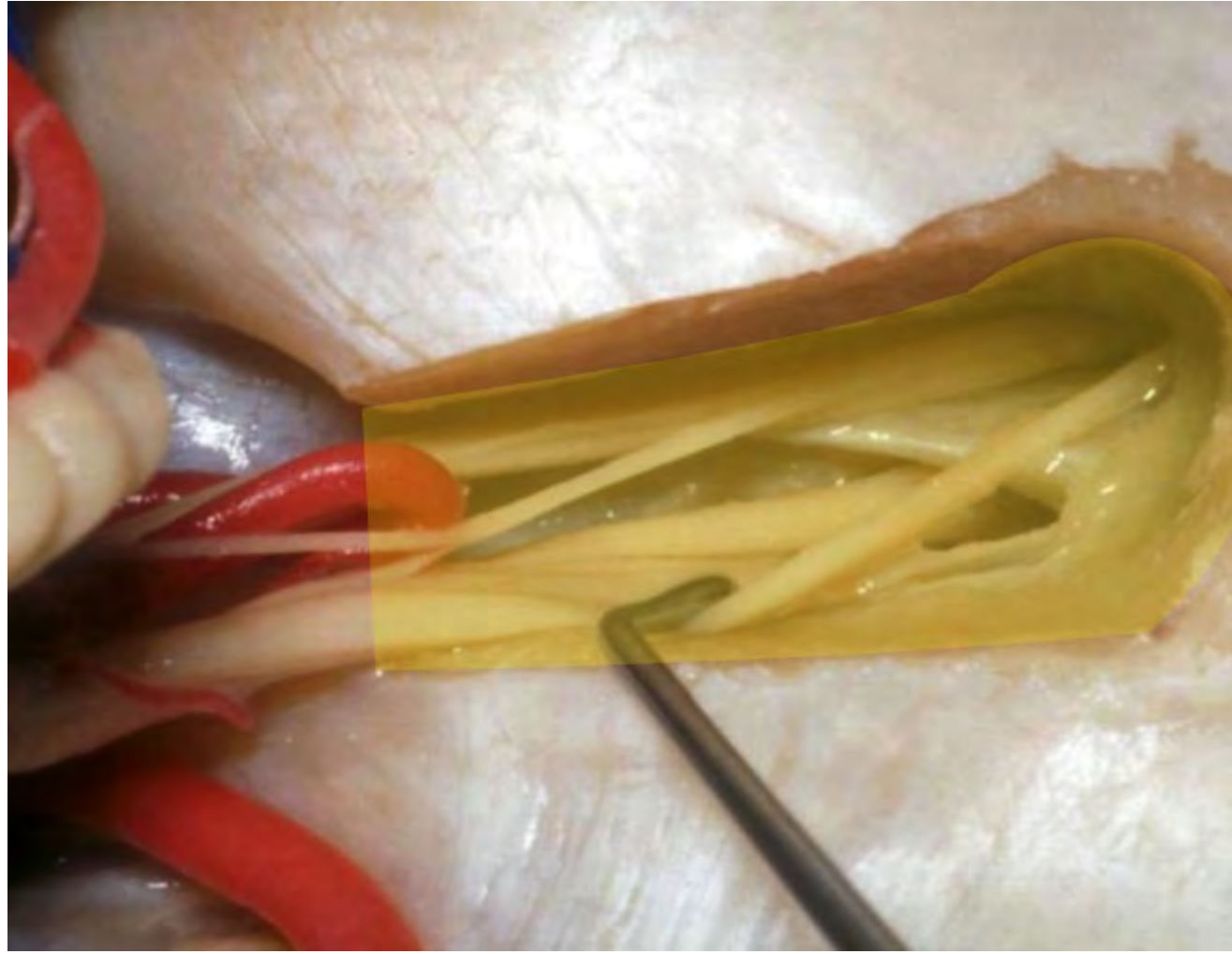


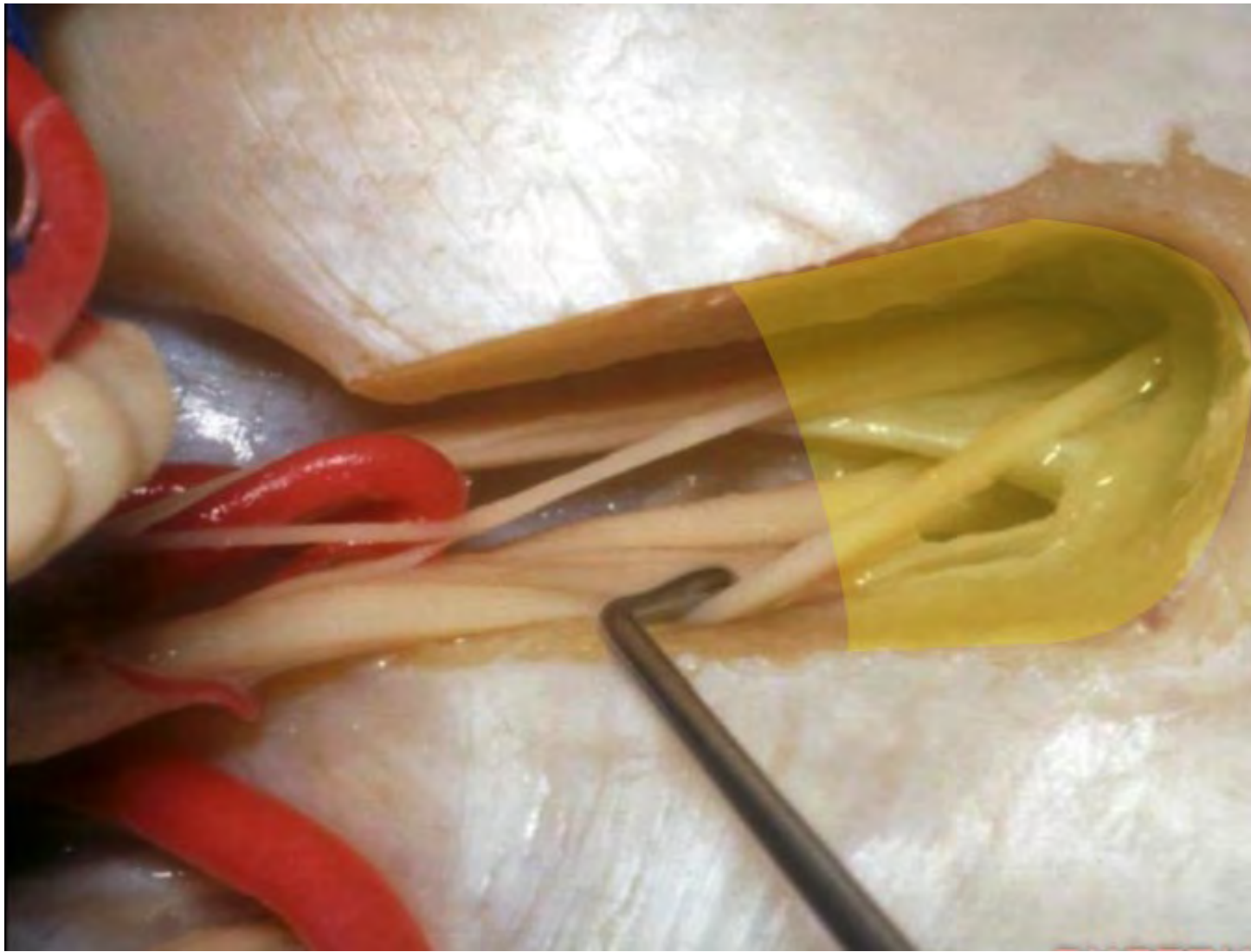


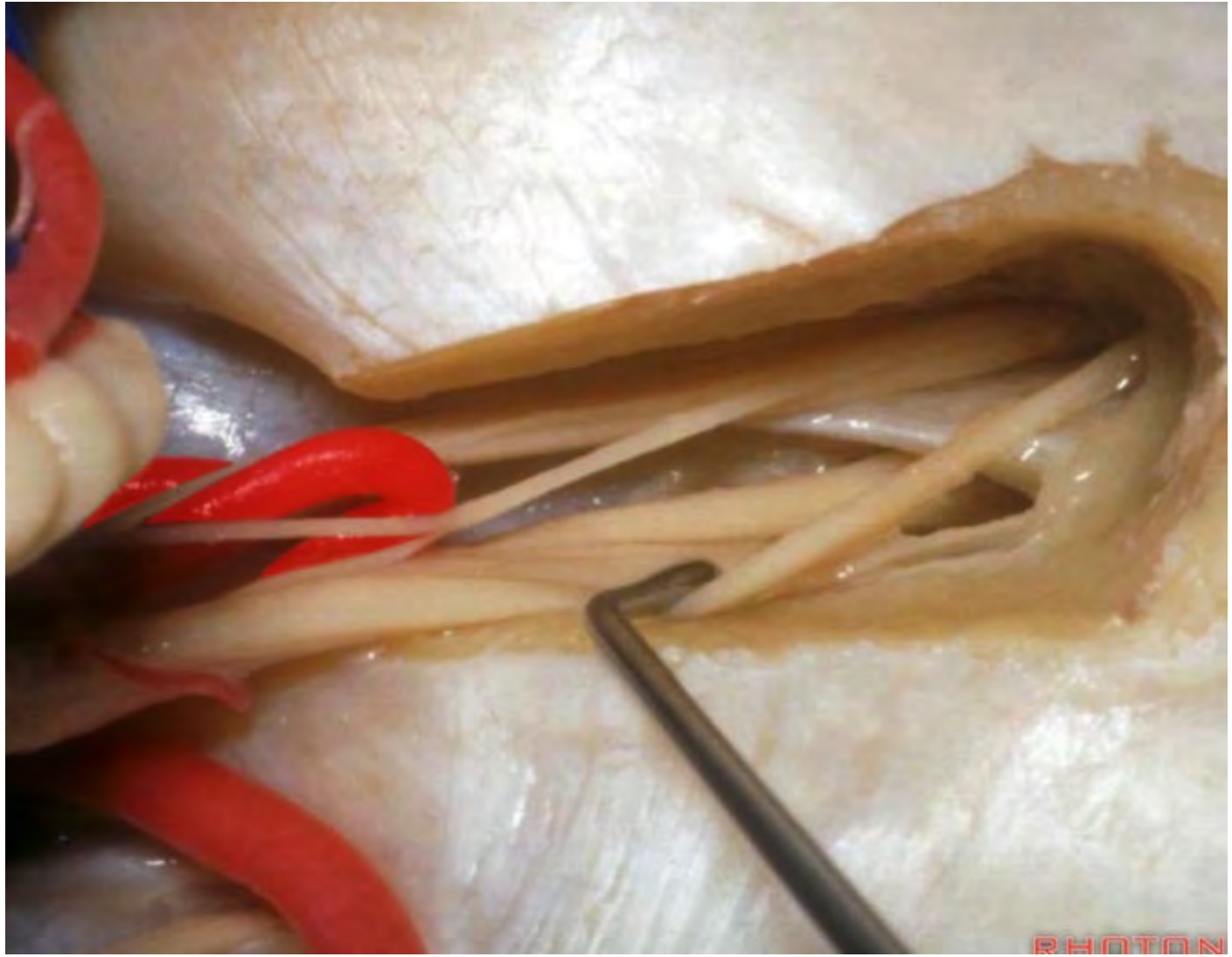




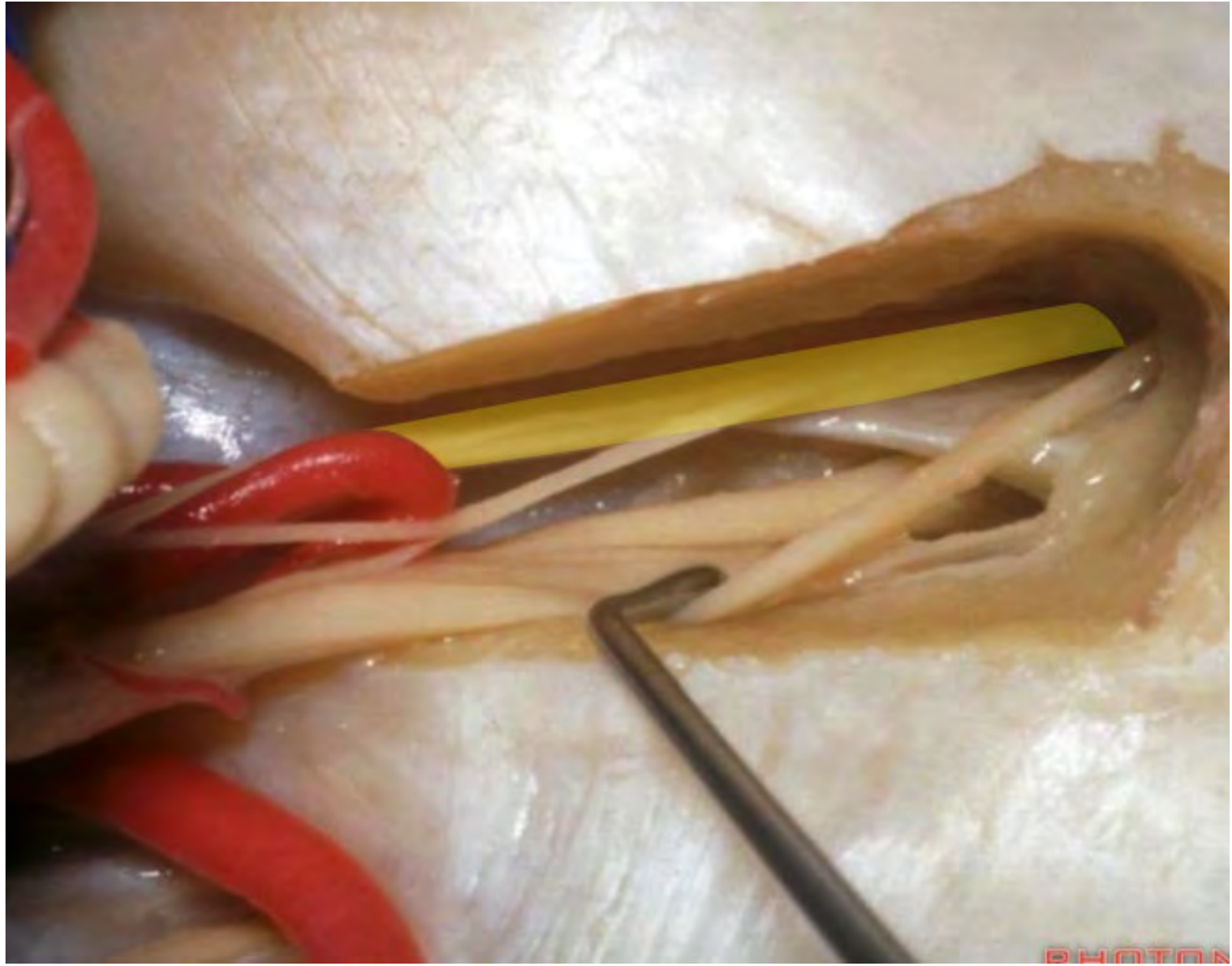
RHOTON

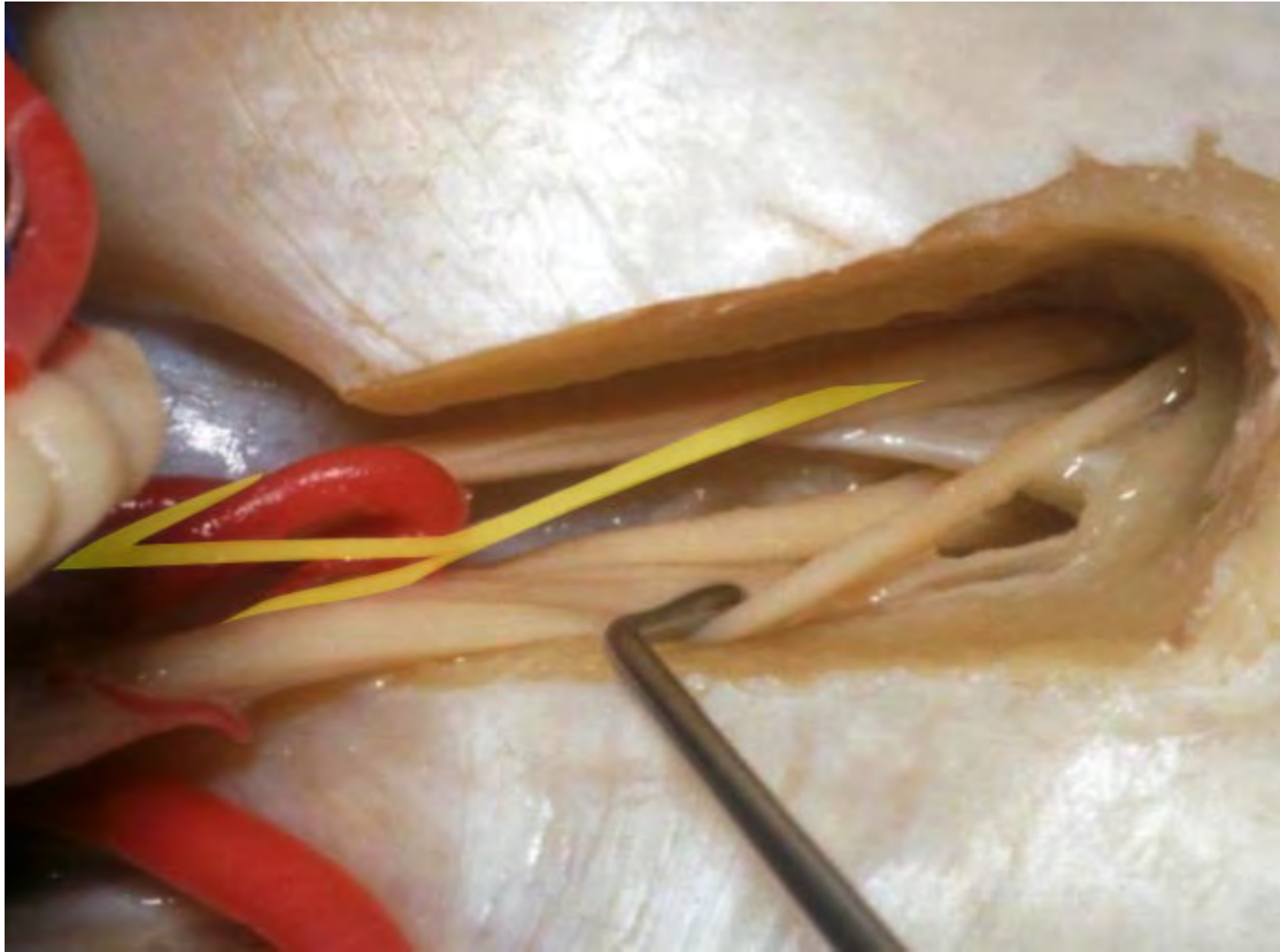




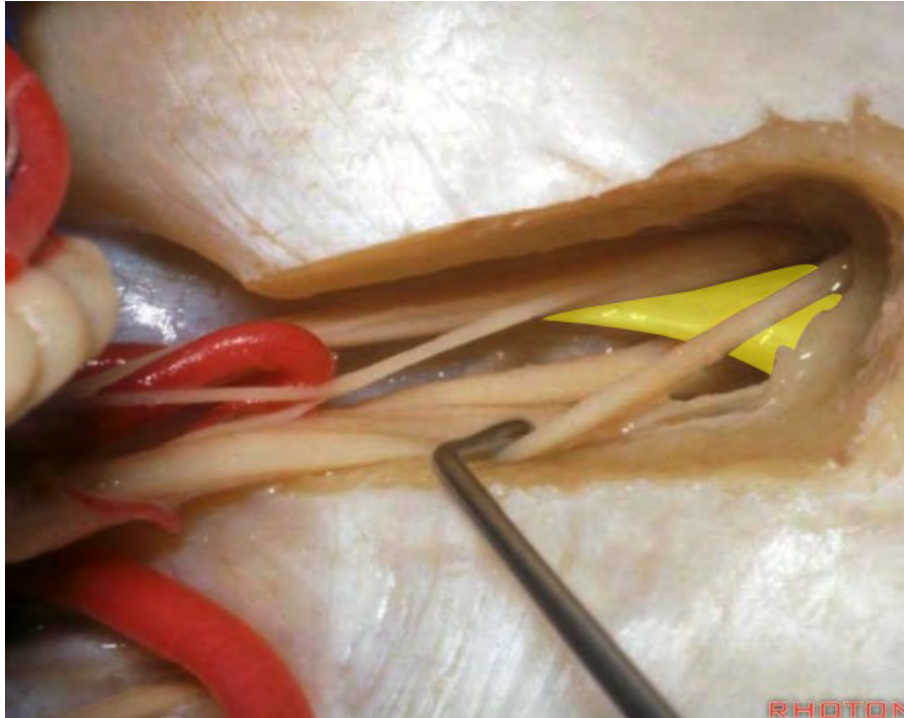




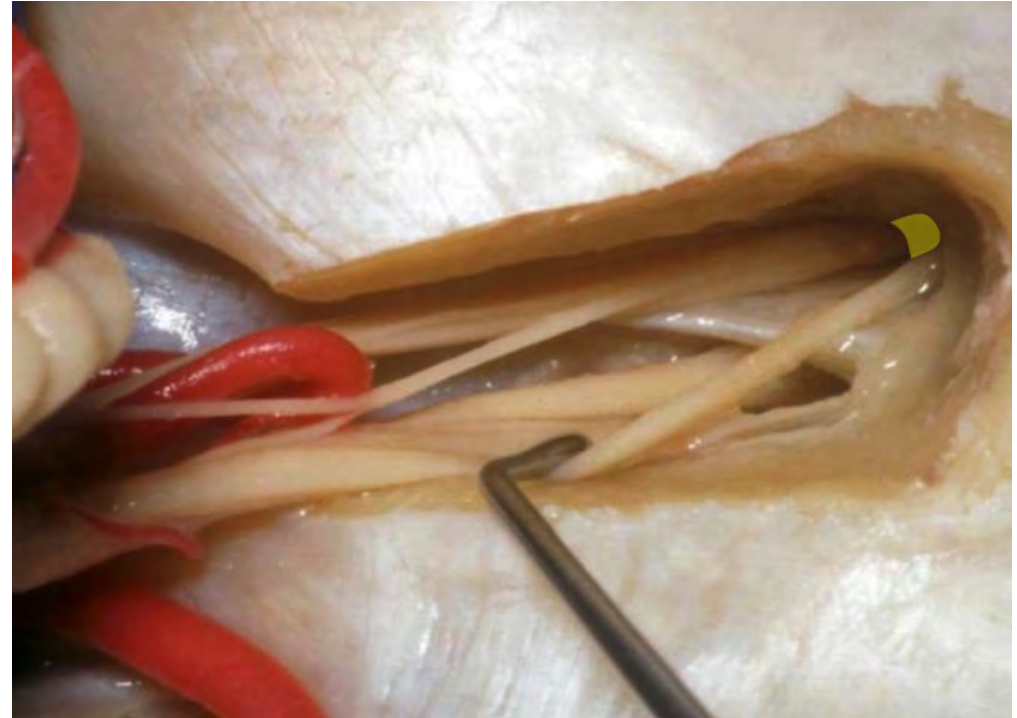



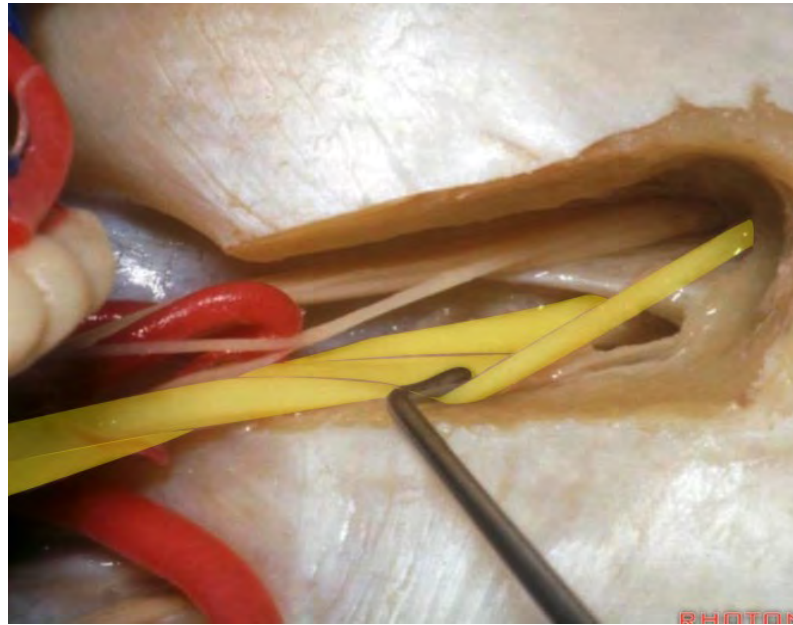
**Transverse crest**



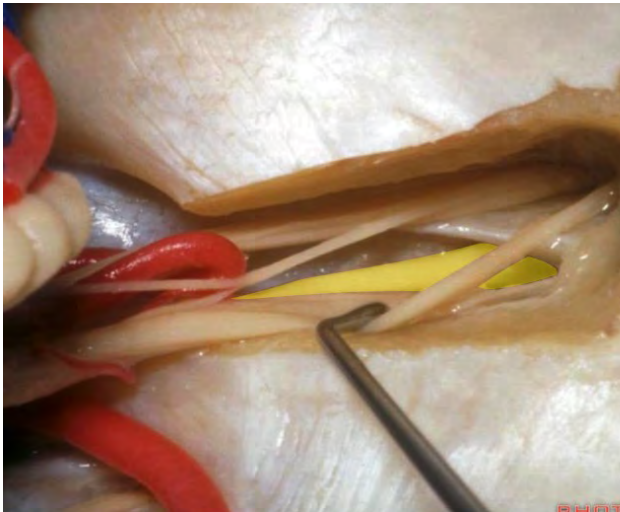**Vertical crest**



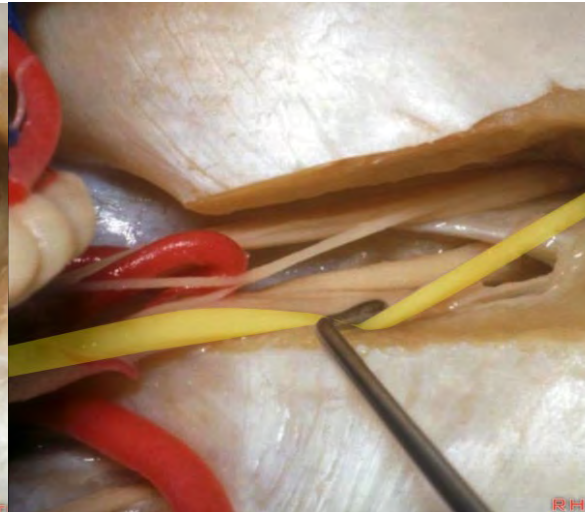
**Vestibulocochlear nerve**



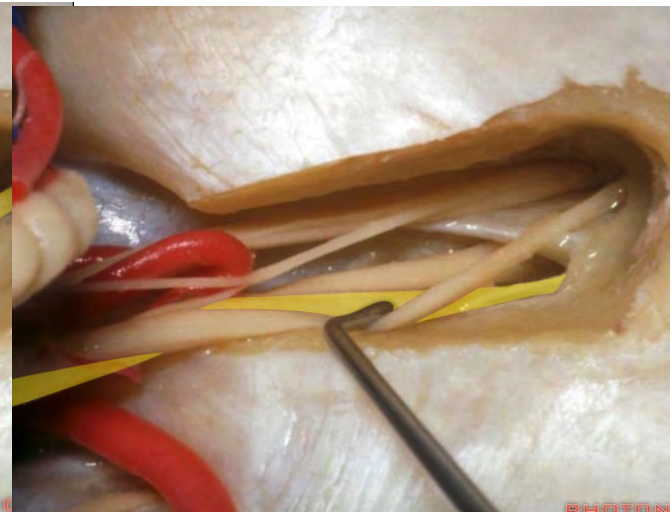
**Auditory nerve**

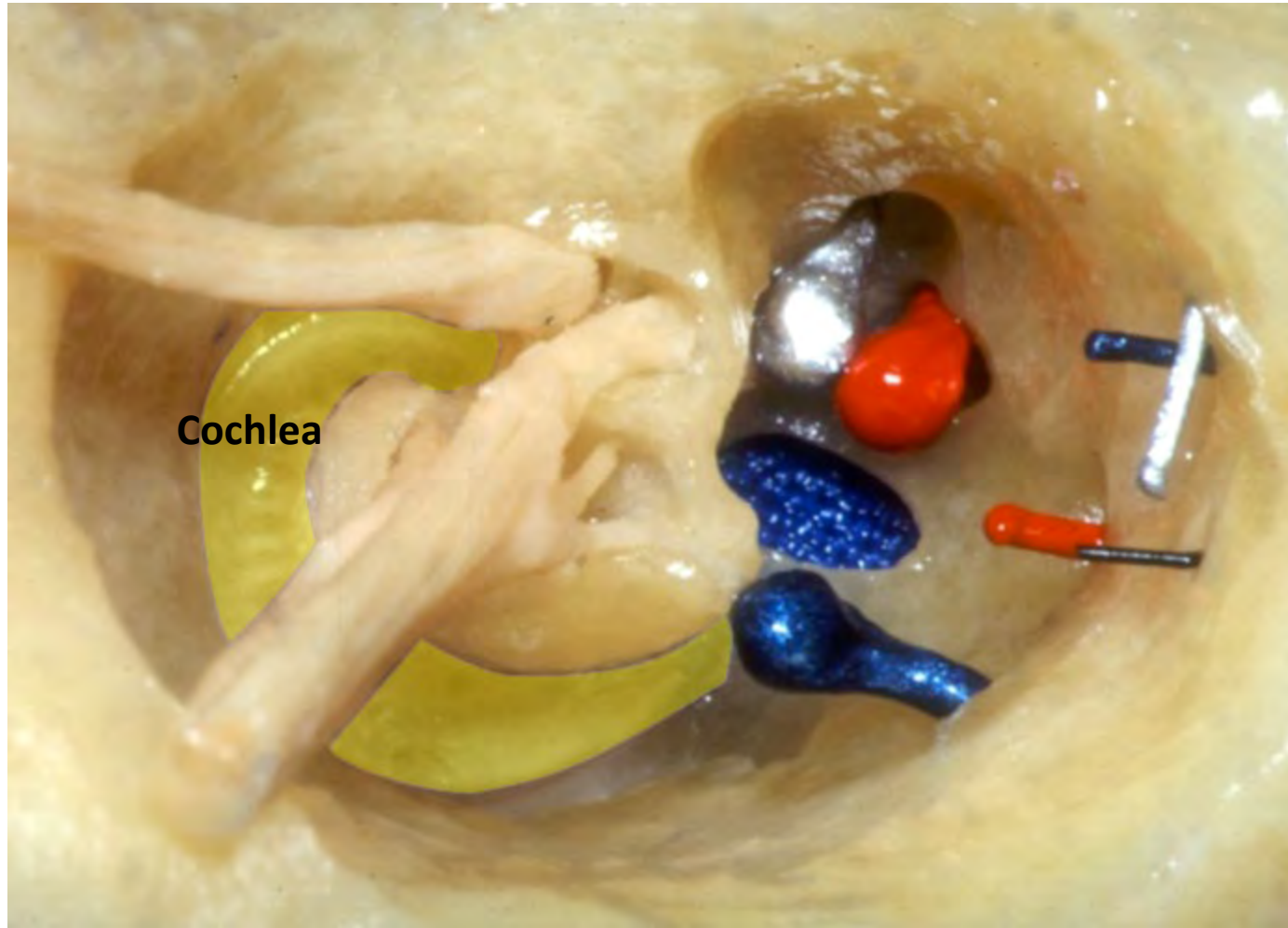


**Superior vestibular nerve**

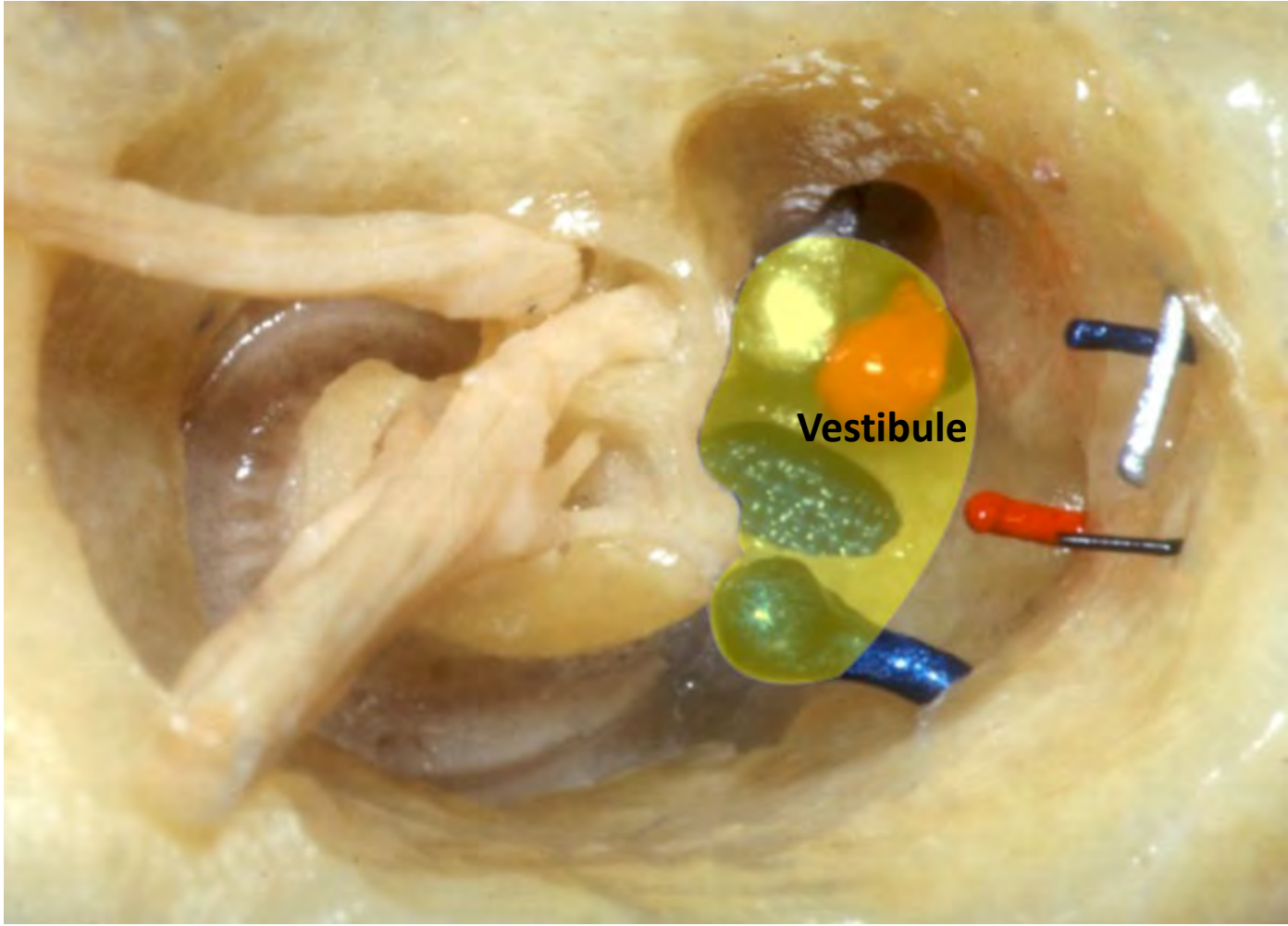


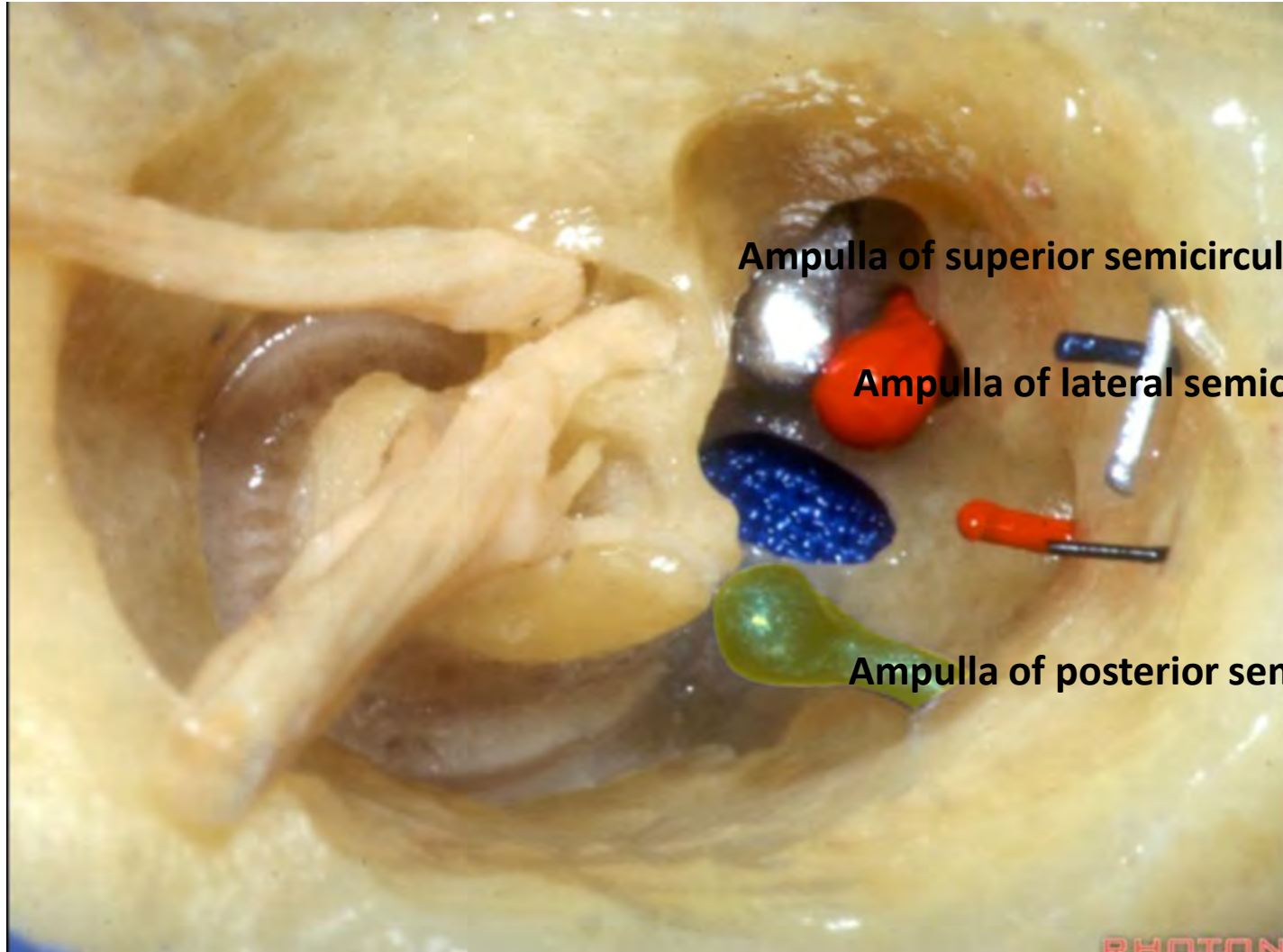
**Inferior vestibular nerve**





Cochlea



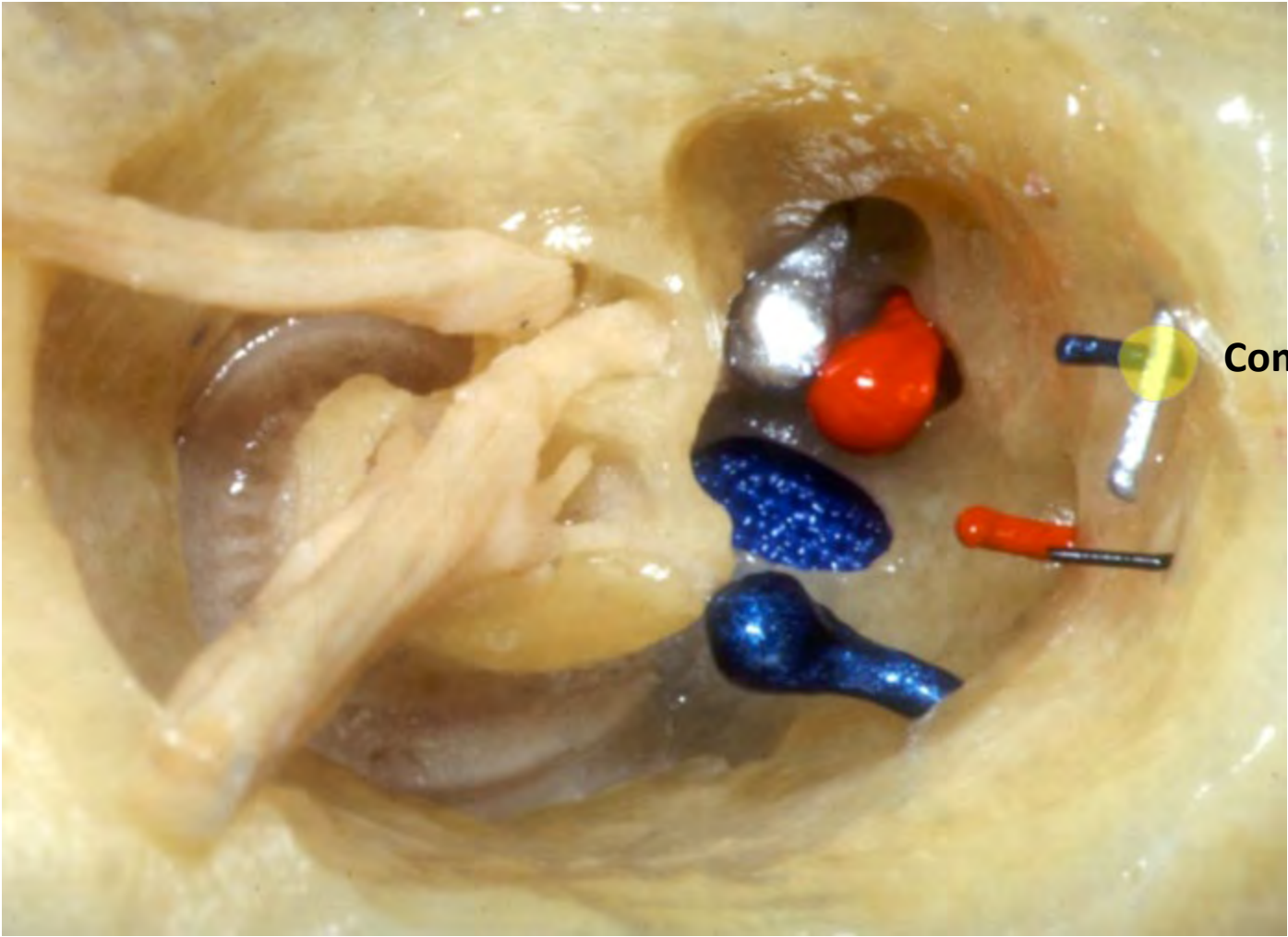


**Ampulla of superior semicircular canal**

**Ampulla of lateral semicircular canal**

**Ampulla of posterior semicircular canal**

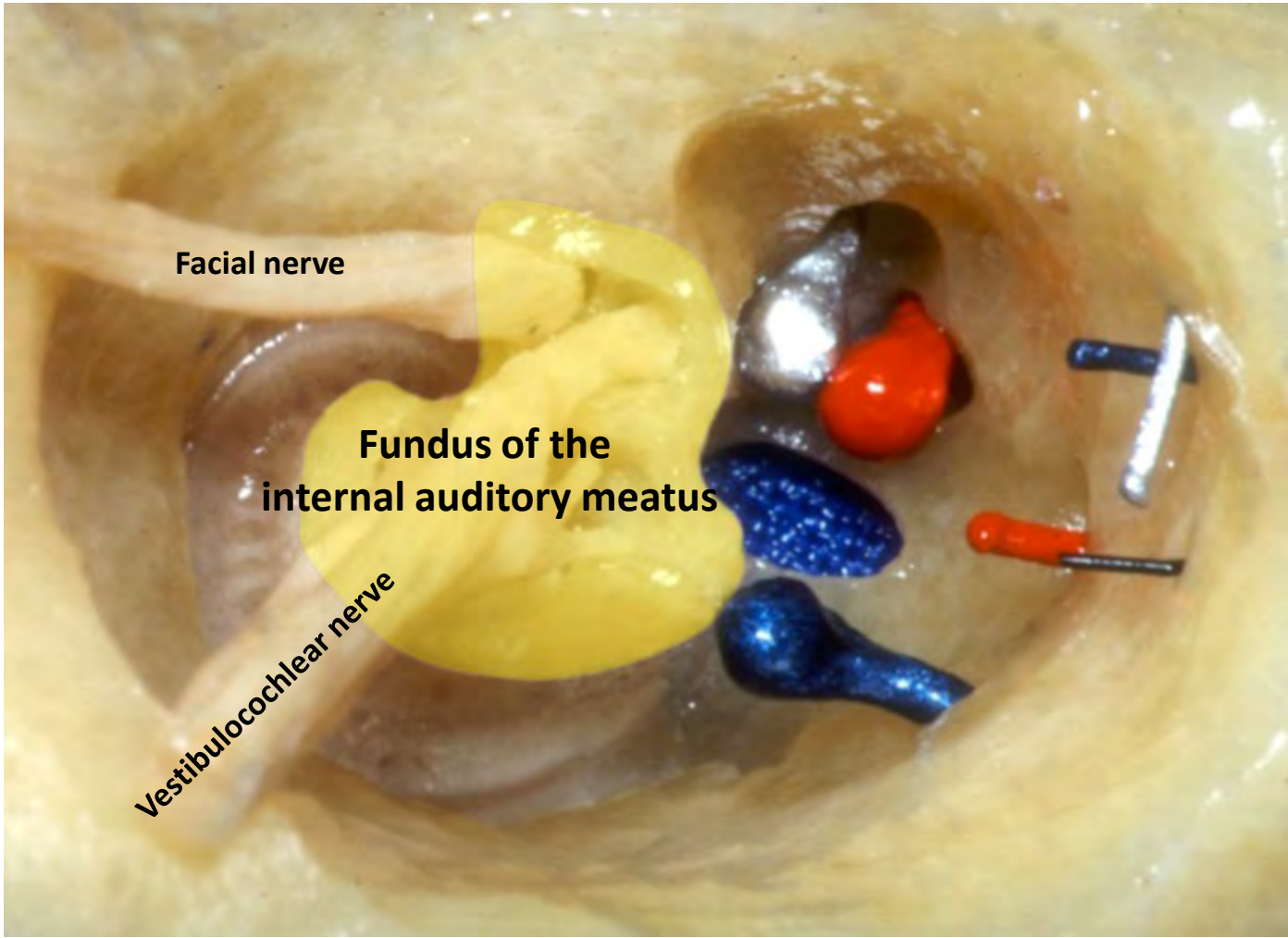
PHOTON



Common crus



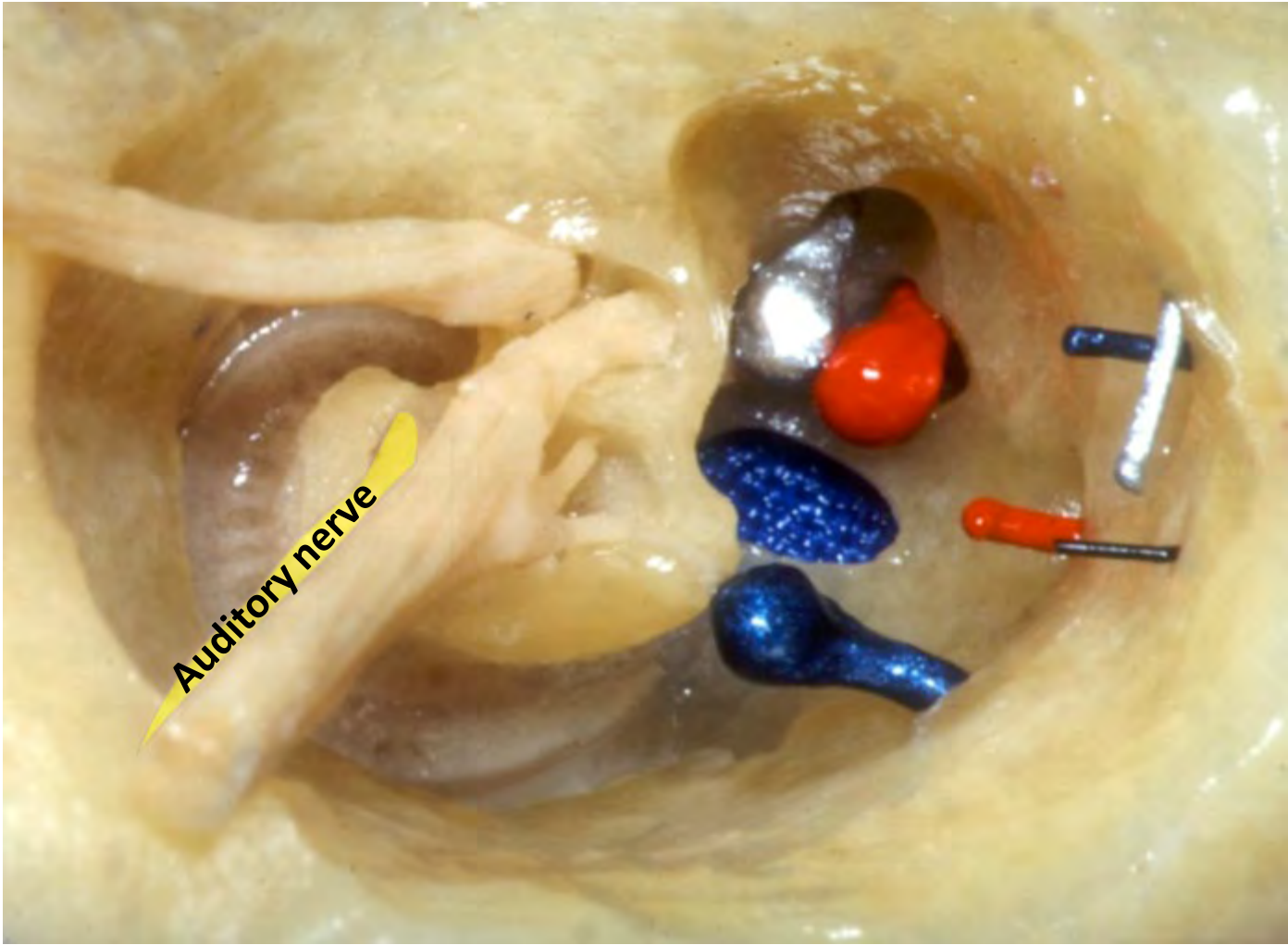




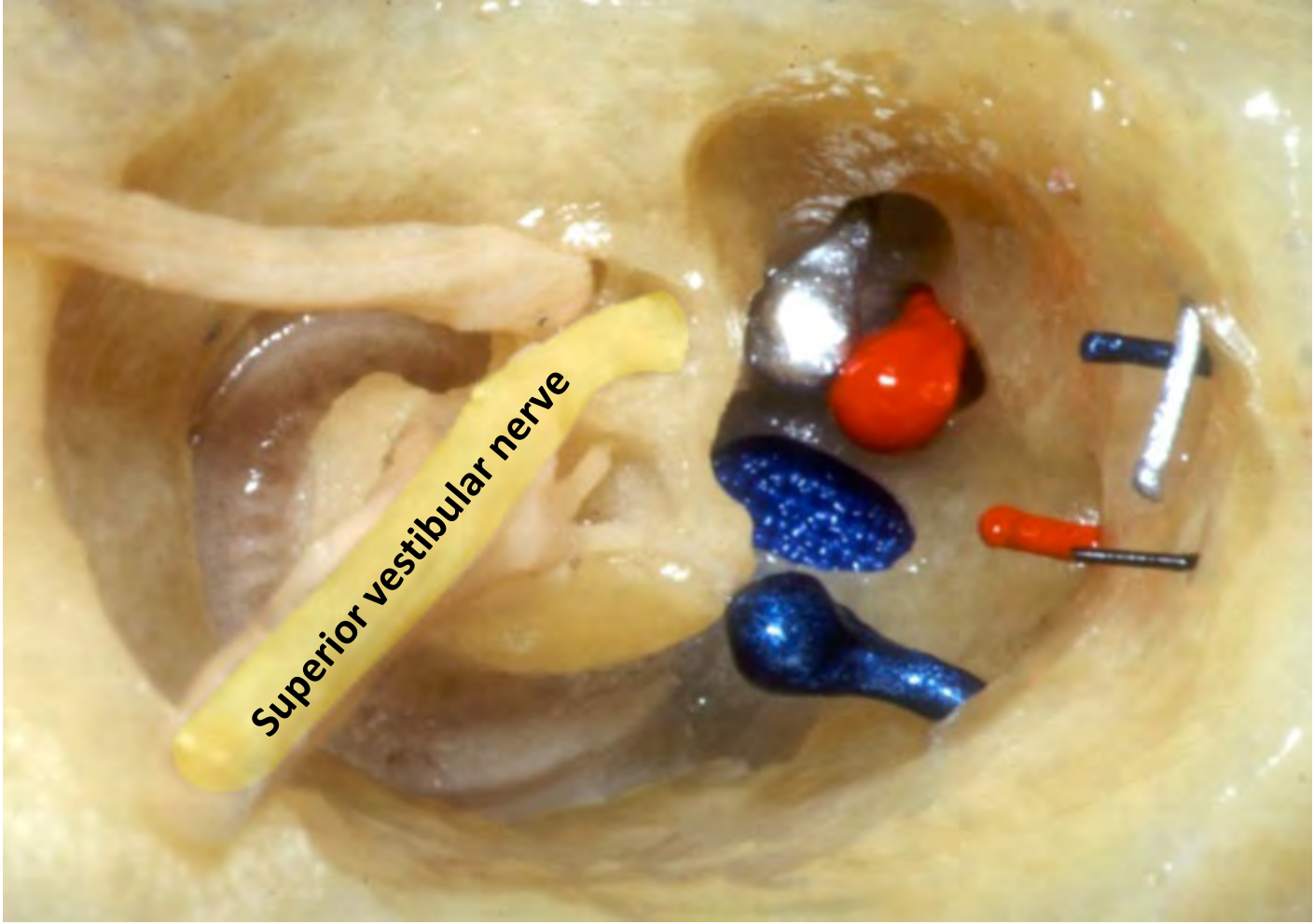
Facial nerve

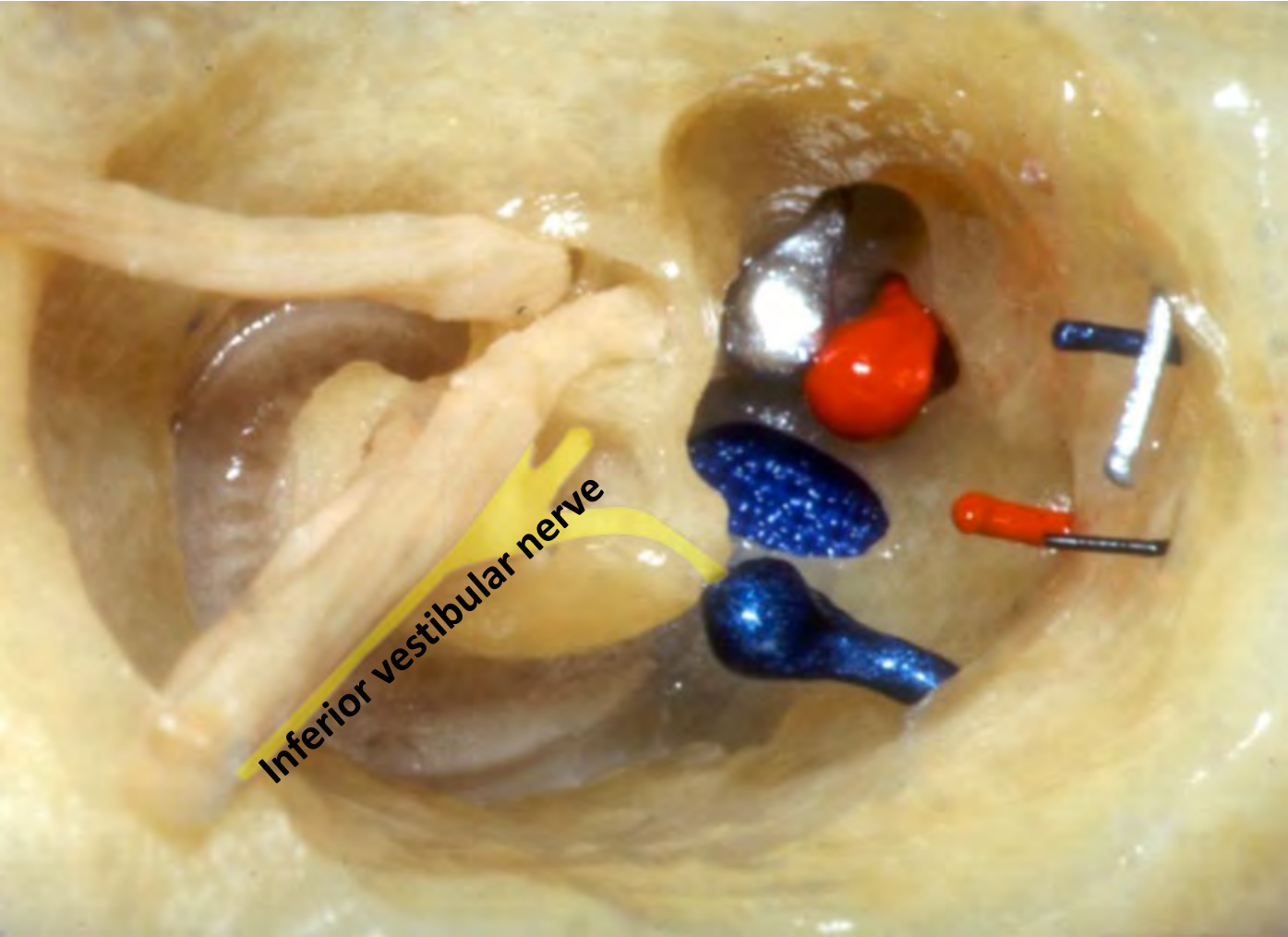
Fundus of the  
internal auditory meatus

Vestibulocochlear nerve

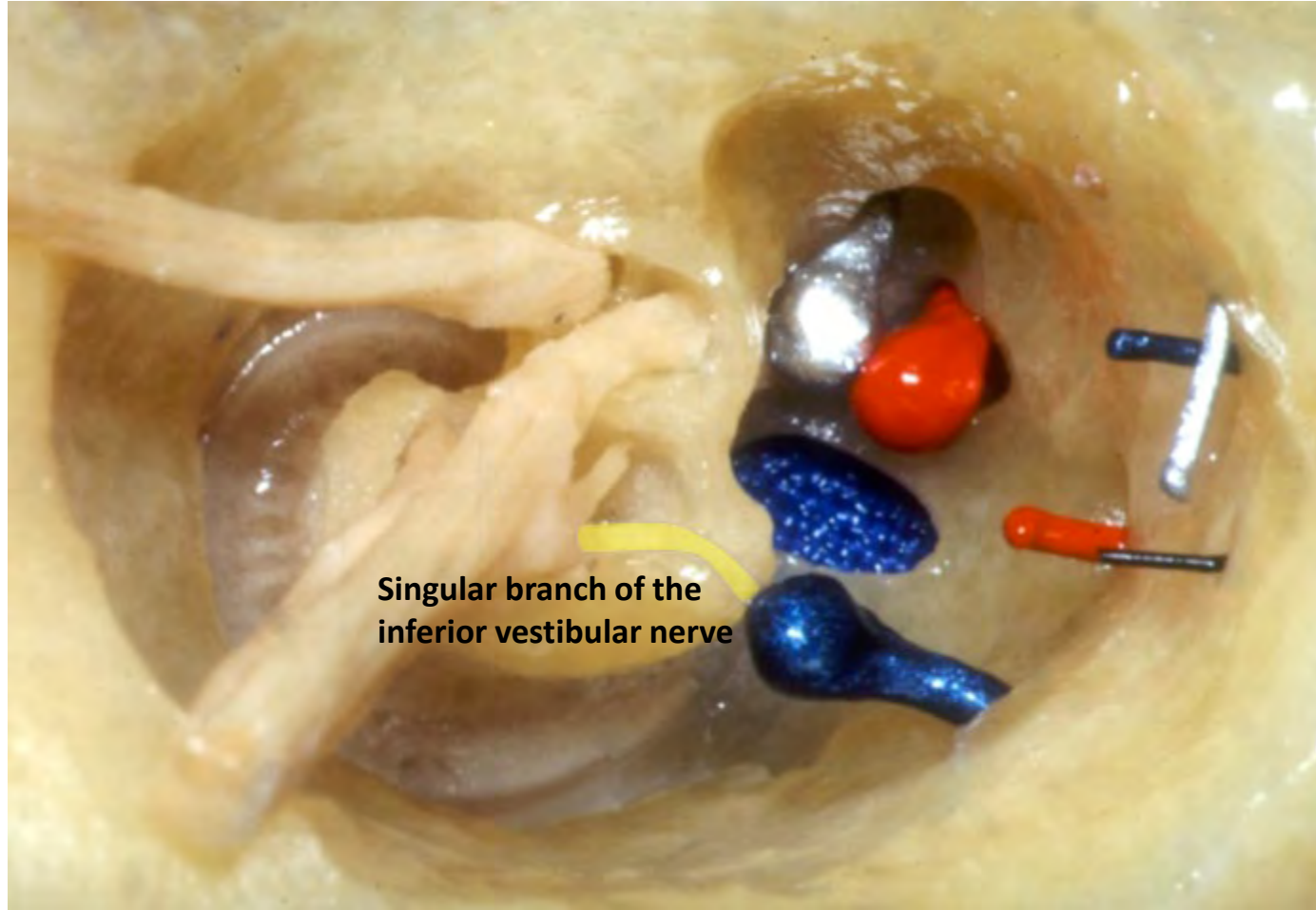


Auditory nerve

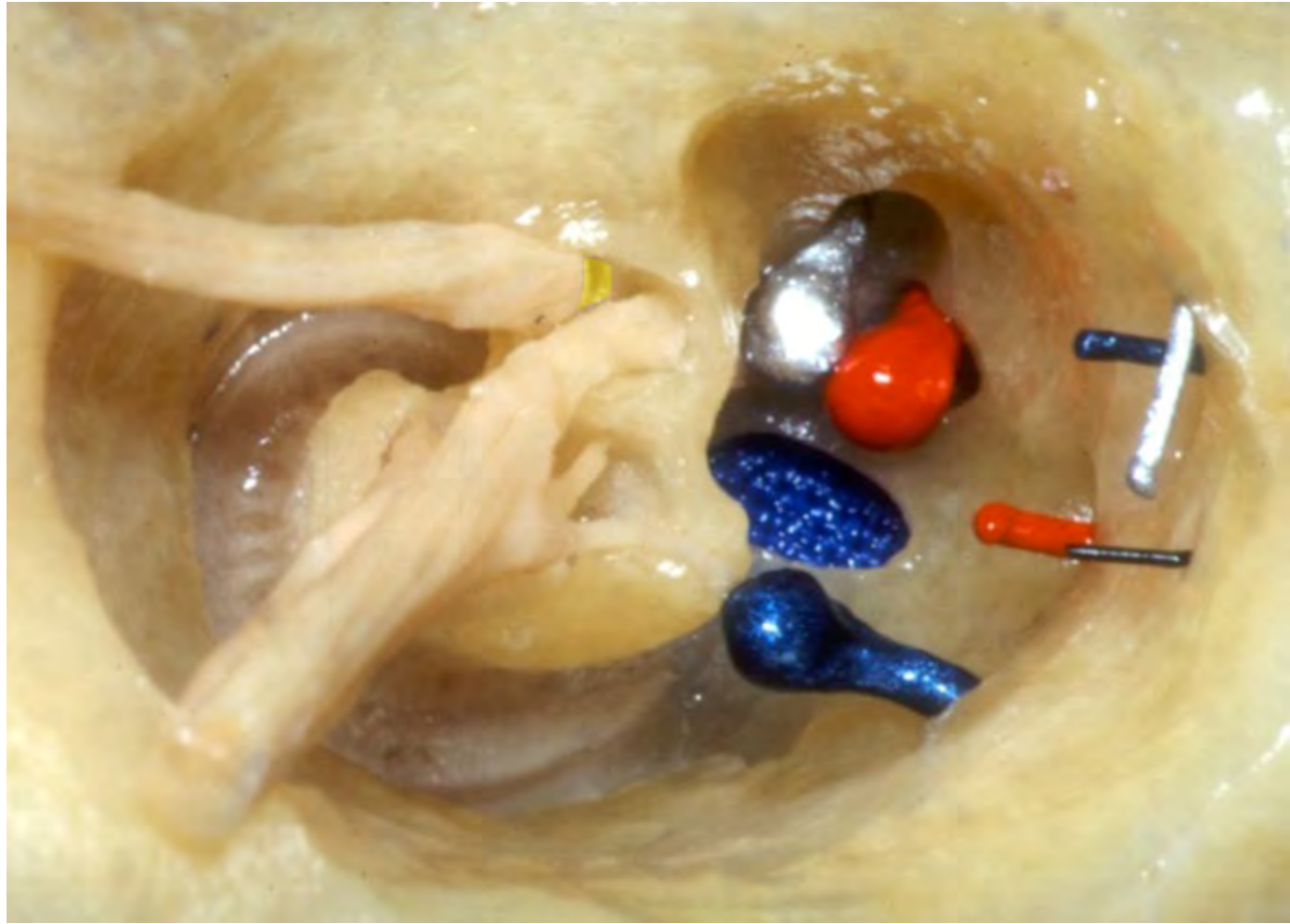


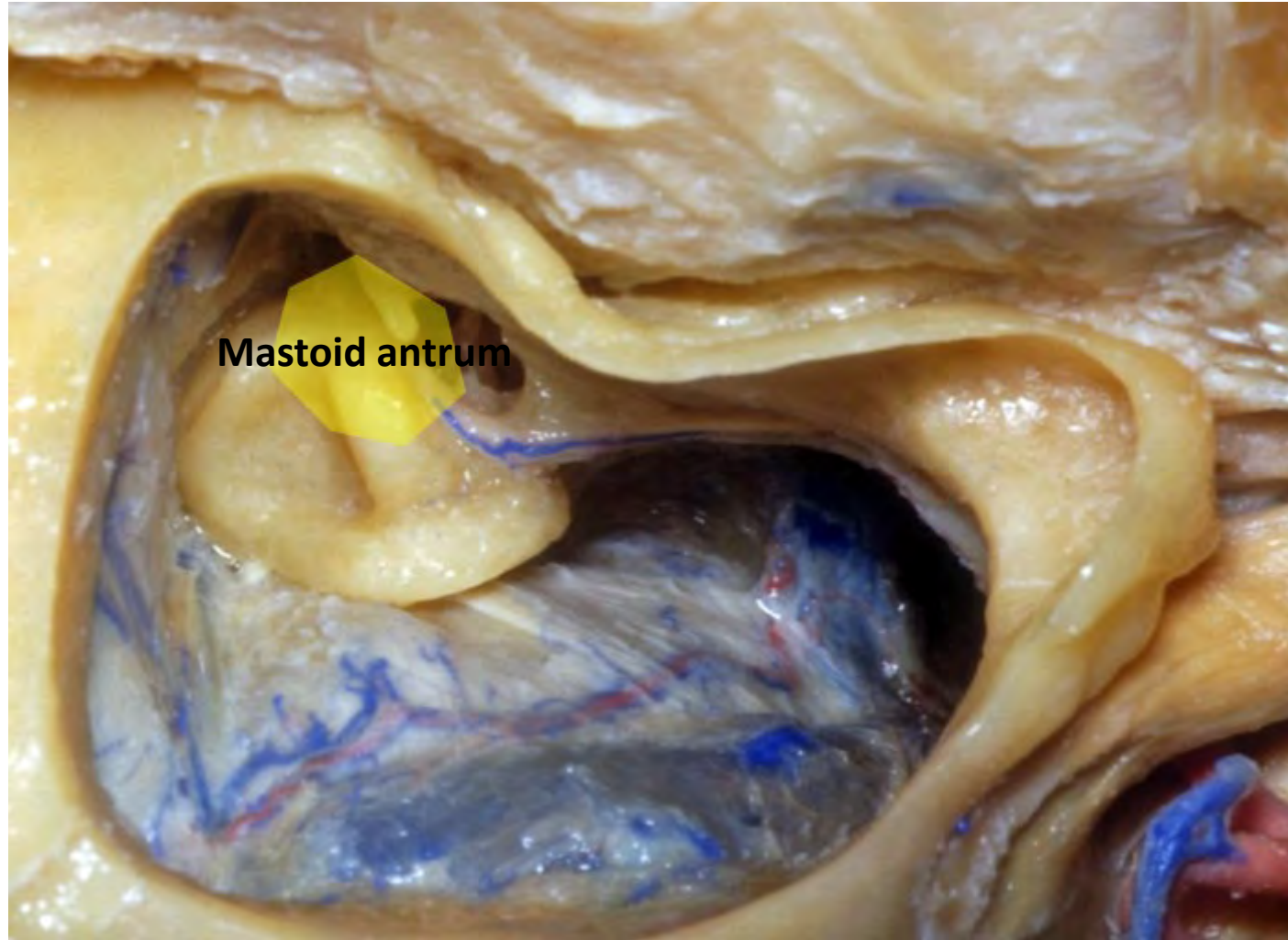


Inferior vestibular nerve

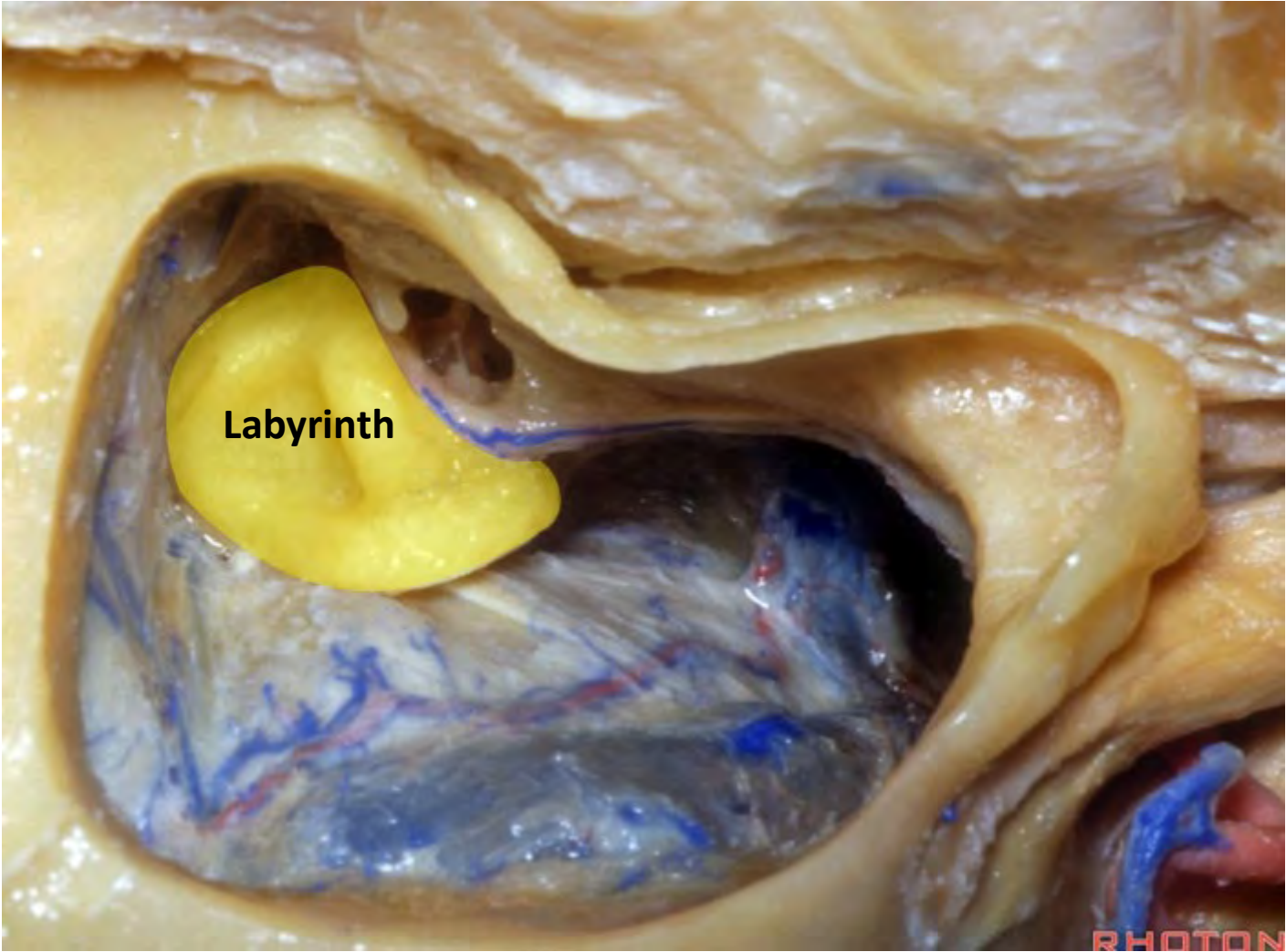


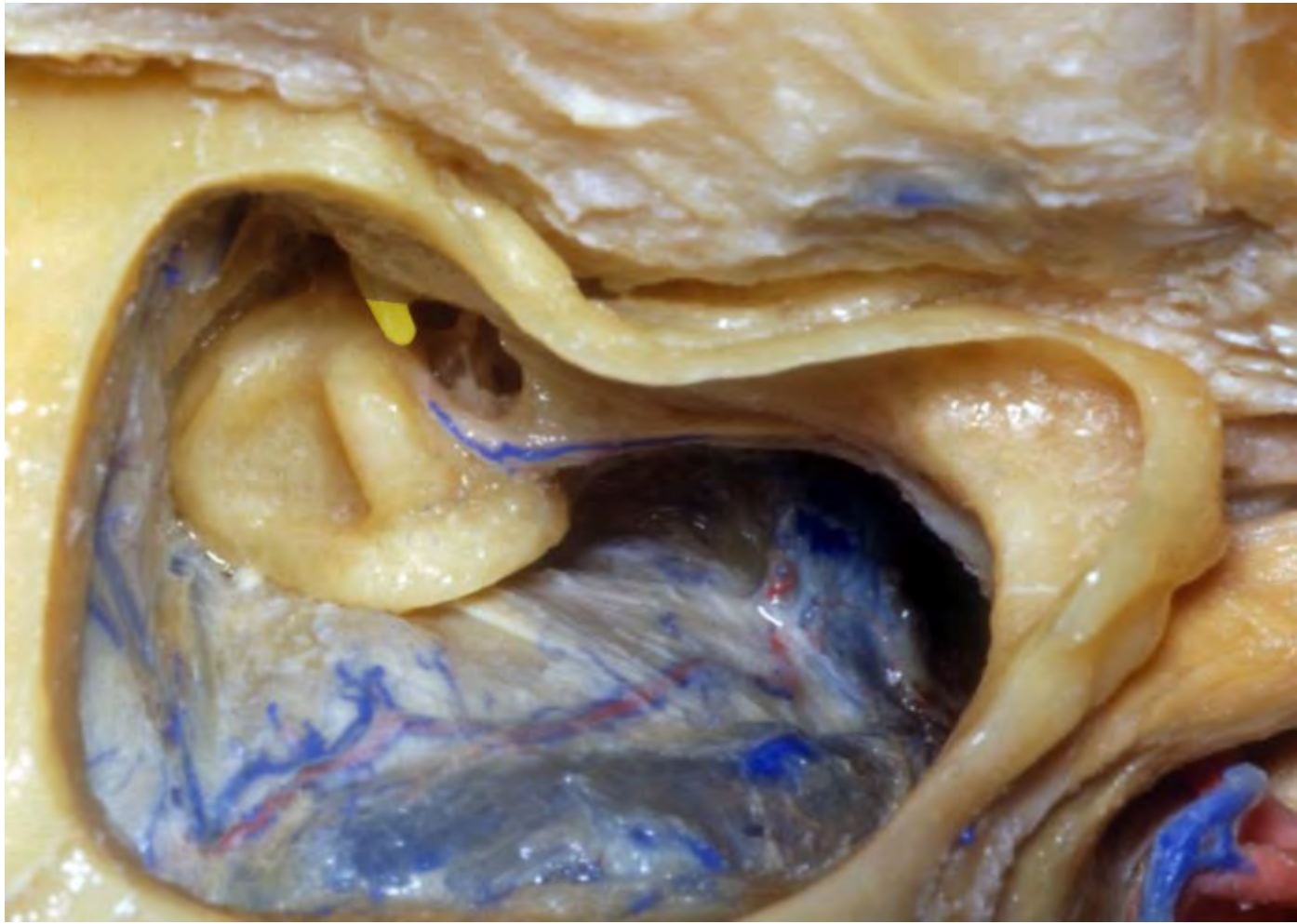
Singular branch of the inferior vestibular nerve

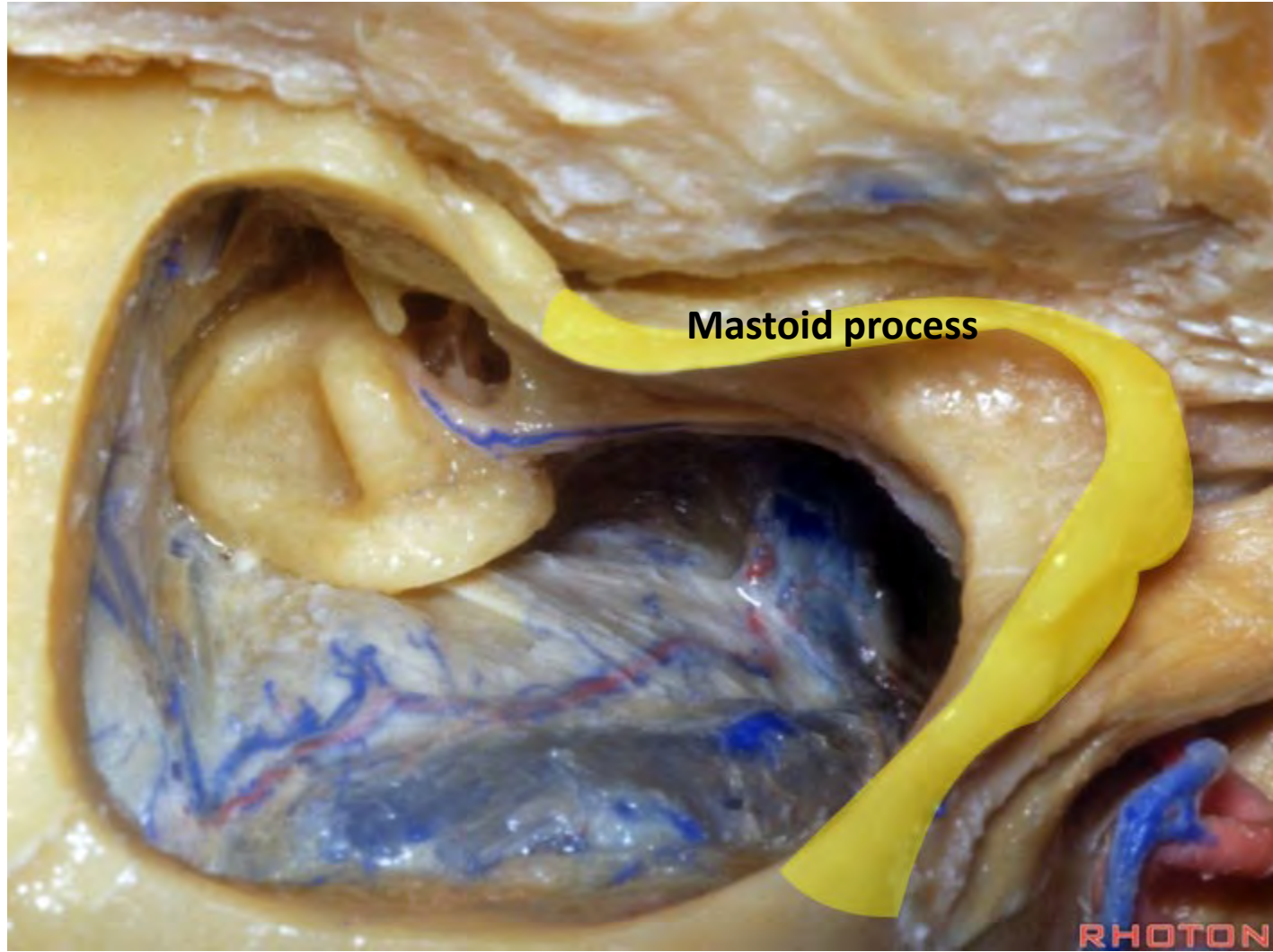






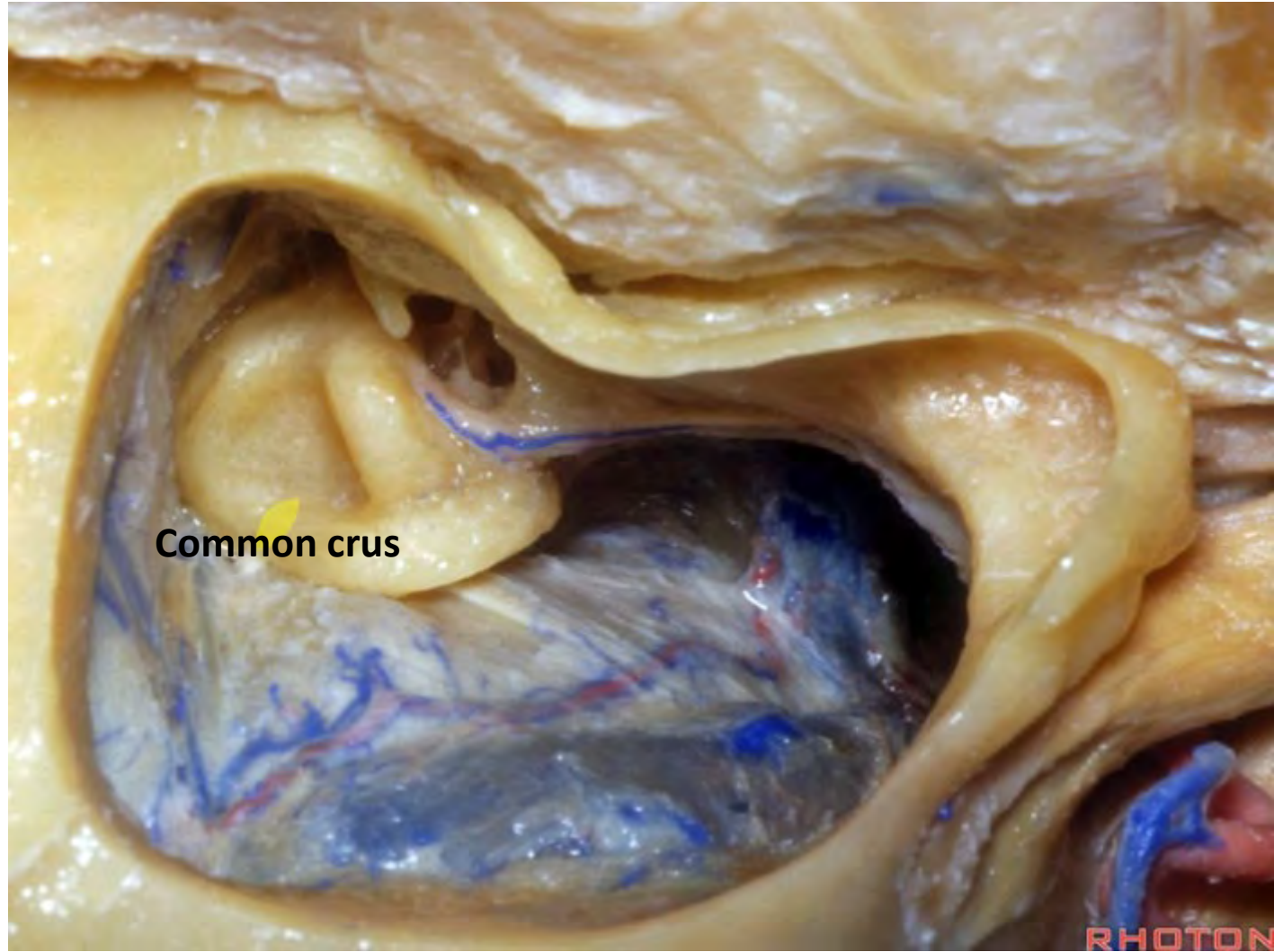






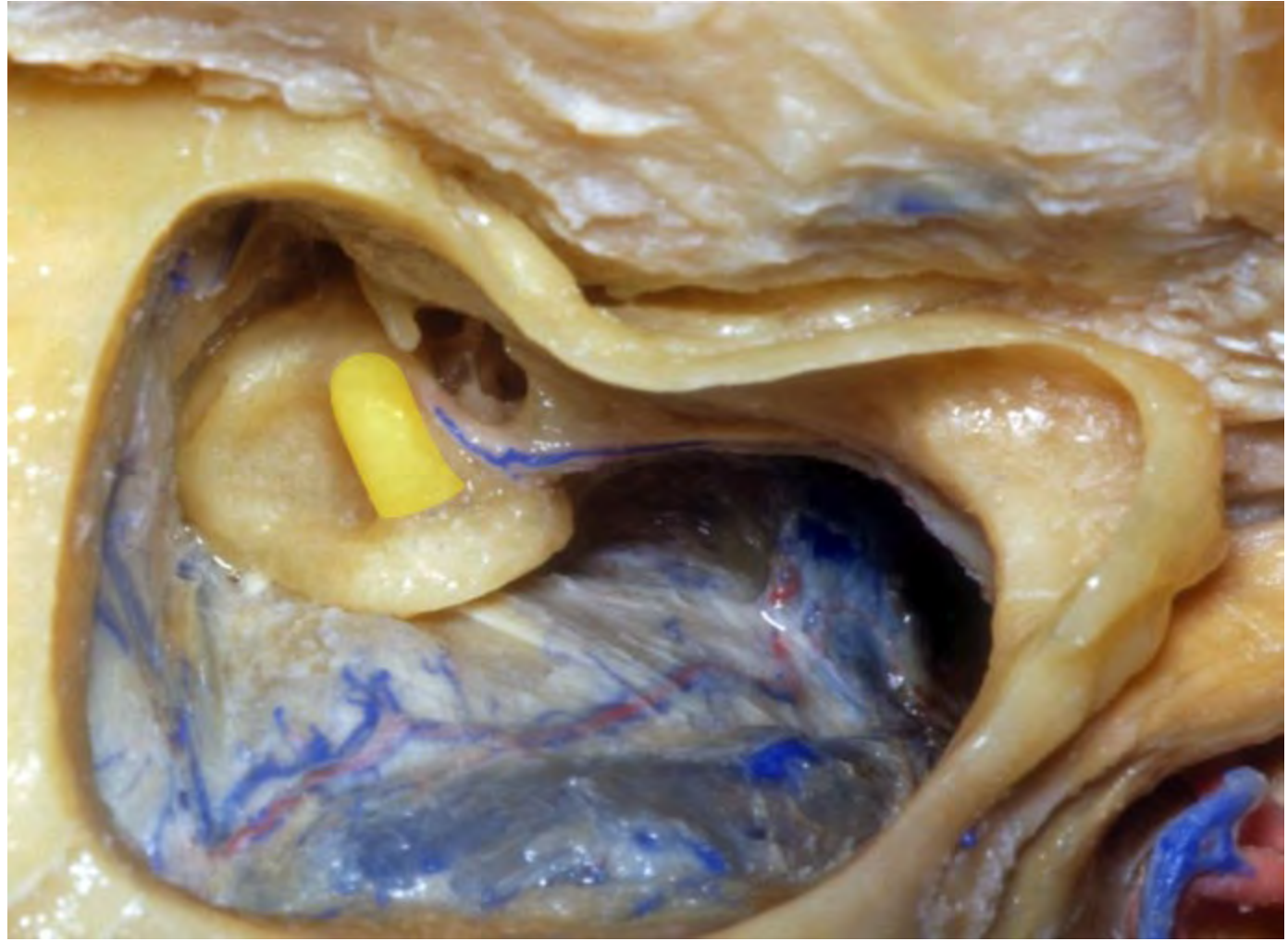
Mastoid process

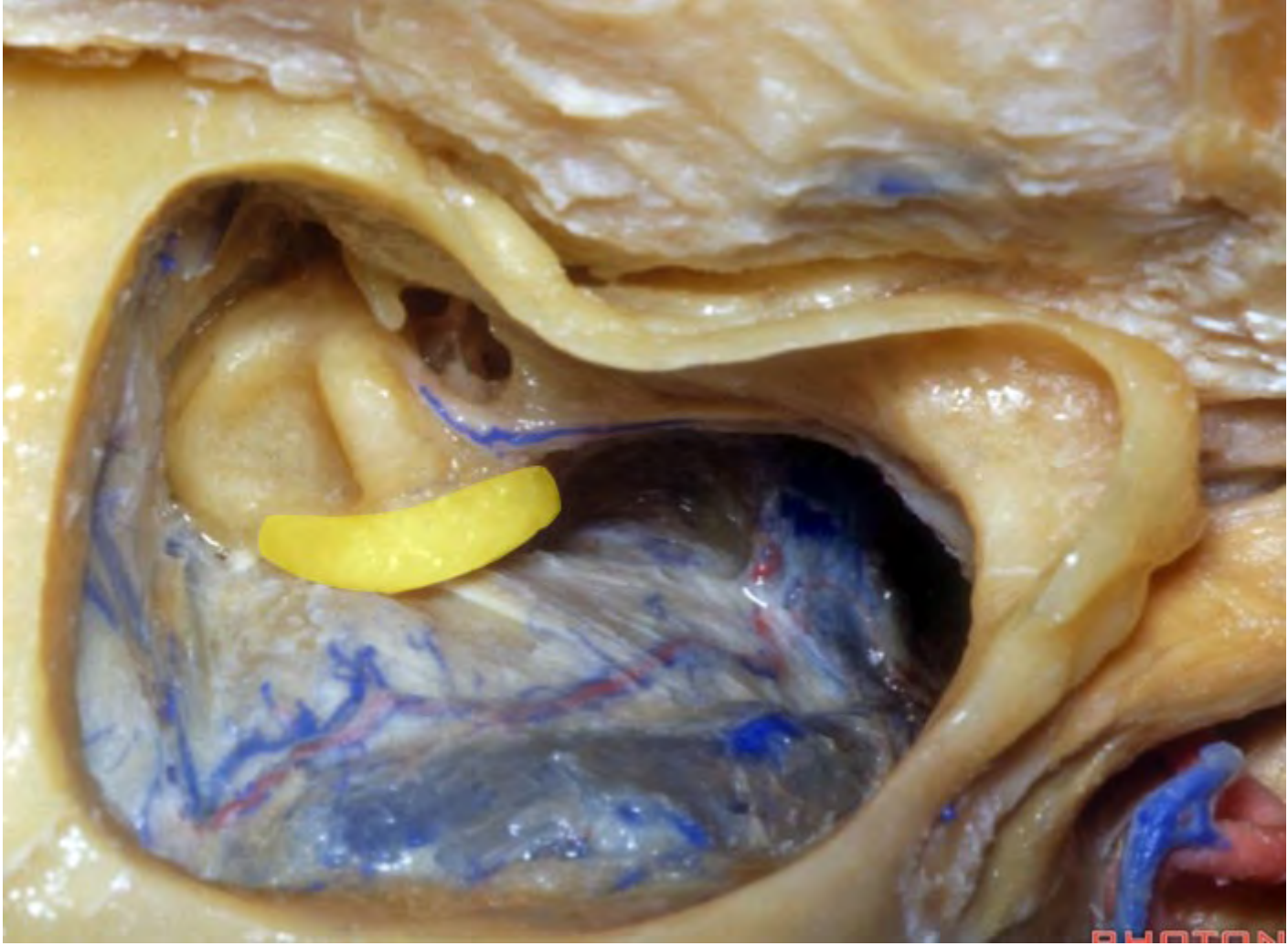
RHOTON



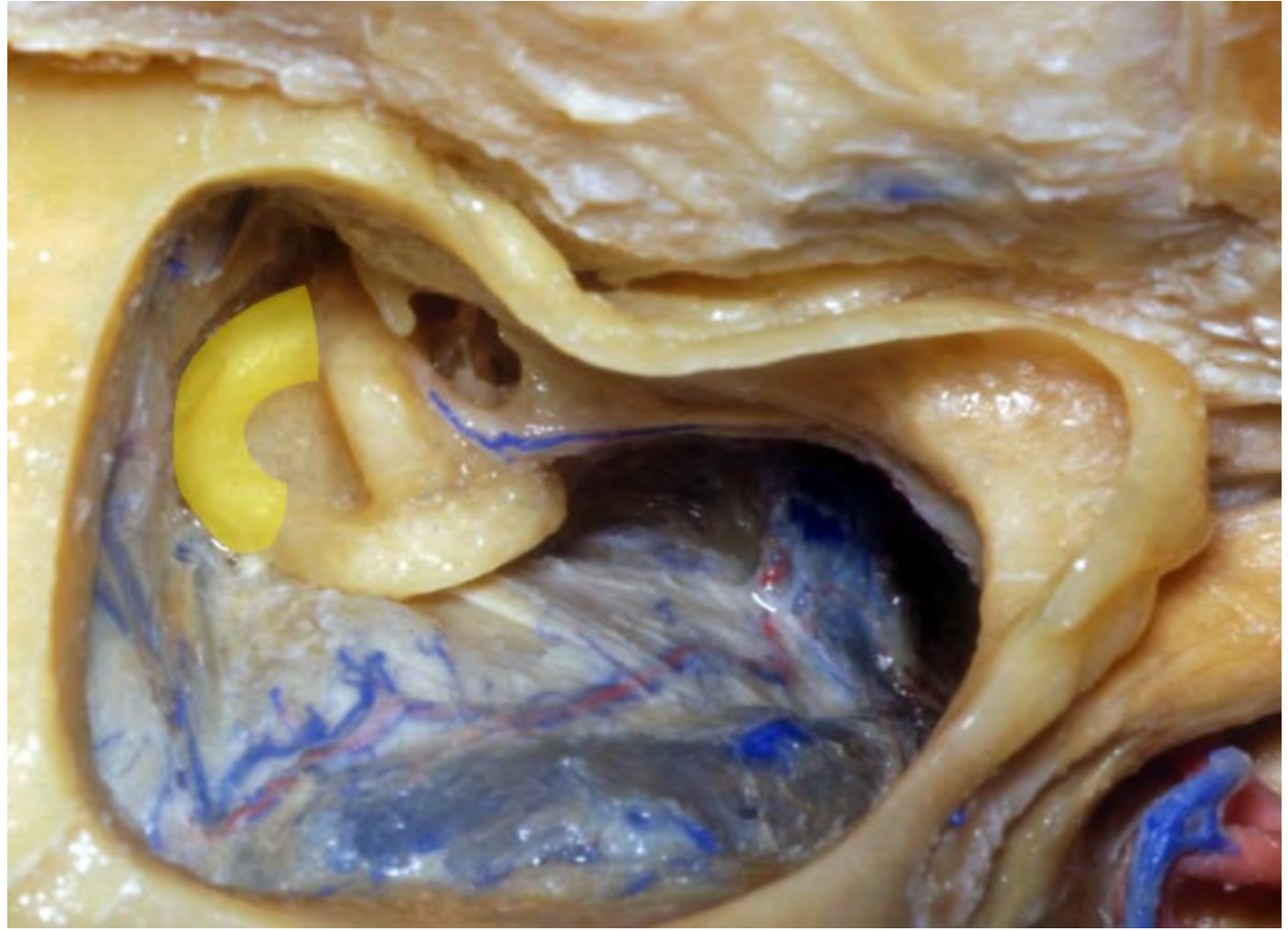
Common crus

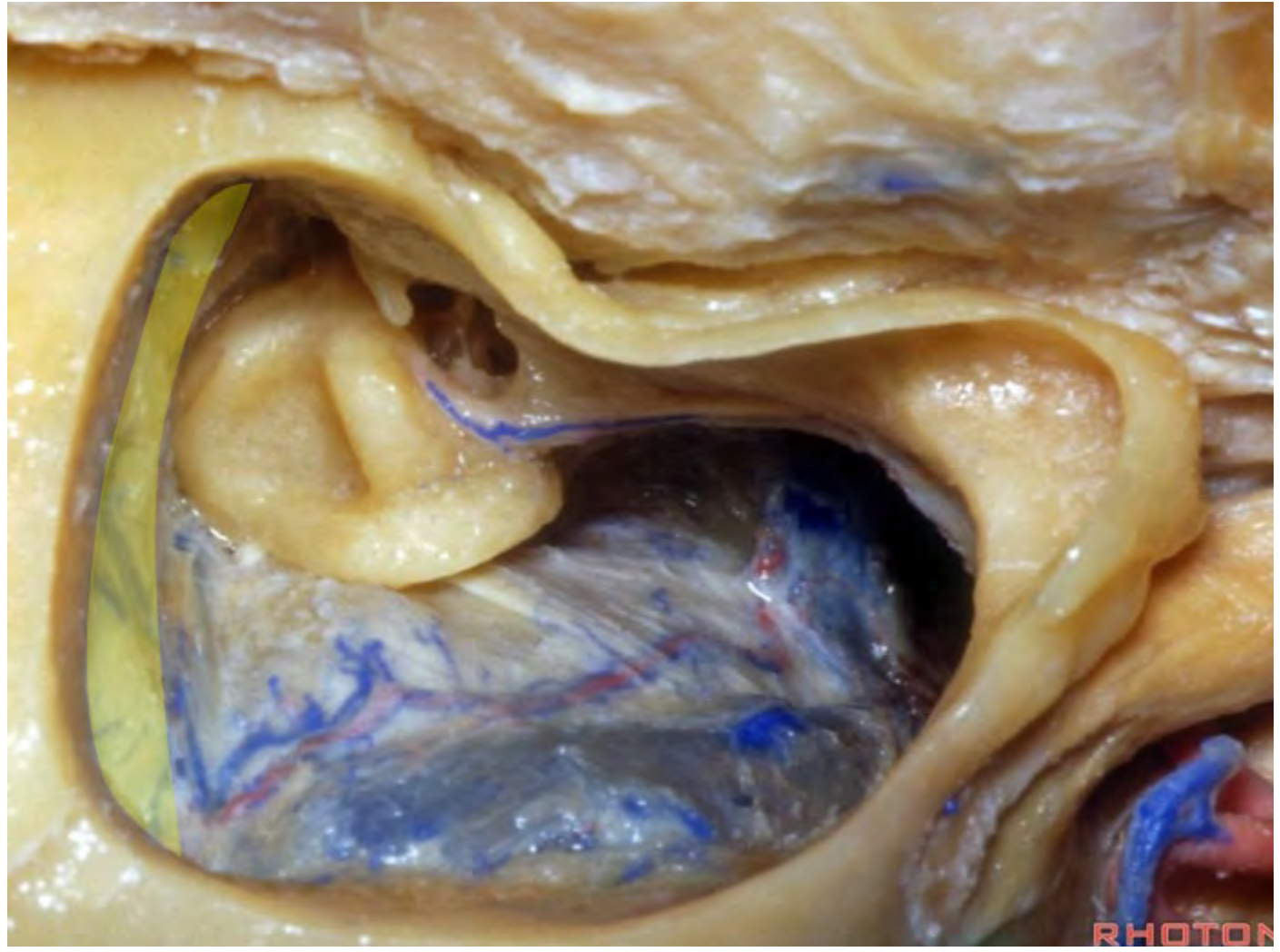RHOTON



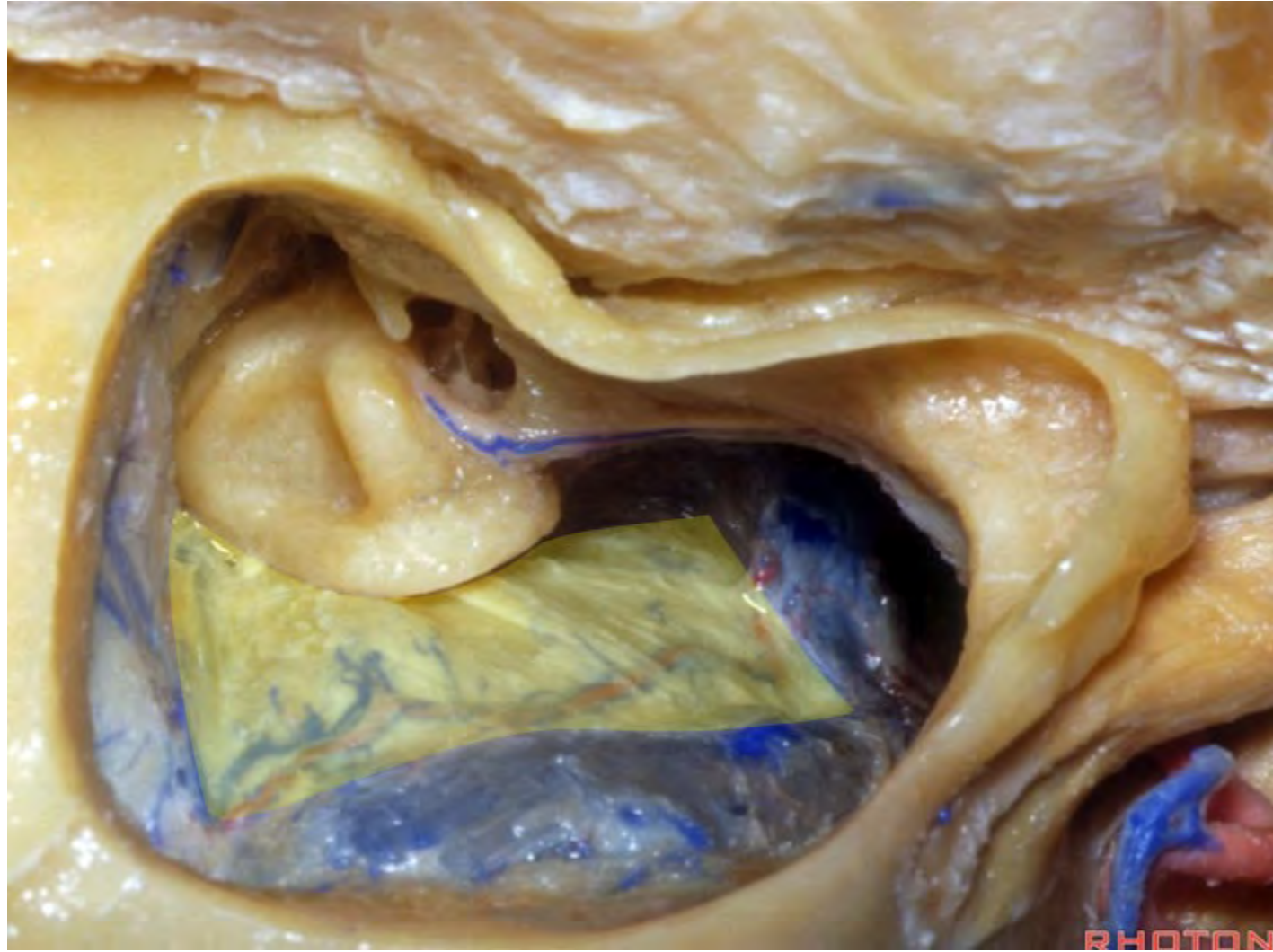


PHOTO



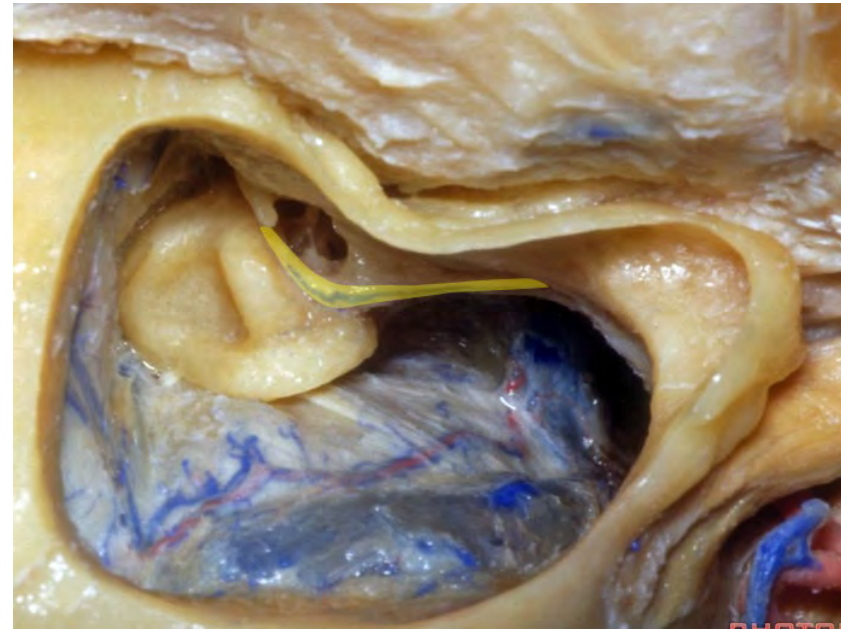




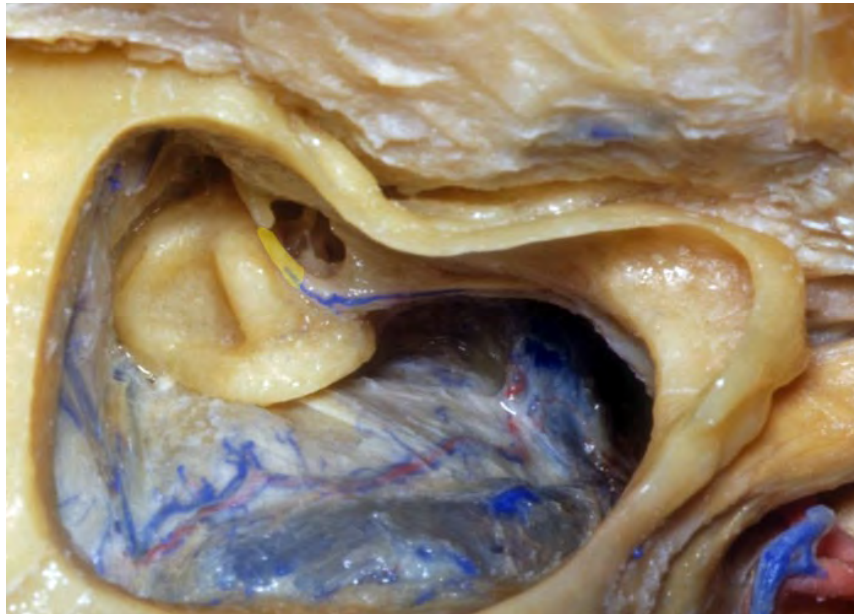



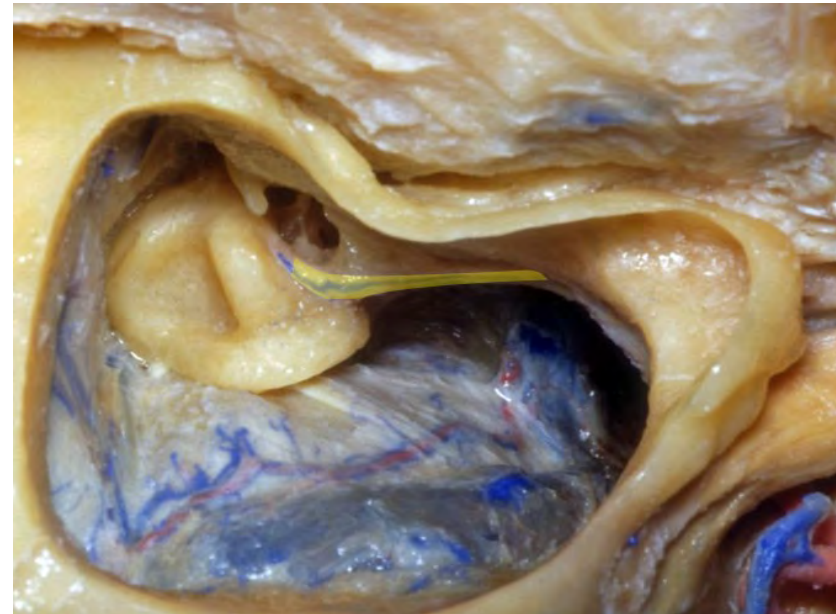
# Facial nerve

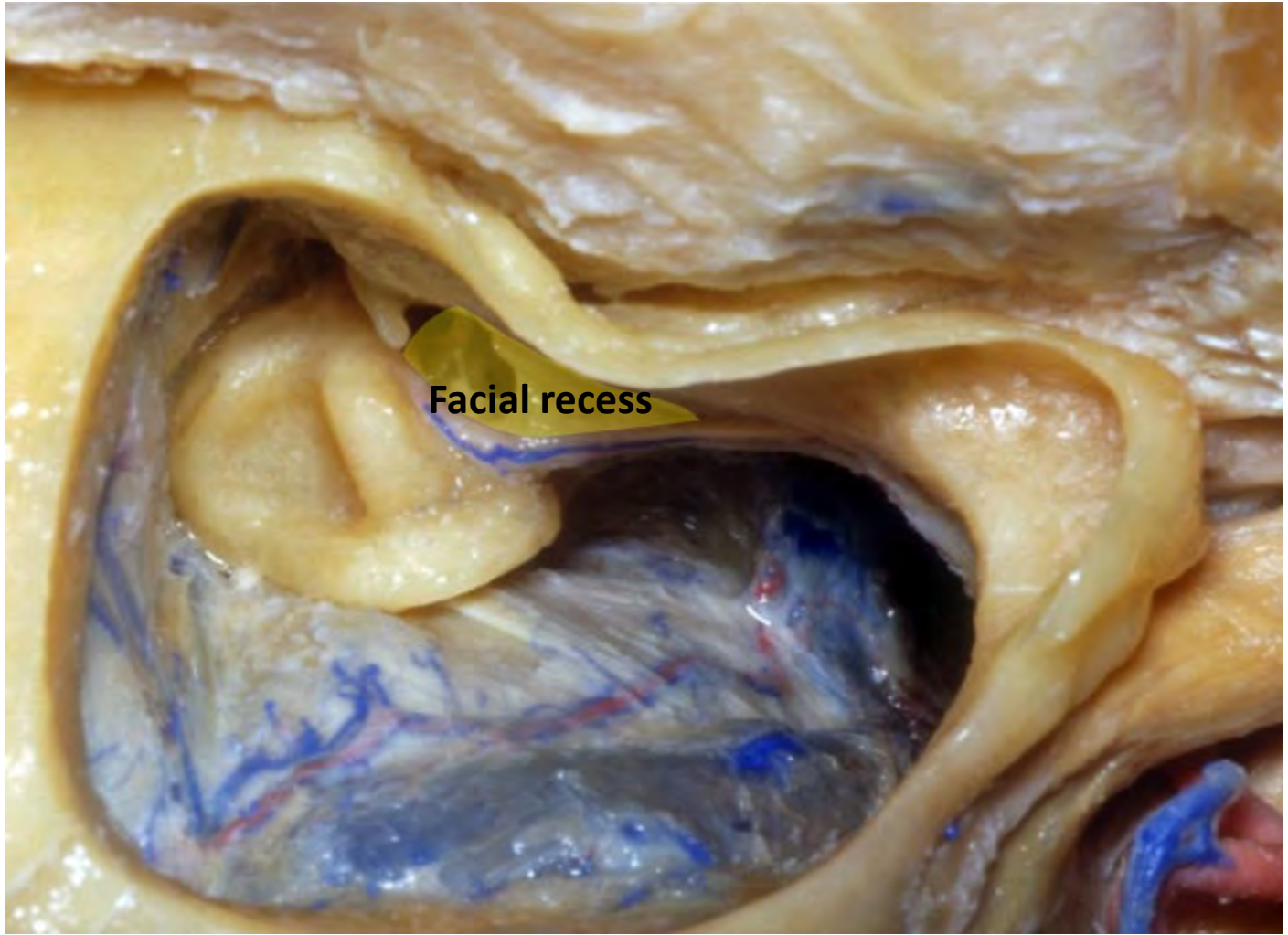


## Tympanic segment of facial nerve

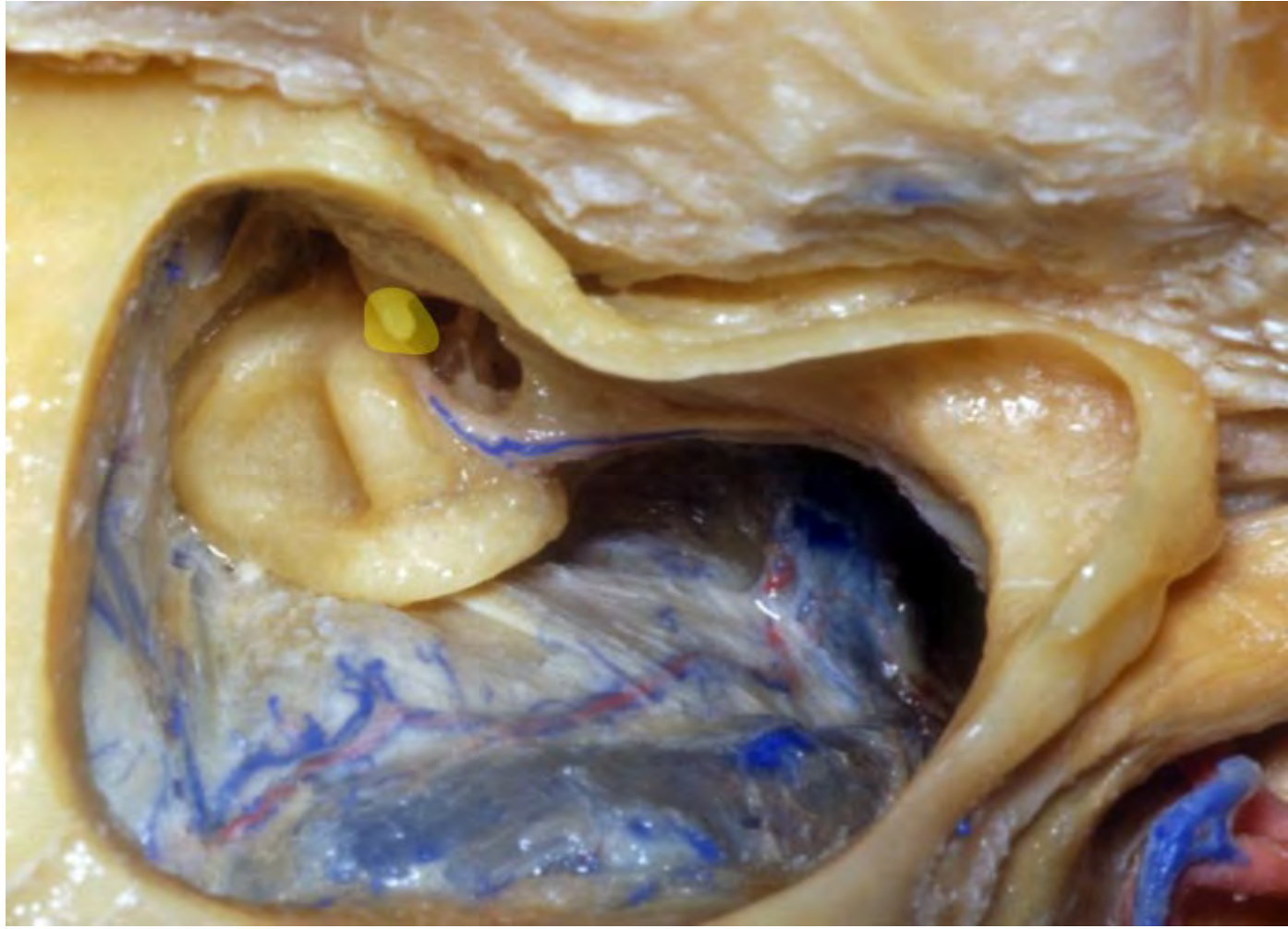


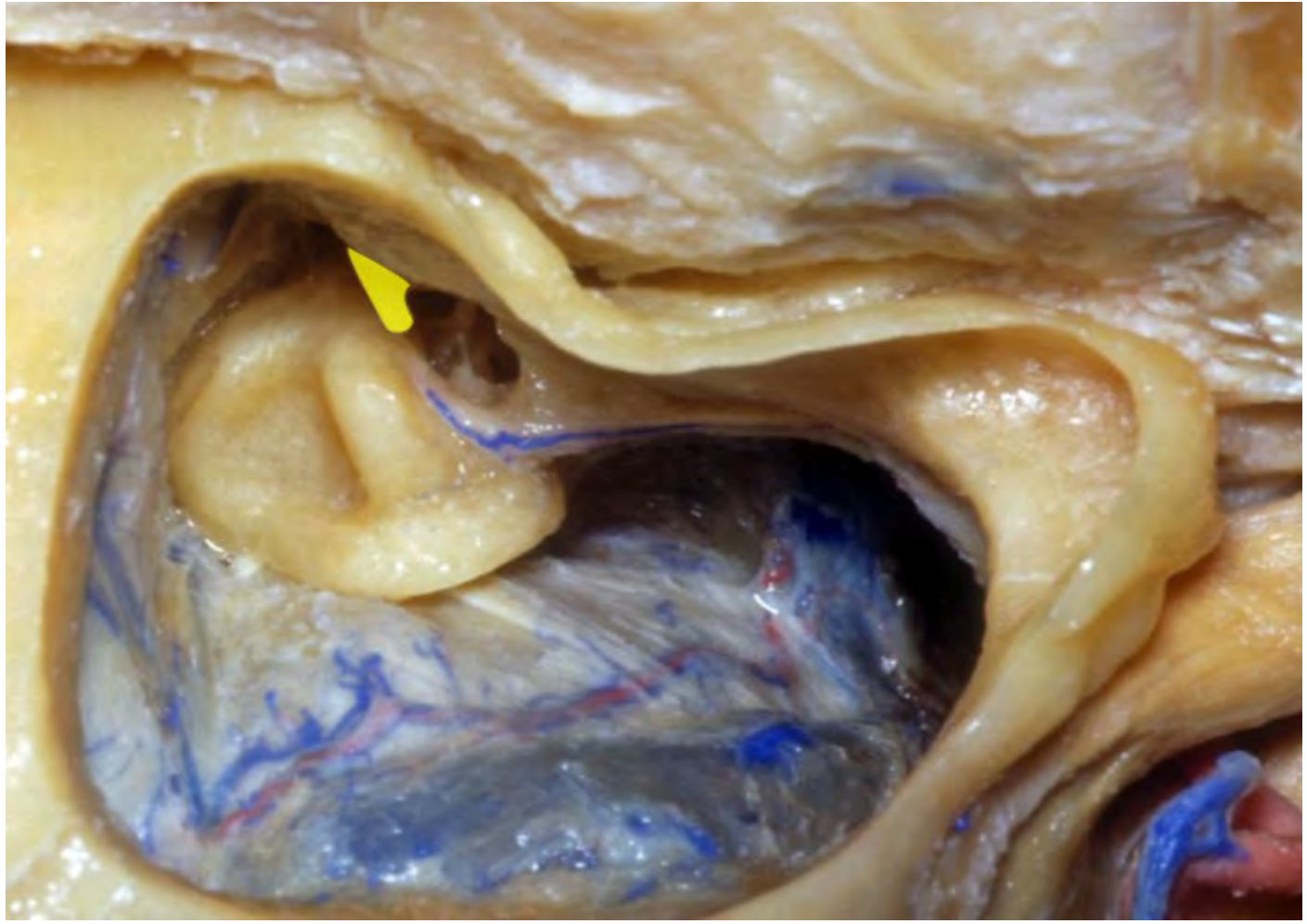
## Mastoid segment of facial nerve

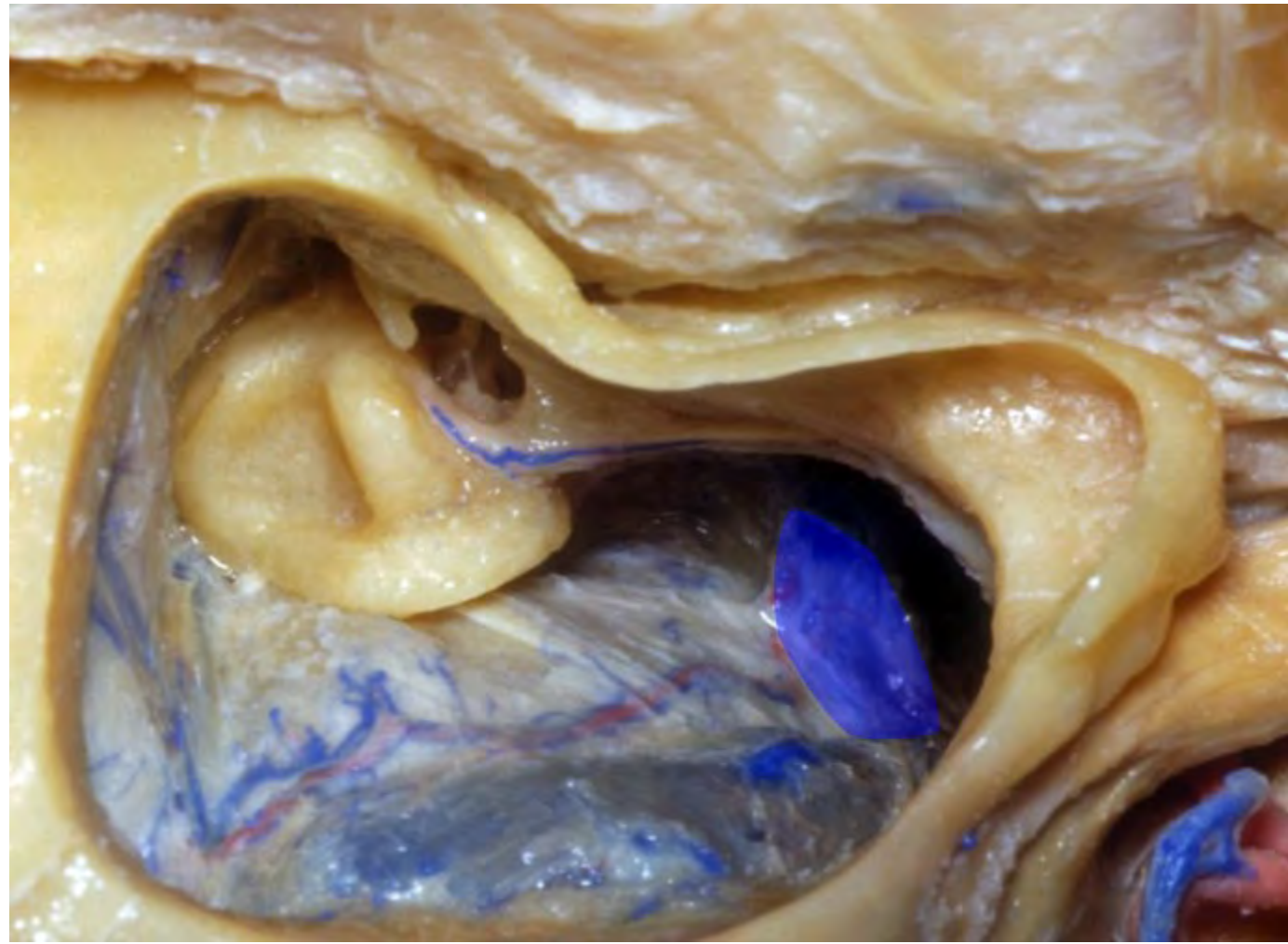


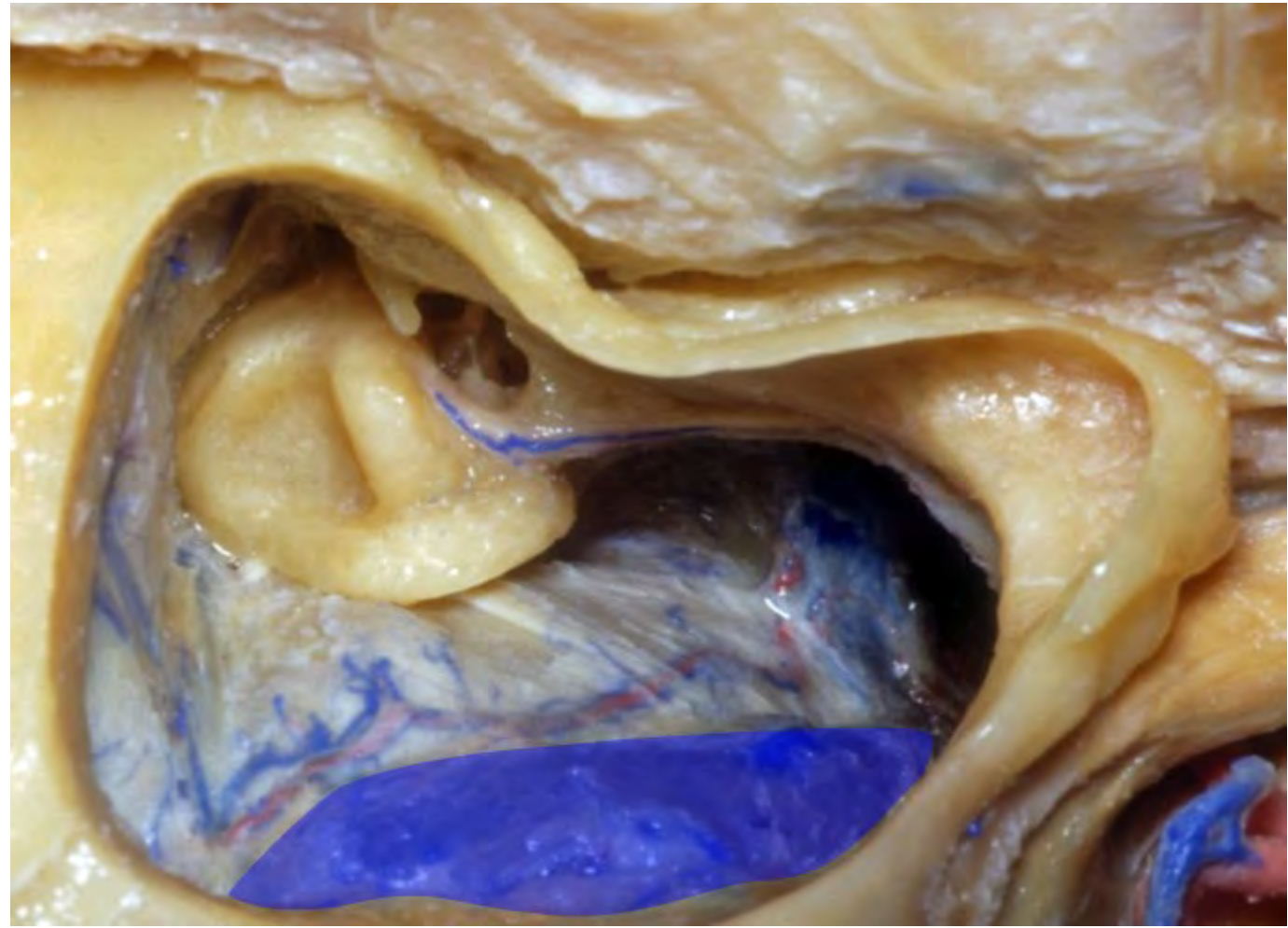


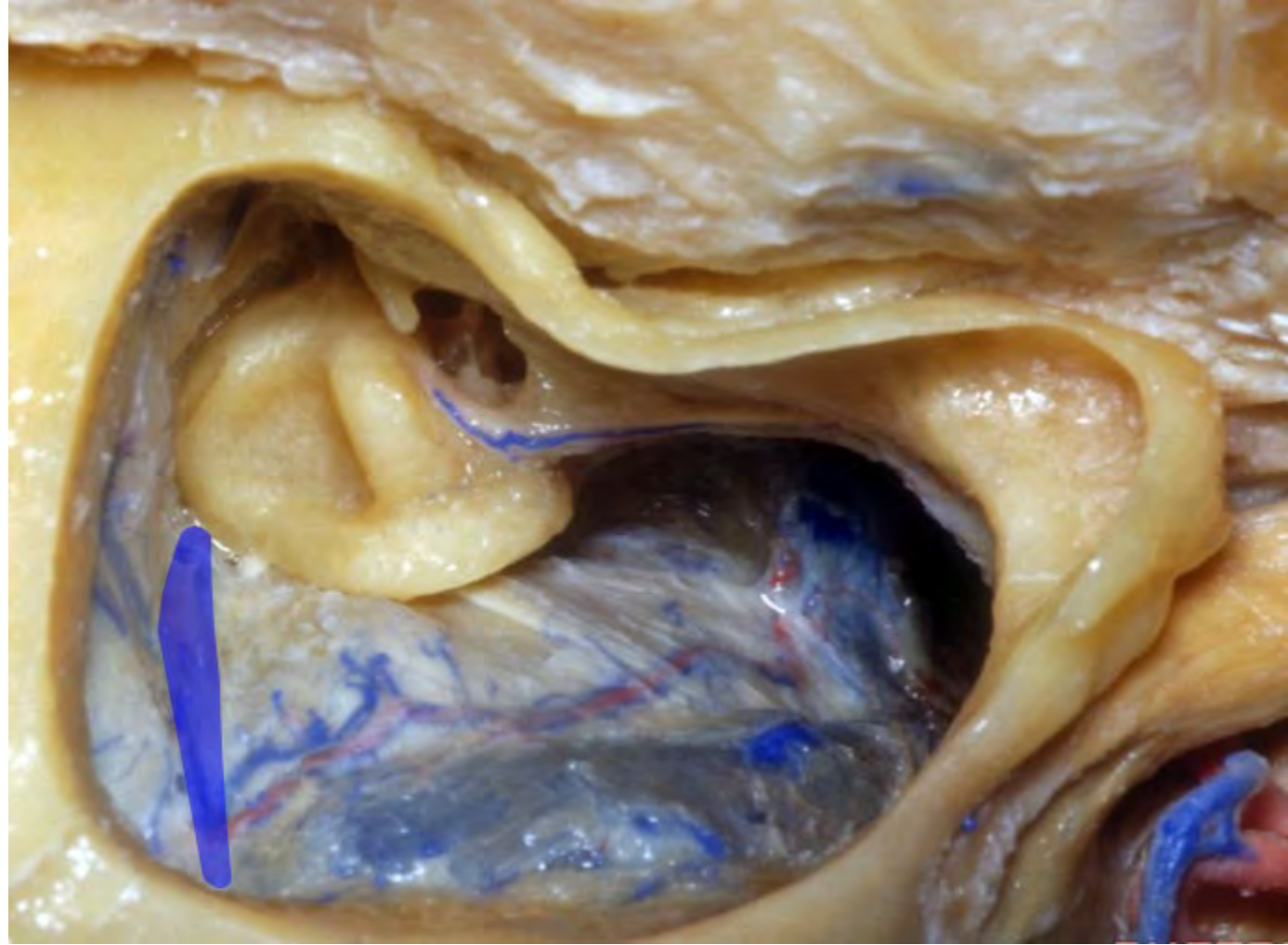Facial recess



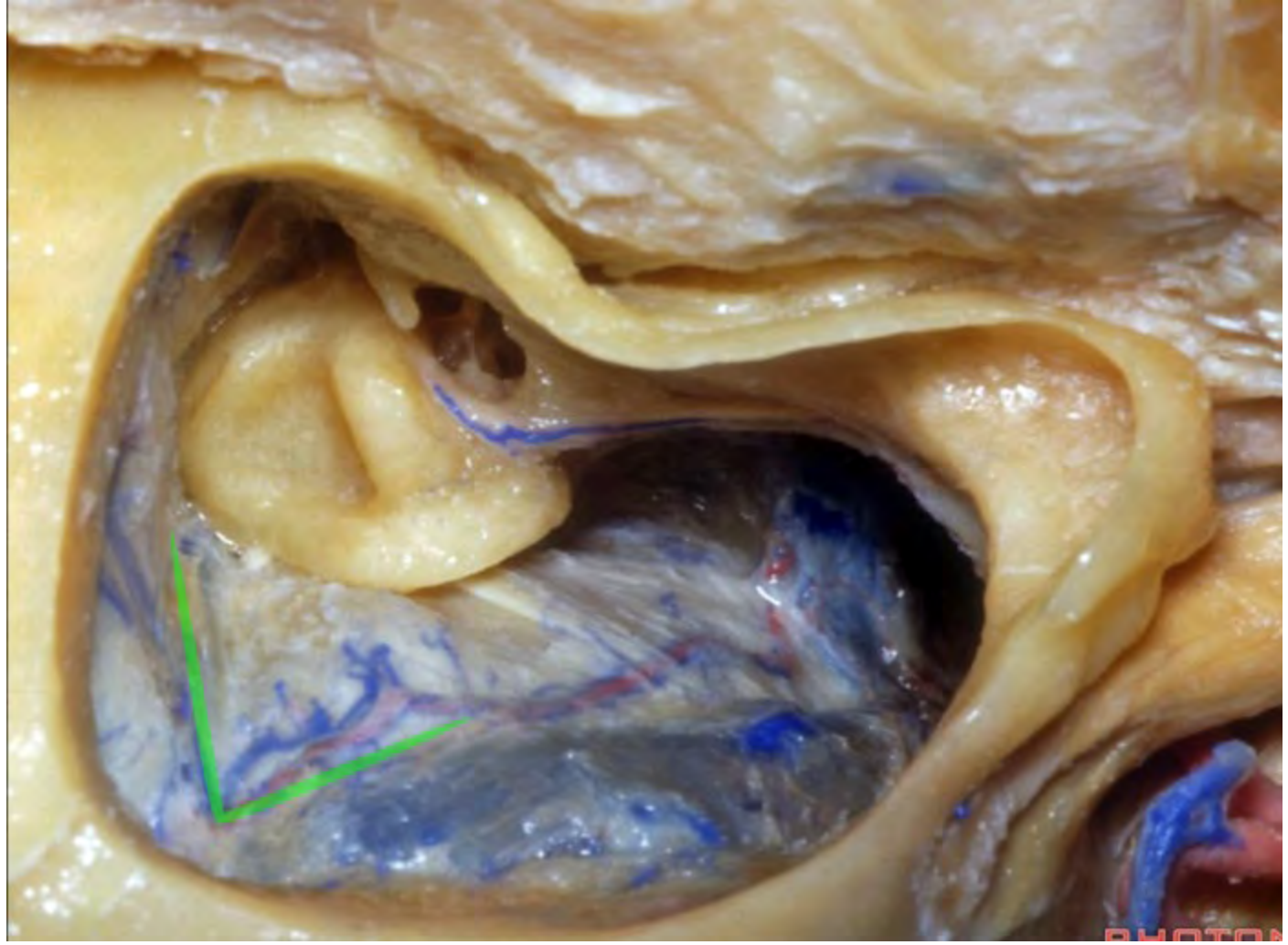




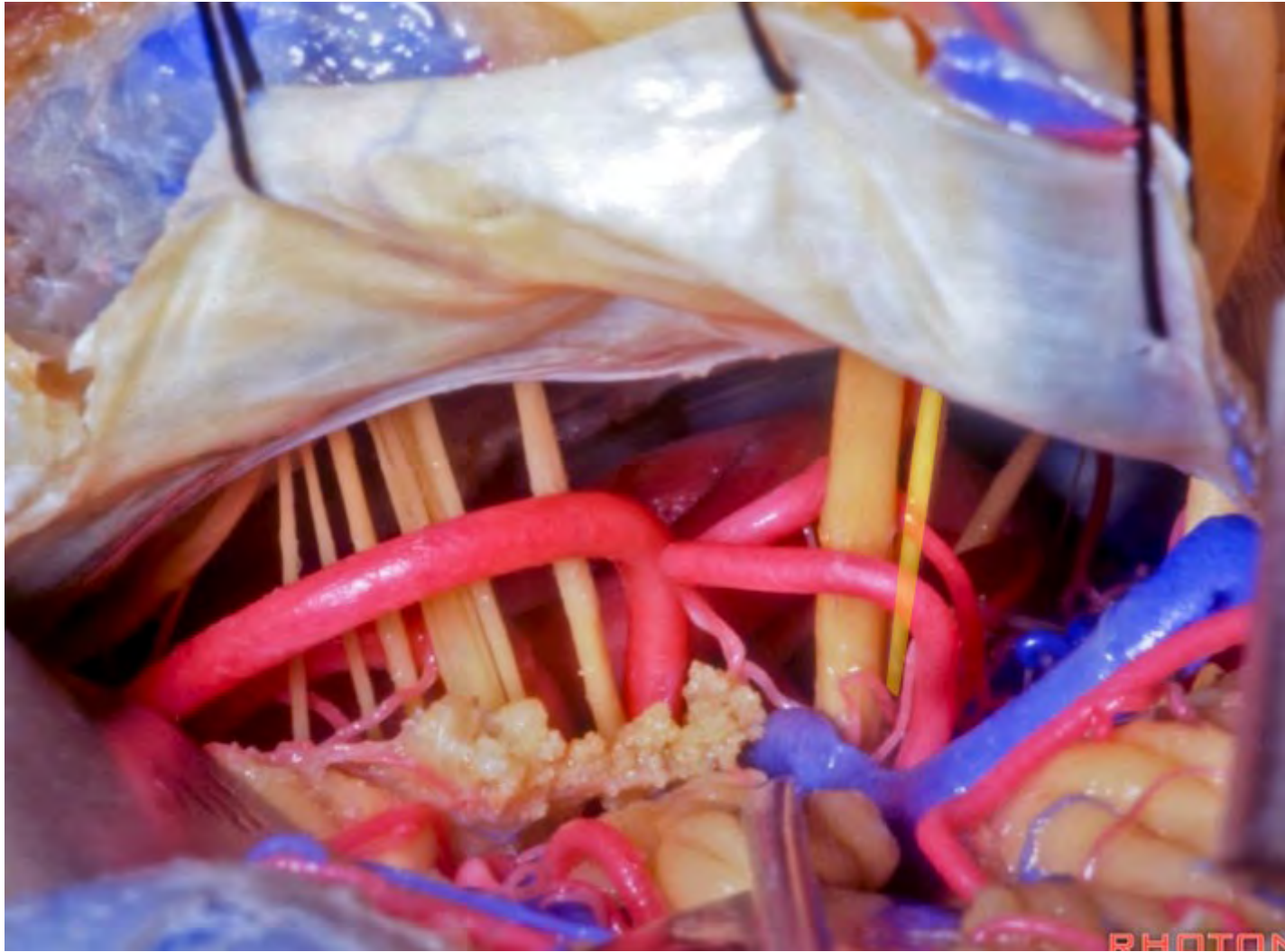


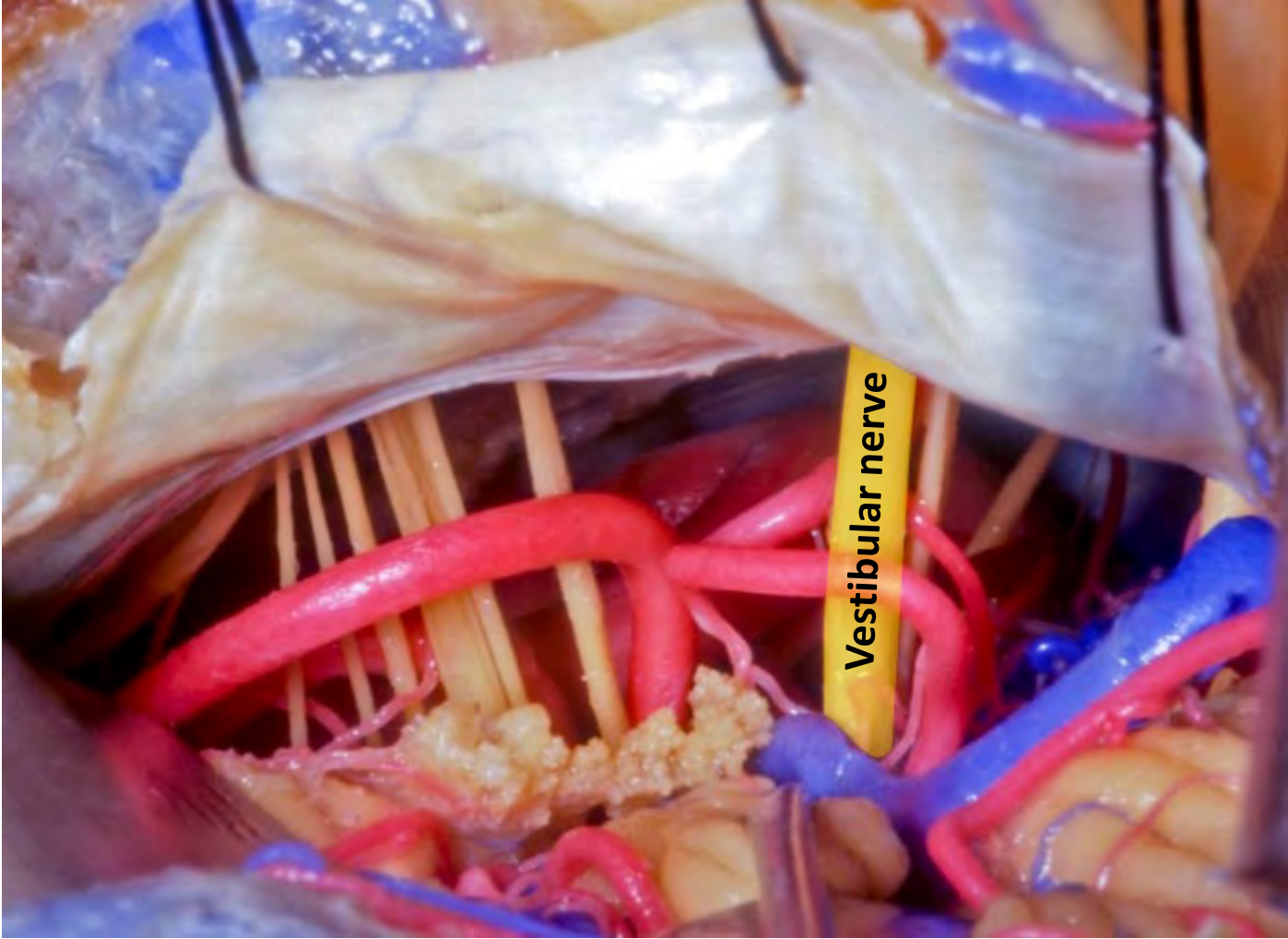


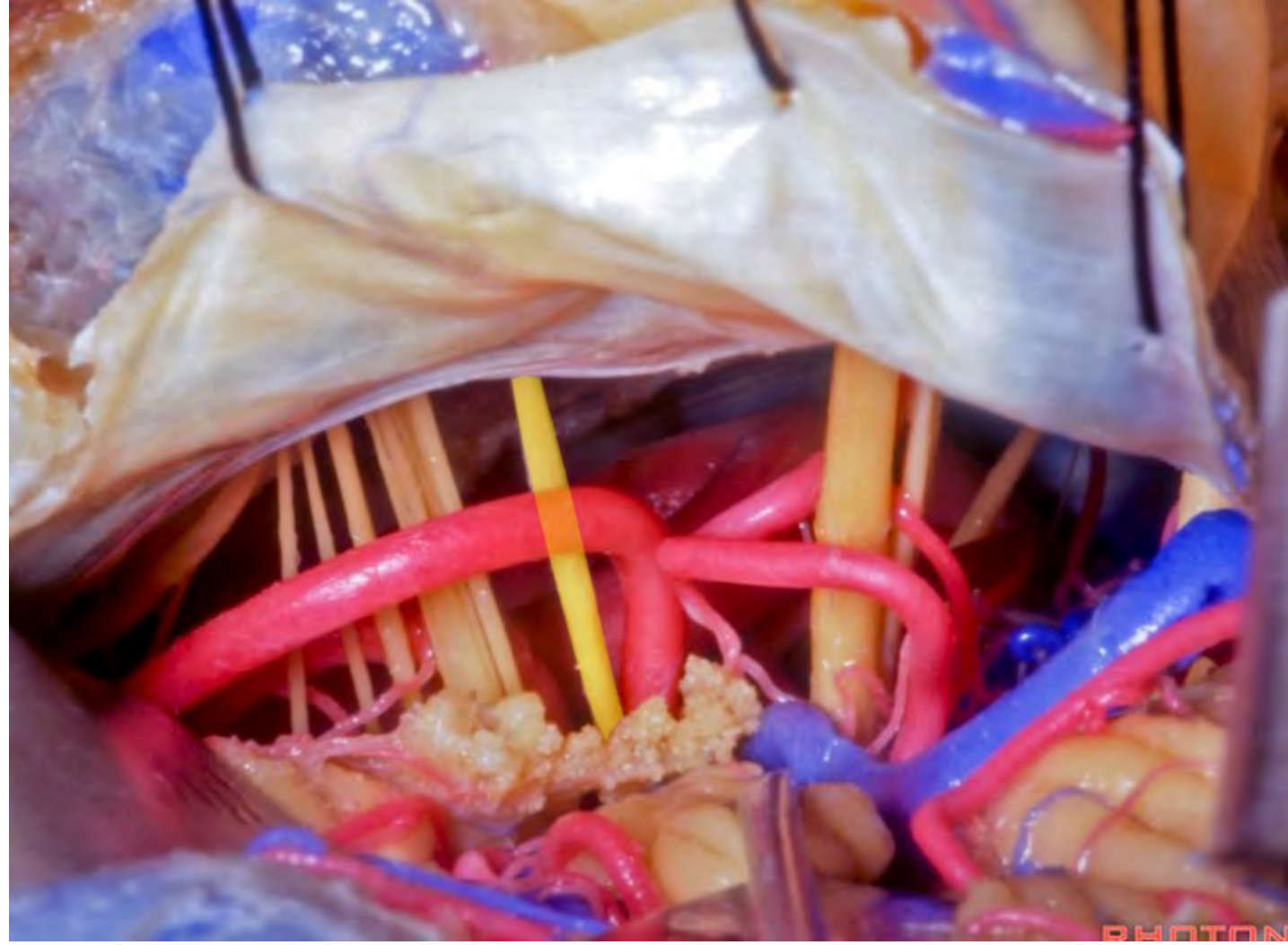


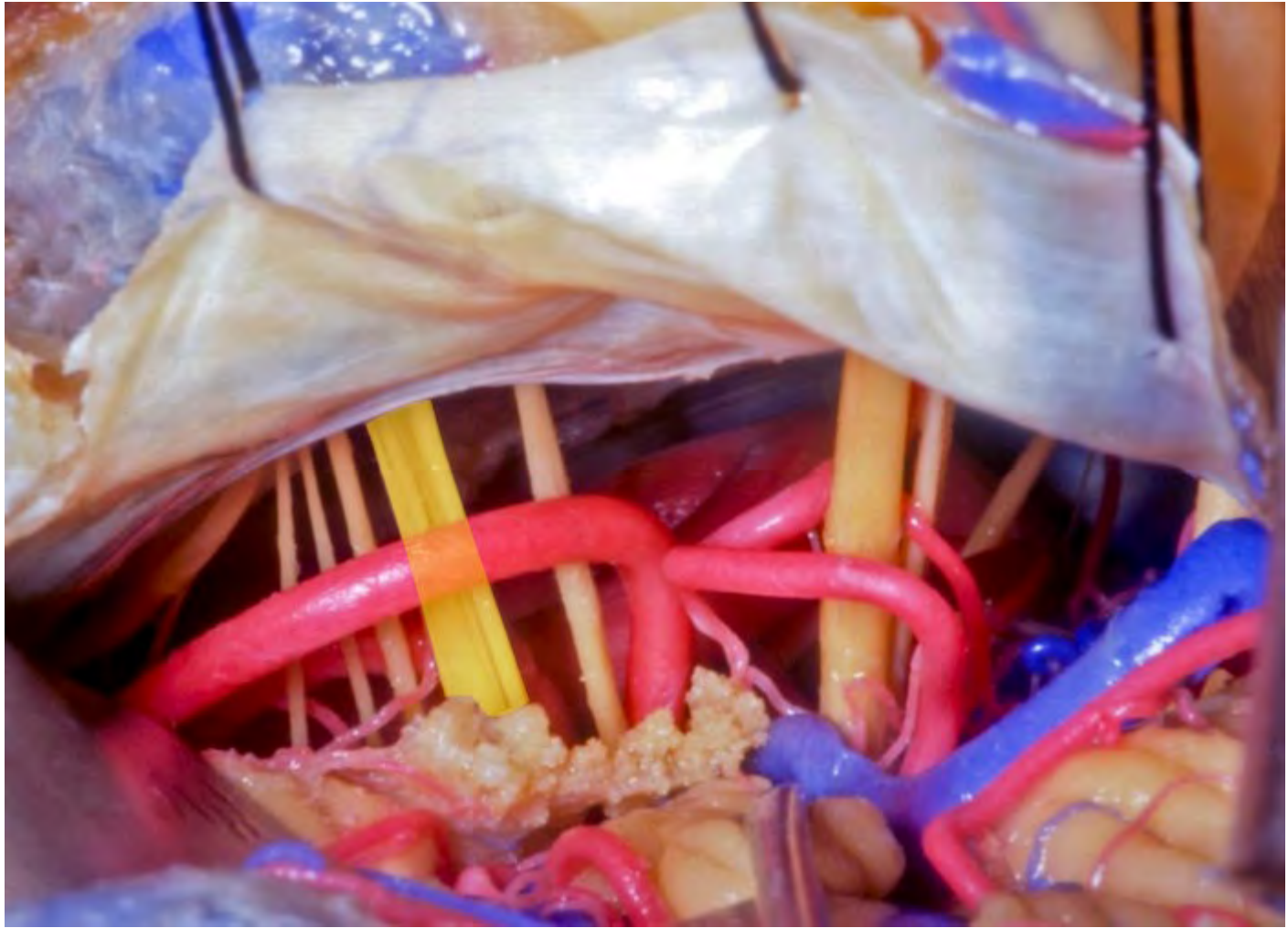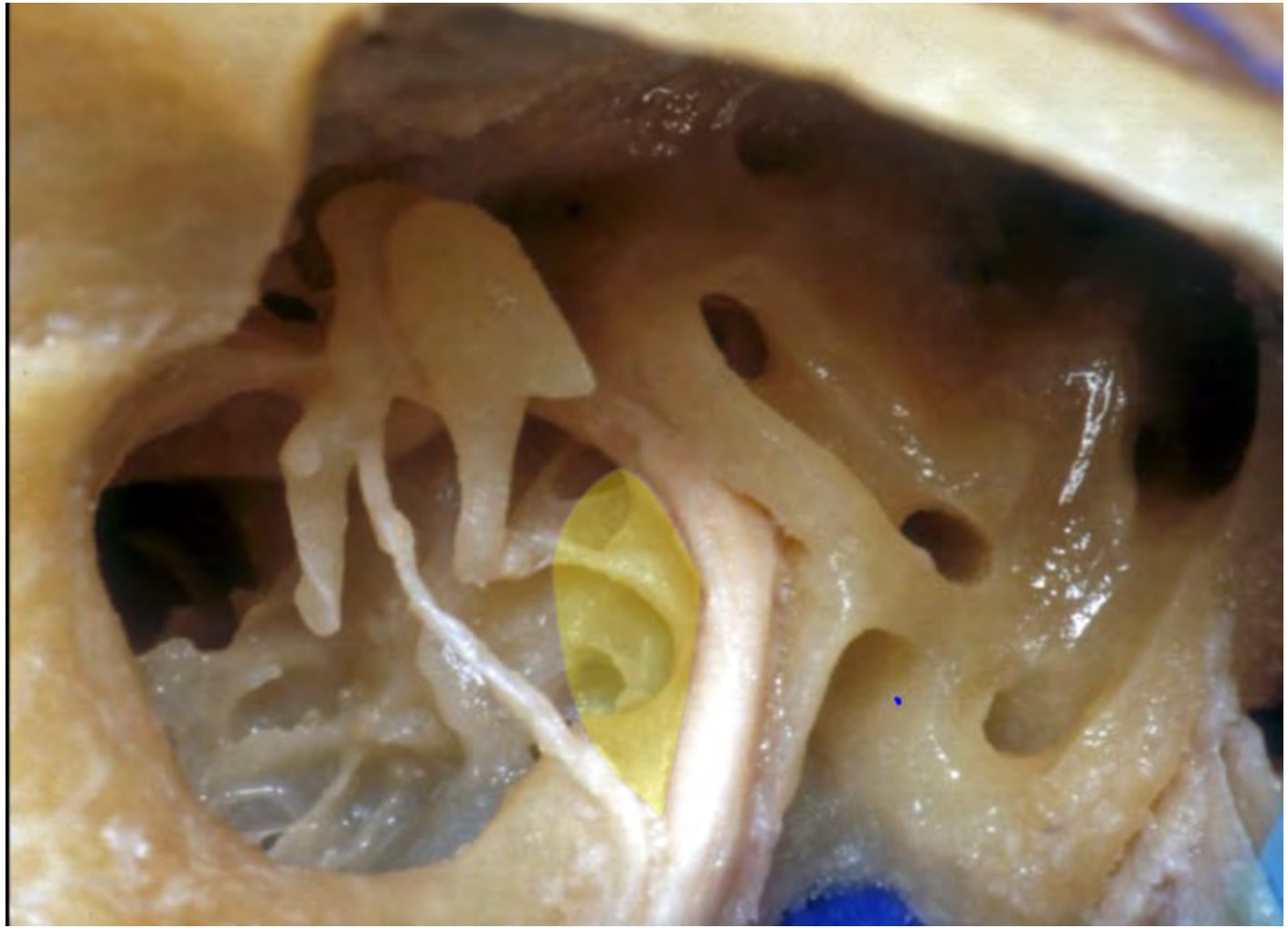
PHOTO



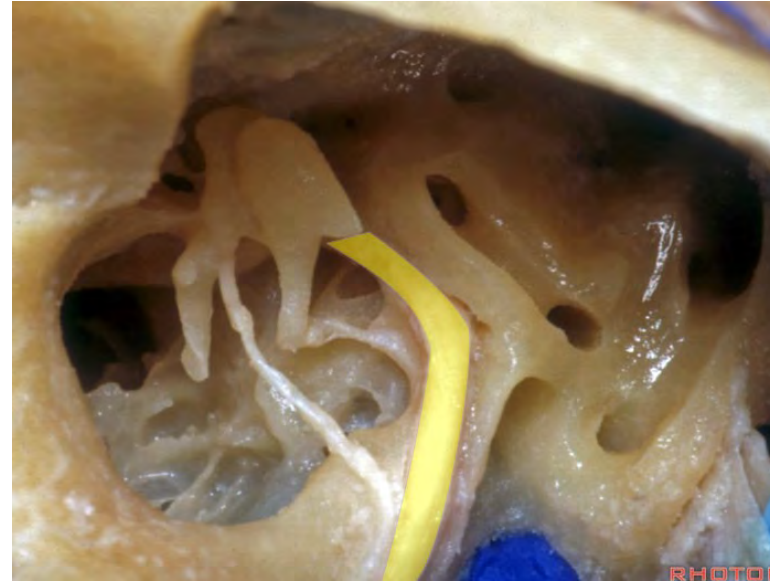




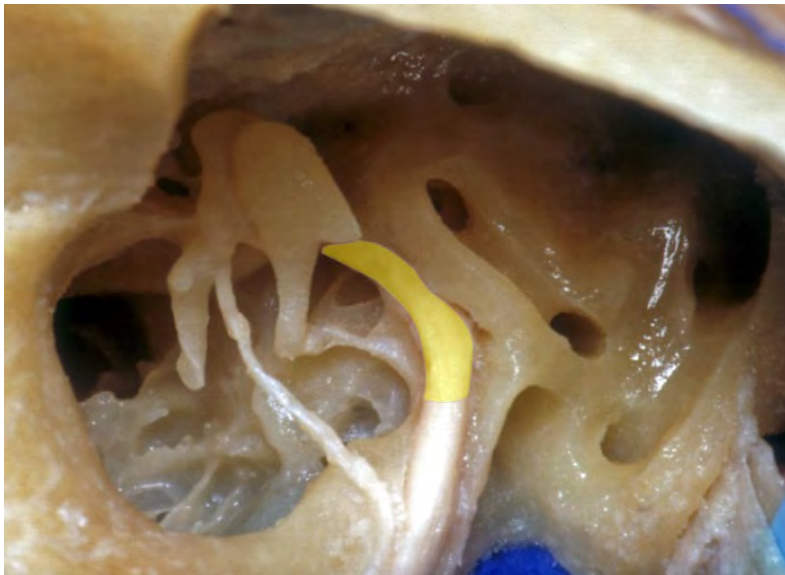




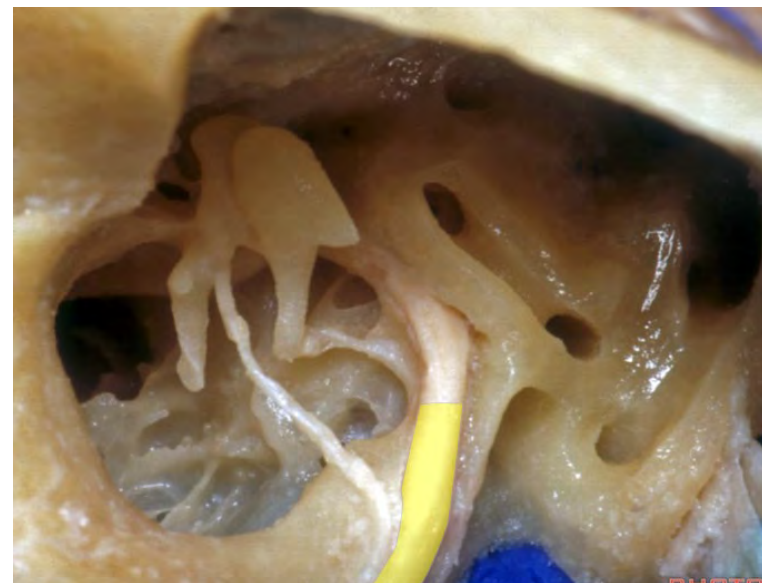
**Facial nerve**

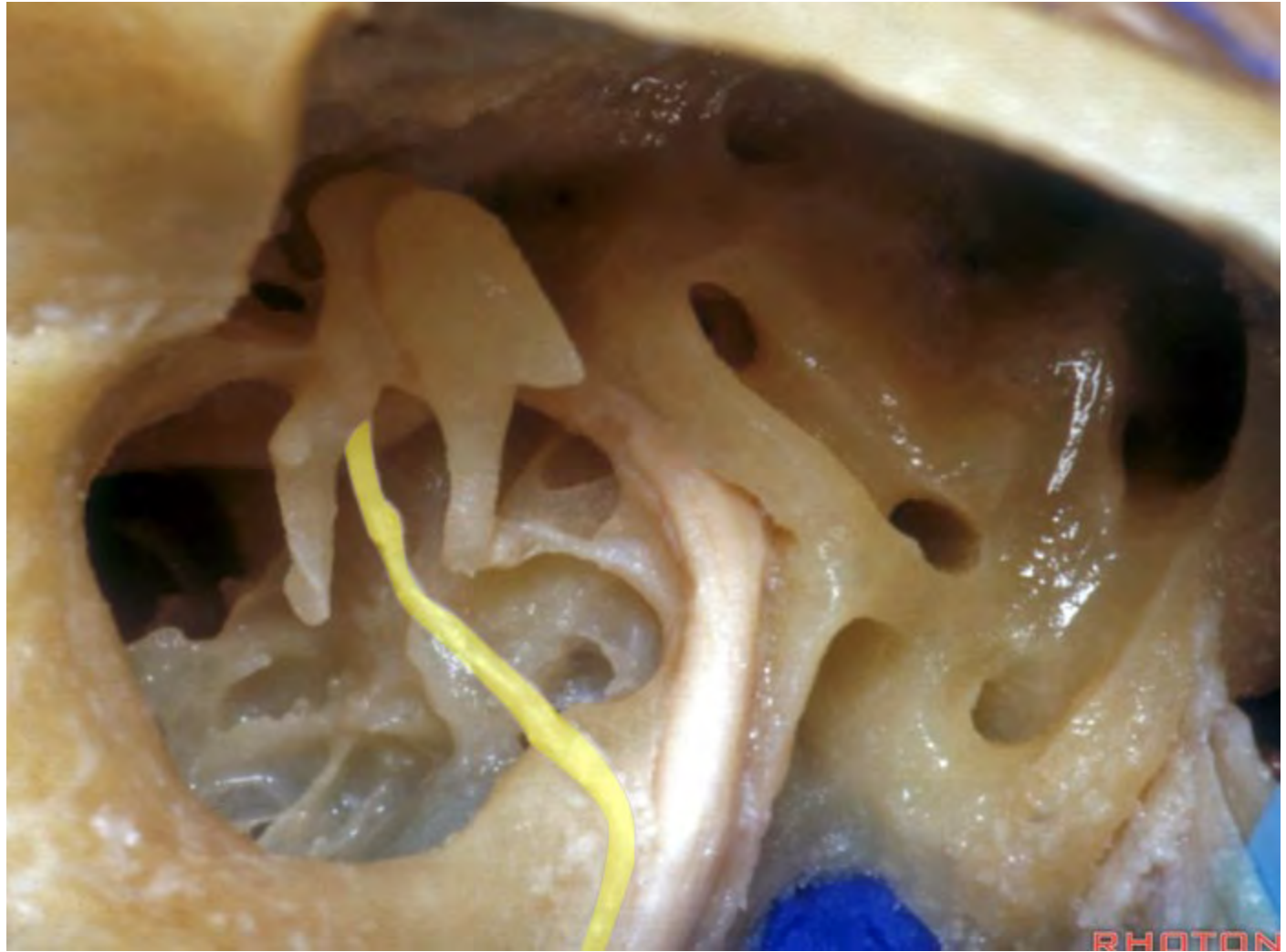


**Tympanic segment of facial nerve**

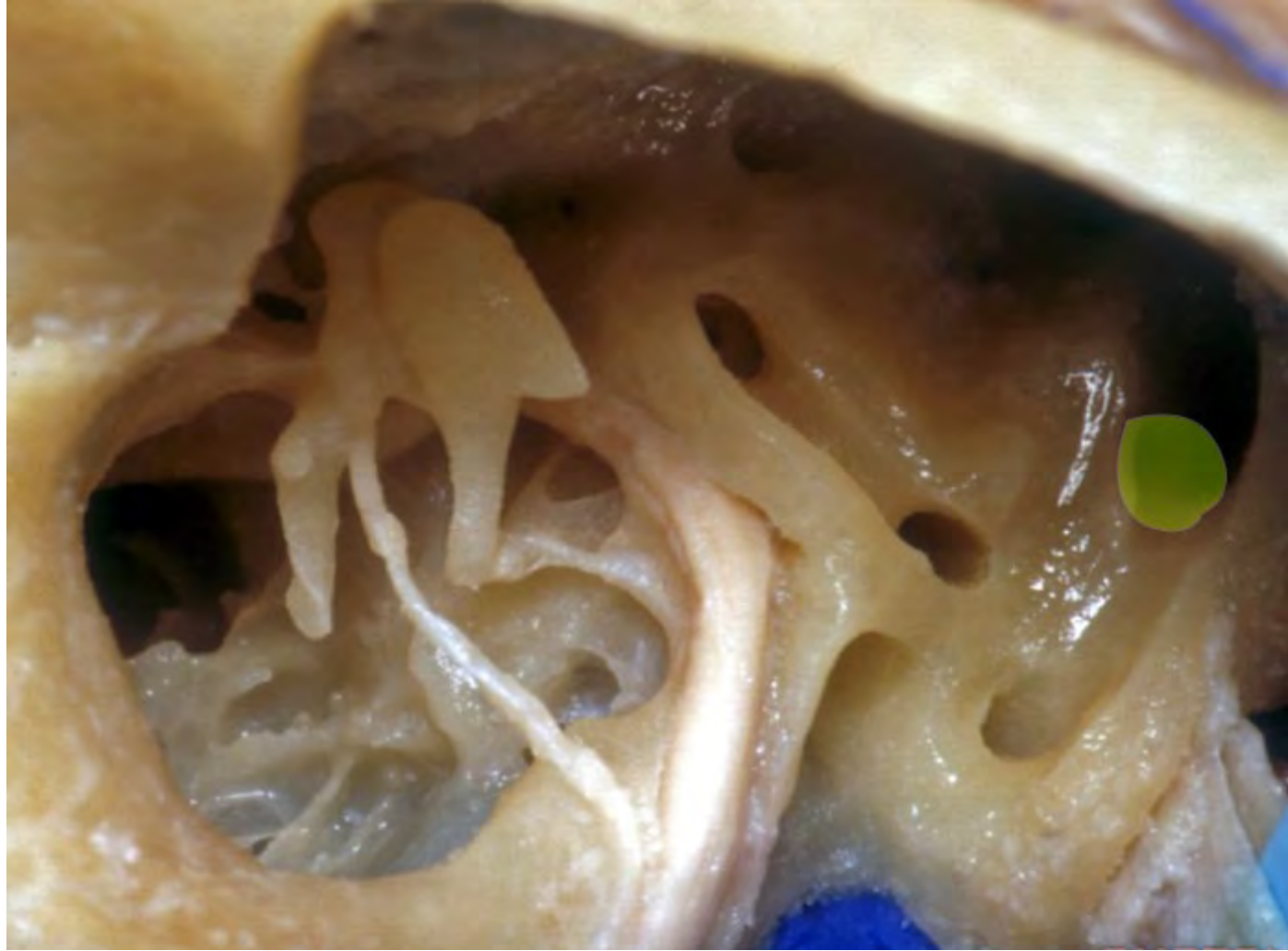

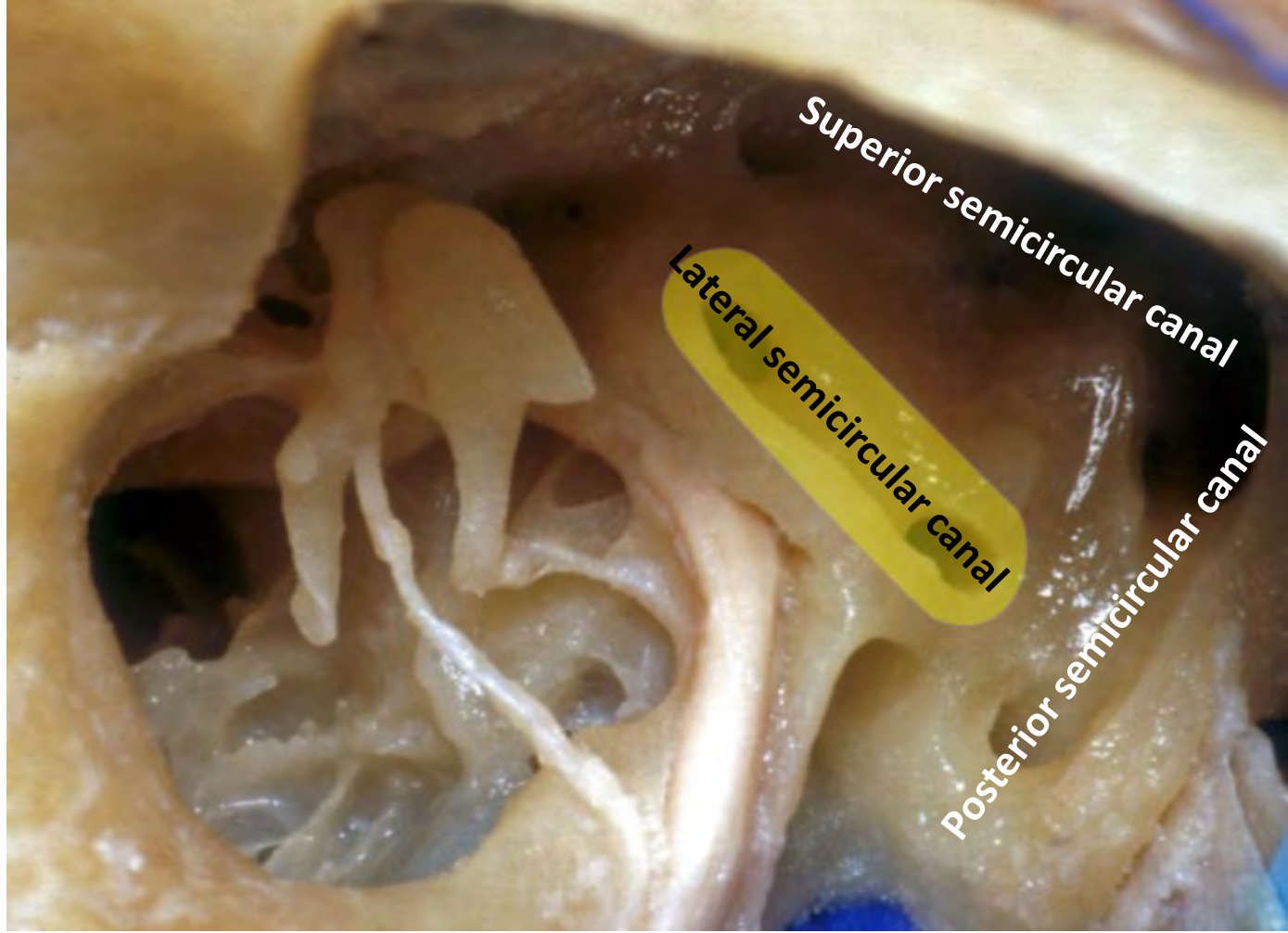
**Mastoid segment of facial nerve**







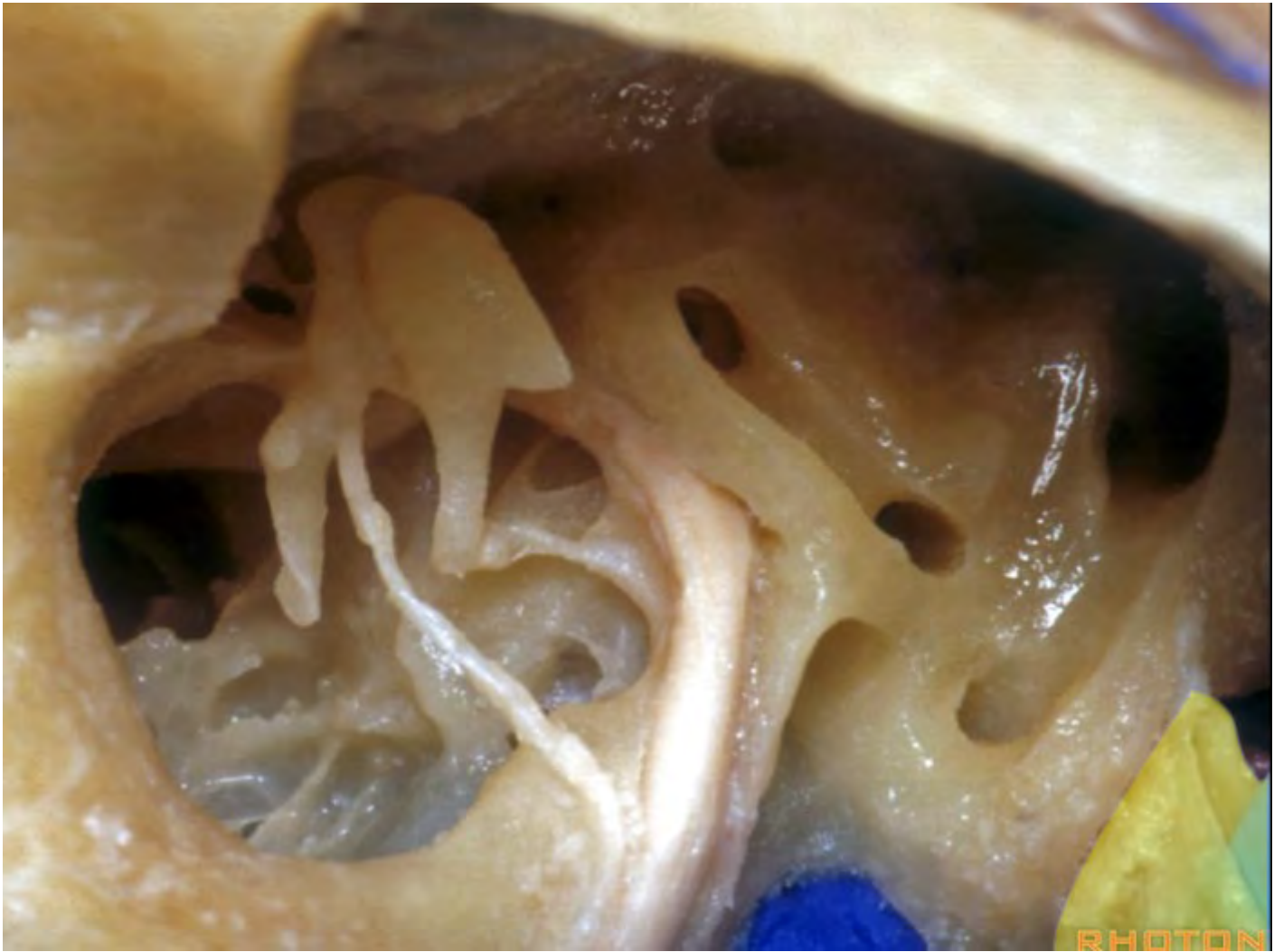


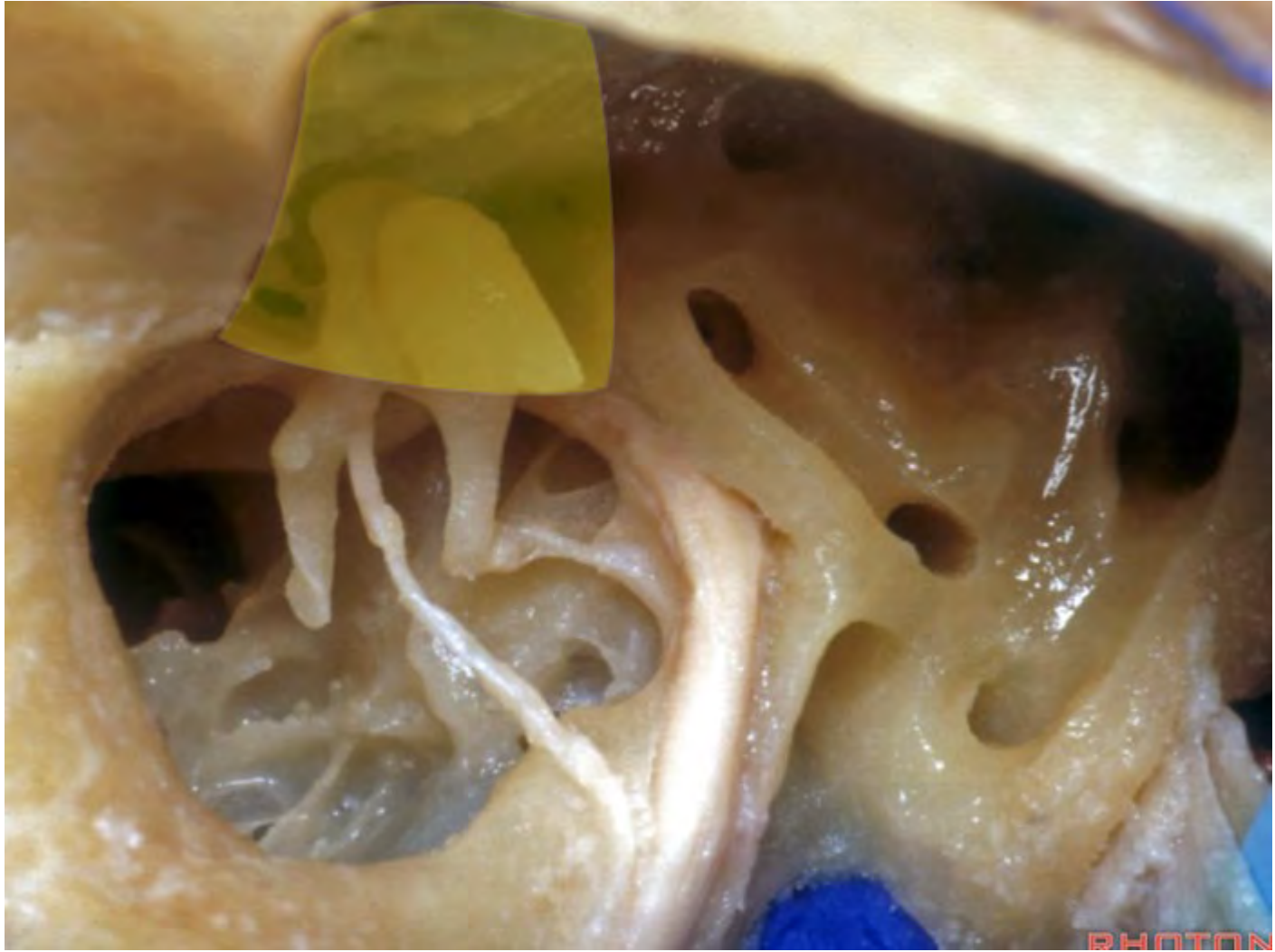


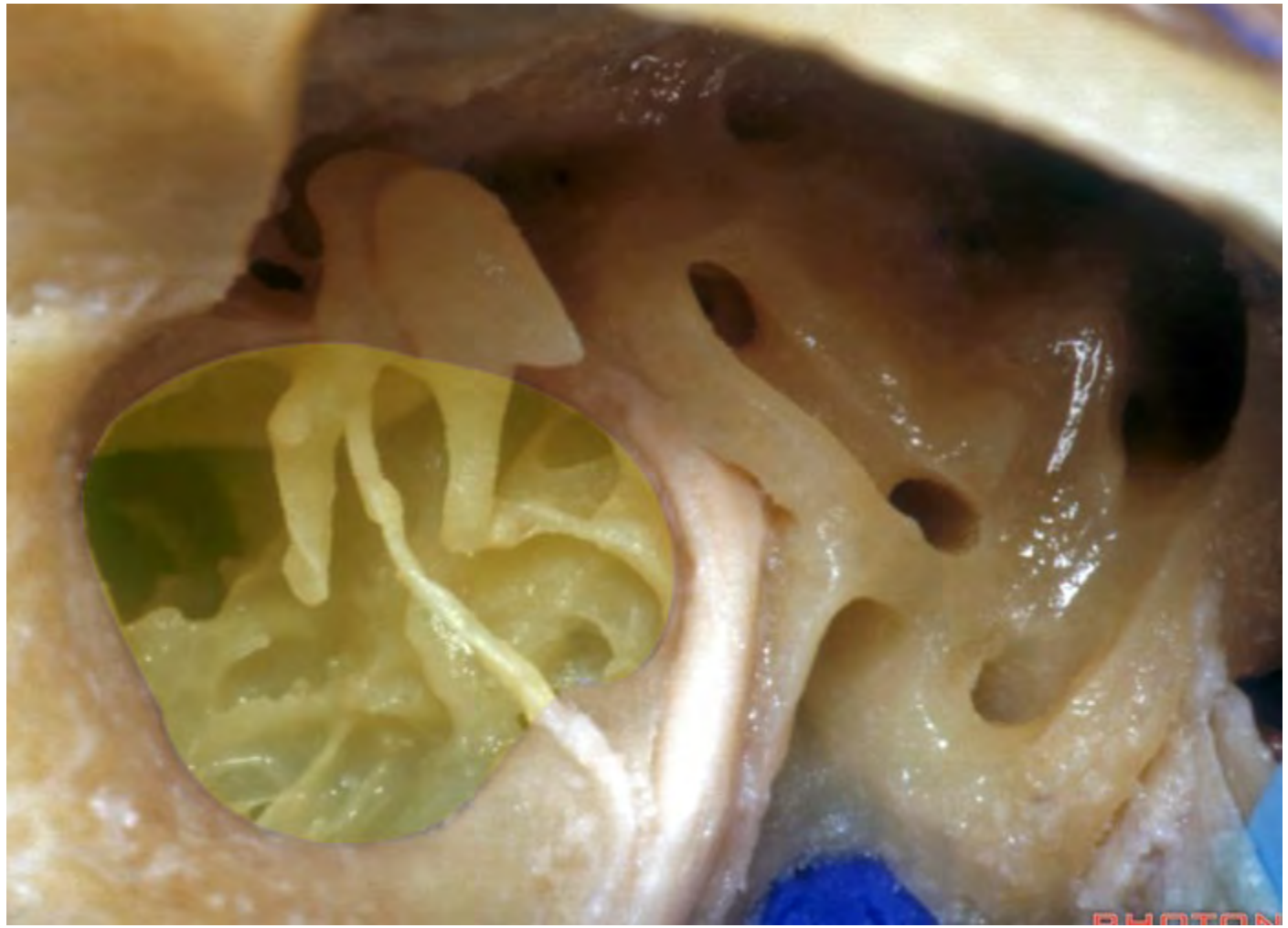
Superior semicircular canal

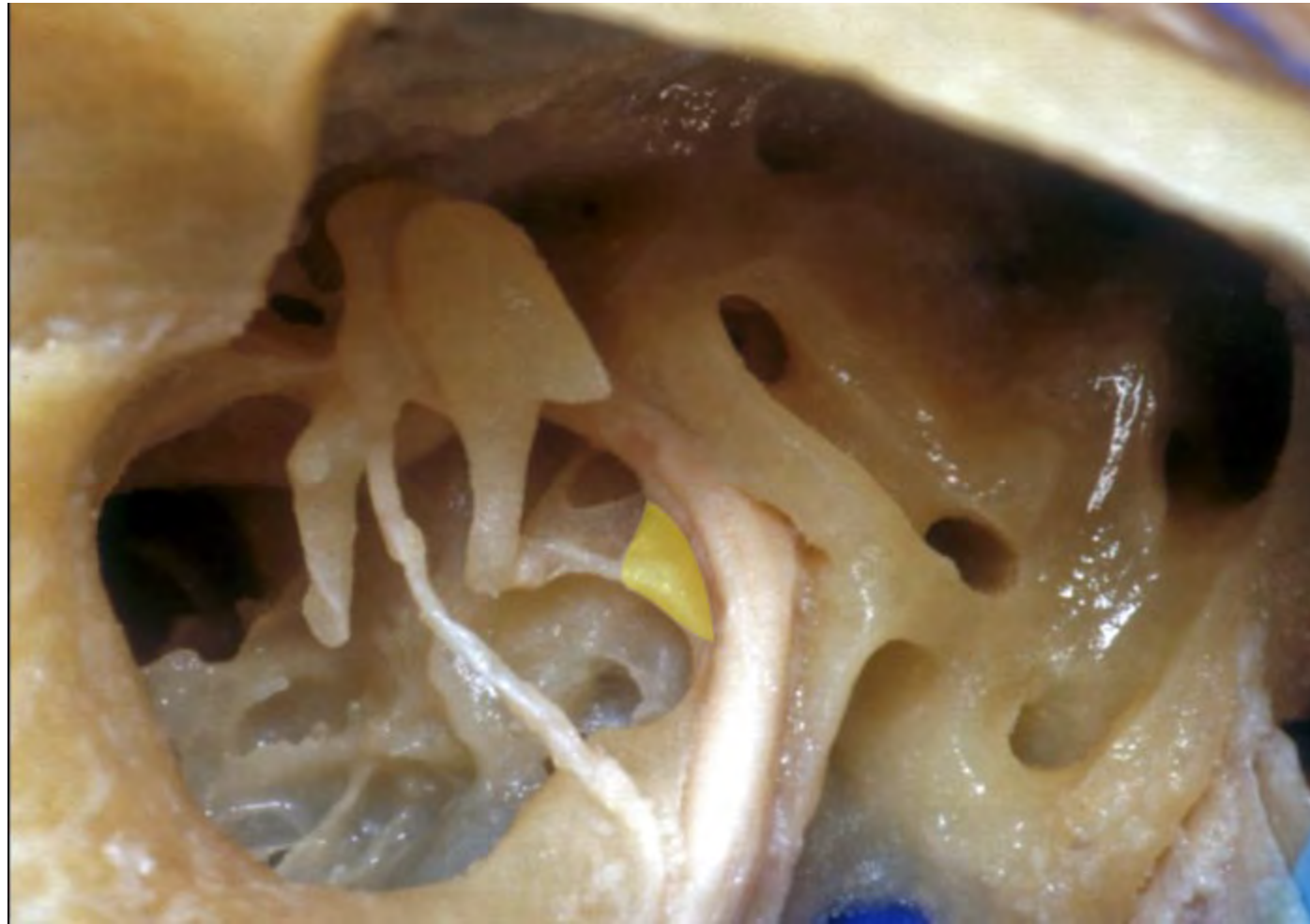
Lateral semicircular canal

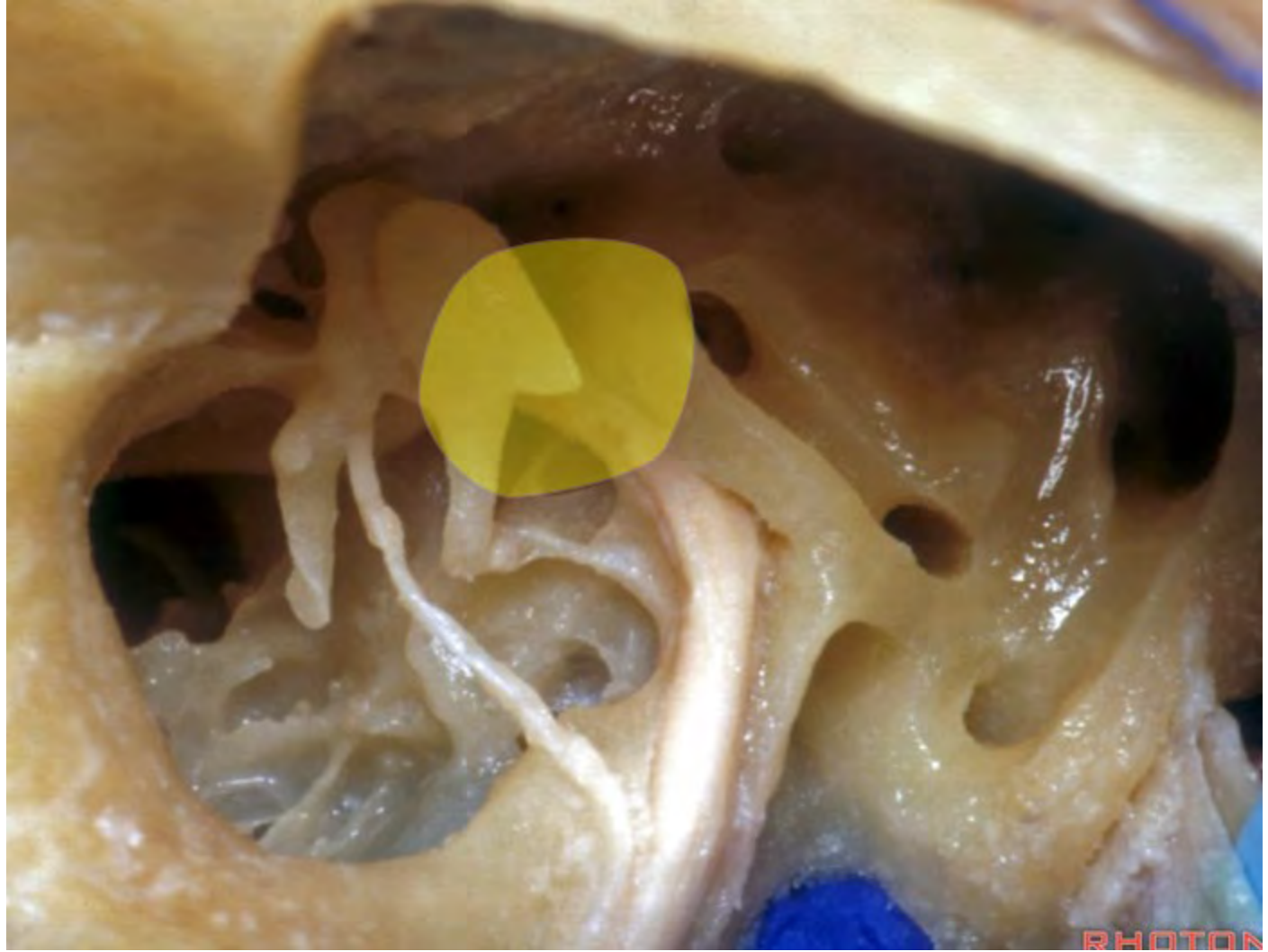
Posterior semicircular canal

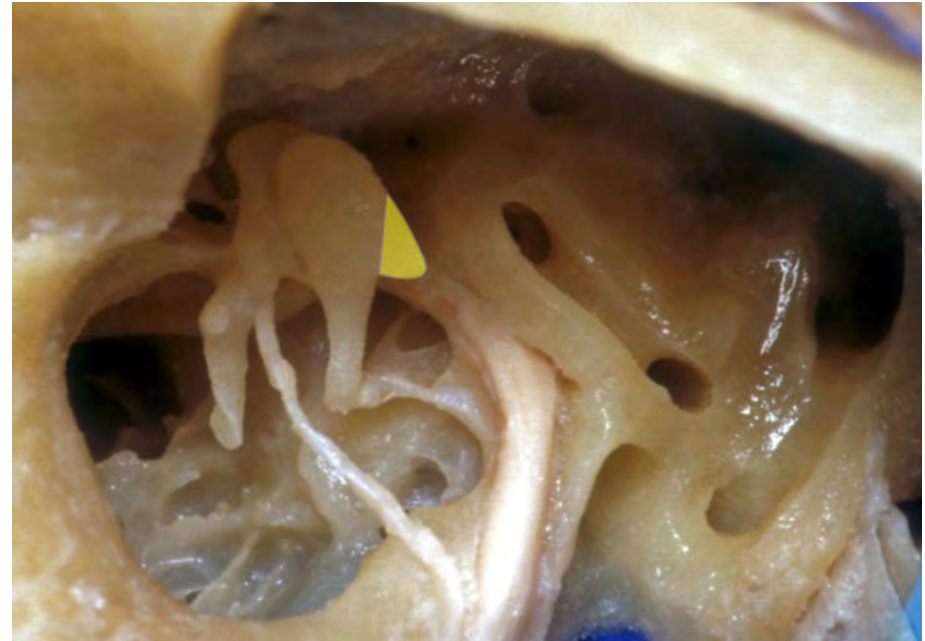
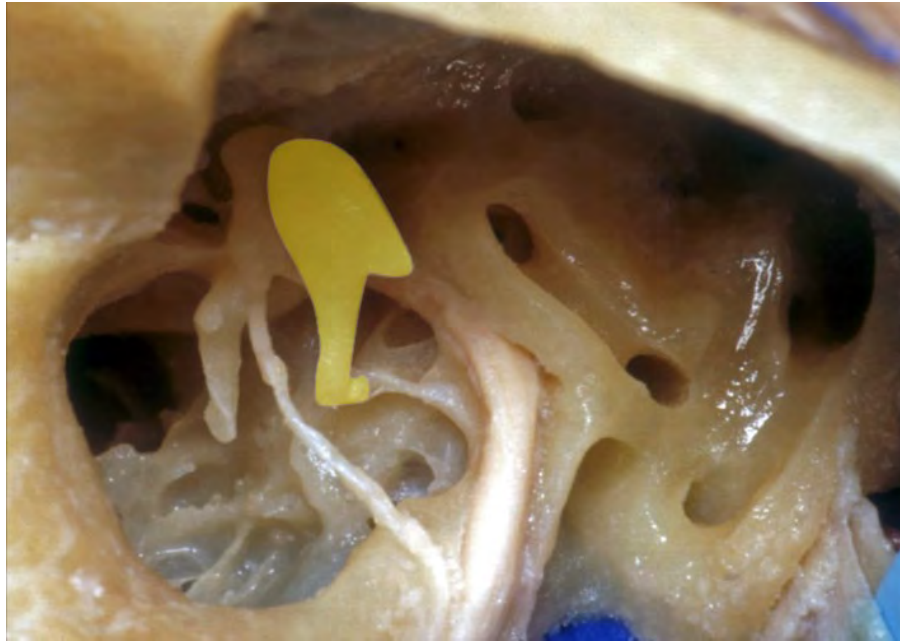




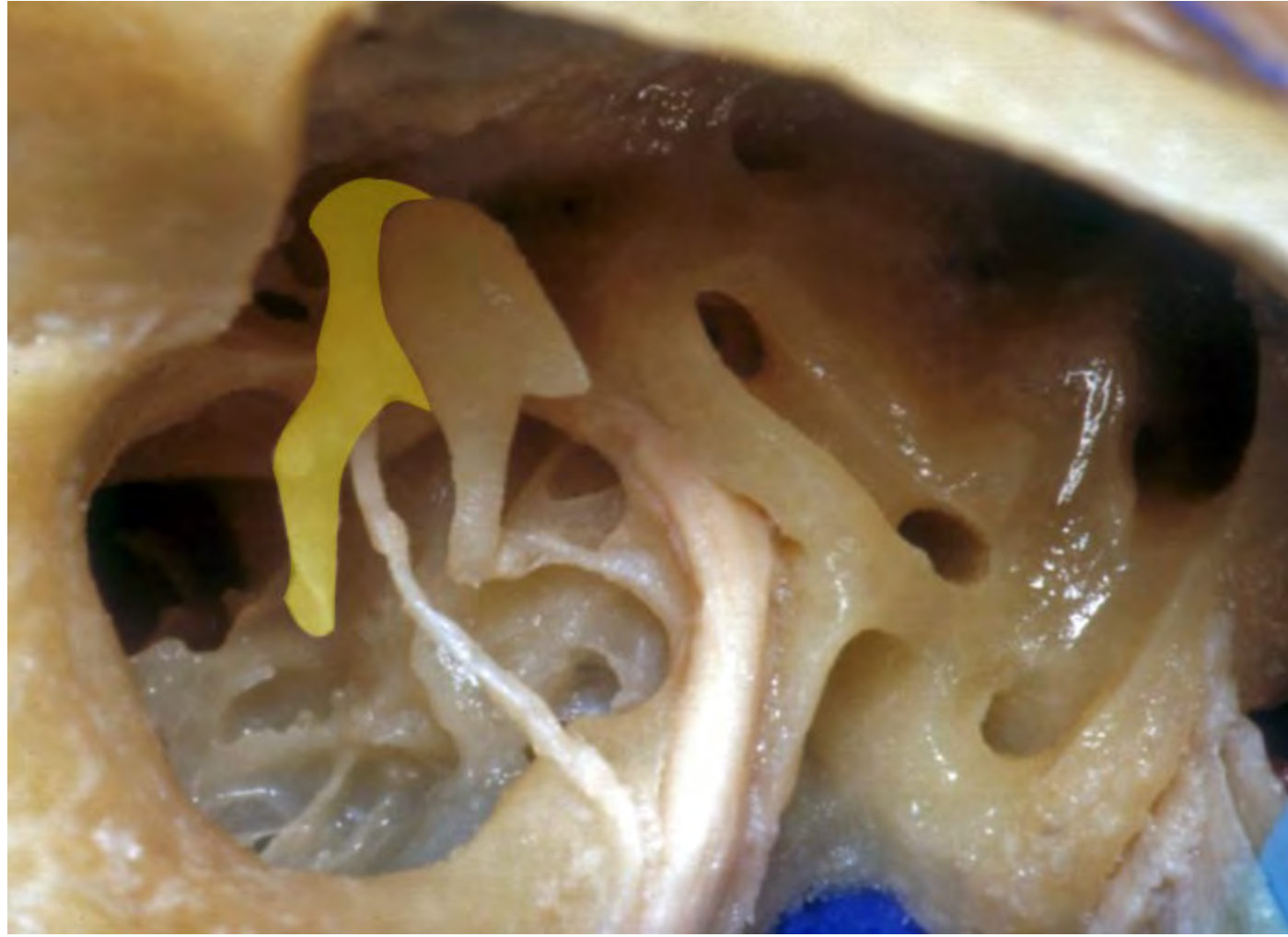


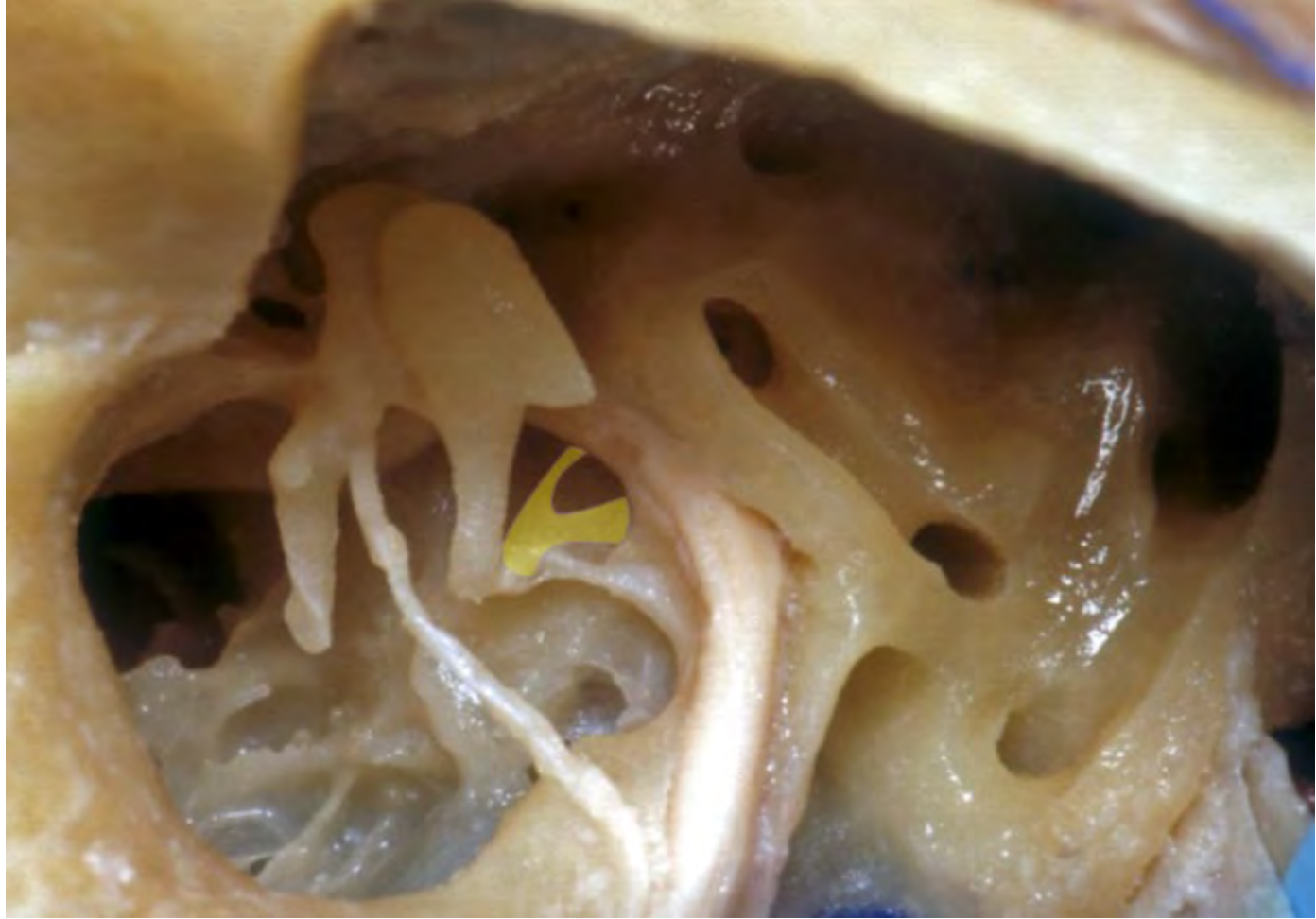

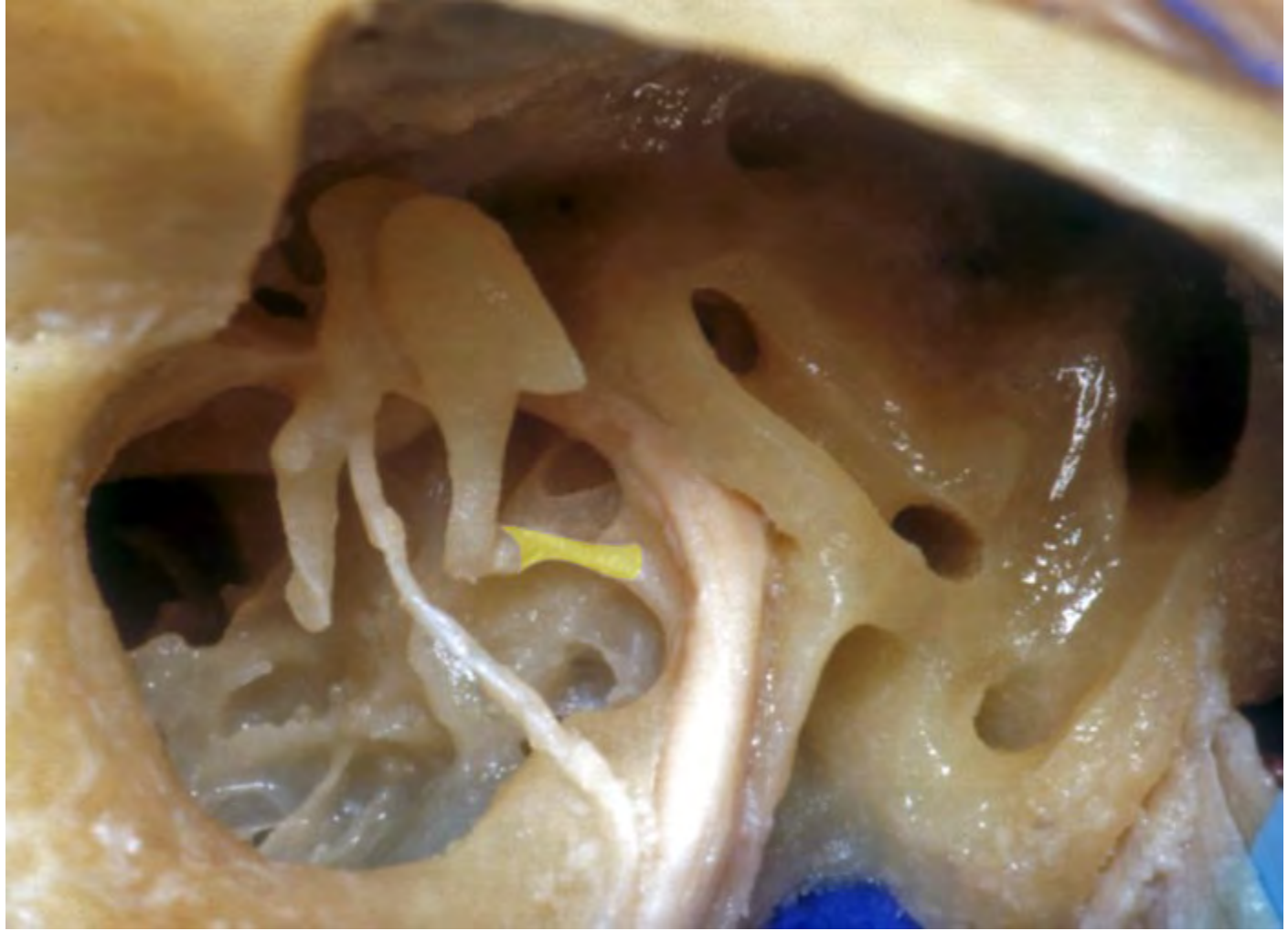



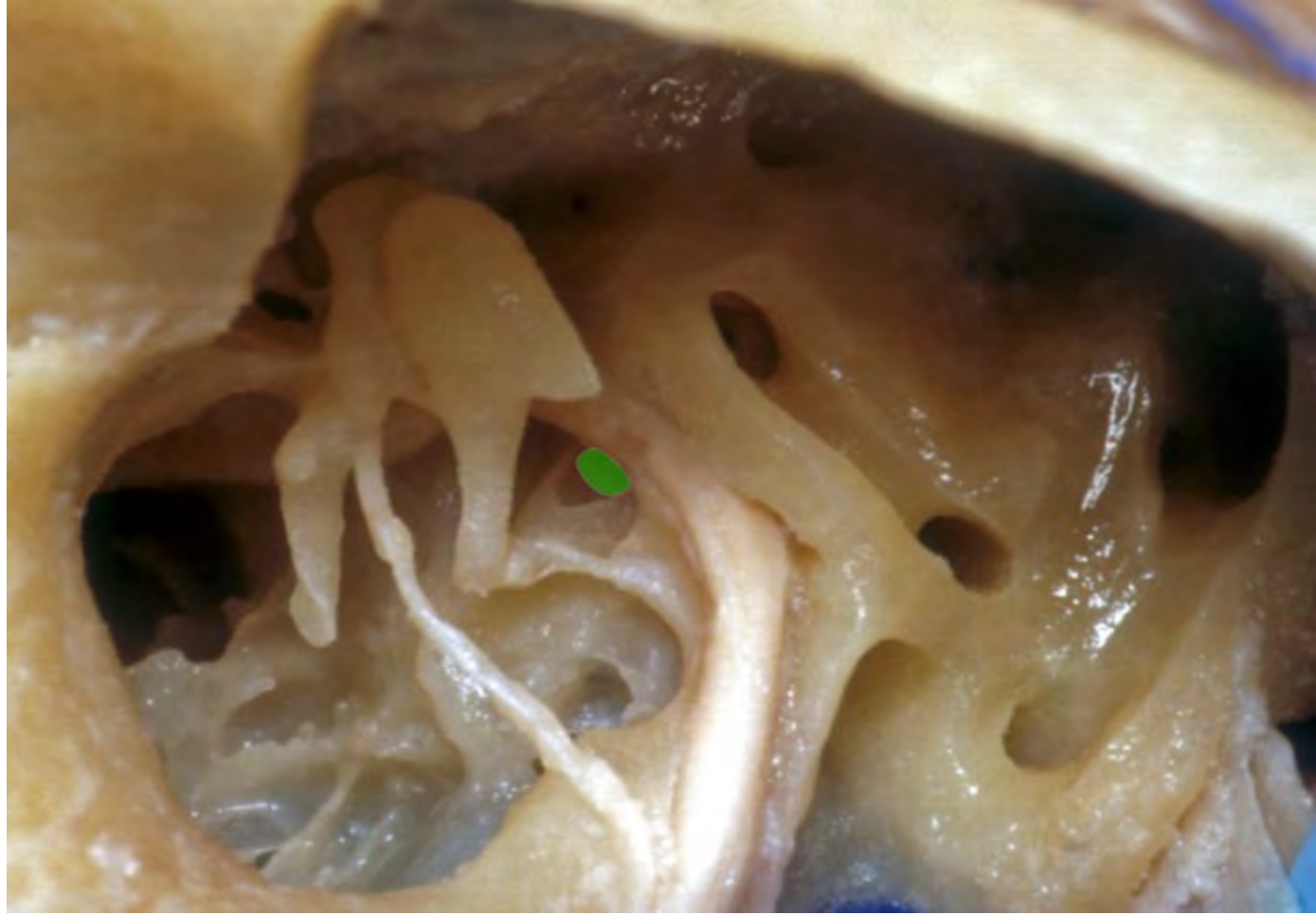


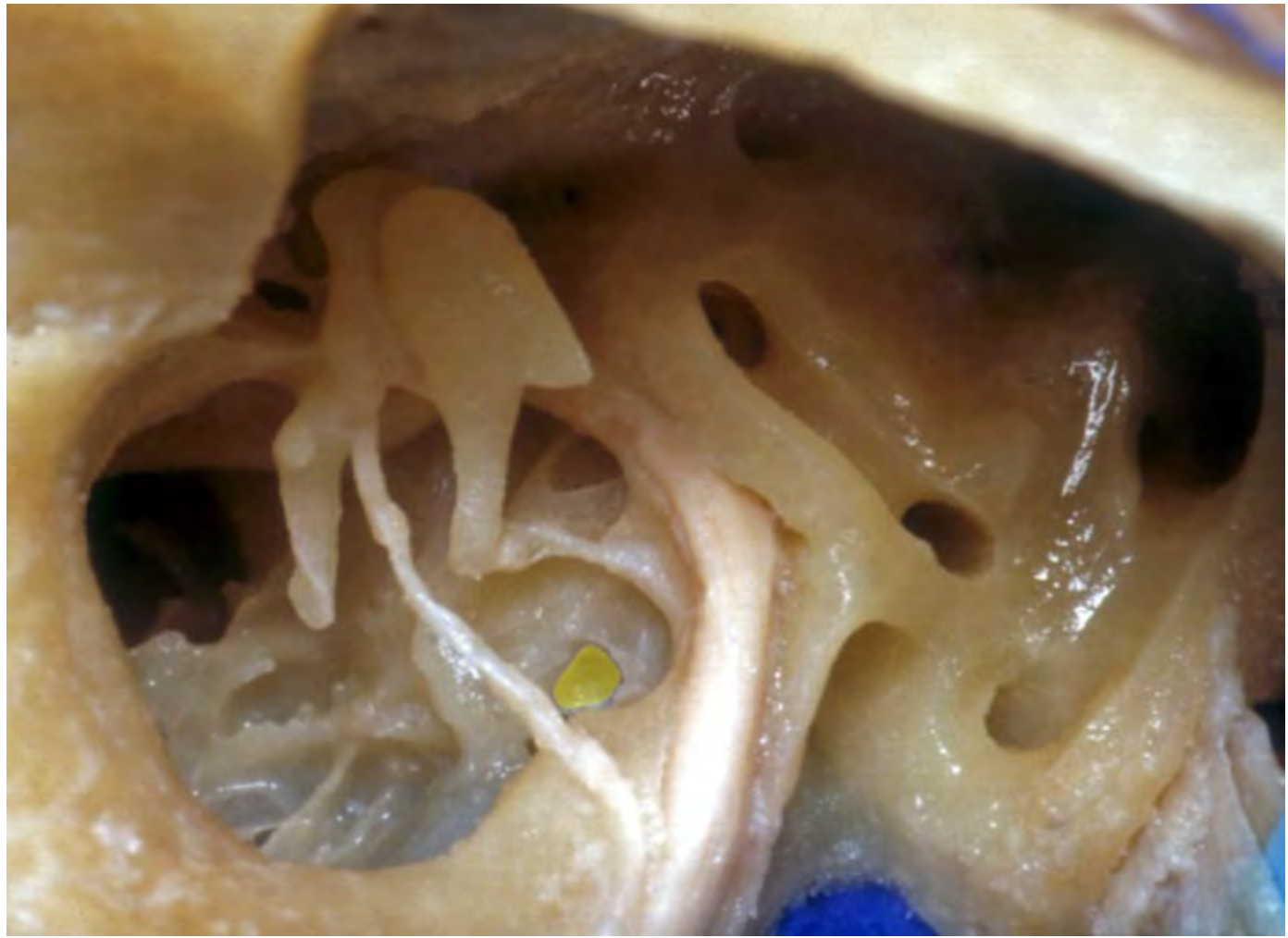

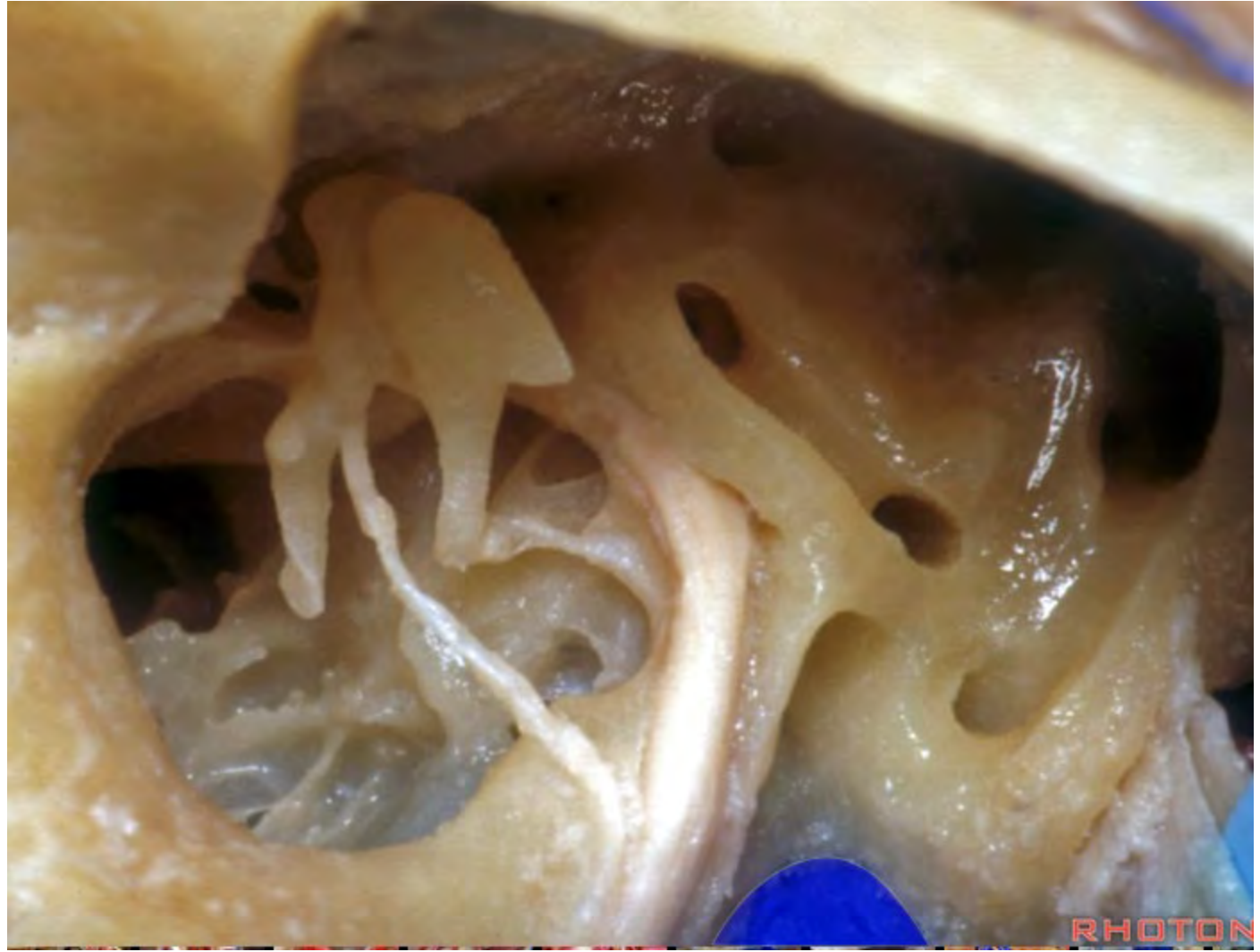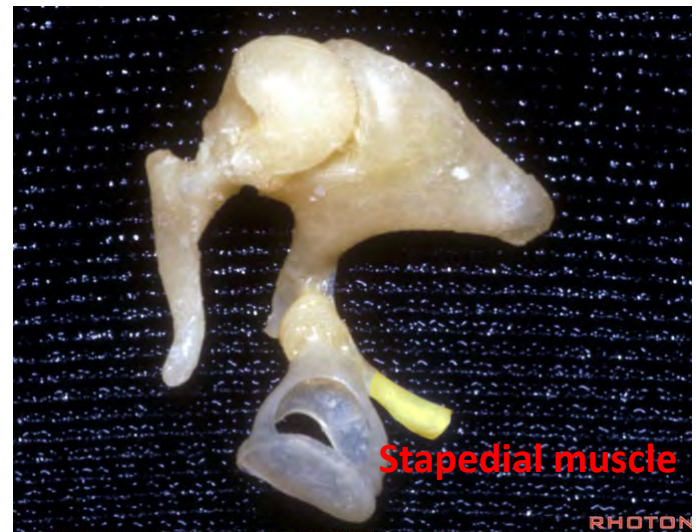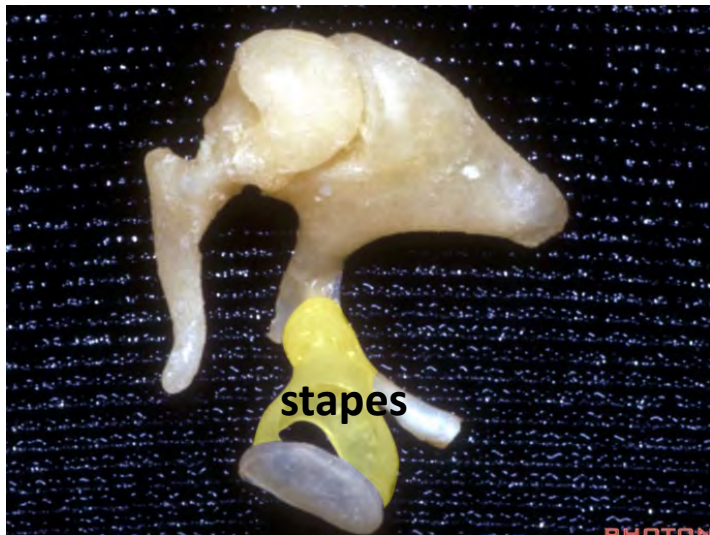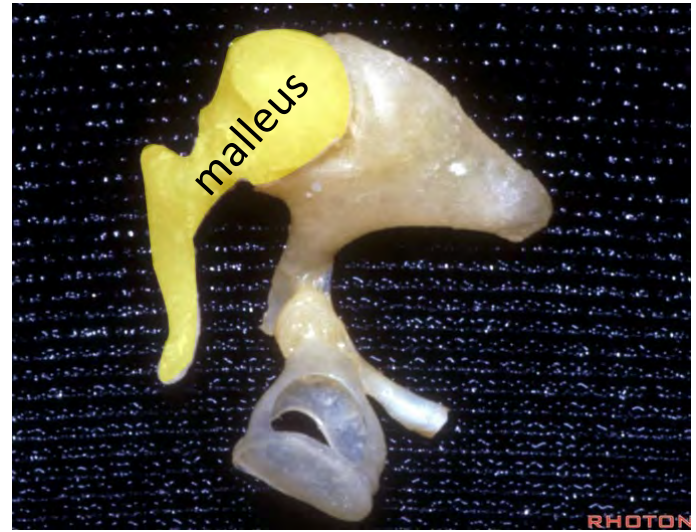
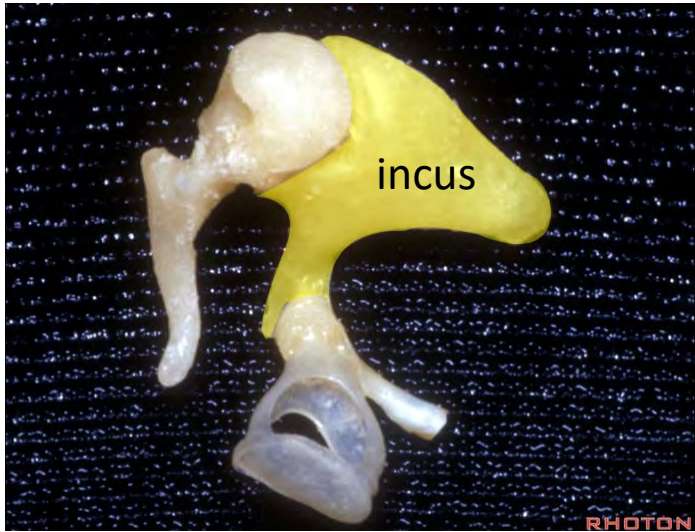


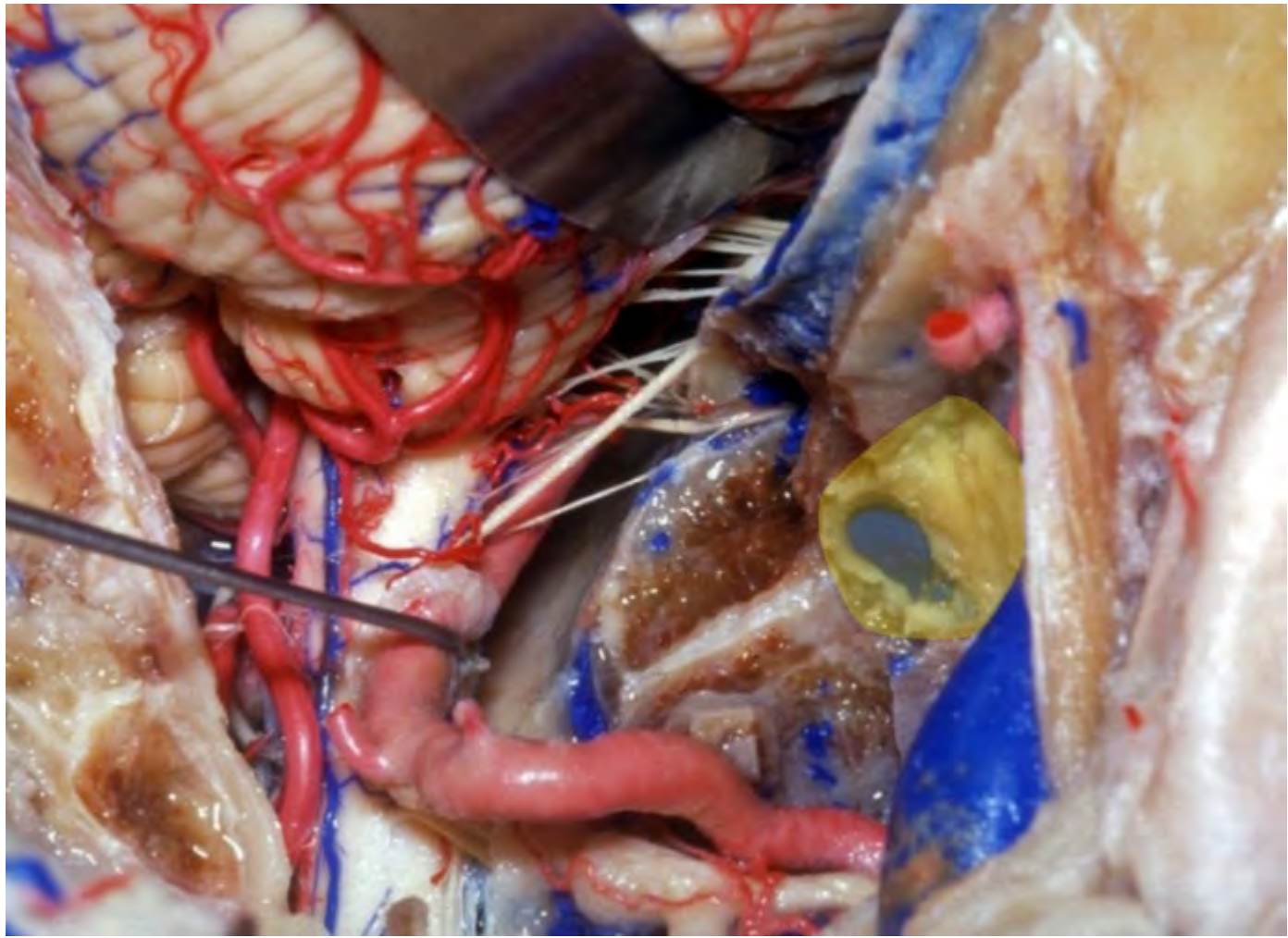




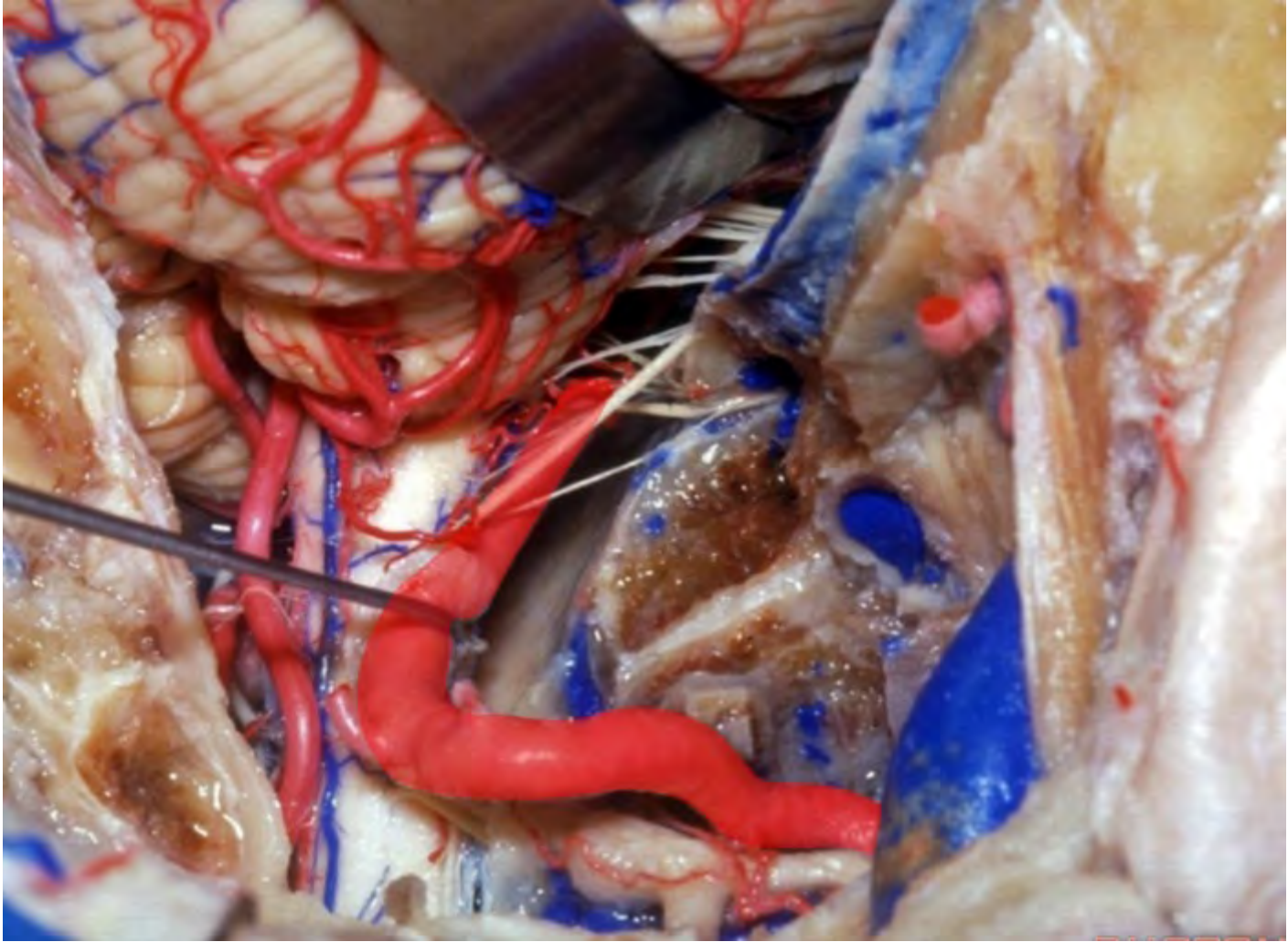


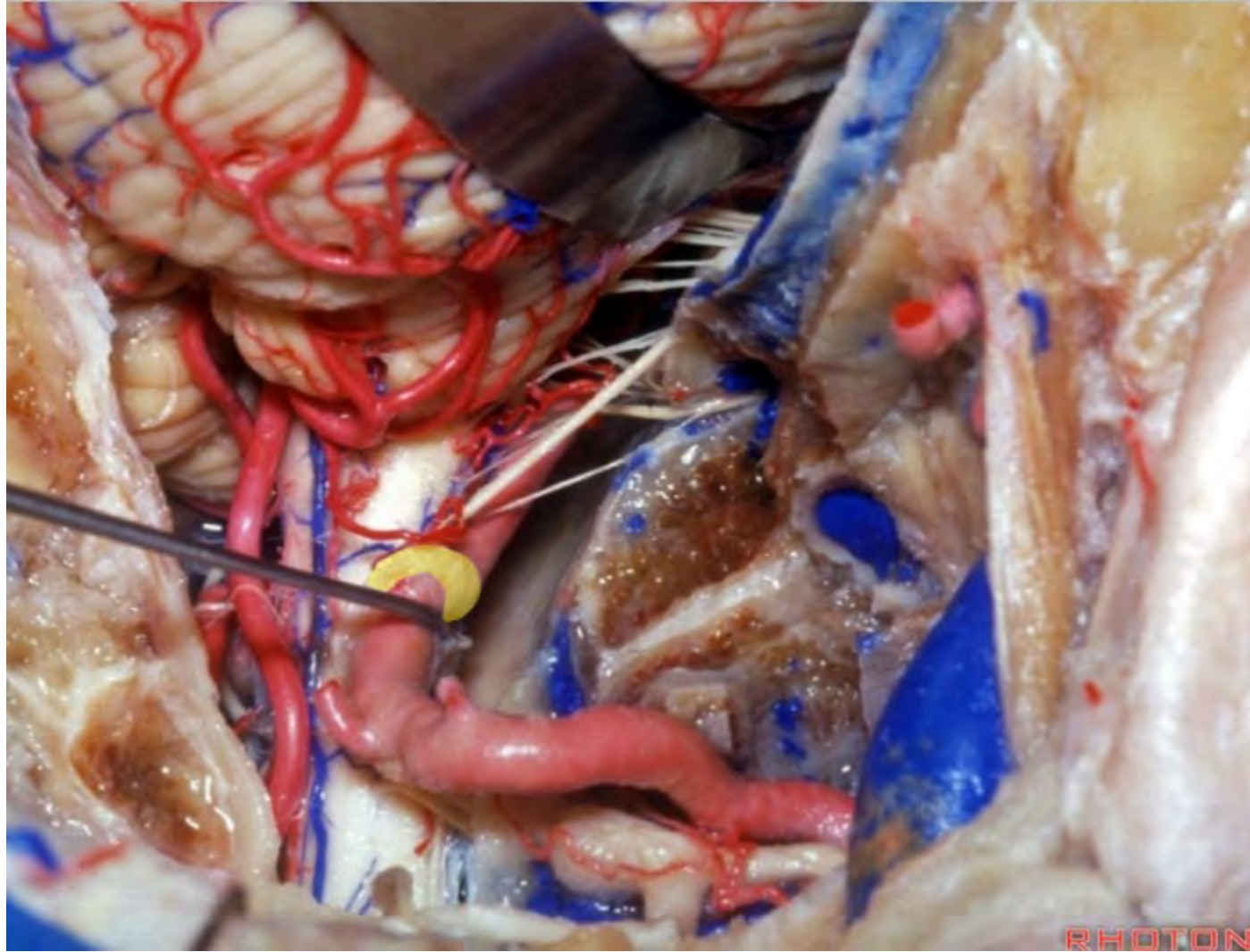




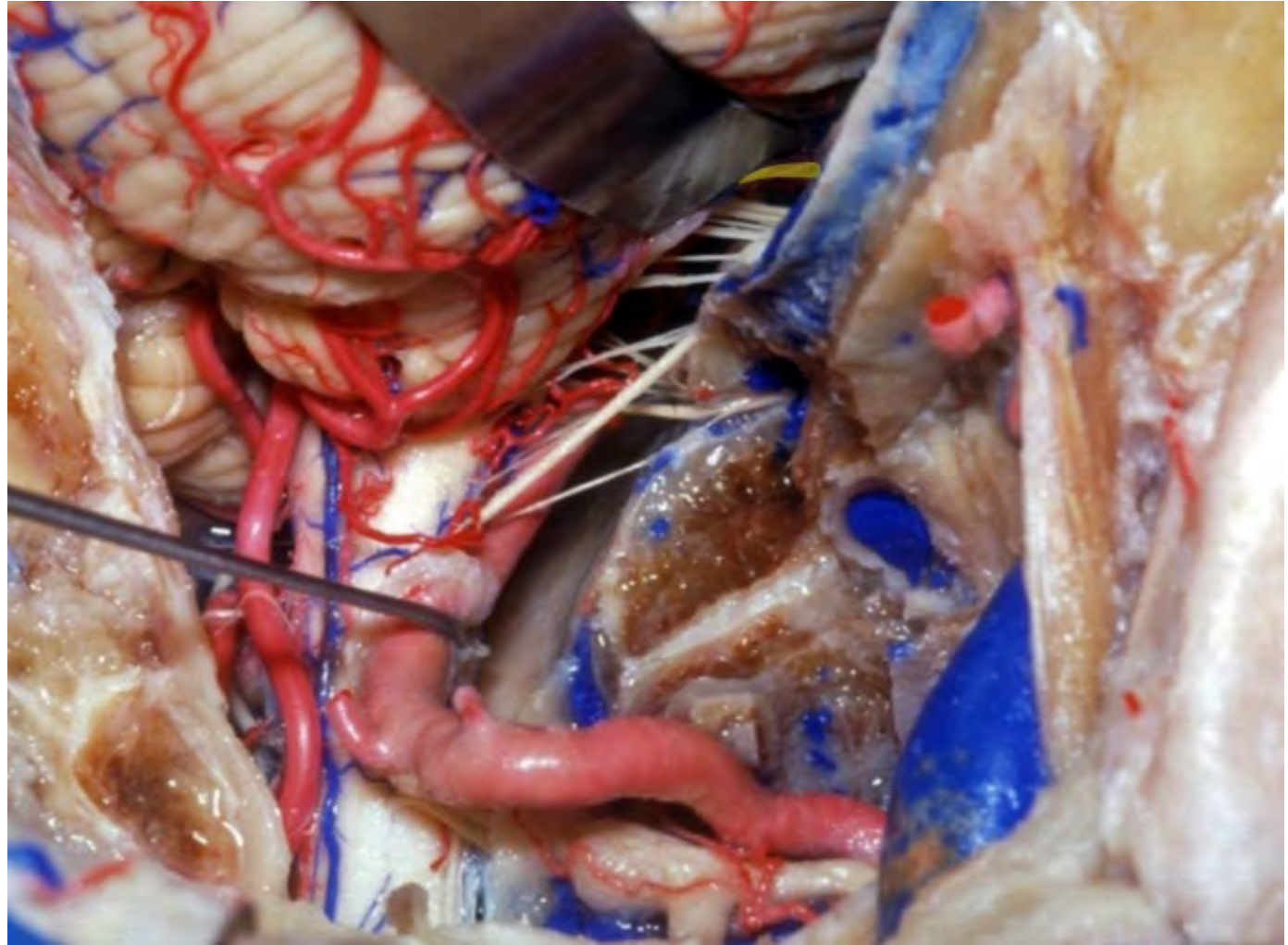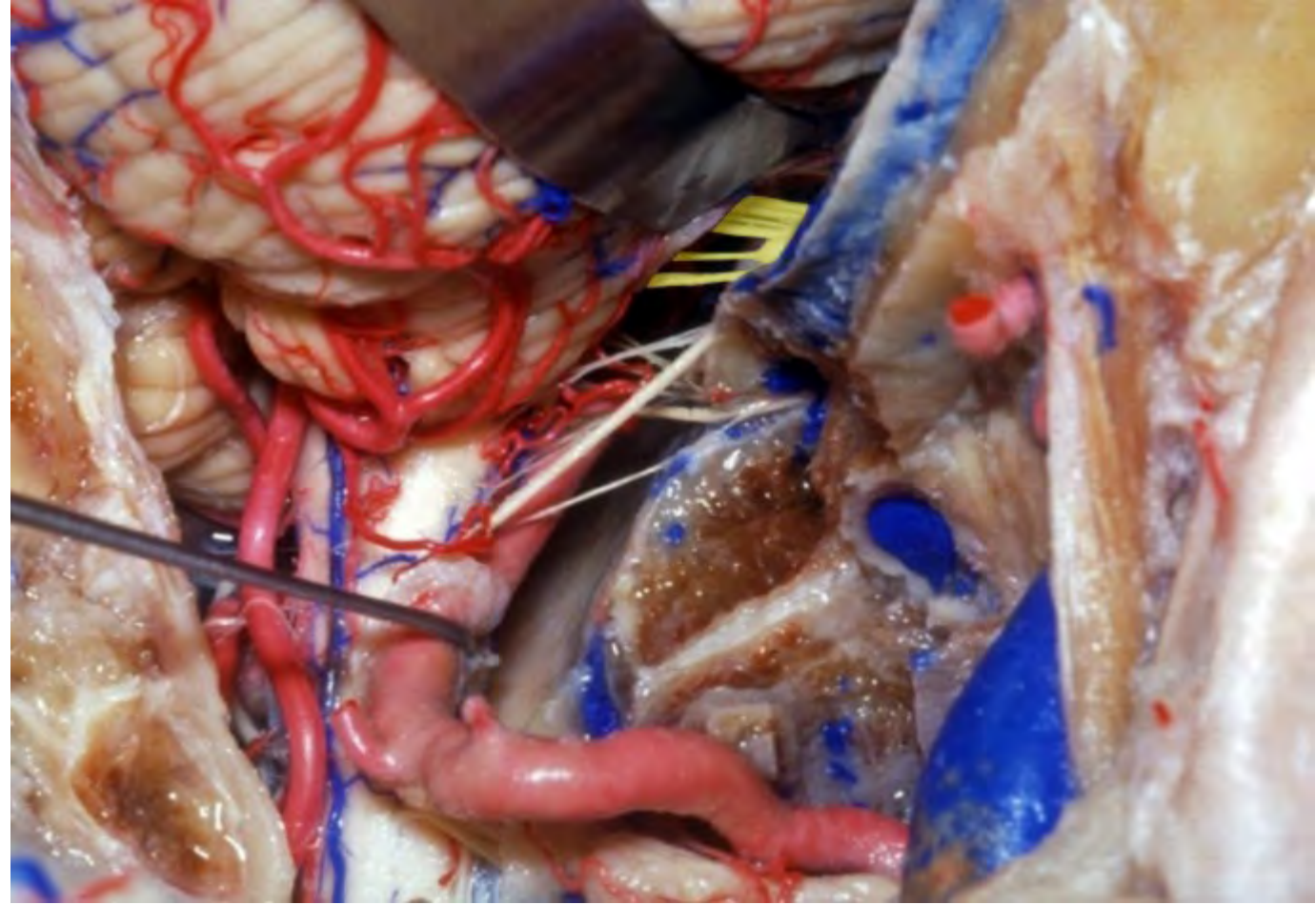


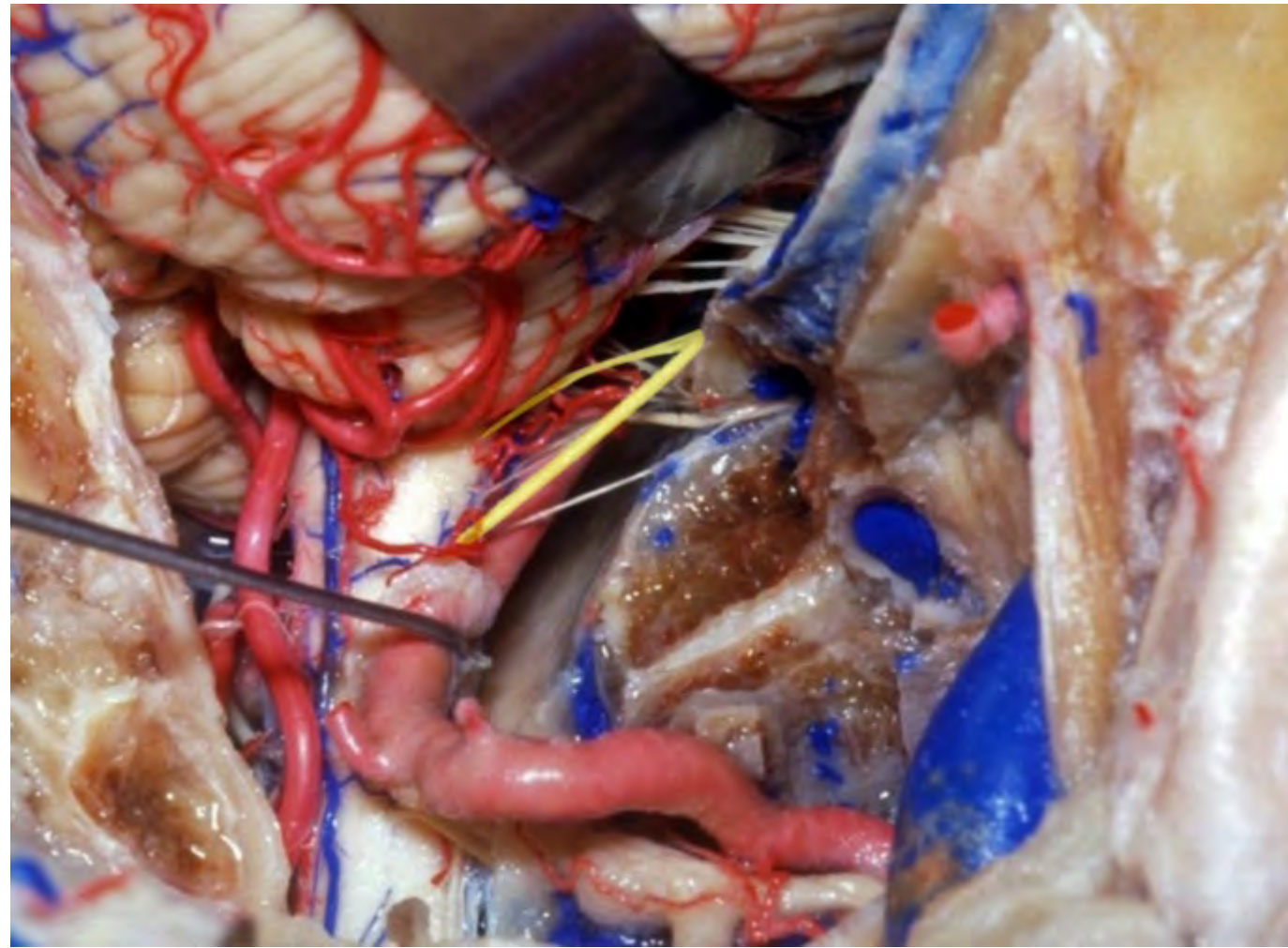


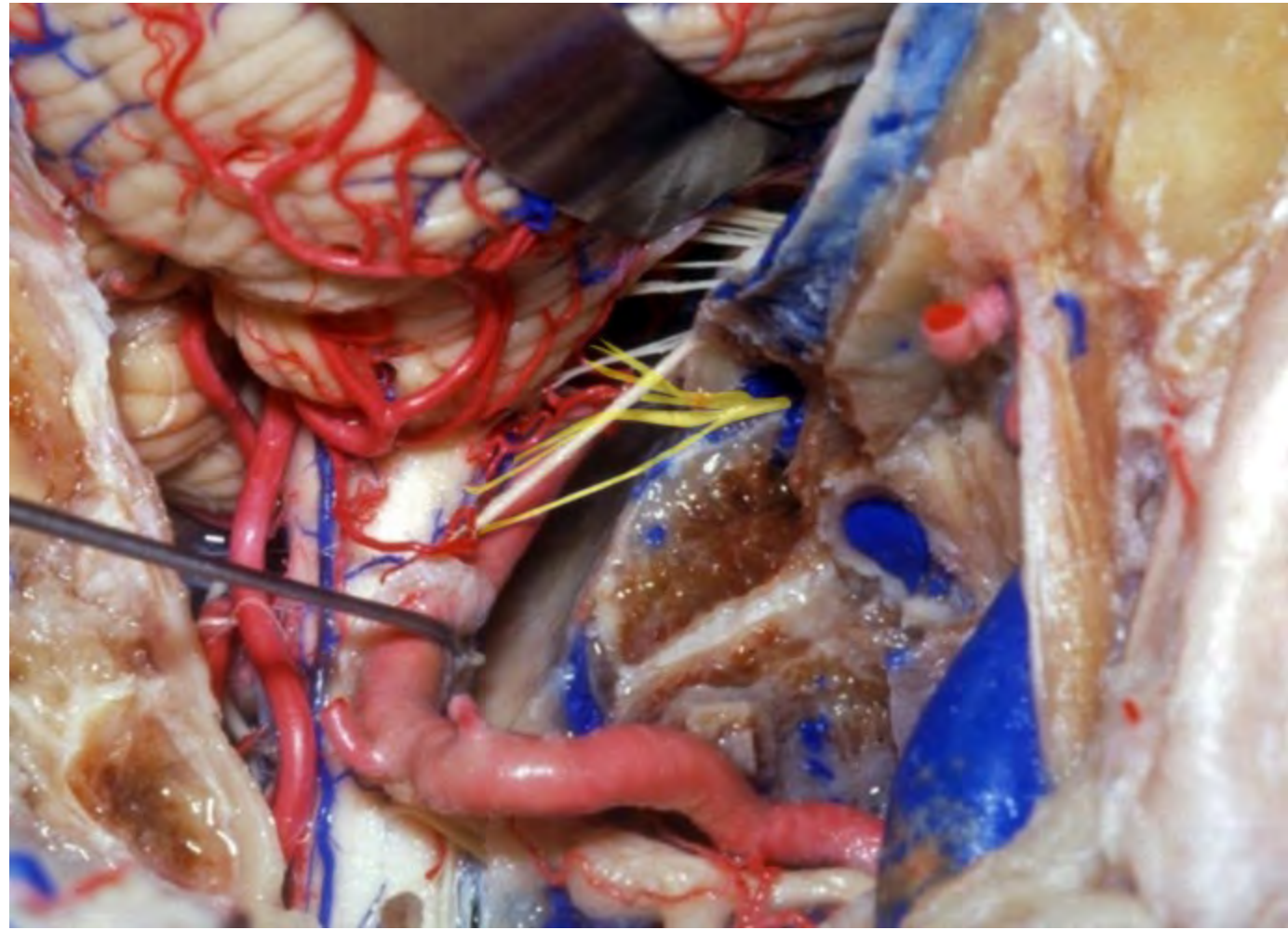


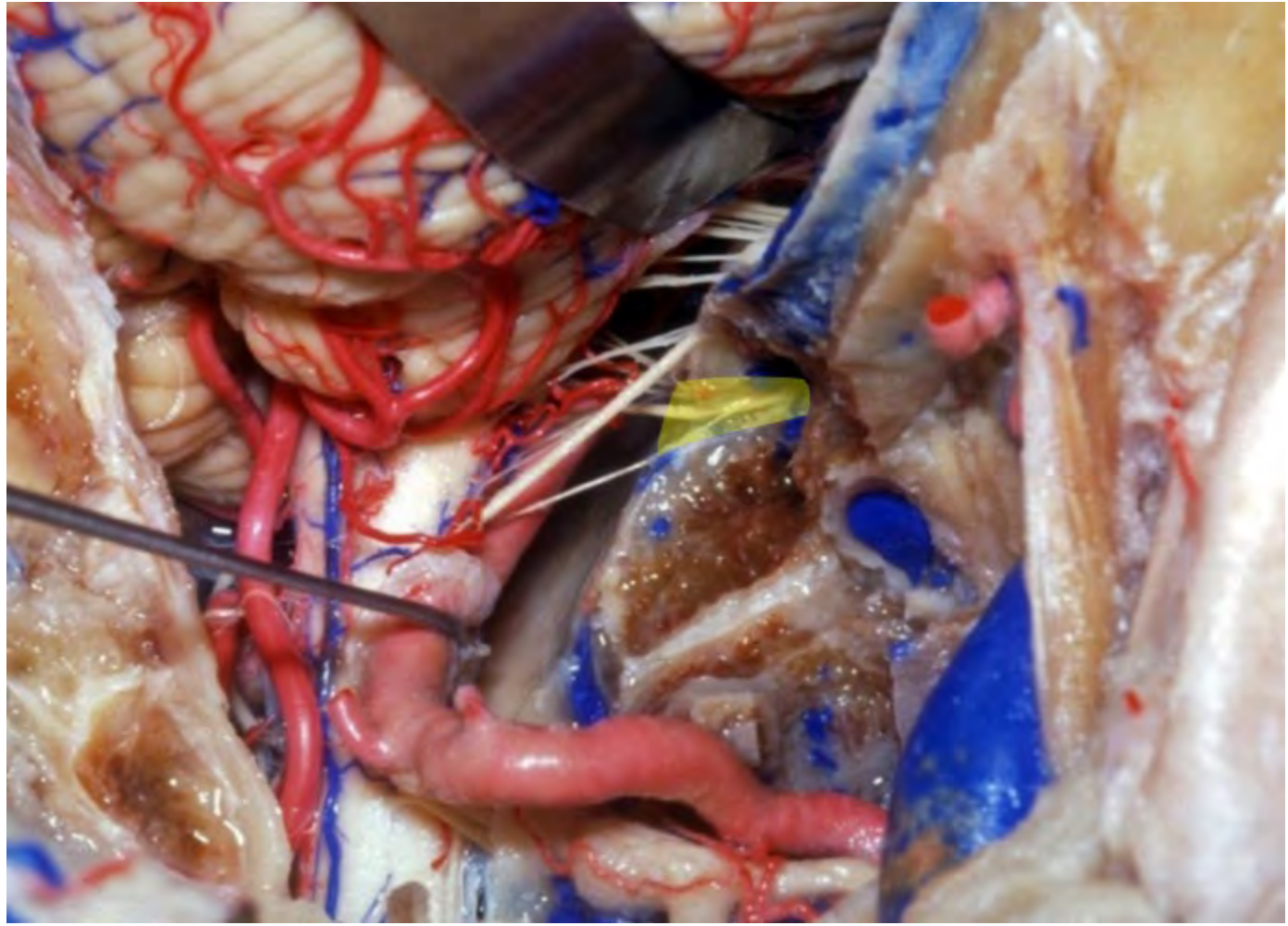


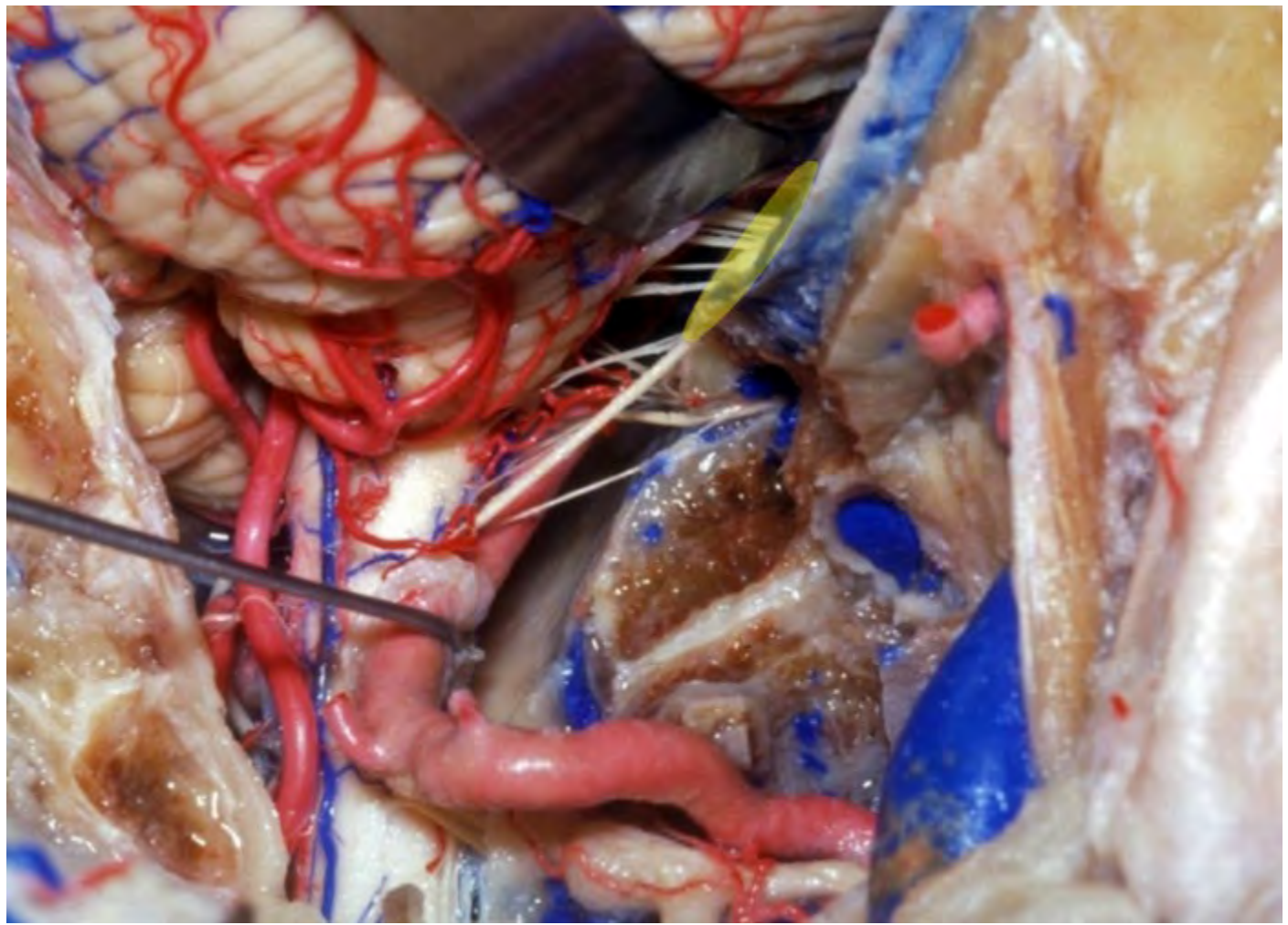















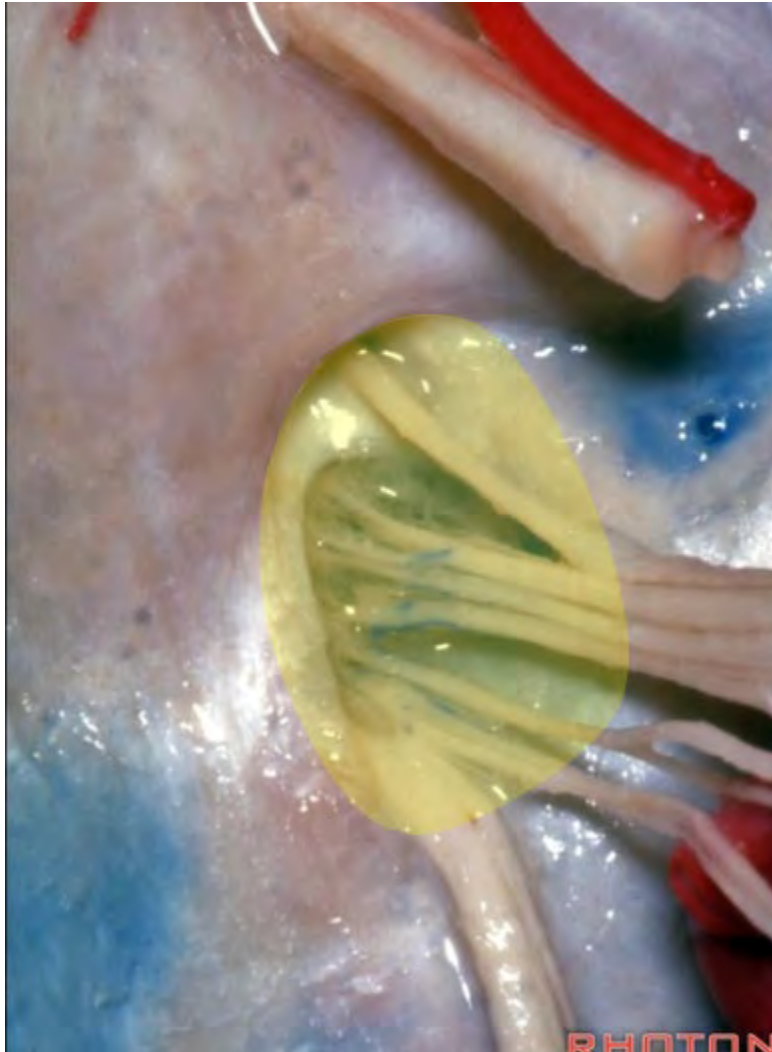
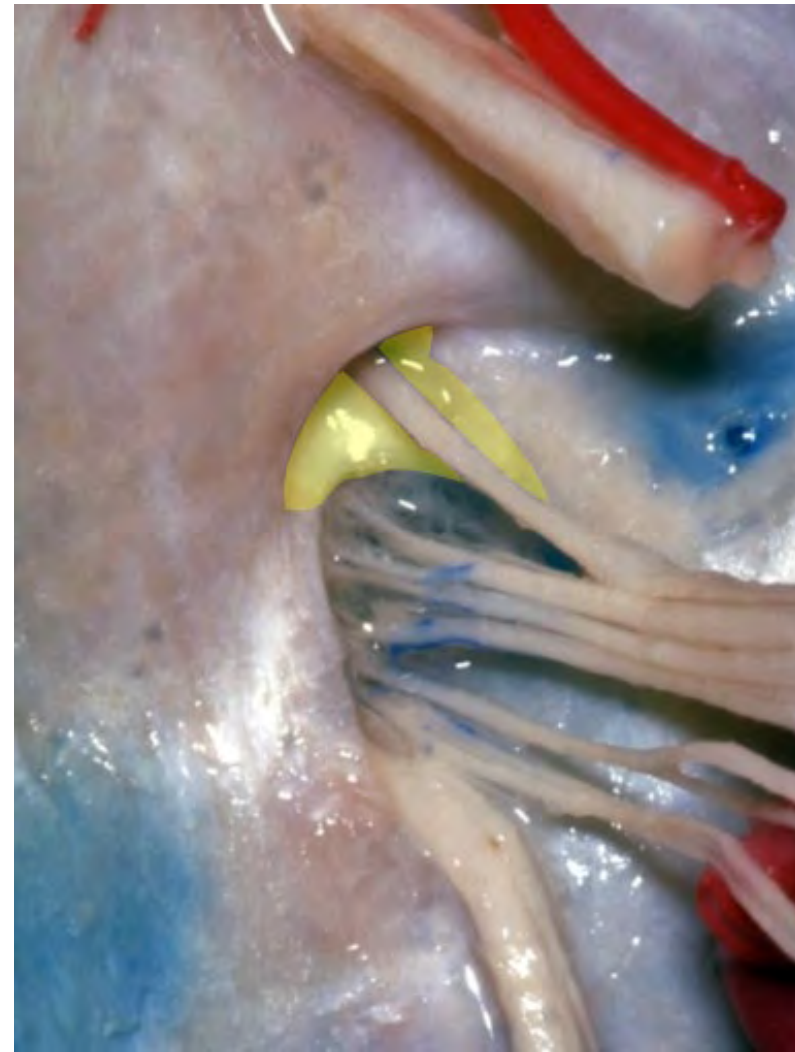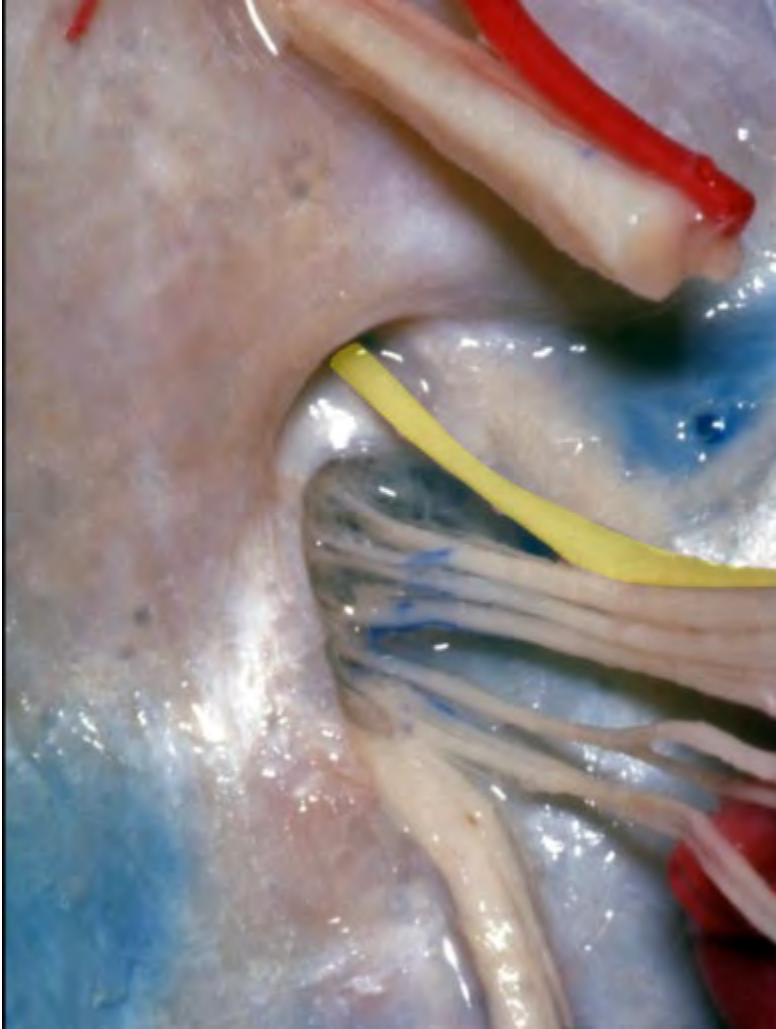
**Jugular foramen**



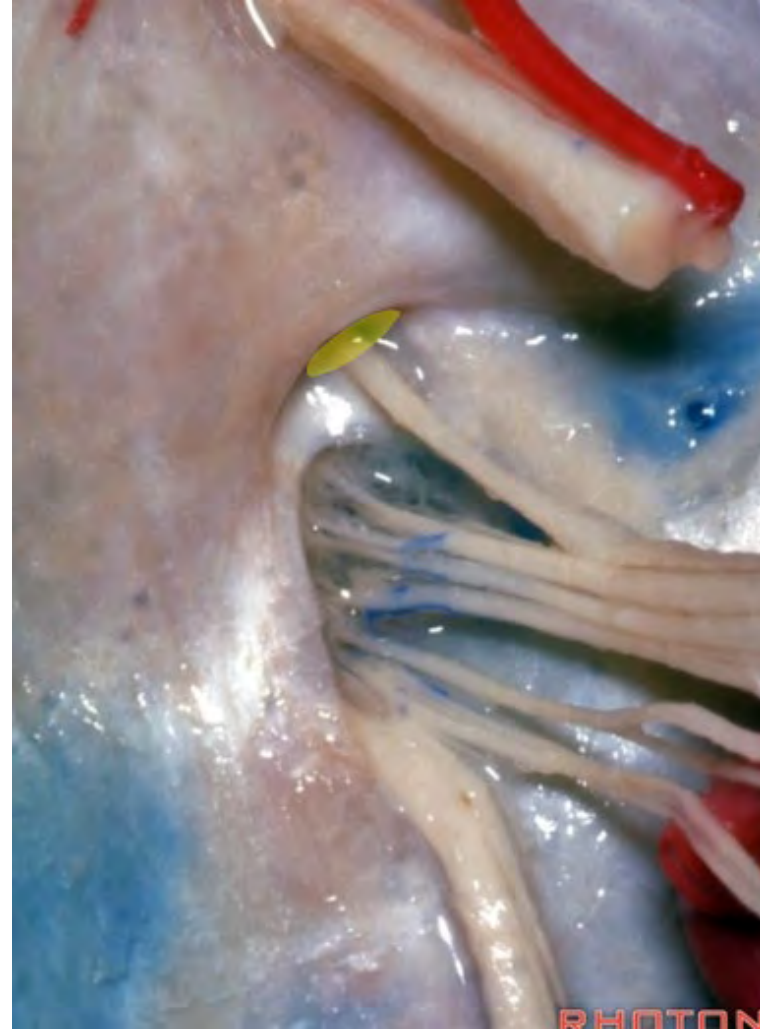**Septum of jugular foramen**



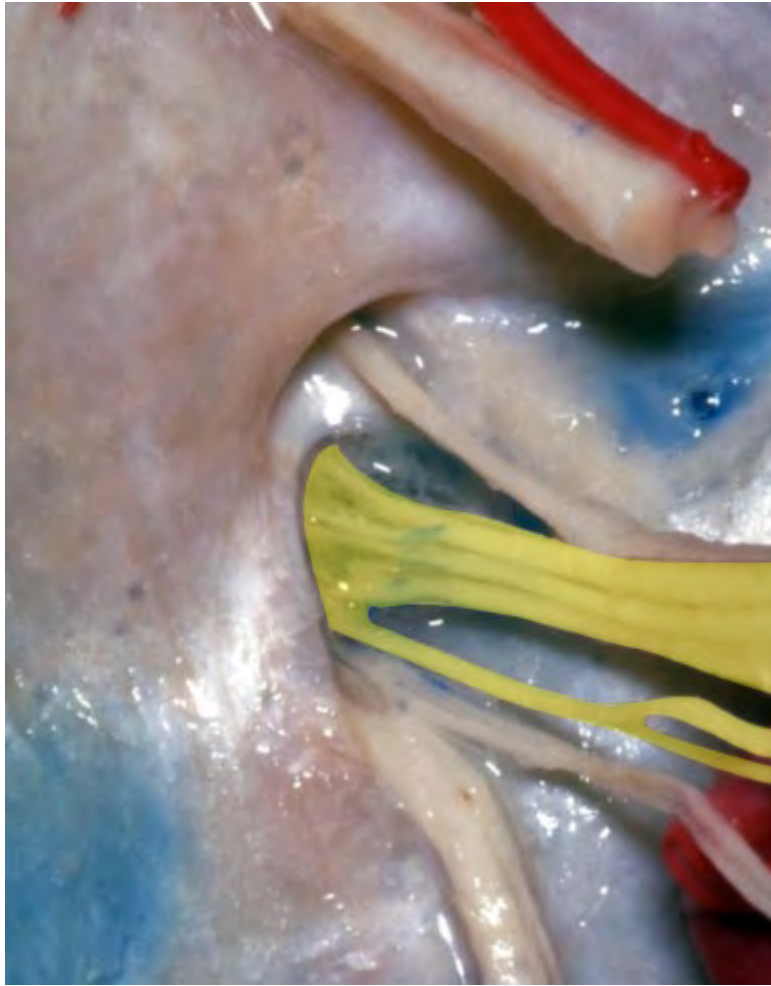**Glossopharyngeal nerve**



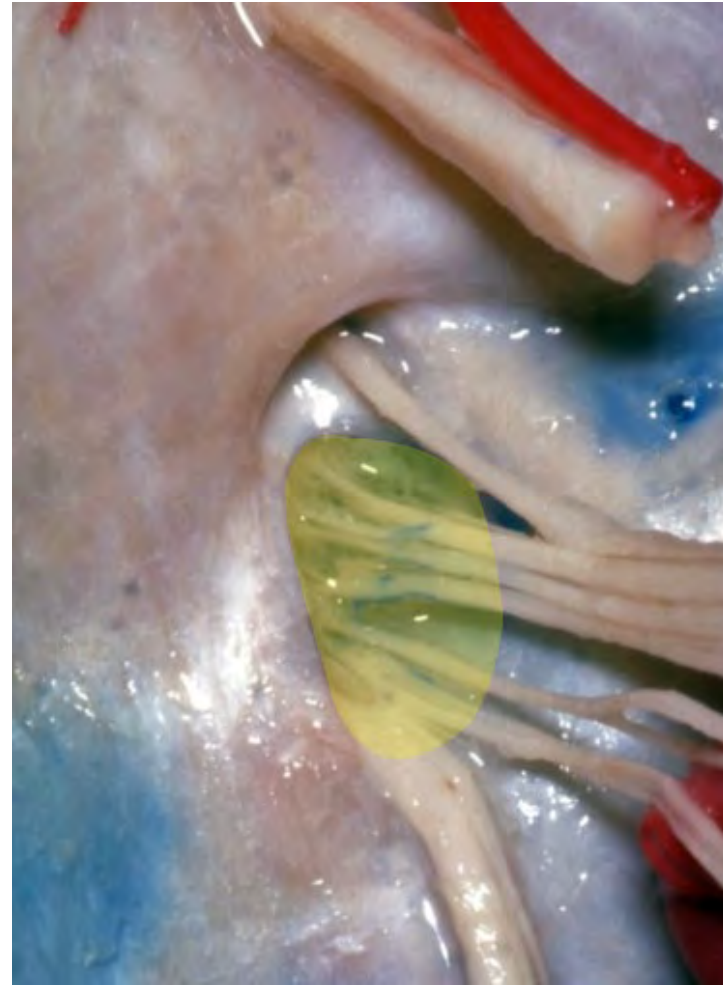**Glossopharyngeal meatus**



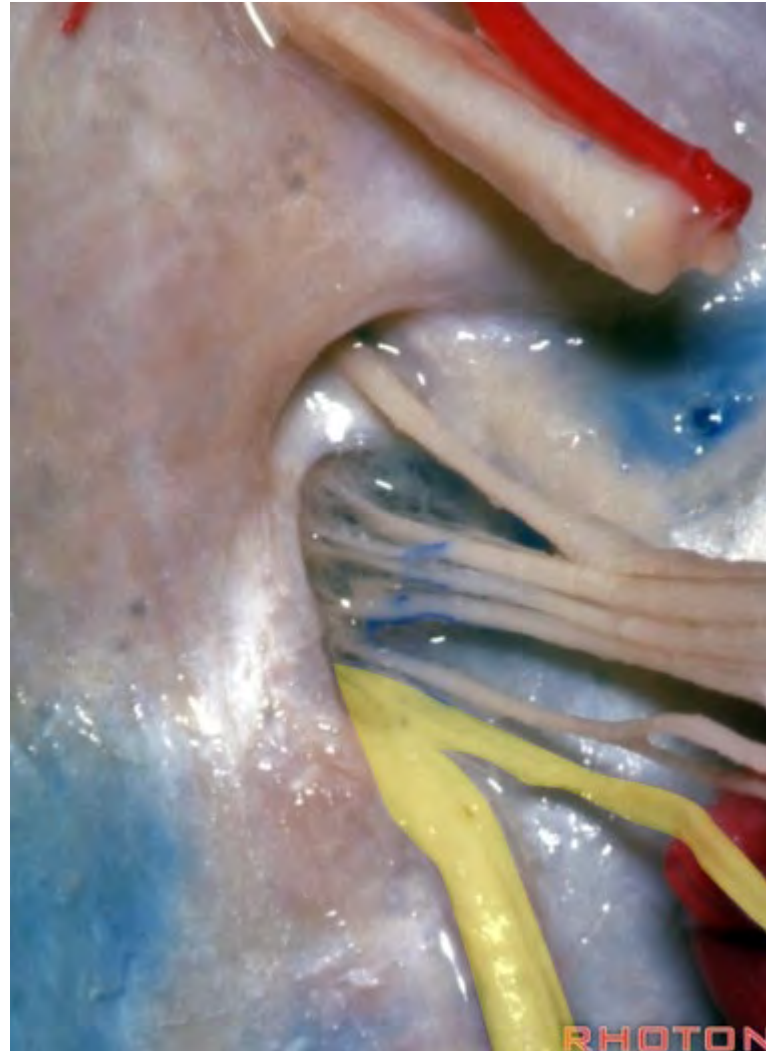**Vagus nerve**

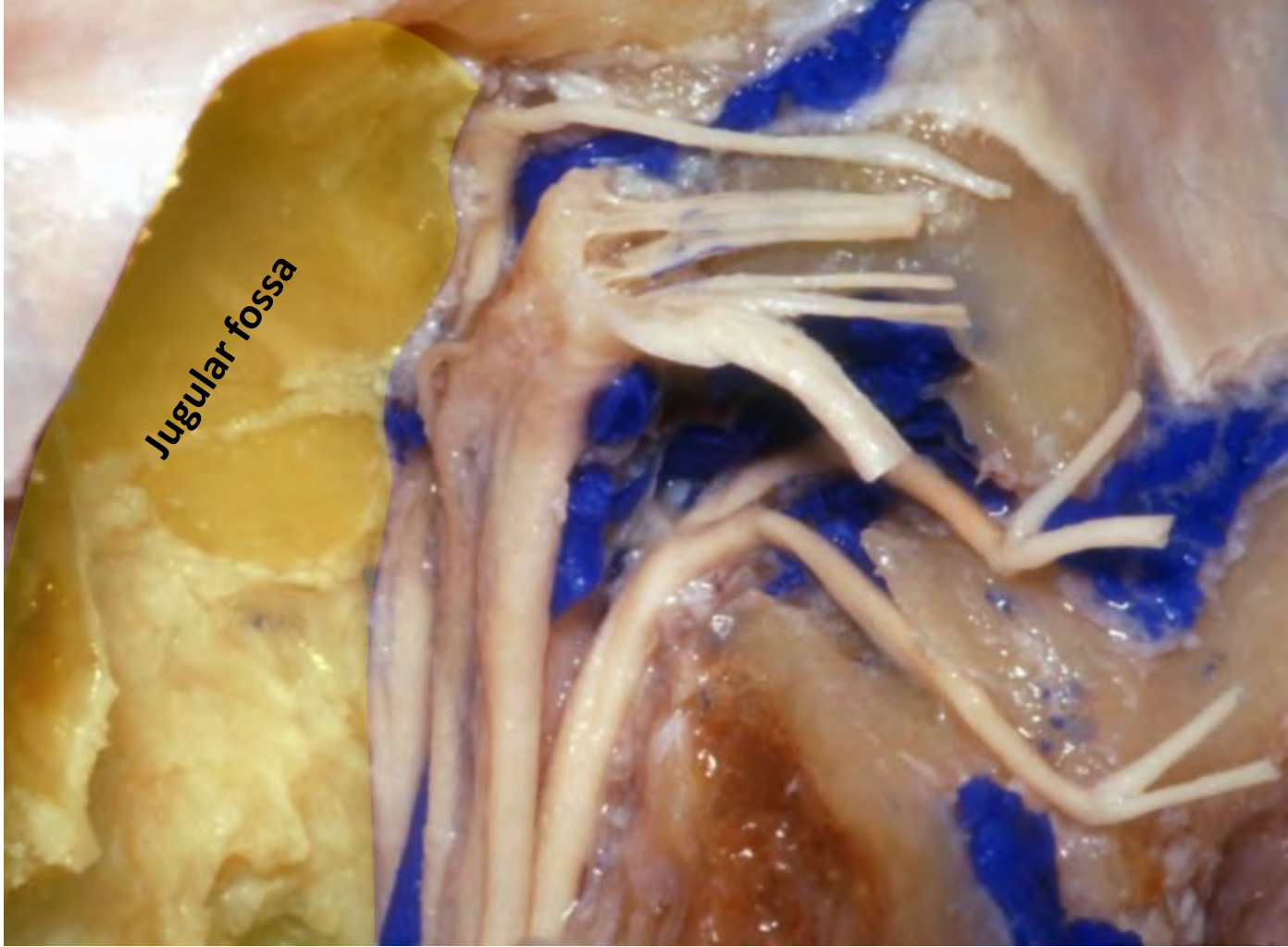


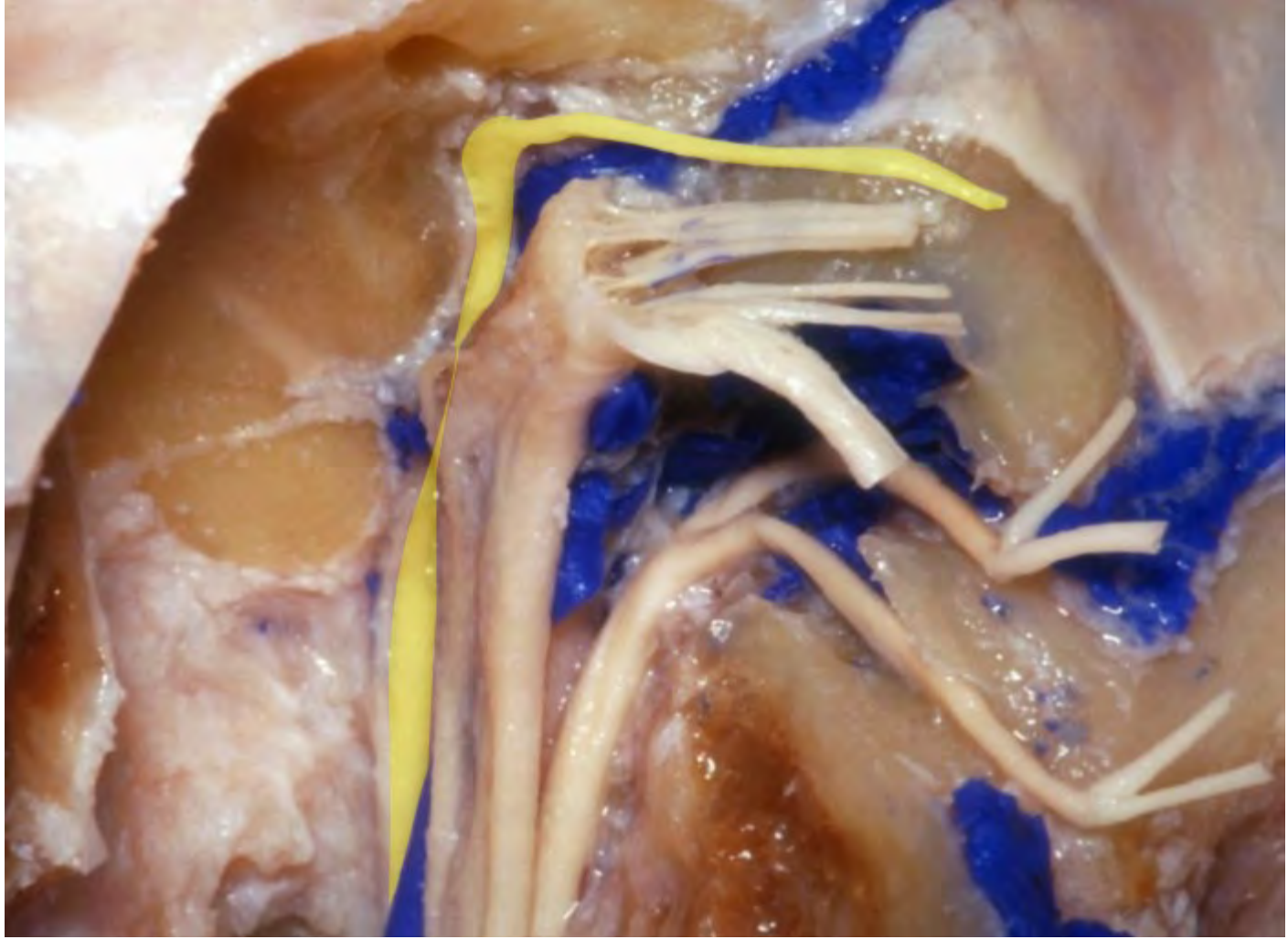
**Vagal meatus**

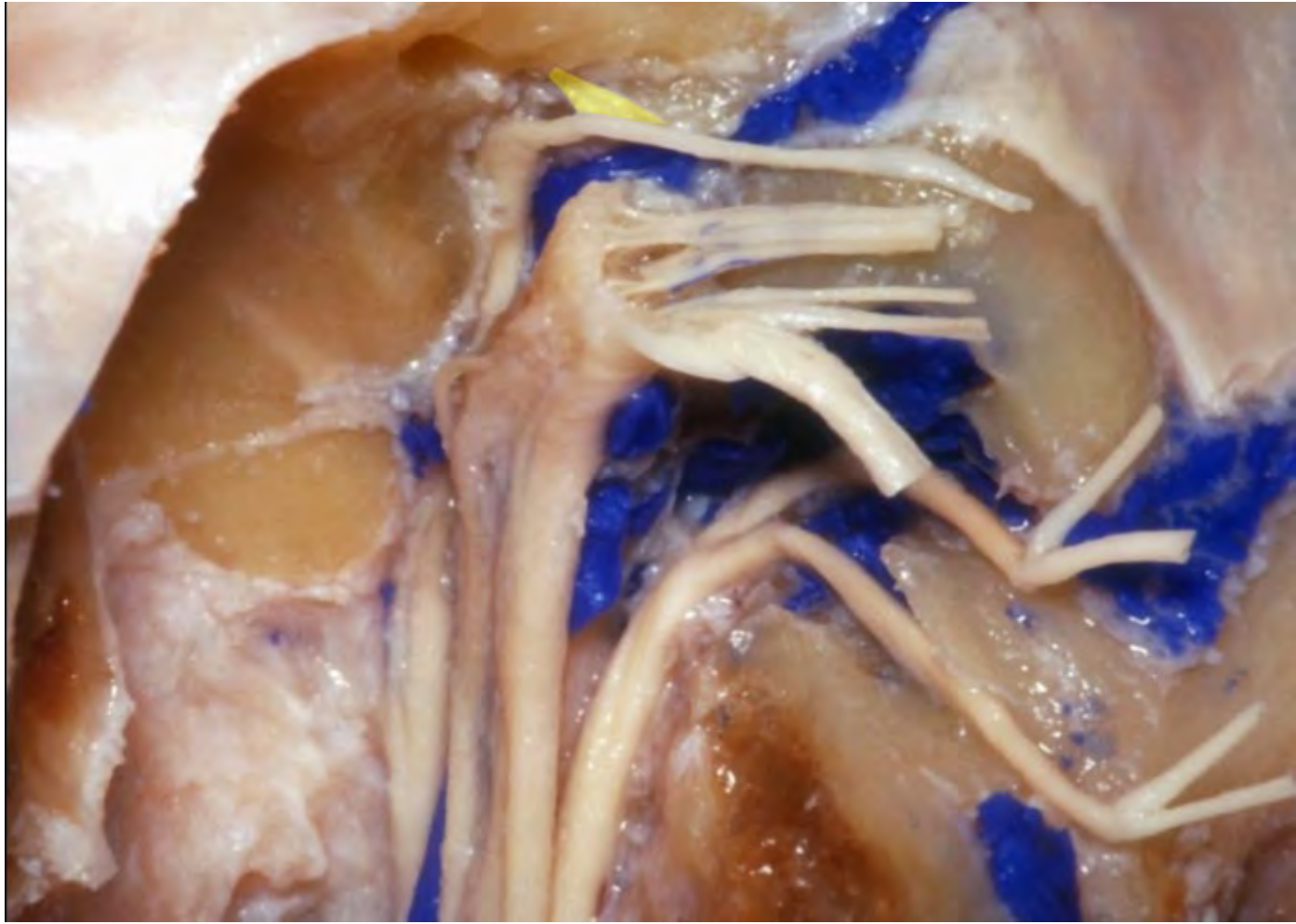


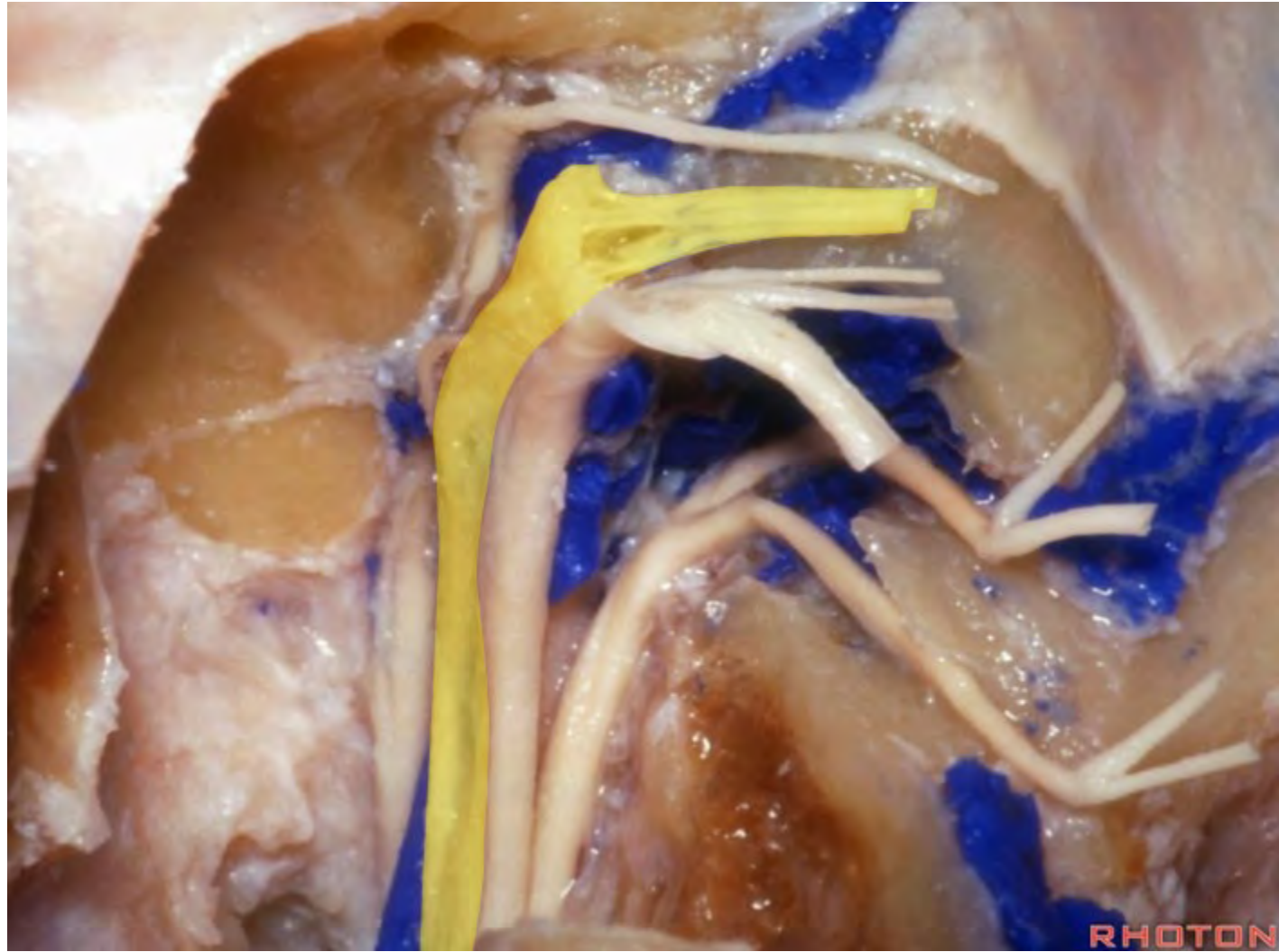
## Spinal accessory nerve





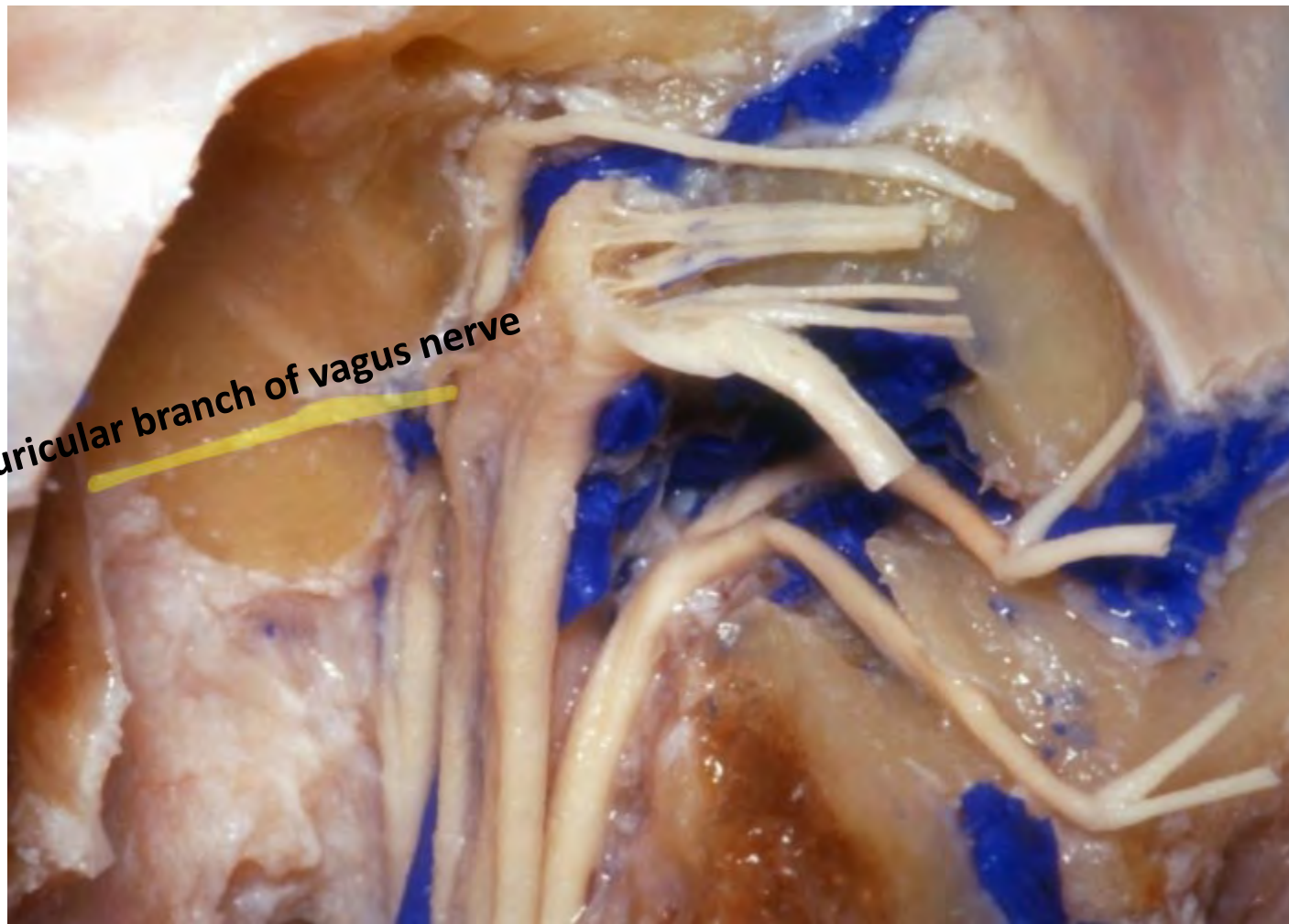

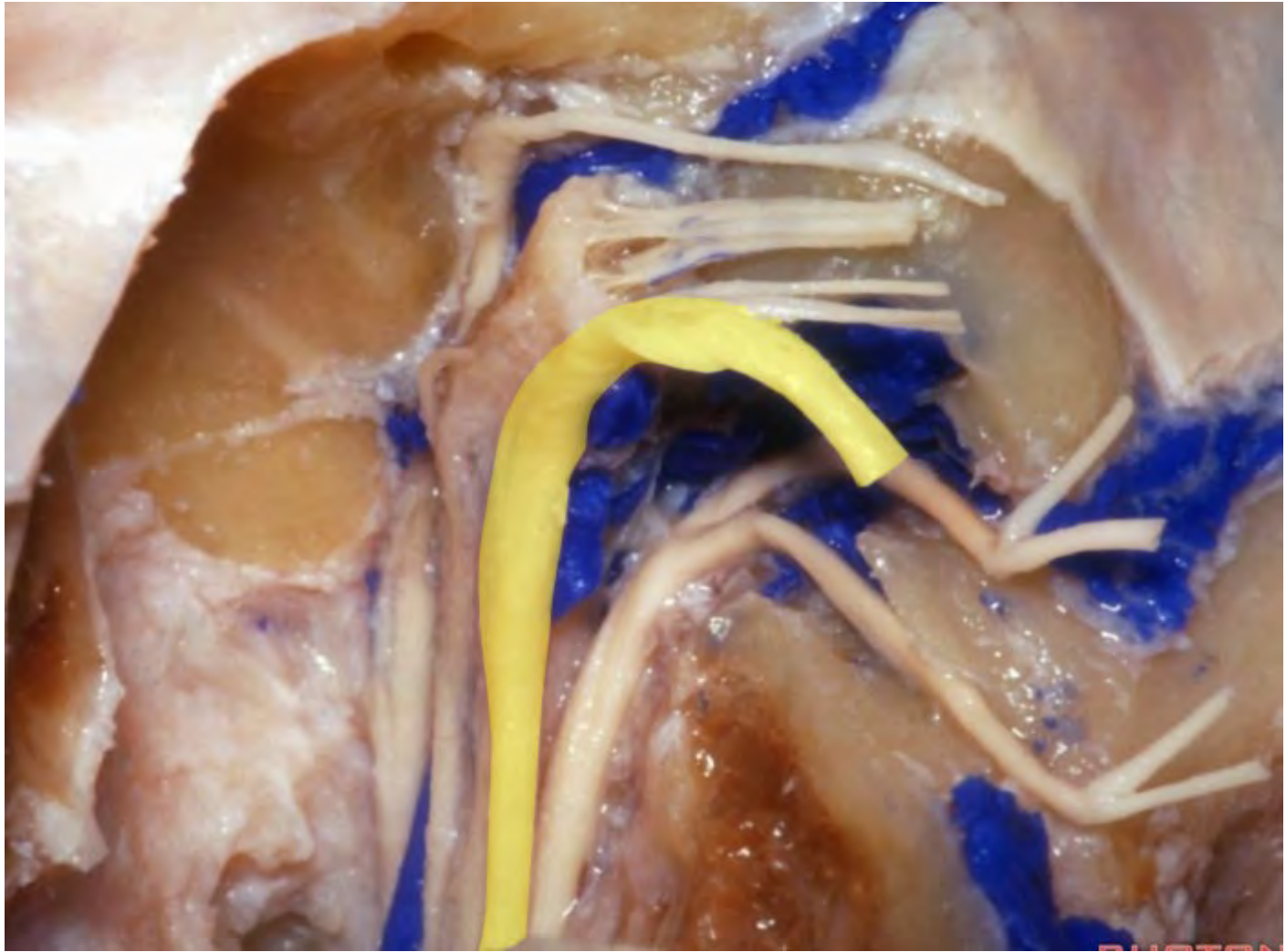


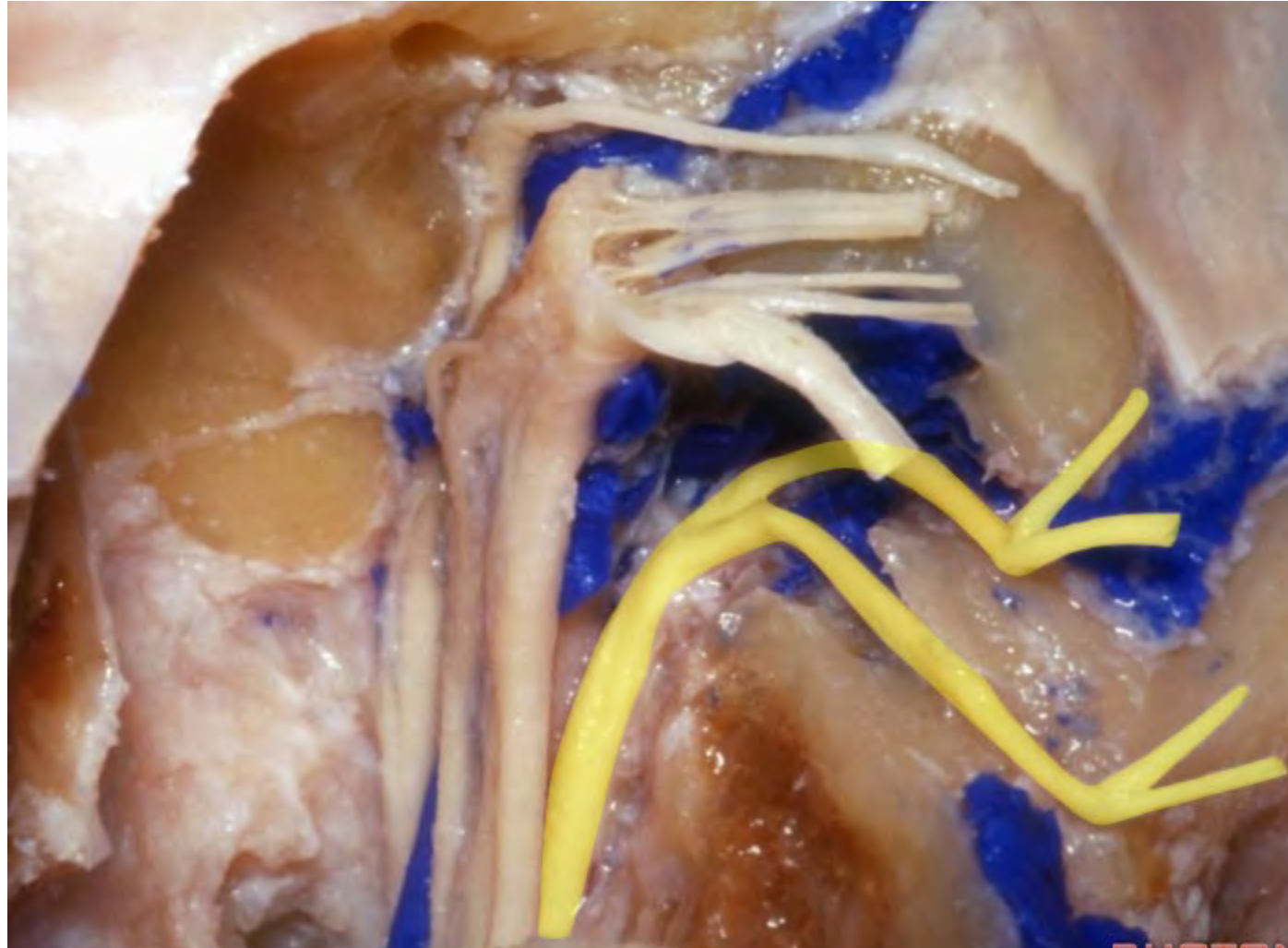




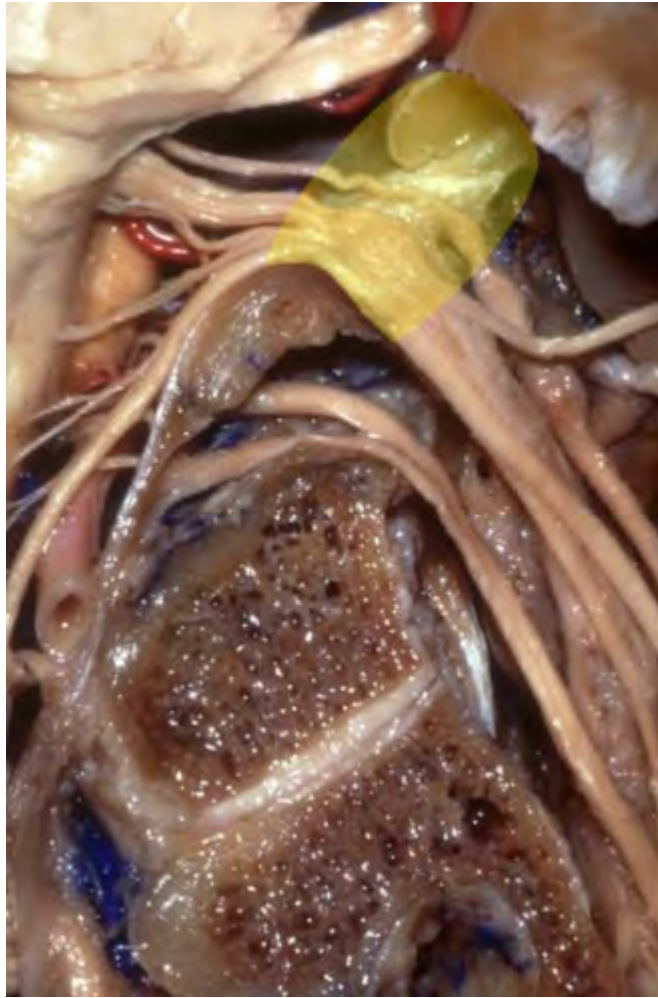**Auricular branch of vagus nerve**



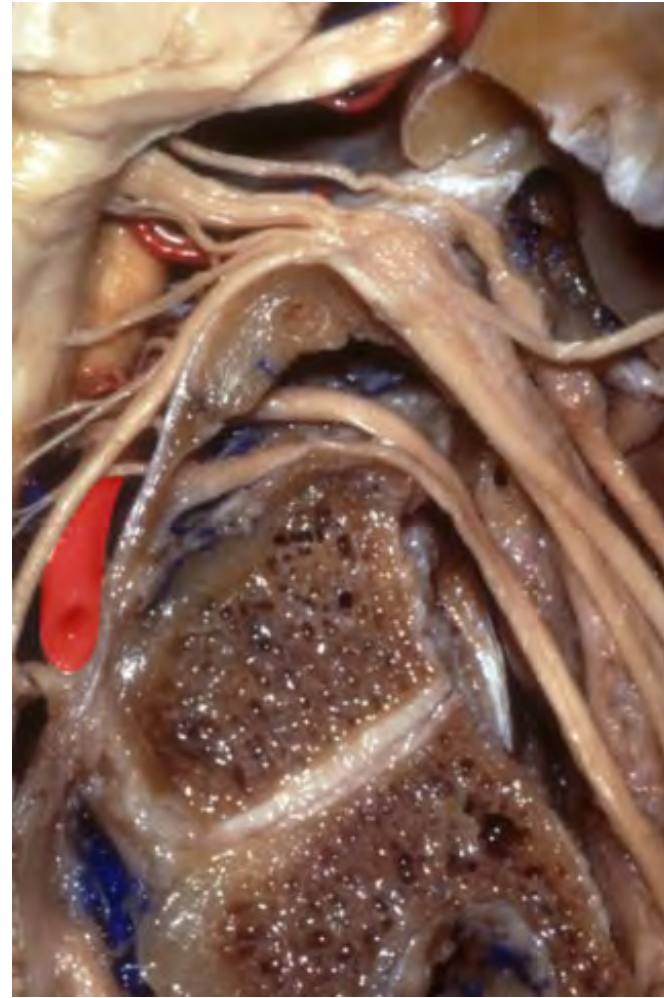


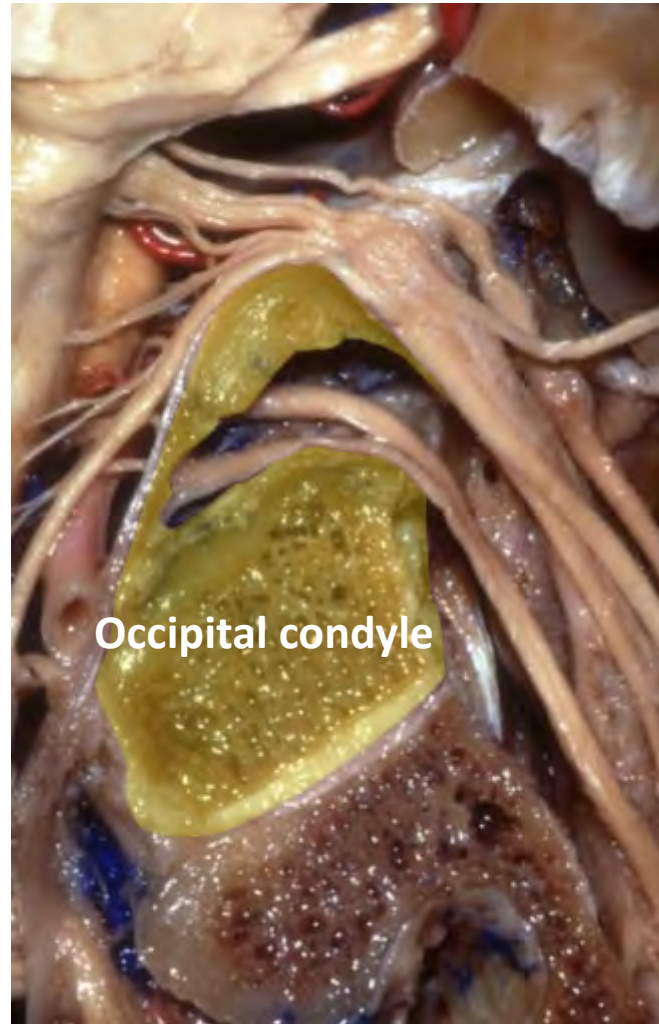


**Jugular foramen**

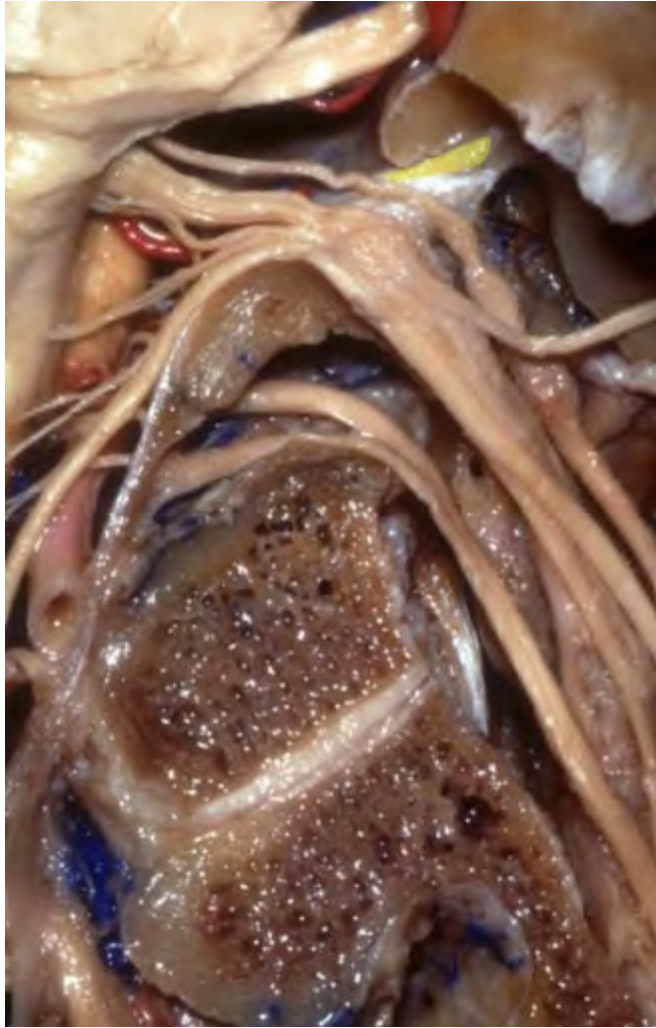

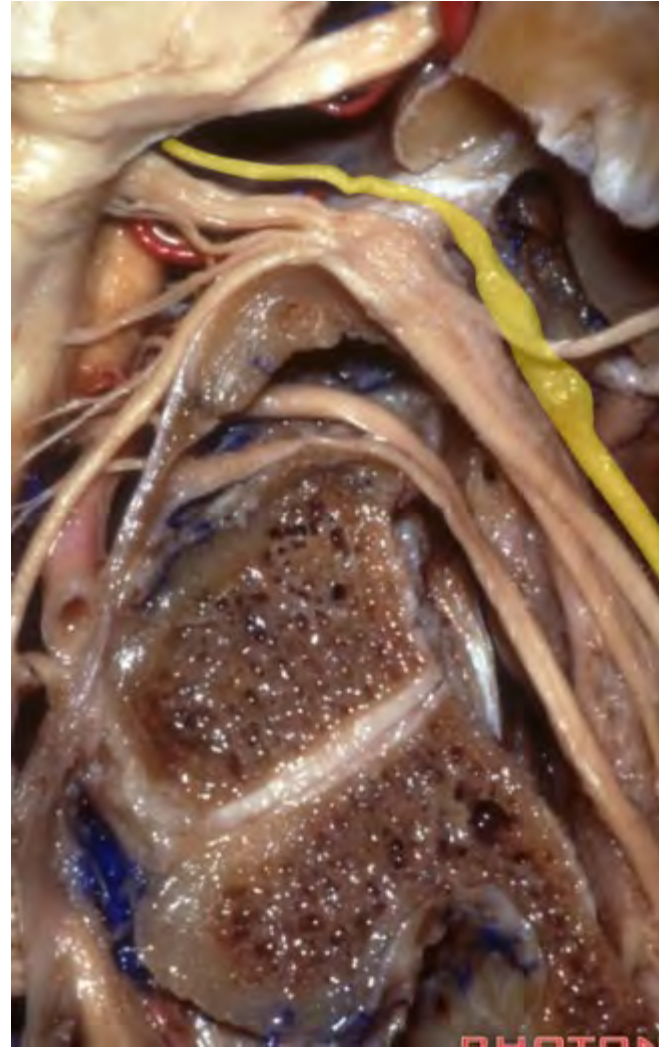**Vertebral artery**

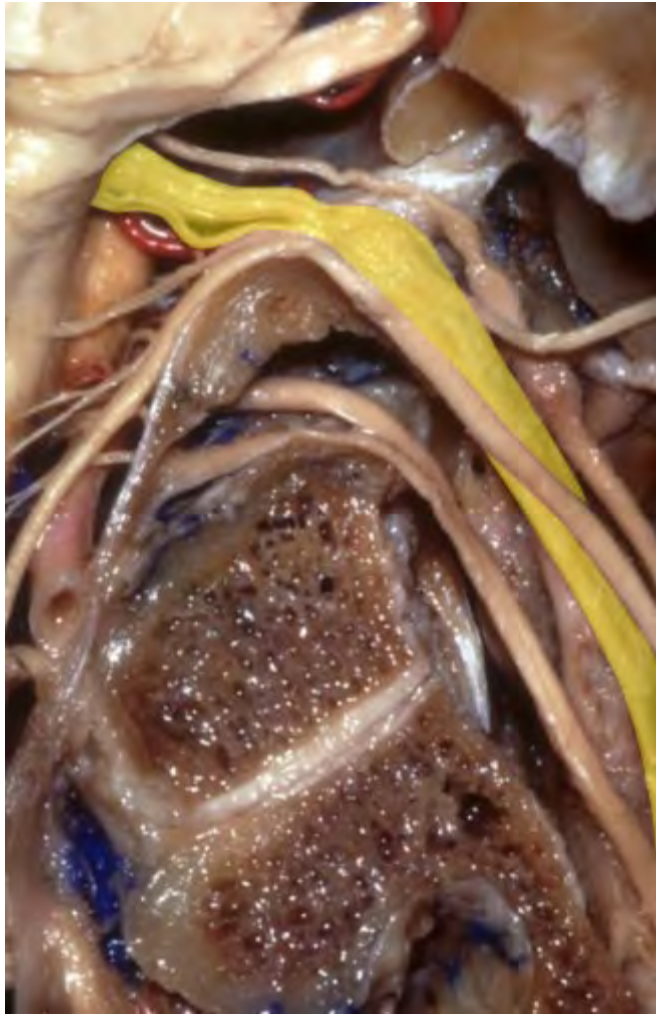



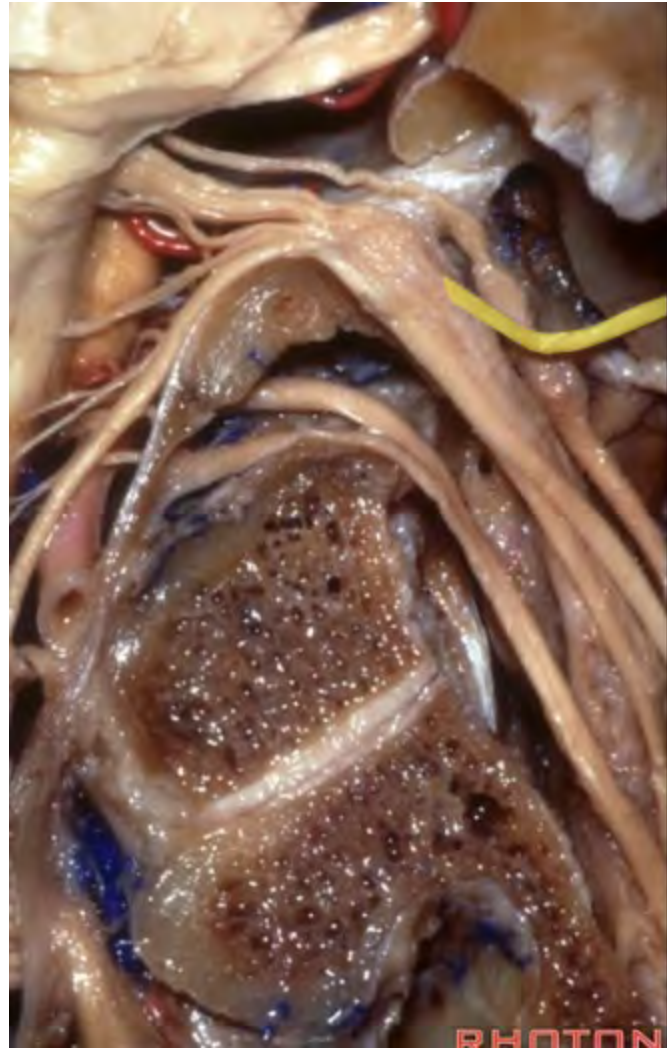Occipital condyle

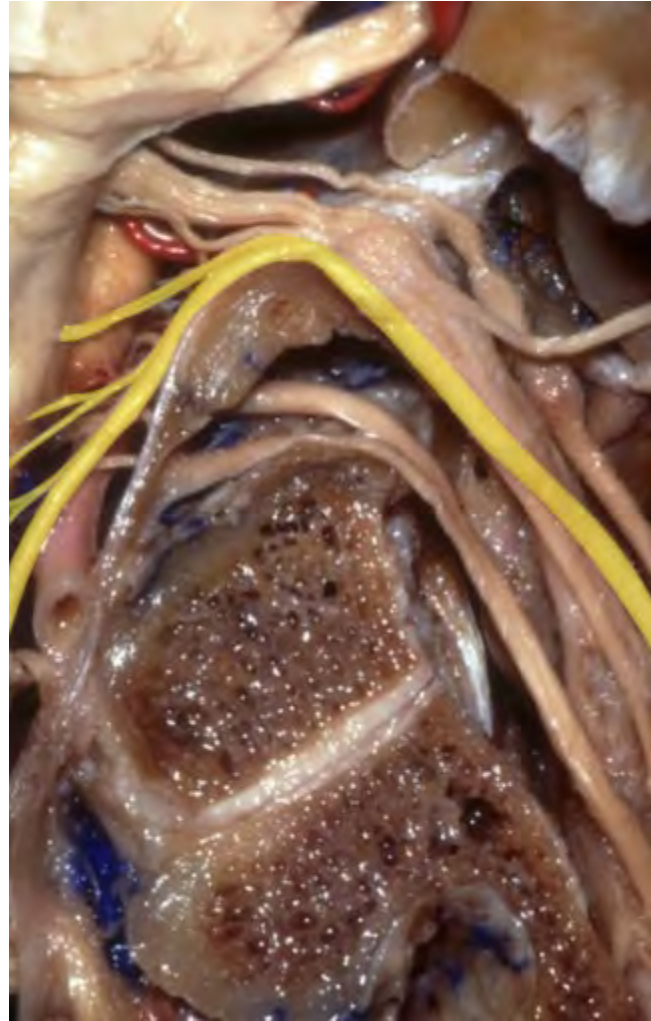


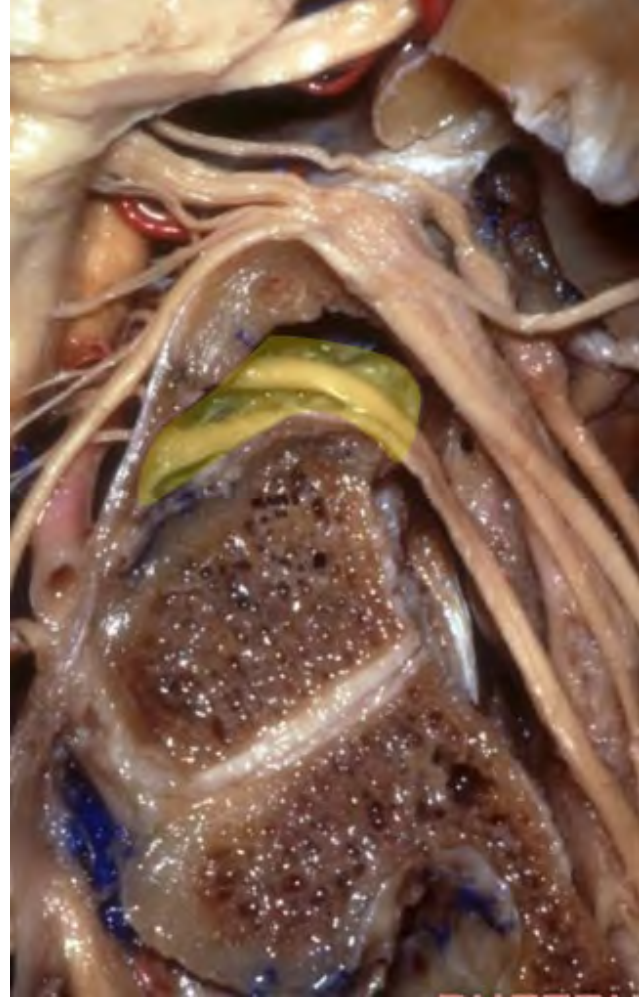
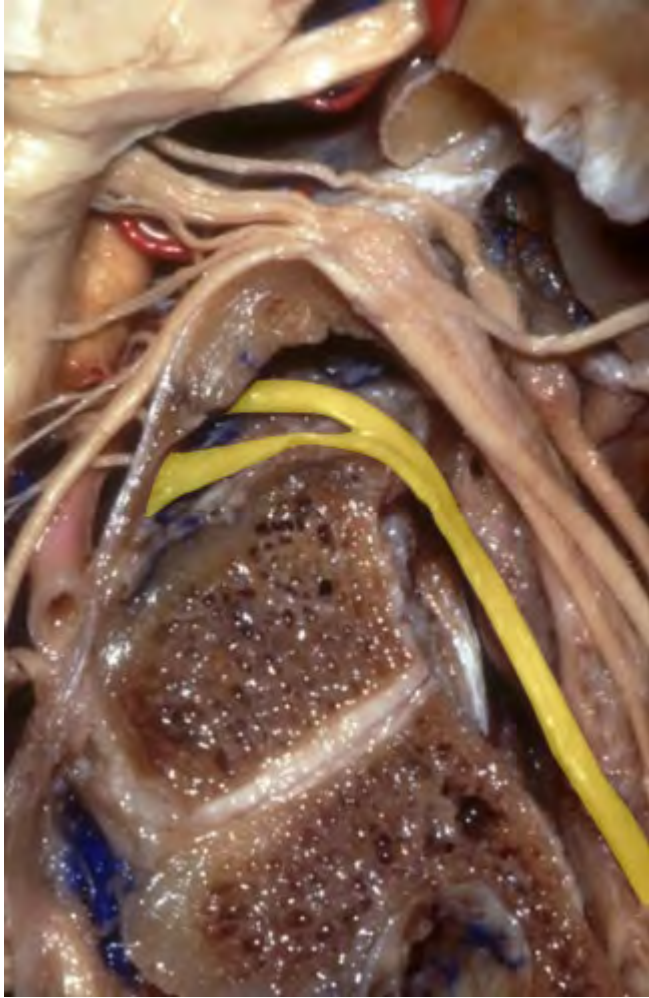



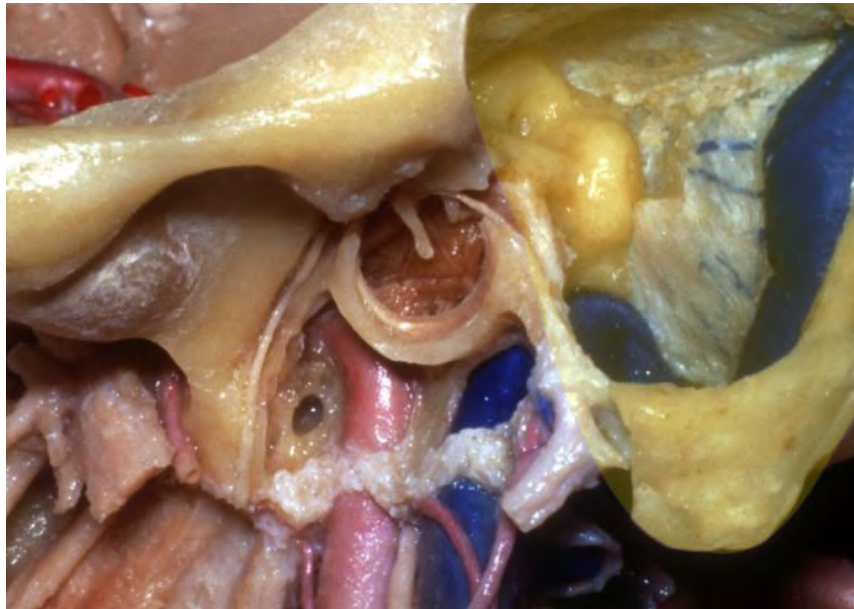






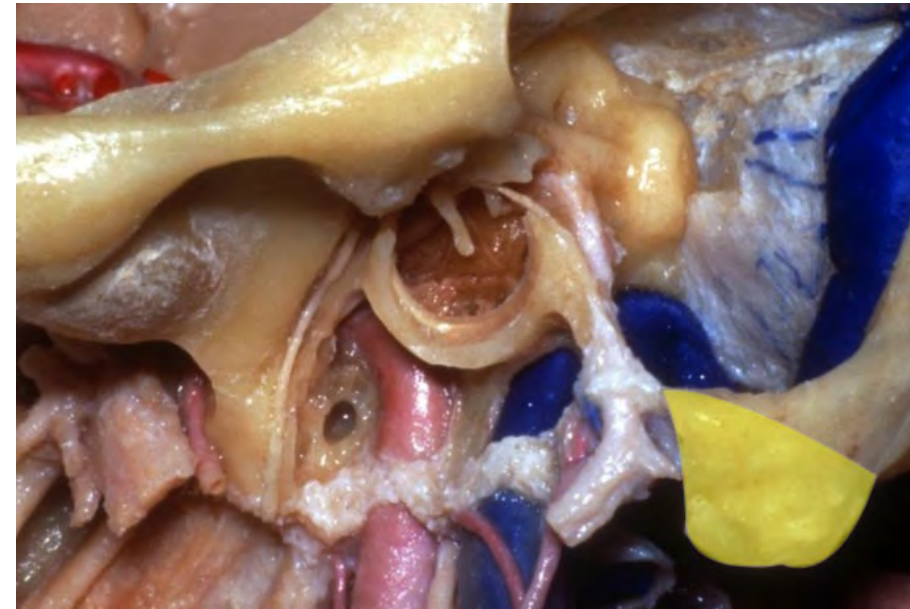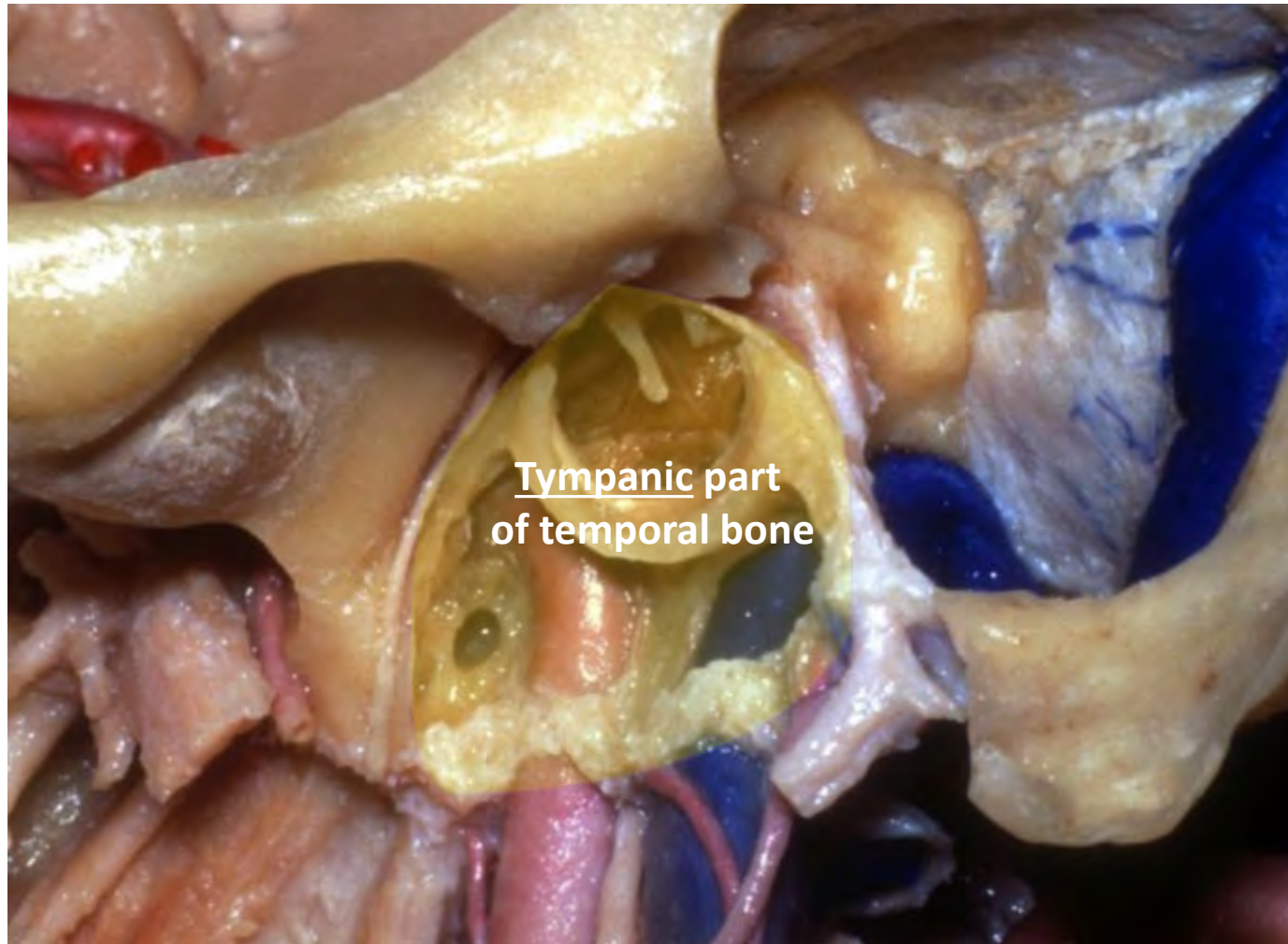


**Mastoid process**



**Mastoid tip**

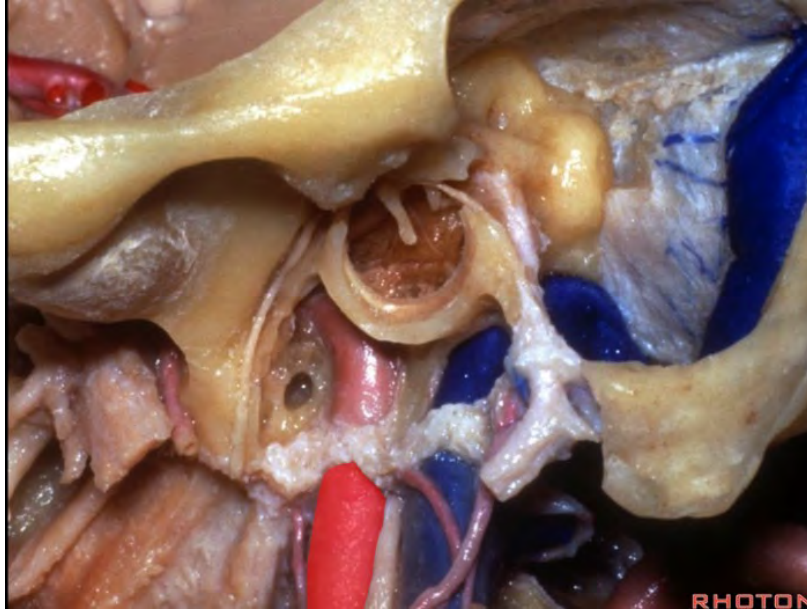




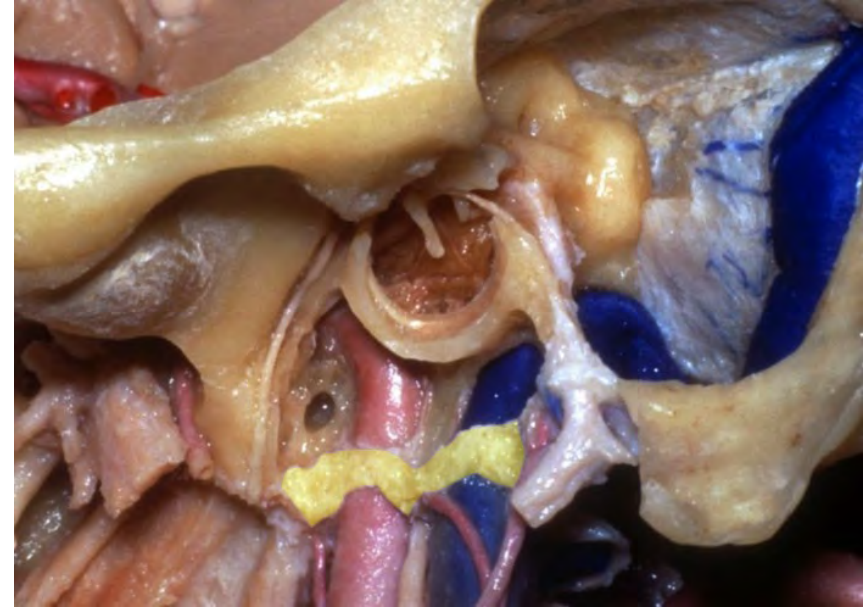
Tympanic part  
of temporal bone



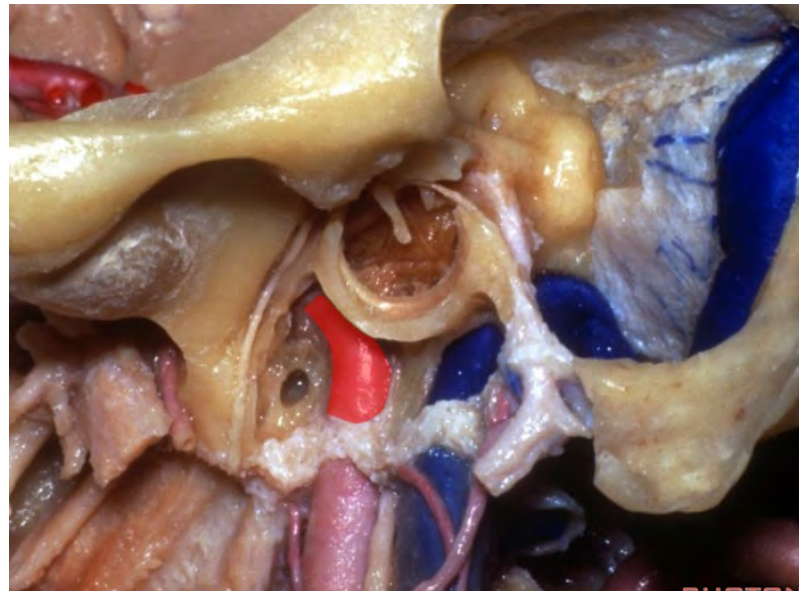
**Cervical portion of ICA**

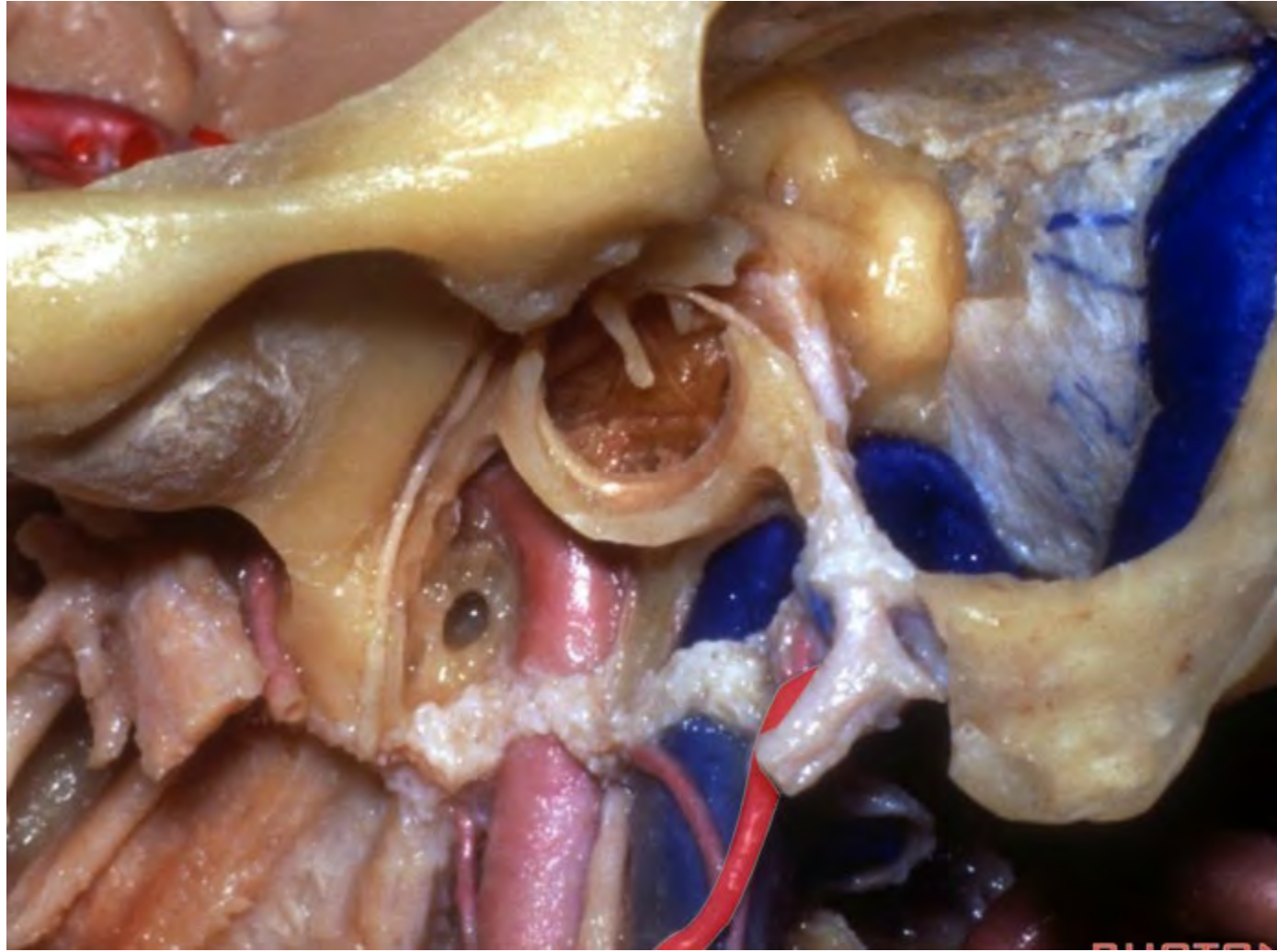


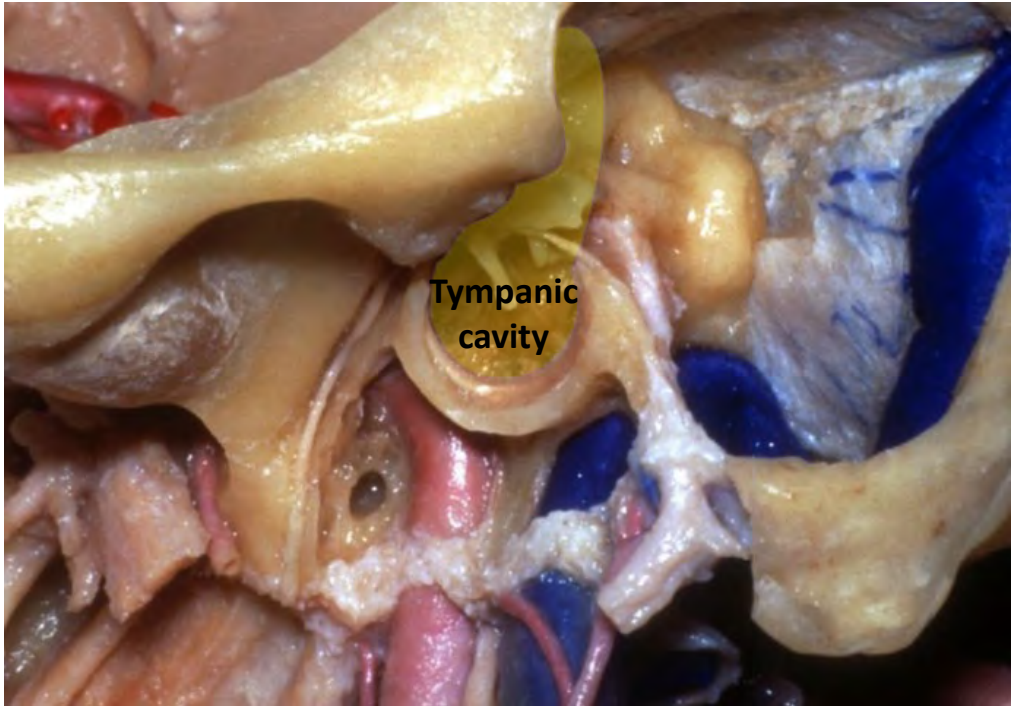
**Carotid sheath**



**Petrous segment of ICA**

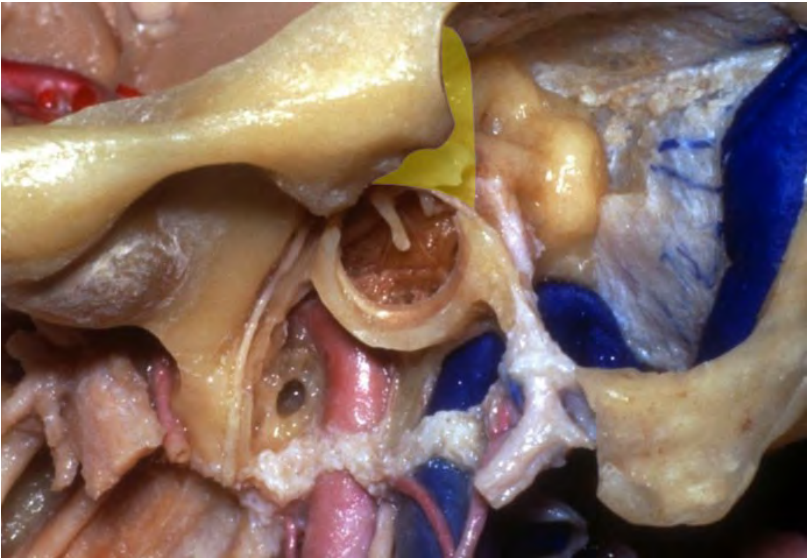




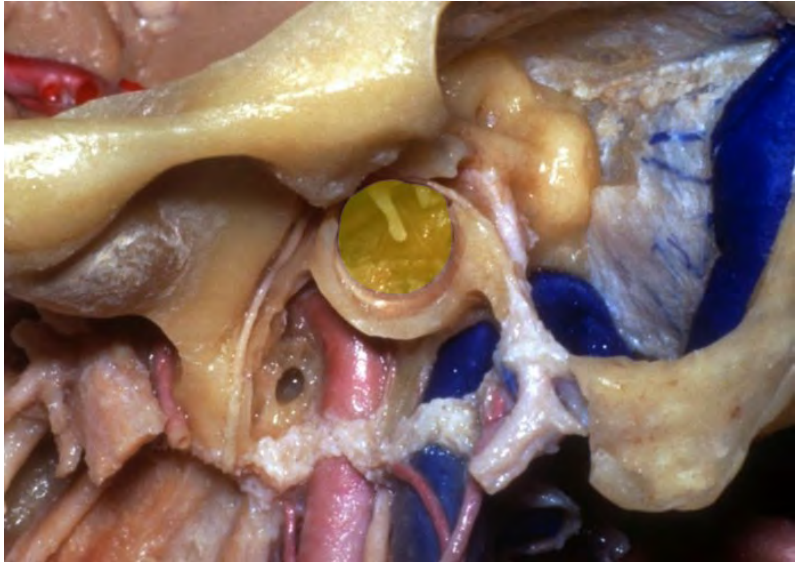


Tympanic  
cavity

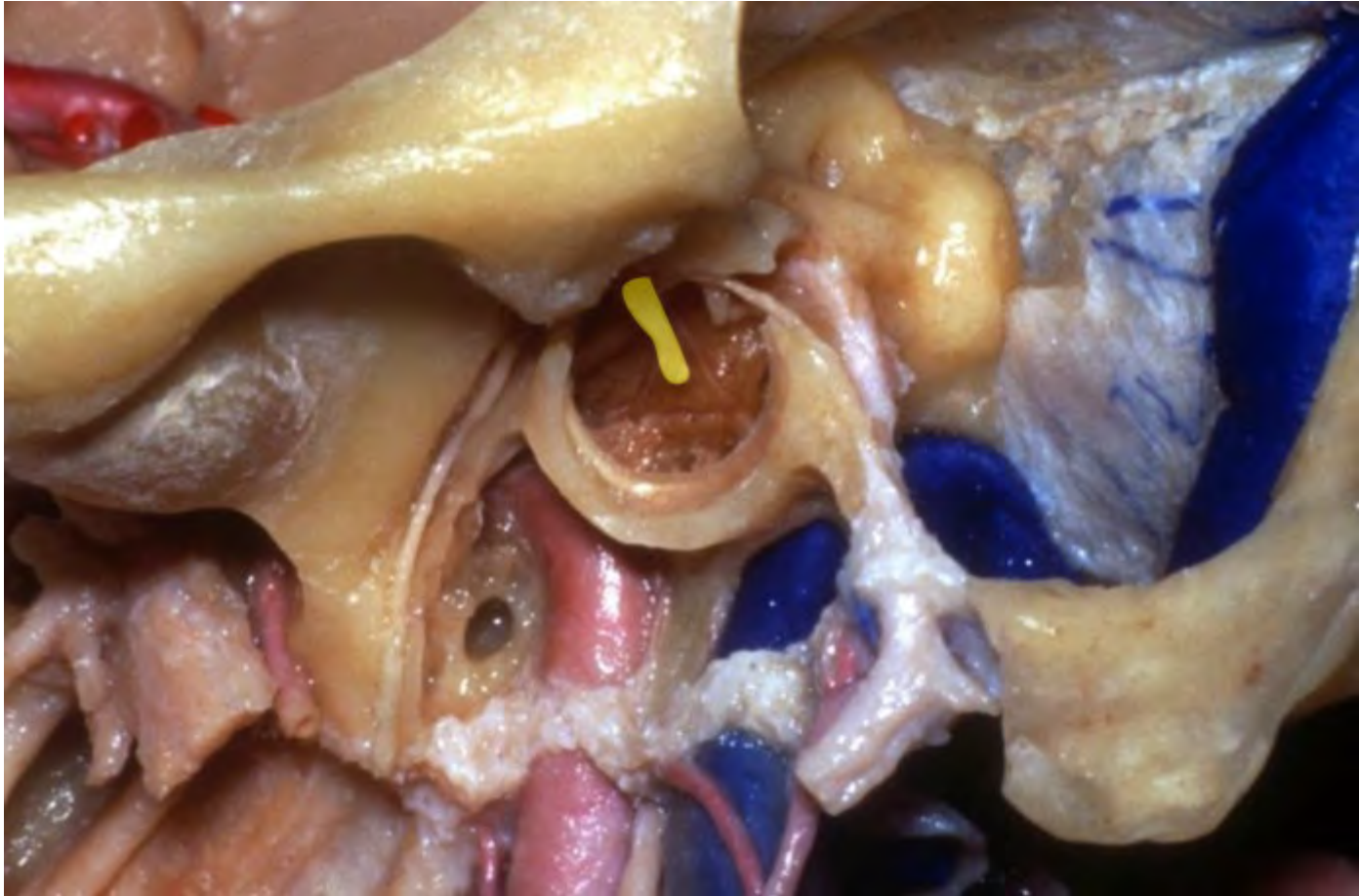
**Epitympanum**

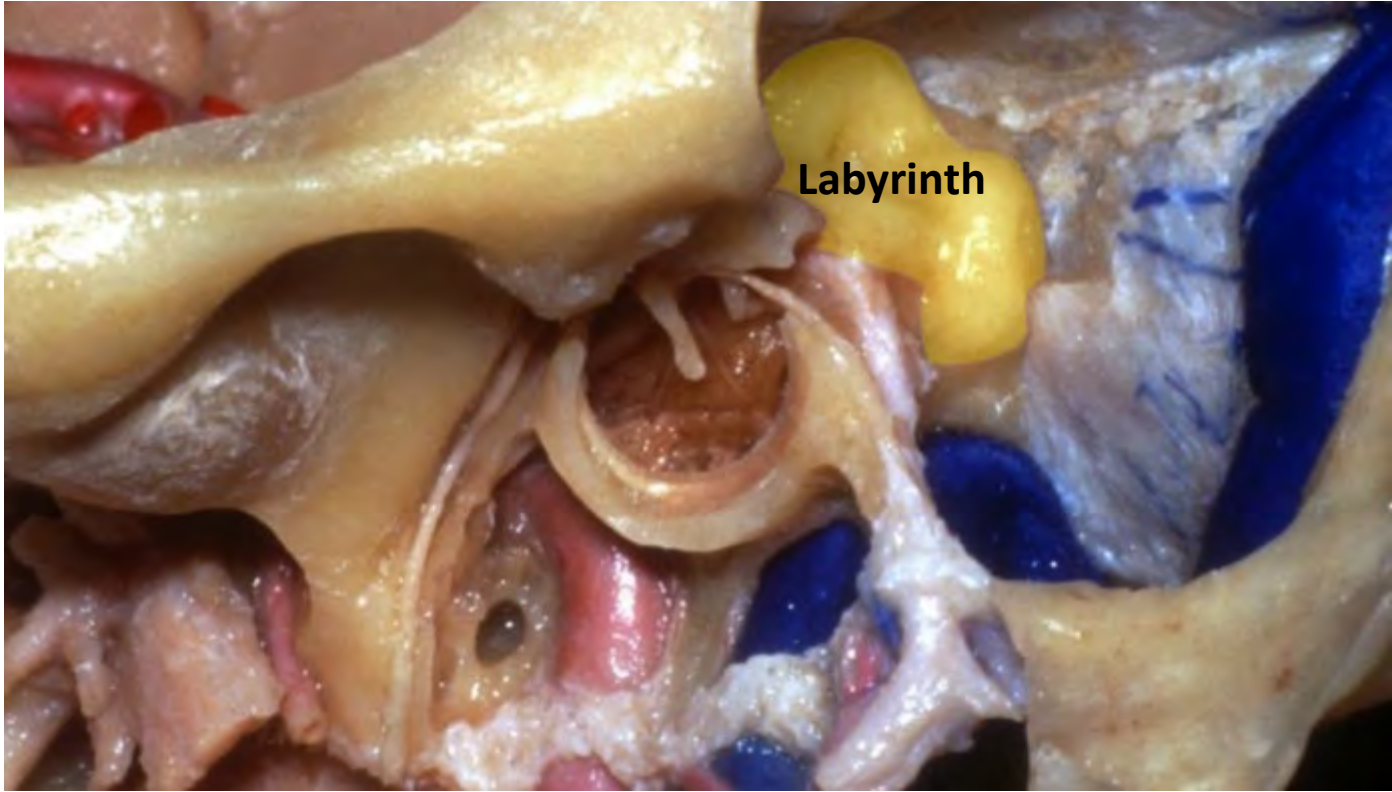


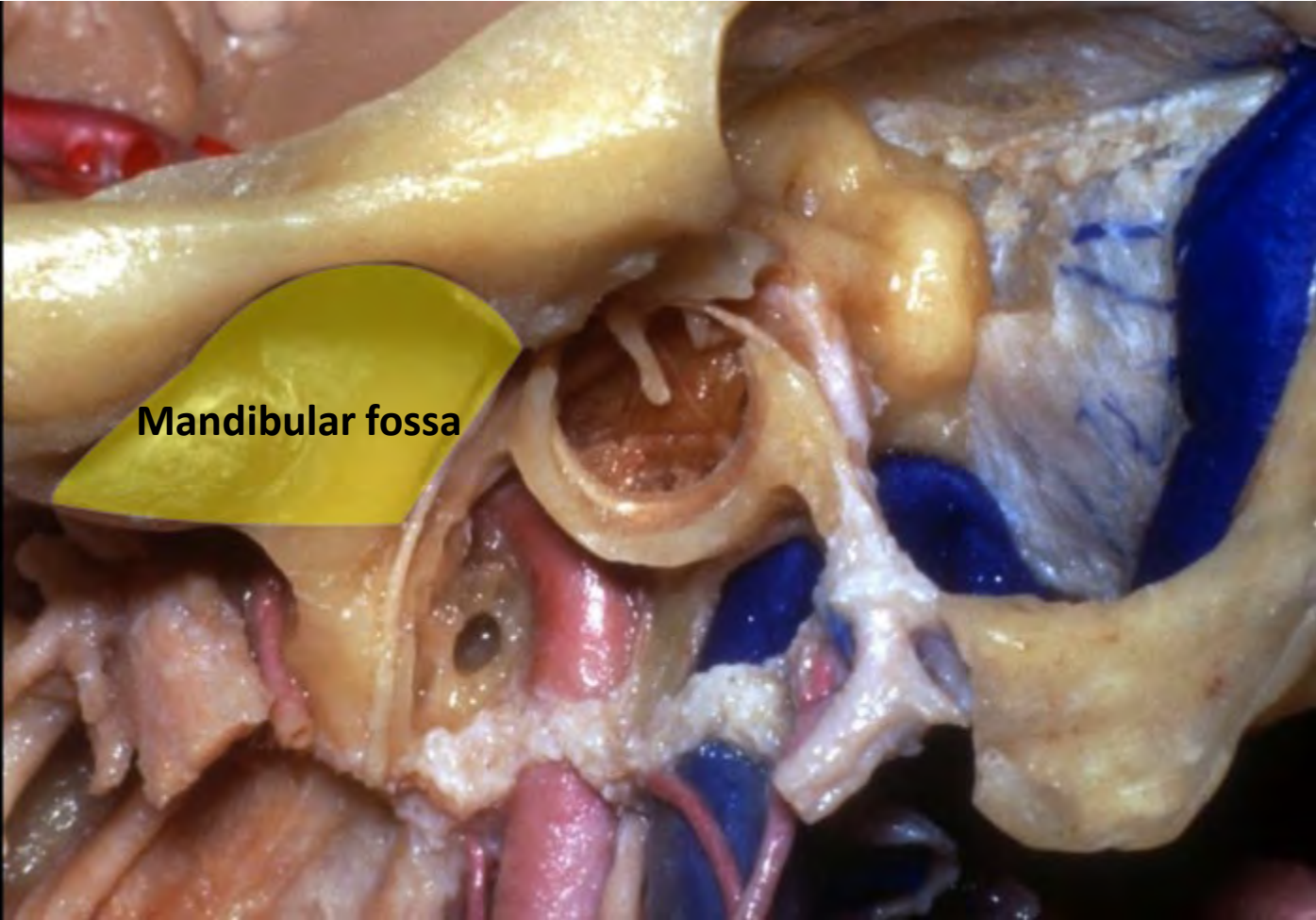
**Mesotympanum**







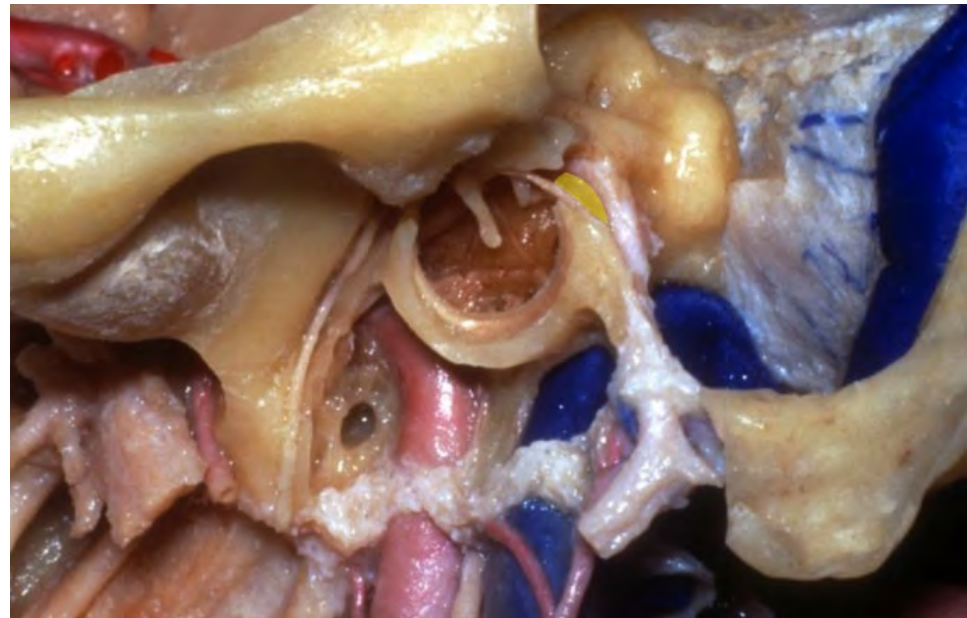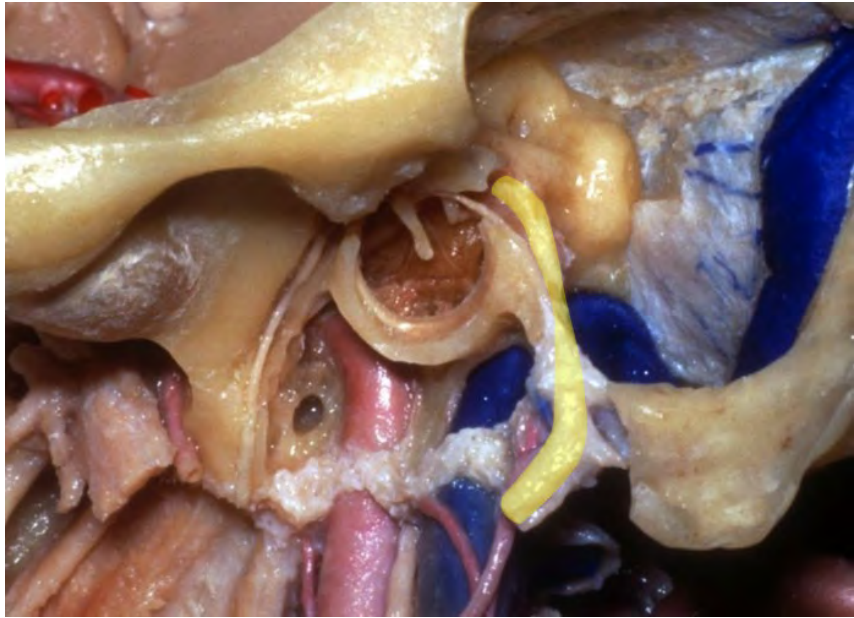


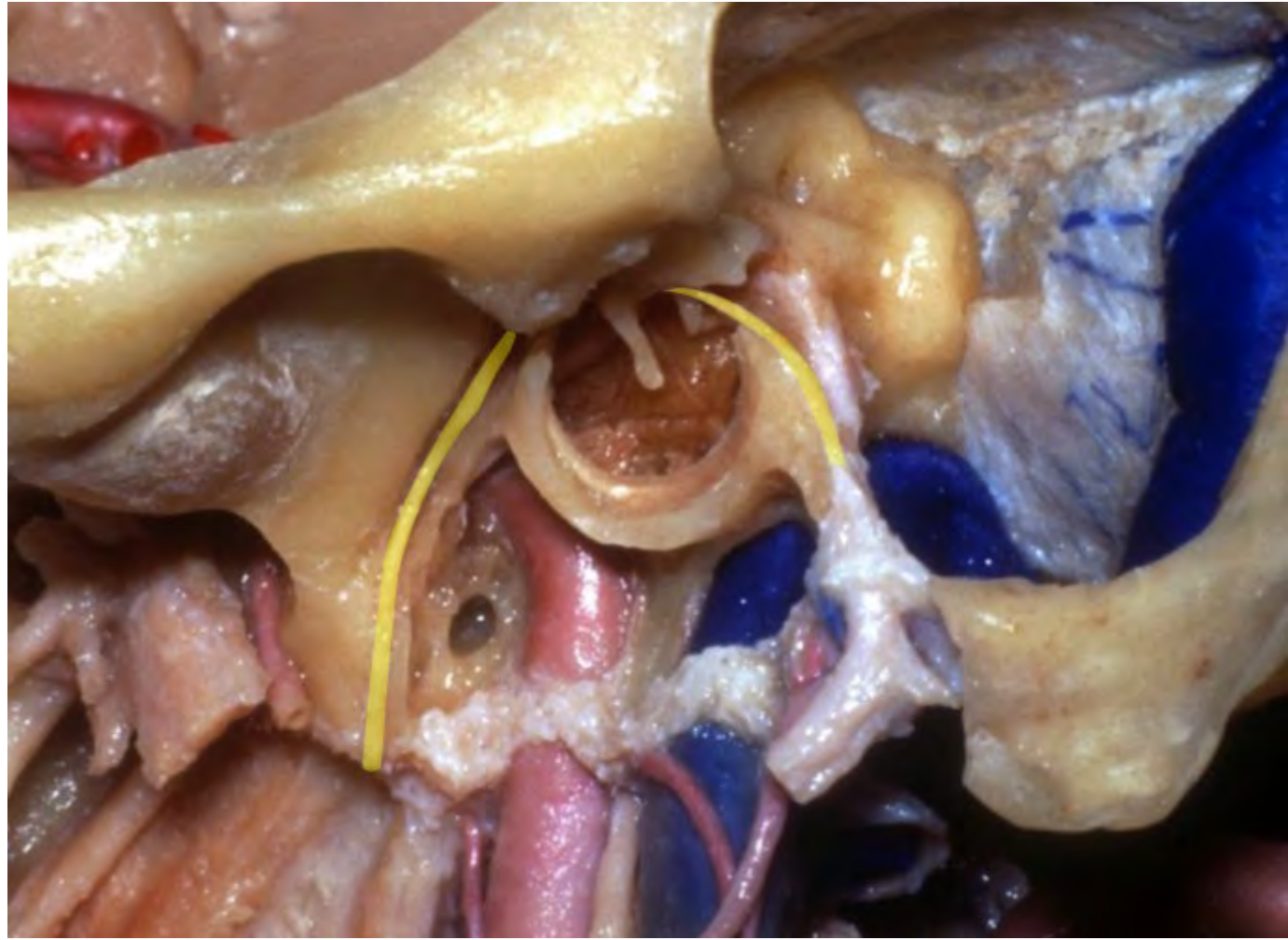


**Mandibular fossa**

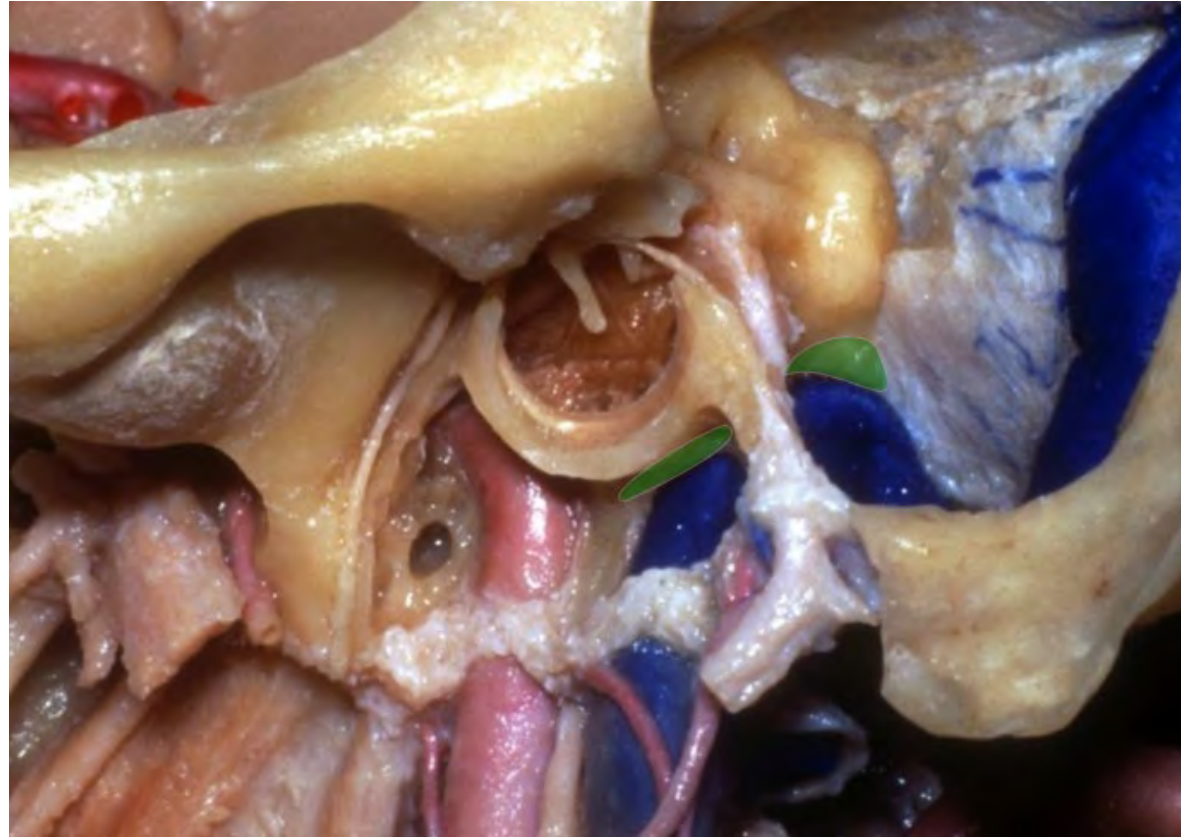






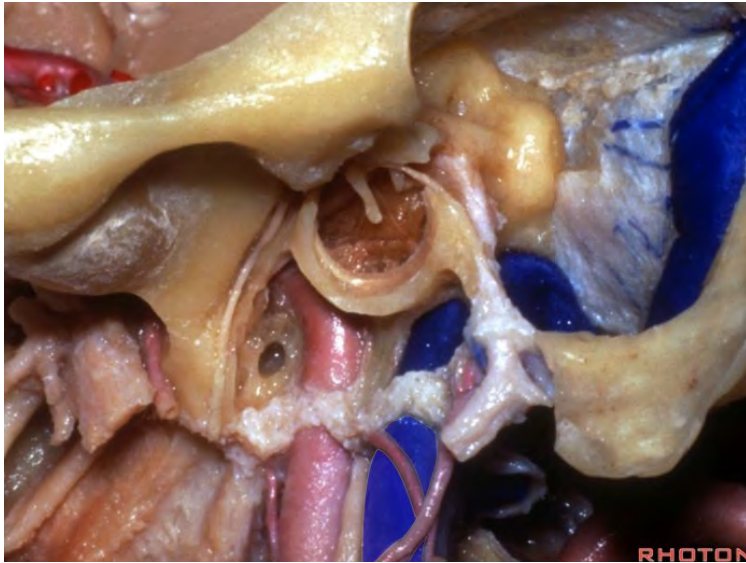


## Jugular fossa

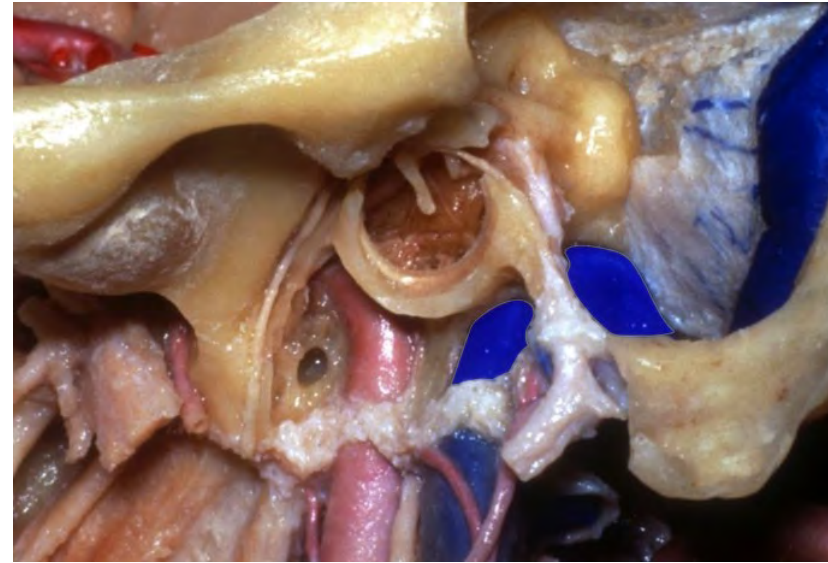




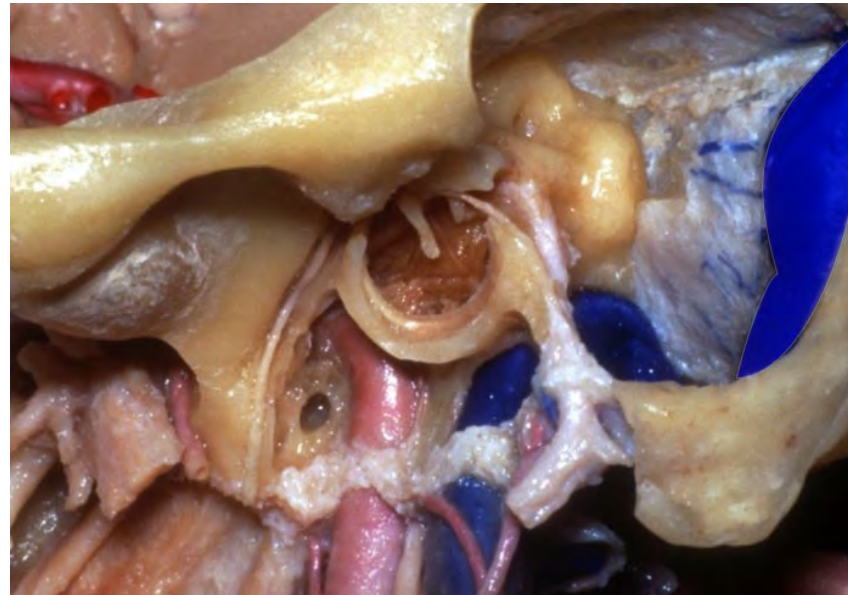
**Internal jugular vein**



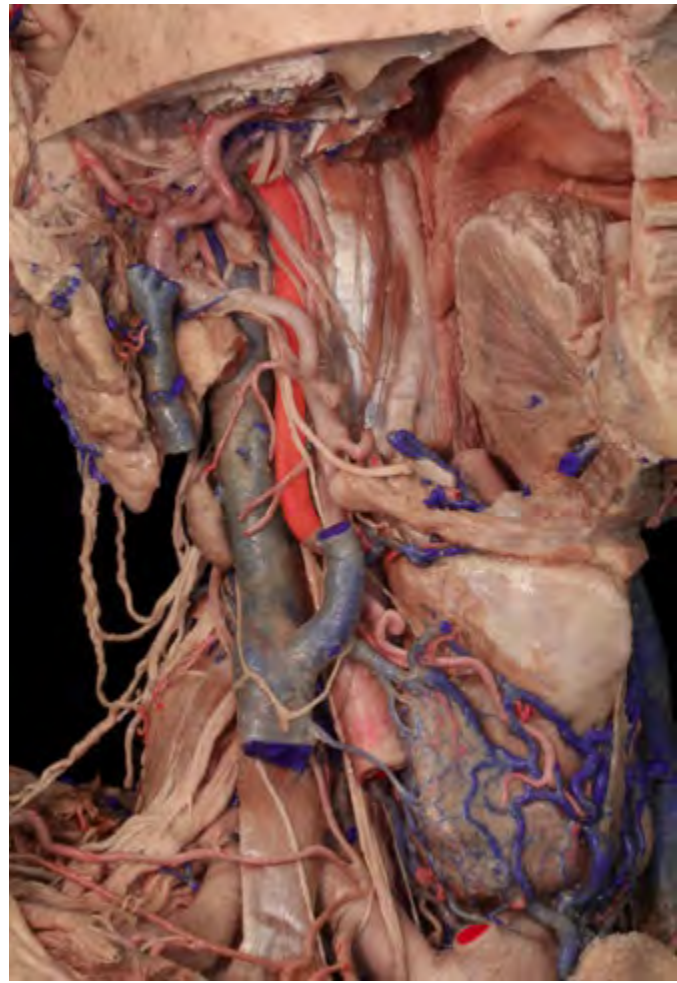**Jugular bulb**



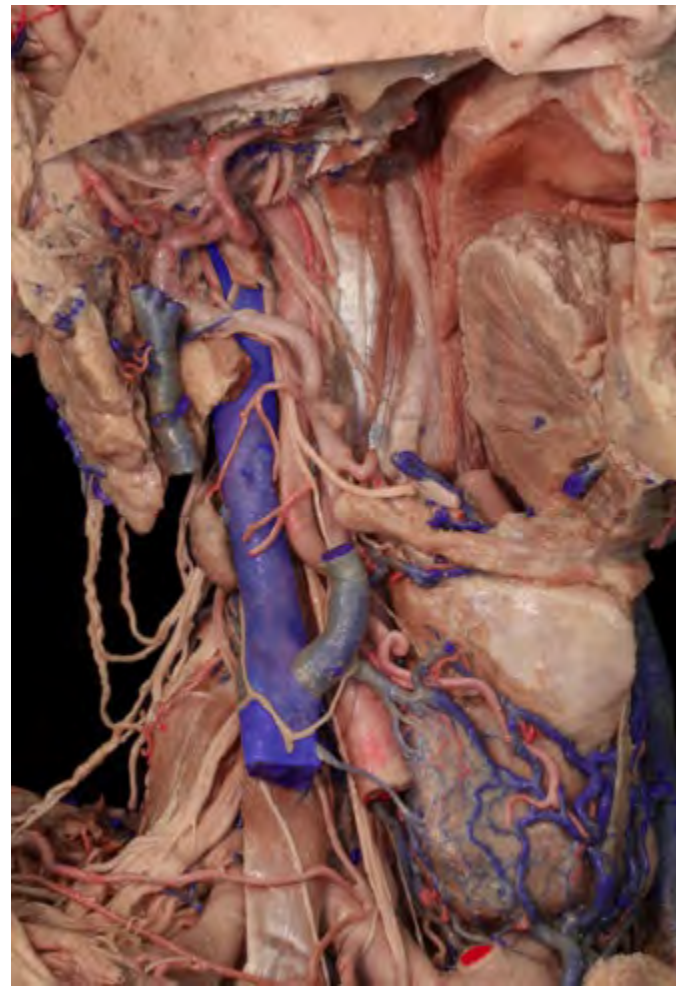**Sigmoid sinus**

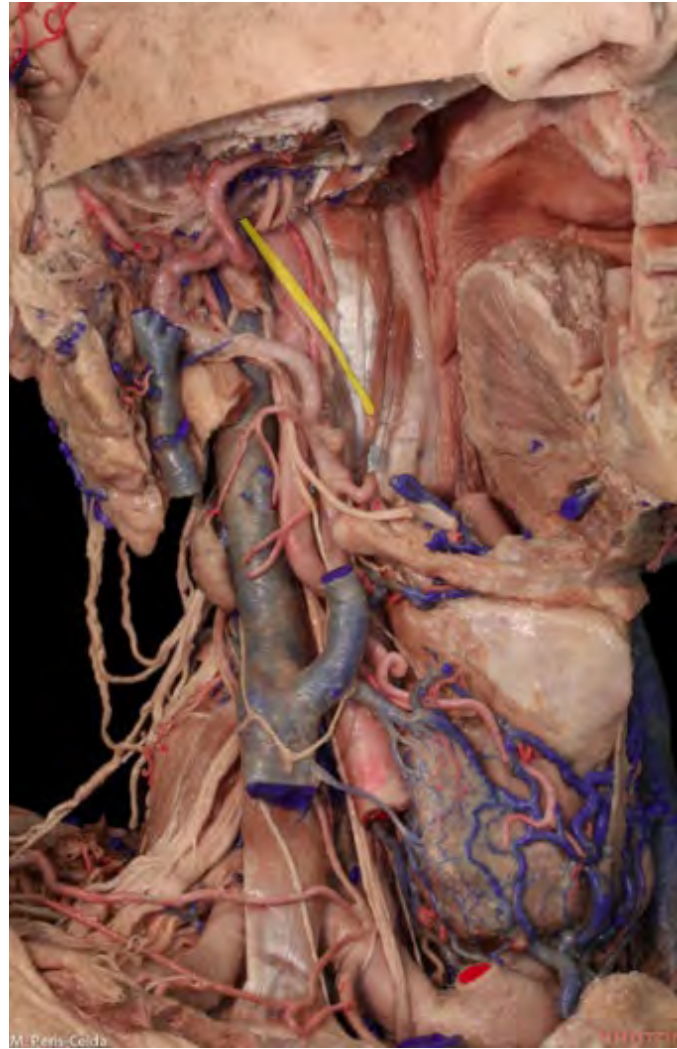

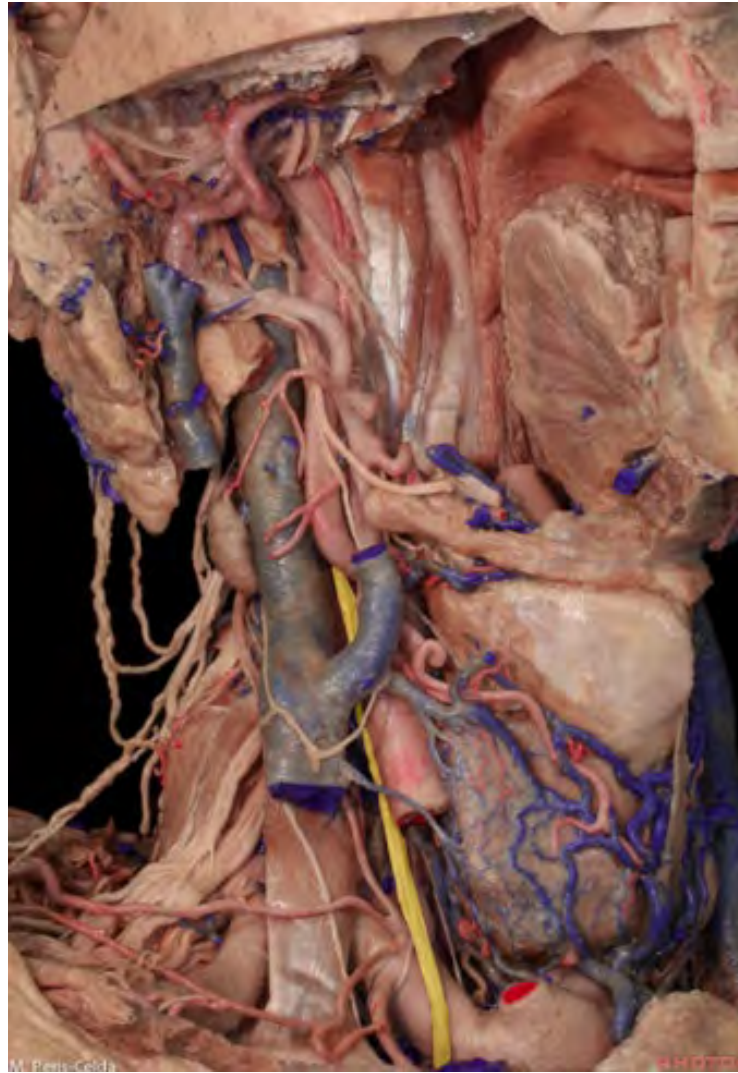**ICA**

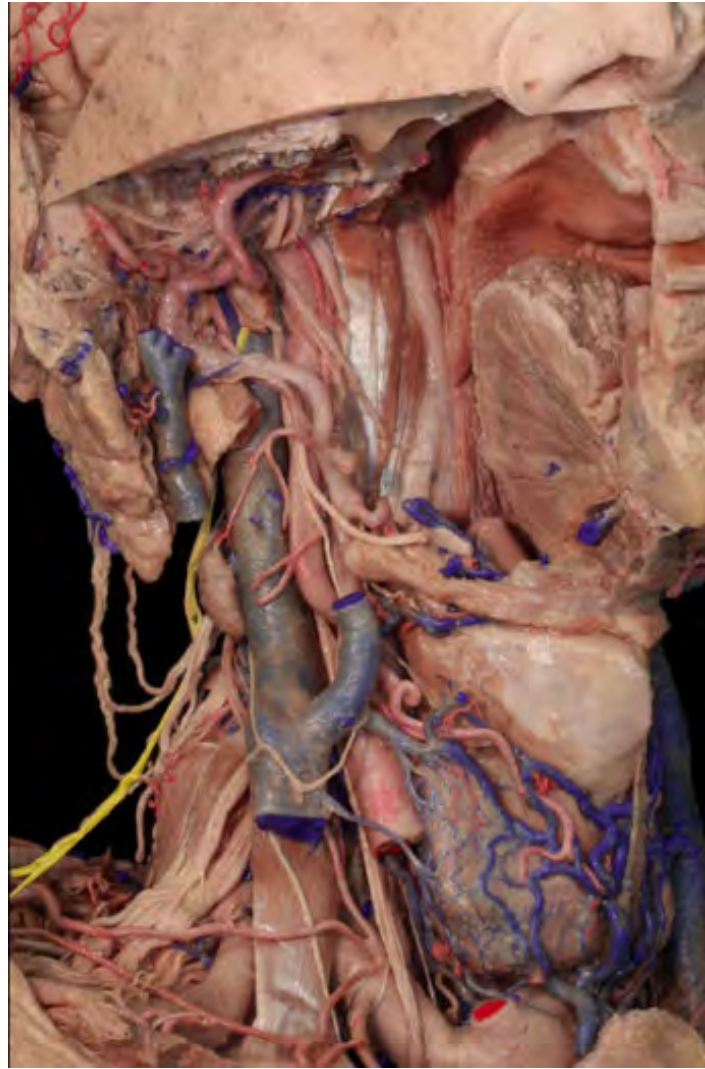

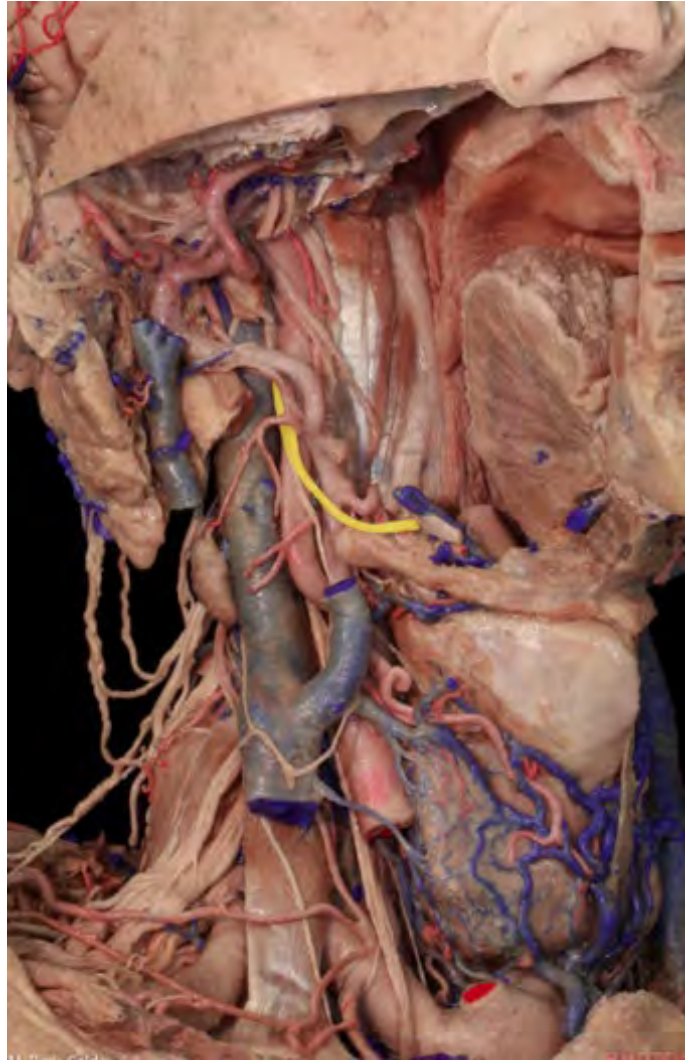**IJV**



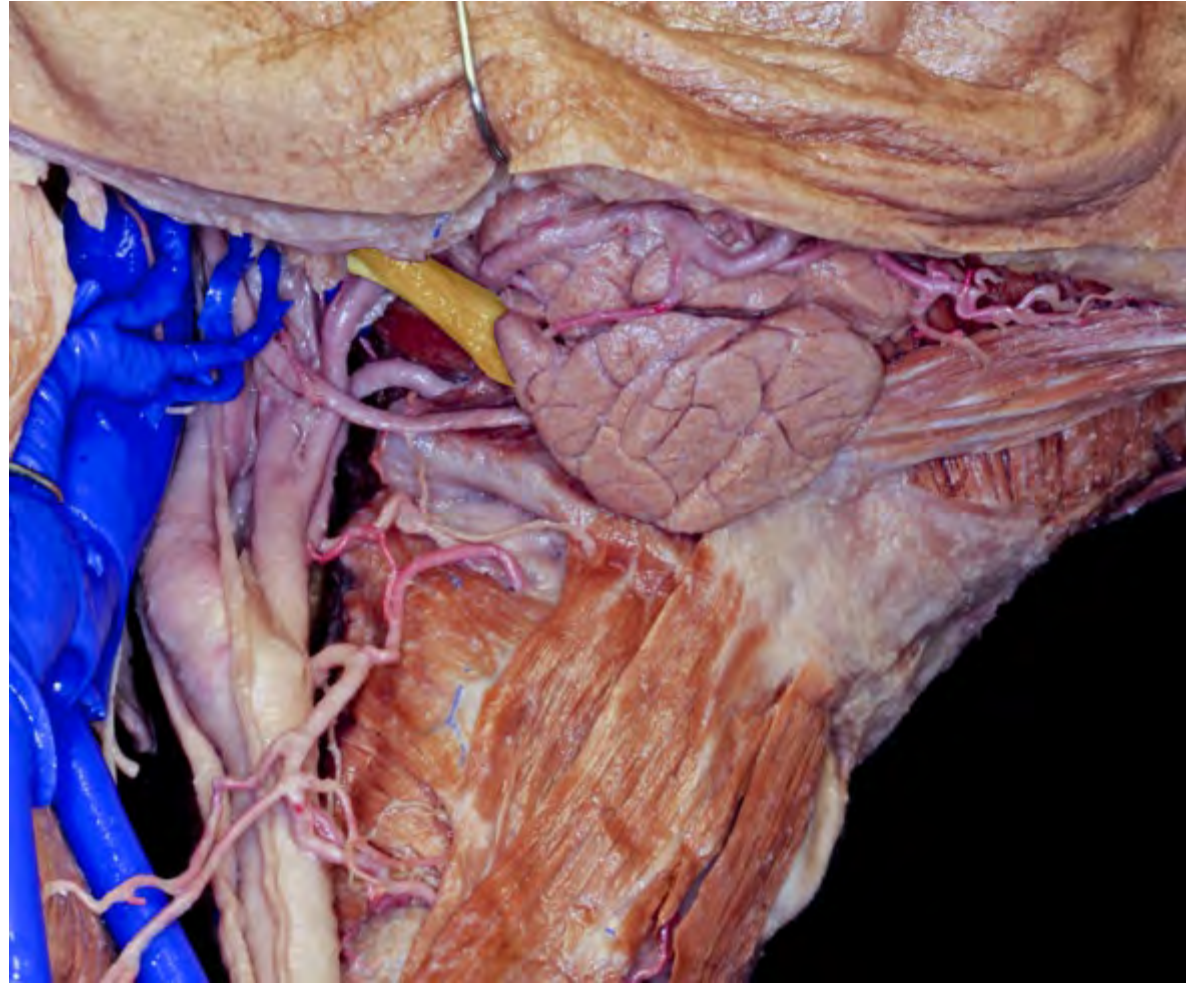




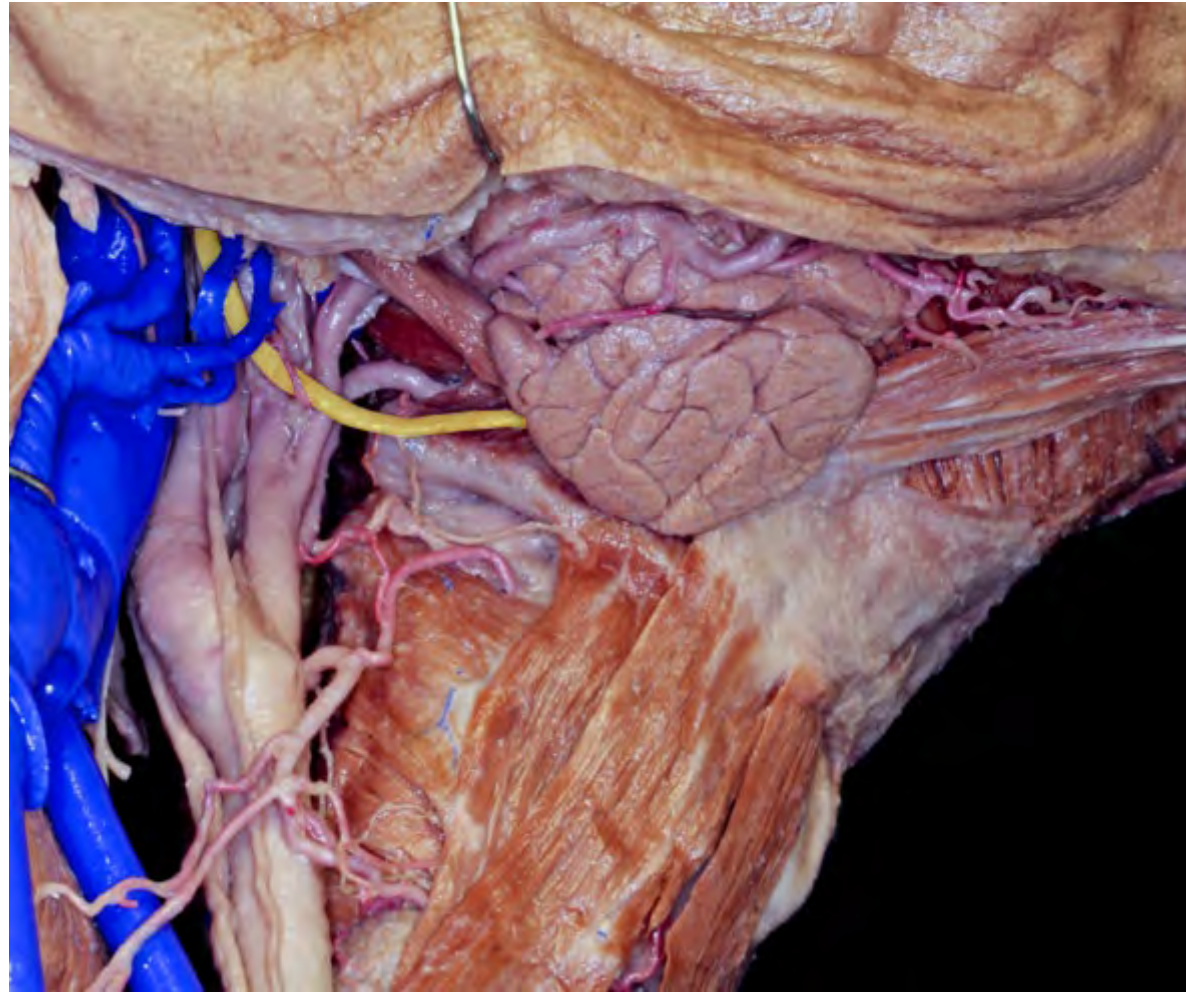




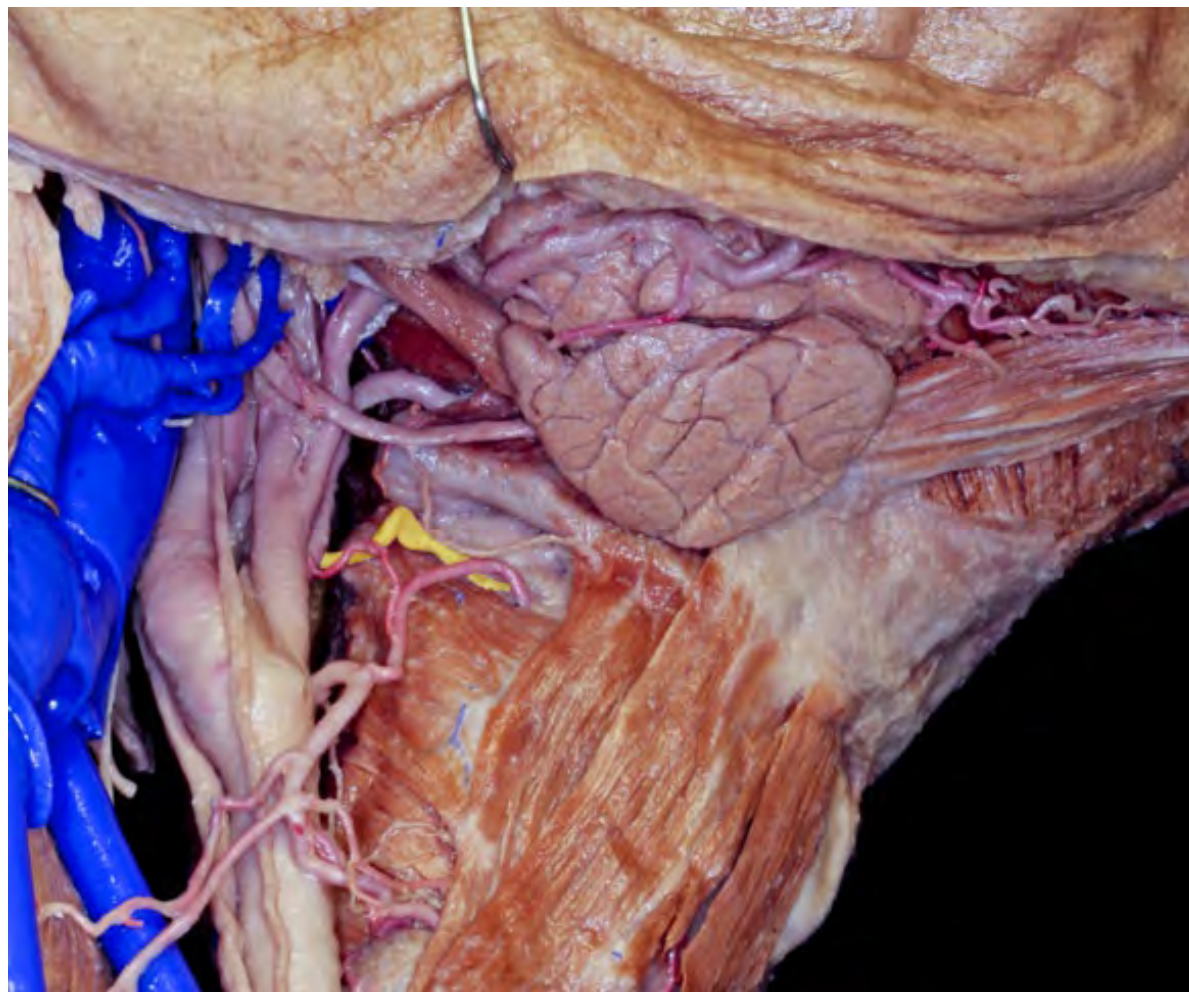




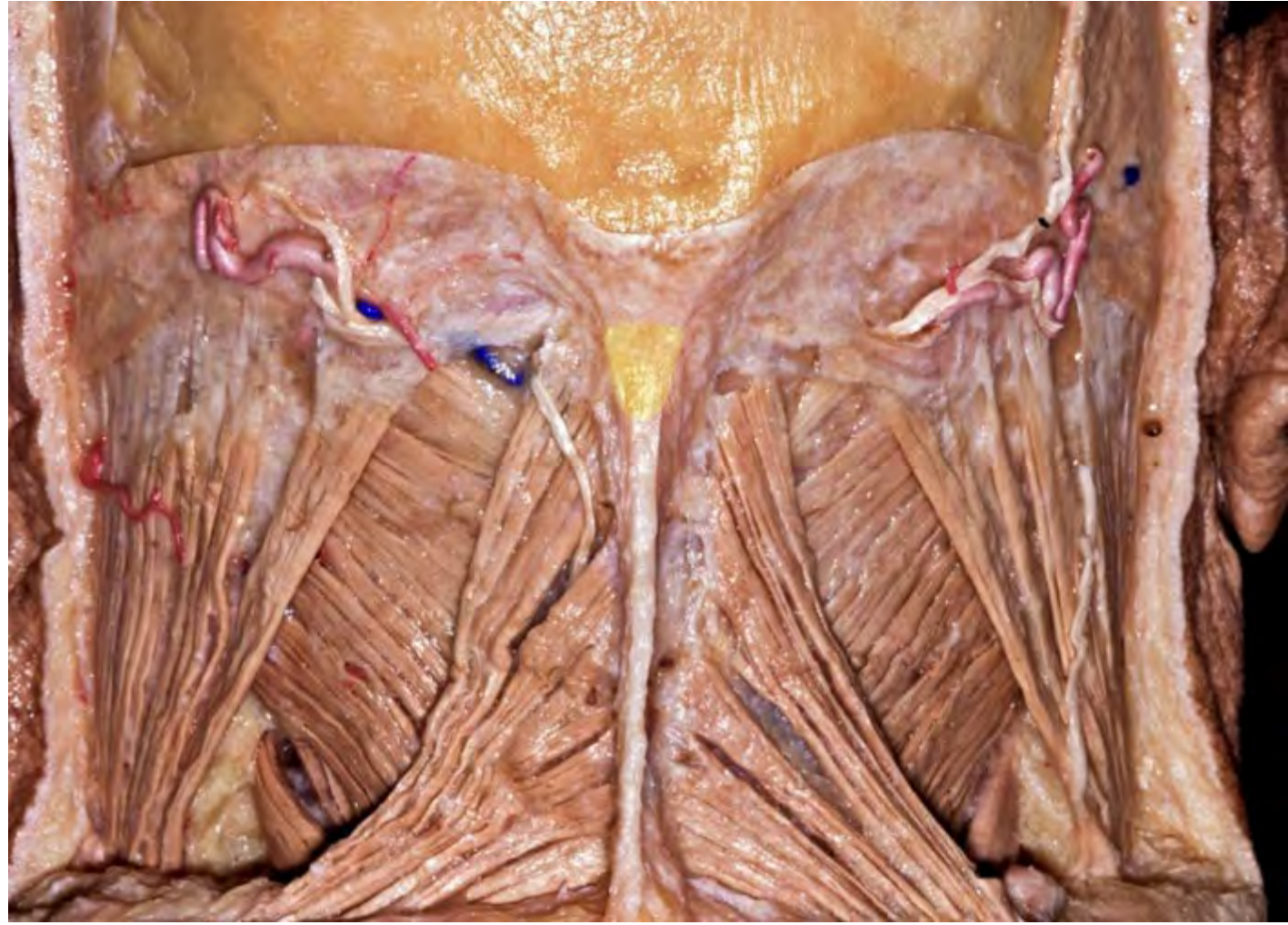


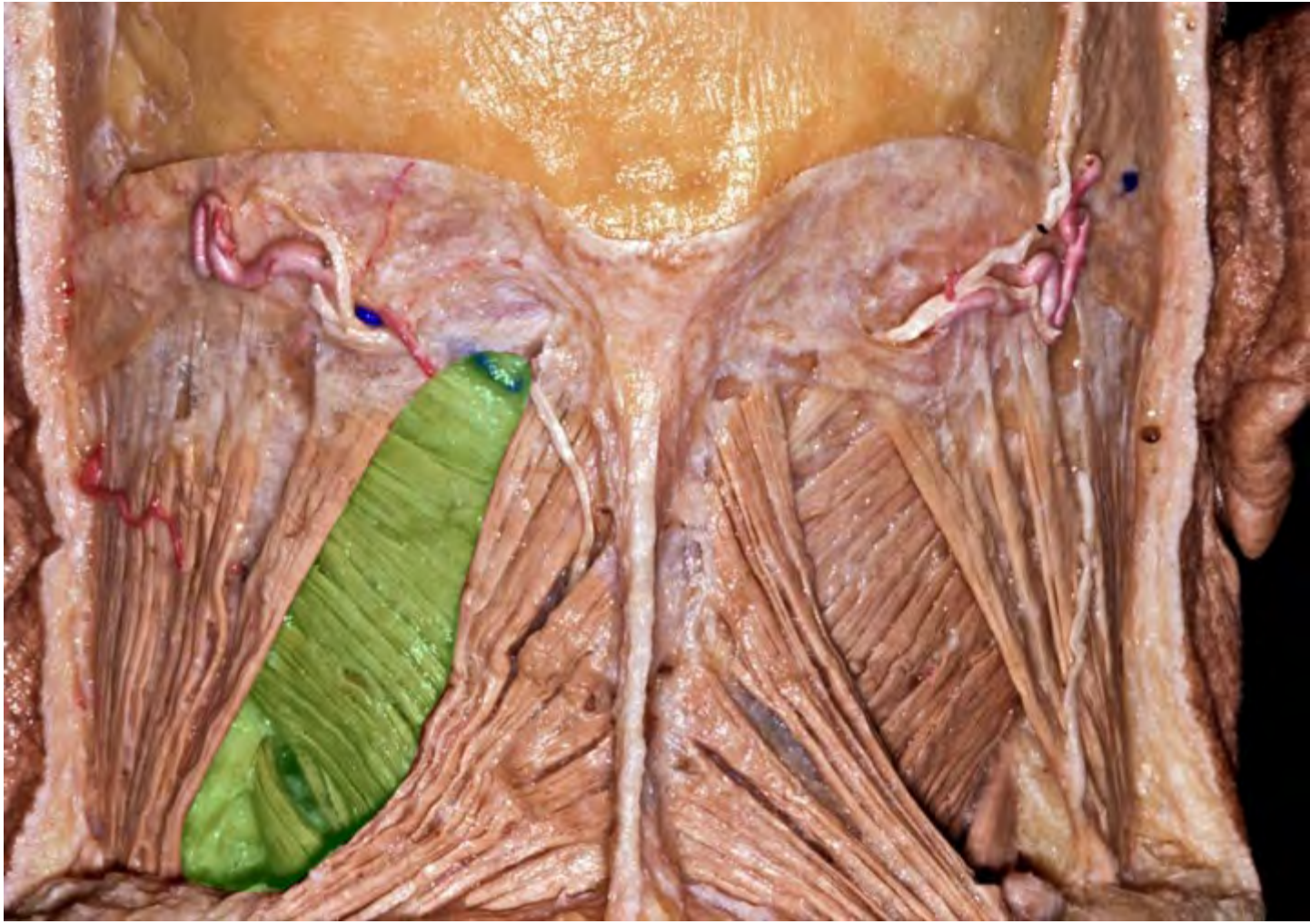


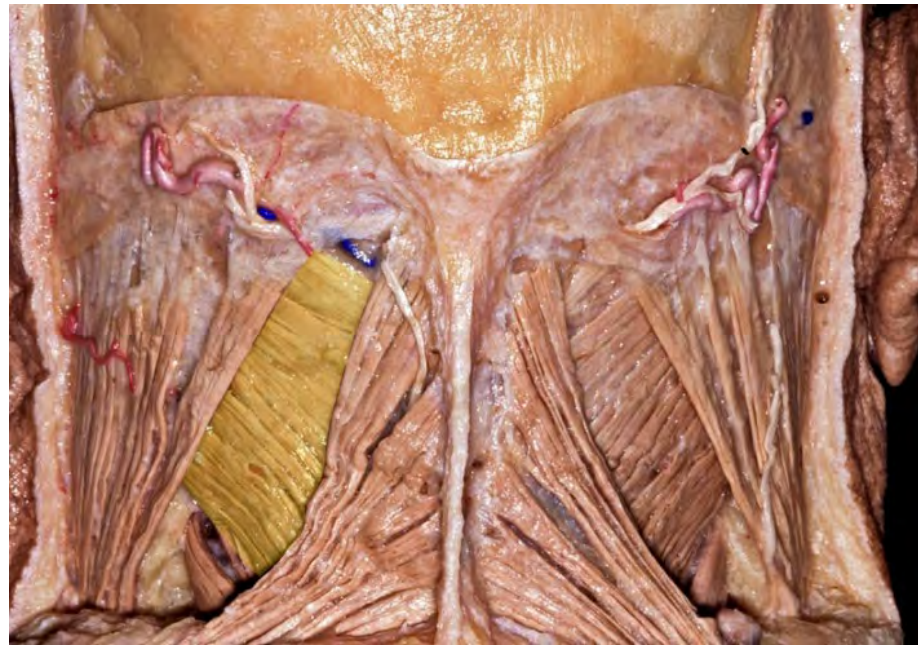
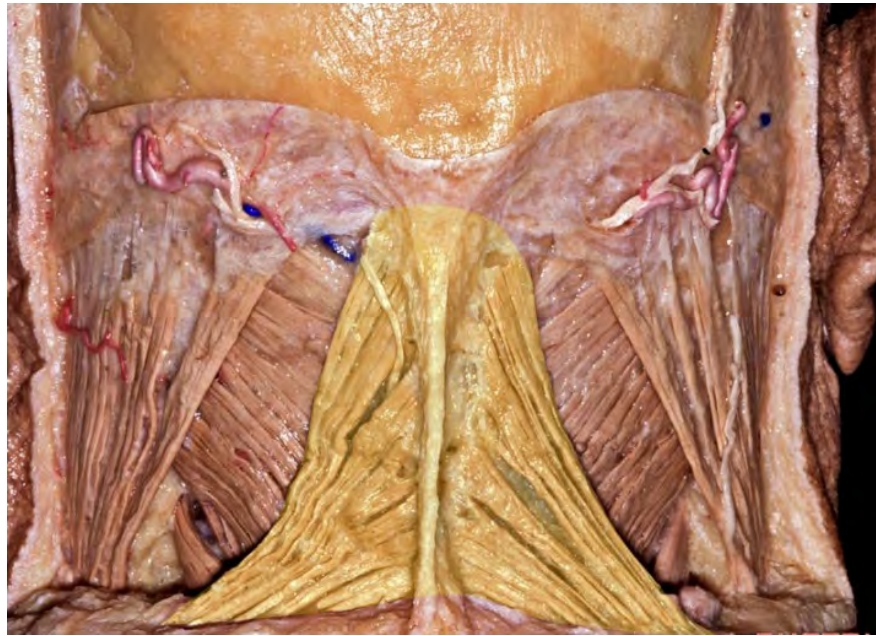
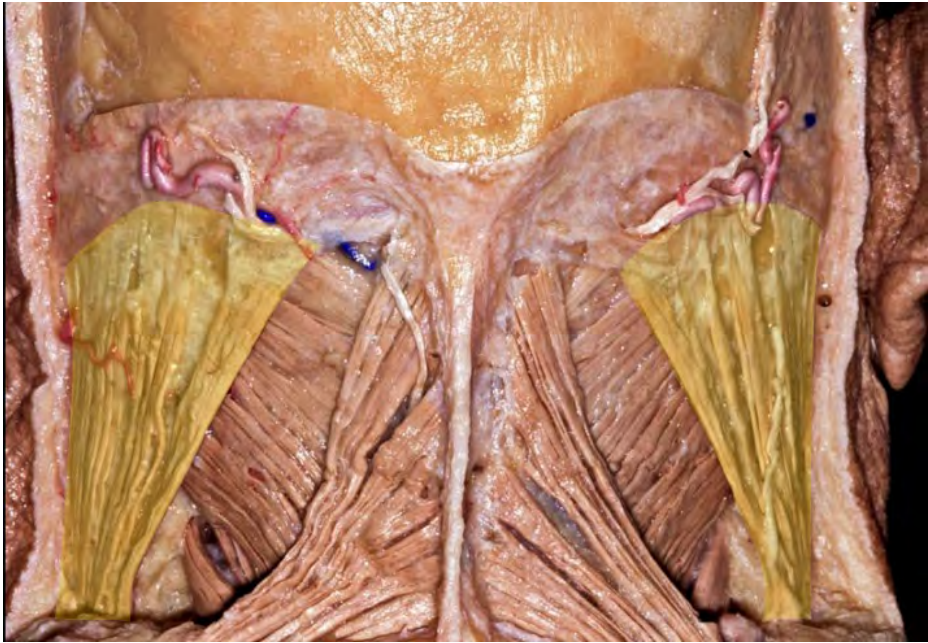


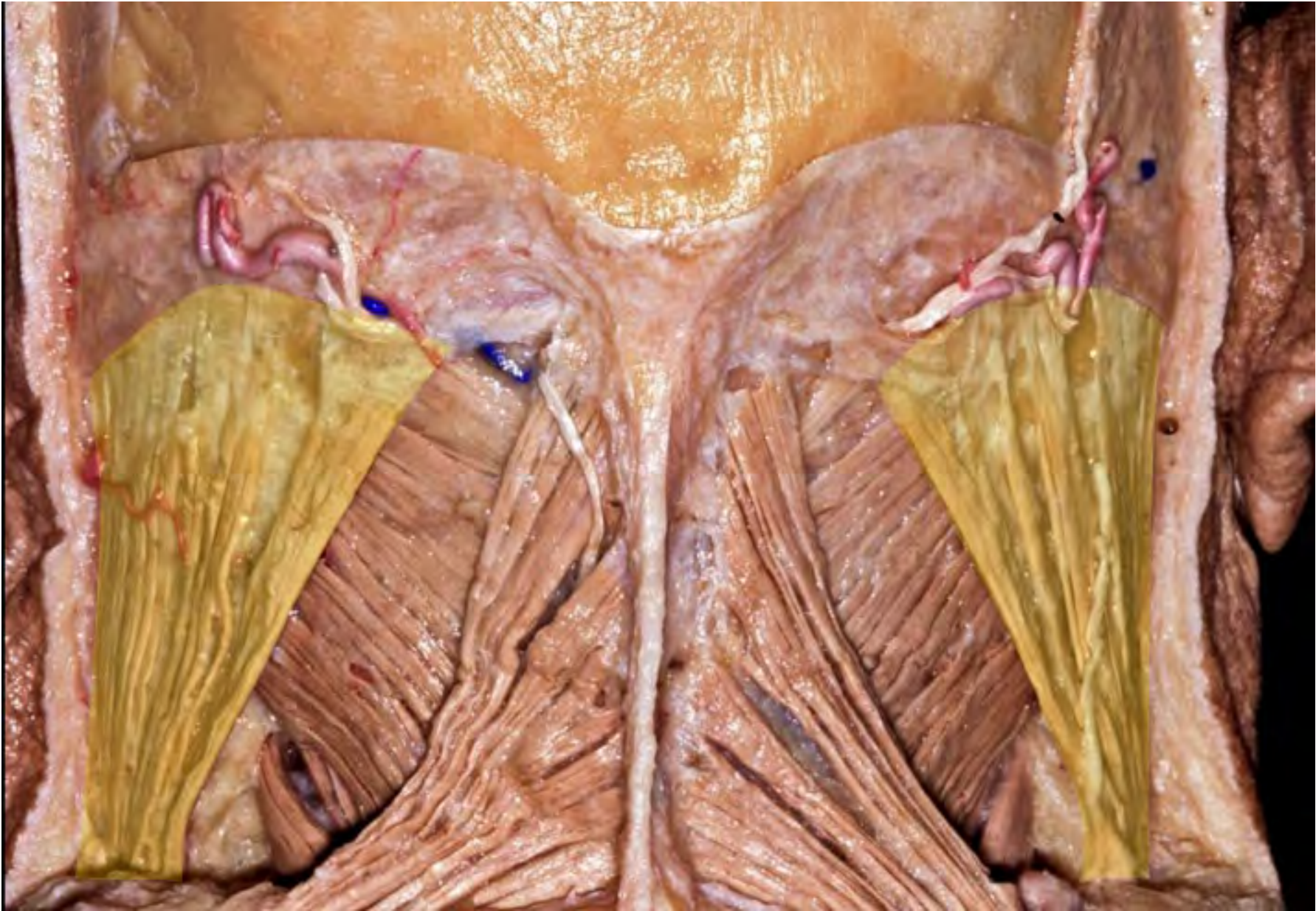



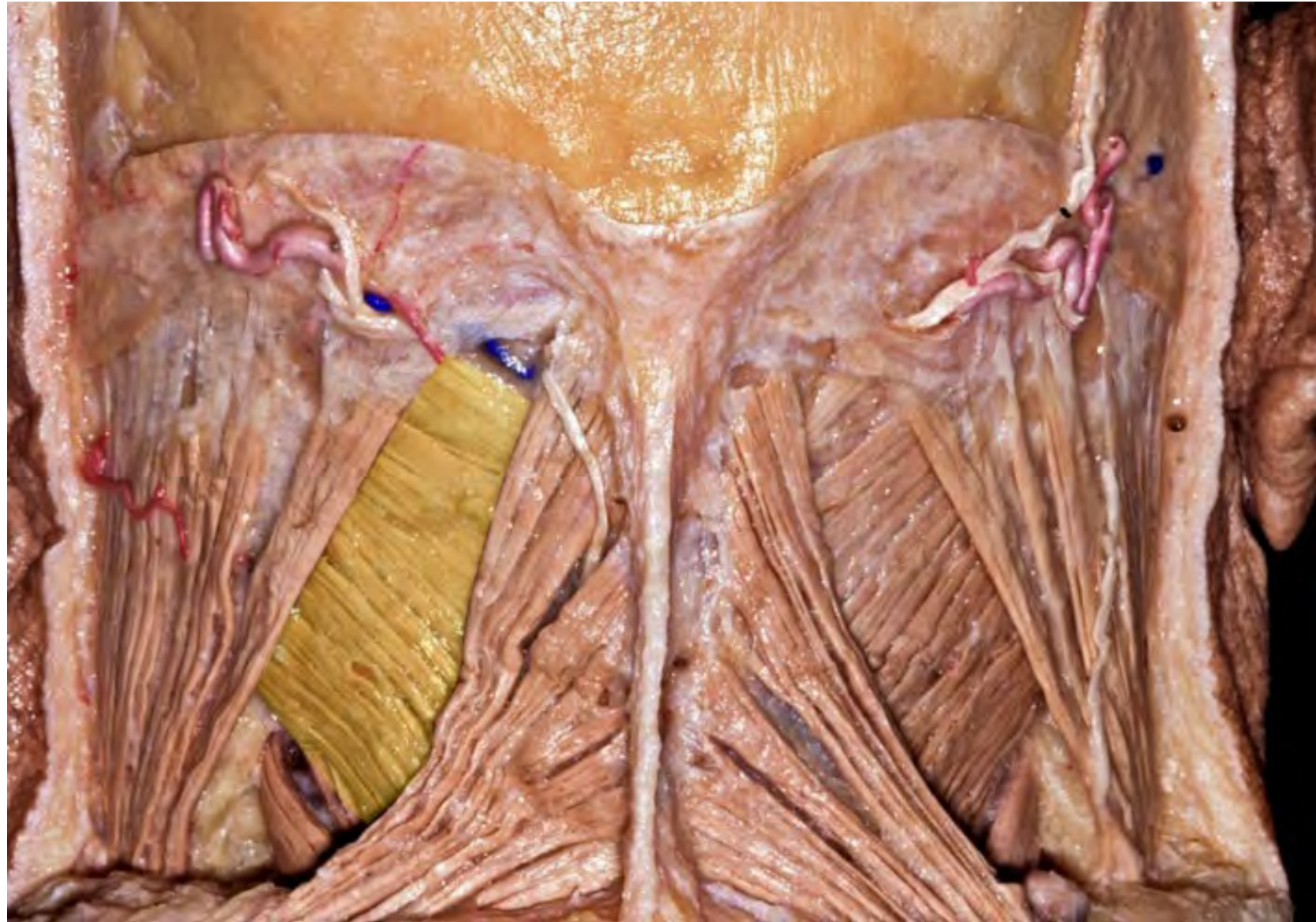


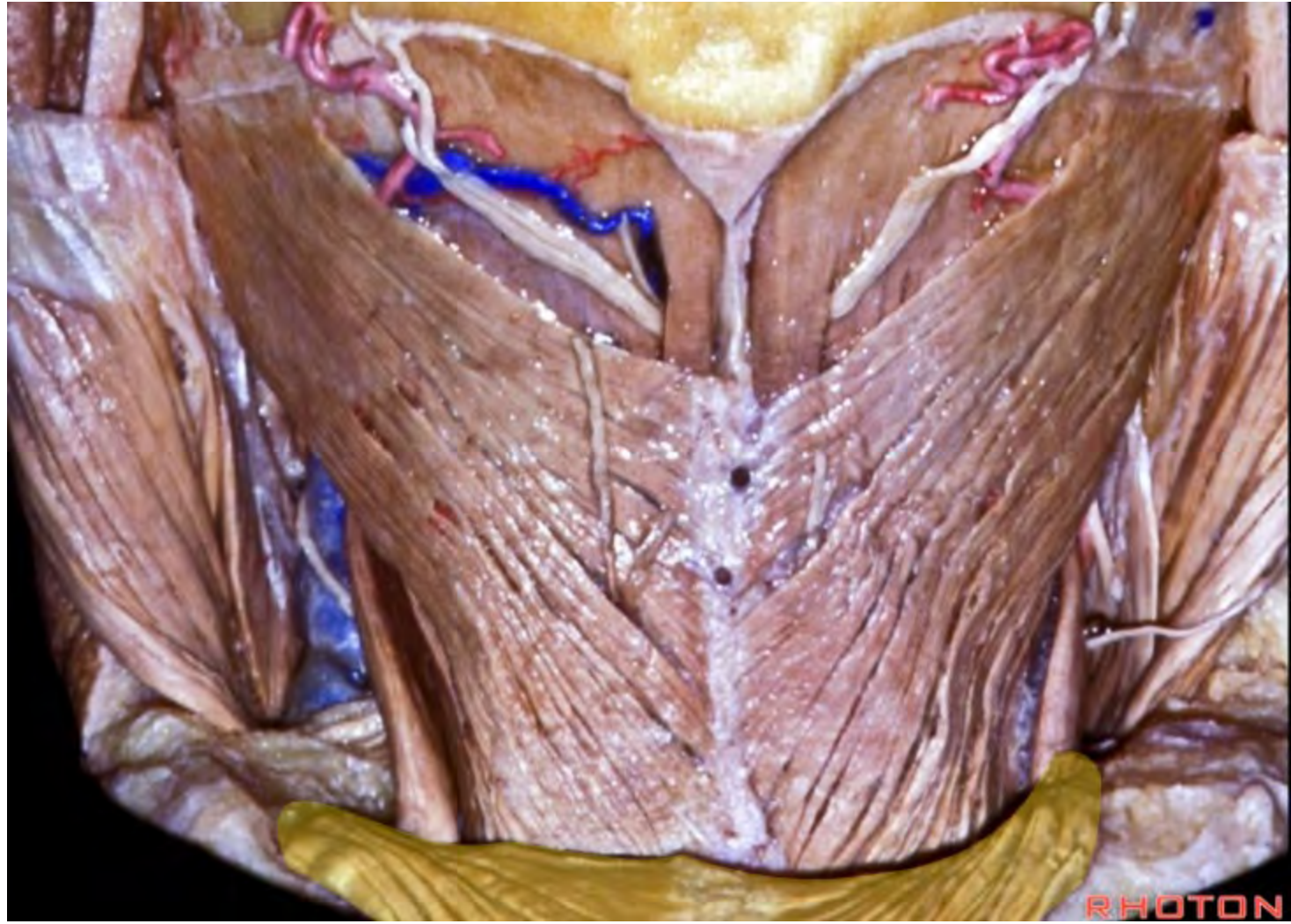


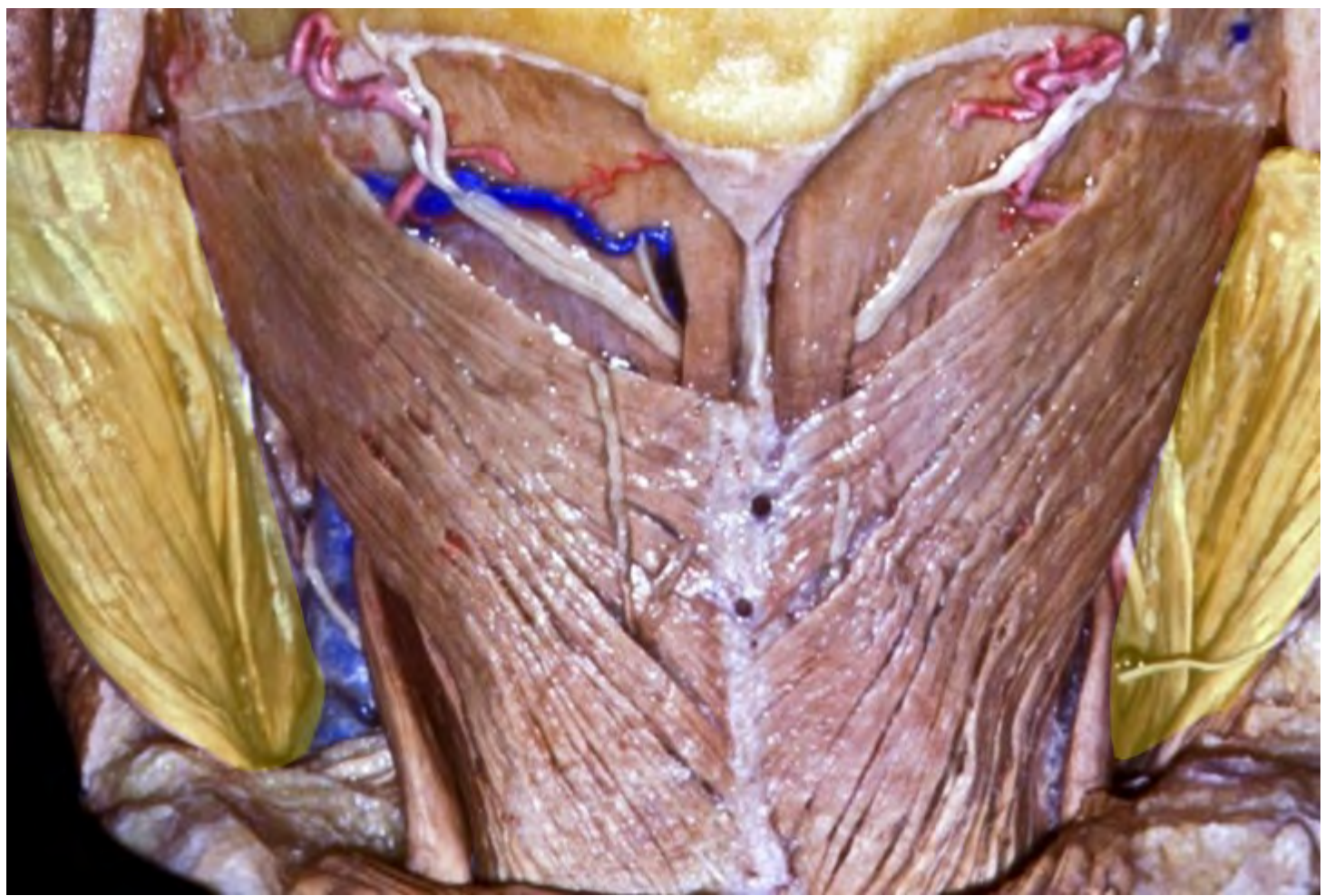





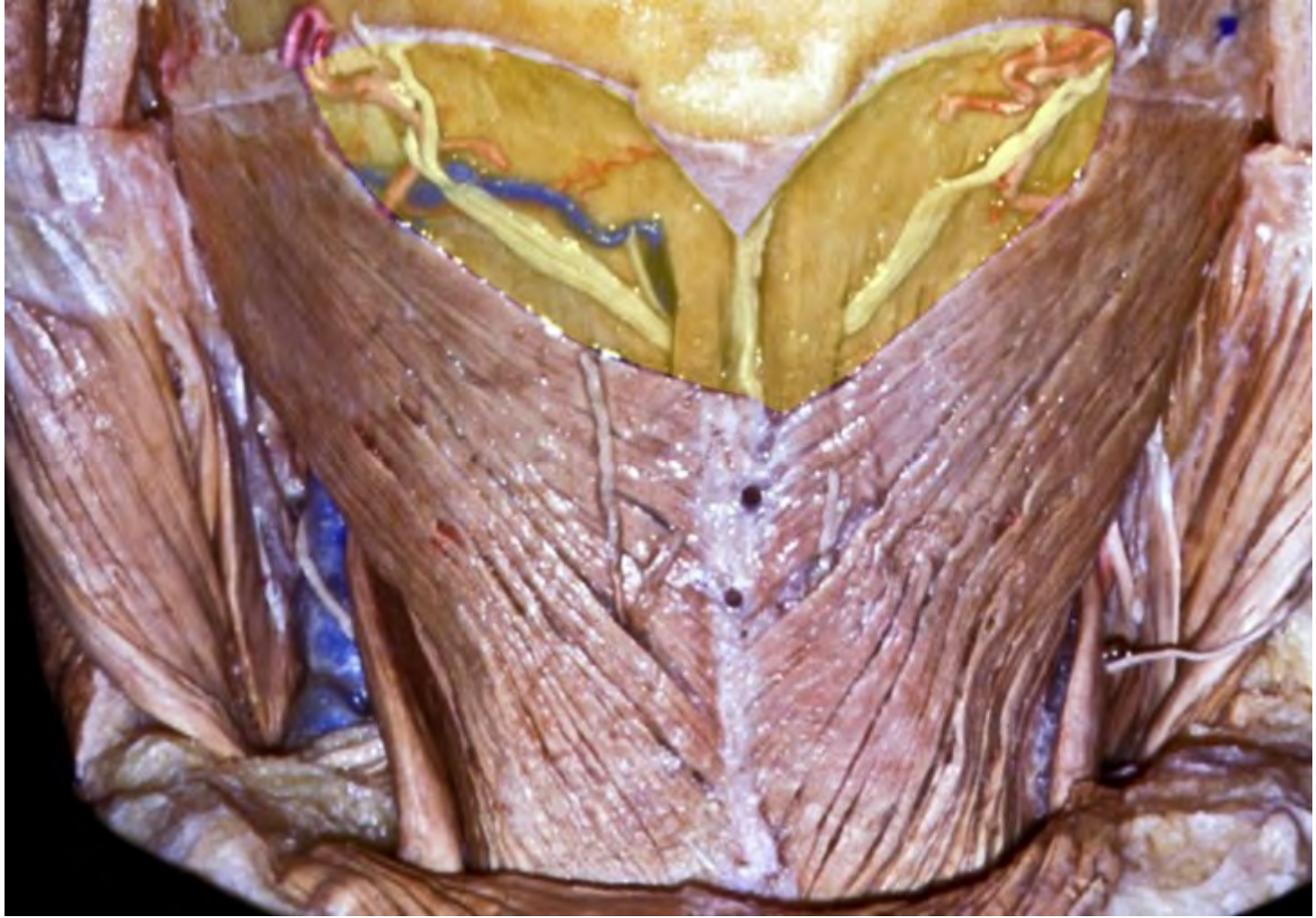
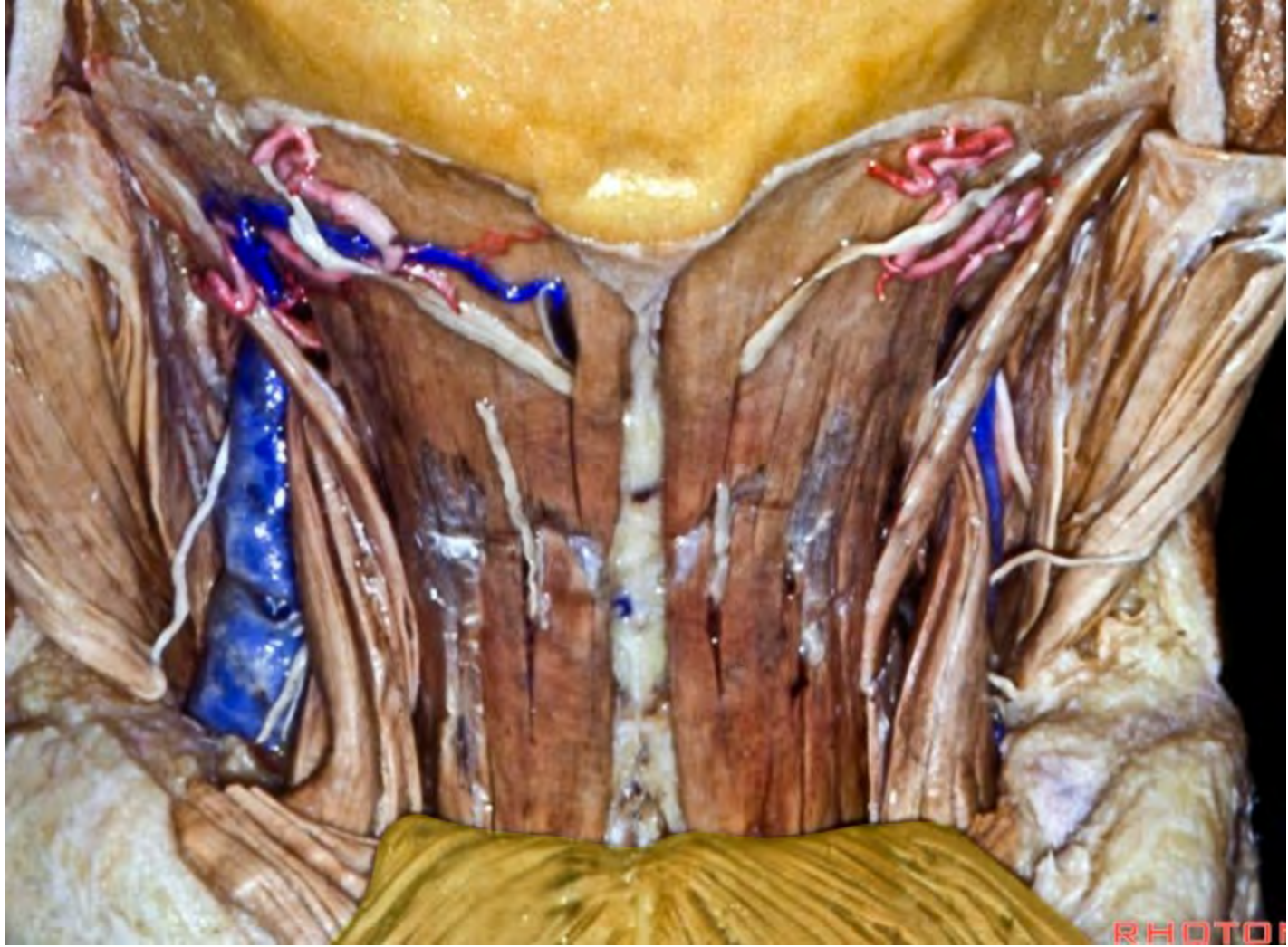


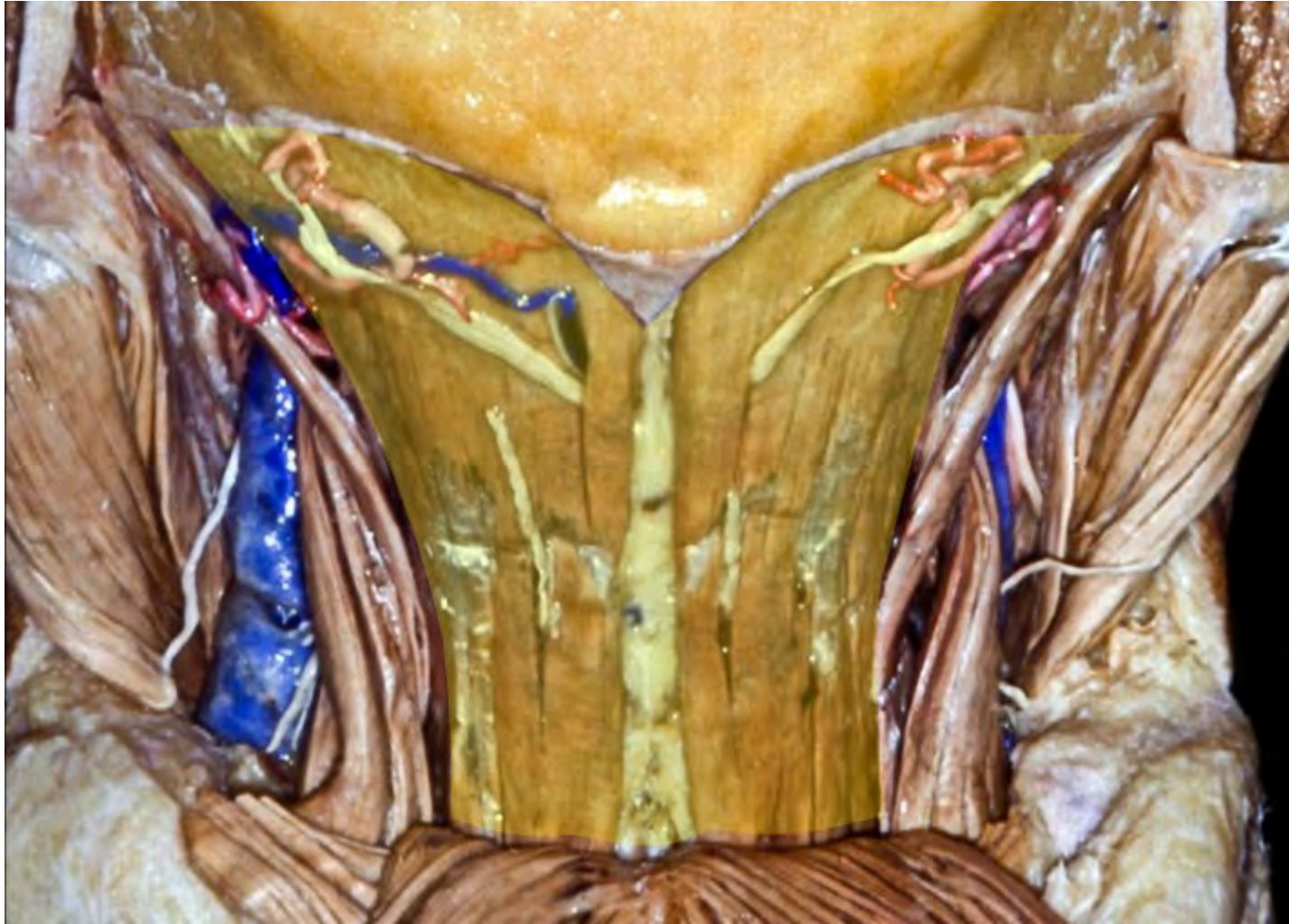


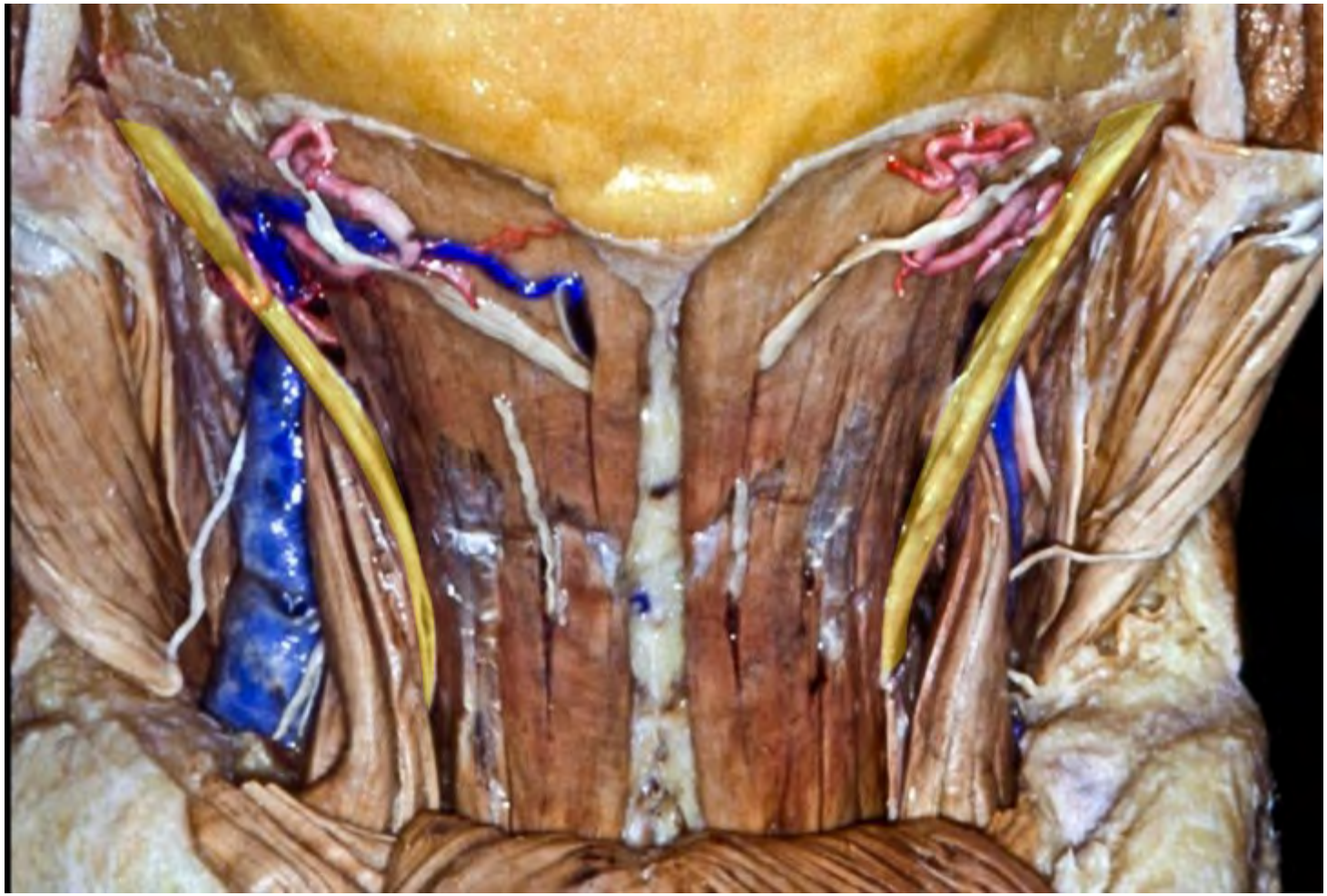




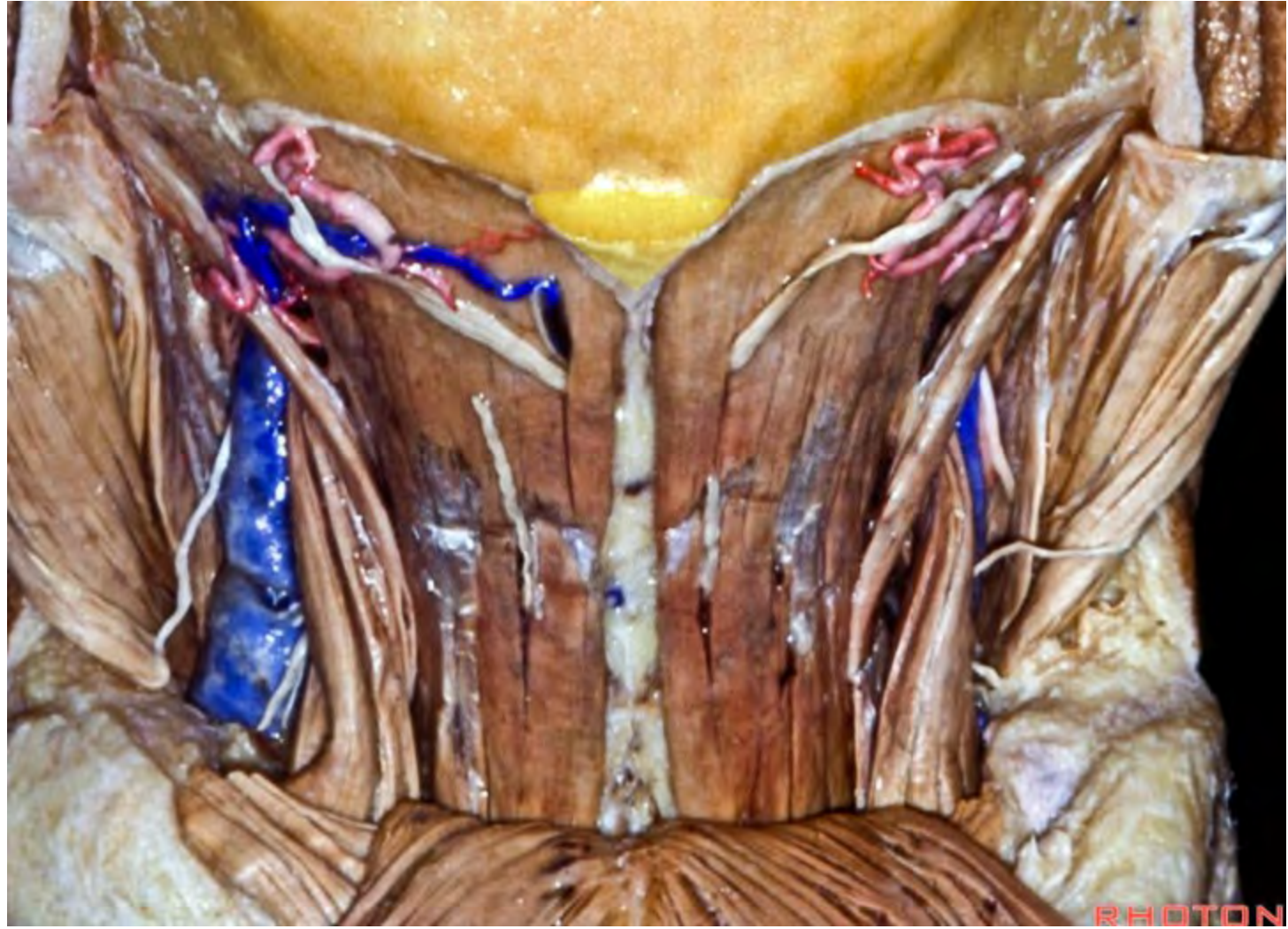


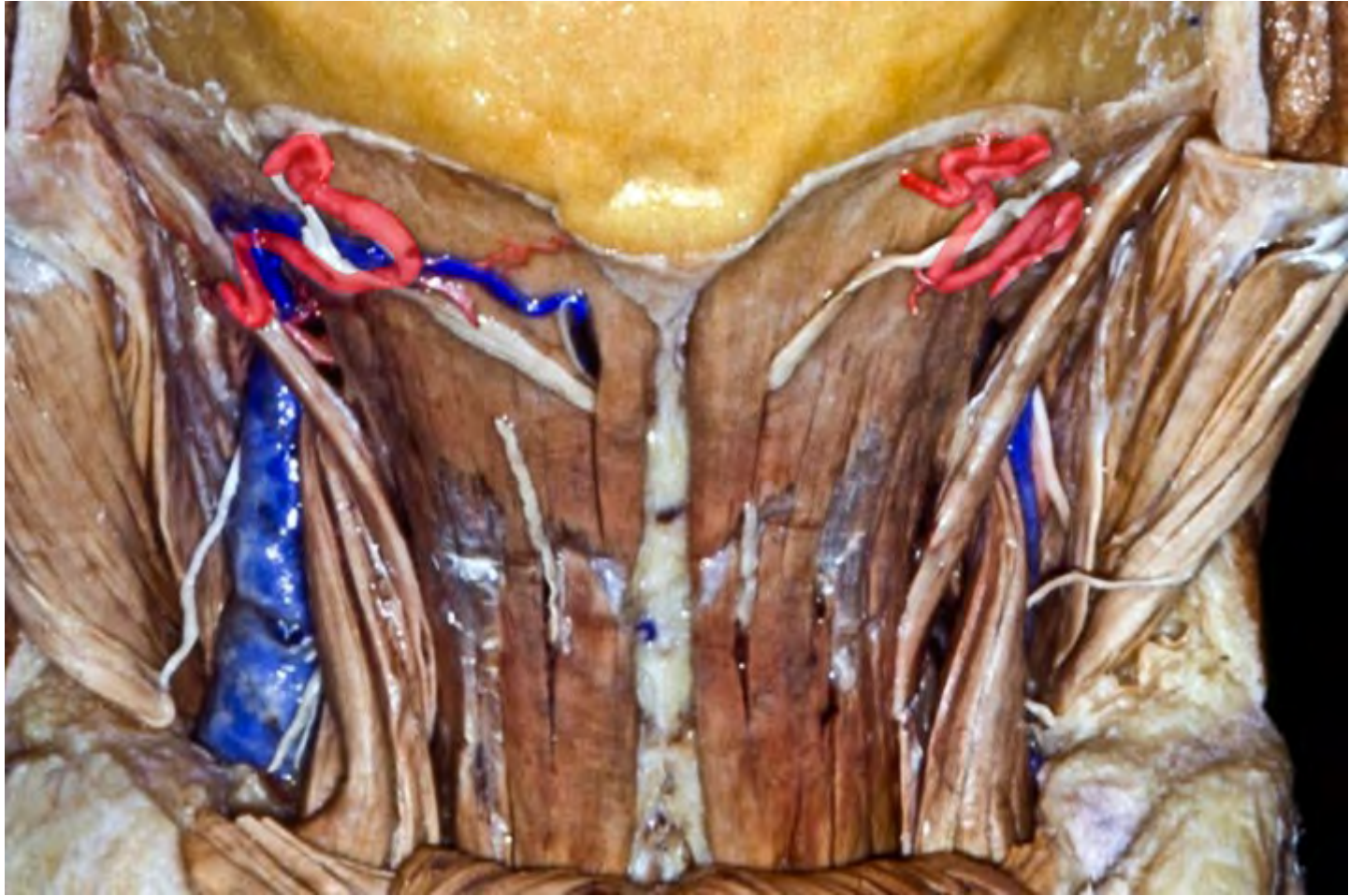


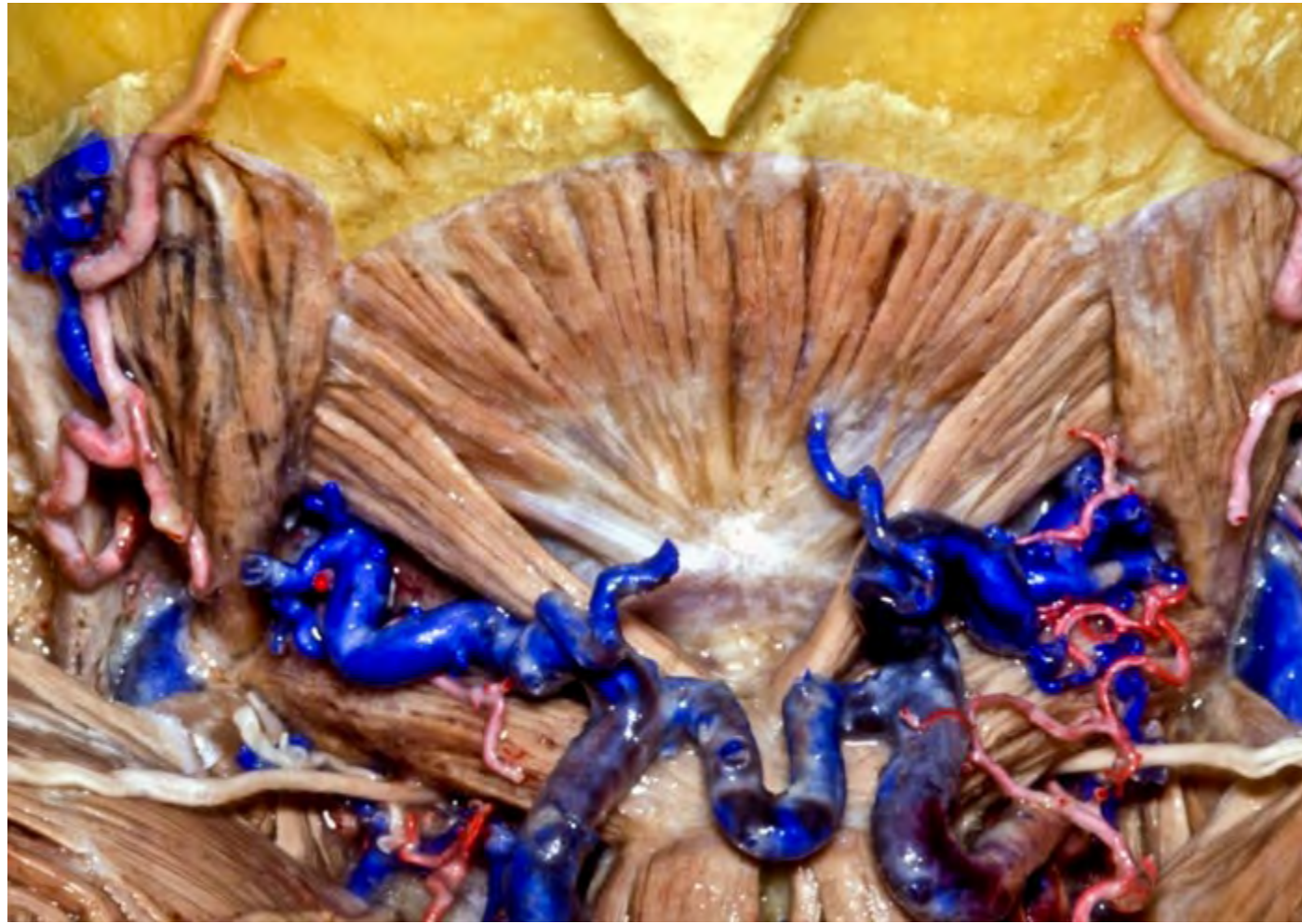


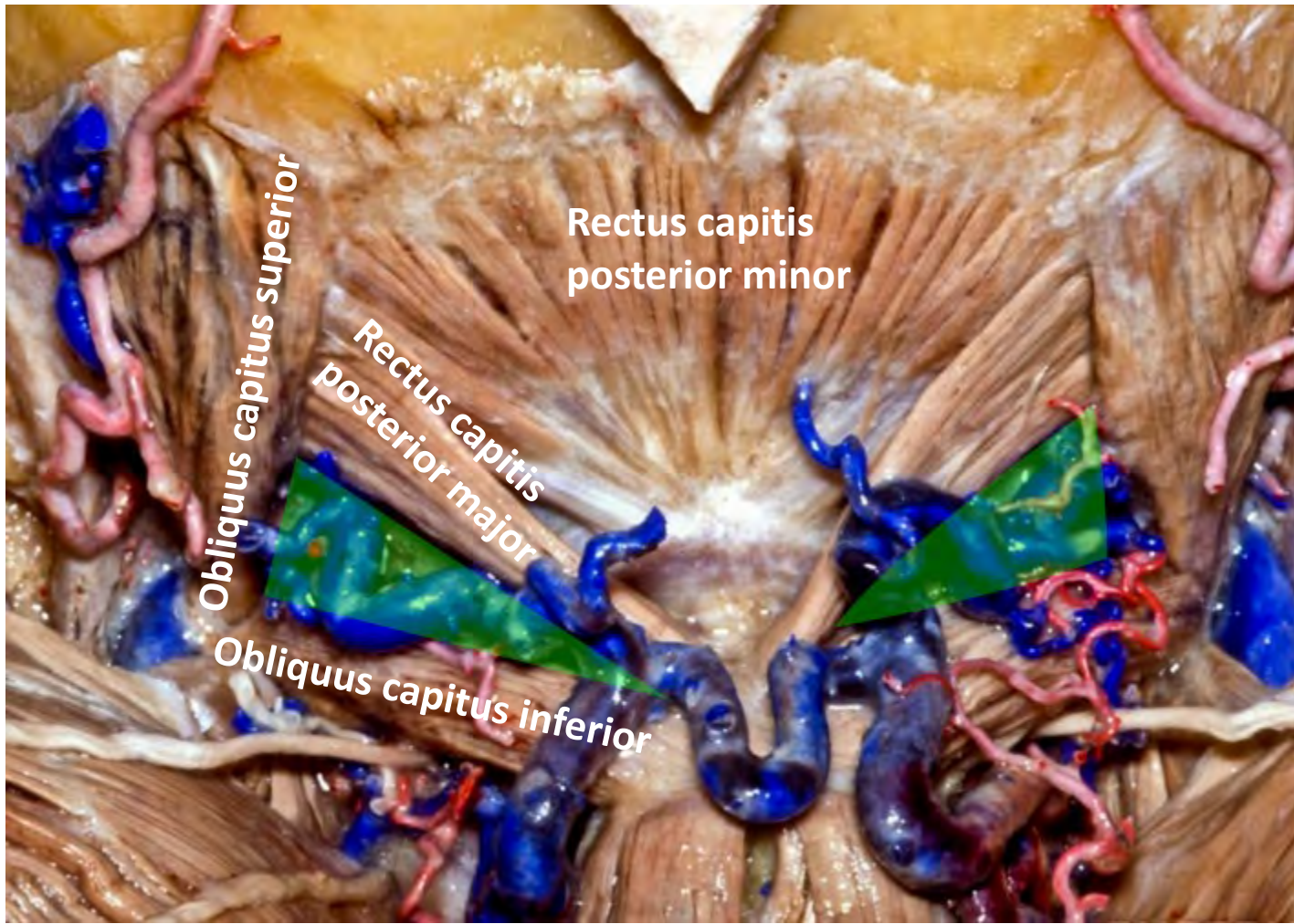


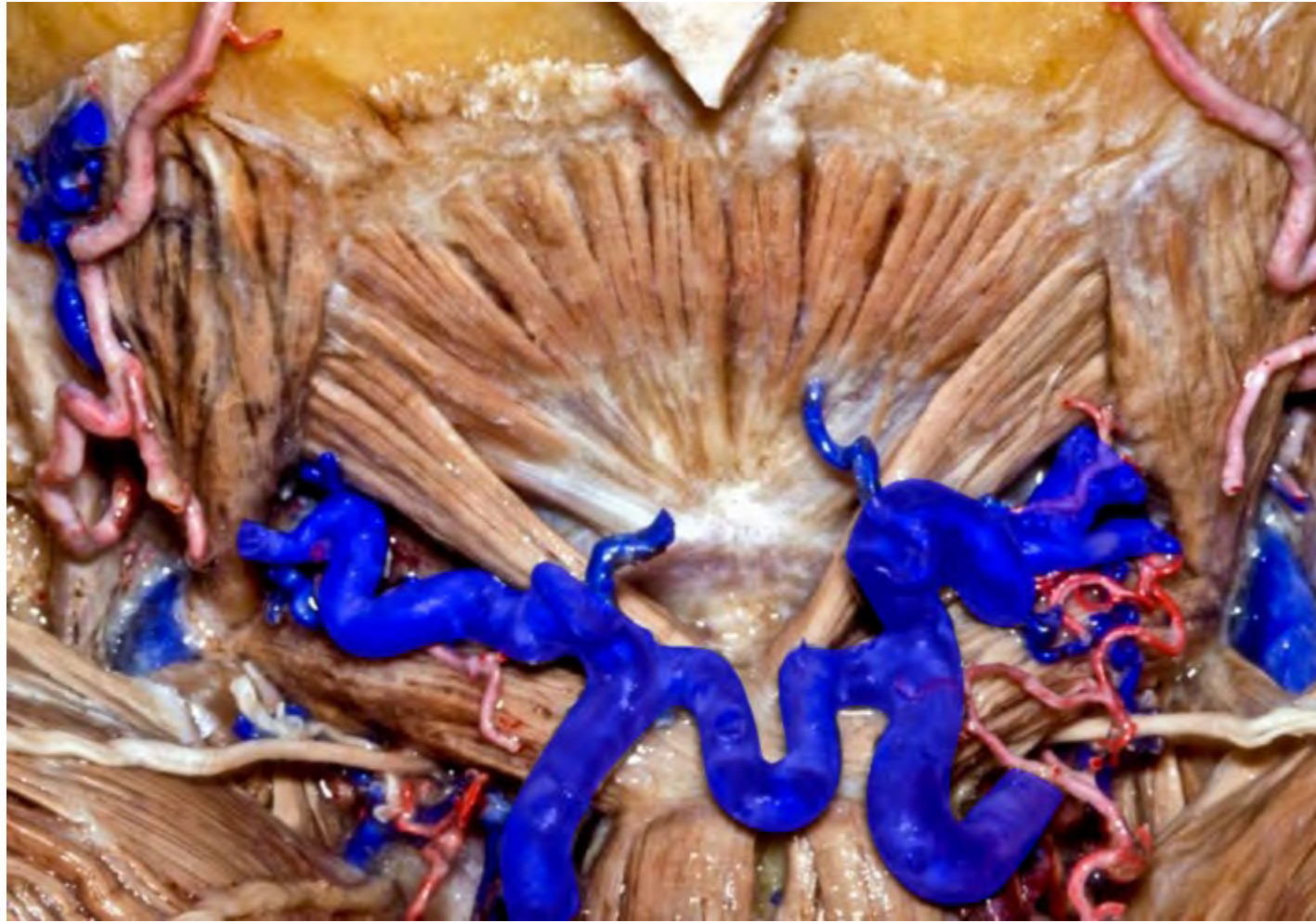




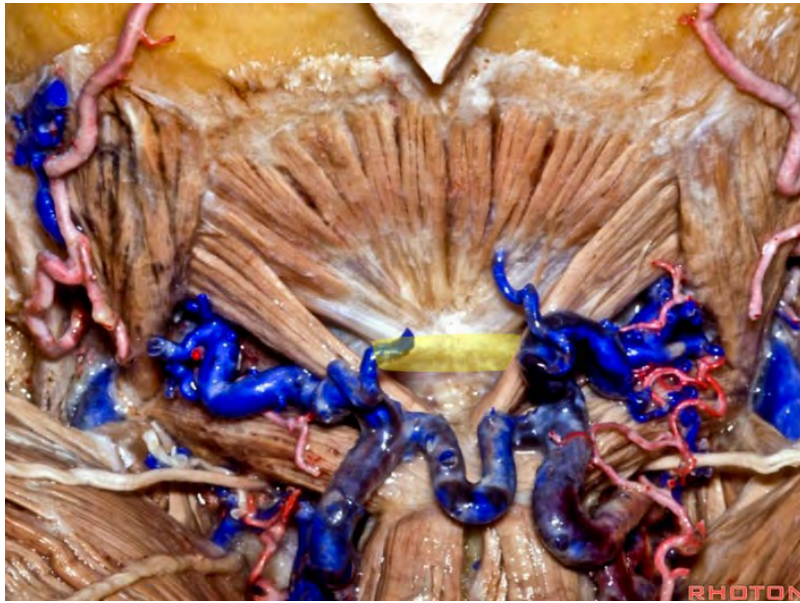




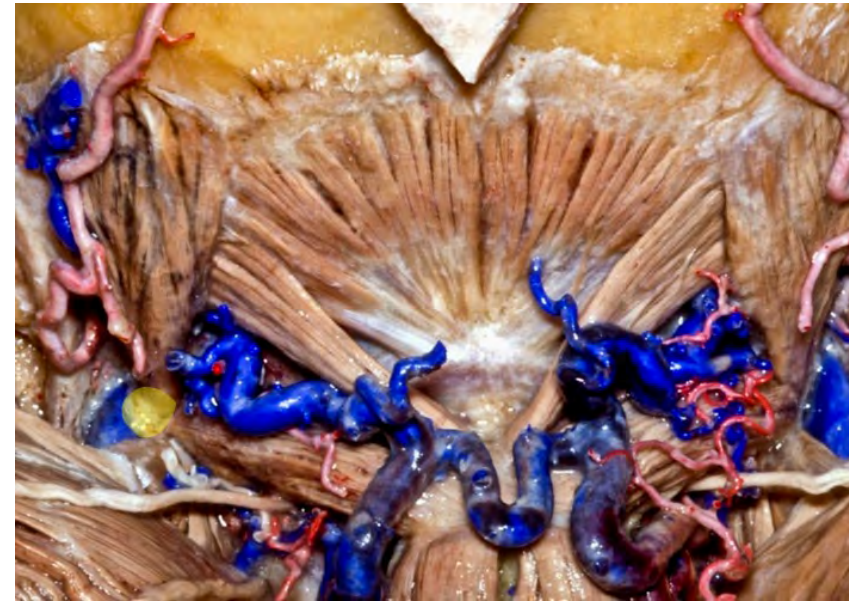




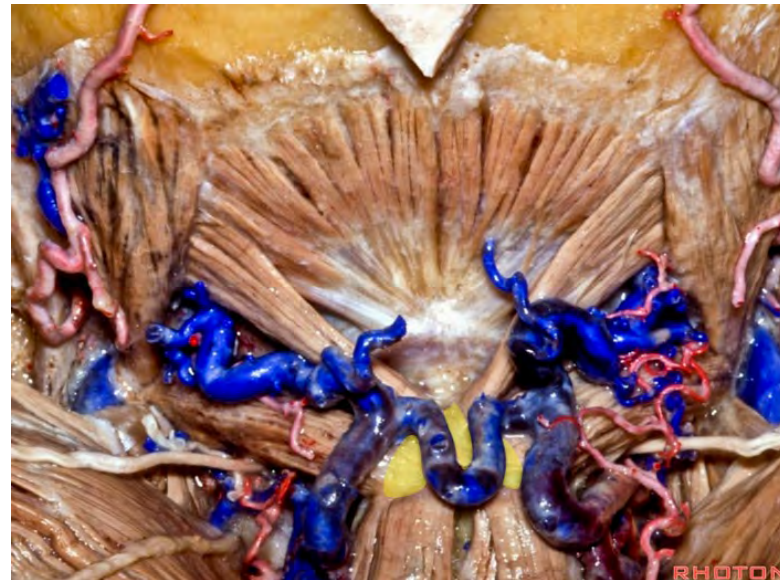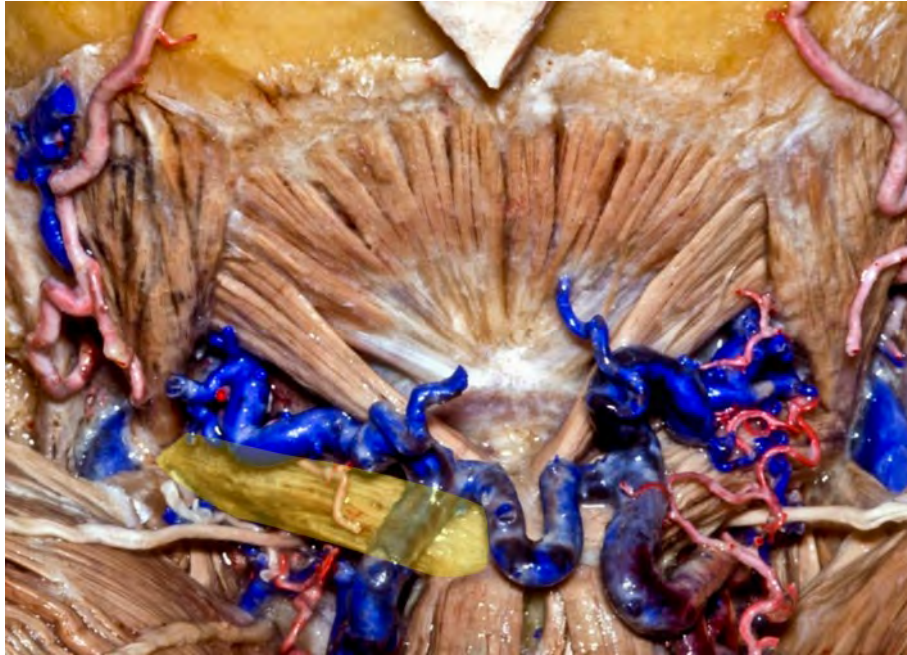**Atlas**



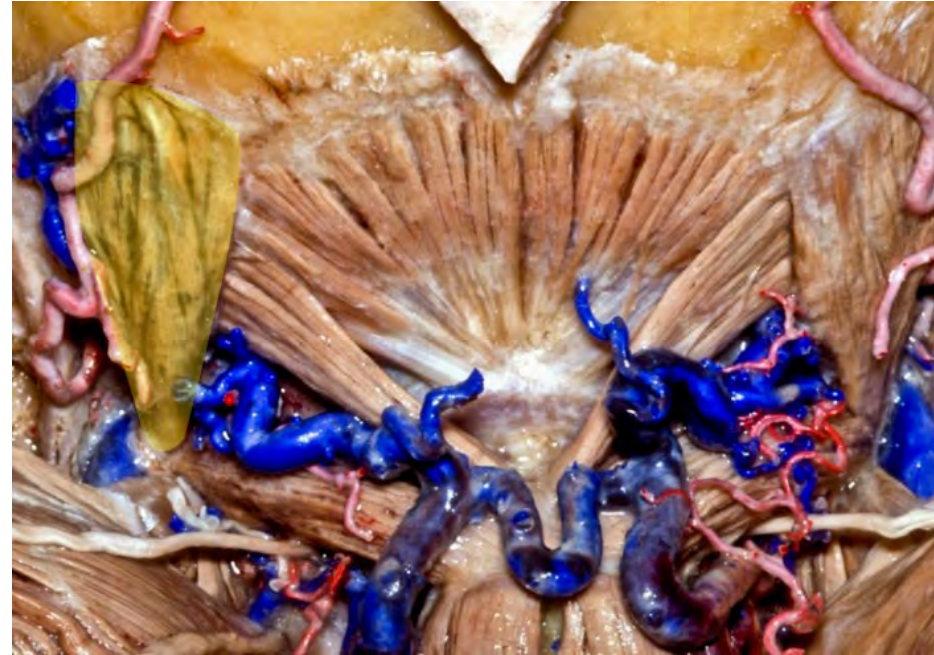**C1 transverse process**



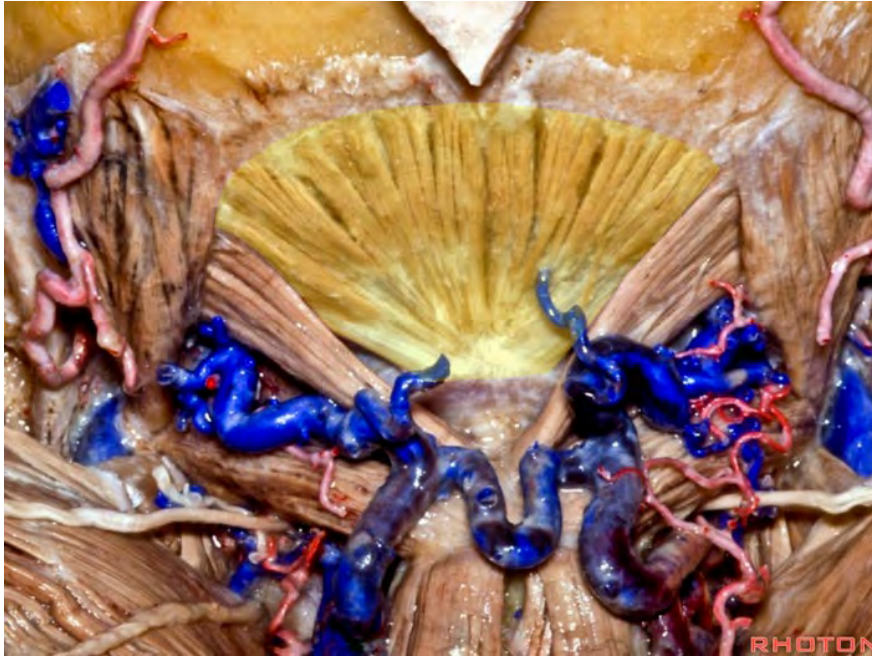
**C2 spinous process**



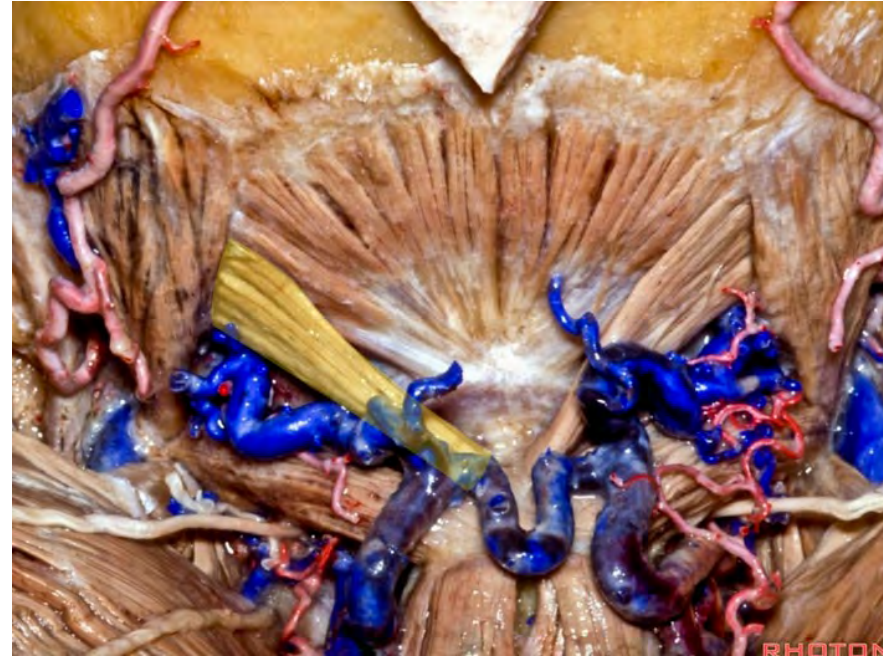**Obliquus capitis inferior**



**Obliquus capitis superior**

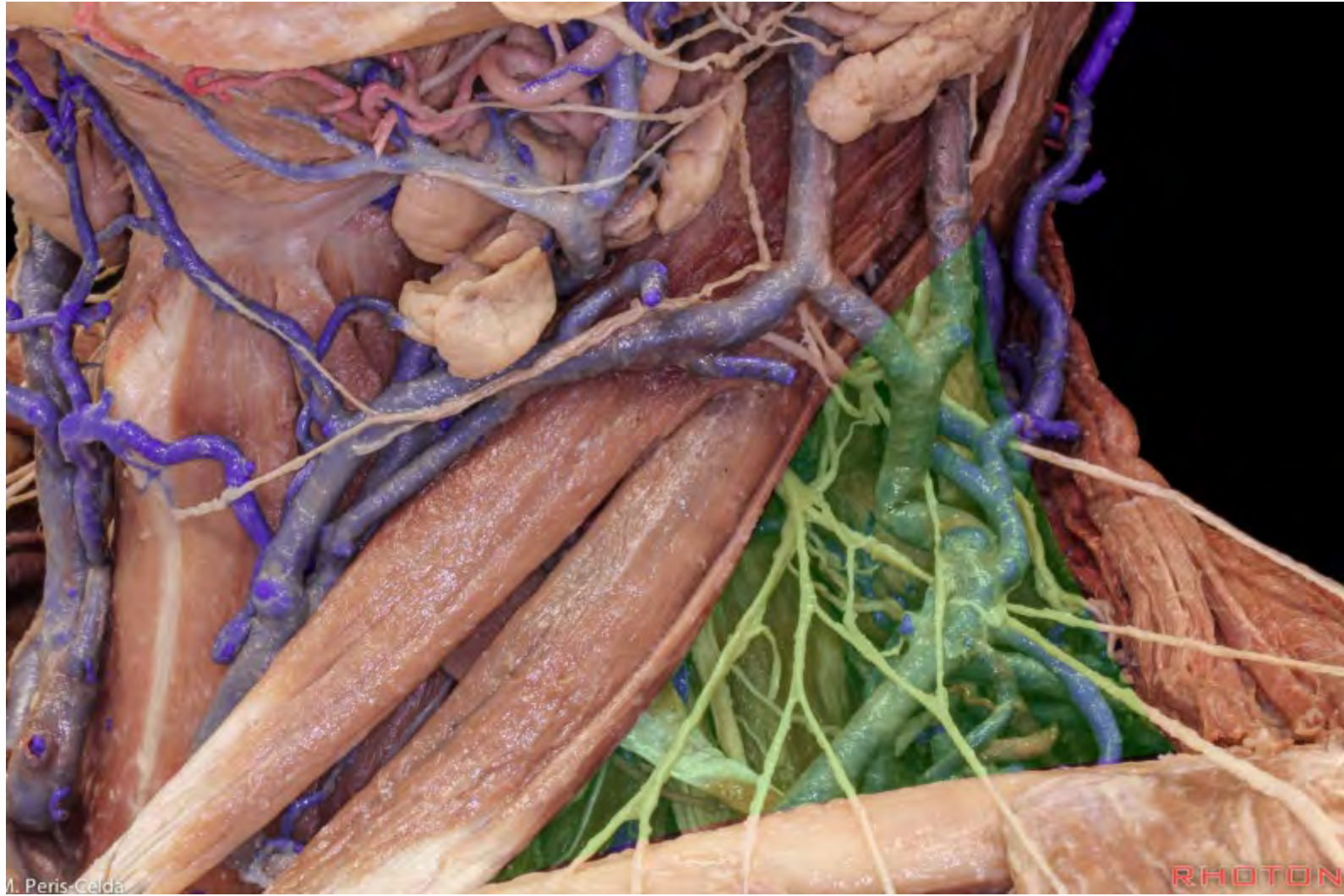

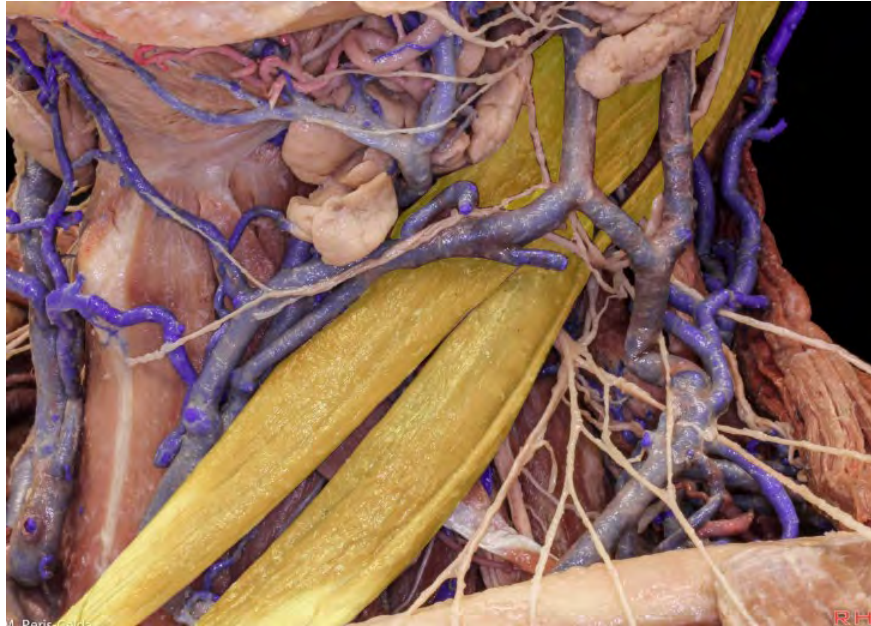**Rectus capitis posterior minor**



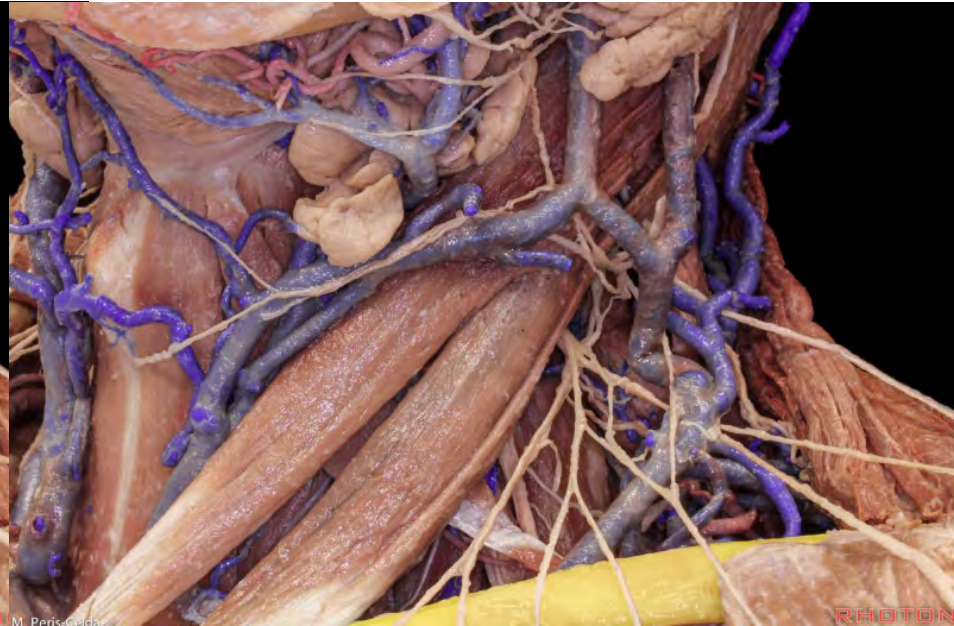**Rectus capitis posterior major**







**Sternocleidomastoid**

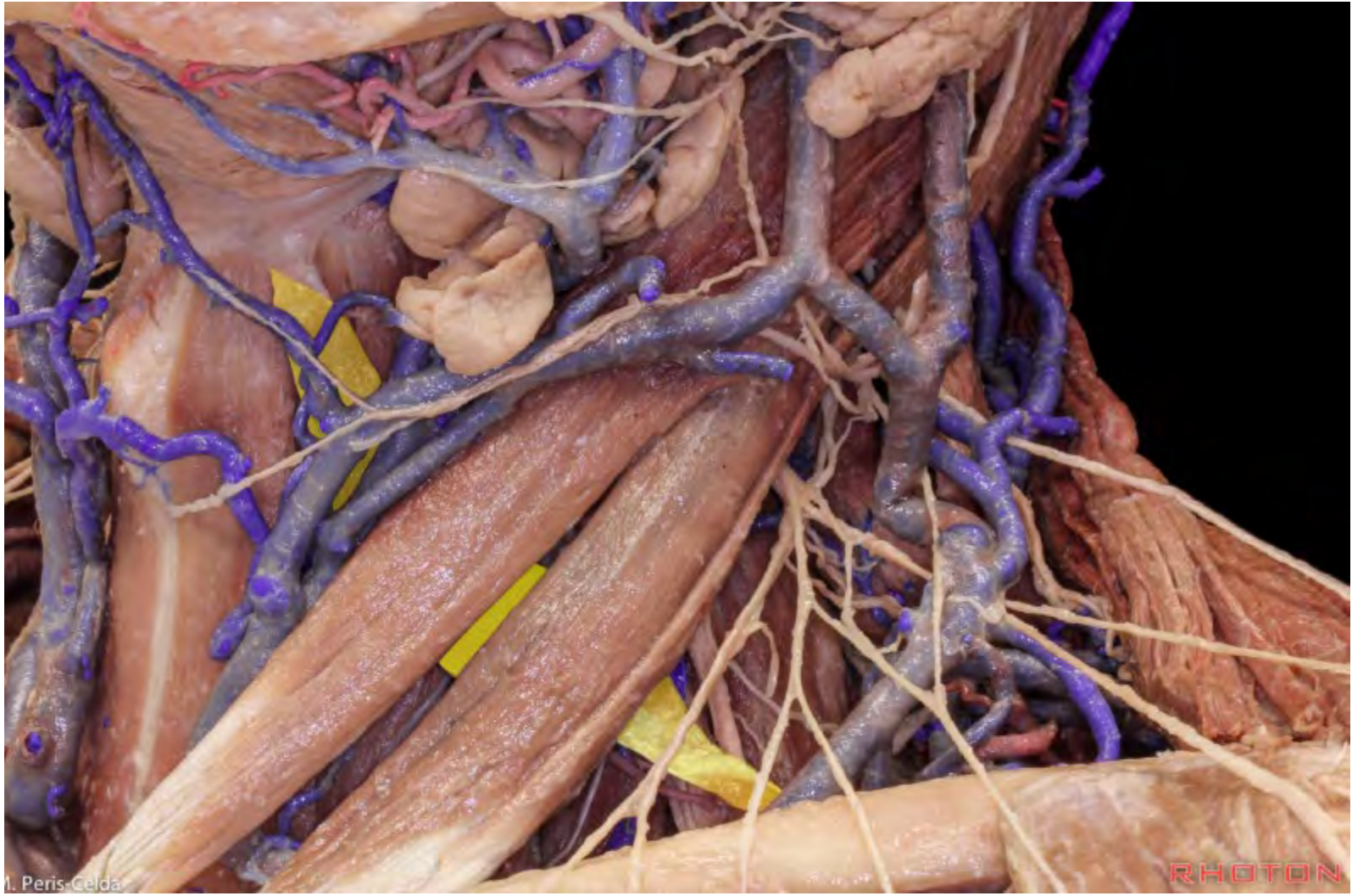

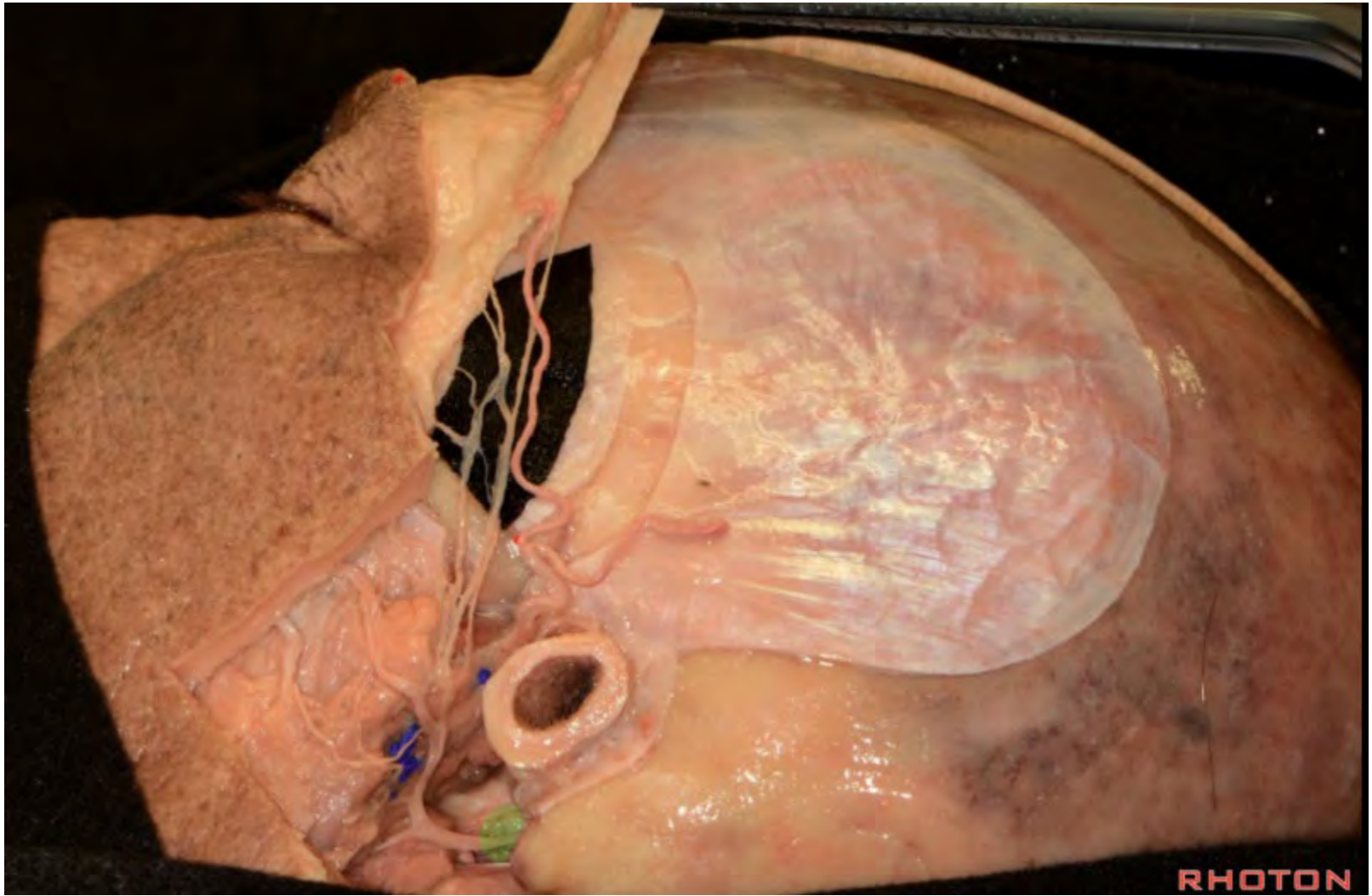
**Clavicle**



**Trapezius**







RHOTON



